



HAL
open science

Risk Factors for Incomplete Aortic Remodeling With Stent-Assisted Balloon-Induced Intimal Disruption and Relamination in Aortic Dissection Repair for Complicated Aortic Dissection: Results of a Multicenter Study

Fabien Vecchini, Gautier Hauptert, Anna Baudry, Julien Mancini, Lucie Dumur, Robert Martinez, Philippe Piquet, Jean Picquet, Marine Gaudry

► To cite this version:

Fabien Vecchini, Gautier Hauptert, Anna Baudry, Julien Mancini, Lucie Dumur, et al.. Risk Factors for Incomplete Aortic Remodeling With Stent-Assisted Balloon-Induced Intimal Disruption and Relamination in Aortic Dissection Repair for Complicated Aortic Dissection: Results of a Multicenter Study. *Journal of endovascular therapy*, 2022, 31 (1), pp.69-79. <10.1177/15266028221111984>. <inserm-04999045>

HAL Id: inserm-04999045

<https://inserm.hal.science/inserm-04999045v1>

Submitted on 14 Apr 2025

HAL is a multi-disciplinary open access archive for the deposit and dissemination of scientific research documents, whether they are published or not. The documents may come from teaching and research institutions in France or abroad, or from public or private research centers.

L'archive ouverte pluridisciplinaire HAL, est destinée au dépôt et à la diffusion de documents scientifiques de niveau recherche, publiés ou non, émanant des établissements d'enseignement et de recherche français ou étrangers, des laboratoires publics ou privés.



HAL Authorization

1 Risk factors for incomplete aortic remodeling with the Stent-assisted balloon-induced intimal
2 disruption and relamination in aortic dissection repair for complicated aortic dissection:
3 Results of a multicenter study

4

5 Fabien Vecchini ^{1, 2}, Guillaume Hauptert ³, Anna Baudry ⁴, Julien Mancini ⁶, Lucie Dumur ³,
6 Robert Martinez ³, Philippe Piquet ^{1, 2}, Jean Picquet ⁴, Marine Gaudry ^{1, 2, 8}

7

8 1. Department of Vascular Surgery, APHM, Timone Hospital, 13005, Marseille,
9 France

10 2. Aortic Center, APHM, Timone Hospital, 13005, Marseille, France

11 3. Department of Vascular Surgery, Tours Academic Center

12 4. Department of Vascular Surgery, Angers Academic Center

13 5. Aix-Marseille Université, CNRS, Ecole Centrale Marseille, IRPHE UMR 7342,
14 13384 Marseille, France. Email address: valerie.deplano@univ-amu.fr

15 6. Aix-Marseille Univ, APHM, INSERM, IRD Biostatistics Department, SESSTIM,
16 BIOSTIC, 13005, Marseille, France

17 7. Department of Radiology, APHM, Timone Hospital, 13005, Marseille, France

18

19 Corresponding author: Marine Gaudry

20 Phone: +33491388120/FAX: +33491388130

21 Email: marine.gaudry@ap-hm.fr

22 Word count: 3296

23 Original manuscript

24 All patients included in this study were clearly informed of the use of their data for clinical
25 research, but we didn't get their written consent, since the institutional review board didn't
26 require it.

27 IRB approval number: 2020-130 on October 14th 2020

28 **Funding:** None.

29 **Disclosures:** None.

30 **Abbreviations**

31 AD = Aortic dissection

32 STABILISE = Stent-assisted balloon-induced intimal disruption and relamination in aortic
33 dissection repair

34 TEVAR = Thoracic endovascular aortic repair

35 TAA= Thoracoabdominal aorta

36 CT = Computed tomography

37 FL= False lumen

38 TL= True lumen

39 SA = Supra-aortic

40 IA = Innominate artery

41 LCC = Left common carotid

42 LSA = Left subclavian artery

43 CFD = Cerebrospinal fluid drainage

44 CI = Confidence interval

45

46 **Central picture legend:** Incomplete reapposition of intimal flap and increase in diameter at
47 the bare-stent level.

48

49 **Central message**

50 Incomplete reapposition of the intimal flap, more frequent in chronic aortic dissection and
51 severe aortic angulation, after STABILISE is a risk factor for an increase diameter at the bare-
52 stent level.

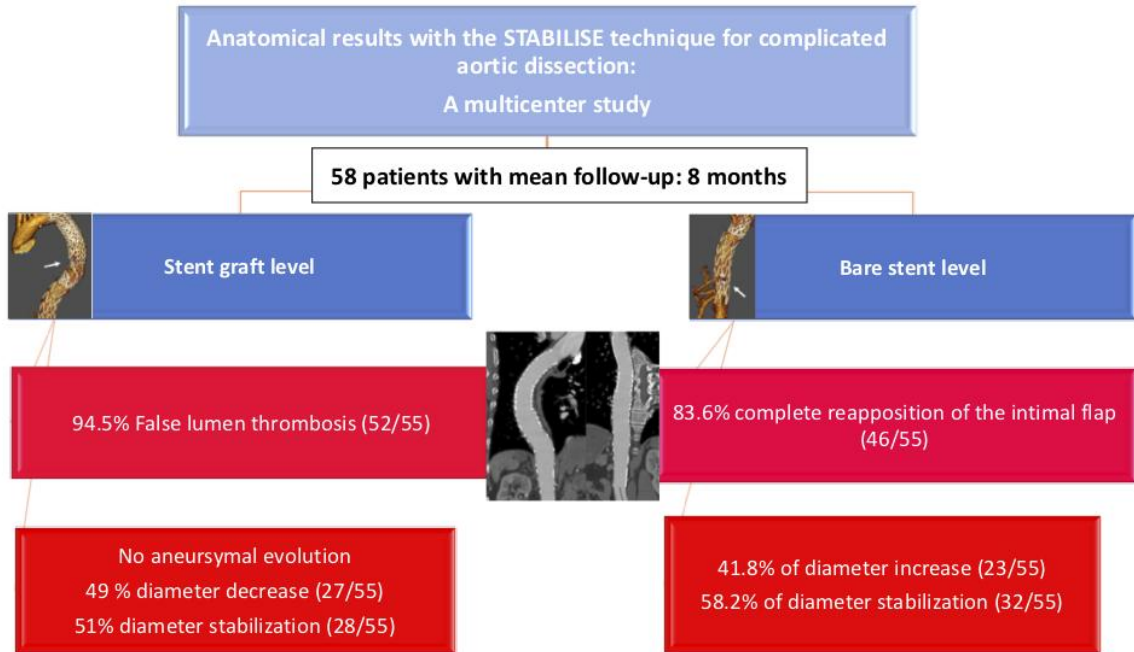
53

54 **Perspective statement**

55 STABILISE for aortic dissection results in false lumen thrombosis, complete reapposition of
56 the intimal flap and a decrease in the maximum aortic diameter in most cases. At the bare-
57 stent level, an increase in the aortic diameter justifies close follow-up and better patient
58 selection; thus, the STABILISE technique should be used with care in chronic aortic
59 dissection and severe aortic angulation.

60 **Graphical abstract**

61



62

63 **ABSTRACT**

64 **Objectives** The STABILISE technique has extended the treatment of aortic dissection to the
65 thoracoabdominal aorta to achieve complete aortic remodeling.

66 The aim of this multicenter study was to analyze the short- and midterm anatomical results of
67 the STABILISE technique.

68 **Methods** We retrospectively analyzed patients treated with the STABILISE technique for
69 complicated aortic dissection at 3 French academic centers. The aortic diameter at different
70 levels was measured preoperatively, postoperatively and at the last follow-up.

71 **Results** Between 2018 and 2020, 58 patients (33, 12 and 13 patients at the Marseille, Angers
72 and Tours centers, respectively), including 47 men (average patient age: 60 ± 11 years), were
73 treated for type B aortic dissection in 34 cases and residual aortic dissection after type A
74 repair in 24 cases. Three (5.2%) patients died postoperatively. Complete aortic remodeling
75 (false lumen thrombosis and complete reapposition of the intimal flap) was achieved in 46/55
76 patients (83.6%), and false lumen thrombosis in the thoracic aorta was achieved in 52/55
77 patients (94.5%). After a one-year follow-up of (mean 10 ± 5 months), with a late computed
78 tomography scan available for 98.2% (54/55) of patients, we observed a significant decrease
79 in the maximal thoracic aortic diameter and a significant increase in the aortic diameter at the
80 bare-stent level compared to the preoperative CT scan. Severe aortic angulation ($p=.045$) was
81 a risk of incomplete aortic remodeling and significant increase aortic diameter ($p=.024$).
82 Chronic aortic dissection was associated with an increased risk of incomplete aortic
83 remodeling ($p=.002$).

84 **Conclusions** STABILISE for complicated aortic dissection results in false lumen thrombosis,
85 complete reapposition of the intimal flap and a decrease in the maximum aortic diameter in
86 most cases. Incomplete reapposition of the intimal flap, which is more frequent in cases of
87 chronic AD and severe aortic angulation, is a risk factor for a significant increase in the aortic

88 diameter at the bare-stent level, and this risk justifies close follow-up and better patient
89 selection.

90

91 **Keywords:** STABILISE technique, aortic dissection, TEVAR, anatomical results, aneurysm
92 evolution, risk factors

93 **INTRODUCTION**

94 Aortic dissection (AD) is a life-threatening disease that is very challenging to treat (1).
95 Thoracic endovascular aortic repair (TEVAR) has emerged as the first-line therapy for the
96 treatment of AD, with better short-term results than open repair due to a significant decrease
97 in perioperative morbidity and mortality (2–5). The long-term results remain controversial,
98 with a high rate of type IB endoleak linked to distal stent-graft–induced new entry tears and a
99 persistent patent false lumen (FL). Moreover, the thoracoabdominal aorta (TAA) cannot be
100 simply treated with a standard stent graft, with a risk of long-term aneurysm evolution of 20-
101 40% and a risk of reintervention near 60% (6).

102 The stent-assisted balloon-induced intimal disruption and relamination in AD repair
103 (STABILISE) technique offers a preventive treatment for AD in the TAA, with encouraging
104 short-term results previously reported for acute, subacute and chronic AD (7–9). This strategy
105 has the potential to achieve complete repair of the dissected aorta with complete aortic
106 remodeling, including thoracoabdominal FL obliteration and relamination with intimal flap
107 reapposition, as well as improved long-term outcomes, reducing the need for future complex
108 reintervention at the distal TAA.

109 However, this new technique must be evaluated to confirm that the initial good anatomical
110 results are maintained during follow-up without a significant increase in diameter or the need
111 for reintervention.

112 Finally, improving indications for treatment with the STABILISE technique by identifying
113 risk factors for treatment failure and incomplete aortic remodeling will improve the
114 management and results of the technique.

115 The aim of this multicenter study was to report the short- and midterm results of the
116 STABILISE technique and to analyze the anatomical results at the stent-graft and bare-stent
117 levels and the risk of treatment failure.

118

119 **METHODS**

120 **Population**

121 All patients included in this study were clearly informed about the use of their data for clinical
122 research. Additionally, they were aware that their data would be used anonymously for
123 research purposes. The institutional review board approved the project (N°2020-130 on
124 October 14th 2020) and waived the requirement of informed consent for the use of the
125 patients' medical data for this study.

126 In this multicenter retrospective cohort study, we included all patients who underwent a
127 STABILISE procedure for complicated AD at 3 French academic hospitals (CHU Timone,
128 CHU Angers, and CHU Tours).

129 The inclusion criteria for the STABILISE procedure were malperfusion syndrome,
130 uncontrolled pain, uncontrolled hypertension, rapid aortic growth or aneurysm evolution (>
131 10 mm/year or an aortic diameter > 55 mm), and aortic rupture.

132 The exclusion criteria were complete FL thrombosis, an abdominal aortic diameter > 42 mm
133 (where the bare stent should be deployed), and/or no adequate distal landing zone < 42 mm in
134 diameter in a 20-mm-long segment above the celiac trunk for the proximal stent graft.

135 We retrospectively collected data regarding demographic, clinical and anatomical
136 characteristics of patients treated with the STABILISE technique.

137 **Perioperative management**

138 All cases were discussed in a multidisciplinary meeting composed of vascular surgeons,
139 cardiac surgeons, interventional radiologists, cardiologists, and anesthesiologists.

140 For patients with residual AD (after type A repair), in the case of total arch replacement
141 combined with stented (or frozen) elephant trunk implantation, the stent graft was deployed in
142 the stented elephant trunk with a minimum overlap of 5 cm.

143 For all other patients, including patients with type B AD or residual AD with ascending or
144 hemiarch replacement during type A repair, hybrid treatment with thoracic endovascular
145 aortic repair (TEVAR) and open supra-aortic debranching to ensure a proximal landing zone
146 > 20 mm remained the first-line therapy.

147 Supra-aortic debranching and TEVAR were performed in at least two steps.

148 Zone 0 debranching was performed using a prosthetic bypass between the ascending aortic
149 replacement, the innominate artery, the left common carotid artery and the left subclavian
150 artery through a median sternotomy.

151 In cases of previous innominate artery debranching (during type A repair), we performed
152 intrathoracic debranching without cardiopulmonary bypass with direct or indirect
153 reimplantation of the left common carotid artery.

154 Zone 1 debranching was performed using an intercarotid prosthetic bypass with
155 reimplantation of the left subclavian artery or with left subclavian artery debranching
156 alone in the case of a bovine arch anatomy.

157 Zone 2 debranching was performed by direct or indirect left subclavian artery reimplantation
158 through a left supraclavicular incision when the residual dissection did not involve the aortic
159 arch.

160 In some cases of contraindications to open repair, complete endovascular treatment was
161 performed with fenestrated or branched endoprostheses.

162 **TEVAR**

163 TEVAR was performed under general anesthesia in a multimodal angiographic suite
164 (Discovery IGS 730, GE Healthcare, Chicago, USA). Transesophageal ultrasound was
165 systematically used to ensure correct positioning of the guide in the true lumen (TL).

166 Stent grafts were advanced and deployed using standard techniques. We used the following
167 two stent grafts: the C-TAG stent graft (WL Gore & Associates, Inc., Flagstaff, AZ) and the
168 Valiant Navion stent graft (Medtronic, Santa Rosa, CA).

169 The decision to extend the proximal landing zone was based on the location of the primary
170 entry tear (aortic arch or descending thoracic aorta).

171 The stent-graft size was determined by measuring the diameter of the proximal and distal
172 landing zones on an orthogonal view of the total aorta using centerline reconstruction on
173 computed tomography (CT). The diameter of the stent graft was sized based on both the TL
174 and the FL within the descending thoracic aorta. Proximal oversizing of 10 % for native aorta
175 and 20% for graft aorta replacement, and distal oversizing of 10% were performed.

176 Cerebrospinal fluid drainage was performed when there was extensive coverage of the
177 thoracic aorta with stent graft (> 250 mm) in the absence of contraindications. Systematic
178 revascularization of left subclavian artery was performed to prevent the risk of spinal cord
179 ischemia.

180

181 **STABILISE technique**

182 We added bare-stent deployment in the TAA to induce remodeling of the distal dissected
183 aorta according to the STABILISE technique, as described by Faure et al. (8,9).

184 The distal part of the stent graft should end up in an area where the diameter does not exceed
185 42 mm over a length of at least 20 mm. When feasible, proximal stent-graft coverage should
186 usually extend 100 to 150 mm above the celiac trunk to preserve intercostal arteries.

187 *Distal aortic bare-stent deployment*

188 The Zenith dissection endovascular stent (ZDES; Cook Medical, Bloomington, IN) was
189 deployed with a 1-stent body overlap in the stent graft and extension as far as the infrarenal
190 aorta. The 36-mm-diameter ZDES was used in the case of a maximum external aortic

191 diameter up to 32 mm, and the 46-mm-diameter ZDES was used in the case of a maximum
192 external aortic diameter between 32 and 42 mm.

193 *Management of visceral arteries*

194 In cases of visceral or renal branches arising from the FL or signs of static malperfusion on
195 preoperative CT scans, we catheterized the targeted vessels before inflating the balloon.

196

197 *Balloon dilatation of the bare stent*

198 Subsequently, a trilobed balloon catheter (WL Gore & Associates, Inc., Flagstaff, AZ) was
199 inserted. Between the distal end of the stent graft and the proximal end of the ZDES, balloon
200 expansion was performed to the point of intimal flap disruption, leading to reapposition of the
201 intimal flap on the aortic wall. In the event of visceral or renal artery malperfusion, a
202 collateral bare stent was deployed.

203 Balloon pressures range from 1 to 2 atmospheres with manual inflation to reach
204 approximately the total aortic size (guided by image fusion), to enable intimal disruption
205 without applying this pressure to the outer aortic wall. In cases of uncomplete flap
206 reapposition, the balloon was not reinflated more than once

207

208 **Radiological analysis**

209 All patients underwent a postoperative CT scan before discharge, at 3 and 6 months
210 postoperatively and annually thereafter. Scan image analysis and measurements were
211 performed by 2 independent vascular surgeons using three-dimensional (3D) imaging
212 software (OsiriX software, Geneva, Switzerland). Diameter measurements were performed on
213 the perpendicular axis according to the centerline using a semiautomated centerline algorithm
214 preoperatively, postoperatively and on the last available CT scan during follow-up at the 6

215 different levels (Figure 1). Angulation was also measured preoperatively on 3D CT
216 reconstructions at the level of the aortic arch and at the level of the thoracoabdominal junction
217 by defining a point upstream and downstream of the angulation in a rectilinear zone and
218 measuring the angle between these two points.

219

220 **Endpoints**

221 FL patency was assessed as FL enhancement anywhere in the downstream aorta on arterial or
222 venous-phase CT. The FL was also considered patent if only partial thrombosis was observed,
223 while disappearance of the FL was considered to indicate complete FL thrombosis.

224 A significant increase in diameter at the end of follow-up was defined as aortic growth > 5
225 mm.

226 Complete aortic remodeling was defined as FL thrombosis in the thoracic aorta and complete
227 reposition of the intimal flap on the aortic wall at the bare-stent level (Figure 2).

228 Incomplete aortic remodeling in the TAA was defined as incomplete reposition of the FL
229 without relamination of the intimal flap.

230

231 **Statistical analysis**

232 Data are presented as the mean \pm standard deviation or median (Q1, Q3) for continuous
233 variables and as counts (%) for categorical data. The normality of the distribution of variables
234 was assessed with the Shapiro-Wilk test. For categorical variables, the relationship between
235 variables was studied using the chi-square test or Fisher's exact test, as appropriate. The
236 Mann-Whitney U test was used to compare continuous variables in subgroups. Repeated-
237 measures ANOVA was used to study the changes in diameters at postoperative and one-year
238 follow-up adjusting for center. All statistical analyses were performed using IBM SPSS
239 Statistics 20.0 (IBM, Inc., New York, USA).

240

241

242 **RESULTS**

243 **Population**

244 Between August 2018 and July 2020, 58 patients (33, 12 and 13 patients at the Marseille,
245 Angers and Tours centers, respectively), including 47 men (average age: 60 ± 11 years), were
246 treated with STABILISE for type B AD in 34 cases and residual AD after type A repair in 24
247 cases.

248 The median interval between the onset of acute symptoms and the procedure was 298 ± 566
249 days (0-3110).

250 Eleven patients were treated during the acute phase (< 14 days), 22 during the subacute phase
251 (14-90 days) and 25 during the chronic phase (> 90 days). Indications for treatment and
252 demographic data are described in Table 1.

253

254 **Perioperative results**

255 Procedural details are presented in Table 2.

256 Three patients (5.2%) died postoperatively. All deaths occurred in patients who underwent
257 emergency treatment for complicated acute AD (2 cases of aortic rupture and 1 case of
258 malperfusion syndrome).

259 In one case of aortic rupture in acute type B AD without perioperative complications, the
260 patient died on the thirteenth postoperative day.

261 In one case of aortic rupture in acute type A AD treated with hemiarch replacement + supra-
262 aortic debranching and TEVAR-STABILISE, the patient died at the time of balloon inflation.

263 In one case of malperfusion syndrome (cerebral and mesenteric malperfusion) in acute type A
264 AD treated with hemiarch replacement + supra-aortic debranching and TEVAR-STABILISE,
265 the patient died on day 3 secondary to pulmonary sepsis with multiple-organ failure.

266 There were 2 cases of stroke (3.4%) (1 minor stroke without sequelae and another with
267 subsequent hemiparesis). There was 1 case of postoperative spinal cord ischemia (1.7%) in a
268 patient with acute type B AD with malperfusion syndrome; this patient underwent emergent
269 treatment with coverage of the left subclavian artery using a 26-cm-long stent graft. Complete
270 recovery was achieved using cerebrospinal fluid drainage.

271 In 2 patients (3.4%), perioperative acute superior mesenteric artery (SMA) dissection
272 occurred after balloon inflation; in 1 patient, treatment was performed with a proximal stent in
273 the SMA, and in the other patient, with distal dissection, medical treatment was performed
274 with curative anticoagulation.

275 There were 5 patients with renal infarct (8.6%) on preoperative CT, with a postoperative
276 increase in the creatinine level in all patients; complete regression occurred in 4 patients, and
277 none of the patients required dialysis. There were no renal complications due to the
278 STABILISE procedure.

279 There were 8 cases of early reintervention (Supplemental Table 1).

280 There were 5 cases of late reintervention (Supplemental Table 2).

281

282 **Postoperative anatomical results (Table 3)**

283 Complete aortic remodeling (FL thrombosis and complete reapposition of the intimal flap)
284 was achieved in 46/55 patients (83.6%), and FL thrombosis in the thoracic aorta was obtained
285 in 52/55 patients (94.5%) (Figure 2).

286 There was 1 case of type IA endoleak; the patient was treated emergently after type A repair
287 for malperfusion syndrome without coverage of the main entry tear at the distal anastomosis
288 of the previous ascending aorta replacement.

289 There were 2 cases of type II endoleak from intercostal arteries.

290 There were 9 cases of incomplete reapposition of the intimal flap with a remaining short
291 segment of patent FL at the bare-stent level.

292 There was a significant increase in the aortic diameter on CT from preoperatively to
293 postoperatively at the three bare-stent levels (see Figure 1) as follows: 31.8 ± 4.4 mm, $26.4 \pm$
294 4.9 mm and 25.5 ± 5.0 mm to 32.8 ± 4.4 mm ($p < .01$), 27.4 ± 5.2 mm ($p < .01$) and 26.4 ± 5.0
295 mm ($p < .01$) (Figure 3A).

296

297 **Follow-up results**

298 After a mean follow-up of 8 ± 6 months, with a late CT scan available for 85.4% (47/55) of
299 patients, the results were as follows:

300 There was a significant decrease in the maximal thoracic aortic diameter at the stent-graft
301 level (48.6 ± 10.4 mm to 41.2 ± 8.1 mm; $p < .01$) (Figure 3A). We observed regression of the
302 aortic diameter in 49% (27/55) of patients and stabilization in 51% (28/55) of patients.

303 There was a significant increase in diameter at the bare-stent level (31.7 ± 4.4 mm to $34.3 \pm$
304 4.2 mm; $p < .01$) (Figure 3B). We observed a significant increase in the aortic diameter in
305 41.8% (23/55) of patients and stabilization in 58.2% (32/55) of patients.

306

307 **Risk factors for significant aortic diameter increase and incomplete aortic remodeling at** 308 **the bare stent level**

309 Incomplete aortic remodeling at the bare-stent level was significantly associated with a risk of
310 a significant increase in diameter (78% (7/9) vs 35% (16/46), $p = .028$).

311 Severe aortic angulation at the bare-stent level was significantly associated with an increased
312 risk of incomplete aortic remodeling (116° versus 65° , $p = .045$) and a significant increase in
313 diameter (96° versus 58° , $p = .024$) (Figure 4).

314 Residual AD (after type A repair) was significantly associated with an increased risk of

315 incomplete aortic remodeling compared to type B AD (36% (8/22) vs 3% (1/33), $p = 0.002$).

316 There were significantly more cases of chronic AD in the residual AD group than in the type
317 B AD group (70.8% (17/24) vs 23.5% (8/34), $p < .001$).

318

319 **DISCUSSION**

320 In the first multicenter study of its kind, we report the short- and midterm results of the
321 STABILISE technique in 58 patients with type B AD.

322 In the present study, the STABILISE technique provided excellent short- and midterm
323 anatomical results, with complete aortic remodeling in 84% of patients, FL thrombosis in
324 94.5% of patients, and a decrease in or stabilization of the thoracic aortic diameter. Similarly,
325 Faure et al reported 100% FL thrombosis at the stent-graft level and 100% complete aortic
326 remodeling in acute dissection.

327 TEVAR alone fails to prevent aneurysm development at the level of the thoracic aorta in most
328 cases, with FL thrombosis achieved in only 10 to 30% of cases (10–15).

329 The STABLE technique (proximal stent grafting with distal bare stenting) yields better results
330 than TEVAR alone (16–18), with reexpansion of the TL and reduction of the FL (19,20).
331 However, FL thrombosis in the thoracic aorta is achieved in only 30 to 60% of cases (19)
332 (20), and Sobocinski et al observed a significant increase in the volume of the abdominal
333 aorta at 12 months (21).

334 Despite the good initial anatomical results of the STABILISE technique, the incidence of a
335 significant increase in diameter on CT at the bare-stent level from preoperatively to
336 postoperatively and during follow-up was 42%. This finding suggests that such increases in
337 diameter are linked to the operating technique (the self-expanding stent continued to conform
338 within the arterial wall, becoming fragile due to forced aortic remodeling) and to the natural
339 evolution of AD. Indeed, more than 60% of patients with AD, regardless of the initial
340 treatment modality, develop aneurysm growth in the 5 years following the procedure (22).,
341 All patients were treated for complicated AD, more often aneurysmal evolution (52% of
342 cases) that is a well-known complication of type B and residual AD, in approximately 50 %
343 of cases. In type B AD preemptive TEVAR in cases of poor anatomical risk factor is a grad

344 IIB recommendation. For residual AD, A more aggressive primary operation with total aortic
345 arch repair or frozen elephant trunk would be beneficial with respect to long-term results.
346 However, ascending aorta or hemiarch replacement remains the most commonly used surgical
347 procedure in most centers because of a lower perioperative mortality risk. The Ascyrus
348 Medical Dissection Stent (a hybrid uncovered stent) could modify the future, inducing
349 relamination of the intimal flap of the aortic arch, and could decrease the aneurysmal
350 evolution risk or promote easier management of these complex patients.

351 The inclusion of all patients with complicated AD treated with the STABILISE technique at 3
352 academic French centers allows the analysis of prognostic criteria, and for the first time, we
353 identified risk factors for failure of the STABILISE technique and an increase in the aortic
354 diameter at the bare-stent level. Incomplete reapposition of the intimal flap at the bare-stent
355 level was significantly associated with a risk of a significant increase in diameter. Chronic
356 AD seems to be associated with an increased risk of incomplete aortic remodeling at the bare-
357 stent level. Indeed, we found that residual AD was significantly associated with this risk of
358 negative results and was directly linked to the large number of chronic AD cases in this group
359 (70.8% vs 23.5%, $p < .01$). During the chronic phase, the intimal flap is stiffer, and disruption
360 by balloon inflation is more difficult, which could explain the better results observed in acute
361 and subacute AD. In the literature, the results of the STABILISE technique for chronic AD
362 are reportedly worse than those for acute and subacute AD (23)(24). Hofferberth et al
363 reported the first series, with only 1 case of failure in the TAA in a patient treated for chronic
364 AD (25). Faure et al reported 100% FL thrombosis at the level of the stent graft in 17 chronic
365 type B AD patients but only 88% at the bare-stent level (9), whereas in their experience with
366 41 acute type B AD patients, complete aortic remodeling was obtained (7).

367 In addition, we observed that aortic angulation ($>90^\circ$) at the bare-stent level was a significant
368 risk factor for incomplete aortic remodeling and a significant increase in diameter during

369 follow-up. This could be linked to incomplete reapposition of the intimal flap in the aortic
370 angulation leading to a large new entry tear. Stent-graft–induced new entry is a well-known
371 risk factor for aneurysm evolution and is more common in chronic AD and when the distal
372 oversizing of the graft stent is > 20% (26).

373 Finally, we believe that a large bare-stent diameter yields improved results by increasing
374 complete reapposition of the intimal flap and reducing aneurysm evolution. The bare stent
375 used here had a low radial force, so oversizing remained safe but was useful in increasing the
376 effect of the stent on the aortic wall.

377 In the case of high risk of incomplete aortic remodeling, alternative should be considered:
378 candy plug, knickerbocker-technique or direct false lumen occlusion by coil, plug or glue
379 embolization.

380 Candy plug described by Kölbel et al, and Rohlffs reported 100% of technical success. Direct
381 false lumen occlusion by embolization was also described: Hofferberth et al described
382 cyanoacrylate glue and coils embolization of false lumen in 31 patients with stabilization or
383 decrease in 22 patients. Idrees et al reported false lumen occlusion by embolization with iliac
384 occluders in 21 patients.

385 Regarding the short-term results, in this study, the 30-day mortality rate was 5.2%, but all
386 deaths occurred in patients treated during the acute (n=2) or subacute (n=1) phase for
387 complicated AD. One patient died as a result of the balloon inflation, we think is better
388 avoiding the STABILISE technique at the acute phase and essential to perform the procedure
389 in a multimodal angiographic suite guided by image fusion to reach approximately the total
390 aortic size with the balloon inflation.

391 In a few other studies, the 30-day mortality rate was low, between 0 and 2%, but was also
392 increased among patients with acute AD. Spinal cord ischemia seems to be the most frequent
393 complication, occurring at a rate between 0 and 10%, and is regressive in most cases

394 (7,23,24). In our study, we observed only one case of spinal cord ischemia, and we believe
395 that limiting the coverage of the thoracic aorta and performing cerebrospinal fluid drainage in
396 cases of extensive coverage and systematic left subclavian artery revascularization would
397 prevent this complication.

398 **Limitations**

399

400 This study has several limitations, including its observational design without a comparative
401 group, small number of patients, lack of long-term follow-up and heterogeneity among
402 included patients. The multicentric nature of this study introduces heterogeneity bias but
403 makes it possible not only to confirm that the technique is safe and reproducible but also to
404 identify prognostic criteria according to the type of pathology and timing. Moreover, to
405 overcome this bias, we separated the anatomical results in 3 groups: acute, subacute and
406 chronic AD.

407

408 Studies comparing the STABILISE technique with TEVAR alone in AD are also needed to
409 confirm that immediate aortic remodeling reduces long-term aneurysm development.

410 The prospective follow-up of patients included in this study is necessary to confirm the long-
411 term good results of the STABILISE technique.

412

413 **CONCLUSION**

414

415 STABILISE for AD results in FL thrombosis, complete reapposition of the intimal flap and a
416 decrease in the maximum aortic diameter in most cases.

417 Incomplete reapposition of the intimal flap, which is more frequent in cases of chronic AD
418 and severe aortic angulation, is a risk factor for a significant increase in the aortic diameter at
419 the bare-stent level, and this risk justifies close follow-up and better patient selection.

420

421 References

- 422 1. MacKenzie KS, LeGuillan M-P, Steinmetz OK, Montreuil B. Management Trends and
423 Early Mortality Rates for Acute Type B Aortic Dissection: A 10-Year Single-Institution
424 Experience. *Ann Vasc Surg.* mars 2004;18(2):158- 66.
- 425 2. Dake MD, Kato N, Mitchell RS, Semba CP, Razavi MK, Shimono T, et al.
426 Endovascular Stent–Graft Placement for the Treatment of Acute Aortic Dissection. *N Engl J*
427 *Med.* 20 mai 1999;340(20):1546- 52.
- 428 3. Tsai TT, Fattori R, Trimarchi S, Isselbacher E, Myrmel T, Evangelista A, et al. Long-
429 Term Survival in Patients Presenting With Type B Acute Aortic Dissection: Insights From the
430 International Registry of Acute Aortic Dissection. *Circulation.* 21 nov
431 2006;114(21):2226- 31.
- 432 4. Suzuki T. Clinical Profiles and Outcomes of Acute Type B Aortic Dissection in the
433 Current Era: Lessons From the International Registry of Aortic Dissection (IRAD).
434 *Circulation.* 9 sept 2003;108(90101):312II--317.
- 435 5. Rimbau V, Böckler D, Brunkwall J, Cao P, Chiesa R, Coppi G, et al. Editor’s Choice
436 – Management of Descending Thoracic Aorta Diseases. *Eur J Vasc Endovasc Surg.* janv
437 2017;53(1):4- 52.
- 438 6. Thrumurthy SG, Karthikesalingam A, Patterson BO, Holt PJE, Hinchliffe RJ, Loftus
439 IM, et al. A Systematic Review of Mid-term Outcomes of Thoracic Endovascular Repair
440 (TEVAR) of Chronic Type B Aortic Dissection. *Eur J Vasc Endovasc Surg.* nov
441 2011;42(5):632- 47.
- 442 7. Faure EM, El Batti S, Abou Rjeili M, Julia P, Alsac J-M. Mid-term Outcomes of Stent
443 Assisted Balloon Induced Intimal Disruption and Relamination in Aortic Dissection Repair
444 (STABILISE) in Acute Type B Aortic Dissection. *Eur J Vasc Endovasc Surg.* août
445 2018;56(2):209- 15.

- 446 8. Faure EM, El Batti S, Sutter W, Bel A, Julia P, Achouh P, et al. Stent-assisted balloon-
447 induced intimal disruption and relamination of distal remaining aortic dissection after acute
448 DeBakey type I repair. *J Thorac Cardiovasc Surg.* juin 2019;157(6):2159- 65.
- 449 9. Faure EM, El Batti S, Sutter W, Bel A, Julia P, Achouh P, et al. Stent-assisted balloon
450 dilatation of chronic aortic dissection. *J Thorac Cardiovasc Surg.* févr
451 2020;S002252232030430X.
- 452 10. Kang WC, Greenberg RK, Mastracci TM, Eagleton MJ, Hernandez AV, Pujara AC, et
453 al. Endovascular repair of complicated chronic distal aortic dissections: Intermediate
454 outcomes and complications. *J Thorac Cardiovasc Surg.* nov 2011;142(5):1074- 83.
- 455 11. Mani K, Clough RE, Lyons OTA, Bell RE, Carrell TW, Zayed HA, et al. Predictors of
456 Outcome after Endovascular Repair for Chronic Type B Dissection. *Eur J Vasc Endovasc*
457 *Surg.* avr 2012;43(4):386- 91.
- 458 12. Sayer D, Bratby M, Brooks M, Loftus I, Morgan R, Thompson M. Aortic Morphology
459 Following Endovascular Repair of Acute and Chronic Type B Aortic Dissection: Implications
460 for Management. *Eur J Vasc Endovasc Surg.* nov 2008;36(5):522- 9.
- 461 13. Manning BJ, Dias N, Ohrlander T, Malina M, Sonesson B, Resch T, et al.
462 Endovascular Treatment for Chronic Type B Dissection: Limitations of Short Stent-Grafts
463 Revealed at Midterm Follow-up. *J Endovasc Ther.* oct 2009;16(5):590- 7.
- 464 14. Scali ST, Feezor RJ, Chang CK, Stone DH, Hess PJ, Martin TD, et al. Efficacy of
465 thoracic endovascular stent repair for chronic type B aortic dissection with aneurysmal
466 degeneration. *J Vasc Surg.* juill 2013;58(1):10-17.e1.
- 467 15. Famularo M, Meyermann K, Lombardi JV. Aneurysmal degeneration of type B aortic
468 dissections after thoracic endovascular aortic repair: A systematic review. *J Vasc Surg.* sept
469 2017;66(3):924- 30.
- 470 16. Canaud L, Patterson BO, Peach G, Hinchliffe R, Loftus I, Thompson MM. Systematic

- 471 review of outcomes of combined proximal stent grafting with distal bare stenting for
472 management of aortic dissection. *T J Thorac Cardiovasc Surg.* juin 2013;145(6):1431- 8.
- 473 17. Sobocinski J, Dias NV, Hongku K, Lombardi JV, Zhou Q, Saunders AT, et al.
474 Thoracic endovascular aortic repair with stent grafts alone or with a composite device design
475 in patients with acute type B aortic dissection in the setting of malperfusion. *J Vasc Surg.* févr
476 2020;71(2):400-407.e2.
- 477 18. Kische S, D'Ancona G, Belu IC, Stoeckicht Y, Agha U, Ortak J, et al. Perioperative
478 and mid-term results of endovascular management of complicated type B aortic dissection
479 using a proximal thoracic endoprosthesis and selective distal bare stenting. *Eur J Cardiothorac*
480 *Surg.* oct 2015;48(4):e77- 84.
- 481 19. Lombardi JV, Cambria RP, Nienaber CA, Chiesa R, Teebken O, Lee A, et al.
482 Prospective multicenter clinical trial (STABLE) on the endovascular treatment of complicated
483 type B aortic dissection using a composite device design. *J Vasc Surg.* mars 2012;55(3):629-
484 640.e2.
- 485 20. Alsac J-M, Girault A, El Batti S, Abou Rjeili M, Alomran F, Achouh P, et al.
486 Experience of the Zenith Dissection Endovascular System in the emergency setting of
487 malperfusion in acute type B dissections. *J Vasc Surg.* mars 2014;59(3):645- 50.
- 488 21. Sobocinski J, Lombardi JV, Dias NV, Berger L, Zhou Q, Jia F, et al. Volume analysis
489 of true and false lumens in acute complicated type B aortic dissections after thoracic
490 endovascular aortic repair with stent grafts alone or with a composite device design. *J Vasc*
491 *Surg.* mai 2016;63(5):1216- 24.
- 492 22. Lombardi JV, Hughes GC, Appoo JJ, Bavaria JE, Beck AW, Cambria RP, et al.
493 Society for Vascular Surgery (SVS) and Society of Thoracic Surgeons (STS) reporting
494 standards for type B aortic dissections. *J Vasc Surg.* mars 2020;71(3):723- 47.
- 495 23. Melissano G, Bertoglio L, Rinaldi E, Mascia D, Kahlberg A, Loschi D, et al.

- 496 Satisfactory short-term outcomes of the STABILISE technique for type B aortic dissection. J
497 Vasc Surg. oct 2018;68(4):966- 75.
- 498 24. Kahlberg A, Mascia D, Bertoglio L, Loschi D, Grandi A, Melissano G, et al. New
499 technical approach for type B dissection: from the PETTICOAT to the STABILISE concept. J
500 Cardiovasc Surg [Internet]. mai 2019;60(3).
- 501 25. Hofferberth SC, Nixon IK, Boston RC, McLachlan CS, Mossop PJ. Stent-Assisted
502 Balloon-Induced Intimal Disruption and Relamination in Aortic Dissection Repair: The
503 STABILISE concept. J Thorac Cardiovasc Surg. avr 2014;147(4):1240- 5.
- 504 26. Canaud L, Gandet T, Sfeir J, Ozdemir BA, Solovei L, Alric P. Risk factors for distal
505 stent graft-induced new entry tear after endovascular repair of thoracic aortic dissection. J
506 Vasc Surg. mai 2019;69(5):1610- 4.
- 507
- 508

509 **Table 1:** Baseline characteristics

Demographic data	Marseille n = 33	Angers n = 12	Tours n =13	Total n = 58
Male sex, n (%)	27 (82)	9 (75)	11 (85)	47 (81)
Age, mean (SD)	62 (12)	59 (13)	57 (8)	60 (11)
Hypertension, n (%)	28 (85)	7 (58)	12 (92)	47 (81)
Dyslipidemia, n (%)	3 (9)	4 (33)	5 (38)	12 (21)
Smoking, n (%)	17 (52)	5 (42)	10 (77)	32 (55)
Diabetes, n (%)	1 (3)	0 (0)	1 (8)	2 (3)
Obesity, n (%)	2 (6)	1 (8)	4 (31)	7 (12)
Renal failure, n (%)	6 (18)	0 (0)	1 (8)	7 (12)
Connective tissue disorder, n (%)	2 (6)	0 (0)	1 (8)	3 (5)
Previous aortic surgery, n (%)	14 (42)	6 (50)	4 (31)	24 (41)
Ascending aorta replacement	0 (0)	1 (8)	0 (0)	1 (2)
Hemiarch replacement	8 (24)	4 (33)	2 (15)	14 (24)
Hemiarch replacement + SA debranching	6 (18)	1 (8)	1 (8)	8 (14)
Thoraflex	0 (0)	0 (0)	1 (8)	1 (2)
Anatomical characteristics				
<i>Mean maximal aortic diameter, mm (SD)</i>	54 (9.5)	40 (7.2)	44 (6.9)	49 (10.4)
<i>Residual aortic dissection, n (%)</i>	14 (42)	6 (50)	4 (31)	24 (41)
<i>Type B aortic dissection, n (%)</i>	19 (58)	6 (50)	9 (62)	34 (59)
<i>Iliac extension of the dissection, n (%)</i>	24 (73)	7 (58)	10 (77)	41 (71)
<i>Visceral arteries supplied by false lumen, n (%)</i>	27/132 (20)	13/48 (27)	9/52 (17)	49/232 (21)
Average time between acute phase of symptoms and STABILISE, days (SD)	413 (714)	124 (198)	168 (199)	298 (566)
<i>Acute phase (< 14 days), n (%)</i>	6 (18)	3 (25)	2 (15)	11 (19)
<i>Subacute phase (14-90 days), n (%)</i>	11 (33)	6 (50)	5 (38)	22 (38)
<i>Chronic phase (> 90 days), n (%)</i>	16 (48)	3 (25)	6 (46)	25 (43)
Indications, n (%)				
<i>Rupture</i>	2 (6)	0 (0)	0 (0)	2 (3)
<i>Malperfusion syndrome</i>	8 (24)	3 (25)	4 (31)	15 (26)
<i>Refractory pain</i>	2 (6)	5 (42)	3 (23)	10 (17)
<i>Refractory hypertension</i>	1 (3)	0 (0)	0 (0)	1 (2)
<i>Rapid aortic growth > 5 mm/6 months</i>	5 (15)	2 (17)	2 (15)	9 (16)
<i>Aneurysm evolution</i>	15 (45)	2 (17)	4 (31)	21 (36)

SD: standard deviation

510

511

512 **Table 2:** Procedural details

Procedural details	Marseille n = 33	Angers n = 12	Tours n =13	Total n = 58
Proximal neck management surgery, n (%)	26 (79)	4 (33)	9 (69)	39 (67)
<i>LSA debranching</i>	9	4	6	19
<i>Intrathoracic SA debranching</i>	8	0	0	8
<i>Replacement of the ascending aorta + SA debranching</i>	8	0	0	8
<i>Thoraflex</i>	0	0	2	2
<i>Fenestrated aortic arch stent graft</i>	1	0	1	2
Proximal landing zone				
Zone 0, n (%)	17 (52)	0 (0)	1 (0)	18 (31)
Zone 1, n (%)	1 (3)	0 (0)	1 (8)	2 (3)
Zone 2, n (%)	10 (30)	4 (33)	4 (31)	18 (31)
Zone 3, n (%)	5 (15)	7 (58)	7 (62)	19 (33)
Zone 4, n (%)	0 (0)	1 (8)	0 (0)	1 (2)
Distal landing zone				
Zone 7, n (%)	1 (3)	1 (8)	0 (0)	2 (3)
Zone 8, n (%)	5 (15)	2 (17)	1 (8)	8 (14)
Zone 9, n (%)	27 (82)	9 (75)	10 (77)	46 (79)
Zone 10, n (%)	0 (0)	0 (0)	2 (15)	2 (3)
Stent graft				
<i>Number (SD)</i>	2.2 (0.5)	1.8 (0.8)	1.7 (0.5)	2 (0.6)
<i>Average diameter, mm (SD)</i>	37.2 (4.2)	31.9 (3.4)	34.5 (2.7)	35.5 (4.2)
<i>Length of coverage, cm (SD)</i>	22.9 (5.5)	18.3 (2.9)	21.1 (4.1)	21.6 (5.1)
<i>Proximal neck oversizing, % (SD)</i>	15.4 (13)	12.3 (22)	-7.6 (15)	9.6 (18)
<i>Distal neck oversizing, % (SD)</i>	14 (12)	5 (15)	3 (11)	10 (13)
Bare stent				
<i>Number (SD)</i>	1.1 (0.3)	1 (0)	1.4 (0.5)	1.2 (0.4)
<i>Average diameter, mm (SD)</i>	43.6 (4.4)	36 (0)	36.8 (2.8)	40.5 (5)
<i>Oversizing, % (SD)</i>	25 (15)	19 (18)	11 (16)	21 (17)
Number of visceral arteries stented per procedure, n (%)	10/132 (7.6)	1/48 (2.1)	5/52 (9.6)	16/232 (6.9)
<i>Artery arising from true lumen, n (%)</i>	2/104 (2)	1/34 (2.9)	1/43 (2)	4/181 (2.2)
<i>Artery arising from false lumen, n (%)</i>	8/27 (30)	0/13 (0)	4/9 (44)	12/49 (24)
CFD, n (%)	10 (30)	1 (8)	12 (92)	23 (40)

513

514

515

516 **Table 3:** Anatomical results

Results	Marseille n=32	Angers n=10	Tours n=13	Total n=55
Hospital stay, days (SD)	13 (11)	7 (4)	10 (5)	11 (9)
Follow-up, days (SD)	233 (193)	250 (230)	230 (104)	236 (183)
FL thrombosis in thoracic aorta	30 (94)	9 (90)	13 (100)	52 (94)
Favorable anatomical result in thoracoabdominal aorta, n (%)	28 (88)	7 (70)	11 (85)	46 (84)
<i>Acute aortic dissection, n</i>	6	1	2	9
<i>Subacute aortic dissection, n</i>	10	4	4	18
<i>Chronic aortic dissection, n</i>	12	2	5	19
Significant increase in diameter of thoracoabdominal aorta, n (%)	9 (28)	6 (60)	8 (62)	23 (42)
<i>Acute aortic dissection, n</i>	1	1	1	3
<i>Subacute aortic dissection, n</i>	2	4	2	8
<i>Chronic aortic dissection, n</i>	6	1	5	12
Favorable anatomical result without aneurysm evolution, n (%)	22 (69)	3 (30)	5 (38)	30 (55)

517

518 **Supplemental Table 1:** Early reinterventions

N	Patient description	Time	Indication	Intervention
1	Subacute type B AD	D 9	Disconnection between stent graft and bare stent	New bare stent with larger overlap with the stent graft and SMA stenting
2	Chronic type B AD with SMA stenting during initial TEVAR-STABILISE	D 3	Mesenteric angina with acute renal insufficiency	Stenting of the right renal artery and extension of the stent at the level of the SMA
3	Subacute type B AD	D 9	Femoral false aneurysm	Repair of the femoral artery bifurcation
4	Subacute type B AD with RSA debranching (aberrant RSA) and LSA debranching for proximal neck management during TEVAR-STABILISE	D 1	Type 1A EL related to a bird-beak configuration	Hemiarch replacement with distal anastomosis of the stent graft and transposition of a bicarotid trunk
5	Subacute type B residual AD (hemiarch replacement)	D 0	Hemorrhagic shock following STABILISE	Extension of the stent graft, followed by mortality
6	Chronic type B residual AD (hemiarch replacement) with RCA replacement and RSA debranching followed by IA stenting and LSA debranching + LCA stenting for proximal neck management	D 2	Asymptomatic stent kinking at the IA on the postoperative control scan	Angioplasty
7	Subacute type B AD with the LRA and CT arising from the false lumen and a history of right nephrectomy	D 21	Stenosis with thrombosis next to the SMA, asymptomatic thrombosis on the computed tomography scan and renal malperfusion	Stenting of the CT, SMA and LRA
8	Subacute type B AD	D 3	Tamponade	Percutaneous pericardial drainage

519 AD= aortic dissection, D= day, SMA= superior mesenteric artery, CT= coeliac trunk, RSA=
520 right subclavian artery, LSA= left subclavian artery, LRA= left renal artery, EL= endoleak,
521 IA= innominate artery, RCA= right carotid artery, LCA= left carotid artery

522

523

524 **Supplemental Table 2:** Late reinterventions

N	Patient description	Time	Indication	Intervention
1	Subacute type B AD	D 242	Aortobronchial fistula	Replacement of the ascending aorta + SA debranching + TEVAR
2	Subacute type B AD	D 139	Lower-limb ischemia by compression of the true lumen by the false lumen	Extension of the bare stent + aorto-bi-iliac kissing stenting
3	Subacute residual type B AD (hemiarch replacement + SA debranching) with coverage of the LSA, initially asymptomatic	D 300	Basilar vertebral insufficiency	LSA debranching
4	Chronic residual type B AD (Thoraflex)	D 151	Left Scarpa lymphocele	Scarpa lymphostasis
5	Chronic residual type B AD (hemiarch replacement + SA debranching)	D 77	Dissecting aneurysm of the left common iliac artery	Aortic bi-iliac endoprosthesis + iliac branch endoprosthesis

525 AD= aortic dissection, D= day, SA= supra-aortic, LSA= left subclavian artery

526

527

528 **Figure Legends**

529

530 **Figure 1:** The aortic diameter was measured on CT preoperatively, postoperatively and at the
531 last follow-up at 3 stent graft level: (A) at the proximal region of the stent graft; (B) at the
532 descending thoracic aorta (maximum aortic diameter); (C) at the distal part of stent graft; and
533 at 3 bare stent level: (D) at the ostium of the celiac trunk; (E) at the junction of the last two
534 bare-stent segments; and (F) at the terminal part of the bare stent.

535

536 **Figure 2:** Example of good anatomical results after the STABILISE technique.

537 (A) Preoperative CT scan of a patient treated for a subacute type B AD. The left renal artery
538 arose from the FL.

539 (B) Two-year postoperative CT scan of the same patient showing complete remodeling of the
540 TAA with stent patency in the left renal artery and no aortic aneurysm development.

541

542 **Figure 3:** Evolution of the diameter of the thoracic aorta and TAA.

543 Preoperatively, the diameter at the first 3 levels of the thoracic aorta was 33.3 ± 6.5 mm, 48.6
544 ± 10.4 mm, and 34.1 ± 5.0 mm, and that at the 3 levels of the TAA (bare stent) was 31.7 ± 4.4
545 mm, 26.4 ± 4.9 mm and 25.4 ± 5.0 mm.

546 Early postoperatively, the diameter at the first 3 levels of the thoracic aorta was stable ($32.8 \pm$
547 5.6 mm, 48.3 ± 10.3 mm, and 33.7 ± 4.8 mm), while that at the 3 levels of the TAA (bare
548 stent) was increased (32.8 ± 4.4 mm, $p < .01$; 27.4 ± 5.2 mm, $p < .01$; and 26.4 ± 5.0 mm, $p <$
549 $.01$).

550 At the end of the mean follow-up of 8 ± 6 months, the aortic diameter at the proximal part of
551 the thoracic aorta was stable, at 33.2 ± 5.3 mm ($p > .05$), the maximum aortic diameter at
552 descending thoracic aorta was decreased, at 41.2 ± 8.1 mm ($p < .01$) (A), and the diameter at

553 the distal part of the thoracic aorta and TAA was increased, at 36.2 ± 5.5 mm ($p < .01$), $34.3 \pm$
554 4.2 mm ($p < .01$), 28.8 ± 5.5 mm ($p < .01$) and 27.7 ± 5.3 mm ($p < .01$) (B).

555

556 **Figure 4:** Example of an incomplete aortic remodeling with aneurysm evolution due to
557 significant angulation at the thoracoabdominal junction.

558 (A) Preoperative CT scan of a patient treated for chronic residual type B AD (hemiarch
559 replacement). Before performing STABILISE-TEVAR, we performed iterative replacement
560 of the ascending aorta + SA debranching to create a satisfactory proximal neck. The angle at
561 the level of the thoracoabdominal junction was 95° .

562 (B) Early postoperative CT scan of the same patient showing a stent-graft apposition defect at
563 the level of the distal neck with a FL permeable to the significant angle at the
564 thoracoabdominal junction.

565 (C) CT scan of the same patient at 1.5 years postoperatively showing a permeable FL channel
566 with aneurysm evolution.

567

568 **Video legend:** STABILISE procedure for complicated aortic dissection: aneurysmal
569 evolution greater than 55 mm. we performed a hybrid treatment with complete supra aortic
570 debranching and TEVAR-STABILISE procedure.