



HAL
open science

International Recommendations on Postoperative Management for Potentially Resectable Locally Recurrent Nasopharyngeal Carcinoma

Ji-Shi Li, Pierre Blanchard, Charlene H L Wong, Yong Chan Ahn, Pierluigi Bonomo, Damien Bresson, Jimmy Caudell, Ming-Yuan Chen, Velda L Y Chow, Melvin L K Chua, et al.

► **To cite this version:**

Ji-Shi Li, Pierre Blanchard, Charlene H L Wong, Yong Chan Ahn, Pierluigi Bonomo, et al.. International Recommendations on Postoperative Management for Potentially Resectable Locally Recurrent Nasopharyngeal Carcinoma. *International Journal of Radiation Oncology, Biology, Physics*, 2024, S0360-3016 (24), pp.02954-02957. 10.1016/j.ijrobp.2024.07.2143 . inserm-04707057

HAL Id: inserm-04707057

<https://inserm.hal.science/inserm-04707057v1>

Submitted on 24 Sep 2024

HAL is a multi-disciplinary open access archive for the deposit and dissemination of scientific research documents, whether they are published or not. The documents may come from teaching and research institutions in France or abroad, or from public or private research centers.

L'archive ouverte pluridisciplinaire **HAL**, est destinée au dépôt et à la diffusion de documents scientifiques de niveau recherche, publiés ou non, émanant des établissements d'enseignement et de recherche français ou étrangers, des laboratoires publics ou privés.



Distributed under a Creative Commons Attribution - NonCommercial - NoDerivatives 4.0 International License

CRITICAL REVIEW

International Recommendations on Postoperative Management for Potentially Resectable Locally Recurrent Nasopharyngeal Carcinoma

Ji-Shi Li, MD,^{*,†} Pierre Blanchard, MD, PhD,[‡] Charlene H.L. Wong, PhD,[§] Yong Chan Ahn, MD,^{||} Pierluigi Bonomo, MD,[¶] Damien Bresson, MD,[#] Jimmy Caudell, MD, PhD,^{**} Ming-Yuan Chen, PhD,^{††} Velda L.Y. Chow, FCSHK,^{‡‡} Melvin L.K. Chua, FRCR,^{§§,|||} June Corry, FRANZCR,^{¶¶} Charles Dupin, MD,^{##} Jordi Giralt, MD, PhD,^{***} Chao-Su Hu, MD,^{†††} Dora L.W. Kwong, FRCR,[§] Quynh-Thu Le, MD,^{†††} Anne W.M. Lee, FRCR,^{*,†} Nancy Y. Lee, MD,^{§§§} You-Zhong Li, PhD,^{||||} Chwee Ming Lim, MRCS,^{¶¶¶} Jin-Ching Lin, MD,^{###} William M. Mendenhall, MD,^{****} A. Moya-Plana, MD,^{††††} Brian O'Sullivan, FRCR,^{††††} Enis Ozyar, MD,^{§§§§} Jian-Ji Pan, MD,^{||||||} Qian-Hui Qiu, PhD,^{¶¶¶¶} David J. Sher, MD, MPH,^{####} Carl H. Snyderman, MD,^{*****} Yun-Gan Tao, MD,[‡] Raymond K. Tsang, FRCSEd(ORL),^{†††††} Xiao-Shen Wang, MD, PhD,^{†††††} Ping-An Wu, PhD,^{§§§§§} Sue S. Yom, MD,^{|||||||} and Wai Tong Ng, FRCR^{*,†,§}

^{*}Department of Clinical Oncology, Shenzhen Key Laboratory for Cancer Metastasis and Personalized Therapy, The University of Hong Kong-Shenzhen Hospital, Shenzhen, China; [†]Clinical Oncology Center, The University of Hong Kong-Shenzhen Hospital, Shenzhen, China; [‡]Department of Radiation Oncology, Gustave Roussy, Université Paris-Saclay, Villejuif, France; [§]Department of Clinical Oncology, Li Ka Shing Faculty of Medicine, The University of Hong Kong, Hong Kong, China; ^{||}Department of Radiation Oncology, Samsung Medical Center, Sungkyunkwan University School of Medicine, Seoul, Korea; [¶]Radiation Oncology, Azienda Ospedaliero-Universitaria Careggi, Florence, Italy; [#]Department of Neurosurgery, Hôpital Foch, Suresnes, France; ^{**}Department of Radiation Oncology, Moffitt Cancer Center, Tampa, Florida; ^{††}Department of Nasopharyngeal Carcinoma, Sun Yat-sen University Cancer Center, Guangzhou, China; ^{‡‡}Division of Head and Neck Surgery, Department of Surgery, The University of Hong Kong, Hong Kong, China; ^{§§}Department of Head and Neck and Thoracic Radiation Oncology; Precision Radiotherapeutics Oncology Programme, Division of Medical Sciences, National Cancer Centre Singapore; ^{|||}Oncology Academic Clinical Programme, Duke-NUS Medical School, Singapore; ^{¶¶}Division of Radiation Oncology, GenesisCare Radiation Oncology, St. Vincent's Hospital, Melbourne, Victoria, Australia; ^{##}Department of Radiation Oncology, Bordeaux University Hospital, Bordeaux, France; ^{***}Department of Radiation Oncology, Vall D'Hebron University Hospital, Barcelona, Spain; ^{†††}Department of Radiation Oncology, Shanghai Proton and Heavy Ion Center, Fudan University Cancer Hospital, Shanghai, China; ^{††††}Department of Radiation Oncology, Stanford University, Stanford, California; ^{§§§}Department of Radiation Oncology, Memorial Sloan Kettering Cancer Center, New York; ^{||||}The Second Xiangya Hospital of Central South University, Department of Otorhinolaryngology, Head and Neck Surgery, Changsha, China; ^{¶¶¶}Department of Otolaryngology-Head and Neck Surgery, Singapore General Hospital, Singapore; ^{###}Department of Radiation Oncology, Changhua Christian Hospital, Changhua, Taiwan; ^{****}Department of Radiation Oncology, University of Florida,

Corresponding author: Wai Tong Ng, FRCR; E-mail: ngwt1@hku.hk

Authors J.-S. Li, Blanchard, C.H.L. Wong, and Ng made equal contributions to this study.

Disclosures: W.T.N., A.W.M.L., and J.-S.L. receive support from Shenzhen Key Medical Discipline Construction Fund (No. SZXK014), Shenzhen Science and Technology Program (Grant No. KQTD20180411185028798), Department of Clinical Oncology, Shenzhen Key Laboratory for cancer metastasis and personalized therapy, The University of Hong Kong-Shenzhen Hospital (Acknowledgment: ZDSYS20210623091811035), the Shenzhen Fundamental Research Program, China (JCYJ20210324114404013) and Sanming Project of Medicine in Shenzhen (SZSM202211017). M.L.K. C. reports personal fees from Astellas, Janssen, Pfizer, MSD, Varian, IQVIA, Telix Pharmaceuticals; personal fees and research funding to

institution from Bayer and BeiGene; personal fees and nonfinancial support from AstraZeneca; nonfinancial support from Decipher Biosciences; consults for immunoSCAPE Inc. and PVMed; and is a coinventor of the patent of a High Sensitivity Lateral Flow Immunoassay For Detection of Analyte in Sample (10202107837T), Singapore and serves on the Board of Directors of Digital Life Line Pte Ltd that owns the licensing agreement of the patent, outside the submitted work.

Author Responsible for Statistical Analyses: Charlene H.L. Wong, E-mail: wonghlc@hku.hk

Data Sharing Statement: Research data are stored in an institutional repository and will be shared upon request to the corresponding author.

Supplementary material associated with this article can be found in the online version at [doi:10.1016/j.ijrobp.2024.07.2143](https://doi.org/10.1016/j.ijrobp.2024.07.2143).

Gainesville, Florida; ^{††††}Department of Head and Neck Oncology, Gustave Roussy, Villejuif, France; ^{‡‡‡‡}Department of Radiation Oncology, Department of Otolaryngology-Head and Neck Surgery, Princess Margaret Cancer Centre, University of Toronto, Toronto, Canada; ^{§§§§}Acibadem MAA University, School of Medicine, Department of Radiation Oncology, Istanbul, Turkey; ^{||||||}Department of Radiation Oncology, Fujian Provincial Cancer Hospital, Provincial Clinical Medical College of Fujian Medical University, Fuzhou, China; ^{¶¶¶¶}Department of Otolaryngology, Guangdong General Hospital, Guangdong Academy of Medical Science, Guangzhou, China; ^{####}Department of Radiation Oncology, University of Texas Southwestern Medical Center, Dallas; ^{*****}Department of Otolaryngology, University of Pittsburgh School of Medicine, Pittsburgh; ^{†††††}Department of Otolaryngology - Head and Neck Surgery, National University of Singapore, Singapore; ^{‡‡‡‡‡}Department of Radiation Oncology, Eye & ENT Hospital, Fudan University, Shanghai, China; ^{§§§§§}Department of Surgery, The University of Hong Kong-Shenzhen Hospital, Shenzhen, China; and ^{|||||||}Department of Radiation Oncology, University of California San Francisco, San Francisco, California

Received Nov 7, 2023; Accepted for publication Jul 1, 2024

Locally recurrent nasopharyngeal carcinoma (NPC) presents substantial challenges in clinical management. Although postoperative re-irradiation (re-RT) has been acknowledged as a potential treatment option, standardized guidelines and consensus regarding the use of re-RT in this context are lacking. This article provides a comprehensive review and summary of international recommendations on postoperative management for potentially resectable locally recurrent NPC, with a special focus on postoperative re-RT. A thorough search was conducted to identify relevant studies on postoperative re-RT for locally recurrent NPC. Controversial issues, including resectability criteria, margin assessment, indications for postoperative re-RT, and the optimal dose and method of re-RT, were addressed through a Delphi consensus process. The consensus recommendations emphasize the need for a clearer and broader definition of resectability, highlighting the importance of achieving clear surgical margins, preferably through an en bloc approach with frozen section margin assessment. Furthermore, these guidelines suggest considering re-RT for patients with positive or close margins. Optimal postoperative re-RT doses typically range around 60 Gy, and hyperfractionation has shown promise in reducing toxicity. These guidelines aim to assist clinicians in making evidence-based decisions and improving patient outcomes in the management of potentially resectable locally recurrent NPC. By addressing key areas of controversy and providing recommendations on resectability, margin assessment, and re-RT parameters, these guidelines serve as a valuable resource for clinical experts involved in the treatment of locally recurrent NPC. © 2024 The Authors. Published by Elsevier Inc. This is an open access article under the CC BY-NC-ND license (<http://creativecommons.org/licenses/by-nc-nd/4.0/>)

Background

Locally recurrent nasopharyngeal carcinoma (NPC) poses substantial challenges in terms of both treatment and management. The disease exhibits high curability in the primary setting, and advancements in intensity modulated radiation therapy (IMRT) have resulted in relatively low rates of local recurrence.^{1,2} When local recurrences do occur, they frequently manifest within the previously irradiated high-dose zone.^{3,4} Notably, the incidences of marginal failure and geographical miss are $\leq 2\%$ and 0% to 1%, respectively, suggesting that these local relapses are predominantly associated with radiation resistance.⁵ With improvements in imaging and blood-based surveillance methods, many of these local recurrences are potentially detectable at an earlier stage, possibly making them salvageable through surgical means. Endoscopic nasopharyngectomy is recently regarded as the preferred option for resectable locally recurrent NPC.^{6,7} Small recurrent tumors confined to the nasopharyngeal cavity, the postnaris or nasal septum, the superficial parapharyngeal space, or the sphenoid sinus floor are usually readily resectable. However, the resectability criteria vary considerably for more advanced lesions, especially if the tumor is close to the carotid vessel or involves other parts of the skull base beyond the sphenoid sinus floor. Accurate histopathological margin assessment is also challenging as it is more

difficult to carry out en bloc resection with more extensive skull base involvement.

To eradicate residual disease and enhance local control, postoperative re-irradiation (re-RT) may be necessary for patients with positive or close resection margins. However, late complications related to re-RT are not uncommon, and high-quality data supporting its efficacy are lacking. There is currently no consensus on which patients would benefit from postoperative re-RT.

In this study, we aimed to establish a consensus guideline on resectability criteria, margin assessment, indications for postoperative re-RT, and the dose and method of re-RT. A systematic literature review was first conducted to formulate pertinent questions, and a modified Delphi process was then used to build consensus among internationally regarded clinical opinion leaders from major centers worldwide. The goal of this process was to enhance treatment outcomes, minimize complications, and guide clinicians in making informed decisions regarding the management of locally recurrent NPC.

Methods and Materials

This study was composed of 3 parts. First, a comprehensive literature search was conducted using EMBASE, Cochrane

CENTRAL, CINAHL Plus, and PubMed databases to investigate the clinical outcomes of recurrent NPC treated with salvage operations, with or without re-RT. The search covered publications from the inception of the databases up to December 10, 2022. The search terms used were “recurrent nasopharyngeal carcinoma” OR “rnp” OR “nasopharyngeal cancer” AND “recurrence” (Table E1). Additionally, the CNKI and Weipu (VIP) databases were searched for studies published in Chinese. Both prospective and retrospective studies published between January 2000 and December 2022 were reviewed, and data on the operation, failure pattern, survival, and/or toxicity outcomes were tabulated. Publications in languages other than Chinese and English were excluded. Furthermore, the references of included research articles were examined for potentially eligible studies. The literature review followed the PRISMA workflow,⁸ as depicted in Figure 1. The extracted information included characteristics of patients, follow-up period, details of postoperative treatments, recurrence rate, as well as survival data. Tables E2 and E3 provide further

details on the research articles included in the first part of the study.

Second, an initial list of questions related to resectability criteria, margin assessment, indications for postoperative re-RT, and dose and method of re-RT was compiled based on the findings from the literature review. This list of questions was then distributed to a panel of international experts, including surgeons and oncologists specializing in recurrent NPC from Asia, Europe, and North America. The experts participated in an initial voting process and exchanged comments using a modified Delphi process. The decision-making process of the panelists was facilitated by considering 2 criteria from the evidence-to-decision framework: benefits and feasibility.⁹ The experts were then asked to give a final rating on each research question using a 4-point Likert scale, ranging from “Fully agree,” “Agree,” “Not agree,” to “Strongly disagree.” They were also invited to provide qualitative comments explaining their rating.

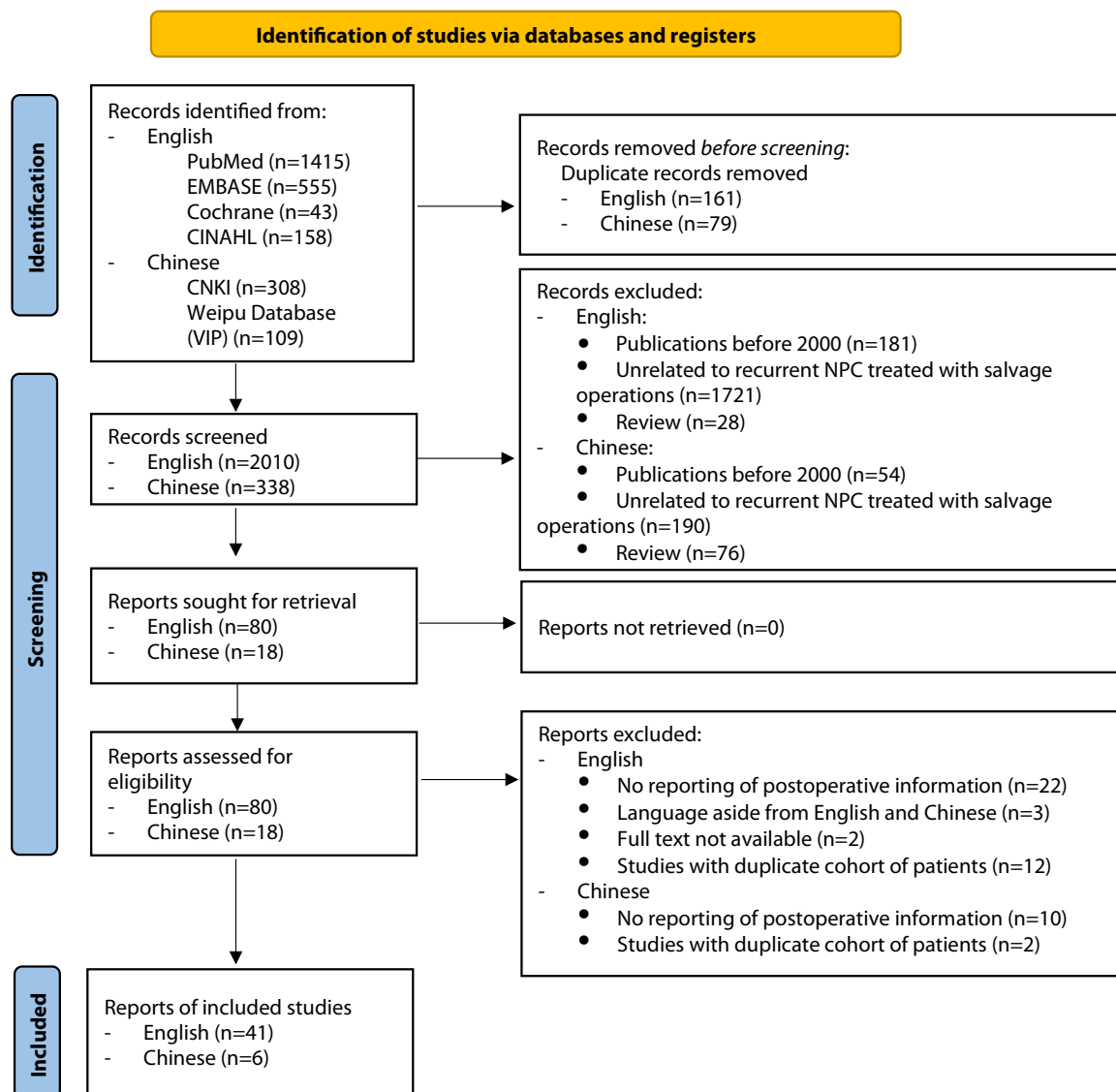


Fig. 1. PRISMA flow diagram.

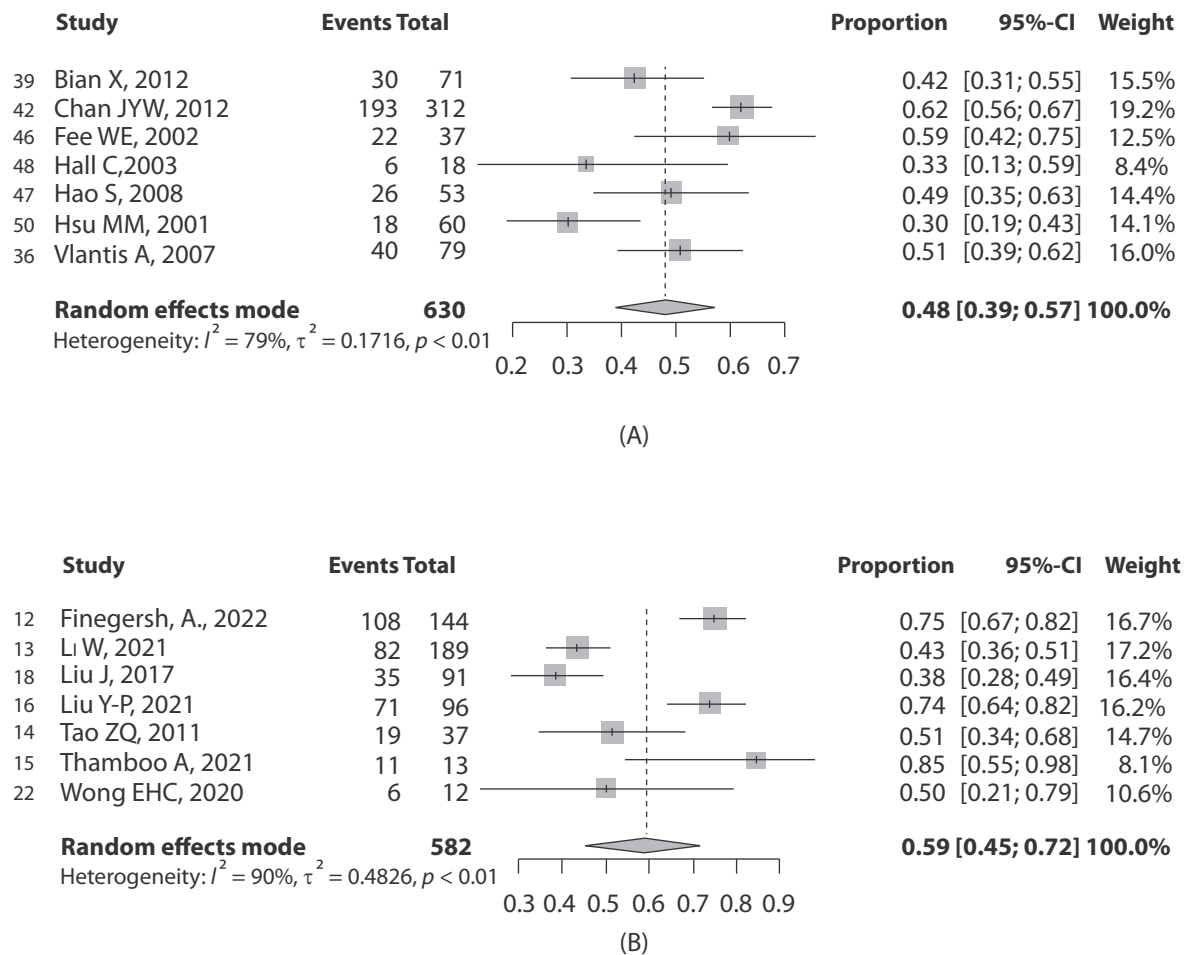


Fig. 2. (A) Random-effects meta-analysis of 5-year overall survival rate of open nasopharyngectomy.^{36,39,42,46–48,50} (B) Random-effects meta-analysis of 5-year overall survival rate of endoscopic nasopharyngectomy.^{12–16,18,22}

Lastly, after repeated iterations and summarizing the feedback received, a follow-up list of questions addressing specific aspects of controversial issues was recirculated for a second round of voting if initial agreement on the subject was below the cut-off of 75%. Considering the limited availability of high-quality published data on this specific clinical problem,^{10,11} this consensus-building process served as the fundamental basis for the group's final recommendations.

Results and Discussion

The systematic literature search identified a total of 47 studies that met the inclusion criteria and were included in the review. The included studies consisted of 46 retrospective cohort or case series studies and 1 prospective trial. The number of patients included in the studies ranged from 2 to 312. The studies reported on surgical methods, the rate of positive margins, postoperative modalities, local control rates, overall survival (OS), disease-free survival, and treatment-related toxicity. The pooled analysis showed that the 5-year OS rates were respectively 48% (95% CI, 39%-57%;

$I^2 = 79\%$; $P < .01$) for the era of open surgery and 59% (95% CI, 45%-72%; $I^2 = 90\%$; $P < .01$) for endoscopic nasopharyngectomy (Fig. 2A, B). However, there was significant heterogeneity in both meta-analyses.

Preparation of the list of research questions and voting results

During the literature search, a single open-label phase III trial was identified,¹⁶ which randomly assigned 200 patients with recurrent NPC to undergo endoscopic nasopharyngectomy or re-RT with IMRT. This trial included patients with tumors limited to the nasopharyngeal cavity, postnaris or nasal septum, superficial parapharyngeal space, or the floor of the sphenoid sinus. The findings showed that the majority of patients who underwent surgery (94%) did not require additional adjuvant radiation therapy or chemotherapy. Similarly, most patients who received IMRT completed the full course of treatment, with the majority (71%) receiving cisplatin as concurrent chemotherapy. Patients undergoing endoscopic nasopharyngectomy had a 3-year OS rate of 86%, compared to 68% for those receiving IMRT (hazard

ratio, 0.47; 95% CI, 0.29-0.76). However, the survival benefit was observed only in patients with T1 and T2 tumors, and not in those with T3 tumors. Furthermore, endoscopic nasopharyngectomy was associated with lower rates of grade ≥ 3 overall adverse events and late adverse events when compared to IMRT (13% versus 37% for both outcomes). Based on the results of this randomized trial, endoscopic nasopharyngectomy could be used for readily resectable disease, such as rT1 disease, rT2 disease with limited parapharyngeal space involvement, and rT3 disease confined to the floor of the sphenoid sinus.

However, resectability criteria for advanced diseases involving the internal carotid artery (ICA), skull base other than the floor of the sphenoid sinus, and rT4 were not well-defined. There was a lack of standardization in the assessment of surgical margins, resulting in variable rates of reporting close and positive margins. Furthermore, indications for postoperative radiation therapy and the dose and methods of re-RT were also poorly described. The lack of uniformity in re-RT approaches highlighted the necessity for proposing guidelines to bridge these gaps and optimize treatment outcomes. Hence, voting questions were focused on the following 5 areas (Table 1): definition of resectability, assessment of surgical margins, definition of the surgical margin, indications for postoperative re-RT, and method and dose for postoperative re-RT. Instead of restricting the voting on surgical questions to surgeons and radiation therapy questions to radiation oncologists (except for specific questions on carotid artery protection, radiation dose, and re-RT method), our study involved the participation of both professions in rating each research question, similar to a multidisciplinary tumor board. This approach ensures that expertise from both specialties is comprehensively considered when formulating the treatment plan for postoperative management of locally recurrent NPC.

During round 1, a total of 12 questions and their sub-questions achieved positive consensus, with an agreement level of more than 75%.¹⁷ However, the remaining 11 questions required additional discussion and iteration. The subsequent agreement percentage in round 2 represented the final voting results for those specific questions after further deliberation and consideration by the expert panel (Table E4).

Consensus recommendations

Definition of resectability

Building upon the commonly accepted resectability criteria as stated in the randomized study by Liu et al,¹⁶ we suggested further expanding the resectability criteria for rT3 NPC to include the posterior maxillary sinus, pterygoid process, and outer table of the clivus as resectable regions.

Regarding the relationship between the recurrent lesion and the ICA, surgeons commonly considered lesions that

were at least 5 mm away from the ICA as resectable, while “close to” referred to locations less than 5 mm from the ICA, which was also one of the exclusion criteria in the randomized trial.¹⁶ There was a high consensus among surgeons that rT2 lesions close to the ICA were resectable. For cases of more advanced rT2 disease in close proximity to the ICA, a balloon occlusion test was proposed to assess the collateral blood flow in the brain during temporary occlusion of the ICA.¹⁸ By evaluating cerebral blood flow and collateral circulation, the surgeon could make informed decisions regarding the risks of ICA manipulation during the resection.

The assessment of resectability in cases involving the ICA varied among surgeons and oncologists, highlighting the importance of a multidisciplinary approach to decision-making.¹⁹ Although the majority of oncologists considered tumors involving the ICA as unresectable, more than half of the surgeons still viewed them as potentially resectable. Managing the ICA presented the greatest challenge in salvage operations, and specialized cancer centers have reported several case series exploring this issue.¹⁸ The surgical technique used in these cases was extracranial-intracranial vascular bypass, which involved bypassing the affected section of the ICA by means of a vascular graft connecting the carotid vessel in the neck to the middle cerebral artery intracranially.²⁰ This bypass procedure established a new route of anterior cerebral circulation and hence enabled safe resection of the tumor with the old route, that is, the affected ICA. However, it is noteworthy that the surgeon's expertise and performance were key determinants of surgical success. Hence, the generalizability of this highly sophisticated surgical technique in different health care settings would be limited.

The role of endoscopic nasopharyngectomy has been generally limited in cases of more advanced rT3 (such as multiple areas of skull base involvement) and rT4 disease. Specifically, lesions involving the foramen lacerum, petrous apex, or the lateral wall of the sphenoid sinus might pose challenges because of their proximity to critical structures such as the cavernous sinus, which comprises multiple cranial nerves and the ICA. It was more difficult to perform resection in these cases. Additionally, repairing the dura in a watertight manner could be challenging if it was inadvertently damaged during the resection of tumors invading both cortices of the clivus.

Surgeons might consider performing such surgery given their strong expertise in neurosurgery and skull base surgery, coupled with access to vascular surgical support.^{18,21,22} However, such high-level expertise was lacking globally and only a few successful cases have been reported.

For instance, a reported series of endoscopic endonasal nasopharyngectomy for 15 patients with rT3 to rT4 disease was conducted at the University Malaya Medical Centre. This procedure was performed without encountering severe operative complications. The 2-year OS and disease-free survival rates were found to be 66.7% and 40%, respectively. Among the cohort, 53.8% of the rT4 patients achieved negative margins. Additionally, the reported 5-year OS and

Table 1 Results of the 2-round Delphi survey on formulating the recommendations on postoperative management for locally recurrent NPC

Category	Recommendation with positive consensus	Recommendation without consensus
1. Definition of resectability	<p>Potentially resectable disease includes:</p> <p>a. rT3 with posterior maxillary sinus and pterygoid process invasion (surgeons' agreement: 89% [8 of 9 voters]; oncologists' agreement: 86% [18 of 21 voters]; reached consensus in round 1)</p> <p>b. rT3 cases involve the "outer table" of the clivus but do not invade the marrow (where the outer table refers to the bony surface facing the nasopharynx) (surgeons' agreement: 100% [9 of 9 voters]; oncologists' agreement: 75% [15 of 20 voters]; reached consensus in round 2)</p> <p>c. rT2 with an extension close to the ICA (surgeons' agreement: 100% [9 of 9 voters]; oncologists' agreement: 85% [17 of 20 voters]; reached consensus in round 2)</p>	<p>Potentially resectable disease includes:</p> <p>a. rT2 with an extension involving the ICA (surgeons' agreement: 56% [5 of 9 voters]; oncologists' agreement: 5% [1 of 21 voters]; did not reach consensus after 2 rounds)</p>
	<p>Unresectable diseases are as follows:</p> <p>a. rT3 with tumor invading both cortices of the clivus (surgeons' agreement: 100% [9 of 9 voters]; oncologists' agreement: 76% [16 of 21 voters]; reached consensus in round 1)</p> <p>b. rT3 with significant involvement of the lateral wall of the sphenoid sinus (surgeons' agreement: 100% [9 of 9 voters]; oncologists' agreement: 76% [16 of 21 voters]; reached consensus in round 1)</p> <p>c. rT4 with frank cavernous sinus or intracranial invasion (surgeons' agreement: 100% [9 of 9 voters]; oncologists' agreement: 81% [17 of 21 voters]; reached consensus in round 1)</p> <p>d. rT3 with multiple areas of skull base involvement (surgeons' agreement: 89% [8 of 9 voters]; oncologists' agreement: 85% [17 of 20 voters]; reached consensus in round 2)</p>	<p>Unresectable diseases are as follows:</p> <p>a. rT3 with foramen lacerum and petrous apex involvement (surgeons' agreement: 67% [6 of 9 voters]; oncologists' agreement: 95% [19 of 20 voters]; reached consensus among oncologists only, but not surgeons after 2 rounds)</p>
	<p>a. Carotid artery protection/embolization should be considered in recurrent lesion abutting/involving the ICA (surgeons' agreement: 89% [8 of 9 voters]; reached consensus in round 1)</p> <p>b. Some form of carotid artery protection should be considered in recurrent lesions located less than 5 mm from ICA (surgeons' agreement: 89% [8 of 9 voters]; reached consensus in round 2)</p>	Not applicable
2. Assessment of surgical margins	<p>a. Routine frozen section examination of the soft tissue resection margins should be performed (surgeons' agreement: 89% (8 of 9 voters); oncologists' agreement: 100% (21 of 21 voters); reached consensus in round 1)</p> <p>b. En bloc resection is the preferred approach whenever possible, but piece-meal removal may be necessary, especially for infiltrative</p>	Not applicable

(Continued)

Table 1 (Continued)	Recommendation with positive consensus	Recommendation without consensus
3. Definition of the surgical margin	<p>recurrence (surgeons' agreement: 89% [8 of 9 voters]; oncologists' agreement: 85% [17 of 20 voters]; reached consensus in round 2)</p> <p>a. Close margin should be defined as >1 and <3 mm (surgeons' agreement: 100% [9 of 9 voters]; oncologists' agreement: 90% [19 of 21 voters]; reached consensus in round 1)</p>	<p>a. A margin that is ≤1 mm but doesn't actually reach the margin should be classified as a "close" margin rather than a "positive" margin (surgeons' agreement: 89% [8 of 9 voters]; oncologists' agreement: 65% [13 of 20 voters]; reached consensus among surgeons only, but not oncologists after 2 rounds)</p>
4. Indications for postoperative re-RT	<p>a. Postoperative re-RT should be offered for tumor cells seen on the surgical margin (Surgeons' agreement: 78% [7 of 9 voters]; oncologists' agreement: 95% [20 of 21 voters]; reached consensus in round 1)</p> <p>b. Postoperative re-RT should be considered for margins less than 1 mm after a thorough evaluation of the prior RT plan and dosimetric feasibility (surgeons' agreement: 100% [9 of 9 voters]; oncologists' agreement: 95% [19 of 20 voters]; reached consensus in round 2)</p>	<p>a. Postoperative re-RT is not recommended if the margin is >1 mm but less than <3 mm. (surgeons' agreement: 67% [6 of 9 voters]; oncologists' agreement: 85% [17 of 20 voters]; reached consensus among oncologists only, but not surgeons after 2 rounds)</p>
5. Method and dose for postoperative re-RT	<p>a. CTV should include the postoperative tumor bed with a 5 mm margin (to account for microscopic disease extension) while respecting the adjacent critical organs at risk (oncologists' agreement: 100% [21 of 21 voters]; reached consensus in round 1)</p> <p>b. A dose of ≥60 Gy (in EQD2) should be given, but should not exceed 66 Gy (EQD2) (oncologists' agreement: 81% [17 of 21 voters]; reached consensus in round 1)</p> <p>c. Conventional fractionation is an acceptable treatment technique in the postoperative setting (oncologists' agreement: 76% [16 of 21 voters]; reached consensus in round 1)</p> <p>d. Doses >2 Gy per fraction should be avoided (oncologists' consensus: 76% [16 of 21 voters]; reached consensus in round 1)</p>	<p>a. Hyperfractionated IMRT should be the preferred treatment technique if resources allow (oncologists' agreement: 70% [14 of 20 voters]; did not reach consensus after 2 rounds)</p>
<p><i>Abbreviations:</i> CTV = clinical target volume; EQD2 = equivalent dose in 2 Gy fractions; ICA = internal carotid artery; IMRT = intensity modulated radiation therapy; NPC = nasopharyngeal carcinoma; re-RT = re-irradiation.</p>		

Progression Free Survival (PFS) rates for 12 patients within the same period were 50% and 20%, respectively.²¹

Notably, a meta-analysis conducted on patients with recurrent rT3 to rT4 NPC indicated that endoscopic surgery might improve survival outcomes compared to IMRT in cases of recurrent NPC with rT3 to rT4 disease. The 5-year OS rates were 52% for patients receiving endoscopic surgery and 31% for IMRT. However, specific details regarding post-operative re-RT in the context of rT3 to rT4 disease following the surgical procedure were not reported in the study.²³

Carotid artery protection techniques have been recommended to safeguard the integrity of the ICA during endoscopic resection of recurrent NPC. These techniques involved measures to prevent injury to the ICA and minimize the risk of carotid blowout syndrome, a potentially life-threatening complication. For instance, the use of a vascularized flap to cover the exposed ICA posttumor extirpation was found to minimize the risk of ICA blowout bleeding.^{24–26}

Pretreatment ICA embolization was another strategy that can be employed in managing recurrent NPC with ICA involvement. This technique selectively blocked the tumor's blood supply by injecting embolic agents into the ICA before surgery. Embolization reduced tumor vascularity, making subsequent tumor resection safer and more effective. By decreasing blood flow to the tumor, embolization could facilitate complete tumor excision, achieve negative margins, and improve patient outcomes.^{18,27} A case-matched study demonstrated that pretreatment with ICA embolization significantly improved the 2-year OS and PFS rates (90.5% vs 53.3% and 71.3% vs 33.0%, respectively; $P = .022$ and $P = .006$). Furthermore, it reduced the incidence of treatment-related complications such as nasopharyngeal hemorrhage and necrosis.²⁸

Recommendations that received a positive consensus under the category of "Definition of resectability" are as follows:

- Potentially resectable disease includes the following
 1. rT3 with posterior maxillary sinus and pterygoid process invasion;
 2. rT3 cases involve the "outer table" of the clivus but not invading the marrow;
 3. rT2 with an extension close to the ICA.
- Unresectable diseases are as follows:
 1. rT3 with tumor invading both cortices of the clivus;
 2. rT3 with significant involvement of the lateral wall of the sphenoid sinus;
 3. rT4 with frank cavernous sinus or intracranial invasion;
 4. rT3 with multiple areas of skull base involvement.

- Carotid artery protection/embolization should be considered in recurrent lesions abutting/involving the ICA.
- Some form of carotid artery protection should be considered in recurrent lesions located less than 5 mm from the ICA.

Assessment of surgical margins

Achieving microscopically clear margins following salvage surgery for recurrent NPC was crucial for effective local disease control and improved survival.²⁹ Several practices could increase the likelihood of achieving clear margins in these cases. These included accurate pre-operative assessment of tumor extent, ensuring adequate exposure of the tumor during surgery, performing en bloc resection with wide margins whenever possible, and conducting frozen section examination of resection margins to ensure the absence of microscopic tumor deposits.³⁰

The concept of en bloc resection was found to be suitable for early rT1 and selected rT2 cases, demonstrating relatively encouraging short-term outcomes.³¹ In selected rT2 scenarios, a careful en bloc resection could be performed by expanding the surgical field and ensuring a clear view of the anatomy associated with the ICA, which was crucial. However, achieving en bloc resection for rT3 tumors with skull base involvement was challenging, and conducting a frozen section for bony margin assessment was not feasible. One criticism of endoscopic approaches was the difficulty in achieving en bloc resection, and in some cases, piece-meal resection might be necessary, especially in deep and critical locations of recurrent tumors close to vital structures. However, some existing studies have shown that the survival outcomes of endoscopic resection for sinonasal and skull base tumors were comparable or even better than those of open resection.^{32,33}

Frozen section analysis (FSA) was commonly employed during salvage surgery for recurrent or residual NPC to assist in margin assessment. Tissue-based analysis revealed that FSA exhibited a sensitivity, specificity, positive predictive value, negative predictive value, and accuracy of 70.6%, 100%, 100%, 95.2%, and 95.7%, respectively. However, it was important to note that only 37% of inconclusive FSA results were negative on permanent histology.³⁴

The expert panel highly agreed that en bloc resection was the preferred approach whenever feasible. However, piece-meal removal might be necessary, particularly for infiltrative recurrence. Routine frozen section examination of soft tissue resection margins should be performed to ensure optimal surgical outcomes and margin assessment. However, the FSA was taken randomly without a definite protocol. It was recommended to take the circumstantial and deep margin for FSA routinely in the Chinese surgical consensus for recurrent NPC.³⁵

Recommendations that received a positive consensus under the category of "Assessment of surgical margins" include the following:

- Routine frozen section examination of the soft tissue resection margins should be performed.
- En bloc resection is the preferred approach whenever possible, but piece-meal removal may be necessary, especially for infiltrative recurrence.

Definition of the surgical margin

Although the presence of tumor cells on the resected surgical margin is typically defined as a positive margin, the definition of a close margin and the indication for re-RT under such circumstances are poorly described in the literature. In a study by Vlantis et al,³⁶ the following cut-off values were used to define margin statuses: clear (≥ 3 mm), close (>1 and <3 mm), and positive (≤ 1 mm).²² Results were analyzed based on these margin statuses. According to the study, the 5-year OS for patients with clear, close, and positive margins were 77%, 46% ($P = .05$), and 23% ($P < .001$), respectively. Another cohort reported by Chan et al³⁷ showed that the chances of clear, close, and involved resection margins at nasopharyngectomy were 44.4%, 31.0%, and 24.6%, respectively. At follow-up, the corresponding risks of local tumor recurrence were 10.7%, 38.5%, and 67.7%, respectively.

It is important to consider that the interpretation of margin status can be complicated by previous radiation therapy, which may require a broader definition than the classic “tumor on ink” approach. Additionally, depending on the methodology used during resection, the final histological margin may be less than the actual distance of the tumor from the edge of the resection. Specific ablation techniques, such as the plasma knife, can vaporize a certain amount of tissue, approximately 2 to 10 mm.³⁸ Therefore, if the reported margin was 1 mm from the edge of the resection specimen, the actual margin might be wider than 3 mm.

During the Delphi consensus process, discrepancies emerged between surgeons and oncologists regarding the definition of a positive margin. In the first round, 33% of surgeons disagreed with classifying a “positive margin” as ≤ 1 mm, whereas 90% of oncologists agreed. In the second round, the statement was revised to classify a margin ≤ 1 mm, but not reaching the margin, as a “close” margin rather than a “positive” margin. Discrepancies persisted between surgeons and oncologists in this regard. Surgeons tended to use a stricter definition (ie, tumor on ink) for a positive margin in the postoperative margin assessment of recurrent NPC, whereas oncologists preferred labeling a margin as positive when the tumor was within 1 mm from the margin.

This discrepancy highlights the critical need for clear definitions of margin assessment and the importance of transparent reporting of these definitions in the literature, especially when re-RT is considered a treatment option. Standardized classification would enhance the comparability of studies and promote a better understanding of the impact of margin status on treatment outcomes in these cases.

The recommendation that received a positive consensus under the category of “Definition of the surgical margin” is as follows:

- Close margin should be defined as >1 and <3 mm

Indications for postoperative re-RT

There was a significant difference in decision-making regarding postoperative re-RT between the eras of open surgery and endoscopic surgery. In the open surgery series, nearly 50% (45.8%, 222/485) of patients received postoperative re-RT, and the indications were not limited to patients with positive margins, which accounted for approximately 50% of cases (Table E2).^{20,29,36,39–54} In a study conducted by Chan et al⁵⁵ in Hong Kong, the overall crude local recurrence rate after nasopharyngectomy was 13.1%, with a significantly higher risk in patients with positive resection margins (39.6% vs 6.9%; $P = .006$). Patients who received postoperative chemoradiation had a significantly lower chance of developing local recurrence compared to those who did not (29.4% vs 64.3%; $P = .04$). A meta-analysis conducted in 2014, based on 17 studies conducted between 1990 and 2012, demonstrated the benefits of postoperative adjuvant therapy, primarily based on data from open surgery series. Patients receiving surgery and postoperative re-RT had a significantly higher 5-year OS rate (63%) than those receiving surgery alone (39%, $P = .05$).⁵⁶ Nonetheless, it is important to note that this meta-analysis included studies published before 2012 and may not include the most up-to-date treatment options. Patient selection for surgery has been evolving rapidly, especially with the advent of IMRT, which is often preferred for bulky locoregional recurrent disease.⁵⁷

However, in cohorts of patients who underwent endoscopic surgery, the proportion of patients receiving postoperative re-RT was considerably lower (only 52 out of approximately 900 patients, 5.8%) (Table E3). Consistent with these findings, a meta-analysis reported that postoperative re-RT was used in 33 out of 95 patients (34.7%) following open surgery, and 8 out of 91 patients (9.7%) following endoscopic surgery.⁵⁸ Although all patients who received postoperative re-RT had positive resection margins, details of close margins were rarely reported in the case series treated by endoscopic surgery.

The differences in the proportion of patients receiving postoperative re-RT might be attributed to several factors, including the following: (1) a selective patient population with small-volume recurrence that was most suitable for the endoscopic approach; (2) a higher likelihood of achieving clear margins in the endoscopy era; (3) challenges in accurately evaluating close/positive margins; and (4) increased awareness of the potential side effects of second-course radiation therapy.⁵⁹ Pooled analysis revealed that a free margin was achieved in 69% of patients after open surgery and 84% after endoscopic surgery ($P = .4$).⁵⁶

In the current Delphi survey, both surgeons and radiation oncologists were inclined to reserve postoperative re-RT for cases with truly positive margins or margins less than 1 mm,

following a thorough evaluation of the prior radiation therapy plan and dosimetric feasibility, as well as whether a vascularized flap has been employed to protect the underlying surgical wound.⁶⁰ Additionally, there are considerations for avoiding or deferring re-RT, especially in cases with a short latency of less than 6 to 12 months following the completion of primary RT or with existing major RT-induced late toxicity.⁶¹

Recommendations that received a positive consensus under the category of “Indications for postoperative re-RT” include the following:

- Postoperative Re-RT should be offered for tumor cells seen on the surgical margin.
- Postoperative Re-RT should be considered for margins less than 1 mm after a thorough evaluation of the prior RT plan and dosimetric feasibility.

Method and dose for postoperative re-RT

Precision re-RT techniques such as IMRT and stereotactic radiation therapy have been commonly employed when residual microscopic disease is suspected after surgery.

However, the existing literature lacks detailed information on the specific application in these cases. Although the clinical target volume (CTV) for such situations has not been clearly defined, experts generally agreed that it should encompass the tumor bed with a 5 mm margin to account for the potential extension of microscopic disease (Fig. 3). It is important to consider the adjacent critical organs at risk (OARs) and natural barriers while defining the CTV. Additionally, the recommended treatment technique, dose, and fractionation are generally aligned with those used in radical radiation therapy for recurrent NPC.⁶¹ Precision radiation therapy is most commonly delivered using IMRT under image guidance, which is widely available worldwide. The optimal approach would be to deliver an equivalent dose in 2 Gy fractions (EQD2) of 60 Gy,⁶² preferably utilizing hyperfractionation (twice daily), if possible.^{63,64} However, conventional fractionation may also be considered, especially in resource-limited conditions. Dose constraints for OARs and considerations of late toxicities can be found in our previous recommendations.⁶¹

Recent high-level evidence supports the use of hyperfractionated IMRT, which is expected to reduce the incidence of severe late complications and improve OS in patients with

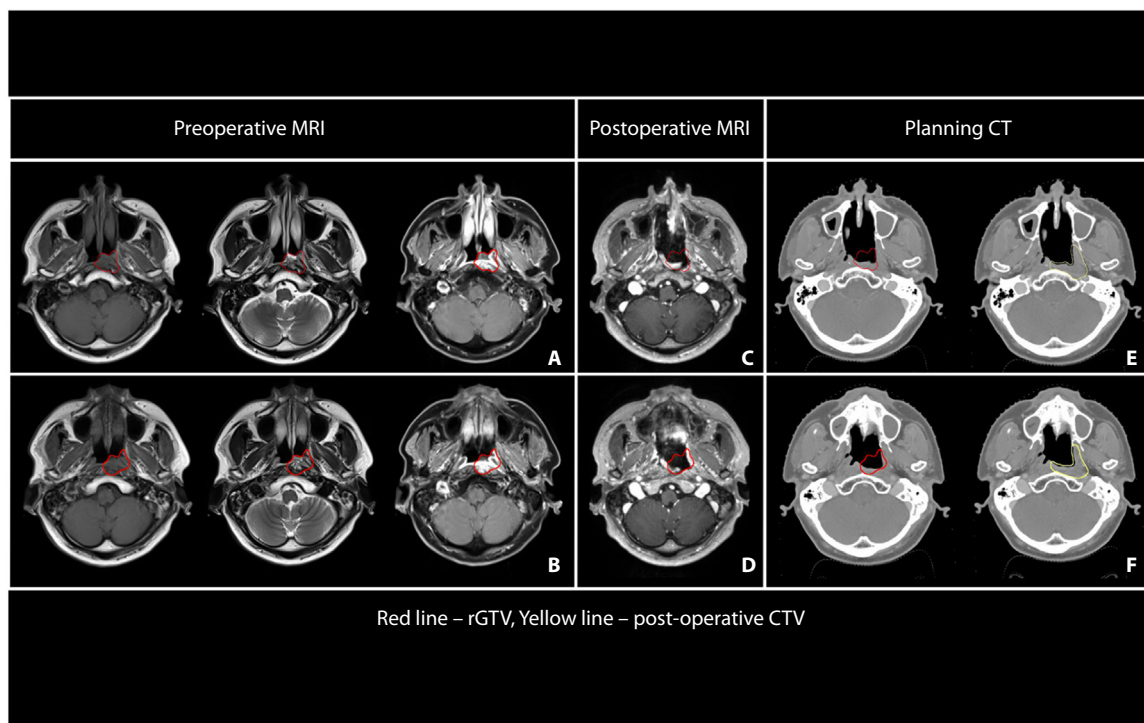


Fig. 3. Illustration of postoperative clinical target volume (CTV) delineation. (A, B) Pre-operative MR images show a patient with a recurrent T2 tumor involving the nasopharynx and prevertebral muscle. Endoscopic resection was performed, and postoperative re-irradiation was offered due to a resection margin of less than 1 mm at the posterolateral deep margin. The recurrent gross tumor (rGTV) is depicted by the red line. (C, D) Postoperative MRI appearance after endoscopic resection. The corresponding location of the pre-operative rGTV is depicted by the red line. (E, F) The corresponding location of the pre-operative rGTV is depicted in the planning CT (red line). The postoperative CTV delineated by expanding the postoperative tumor bed based on the location of the pre-operative tumor with an approximately 5-mm expansion, taking into consideration the area of concern regarding the resection margin status, followed by anatomical editing to exclude air and natural barriers (depicted by the yellow line).

locally advanced recurrent NPC. In a trial that randomly assigned 144 patients to receive hyperfractionation (65 Gy in 54 fractions, given twice daily) or standard fractionation (60 Gy in 27 fractions, given once a day), the hyperfractionation group exhibited a significantly lower incidence of grade 3 or worse late radiation-induced toxicity (34% vs 57%) and better 3-year OS (74.6% vs 55.0%) than the standard fractionation group after a median follow-up of 45.0 months. Moreover, the hyperfractionation group experienced a lower occurrence of grade 5 late complications (7% vs 24%) when compared to its counterpart.⁶⁵ Similar promising results were also observed among patients using hypofractionated stereotactic body radiation therapy (SBRT). For example, a retrospective study involving 51 patients with locally recurrent NPC showed that the 2-year cancer-specific survival rates were 64% for the robotic SBRT arm and 47% for the 3-dimensional conformal radiation therapy (3D-CRT) arm ($P = .4$), and the SBRT group had significantly fewer serious late toxicities (grade 3 and above) than the 3D-CRT arm (21% vs 48%, $P = .04$).⁶⁶ The SBRT treatment was delivered using CyberKnife, with patients in the SBRT arm receiving a dose of 30 Gy over 5 consecutive days. The median follow-up period was 24 months. However, it is important to note that the 3D-CRT used in the study might not be the most updated technology. This may potentially exaggerate the effectiveness of SBRT. Furthermore, individual experiences with SBRT should be taken into account, because some studies have reported noticeable negative late effects on vasculature, bone, and soft tissues at 2 to 3 years, particularly for large-volume treatments or in proximity to oropharyngeal or laryngeal soft tissues.⁶⁷ Nevertheless, both studies focused on salvage treatment with re-RT to intact tumors and may not be directly applied to the postoperative setting. Emerging technologies such as proton therapy might offer additional advantages over IMRT.^{68–70} Further research would be mandatory to explore these emerging treatment approaches and evaluate their efficacy in managing recurrent NPC.

Recommendations that received a positive consensus under the category of “Method and dose for postoperative re-RT” include the following:

- CTV should include the postoperative tumor bed with a 5 mm margin (to account for microscopic disease extension) while respecting the adjacent critical OARs.
- A dose of ≥ 60 Gy (in EQD2) should be given, but should not exceed 66 Gy (EQD2).
- Conventional fractionation is an acceptable treatment technique in the postoperative setting.
- Doses >2 Gy per fraction should be avoided.

Further consideration on the combined treatment for locally recurrent NPC

Systemic therapy plays a crucial role in the treatment of NPC, serving as induction therapy, concurrent therapy with radiation therapy, adjuvant/maintenance therapy in the

primary setting, and palliative intent in recurrent disease. With the advent of immunotherapy, the combination of checkpoint inhibitors and the cisplatin/gemcitabine regimen has emerged as the first-line systemic treatment for recurrent/metastatic NPC in clinical trials such as JUPITER-02,⁷¹ CAPTAIN-1st,⁷² and RATIONALE-309.⁷³ However, because of the lack of concrete evidence regarding the use of systemic treatment after resection of locally recurrent NPC, this aspect was not considered in the Delphi consensus process for this study. Further exploration is needed to better understand the incorporation of systemic treatment in this context.

In the concurrent setting, several treatment options have been suggested, such as cisplatin⁷⁴ or weekly docetaxel and cetuximab.⁷⁵ A single-arm, phase II trial demonstrated that the combination of toripalimab and IMRT was well-tolerated and showed promising antitumor activity in patients with recurrent NPC.⁷⁶ Limited data also suggested the potential benefits of combining SBRT with immunotherapy.^{77,78} Additionally, ongoing phase II clinical trials (NCT05011227, NCT05092217, NCT04778956, NCT05350891) are currently investigating the benefits of applying immunotherapy as induction and/or adjuvant therapy after endoscopic resection for recurrent NPC. These trials may help shed light on the optimal integration of systemic therapy in resectable locally recurrent NPC.

Conclusions

The 2-round Delphi survey demonstrated a high consensus regarding the expanded criteria of resectability. Whenever feasible, en bloc resection should be the preferred approach, although piece-meal removal may be necessary, particularly for infiltrative recurrence. A margin that is ≤ 1 mm but does not actually involve the margin should be classified as a “close” margin rather than a “positive” margin, and postoperative re-RT was recommended when the margin is ≤ 1 mm. The most optimal postoperative re-RT approach was to deliver an equivalent dose to the tumor bed of EQD2 of 60 Gy, preferably using hyperfractionation (twice daily). This treatment regimen has shown strikingly favorable outcomes in the nonoperated re-RT setting. However, the effectiveness of techniques such as the combined use of immunotherapy or novel systemic approaches with SBRT and proton or other heavy ion therapy is currently being investigated. Further research is needed to fully understand the efficacy and benefits of these emerging approaches in the management of recurrent NPC.

References

1. Tian Y, Huang WZ, Zeng L, Bai L, Han F, Lan Y. The failure patterns of nasopharyngeal carcinoma after intensity-modulated radiotherapy and implications for surveillance. *Cancer Manag Res* 2022;14:2813-2823.

2. Chen S, Yang D, Liao X, et al. Failure patterns of recurrence and metastasis after intensity-modulated radiotherapy in patients with nasopharyngeal carcinoma: Results of a multicentric clinical study. *Front Oncol* 2021;11 693199.
3. Kong F, Ying H, Du C, et al. Patterns of local-regional failure after primary intensity modulated radiotherapy for nasopharyngeal carcinoma. *Radiat Oncol* 2014;9:60.
4. Liu X, Wu B, Huang J, et al. Tumor factors associated with in-field failure for nasopharyngeal carcinoma after intensity-modulated radiotherapy. *Head Neck* 2022;44:876-888.
5. Ng WT, Lee MCH, Hung WM, et al. Clinical outcomes and patterns of failure after intensity-modulated radiotherapy for nasopharyngeal carcinoma. *Int J Radiat Oncol Biol Phys* 2011;79:420-428.
6. Lee AWM, Ng WT, Chan JYW, et al. Management of locally recurrent nasopharyngeal carcinoma. *Cancer Treat Rev* 2019;79 101890.
7. Li G, Wang J, Tang H, et al. Comparing endoscopic surgeries with open surgeries in terms of effectiveness and safety in salvaging residual or recurrent nasopharyngeal cancer: systematic review and meta-analysis. *Head Neck* 2020;42:3415-3426.
8. Page MJ, McKenzie JE, Bossuyt PM, et al. The PRISMA 2020 statement: An updated guideline for reporting systematic reviews. *Int J Surg* 2021;88 105906.
9. Alonso-Coello P, Schünemann HJ, Moher J, et al. GRADE Evidence to Decision (EtD) frameworks: A systematic and transparent approach to making well informed healthcare choices. 1: Introduction. *BMJ* 2016;353:i2016.
10. Milholland AV, Wheeler SG, Heieck JJ. Medical assessment by a Delphi group opinion technic. *N Engl J Med* 1973;288:1272-1275.
11. Boukaid R, Abdoul H, Loustau M, Sibony O, Alberti C. Using and reporting the Delphi method for selecting healthcare quality indicators: A systematic review. *PLOS ONE* 2011;6:e20476.
12. Finegersh A, Said M, Deconde A, et al. Open and endoscopic surgery improve survival for squamous and nonsquamous cell nasopharyngeal carcinomas: an NCDB cohort study. *Int Forum Allergy Rhinol* 2022;12:1350-1361.
13. Li W, Lu H, Wang H, et al. Salvage endoscopic nasopharyngectomy in recurrent nasopharyngeal carcinoma: prognostic factors and treatment outcomes. *Am J Rhinol Allergy* 2021;35:458-466.
14. Tao ZQ, Si YF, Lan SY, et al. Choice of surgical approaches for salvage surgery of primary lesion recurrence and residual cases of nasopharyngeal carcinoma. *Zhonghua Er Bi Yan Hou Tou Jing Wai Ke Za Zhi* 2011;46:108-113.
15. Thamboo A, Patel VS, Hwang PH. 5-year outcomes of salvage endoscopic nasopharyngectomy for recurrent nasopharyngeal carcinoma. *J Otolaryngol Head Neck Surg* 2021;50:12.
16. Liu YP, Wen YH, Tang J, et al. Endoscopic surgery compared with intensity-modulated radiotherapy in resectable locally recurrent nasopharyngeal carcinoma: A multicentre, open-label, randomised, controlled, phase 3 trial. *Lancet Oncol* 2021;22:381-390.
17. Diamond IR, Grant RC, Feldman BM, et al. Defining consensus: A systematic review recommends methodologic criteria for reporting of Delphi studies. *J Clin Epidemiol* 2014;67:401-409.
18. Liu J, Yu H, Sun X, et al. Salvage endoscopic nasopharyngectomy for local recurrent or residual nasopharyngeal carcinoma: A 10-year experience. *Int J Clin Oncol* 2017;22:834-842.
19. Lee VH, Au JSK, Mu JW, et al. Real-world perspectives from surgeons and oncologists on resectability definition and multidisciplinary team discussion of stage III NSCLC in People's Republic of China, Hong Kong, and Macau: A physician survey. *JTO Clin Res Rep* 2022;3 100308.
20. Chan JYW, Wong STS, Chan RCL, Wei WI. Extracranial/intracranial vascular bypass and craniofacial resection: New hope for patients with locally advanced recurrent nasopharyngeal carcinoma. *Head Neck* 2016;38:E1404-E1412.
21. Wong EHC, Liew YT, Abu Bakar MZ, Lim EYL, Prepageran N. A preliminary report on the role of endoscopic endonasal nasopharyngectomy in recurrent rT3 and rT4 nasopharyngeal carcinoma. *Eur Arch Otorhinolaryngol* 2017;274:275-281.
22. Wong EHC, Liew YT, Loong SP, Prepageran N. Five-year survival data on the role of endoscopic endonasal nasopharyngectomy in advanced recurrent rT3 and rT4 nasopharyngeal carcinoma. *Ann Otol Rhinol Laryngol* 2020;129:287-293.
23. Peng Z, Wang Y, Wang Y, et al. Comparing the effectiveness of endoscopic surgeries with intensity-modulated radiotherapy for recurrent rT3 and rT4 nasopharyngeal carcinoma: A meta-analysis. *Front Oncol* 2021;11 703954.
24. Song B, Kim HY, Jung YG, Baek C-H, Chung MK, Hong SD. Endoscopic debridement of post-radiation nasopharyngeal necrosis: The effects of resurfacing with a vascularized flap. *Clin Exp Otorhinolaryngol* 2022;15:354-363.
25. Hadad G, Bassagasteguy L, Carrau RL, et al. A novel reconstructive technique after endoscopic expanded endonasal approaches: Vascular pedicle nasoseptal flap. *Laryngoscope* 2006;116:1882-1886.
26. Gan JY, Yeo MSW, Fu EWZ, Tan NC, Lim M. Surgery N. Reconstruction of nasopharynx defect using a free flap after endoscopic nasopharyngectomy—Feasibility and technical considerations. 2021;147:104-106.
27. Li W, Liu Q, Wang H, et al. Innovative application of internal carotid artery embolization in salvage endoscopic nasopharyngectomy for recurrent nasopharyngeal carcinoma: A case-matched comparison. *Int Forum Allergy Rhinol* 2022;12:838-848.
28. Wang ZQ, Xie YL, Liu YP, et al. Endoscopic nasopharyngectomy combined with internal carotid artery pretreatment for recurrent nasopharyngeal carcinoma. *Otolaryngol Head Neck Surg* 2022;166:490-497.
29. Chan JYW, To VSH, Chow VLY, Wong STS, Wei WI. Multivariate analysis of prognostic factors for salvage nasopharyngectomy via the maxillary swing approach. *Head Neck* 2014;36:1013-1017.
30. Chan JYW, Wong STS, Wei WIJC. The role of Epstein-Barr virus—encoded microRNA BART7 status of resection margins in the prediction of local recurrence after salvage nasopharyngectomy for recurrent nasopharyngeal carcinoma. *Cancer* 2015;121:2358-2366.
31. Hsu NI, Shen PH, Chao SS, Ong YK, Li CS. En bloc resection concept for endoscopic endonasal nasopharyngectomy: Surgical anatomy and outcome. *Chin Med J (Engl)*. 2014;127:2934-2939.
32. Jiang S, Fan R, Zhang H, Jiang W, Xie Z. Outcomes of endoscopic and open resection of sinonasal malignancies: A systematic review and meta-analysis. *Braz J Otorhinolaryngol*. 2022;88:S19-S31.
33. Abdelmeguid AS, Raza SM, Su SY, et al. Endoscopic resection of sinonasal malignancies. *Head Neck* 2020;42:645-652.
34. Chan RC, Ho SL, Chan JY. Accuracy of intraoperative frozen section analysis of nasopharyngeal carcinoma resection margins. *Head Neck* 2014;36:638-642.
35. Chen MY, Wen WP, Han DM, et al. The consensus recommendation of surgical treatment for nasopharyngeal cancer. *Zhonghua Er Bi Yan Hou Tou Jing Wai Ke Za Zhi* 2023;58:533-543 [in Chinese].
36. Vlantis AC, Tsang RK, Yu BK, et al. Nasopharyngectomy and surgical margin status: a survival analysis. *Arch Otolaryngol Head Neck Surg* 2007;133:1296-1301.
37. Chan JYW, Wei WI. Impact of resection margin status on outcome after salvage nasopharyngectomy for recurrent nasopharyngeal carcinoma. *Head Neck* 2016;38:E594-E599.
38. Xiao A, Liu D, He D, Lu X, Ostrikov KK. Plasma scalpels: Devices, diagnostics, and applications. *Biomedicine* 2022;10:2967.
39. Bian X, Chen H, Liao L. A retrospective study of salvage surgery for recurrent nasopharyngeal carcinoma. *Int J Clin Oncol* 2012;17:212-217.
40. Bridger GP, Smee R, Baldwin MA, Bridger AG. Salvage nasopharyngectomy for radiation recurrences. *ANZ J Surg* 2005;75:1065-1069.
41. Chan JYW, Chow VLY, Tsang R, Wei WI. Nasopharyngectomy for locally advanced recurrent nasopharyngeal carcinoma: Exploring the limits. *Head Neck* 2012;34:923-928.
42. Chan JYW, Wei WI. Critical appraisal of maxillary swing approach for nasopharyngeal carcinoma. *Expert Opin Ther Targets* 2012;16:S111-S117.
43. Chang KP, Hao SP, Tsang NM, Ueng SH. Salvage surgery for locally recurrent nasopharyngeal carcinoma—A 10-year experience. *Otolaryngol Head Neck Surg* 2004;131:497-502.

44. Chen C, Fee W, Chen J, et al. Salvage treatment for locally recurrent nasopharyngeal carcinoma (NPC). *Am J Clin Oncol* 2014;37:327-331.
45. Choi JY, Lee WS. Curative surgery for recurrent nasopharyngeal carcinoma via the infratemporal fossa approach. *Arch Otolaryngol Head Neck Surg* 2005;131:213-216.
46. Fee Jr WE, Moir MS, Choi EC, Goffinet D. Nasopharyngectomy for recurrent nasopharyngeal cancer: A 2- to 17-year follow-up. *Arch Otolaryngol Head Neck Surg* 2002;128:280-284.
47. Hao SP, Tsang NM, Chang CN. Salvage surgery for recurrent nasopharyngeal carcinoma. *Arch Otolaryngol Head Neck Surg* 2002;128:63-67.
48. Hall CEJ, Harris R, A'Hern R, et al. Le Fort I osteotomy and low-dose rate Ir192 brachytherapy for treatment of recurrent nasopharyngeal tumours. *Radiother Oncol* 2003;66:41-48.
49. Hao SP, Tsang NM, Chang KP, Hsu YS, Chen CK, Fang KH. Nasopharyngectomy for recurrent nasopharyngeal carcinoma: A review of 53 patients and prognostic factors. *Acta Otolaryngol* 2008;128:473-481.
50. Hsu MM, Hong RL, Ting LL, Ko JY, Sheen TS, Lou PJ. Factors affecting the overall survival after salvage surgery in patients with recurrent nasopharyngeal carcinoma at the primary site: Experience with 60 cases. *Arch Otolaryngol Head Neck Surg* 2001;127:798-802.
51. King WW, Ku PK, Mok CO, Teo PM. Nasopharyngectomy in the treatment of recurrent nasopharyngeal carcinoma: A twelve-year experience. *Head Neck* 2000;22:215-222.
52. Ng LS, Lim CM, Loh KS. Long-term outcomes of nasopharyngectomy using partial maxillectomy approach. *Laryngoscope* 2016;126:1103-1107.
53. Shu CH, Cheng H, Lirng JF, et al. Salvage surgery for recurrent nasopharyngeal carcinoma. *Laryngoscope* 2000;110:1483-1488.
54. To EWH, Lai ECH, Cheng JHH, Pang PCW, Williams MD, Teo PML. Nasopharyngectomy for recurrent nasopharyngeal carcinoma: A review of 31 patients and prognostic factors. *Laryngoscope* 2002;112:1877-1882.
55. Chan JYW, Wei WIJ. Recurrent nasopharyngeal carcinoma after salvage nasopharyngectomy. *Arch Otolaryngol Head Neck Surg* 2012;138:572-576.
56. Na'ara S, Amit M, Billan S, Cohen JT, Gil Z. Outcome of patients undergoing salvage surgery for recurrent nasopharyngeal carcinoma: A meta-analysis. *Ann Surg Oncol* 2014;21:3056-3062.
57. Ng WT, Wong ECY, Cheung AKW, et al. Patterns of care and treatment outcomes for local recurrence of NPC after definite IMRT—A study by the HKNPCSG. *Head Neck* 2019;41:3661-3669.
58. Feng Y, Dai Z, Yan R, et al. Outcomes of recurrent nasopharyngeal carcinoma patients treated with salvage surgery: A meta-analysis. *Front Oncol* 2021;11 720418.
59. Kong L, Lu JJ. Reirradiation of locally recurrent nasopharyngeal cancer: History, advances, and promises for the future. *Chin Clin Oncol* 2016;5:26.
60. Chen MY, Wang SL, Zhu YL, et al. Use of a posterior pedicle nasal septum and floor mucoperiosteum flap to resurface the nasopharynx after endoscopic nasopharyngectomy for recurrent nasopharyngeal carcinoma. *Head Neck* 2012;34:1383-1388.
61. Ng WT, Soong YL, Ahn YC, et al. International recommendations on reirradiation by intensity modulated radiation therapy for locally recurrent nasopharyngeal carcinoma. *Int J Radiat Oncol Biol Phys* 2021;110:682-695.
62. Ng WT, Lee MC, Fung NT, et al. Dose volume effects of re-irradiation for locally recurrent nasopharyngeal carcinoma. *Head Neck* 2020;42:180-187.
63. Lee AW, Foo W, Law SC, et al. Reirradiation for recurrent nasopharyngeal carcinoma: factors affecting the therapeutic ratio and ways for improvement. *Int J Radiat Oncol Biol Phys* 1997;38:43-52.
64. Lee AW, Foo W, Law SC, et al. Total biological effect on late reactive tissues following reirradiation for recurrent nasopharyngeal carcinoma. *Int J Radiat Oncol Biol Phys* 2000;46:865-872.
65. You R, Liu YP, Xie YL, et al. Hyperfractionation compared with standard fractionation in intensity-modulated radiotherapy for patients with locally advanced recurrent nasopharyngeal carcinoma: A multicentre, randomised, open-label, phase 3 trial. *Lancet* 2023;401:917-927.
66. Ozyigit G, Cengiz M, Yazici G, et al. A retrospective comparison of robotic stereotactic body radiotherapy and three-dimensional conformal radiotherapy for the reirradiation of locally recurrent nasopharyngeal carcinoma. *Int J Radiat Oncol Biol Phys* 2011;81:e263-e268.
67. Ling DC, Vargo JA, Ferris RL, et al. Risk of severe toxicity according to site of recurrence in patients treated with stereotactic body radiation therapy for recurrent head and neck cancer. *Int J Radiat Oncol Biol Phys* 2016;95:973-980.
68. Kong L, Hu J, Guan X, Gao J, Lu R, Lu JJ. Phase I/II trial evaluating carbon ion radiotherapy for salvaging treatment of locally recurrent nasopharyngeal carcinoma. *J Cancer* 2016;7:774-783.
69. Dionisi F, Croci S, Giacomelli I, et al. Clinical results of proton therapy reirradiation for recurrent nasopharyngeal carcinoma. *Acta Oncol* 2019;58:1238-1245.
70. Hu J, Bao C, Gao J, et al. Salvage treatment using carbon ion radiation in patients with locoregionally recurrent nasopharyngeal carcinoma: initial results. *Cancer* 2018;124:2427-2437.
71. Mai HQ, Chen QY, Chen D, et al. Toripalimab plus chemotherapy for recurrent or metastatic nasopharyngeal carcinoma: The JUPITER-02 randomized clinical trial. *JAMA* 2023;330:1961-1970.
72. Yang Y, Qu S, Li J, et al. Camrelizumab versus placebo in combination with gemcitabine and cisplatin as first-line treatment for recurrent or metastatic nasopharyngeal carcinoma (CAPTAIN-1st): A multicentre, randomised, double-blind, phase 3 trial. *Lancet Oncol* 2021;22:1162-1174.
73. Yang Y, Pan J, Wang H, et al. Tislelizumab plus chemotherapy as first-line treatment for recurrent or metastatic nasopharyngeal cancer: A multicenter phase 3 trial (RATIONALE-309). *Cancer Cell* 2023;41:1061-1072.e4.
74. Guan Y, Liu S, Wang HY, et al. Long-term outcomes of a phase II randomized controlled trial comparing intensity-modulated radiotherapy with or without weekly cisplatin for the treatment of locally recurrent nasopharyngeal carcinoma. *Chin J Cancer* 2016;35:20.
75. Ng WT, Ngan RKC, Kwong DLW, et al. Prospective, multicenter, phase 2 trial of induction chemotherapy followed by bio-chemoradiotherapy for locally advanced recurrent nasopharyngeal carcinoma. *Int J Radiat Oncol Biol Phys* 2018;100:630-638.
76. Hua Y, You R, Wang Z, et al. Toripalimab plus intensity-modulated radiotherapy for recurrent nasopharyngeal carcinoma: An open-label single-arm, phase II trial. *J Immunother Cancer* 2021;9 e003290.
77. Wu JS, Jen CW, Chen HH, Cheng SH. Stereotactic body radiotherapy and checkpoint inhibitor for locally recurrent unresectable nasopharyngeal carcinoma. *BMJ Case Rep* 2021;14 e240806.
78. Lin J, Guo Q, Guo Z, et al. Stereotactic body radiotherapy extends the clinical benefit of PD-1 inhibitors in refractory recurrent/metastatic nasopharyngeal carcinoma. *Radiat Oncol* 2022;17:117.