



**HAL**  
open science

## Response to the article "The tube-in-tube thoracodorsal perforator flap phalloplasty"

G. Henry, D. Carnicelli, N. Morel Journal, A. Mojallal, F. Boucher

### ► To cite this version:

G. Henry, D. Carnicelli, N. Morel Journal, A. Mojallal, F. Boucher. Response to the article "The tube-in-tube thoracodorsal perforator flap phalloplasty". *Annales de Chirurgie Plastique Esthétique*, 2024, 69 (4), pp.331-336. 10.1016/j.anplas.2024.03.001 . inserm-04661751

**HAL Id: inserm-04661751**

**<https://inserm.hal.science/inserm-04661751v1>**

Submitted on 25 Jul 2024

**HAL** is a multi-disciplinary open access archive for the deposit and dissemination of scientific research documents, whether they are published or not. The documents may come from teaching and research institutions in France or abroad, or from public or private research centers.

L'archive ouverte pluridisciplinaire **HAL**, est destinée au dépôt et à la diffusion de documents scientifiques de niveau recherche, publiés ou non, émanant des établissements d'enseignement et de recherche français ou étrangers, des laboratoires publics ou privés.



Available online at  
**ScienceDirect**  
[www.sciencedirect.com](http://www.sciencedirect.com)

Elsevier Masson France  
**EM|consulte**  
[www.em-consulte.com](http://www.em-consulte.com)



LETTER TO THE EDITOR

**Response to the article “The tube-in-tube thoracodorsal perforator flap phalloplasty”**

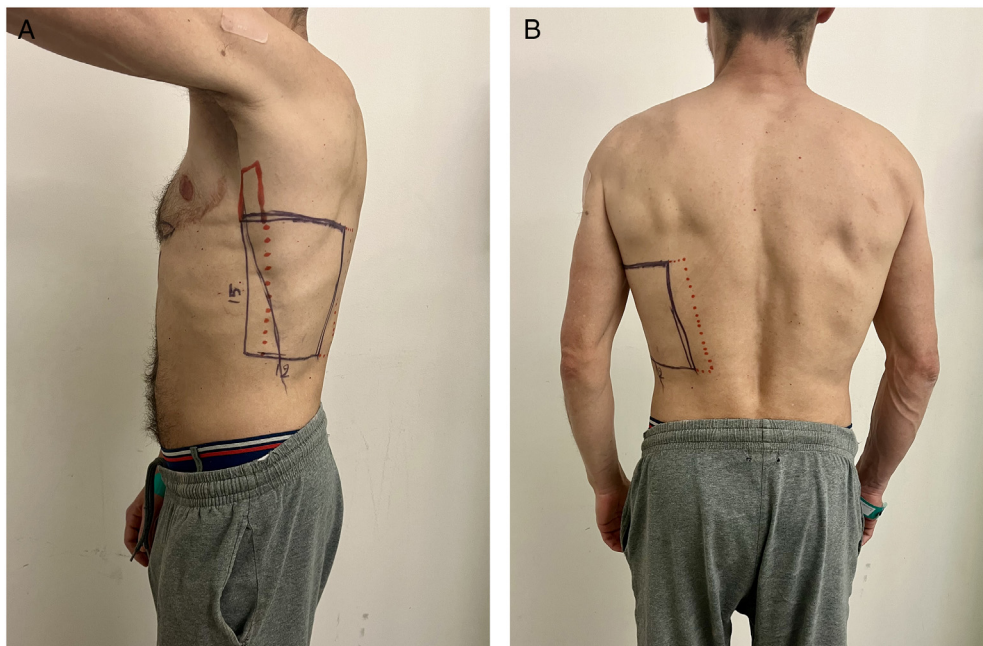


Dear Marque M. *et al.*,

We appreciate your initial description of dorsal phalloplasty “tube within the tube” [1]. This enhancement of the dorsal harvesting technique allows for the integration of advantages similar to those of the gold standard radial forearm free flap [2,3], such as creating the urethra in the initial surgical step, thereby reducing the total number of procedures required for complete neophallus reconstruction while providing aesthetically satisfactory results for the reconstructed phallus and minimizing scars and distortions at the recipient site. In addition to these benefits, dorsal techniques, with limited morbidity at the donor site, are less stigmatizing and facilitate the attainment of more sub-

stantial phallus lengths. This case report helps bring dorsal phalloplasty closer to the gold standard by balancing the sensitivity finesse of the neophallus with the morbidity of the harvesting site of the two flaps.

Few years ago, we presented our management algorithm, recommending dorsal phalloplasty in cases where ante-brachial phalloplasty is contraindicated, such as a negative Allen test, inadequate tissue thickness for subsequent erectile prosthesis insertion, and intolerance to the scarring associated with flap harvesting. Additionally, this approach is advocated in the presence of contraindications specific to harvesting an anterolateral thigh flap, such as excessive adipose tissue thickness or the absence of perforators identified during preoperative mapping. This dorsal technique was often chosen as a tertiary intervention [4]. However, it is crucial to qualify this decision tree based on the patient’s expectations regarding standing urination, penetration, neophallus size, and the willingness to accept the risk of microsurgical failure.



**Figure 1** Preoperative marking, (a) profile view, (b) dorsal view, the blue marking corresponds to the drawing of a conventional dorsal phalloplasty skin paddle, while the red marking corresponds to a dorsal tube-in-tube skin paddle.

On one hand, the implantation of erectile prostheses is conditioned by the adipo-cutaneous thickness of the forearm for this technique, and excessive thinness is a contraindication. On the other hand, an adipo-cutaneous thickness greater than 1 cm makes it difficult, if not impossible, to shape a tube-in-tube flap from the thigh donor site [5], and this consideration appears to be transferable to the dorsal region. Subcutaneous tissue thickness is correlated with skinfold and BMI, without specificity of body location [6]. In the case of excessively thin adipose tissue at the forearm, it is therefore possible to find a thickness compatible with a dorsal tube-in-tube flap and thus, a continuum of these indications.

We describe herein the utilization of a variant to that presented by Marque et al., involving a muscle-sparing latissimus dorsi flap configured in a tube-in-tube manner to discuss its advantages and disadvantages.

The case is a 45-year-old female-to-male transgender individual who initiated a transition in 2012, involving hormone therapy and masculinizing mastectomy in 2014, followed by a total hysterectomy in 2019. This patient has a history of intravenous drug abuse, potentially compromising the venous capital of the forearm, prompting a preference for an alternative phalloplasty technique.

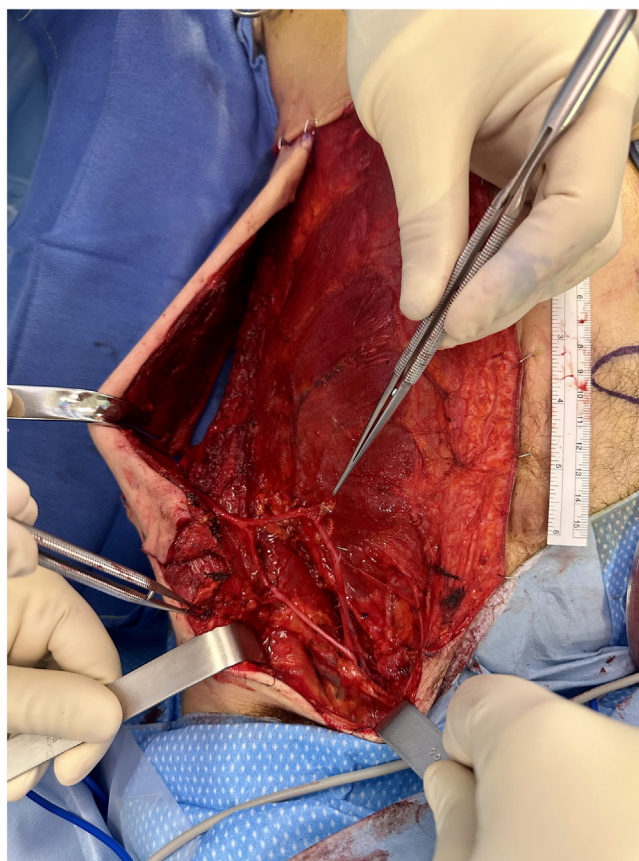
The preoperative drawing was performed upon the patient's hospital admission, in an upright position, on the non-dominant side. The anterior border of the Latissimus Dorsi muscle was identified, along with the level of the

scapula's tip. The drawing of the skin paddle in a tube-in-tube fashion was executed slightly above this level to encompass the lateral perforator cluster zone [7] while allowing the part of the paddle intended for the urethra to extend beyond the anterior edge of the muscle, facilitating its future conformation (Fig. 1).

The initial patient positioning involved a supine arrangement with a paravertebral support on the side selected for flap harvesting, complemented by upper limb support on the contralateral side to expose the axillary region. Additionally, a gynecological position was adopted to facilitate surgical perineal phase. This setup facilitated dual-team work.

The flap harvest commenced from the anterior edge, spanning its entire length to the thoracic wall. This method facilitated the identification of the dissection plane between the Serratus and Latissimus Dorsi muscles. The dissection in this space extended posteriorly for a few centimeters, revealing the descending branch of the pedicle and its bifurcation with the horizontal branch.

The thoracodorsal vascular pedicle was then located and dissected to its origin on the subscapular artery. Careful separation from the thoracodorsal nerve was maintained along the entire length of the pedicle. Collateral branches were precisely clipped, and the horizontal division of the pedicle was also ligatured, while preserving the integrity of the accompanying nerve. The accompanying nerve of the descending branch was deliberately sectioned. The projection of this descending branch onto the skin paddle served as



**Figure 2** View of the dissection of the pedicle, individualized nerve, and the skin paddle.

a guide for subsequent steps. The paddle was incised along its edges and skillfully lifted within the plane of the dorsal fascia, moving from posterior to anterior. This process halted just before reaching the projection of the descending branch. The muscle was then sectioned from distal to proximal with the descending branch under visual control at the deep face of the muscle. A minimum distance of 1 cm was maintained from vessels, and the sectioning occurred below the nerve bifurcation (Fig. 2). Subsequently, the neophallus was shaped on-site, following the de-epidermization of the strip separating the two paddles. Suturing of the two tubes was meticulously performed over a size 16 urinary catheter (Fig. 3).

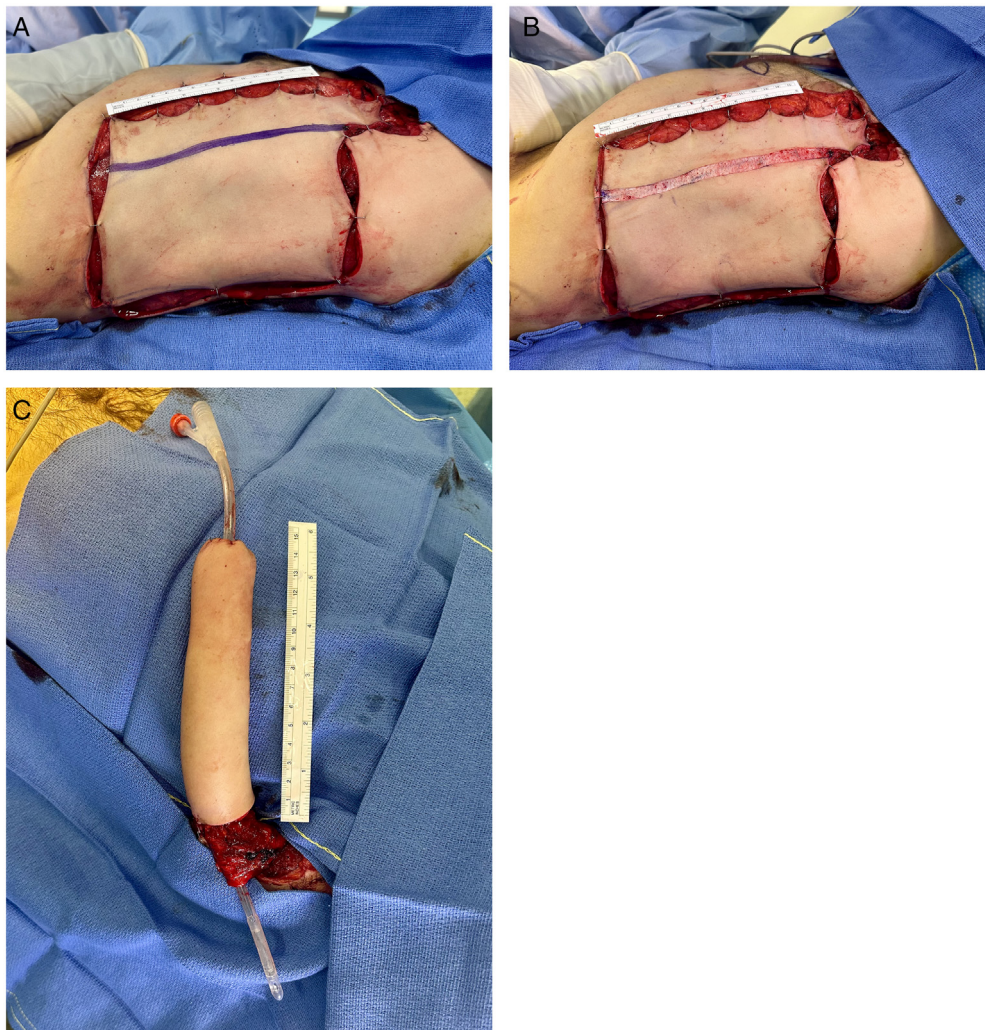
Simultaneously, the perineal component was performed in tandem with the preparation of the deep inferior epigastric vessels through an inguinal counter-incision, following a similar approach as described in the study by Marque et al.

Microsurgical anastomoses were subsequently executed between the artery and vein of the thoracodorsal flap and the deep inferior epigastric artery and vein (Fig. 4). Management of the neourethra and clitoral burial followed the procedures outlined by our colleagues.

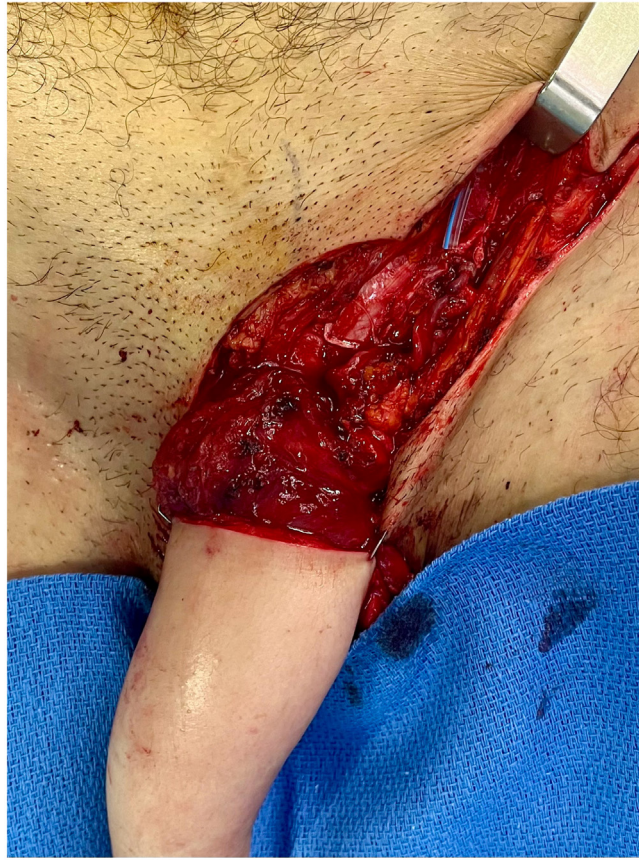Given the non-self-closing nature of the recipient site, the central region was grafted with a combination of a thin skin graft and a single-layer artificial dermis (Fig. 5).

The patient experienced a smooth postoperative course, allowing for discharge on Day 10. The patient was reevaluated at 6 weeks postoperatively with no complications in the healing process and expressed contentment with the overall procedure (Fig. 6).

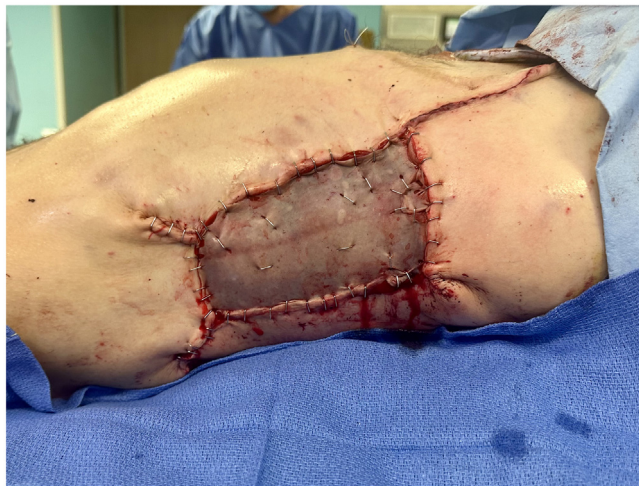Our adaptation of the dorsal tube-in-tube technique, inspired by the model described by Marque et al., offers several notable advantages. It eliminates the need for preoperative identification of perforators, thereby obviating the requirement for expertise in preoperative Doppler ultrasonography. This modification also allows for increased flexibility in positioning the skin paddle, reducing its dependence on the anatomical variations of the perforators. The same team had previously outlined their harvesting technique for the thoracodorsal artery perforator flap a few years ago, incorporating a 2 cm muscular cuff to reduce operative time by avoiding an extended perforator dissection and enhancing venous drainage [8]. The utilization of a muscle-sparing Latissimus Dorsi flap in the current approach further sim-



**Figure 3** Flap before and after conformation, (a) drawing of the de-epidermization zone, (b) de-epidermized strip, (c) flap conformed in a tube-in-tube configuration.



**Figure 4** Anastomosis on the deep inferior epigastric vessels.



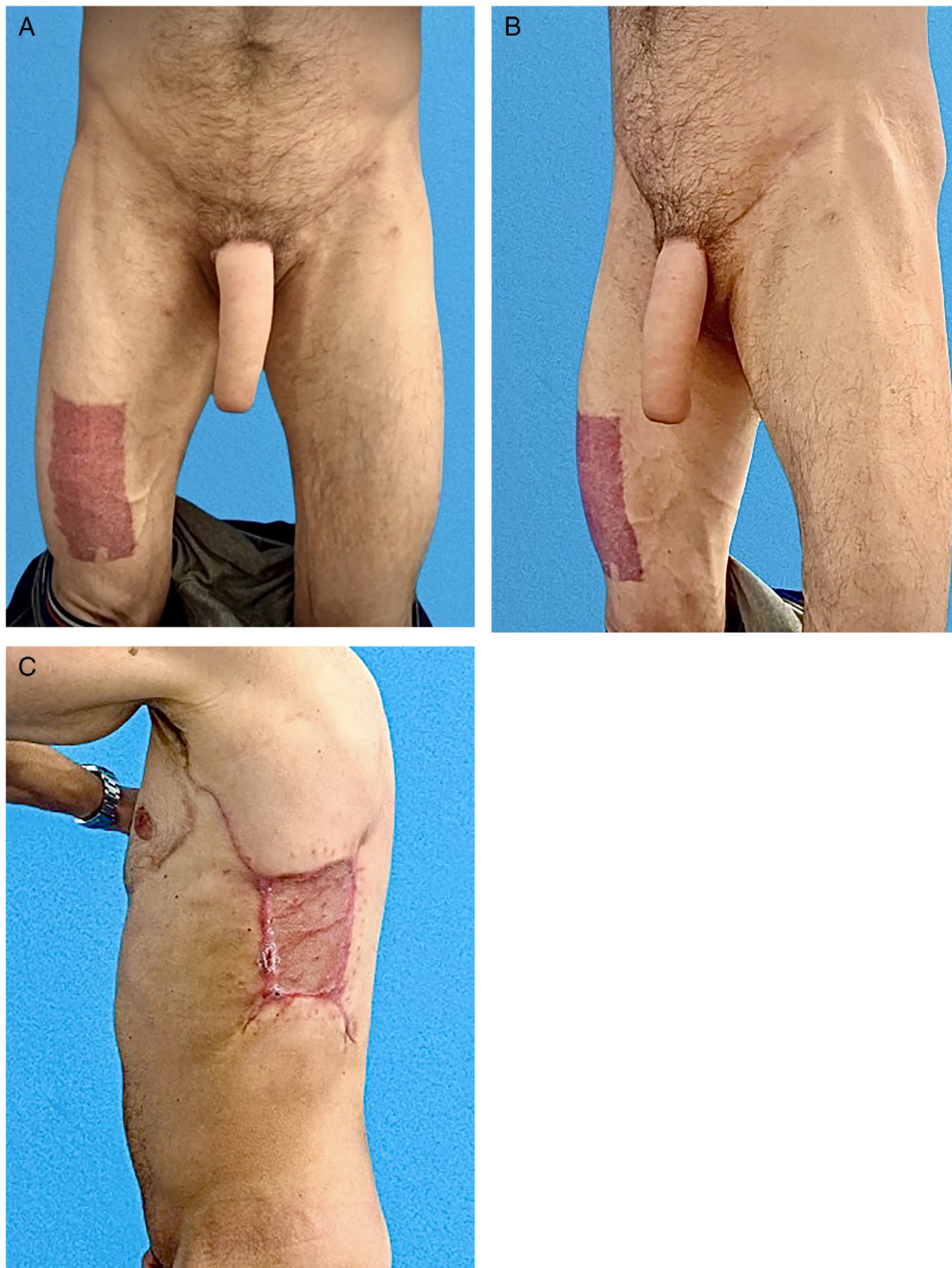**Figure 5** Grafted non-self-closing donor site.

plifies the harvest by abstaining from the identification and dissection of perforators, without significantly increasing morbidity [9,10]. Additionally, this approach mitigates any risk to the perforators during the plication, especially concerning the urethral paddle.

However, a drawback associated with our method is the potential addition of thickness to the flap, which could impede the folding of the tube within the tube. Neverthe-

less, by opting for a highly selective muscle harvest, we successfully navigated this challenge.

Another consideration is the necessity of grafting the donor site, which is not self-closing, to achieve a flap of similar size to that presented in our colleagues' article. This requirement increases morbidity, leaving a grafted area and adding an additional site for a thin skin graft from the thigh. This limitation may be attributed to the dorsal position with a



**Figure 6** Photographs of the patient at two months postoperative. (a) frontal view, (b)  $\frac{3}{4}$  view, (c) donor site.

paravertebral support, which does not allow as effective closure of the donor site as achieved in the lateral decubitus position. However, it will be more feasible to make adjustments in subsequent interventions to reduce the grafted area.

The dorsal tube-in-tube technique described by Marque et al. aims to bring this approach closer to the “gold standard” ante-brachial technique. We propose a variation of this method that requires less technical expertise in terms of pre- and intra-operative perforator identification, although it may theoretically pose additional challenges during conformation. This description serves to afford

greater consideration to the dorsal technique within our management algorithm.

#### **Disclosure of interest**

The authors declare that they have no competing interest.

#### **Financial disclosure statement**

The authors have no financial interest to declare in relation to the content of this article.

## References

- [1] Marque M, Chartier R, Donette I, Assaf N, Dast S, Sinna R. Phalloplastie par Lambeau perforant thoracodorsal « tube in tube ». *Ann Chir Plast Esthet* 2023;68(4):378–84. <http://dx.doi.org/10.1016/j.anplas.2023.01.003>.
- [2] Morrison SD, Shakir A, Vyas KS, Kirby J, Crane CN, Lee GK. Phalloplasty: a review of techniques and outcomes. *Plast Reconstr Surg* 2016;138(3):594–615. <http://dx.doi.org/10.1097/PRS.0000000000002518>.
- [3] Hu W, Henry AS, Rouanet M, et al. Phallopièse par lambeau antébrachial radial libre dans la chirurgie de réassignation sexuelle femme à homme. *Ann Chir Plast Esthet* 2023;68(5–6):446–54. <http://dx.doi.org/10.1016/j.anplas.2023.08.003>.
- [4] Boucher F, Brosset S, Mojallal AA, Braye F, Chateau J, Morel Journal N. Phalloplastie : options microchirurgicales et algorithme décisionnel. *Ann Chir Plast Esthet* 2017;62(6):617–24. <http://dx.doi.org/10.1016/j.anplas.2017.03.008>.
- [5] Boczar D, Huayllani MT, Saleem HY, et al. Surgical techniques of phalloplasty in transgender patients: a systematic review. *Ann Transl Med* 2021;9(7):607. <http://dx.doi.org/10.21037/atm-20-3527>.
- [6] Ludescher B, Machann J, Eschweiler GW, et al. Correlation of fat distribution in whole body MRI with generally used anthropometric data. *Invest Radiol* 2009;44(11):712–9. <http://dx.doi.org/10.1097/RLI.0b013e3181afbb1e>.
- [7] Boucher F, Mojallal A. Atlas des artères perforantes du tronc et des membres par artère source. In: Atlas des artères perforantes cutanées du tronc et des membres. France: Elsevier; 2015: 11–50. <http://dx.doi.org/10.1016/B978-2-294-73993-4.00003-3>.
- [8] Vaucher R, Dast S, Bout-Roumazeilles A, Herlin C, Bekara F, Sinna R. Technique de prélèvement d'un lambeau perforant thoracodorsal : mise au point. *Ann Chir Plast Esthet* 2019;64(3):266–70. <http://dx.doi.org/10.1016/j.anplas.2018.07.007>.
- [9] Ismaïl M, Boucher F, Chauvel-Picard J, Shipkov H, Braye F, Mojallal A. Séquelles du prélèvement du lambeau de grand dorsal et ses dérivés – Revue de la littérature. *Ann Chir Plast Esthet* 2014;59(5):348–54. <http://dx.doi.org/10.1016/j.anplas.2014.05.002>.
- [10] Lee KT, Mun GH. A systematic review of functional donor-site morbidity after Latissimus Dorsi muscle transfer. *Plast Reconstr Surg* 2014;134(2):303–14. <http://dx.doi.org/10.1097/PRS.0000000000000365>.

Guillaume Henry<sup>a,c</sup>Damien Carnicelli<sup>b,c</sup>Nicolas Morel Journal<sup>b,c</sup>Ali Mojallal<sup>a,c</sup>Fabien Boucher<sup>a,c,\*</sup>

<sup>a</sup>Plastic, Reconstructive, and Aesthetic Surgery Department, hôpital de la Croix-Rousse, hospices civils de Lyon, 69004 Lyon, France

<sup>b</sup>Urology Department, Lyon Sud Hospital Center, hospices civils de Lyon, 69310 Pierre-Bénite, France

<sup>c</sup>Gender Team, hospices civils de Lyon, Lyon, France

\*Corresponding author. Plastic, Reconstructive, and Aesthetic Surgery Department, hôpital de la Croix-Rousse, hospices civils de Lyon, 69004 Lyon, France.

E-mail address: drfabienboucher@icloud.fr (F. Boucher).

Received 12 February 2024

Accepted 6 March 2024