



**HAL**  
open science

## Can novel CT-and MR-based neuroimaging biomarkers further improve the etiological diagnosis of lobar intra-cerebral hemorrhage?

Jean-Claude Baron, Ulf Jensen-Kondering, Simona Sacco, Sacha Posener, Joseph Benzakoun, Johan Pallud, Catherine Oppenheim, Pascale Varlet, Guillaume Turc

### ► To cite this version:

Jean-Claude Baron, Ulf Jensen-Kondering, Simona Sacco, Sacha Posener, Joseph Benzakoun, et al.. Can novel CT-and MR-based neuroimaging biomarkers further improve the etiological diagnosis of lobar intra-cerebral hemorrhage?. *Journal of Neurology*, 2022, 270 (1), pp.582-588. 10.1007/s00415-022-11434-y . inserm-04546079

**HAL Id: inserm-04546079**

**<https://inserm.hal.science/inserm-04546079>**

Submitted on 15 Apr 2024

**HAL** is a multi-disciplinary open access archive for the deposit and dissemination of scientific research documents, whether they are published or not. The documents may come from teaching and research institutions in France or abroad, or from public or private research centers.

L'archive ouverte pluridisciplinaire **HAL**, est destinée au dépôt et à la diffusion de documents scientifiques de niveau recherche, publiés ou non, émanant des établissements d'enseignement et de recherche français ou étrangers, des laboratoires publics ou privés.

## **Can novel CT- and MR-based neuroimaging biomarkers further improve the etiological diagnosis of lobar intra-cerebral hemorrhage?**

**Jean-Claude Baron<sup>1</sup>, Ulf Jensen-Kondering<sup>2</sup>, Simona Sacco<sup>3</sup>, Sacha Posener<sup>1</sup>, Joseph Benzakoun<sup>4</sup>, Johan Pallud<sup>5</sup>, Catherine Oppenheim<sup>4</sup>, Pascale Varlet<sup>6</sup>, Guillaume Turc<sup>1</sup>**

### Affiliations:

1. Dept of Neurology, Groupe Hospitalier Paris Neurosciences et Psychiatrie, Université Paris Cité, Inserm U1266, Institut de Psychiatrie et Neurosciences de Paris
2. Dept of Neuroradiology, University Medical Center Schleswig-Holstein, Campus Lübeck, Lübeck, Germany
3. Dept of Biotechnological and Applied Clinical Sciences - University of L'Aquila, Italy
4. Dept of Neuroradiology, Groupe Hospitalier Paris Neurosciences et Psychiatrie, Université Paris Cité, Inserm U1266, Institut de Psychiatrie et Neurosciences de Paris
5. Dept of Neurosurgery, Groupe Hospitalier Paris Neurosciences et Psychiatrie, Université Paris Cité, Inserm U1266, Institut de Psychiatrie et Neurosciences de Paris
6. Dept of Pathology, Groupe Hospitalier Paris Neurosciences et Psychiatrie, Université Paris Cité, Inserm U1266, Institut de Psychiatrie et Neurosciences de Paris

Correspondence: Prof. Jean-Claude Baron

[jean-claude.baron@inserm.fr](mailto:jean-claude.baron@inserm.fr)

## **Abstract**

Lobar haematomas represent around half of all supratentorial haemorrhages and have high mortality and morbidity. Their management depends on the underlying cause. Apart from local causes such as vascular malformation, which are rare and can usually be easily excluded thanks to imaging, the vast majority of lobar hematomas equally frequently result from either hypertensive arteriopathy (HA) or cerebral amyloid angiopathy (CAA). Distinguishing between CAA and HA is important for prognostication (risk of recurrence nearly 7-fold higher in the former), for decision-making regarding e.g. antithrombotic therapies (for other indications) and for clinical trials of new therapies. Currently, a non-invasive diagnosis of probable CAA can be made using the MR-based modified Boston criteria, which have excellent specificity but moderate sensitivity against histopathological reference, leading to the clinically largely irrelevant diagnosis of “possible CAA”. Furthermore, the Boston criteria cannot be applied when both lobar and deep MRI hemorrhagic markers are present, a not uncommon situation. Here we propose to test whether new CT- and MR-based imaging biomarkers, namely finger-like projections of the hematoma and adjacent subachnoïd haemorrhage on acute-stage CT or MRI, and remote punctate diffusion-weighted imaging ischemic lesions on acute- or subacute-stage MRI, have the potential to improve the performance of the Boston criteria. Furthermore, we also propose to test whether clinical-radiological biomarkers may also allow a positive diagnosis of HA to be made in lobar hematomas, which, if feasible, would not only further reduce the prevalence of “possible CAA” but also permit a diagnosis of HA and/or CAA to be made in the presence of mixed deep and lobar MRI hemorrhagic markers.

Intracerebral hemorrhage (ICH) accounts for ~20% of all strokes and its mortality and morbidity (i.e., dependency) have remained high to this day (~50% and 30%, respectively)<sup>1, 2</sup>. Supratentorial ICHs, which represent the vast majority of ICHs, are classically categorized as deep-seated - affecting the basal ganglia and neighboring white matter - or lobar - affecting one of cerebral lobes. The vast majority of deep-seated hemorrhages are related to arterial hypertension (HTN) and rarely pose diagnostic difficulties regarding etiology - save for the rare presentation in young, non-hypertensive subjects. Conversely, lobar ICHs, which represent ~45% of all supratentorial ICHs<sup>1</sup>, have a myriad of causes including local conditions such as vascular malformation, tumor and acute vasculitis, most of which are rare and can usually be easily identified. The remaining account for the vast majority of lobar ICHs and result from the two major subtypes of sporadic cerebral small vessel disease (cSVD), namely hypertensive arteriopathy and cerebral amyloid angiopathy (CAA).

#### **Lobar ICH: CAA versus hypertensive arteriopathy and the issue of 'Possible CAA'**

Distinguishing between CAA and hypertensive arteriopathy (i.e., arteriosclerosis)<sup>3</sup> in lobar ICH is important for prognostication, as the risk of recurrence is around 7%/year in CAA-related ICH, nearly 7-fold higher than in non-CAA-related ICH<sup>4</sup>. Identifying the underlying etiology also has important implications for decision-making, notably regarding antithrombotic therapies (for other indications), and for clinical trials of new therapies, for instance targeting the underlying pathogenic mechanism. In pathological autopsy specimen, moderate-to-severe CAA (the degree which is expected to potentially lead to ICH) was present in 33% to 58% of lobar ICH cases in four studies<sup>5-8</sup>, while an older study reported a prevalence of 74%<sup>9</sup>. Across these five studies, moderate-to-severe CAA was present in 97 out of 172 patients, i.e., a prevalence of 56.4%. Therefore, slightly over half of no-clear-cause lobar ICH patients have CAA, with hypertensive arteriopathy being the likely cause of lobar ICH in the rest.

No major progress has taken place lately regarding the etiological diagnosis of lobar ICH over and above the development in the early 2000s of the MR-based 'Boston criteria'<sup>9</sup> (modified in 2010<sup>10</sup>), which have been validated against pathological material (autopsy, biopsy or hematoma evacuation). The modified Boston criteria allow, in the absence of a pathological sample, a diagnosis of 'probable CAA' to be made in living patients presenting with lobar ICH in whom no other cause has been identified. In patients aged 55yrs or above with first-ever symptomatic lobar ICH, this diagnosis requires the presence on T2\* or susceptibility-weighted imaging (SWI) MRI of at least one additional lobar hemorrhagic markers, i.e., previous asymptomatic ICH, cerebral microbleed (CMB) or cortical superficial siderosis (cSS, which although much less common than lobar CMBs, is highly specific for

CAA)<sup>10, 11</sup>. Although the modified Boston criteria have high specificity (~90%), they have only moderate sensitivity (~70%)<sup>12-14</sup>. Reflecting this moderate sensitivity, patients with isolated lobar ICH receive the diagnosis of “possible CAA”, which applied to 37% of all lobar ICHs in a recent study<sup>15</sup>. However, “possible CAA” lacks clinical utility for patient management, and is of limited use for inclusion in clinical trials. An international consortium retrospectively collecting patients aged 50 yrs or older in whom a pathological diagnosis was available and who had MRI including T2\*-sensitive sequences during life<sup>16</sup> recently led to the addition to the modified Boston criteria of multiple cSS as well as of two non-hemorrhagic MRI markers, namely multiple peri-vascular dilatations in the centrum semi-ovale and multi-spot pattern white matter FLAIR hyperintense lesions. Adding these imaging markers moderately but significantly improved the sensitivity of the modified Boston criteria to ~80% in the whole cohort (74.5% in the subset that had autopsy as the diagnostic standard)<sup>13</sup>. To reduce further the proportion of lobar ICH patients categorized as “possible CAA”, it would be desirable to further improve the performance, particularly the sensitivity, of the Boston criteria (**Figure 1**).

### **Mixed location hemorrhage**

In addition to the above “possible CAA” issue, another commonly encountered clinical situation (around 20% of all lobar ICHs in two studies<sup>15, 17</sup>) is the presence on MRI of “mixed” deep and lobar hemorrhagic markers, which according to the Boston criteria preclude a diagnosis of CAA. Although as per the latter criteria the presence of at least two lobar CMBs in the absence of deep CMB has strong specificity for CAA, post-mortem studies have documented that lobar CMBs per se lack specificity and can be found in a good fraction of non-CAA-related lobar ICHs<sup>6</sup>. Yet, the “no-deep-CMB” requirement regardless of the number of lobar CMBs or even the presence of cSS may be too conservative and lead to reduced sensitivity. Although studies using amyloid PET suggest that the vast majority of patients with mixed-location CMBs do not have CAA, some patients apparently do<sup>18</sup>. Likewise, up to 15% of patients with mixed location hemorrhage (ICH and/or CMBs) have cSS<sup>19</sup>, suggesting the co-existence of CAA- and HTN-related arteriopathies. Indeed, in autopsy studies, 42 % to 60% of lobar ICH patients had both CAA and documented (presumably hypertensive) moderate-to-severe arteriolosclerosis<sup>5, 20</sup>. Consistent with this observation, in three studies one-half to two-thirds of patients with pathology-proven CAA-related lobar ICH had a clinical history of HTN<sup>5, 6, 21</sup>. New biomarkers are therefore needed to afford a diagnosis of CAA even in the presence of HTN-related markers such as deep CMBs. An attractive approach in such patients would be to apply not just the Boston criteria but also HTN-related arteriopathy (HTN-A) probabilistic diagnostic criteria, and assess the presence of either, or both diagnoses (**Figure 2**).

### **Classification algorithms**

Clinical classification algorithms, notably H-ATOMIC<sup>22</sup> and SMASH-U<sup>23</sup>, have been proposed to facilitate the etiological diagnosis of ICH and differentiate among CAA, HTN-related arteriopathy and other less common etiologies. However, both scores have intrinsic limitations. Neither used pathology as gold-standard, and both therefore lack formal validation. Both applied the Boston criteria to classify patients as CAA, creating a circular

argument. They considered HTN as underlying etiology based mainly on clinical history, yet as stated above the majority of proven CAA-related ICH patients, and up to two-thirds of lobar ICH patients diagnosed as probable CAA, are hypertensive<sup>24</sup>. Finally, they included antithrombotic therapy as a separate etiology, whereas it is now widely admitted that, in this clinical situation, the true underlying cause of the ICH is cSVD, while the antithrombotics act as facilitators only<sup>25, 26</sup>. More broadly, such classification schemes do not allow the option that bleeding may be due to two or more contributing factors.

Novel imaging biomarkers, in association with established imaging, clinical and biological markers, may not only improve the accuracy of the Boston-criteria but also perhaps allow a positive diagnosis of HTN-related lobar ICH to be made. This would in turn allow more patients with lobar ICH - either isolated or in conjunction with deep hemorrhagic markers - to be accurately diagnosed as CAA, hypertensive vasculopathy, both or neither.

### **Novel CT-based biomarkers**

Based on earlier clinical observations<sup>27, 28</sup> and own preliminary work<sup>29, 30</sup>, the Edinburgh group published in 2018 the results of a study that assessed the diagnostic value of admission plain CT for CAA<sup>5</sup>. To this end, they exploited a large sample of patients who died early after ICH, had undergone admission CT, and in whom full autopsy was available, collected as part of a prospective population-based registry. Focusing on lobar ICH (N=62 patients; moderate-to-severe CAA present pathologically in 58%), they assessed the diagnostic value of two potential hemorrhagic CT markers: finger-like projections (FLP) of the hematoma and presence of acute sub-arachnoid hemorrhage (SAH) near the hematoma, and one biological marker, the APO-E genotype. Although combination of all three markers had an excellent positive predictive value (PPV; 96%), APO-E genotyping is not part of clinical practice, and in many countries formal consent is required to carry out genotyping. Because of this practical limitation, the authors proposed a “simplified” version of their criteria solely based on the CT markers and using the practical rule-in/rule-out approach. Accordingly, the “rule-in” criteria, meant to confidently diagnose CAA, are based on presence of both SAH and FLP (at least one of these markers was absent in 100% of patients without histopathologically proven CAA, i.e., perfect specificity), while “rule-out” criteria, meant to confidently exclude CAA, are based on the absence of SAH (which was true in 89% of the proven CAA cases). However, according to this paradigm, no clinically meaningful conclusion can be reached in those patients fulfilling neither of these criteria. In a subsequent purely imaging-based study of lobar ICH in hereditary Dutch-type CAA, van Etten et al<sup>31</sup> reported sensitivities of 58% and 76% for FLP and SAH, respectively, both of which however markedly declined with smaller hematoma size. Because by definition all their subjects had hereditary CAA, specificity could not be assessed. Another study tested the diagnostic value of FLP and SAH in 16 patients with lobar ICH in whom a pathological diagnosis was made on hematoma evacuation in all patients but one<sup>32</sup>. The population studied mostly survived the index event, as is true for 57% of the symptomatic lobar ICH population<sup>1</sup>, and was therefore representative of the majority of lobar ICH patients in whom making a diagnosis CAA has strong clinical relevance. CAA was present histopathologically in 7 patients (44%), and SAH and FLP in 12 (75%) and 10 (62%) patients, respectively. Consistent with Rodrigues et al<sup>5</sup>, SAH had 100% sensitivity for CAA but low specificity, while FLP had lower performance and did not add upon SAH. Interestingly, all patients with ‘possible CAA’ based on MRI but with

CAA on pathology had SAH, suggesting SAH may improve the sensitivity of the Boston criteria.

Consistent with the above idea, four retrospective studies without pathological reference that compared acute CT findings to follow-up MRI found a significantly higher prevalence of both SAH and FLP in patients with probable CAA vs no CAA, defined as per the Boston criteria<sup>15, 33-35</sup>. These studies also support the idea of a potential diagnostic utility of CT in situations where MRI is not available<sup>36</sup>. In the Sembill et al study<sup>15</sup>, the inter-observer reproducibility of FLP was suboptimal, consistent with the Baron et al study<sup>32</sup>, together suggesting that SAH may be a more reliable CT biomarker than FLP. Interestingly, one of these studies<sup>35</sup> reported specific associations of SAH with cSS, and of FLP with lobar MBs, arguing for a distinct pathophysiology of these two acute CT hemorrhagic markers, in turn supporting the rationale to study them as separate potential CAA markers. However, these findings were not replicated by Sembill et al<sup>15</sup>. to distinguish acute lobar ICH-associated SAH from acute SAH without lobar ICH, which is part of the Boston criteria<sup>11, 16</sup>, Schwarz et al named “subarachnoid extension” (SAE) the finding of SAH on admission CT in the context of acute lobar ICH<sup>35</sup>. In conclusion, whether SAH and FLP on acute-stage CT may improve the sensitivity of the Boston criteria now needs to be assessed in larger, multi-center samples with pathological diagnosis.

### **Novel MR-based biomarkers**

In some countries such as France and Switzerland, a significant number of acute stroke centers use MRI as first-line imaging modality in patients admitted for suspected stroke. The sensitivity of acute-stage MRI to acute SAH is known to be at least equal to, and probably even higher than, plain CT<sup>37</sup>. Regarding FLP, a recent study found a very high concordance (89%) of MRI and CT for presence of FLP<sup>34</sup>. Thus, MR-based datasets may in all likelihood be used to assess the diagnostic value of these two acute-stage imaging biomarkers.

Punctate DWI lesions remote from the site of hemorrhage (RDWILs) are a frequent observation in patients with acute ICH, with a prevalence of ~30% within 3 days of stroke onset. Although their prevalence declines in the first few days, it then remains nearly stable over the subsequent 3 months<sup>38-40</sup>. Punctate DWI lesions are exceptionally observed in unselected non-ICH population studies<sup>41</sup>, yet their prevalence is also around 30% in prospective studies of non-ICH subjects with cSVD<sup>42-44</sup>. In the context of ICH, RDWILs are more frequently located in cortical/juxta-cortical and sub-cortical white matter regions than in deep-seated regions, are often multiple, and may have slightly higher prevalence in deep-seated versus lobar ICH<sup>45, 46</sup>. They are associated with MRI markers of cSVD<sup>20, 46</sup> and are considered to reflect ischemic damage secondary to cSVD-related arteriolar obstruction, which includes cortical micro-infarcts<sup>42</sup>. Accordingly, the majority of RDWILs progress to cavitated or non-cavitated micro-infarcts on 1.5T MRI<sup>47</sup>, as also recently documented pathologically in CAA<sup>48</sup>. By analogy, in the context of spontaneous ICH, RDWILs are considered a marker of the underlying arteriopathy, and accordingly are predictive of stroke recurrence, both hemorrhagic and ischemic,<sup>39, 44</sup> as well as of poor outcome<sup>49</sup>. Thus, both the presence and the location (i.e., deep vs lobar) of RDWILs may have diagnostic value to differentiate CAA from hypertensive arteriopathy.

### **Additional potential biomarkers**

Although this update review focuses on novel yet routinely obtainable CT and MR-based imaging biomarkers, other potential diagnostic markers such as CSF-based A $\beta$  assay<sup>50</sup> and amyloid PET<sup>51</sup> may also be considered towards improving the etiological classification of no-clear-cause lobar ICH, particularly in case of small hematomas for which histopathological validation is lacking. Although both biomarkers appear to hold value in distinguishing CAA from healthy age-matched controls and may eventually be added in the Boston criteria, they are limited by substantial overlap with incipient Alzheimer's disease (AD). Thus, based on amyloid PET, incipient AD affects up to one-third of cognitively intact aged people<sup>52</sup>. Likewise, pathological studies show that AD may be associated with CAA in similar proportions<sup>53</sup>, although these estimates represent end-stage CAA and may not reflect the clinical situation. Pending more work, the diagnostic utility of these biomarkers therefore remains uncertain. This is also true of MR-based cerebrovascular reactivity assessment<sup>54</sup> and blood-based biomarkers<sup>55</sup>. Furthermore, as these potential biomarkers are currently assessed as part of prospective research protocols, their validation against histopathology is unlikely to take place in the near future - although could be approached from investigations in hereditary CAA<sup>56, 57</sup>.

## Conclusion

Studies are needed to assess whether the above new CT- and MRI-based imaging biomarkers, in conjunction with and comparison to the previously established MRI and clinical biomarkers, may improve the etiological diagnosis in patients with no-clear-cause lobar ICH, and specifically reduce the proportion of patients categorized as "possible CAA" (**Figure 1**) and allow etiological classification in patients with "mixed" deep and lobar MRI hemorrhagic markers (**Figure 2**).

**Acknowledgements:** None.

**Conflict of Interest:** On behalf of all authors, the corresponding author states that there is no conflict of interest.

## References

1. Li L, Poon MTC, Samarasekera NE, Perry LA, Moullaali TJ, Rodrigues MA, et al. Risks of recurrent stroke and all serious vascular events after spontaneous intracerebral haemorrhage: Pooled analyses of two population-based studies. *Lancet Neurol*. 2021;20:437-447
2. An SJ, Kim TJ, Yoon BW. Epidemiology, risk factors, and clinical features of intracerebral hemorrhage: An update. *J Stroke*. 2017;19:3-10
3. Blevins BL, Vinters HV, Love S, Wilcock DM, Grinberg LT, Schneider JA, et al. Brain arteriolosclerosis. *Acta Neuropathol*. 2021;141:1-24
4. Charidimou A, Imaizumi T, Moulin S, Biffi A, Samarasekera N, Yakushiji Y, et al. Brain hemorrhage recurrence, small vessel disease type, and cerebral microbleeds: A meta-analysis. *Neurology*. 2017;89:820-829



5. Rodrigues MA, Samarasekera N, Lerpiniere C, Humphreys C, McCarron MO, White PM, et al. The edinburgh ct and genetic diagnostic criteria for lobar intracerebral haemorrhage associated with cerebral amyloid angiopathy: Model development and diagnostic test accuracy study. *Lancet Neurol.* 2018;17:232-240
6. Guidoux C, Hauw JJ, Klein IF, Labreuche J, Berr C, Duyckaerts C, et al. Amyloid angiopathy in brain hemorrhage: A postmortem neuropathological-magnetic resonance imaging study. *Cerebrovasc Dis.* 2018;45:124-131
7. Ritter MA, Droste DW, Hegedus K, Szepesi R, Nabavi DG, Csiba L, et al. Role of cerebral amyloid angiopathy in intracerebral hemorrhage in hypertensive patients. *Neurology.* 2005;64:1233-1237
8. Charidimou A, Jaunmuktane Z, Baron JC, Burnell M, Varlet P, Peeters A, et al. White matter perivascular spaces: An mri marker in pathology-proven cerebral amyloid angiopathy? *Neurology.* 2014;82:57-62
9. Knudsen KA, Rosand J, Karluk D, Greenberg SM. Clinical diagnosis of cerebral amyloid angiopathy: Validation of the boston criteria. *Neurology.* 2001;56:537-539
10. Linn J, Halpin A, Demaerel P, Ruhland J, Giese AD, Dichgans M, et al. Prevalence of superficial siderosis in patients with cerebral amyloid angiopathy. *Neurology.* 2010;74:1346-1350
11. Charidimou A, Linn J, Vernooij MW, Opherk C, Akoudad S, Baron JC, et al. Cortical superficial siderosis: Detection and clinical significance in cerebral amyloid angiopathy and related conditions. *Brain.* 2015;138:2126-2139
12. Greenberg SM, Charidimou A. Diagnosis of cerebral amyloid angiopathy: Evolution of the boston criteria. *Stroke.* 2018;49:491-497
13. Charidimou A, Boulouis G, Frosch MP, Baron JC, Pasi M, Albuher JF, et al. The boston criteria version 2.0 for cerebral amyloid angiopathy: A multicentre, retrospective, mri-neuropathology diagnostic accuracy study. *Lancet Neurol.* 2022;21:714-725
14. Charidimou A, Boulouis G. Clinical diagnosis of probable cerebral amyloid angiopathy: Diagnostic accuracy meta-analysis of the boston criteria. *Stroke.* 2022:101161STROKEAHA122039501
15. Sembill JA, Knott M, Xu M, Roeder SS, Hagen M, Sprugel MI, et al. Simplified edinburgh ct criteria for identification of lobar intracerebral hemorrhage associated with cerebral amyloid angiopathy. *Neurology.* 2022
16. Charidimou A, Frosch MP, Al-Shahi Salman R, Baron JC, Cordonnier C, Hernandez-Guillamon M, et al. Advancing diagnostic criteria for sporadic cerebral amyloid angiopathy: Study protocol for a multicenter mri-pathology validation of boston criteria v2.0. *Int J Stroke.* 2019;14:956-971
17. Pasi M, Charidimou A, Boulouis G, Auriel E, Ayres A, Schwab KM, et al. Mixed-location cerebral hemorrhage/microbleeds: Underlying microangiopathy and recurrence risk. *Neurology.* 2018;90:e119-e126
18. Tsai HH, Pasi M, Tsai LK, Chen YF, Lee BC, Tang SC, et al. Microangiopathy underlying mixed-location intracerebral hemorrhages/microbleeds: A pib-pet study. *Neurology.* 2019;92:e774-e781
19. Charidimou A, Jager RH, Fox Z, Peeters A, Vandermeeren Y, Laloux P, et al. Prevalence and mechanisms of cortical superficial siderosis in cerebral amyloid angiopathy. *Neurology.* 2013;81:626-632
20. Charidimou A, Martinez-Ramirez S, Reijmer YD, Oliveira-Filho J, Lauer A, Roongpiboonsopit D, et al. Total magnetic resonance imaging burden of small vessel disease in cerebral amyloid angiopathy: An imaging-pathologic study of concept validation. *JAMA Neurol.* 2016;73:994-1001
21. Smith EE, Nandigam KR, Chen YW, Jeng J, Salat D, Halpin A, et al. Mri markers of small vessel disease in lobar and deep hemispheric intracerebral hemorrhage. *Stroke.* 2010;41:1933-1938

22. Marti-Fabregas J, Prats-Sanchez L, Martinez-Domeno A, Camps-Renom P, Marin R, Jimenez-Xarrie E, et al. The h-atomic criteria for the etiologic classification of patients with intracerebral hemorrhage. *PLoS One*. 2016;11:e0156992
23. Meretoja A, Strbian D, Putaala J, Curtze S, Haapaniemi E, Mustanoja S, et al. Smash-u: A proposal for etiologic classification of intracerebral hemorrhage. *Stroke*. 2012;43:2592-2597
24. Jensen-Kondering UR, Weiler C, Langguth P, Larsen N, Fluh C, Kuhlenthal G, et al. Clinical and radiological differences between patients with probable cerebral amyloid angiopathy and mixed cerebral microbleeds. *J Neurol*. 2020;267:3602-3608
25. Seiffge DJ, Wilson D, Ambler G, Banerjee G, Hostettler IC, Houlden H, et al. Small vessel disease burden and intracerebral haemorrhage in patients taking oral anticoagulants. *J Neurol Neurosurg Psychiatry*. 2021
26. Malhotra K, Zompola C, Theodorou A, Katsanos AH, Shoamanesh A, Gupta H, et al. Prevalence, characteristics, and outcomes of undetermined intracerebral hemorrhage: A systematic review and meta-analysis. *Stroke*. 2021;52:3602-3612
27. Wagle WA, Smith TW, Weiner M. Intracerebral hemorrhage caused by cerebral amyloid angiopathy: Radiographic-pathologic correlation. *AJNR Am J Neuroradiol*. 1984;5:171-176
28. Wakai S, Kumakura N, Nagai M. Lobar intracerebral hemorrhage. A clinical, radiographic, and pathological study of 29 consecutive operated cases with negative angiography. *J Neurosurg*. 1992;76:231-238
29. Miller JH, Wardlaw JM, Lammie GA. Intracerebral haemorrhage and cerebral amyloid angiopathy: Ct features with pathological correlation. *Clin Radiol*. 1999;54:422-429
30. Samarasekera N, Rodrigues MA, Toh PS, Al-Shahi Salman R. Correction: Imaging features of intracerebral hemorrhage with cerebral amyloid angiopathy: Systematic review and meta-analysis. *PLoS One*. 2017;12:e0187386
31. van Etten ES, Kaushik K, van Zwet EW, Voigt S, van Walderveen MAA, van Buchem MA, et al. Sensitivity of the edinburgh criteria for lobar intracerebral hemorrhage in hereditary cerebral amyloid angiopathy. *Stroke*. 2020;51:3608-3612
32. Baron JC, Boulouis G, Benzakoun J, Schwall C, Oppenheim C, Turc G, et al. Cerebral amyloid angiopathy-related acute lobar intra-cerebral hemorrhage: Diagnostic value of plain ct. *J Neurol*. 2021
33. Renard D, Parvu T, Tatu L, Thouvenot E. Subarachnoid extension of lobar hemorrhage on acute/subacute mri is associated with cerebral amyloid angiopathy criteria. *Acta Neurol Belg*. 2020;120:863-866
34. Renard D, Parvu T, Thouvenot E. Finger-like projections in lobar haemorrhage on early magnetic resonance imaging is associated with probable cerebral amyloid angiopathy. *Cerebrovasc Dis*. 2019;47:121-126
35. Schwarz G, Banerjee G, Hostettler IC, Ambler G, Seiffge DJ, Ozkan H, et al. Mri and ct imaging biomarkers of cerebral amyloid angiopathy in lobar intracerebral hemorrhage. *Int J Stroke*. 2022:17474930211062478
36. Ornello R, Colangeli E, Tommasino E, Tiseo C, Perrotta G, Scarpato C, et al. Clinical usefulness of edinburgh ct criteria in patients with lobar intracerebral hemorrhage. *Eur Stroke J*. 2021;6:36-43
37. Edjlali M, Rodriguez-Regent C, Hodel J, Aboukais R, Trystram D, Pruvo JP, et al. Subarachnoid hemorrhage in ten questions. *Diagn Interv Imaging*. 2015;96:657-666
38. Murthy SB, Cho SM, Gupta A, Shoamanesh A, Navi BB, Avadhani R, et al. A pooled analysis of diffusion-weighted imaging lesions in patients with acute intracerebral hemorrhage. *JAMA Neurol*. 2020;77:1390-1397
39. Murthy SB, Zhang C, Gupta A, Cho SM, Rivera-Lara L, Avadhani R, et al. Diffusion-weighted imaging lesions after intracerebral hemorrhage and risk of stroke: A mistie iii and atach-2 analysis. *Stroke*. 2021;52:595-602

40. Gregoire SM, Charidimou A, Gadapa N, Dolan E, Antoun N, Peeters A, et al. Acute ischaemic brain lesions in intracerebral haemorrhage: Multicentre cross-sectional magnetic resonance imaging study. *Brain*. 2011;134:2376-2386
41. Yamada K, Nagakane Y, Sasajima H, Nakagawa M, Mineura K, Masunami T, et al. Incidental acute infarcts identified on diffusion-weighted images: A university hospital-based study. *AJNR Am J Neuroradiol*. 2008;29:937-940
42. Ter Telgte A, Wiegertjes K, Gesierich B, Baskaran BS, Marques JP, Kuijf HJ, et al. Temporal dynamics of cortical microinfarcts in cerebral small vessel disease. *JAMA Neurol*. 2020;77:643-647
43. Ter Telgte A, Wiegertjes K, Gesierich B, Marques JP, Huebner M, de Klerk JJ, et al. Contribution of acute infarcts to cerebral small vessel disease progression. *Ann Neurol*. 2019;86:582-592
44. Wiegertjes K, Dinsmore L, Drever J, Hutchison A, Stephen J, Valdes Hernandez MC, et al. Diffusion-weighted imaging lesions and risk of recurrent stroke after intracerebral haemorrhage. *J Neurol Neurosurg Psychiatry*. 2021;92:950-955
45. Pszczolkowski S, Sprigg N, Woodhouse LJ, Gallagher R, Swinton D, Law ZK, et al. Effect of tranexamic acid administration on remote cerebral ischemic lesions in acute spontaneous intracerebral hemorrhage: A substudy of a randomized clinical trial. *JAMA Neurol*. 2022
46. Boulanger M, Schneckenburger R, Join-Lambert C, Werring DJ, Wilson D, Hodel J, et al. Diffusion-weighted imaging hyperintensities in subtypes of acute intracerebral hemorrhage. *Stroke*. 2018:STROKEAHA118021407
47. van Veluw SJ, Lauer A, Charidimou A, Bounemia N, Xiong L, Boulouis G, et al. Evolution of dwi lesions in cerebral amyloid angiopathy: Evidence for ischemia. *Neurology*. 2017;89:2136-2142
48. Ter Telgte A, Scherlek AA, Reijmer YD, van der Kouwe AJ, van Harten T, Duering M, et al. Histopathology of diffusion-weighted imaging-positive lesions in cerebral amyloid angiopathy. *Acta Neuropathol*. 2020;139:799-812
49. Garg RK, Khan J, Dawe RJ, Connors J, John S, Prabhakaran S, et al. The influence of diffusion weighted imaging lesions on outcomes in patients with acute spontaneous intracerebral hemorrhage. *Neurocrit Care*. 2020;33:552-564
50. Margraf NG, Jensen-Kondering U, Weiler C, Leyboldt F, Maetzler W, Philippen S, et al. Cerebrospinal fluid biomarkers in cerebral amyloid angiopathy: New data and quantitative meta-analysis. *Front Aging Neurosci*. 2022;14:783996
51. Farid K, Charidimou A, Baron JC. Amyloid positron emission tomography in sporadic cerebral amyloid angiopathy: A systematic critical update. *Neuroimage Clin*. 2017;15:247-263
52. Roberts RO, Aakre JA, Kremers WK, Vassilaki M, Knopman DS, Mielke MM, et al. Prevalence and outcomes of amyloid positivity among persons without dementia in a longitudinal, population-based setting. *JAMA Neurol*. 2018;75:970-979
53. Viswanathan A, Greenberg SM. Cerebral amyloid angiopathy in the elderly. *Ann Neurol*. 2011;70:871-880
54. Switzer AR, Cheema I, McCreary CR, Zwiers A, Charlton A, Alvarez-Veronesi A, et al. Cerebrovascular reactivity in cerebral amyloid angiopathy, alzheimer disease, and mild cognitive impairment. *Neurology*. 2020;95:e1333-e1340
55. Chantran Y, Capron J, Doukhi D, Felix J, Feroul M, Kruse F, et al. Letter to the editor: Serum anti- $\beta$  antibodies in cerebral amyloid angiopathy. *Autoimmun Rev*. 2021;20:102870
56. Chatterjee P, Fagan AM, Xiong C, McKay M, Bhatnagar A, Wu Y, et al. Presymptomatic dutch-type hereditary cerebral amyloid angiopathy-related blood metabolite alterations. *J Alzheimers Dis*. 2021;79:895-903
57. Schultz AP, Kloet RW, Sohrabi HR, van der Weerd L, van Rooden S, Wermer MJH, et al. Amyloid imaging of dutch-type hereditary cerebral amyloid angiopathy carriers. *Ann Neurol*. 2019;86:616-625

**Figure Legends**

**Figure 1:** Proposed paradigm to reduce the proportion of no-clear-cause lobar ICH patients currently categorized as “possible CAA” by both i) increasing the sensitivity of the Boston criteria to diagnose probable CAA (red arrow), and ii) allowing a diagnosis of “probable hypertensive arteriopathy” thanks to a new set of histopathologically validated criteria (green arrow). Note: the arrows are meant to represent the shrinking of the “possible CAA” diagnostic category following the enlargement of the “probable CAA” category and the creation of the new “probable hypertensive arteriopathy” diagnostic category (i.e., as if drawing curtains).

**Figure 2:** Proposed paradigm to reduce the occurrence of “no-CAA” as per current Boston criteria in case of mixed superficial and deep hemorrhagic MRI biomarkers. The novel scheme proposed here is to allow a positive diagnosis of hypertensive arteriopathy (HA) to be made in the presence of lobar ICH and other superficial hemorrhagic markers. This would in turn allow a diagnosis of CAA to be made despite the presence of deep hemorrhagic markers. This paradigm therefore opens up the possibility to identify the co-occurrence of both .probable CAA and probable HA, or the presence of neither.

Figure 1

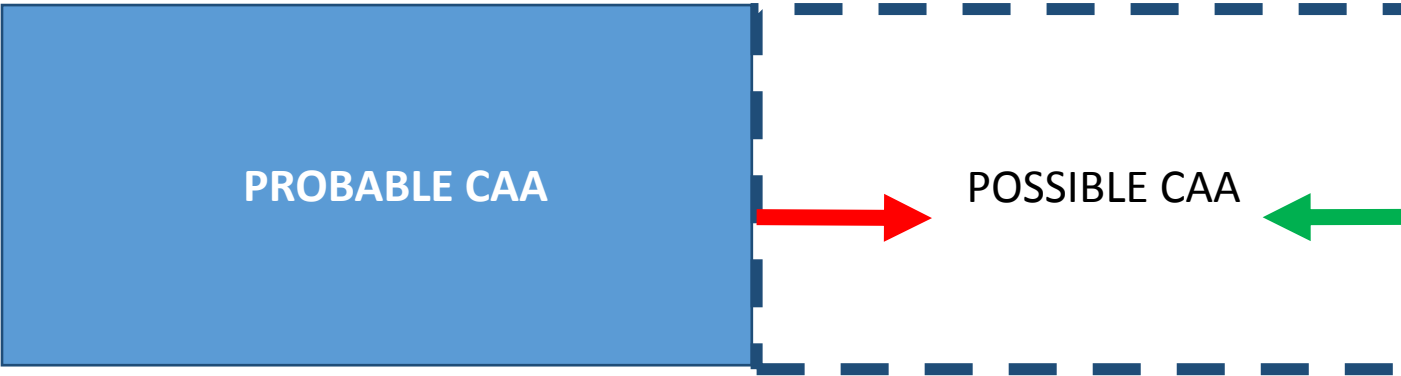


Figure 2

