



HAL
open science

European consensus-based interdisciplinary guideline for invasive cutaneous squamous cell carcinoma. Part 1: Diagnostics and prevention–Update 2023

Alexander Stratigos, Claus Garbe, Clio Dessinioti, Celeste Lebbe, Alexander van Akkooi, Veronique Bataille, Lars Bastholt, Brigitte Dreno, Reinhard Dummer, Maria Concetta Fargnoli, et al.

► To cite this version:

Alexander Stratigos, Claus Garbe, Clio Dessinioti, Celeste Lebbe, Alexander van Akkooi, et al.. European consensus-based interdisciplinary guideline for invasive cutaneous squamous cell carcinoma. Part 1: Diagnostics and prevention–Update 2023. *European Journal of Cancer*, 2023, 193, pp.113251. 10.1016/j.ejca.2023.113251 . inserm-04210036

HAL Id: inserm-04210036

<https://inserm.hal.science/inserm-04210036>

Submitted on 18 Sep 2023

HAL is a multi-disciplinary open access archive for the deposit and dissemination of scientific research documents, whether they are published or not. The documents may come from teaching and research institutions in France or abroad, or from public or private research centers.

L'archive ouverte pluridisciplinaire **HAL**, est destinée au dépôt et à la diffusion de documents scientifiques de niveau recherche, publiés ou non, émanant des établissements d'enseignement et de recherche français ou étrangers, des laboratoires publics ou privés.



Distributed under a Creative Commons Attribution 4.0 International License



Original Research

European consensus-based interdisciplinary guideline for invasive cutaneous squamous cell carcinoma. Part 1: Diagnostics and prevention—Update 2023



Alexander J. Stratigos^{a,*}, Claus Garbe^b, Clio Dessinioti^a, Celeste Lebbe^c, Alexander van Akkooi^{d,e,f}, Veronique Bataille^g, Lars Bastholt^h, Brigitte Drenoⁱ, Reinhard Dummer^j, Maria Concetta Fargnoli^k, Ana Maria Forsea^l, Catherine A. Harwood^m, Axel Hauschildⁿ, Christoph Hoeller^o, Lidija Kandolf-Sekulovic^p, Roland Kaufmann^q, Nicole WJ Kelleners-Smeets^{r,s}, Aimilios Lallas^t, Ulrike Leiter^b, Josep Malvehy^u, Veronique del Marmol^v, David Moreno-Ramirez^w, Giovanni Pellacani^x, Ketty Peris^{y,z}, Philippe Saiag^{aa}, Luca Tagliaferri^{ab}, Myrto Trakatelli^{ac}, Dimitrios Ioannides^t, Ricardo Vieira^{ad}, Iris Zalaudek^{ae}, Petr Arenberger^{af}, Alexander M.M. Eggermont^{ag,ah}, Martin Röcken^b, Jean-Jacques Grob^{ai}, Paul Lorigan^{aj,ak}, On behalf of EADO, EDF, ESTRO, UEMS, EADV and EORTC^l

^a First Department of Dermatology-Venereology, National and Kapodistrian University of Athens, Andreas Sygros Hospital, Athens, Greece

^b Centre for Dermatooncology, Department of Dermatology, Eberhard Karls University, Tuebingen, Germany

^c Université Paris Cite, Dermato-Oncology AP-HP Hôpital Saint Louis, Cancer Institute APHP. Nord-Université Paris Cite, INSERM U976, Paris, France

^d Department of Melanoma and Surgical Oncology, Royal Prince Alfred Hospital, Sydney, New South Wales, Australia

^e Faculty of Medicine and Health, University of Sydney, Sydney, New South Wales, Australia

^f Melanoma Institute Australia, Sydney, New South Wales, Australia

^g Mount Vernon Cancer Centre, East and North NHS Trust, Northwood, UK

^h Department of Oncology, Odense University Hospital, Odense, Denmark

ⁱ Nantes Université, INSERM, CNRS, Immunology and New Concepts in ImmunoTherapy, INCIT, UMR 1302/EMR6001, Nantes, France

^j Skin Cancer Centre at University Hospital Zurich, Zurich, Switzerland

* Corresponding author: First Department of Dermatology-Venereology, National and Kapodistrian University of Athens, Andreas Sygros Hospital, Athens, Greece.

E-mail address: alstrat2@gmail.com (A.J. Stratigos).

^l EADO, European Association of Dermato-Oncology; EDF, European Dermatology Forum; ESTRO, European Society for Radiotherapy and Oncology; UEMS, European Union of Medical Specialists (Union Européenne des Médecins Spécialistes); EADV, European Academy of Dermatology and Venereology; EORTC, European Organization for Research and Treatment of Cancer.

<https://doi.org/10.1016/j.ejca.2023.113251>

0959-8049/© 2023 The Author(s). Published by Elsevier Ltd. This is an open access article under the CC BY-NC-ND license (<http://creativecommons.org/licenses/by-nc-nd/4.0/>).

- ^k Dermatology Department of Biotechnological and Applied Clinical Sciences, University of L'Aquila, L'Aquila, Italy
- ^l Carol Davila University of Medicine and Pharmacy Bucharest, Department of Oncologic Dermatology, Elias University Hospital Bucharest, Bucharest, Romania
- ^m Centre for Cell Biology and Cutaneous Research, Blizard Institute, Barts and the London School of Medicine and Dentistry, Queen Mary University of London, London, UK
- ⁿ Department of Dermatology, University Hospital (UKSH), Kiel, Germany
- ^o Department of Dermatology, Medical University of Vienna, Vienna, Austria
- ^p Department of Dermatology, Medical Faculty, Military Medical Academy, Belgrade, Serbia
- ^q Department of Dermatology, Venereology and Allergology, Frankfurt University Hospital, Frankfurt, Germany
- ^r GROW-School for Oncology and Reproduction, Maastricht, the Netherlands
- ^s Department of Dermatology, Maastricht University Medical Centre+, Maastricht University, Maastricht, the Netherlands
- ^t First Department of Dermatology, Aristotle University, Thessaloniki, Greece
- ^u Dermatology Department of Hospital Clinic of Barcelona, University of Barcelona, IDIBAPS, CIBER de enfermedades raras, Instituto Carlos III, Barcelona Spain
- ^v Department of Dermatology, University Hospital Erasme, Université Libre de Bruxelles, Brussels, Belgium
- ^w Department of Medical and Surgical Dermatology Service, Hospital Universitario Virgen Macarena, Sevilla, Spain
- ^x Dermatology Unit, University of Rome La Sapienza, Rome, Italy
- ^y UOC di Dermatologia, Dipartimento di Scienze Mediche e Chirurgiche Addominali ed Endocrino Metaboliche, Fondazione Policlinico Universitario A. Gemelli-IRCCS, Rome, Italy
- ^z Dermatologia, Università Cattolica del Sacro Cuore, Rome, Italy
- ^{aa} Department of General and Oncologic Dermatology, Ambroise-Paré hospital, APHP, and EA 4340 'Biomarkers in Cancerology and Hemato-oncology', UVSQ, Université Paris-Saclay, Boulogne-Billancourt, France
- ^{ab} UOC Radioterapia Oncologica, Dipartimento di Diagnostica per Immagini, Radioterapia Oncologica ed Ematologia, Fondazione Policlinico Universitario A. Gemelli IRCCS, Rome, Italy
- ^{ac} Department of Dermatology, Papageorgiou Hospital, Aristotle University Department of Medicine, Thessaloniki, Greece
- ^{ad} Department of Dermatology Coimbra Hospital and University Centre, Coimbra, Portugal
- ^{ae} Department of Dermatology, University of Trieste, Trieste, Italy
- ^{af} Department of Dermatovenereology, Third Faculty of Medicine, Charles University, Prague, Czech Republic
- ^{ag} University Medical Center Utrecht and Princess Máxima Center, Utrecht, the Netherlands
- ^{ah} Comprehensive Cancer Center Munich, Technical University Munich and Ludwig Maximilian University, Munich, Germany
- ^{ai} Aix Marseille University, APHM Hospital, Marseille, France
- ^{aj} Division of Cancer Sciences, University of Manchester, Manchester, UK
- ^{ak} Department of Medical Oncology, Christie NHS Foundation Trust, Manchester, UK

Received 18 July 2023; Accepted 18 July 2023

Available online 28 July 2023

KEYWORDS

Invasive cutaneous squamous cell carcinoma; Advanced; High-risk; Locally advanced cSCC; Metastatic cSCC; Diagnosis; Prognosis; Staging; Prevention; Immunosuppression

Abstract Invasive cutaneous squamous cell carcinoma (cSCC) is one of the most common cancers in white populations, accounting for 20% of all cutaneous malignancies. Overall, cSCC mostly has very good prognosis after treatment, with 5-year cure rates greater than 90%. Despite the overall favourable prognosis and the proportionally rare deaths, cSCC is associated with a high total number of deaths due to its high incidence. A collaboration of multidisciplinary experts from the European Association of Dermato-Oncology (EADO), the European Dermatology Forum (EDF), the European Society for Radiotherapy and Oncology (ESTRO), the European Union of Medical Specialists (UEMS), the European Academy of Dermatology and Venereology (EADV) and the European Organization of Research and Treatment of Cancer (EORTC), was formed to update recommendations on cSCC, based on current literature and expert consensus. Part 1 of the guidelines addresses the updates on classification, epidemiology, diagnosis, risk stratification, staging and prevention in immunocompetent as well as immunosuppressed patients.

© 2023 The Author(s). Published by Elsevier Ltd. This is an open access article under the CC BY-NC-ND license (<http://creativecommons.org/licenses/by-nc-nd/4.0/>).

1. Information about the guidelines

1.1. Societies in charge

These Guidelines were developed on behalf of the European Dermatology Forum (EDF), as decided at the EDF meeting in January 2017. The European

Association of Dermato-Oncology (EADO) coordinated the authors' contributions, in collaboration with the European Society for Radiotherapy and Oncology (ESTRO), the European Union of Medical Specialists (Union Européenne des Médecins Spécialistes, UEMS), and the European Academy of Dermatology and Venereology (EADV). In order to

guarantee the interdisciplinary character of these guidelines, they were developed in cooperation with the European Organization for Research and Treatment of Cancer (EORTC). The responsible editors and coordinators of the guideline are: Alexander J. Stratigos, Claus Garbe and Jean-Jacques Grob. Thirty-five experts from 16 countries, all of which were delegates of national and/or international medical societies, collaborated in the development of these guidelines.

1.2. Financing of these guidelines

The authors did this work on a voluntary basis and did not receive any honorarium. Travel costs for participation in Consensus meetings were in part reimbursed by EADO. Guidelines development group members stated their conflicts of interest in the relevant section.

1.3. Disclaimer

Medicine is subject to a continuous development process. This entails that all statements, especially with regard to diagnostic and therapeutic procedures, can only reflect scientific knowledge current at the time of printing of these guidelines. Upmost care was applied with respect to stated therapeutic recommendations and the selection as well as dosage of drugs. Nevertheless, users are prompted to use package inserts and expert information by the manufacturers as backup and, in case of doubt, consult a specialist. Pursuant to public interest, questionable discrepancies shall be communicated to the Guideline Program in Oncology (GPO) editors. The user remains responsible for all diagnostic and therapeutic applications, medications, and doses. Registered trademarks (protected product names) are not specified in these guidelines. From the absence of respective indications, it may thus not be inferred that product names are unprotected.

This work is protected by copyrights in all its parts. Any utilization outside the provision of the copyright act without the written permission by the GPO of the EADO is prohibited and punishable by law. No part of this work may be reproduced in any way without written permission by the GPO. This applies, in particular, to duplications, translations, microfilming, and the storage, application, and utilization in electronic systems, intranets, and internet.

1.4. Scope

These guidelines were written to assist clinicians in the diagnosis, follow-up and treatment of patients with invasive cutaneous squamous cell carcinoma (cSCC). This update was initiated mainly due to advances in systemic treatments and new evidence on prognostic risk factors,

imaging and adjuvant radiotherapy, which justify a newer approach to definitions, risk classification and multidisciplinary therapeutic strategies. The use of these guidelines in clinical routine should improve patient care.

1.5. Target population

These two parts of the cSCC guideline contain recommendations for the diagnosis, follow-up and treatment of patients with invasive cSCC. The guideline is addressed to the attending physicians and the medical nursing staff. An attempt has been made to write and present the guideline recommendations in a way that are easy to understand, so that patients can also understand the recommendation.

1.6. Objectives and formulation of questions

We focus on invasive cSCC (hereafter cSCC), excluding the early intra-epidermal SCC-like actinic keratoses (AK), Bowen's disease, and mucosal SCCs, such as those located in the genital area, or those in the labial-buccal-nasal area, which are often mixed with cSCC under the label of 'head and neck' tumours. Particular emphasis is given to the definitions of cSCC, the diagnosis, risk classification, updated staging systems and treatment modalities. Patient education and prevention issues are also addressed. Formulation of clear sections has been made to support clinicians in their practice.

1.7. Audience and period of validity

This set of guidelines will assist healthcare providers in managing their patients according to the current standards of care and evidence-based medicine. It is not intended to replace accepted national guidelines. The guidelines published here reflect the best published data available at the time the report was prepared. Caution should be exercised in interpreting the data; the results of future studies may modify the conclusions or recommendations in this report. In addition, it may be necessary to deviate from these guidelines for individual patients or under special circumstances. Just as adherence to the guidelines may not constitute defence against a claim of negligence (malpractice), deviation from them should not necessarily be deemed negligent. These guidelines will require updating approximately every 2 years (expiration date: December 2025) but advances in medical sciences may demand an earlier update.

1.8. Methods

The European Interdisciplinary Guidelines on invasive squamous cell carcinoma of the skin are written as a uniform text and then published in two separate but integral parts: part 1 on definitions, epidemiology, etiopathogenesis,

diagnosis, risk classification, staging and prevention and part 2 on treatments, supportive care, patient education and follow-up (Stratigos et al. part 2. 2023).

The guidelines published here are an update of the existing European consensus-based (EDF/EADO/EORTC) interdisciplinary guidelines for the management of invasive cSCC (former version 2020) [1,2] and are additionally informed by other up-to-date guidelines, including the National Comprehensive Cancer Network (NCCN) Clinical Practice Guidelines in Oncology for squamous cell skin cancer (version 1.2023) [3], and the British Association of Dermatologists guidelines for the management of people with cutaneous squamous cell carcinoma 2020 [4]. *De novo* literature search was conducted by the authors by Medline search in English language publications with search date on November 1, 2022. Search terms included: ‘cutaneous squamous cell carcinoma’, ‘squamous cell carcinoma’, and ‘advanced, locally advanced, low-risk, high-risk common primary cSCC, locally advanced cSCC, metastatic cSCC’. These terms were combined with ‘diagnosis, prognosis, staging, imaging, prevention, chemoprevention, guidelines, treatment, surgical excision, radiotherapy, adjuvant, systemic, anti-PD-1 antibody, cemiplimab, pembrolizumab, chemotherapy, cetuximab, epidermal growth factor receptor-inhibitors, clinical trials, follow up, patient education’. The references cited in selected papers were also searched for further relevant publications. The final updated literature search was performed on 10th March 2023. The methodology of these updated guidelines was based on the standards of the Appraisal of Guidelines for Research and Evaluation (AGREE II) instrument [5].

Recommendations are based on the level of best quality available evidence and good clinical practice points (GPP). The levels of evidence were graded according to the Oxford classification (Table 1) [6]. In brief, level 1 indicates strongest evidence based on systematic review of randomized controlled trials or high-quality studies, level 2 is based on randomized or well-designed cohort or cross-sectional studies, level 3 is based on non-randomized adequately designed studies, and levels 4 and 5 indicate the weakest evidence based on smaller number of patients or poor quality. Level may be graded down based on study quality, imprecision, indirectness, because of inconsistency between studies, or because the absolute effect size is very small. Level may be graded up if there is a large or very large effect size. (Table 1).

The grades of recommendation were classified as follows:

A: Strong recommendation. Syntax: ‘shall’.

B: Recommendation. Syntax: ‘should’.

C: Weak recommendation. Syntax: ‘may/can’.

X: Should not be recommended.

0: Recommendation pending. Currently not available or not sufficient evidence to make a recommendation in favour or against.

Expert consensus was provided wherever adequate evidence is not available, as a good clinical practice point (GPP).

The guideline manuscripts were additionally reviewed by reviewers from each participating society, who were not included as authors of the guidelines.

1.9. Consensus building process

The consensus building process was conducted as follows: in a first-round medical experts who participated in their national guideline development processes were involved in producing an initial draft. In a second round the EORTC selected experts from different specialties to contribute to these guidelines. A consensus meeting was held in Rome, Italy, on 25th November 2022 with final outcomes: (1) the approval of the text and (2) a consensus rate of agreement of at least 80%, for recommendations provided in structured boxes and the figure. Voting of the recommendations included the selection of ‘Agree’, ‘Disagree’ or ‘Abstentional’ vote, and the possibility of providing comments. Twenty-four experts were present in the consensus meeting. After the consensus meeting, it was decided to add a box on the prevention of cSCC in solid organ transplant recipients. The final literature search update on 10th March 2023, did not result in changes in the recommendation boxes; new references were added in the text and the [Supplementary Tables 2 and 3](#) were updated based on the meta-analysis of Zakhem et al., 2023 [7]. The finalization of the draft and recommendations was conducted among all co-authors through emailing in the first semester 2023.

Compared with the guideline 2020 recommendations, in this update, the following recommendation boxes were kept the same: [Box 4](#). List of high-risk factors, and [Box 7](#). Prevention. The following boxes were updated: [Box 1](#). Definitions and classifications of invasive cSCC, [Box 2](#). Clinical and non-invasive diagnosis of primary cSCC, [Box 3](#). Pathology report, [Box 5](#). Imaging for staging, and [Box 6](#). Sentinel lymph node biopsy (SLNB). Two new boxes were added: [Box 8](#). Nicotinamide for chemoprevention in immunocompetent patients with a history of multiple cSCC, and [Box 9](#). Prevention of cSCC in solid organ transplant recipients.

A summarizing box of recommendations with practice-oriented statements is provided at the end of the article.

2. Definitions of cSCC

Cutaneous SCC (cSCC) is a common skin cancer characterized by the malignant proliferation of epidermal keratinocytes and it is classified as a keratinocyte carcinoma together with basal cell carcinoma [8]. It is distinguished into *in situ* (Bowen’s disease) and invasive form, and invasive cSCC is probably often the ultimate step of a long lasting intraepidermal dysplasia [9,10]. These guidelines focus on invasive cSCC.

Depending on the extent of the disease, cSCC is distinguished as common primary, by far the most frequent, and advanced cSCC. Common primary cSCCs are non-metastatic cSCC, usually easy-to-treat lesions, which can be

Table 1
Oxford centre for evidence-based medicine 2011 level of evidence.

Question	Step 1 (Level 1 ^a)	Step 2 (Level 2 ^a)	Step 3 (Level 3 ^a)	Step 4 (Level 4 ^b)	Step 5 (Level 5)
How common is the problem?	Local and current random sample surveys (or censuses)	Systematic review of surveys that allow matching to local circumstances ^b	Local non-random sample ^b	Case-series ^b	n/a
Is this diagnostic or monitoring test accurate? (Diagnosis)	Systematic review of cross-sectional studies with consistently applied reference standard and blinding	Individual cross-sectional studies with consistently applied reference standard and blinding	Non-consecutive studies, or studies without consistently applied standards ^b	Case-control studies, or “poor or non-independent reference standard” ^b	Mechanism-based reasoning
What will happen if we do not add a therapy? (Prognosis)	Systematic review of inception cohort studies	Inception cohort studies	Cohort study or control arm of randomized trial ^a	Case-series or case-control studies, or poor-quality prognostic cohort study ^b	n/a
Does this intervention help? (Treatment Benefits)	Systematic review of randomized trials or <i>n</i> -of-1 trials	Randomized trial or observational study with dramatic effect	Non-randomized controlled cohort/follow-up study ^b	Case-series, case-control studies, or historically controlled studies ^b	Mechanism-based reasoning
What are the COMMON harms? (Treatment Harms)	Systematic review of randomized trials, systematic review of nested case-control studies, <i>n</i> -of-1 trial with the patient you are raising the question about, or observational study with dramatic effect	Individual randomized trial or (exceptionally) observational study with dramatic effect	Non-randomized controlled cohort/follow-up study (post-marketing surveillance) provided there are sufficient numbers to rule out a common harm. (For long-term harms the duration of follow-up must be sufficient.) ^b	Case-series, case-control, or historically controlled studies ^b	Mechanism-based reasoning
What are the RARE harms? (Treatment Harms)	Systematic review of randomized trials or <i>n</i> -of-1 trial	Randomized trial or (exceptionally) observational study with dramatic effect	Non-randomized controlled cohort/follow-up study ^b	Case-series, case-control, or historically controlled studies ^b	Mechanism-based reasoning
Is this (early detection) test worthwhile? (Screening)	Systematic review of randomized trials	Randomized trial	Non-randomized controlled cohort/follow-up study ^b	Case-series, case-control, or historically controlled studies ^b	Mechanism-based reasoning

^a Level may be graded down on the basis of study quality, imprecision, indirectness (study PICO), because of inconsistency between studies, or because the absolute effect size is very small; Level may be graded up if there is a large or very large effect size.

^b As always, a systematic review is generally better than an individual study.

further classified as low-risk or high-risk, depending on the risk of recurrence. High-risk cSCC is defined as invasive cSCC without locoregional (in transit or regional nodal metastasis) or distant metastasis (staged as N0 and M0), that has features associated with a higher risk for local recurrence and metastasis (detailed in Section 6, Box 4), and that is amenable to curative surgery or radiotherapy (RT). Advanced cSCC is classified as locally advanced (lacSCC), and metastatic (mcSCC) including locoregional metastatic or distant metastatic cSCC, respectively.

LacSCC shall be defined as non-metastatic cSCC, not amenable to either surgery or radiotherapy with reasonable hope for cure, because of multiple recurrences, large size, bone erosion or invasion, or deep infiltration beyond subcutaneous tissue into muscle or along nerves, or tumours in which curative resection would result in unacceptable complications, morbidity or deformity [11–13]. This corresponds to unresectable T3/T4 (tumour invading deep structures) according to the 8th edition AJCC or UICC staging classification [14,15].

McSCC includes loco-regional metastatic cSCC with in-transit metastases or metastasis to regional lymph nodes, or distant metastatic cSCC requiring systemic treatments. cSCC with regional nodal metastasis corresponds to stage III or IV according to the 8th edition AJCC or UICC staging classification. Metastatic cSCC with distant metastasis corresponds to stage IV. The presence of in-transit metastases is not included in the 8th edition AJCC/UICC staging systems.

Box 1 Definitions and classifications of invasive cSCC.

Definitions and classifications of invasive cSCC	Evidence- based statement
Grade of recommendation: A	Common primary cSCC shall be classified as high-risk or low-risk. High-risk cSCC is defined as invasive cSCC without locoregional (in transit or regional nodal metastasis) or distant metastasis (staged as N0 and M0), that has features associated with a higher risk for local recurrence and metastasis (Box 4). Advanced cSCC shall be classified as locally advanced (LacSCC), locoregional metastatic or distant metastatic cSCC. LacSCC shall be defined as non-metastatic cSCC, not amenable to either surgery or radiotherapy with reasonable hope for cure, because of multiple recurrences, large size, bone erosion or invasion, or deep infiltration beyond subcutaneous tissue into muscle or along nerves, or else tumours in which curative resection would result in unacceptable complications, morbidity or deformity.
Level of evidence: 1	Meta-analysis [16], phase 1 and phase 2 cohort studies [13]. Strength of consensus: 100%.

3. Epidemiology

cSCC is the second most common form of skin cancer, accounting for 20% of keratinocyte carcinomas [8,17]. Ratios of basal cell carcinoma (BCC) to cSCC range from 2 to 4:1 [17,18]. Most primary cSCC (80–90%) are located on the head and neck [19]. Reliable population-based cSCC incidence data are limited, sometimes flawed by inclusion of AK and in situ-SCC, but indicate that rates are increasing in most white populations globally [18,20] and are predicted to continue to increase [20–23].

International incidence data are presented in Table 2 [24–32]. Rates increase with age, male sex (standardized incidence ratio, 2.1; 95% confidence interval [CI], 2.06–2.14) and low latitude. Multiplicity is strongly correlated with age [24]. In the United Kingdom, between 2013 and 2015, 62.7% of cSCC arose in men (median age 80 years). The mean annual percentage increase was 5% between 2013 and 2015 [26,27]. In Norway, age-adjusted incidence rates increased nine-fold in females and six-fold in males from 1963 to 2011, particularly in the age group 70–79 years [28]. Data from the Swedish Cancer Registry showed higher incidence for populations at the same latitude but resident in coastal areas where hours of sunshine are higher than in inland areas [33]. Age-adjusted cSCC incidence data from the northern latitude Rochester Epidemiology Project (United States of America) reported a 263% increase between 1976 and 1984 and 2000–2010 and a disproportionate increase in women and people under 40 years [31].

Much of the challenge in obtaining accurate incidence data is related to inconsistent cSCC registration practices in many countries: high incidence, multiplicity and low mortality contribute to a tendency to poor ascertainment by cancer registries in which frequently only the first diagnosis of cSCC is recorded, if at all [20,26]. A particularly important consequence is that the associated public health burden of cSCC is substantially underestimated [17,18,21,30,34].

Markedly increased rates of cSCC have been reported in solid organ transplant patients [35] and in patients with chronic lymphocytic leukaemia (CLL) [36] or human immunodeficiency virus (HIV) infection [37]. Risk was increased by 9–18-fold in Danish and US haematopoietic stem cell transplant recipients compared with the general population [38,39]. In a US cohort, HIV patients with CD4 count < 200 cells/mL had a 2.2 times increased risk compared to HIV uninfected individuals for subsequent cSCC after a first cSCC [40].

3.1. Prognosis

Common primary cSCC are typically indolent tumours, rarely giving rise to metastasis, when they are treated

Table 2
International incidence data for cSCC.

Country	Time period	Age-standardized incidence (per 100,000 PY)	Reference
Australia	2011-2014	270	[24]
Queensland	2011-2014	467	
Tasmania	2011-2014	175	
UK	2013–2015	77 in men 34.1 in women (for first cSCC, per annum)	[26,27]
Ireland	1994–2011	66.1 in men 30.6 in women	[25]
Norway	2008–2011	20 in men 15 in women	[28]
USA	2012	In northern latitudes: 46.3–134.5 in men 15.7–42.9 in women In southern latitudes: 233.2–497.1 in men 83.3–180.5 in women	[30]
USA the northern latitude Rochester Epidemiology Project	1976–1984 2000–2010	207.5 in men 128.8 in women	[31]
Japan	2007–2016	Increased from 14.7 to 51.6 in people aged 80 years or more	[29]

cSCC, cutaneous squamous cell carcinoma; PY, person-years; UK, United Kingdom; USA, United States of America.

early and correctly. Most cSCC tumours have a very good prognosis, with 5-year cure rates of greater than 90% [41]. The rate of recurrence was reported to be 4.6% in a large single centre study of more than 900 patients with cSCC followed for approximately 10 years, 3.7% for nodal disease and 2.1% for disease-specific death [42]. The rate of local recurrence was 3% in a prospective study of 615 patients with surgically resected cSCC, with a 4% rate of metastases, after a median follow up of 43 months [43]. In a large cohort study in the UK, the recurrence rate was 2.7% and the metastasis rate was 1.2% of which 85% were metastases from head and neck cSCCs [44].

The population-based incidence of advanced cSCC has been reported [18,26,45–47]. The most recent European data on metastatic risk came from the UK National Cancer Registration and Analysis Service (NCRAS): cumulative incidence of loco-regional or distant metastasis after a median follow up of 15.2 months was 2.1% (1.1% in women, 2.4% in men) in 2013–15. Most mcSCC (85.2%) were diagnosed within 2 years from the primary cSCC. For most patients with mcSCC, the site of metastasis was the head and neck or parotid lymph nodes (73.6%). Risk increased with age, in males, in patients with immunosuppression, in higher deprivation quintiles, and location on the ear and lip [26].

Several studies have shown worse outcomes for cSCC in immunosuppressed patients compared to immunocompetent patients [45,48–51]. In immunosuppressed patients, loco-regional recurrence was more common [48], whereas the risk of metastatic cSCC

at least doubled [26] and outcomes for advanced disease were significantly worse [52]. Mortality rates of 494 per 100,000 were reported for the US transplant population [53]; higher risk of recurrence, nodal metastasis and death is also reported in CLL [36,54,55] and survival after nodal disease in immunosuppressed individuals is significantly reduced [52]. In addition, patients with epidermolysis bullosa have a high risk of early-onset, aggressive and often multiple cSCCs developing at sites of chronic skin blistering and scarring. In a UK study between 1991 and 2019, in 31 individuals with severe recessive dystrophic epidermolysis bullosa, metastatic disease occurred in 52% of patients, and cSCC was the leading cause of death [56].

There are some population-based reports of the mortality of advanced cSCC [18,26,45,46]. A study in the Cancer Registry of Norway for the period from 2000 to 2011, reported 5-year relative survival rates for localized cSCC of 88% in women and 82% in men, and of 64% in women and 51% in men for advanced cSCC [28]. A prospective study in 2149 cSCC (1434 patients) reported 2.8% disease-specific death after a median follow-up of 36.5 months [57]. Of note, disease-specific death has been reported to occur not only as a result from metastasis but also due to local complications and underlying tissue destruction in lacSCC [57].

4. Aetiology and pathogenesis

Beside ultraviolet radiation (UVR) exposure (sun exposure and use of tanning beds [58]), which is by far the most important causal factor for cSCC, some others

have been implicated such as immunosuppression [59], BRAF inhibitor (BRAFi) single agent therapy, β -human papilloma virus (β -HPV) subtypes [60,61] and smoking [62,63]. The main carcinogen for cSCC development is UVR exposure. While most cSCCs will arise in the context of AKs and in patients with chronic photoaging, the rate of transformation of clinically evident AKs into cSCC is very low, at least in a few years period of follow-up (less than 1/1000 per year during a 5-year follow up) [64–66]. BRAFi monotherapy with vemurafenib, dabrafenib or encorafenib in patients with metastatic melanoma, is associated with a higher risk of inducing cSCC compared to combined BRAF/MEK inhibitors [67]. The mechanism of cSCC development is proposed to be hyperproliferation of keratinocytes due to paradoxical activation of the mitogen-activated protein kinase (MAPK) pathway in wild-type BRAF cells, particularly in the presence of oncogenic RAS mutations [68–70]. The development of cSCC during vismodegib (hedgehog pathway inhibitor) treatment in patients with locally advanced or metastatic BCC has also been reported, but it remains unclear whether it is related to treatment [71,72]. Photosensitizing anti-hypertensive drugs have been associated with risk of cSCC [73]. Regarding the thiazide diuretics (TZ) drugs, hydrochlorothiazide (HCTZ) has been associated with a dose-dependent risk of cSCC [74–76]. In 2018, the European Medicines Agency (EMA) recommended updating the product information to advise patients about the risk of keratinocyte carcinoma with use of HCTZ and that the use of HCTZ may need to be reconsidered in patients with a history of keratinocyte carcinoma [77]. On the other hand, bendroflumethiazide was not associated with risk of any type of skin cancer and was suggested as a possible safer alternative TZ for patients at increased risk of skin cancer [78].

4.1. Molecular pathogenesis

cSCC are complex genetic tumours with a very high mutation rate (median of 45.2 mutations per megabase [Mb] of genomic DNA) [79–82]. Most cSCC carry a UV mutation signature with characteristic C > T or CC > TT dinucleotide mutations [83]. Normal sun exposed skin and actinic keratosis have a lower mutation rate than cSCC, but most of them had driver mutations in NOTCH1 and TP53. Whether or not they are true precursors of cSCC and clonally related remains uncertain [84].

Genes altered in UV-induced cSCC include TP53, CDKN2A involved in cell cycle control, NOTCH1 and NOTCH2, the epigenetic regulators KMT2C, KMT2D, TET2, members of the Hippo pathway and of the SWI/SNF chromatin remodelling complex and mutations of

transforming growth factor β (TGF- β) receptors leading to their inactivation [80,81,85]. Genetic alterations that may be targeted with treatments are infrequent but include PIK3CA, FGFR3, BRAF, and epidermal growth factor receptor (EGFR) [86,87]. Genetic signatures have been linked to azathioprine exposure in SCC arising in immunosuppressed patients [80], in cSCC in recessive epidermolysis bullosa patients and possibly in other cSCC arising on burn scars or on chronic ulcers [88]. The apolipoprotein B mRNA-editing enzyme catalytic polypeptide-like (APOBEC) deaminases-associated mutation profile has been reported in 100% of cSCC tumors from patients with recessive dystrophic epidermolysis bullosa [88].

Genome-wide association studies have highlighted single nucleotide polymorphisms associated with cSCC risk, including *MC1R*, *ASIP*, *TYR*, *SLC45A2*, *OCA2*, *IRF4*, *BNC2*, the metastasis suppressor gene *CADM1*, *AHR*, a transcription factor that regulates cell proliferation, *SEC16A* involved in secretion and cellular proliferation, and more recently other loci involved in pigmentation phenotypes (*TYRP1*, *TRSP1*) in tumour immunosuppression HLA variants, *BACH2*, invasion and metastasis (*SETDB1*, *ECM1*, and *CERS2*) [89–93]. Immunosurveillance is involved in cSCC progression with a higher number of CD8+ and CD4+ T-cells in primary tumours from non-progressing SCC compared to high-risk SCC [94]. PD-L1 expression was detected in around 26% of primary cSCC [95–97] and up to 50% of metastatic lesions [96,97]. Hereditary syndromes that increase cSCC risk include xeroderma pigmentosum, epidermolysis bullosa, congenital epidermodysplasia verruciformis, oculocutaneous albinism, Fanconi anaemia and Lynch syndrome/Muir Torre syndrome [8].

5. Diagnostic approach in primary cSCC

5.1. Clinical diagnosis

cSCC may have variable clinical presentations depending on tumour size, differentiation, pigmentation, location and skin type. It most commonly arises on sun-exposed sites (head, neck, forearms, dorsum of the hands). The presence of multiple AK represents an established predictor of cSCC development in previously unaffected individuals [65,66].

In its early minimally invasive phase, cSCC is usually a small flesh-coloured papule or plaque, often with a scaly/hyperkeratotic surface, not easily distinguishable from a hyperplastic/hyperkeratotic AK or *in situ* SCC (Bowen's disease). It enlarges over time at a variable rate, often with ulceration and crusting. There is usually some induration upon palpation. cSCC may be pigmented, displaying a light to dark brown colour, especially in non-white skin populations. Well-differentiated

cSCC usually manifests as a hyperkeratotic and verrucous tumour, sometimes with a crateriform appearance. Poorly differentiated cSCC may appear as red-coloured non-keratotic tumour, is frequently ulcerated or bleeding and may be difficult to distinguish from other non-pigmented tumours like amelanotic melanoma, Merkel cell carcinoma, atypical fibroxanthoma and other less frequent neoplasms. cSCC may be tender on palpation or spontaneously painful, and this may be a sign of perineural involvement.

Keratoacanthoma represents a subtype of well-differentiated cSCC (keratoacanthoma-like SCC) with a distinct clinical behaviour. Keratoacanthoma typically does not arise on the background of actinic keratosis, grows rapidly (within a few weeks), occasionally regresses spontaneously and is typified by distinctive histological criteria [98,99]. Clinically, keratoacanthoma manifests as a solitary symmetrical dome-shaped nodule capped with keratin especially in the centre, usually arising on sun-exposed skin areas [99].

LacSCC may result either from tumours with a particularly aggressive biologic potential, from multiple relapses after inadequate initial management of primary cSCC or from neglected lesions. This results in large, indurated tumours that infiltrate the surrounding skin and may invade regional anatomic sites such as the orbits or sinuses with pain and other associated symptoms. The actual tumour extent, infiltration and depth of invasion are not easily predictable by simple clinical examination. In mcSCC, the tumour may present with in-transit, nodal or distant metastasis. Clinical examination of the draining basins and imaging in addition to clinical diagnosis of the primary tumour, has to be considered for staging in high-risk cSCC when metastases need to be ruled out.

The clinical differential diagnosis includes in early cases inflamed seborrheic keratosis, high-grade AK, or keratotic basal cell carcinoma. Less differentiated cases may be confused with amelanotic melanoma, or with rarer neoplasms such as atypical fibroxanthoma, Merkel cell carcinoma or adnexal tumours among others.

Adequate documentation of the cutaneous tumour with measurement of the maximum clinical diameter in the patient's medical file is necessary prior to biopsy and surgery. Recording of symptoms and photographic documentation (clinical and, whenever possible, dermatoscopic) is recommended prior to biopsy. Recording the clinical diameter is important as this is a critical parameter in risk classification and staging of cSCC unlike the size recorded in the histologic report, which is usually reduced due to the shrinkage during sample-processing techniques.

5.2. Dermatoscopy and other non-invasive techniques

Dermatoscopy represents an integral part of clinical examination for the assessment of skin tumours. The

dermatoscopic features of cSCC have been extensively investigated and shown to depend on the grade of histopathological differentiation. Well-differentiated cSCC is dermatoscopically dominated by a white colour that might be present in the form of keratin masses, white structureless areas, white perifollicular circles or white perivascular halos, the latter surrounding hairpin or coiled vessels. Each one of these features has a particular diagnostic significance, according to the clinical differential diagnosis. Keratin masses, although very frequent in cSCC, are not specific, since several other, benign and malignant, tumours may display signs of keratinization. White structureless areas, possibly corresponding to extensive acanthosis, were shown to predict cSCC over AK. White circles surrounding follicles which are frequently dilated and filled with keratin plugs, are considered as a specific sign of cSCC over several other nodular tumours, including BCC, seborrheic keratosis, nevi, warts and others. White perivascular halos are seen in cSCC and other keratinizing tumours as well, such as seborrheic keratosis (mainly irritated subtype) or common warts. However, the distribution of the vessels (and the surrounding halos) differs, being irregular in cSCC as compared to the homogeneous arrangement in benign tumours.

Keratoacanthoma is typified by a peculiar dermatoscopic pattern consisting of a central mass of keratin surrounded by radially arranged hairpin or coiled vessels, usually surrounded by a white halo.

Poorly differentiated cSCC is substantially different in terms of its dermatoscopic characteristics. It is predominated by a red colour, resulting from a rich vascularity composed of dotted, coiled, hairpin, short linear and linear irregular vessels (polymorphous vascular pattern). Haemorrhage is also very frequent and signs of keratinization are absent.

Moderately differentiated cSCC displays mixed dermatoscopic criteria, including white-coloured and vascular structures [100–102].

Other non-invasive techniques such as *in vivo* Reflectance Confocal Microscopy (RCM), Line field confocal OCT (LC-OCT), and Optical Coherence Tomography (OCT) have been used in limited case series but there is currently insufficient evidence for their routine diagnostic use at this point in time. Although RCM identifies characteristics which have good histopathologic correlations (i.e. parakeratosis, atypical keratinocytes, and vascular alterations), the limited laser penetration frequently hampers the full-thickness examination of the tumour. Thus, there is currently insufficient evidence for its routine diagnostic use. A possible role for RCM in clinical practice would be to differentiate cSCCs from BCCs [103–105]. LC-OCT and OCT, in different modalities, provides deeper vertical sections of the tissue, and may thus help to distinguish *in situ* versus early invasive cSCC [106–108].

Table 3
WHO classification of skin tumours: SCC [98].

	ICD-O code
Squamous cell carcinoma not otherwise specified	8070/3
Keratoacanthoma (synonym: well-differentiated SCC)	8071/3
Acantholytic SCC	8075/3
Spindle cell SCC	8074/3
Verrucous SCC	8051/3
Clear cell SCC	8084/3
Other (uncommon) variants	
SCC with sarcomatoid differentiation	8074/3
Lymphoepithelioma-like carcinoma	8082/3
Pseudovascular SCC	8074/3
SCC with osteoclast-like giant cells	8035/3
SCC in situ (Bowen disease)	8070/2

WHO, World Health Organisation. ICD: International Classification of Diseases

Box 2 Clinical and non-invasive diagnosis of the primary cSCC.

Clinical and non-invasive diagnosis of the primary cSCC	Consensus-based statement
GPP	<p>Clinical diagnosis of the primary cSCC includes description of the lesion, recording of symptoms and location and measurement of the diameter.</p> <p>Photographic documentation is strongly recommended.</p> <p>Dermatoscopy can help in the differential diagnosis of cSCC pre-operatively.</p> <p>Confocal microscopy or OCT if available, can help in the differential diagnosis of cSCC pre-operatively.</p> <p>Strength of consensus: 100%</p>

5.3. Histopathological diagnosis

The gold standard for the diagnosis of cSCC is histology. A biopsy or excision and histological confirmation should be performed in all clinically suspected cSCCs. A lower threshold for biopsy of suspicious lesions has been proposed for solid organ transplant recipients [109]. Depending on the size of the tumour and treatment approach, an incisional biopsy, i.e., incision or punch biopsy or an excisional biopsy of the entire lesion can be performed initially. Preoperatively, the longest clinical diameter of the lesion (including the peripheral rim of erythema) should be recorded and noted on the surgery report as it is part of further prognostic staging [110].

cSCCs consist of atypical epithelial tumour cell formations that extend beyond the epidermis into the underlying dermis. Like the cells of the stratum spinosum of the epidermis, the cells tend to cornify and horny pearls are formed [17,111]. cSCC may be classified according to the WHO classification of skin tumours (4th edition, 2018) [98] as presented in Table 3. Not yet included in the World Health Organisation (WHO) classification is desmoplastic cSCC with a high proportion of stroma and narrow cell strands, which grows markedly infiltrative, perineurally or perivascular [112]. This type must be separated from the common primary cSCC group and it is considered a high-risk histological subtype in the NCCN guidelines [3].

Clinical information to be noted on the biopsy as well as the excision request should include patient demographics, the location and the clinical diameter of the lesion as the latter is necessary for staging. The final histopathological report (after excision) should include histological risk factors that are relevant for the staging and prognosis of cSCC including the thickness, depth of invasion, the presence or absence of perineural invasion (PNI), the grade of differentiation, desmoplastic type and margins status [3]. Additional useful histologic features may be recorded including the histological subtype, lymphovascular invasion and calibre of nerves affected by PNI if ≥ 0.1 mm (Table 4). According to the AJCC 8th edition cancer staging manual, for cSCC, the maximum vertical tumour thickness is measured in mm, from the granular layer of the adjacent normal epidermis, or ‘shoulder’ of the tumour, to the deepest part (base) of the tumour [113]. The depth of invasion reports the invasion or not into the subcutaneous fat (Clark level V), or even below for more aggressive tumours. For PNI, there is need for standardization in reporting [114]. The histopathological subtypes that have been associated with higher risk for local recurrence or metastases include desmoplastic, metaplastic (spindle cell), acantholytic (adenoid), or adenosquamous (showing mucin production) subtypes [3], and their presence is a NCCN high-risk criterion. The guideline author group proposes the use of a standardized definition for desmoplasia, based on the criteria by Breuninger et al.[112], also used in subsequent studies [57,115,116]. Desmoplastic cSCC is diagnosed when at least one third of the tumour specimen shows infiltrating nests of atypical squamous epithelial cells, often featuring single cell strands, surrounded by a distinct sclerotic stromal reaction. The degree of differentiation may classify cSCC into well-differentiated subtypes with low metastatic potential and into poorly differentiated, more aggressive subtypes [17].

Table 4
Basic features included in the histopathological report of a cSCC diagnosis (modified from [1,266]).

Histopathologic report of cSCC		
Type of specimen	<input type="checkbox"/> punch <input type="checkbox"/> shave	<input type="checkbox"/> excisional
Histologic subtype:	<input type="checkbox"/> Common <input type="checkbox"/> Keratoacanthoma <input type="checkbox"/> Acantholytic <input type="checkbox"/> Spindle cell SCC <input type="checkbox"/> Verrucous	<input type="checkbox"/> Adenosquamous <input type="checkbox"/> Clear cell SCC <input type="checkbox"/> Desmoplastic <input type="checkbox"/> Other:
Degree of differentiation	<input type="checkbox"/> Well differentiated <input type="checkbox"/> Moderately differentiated <input type="checkbox"/> Poorly differentiated	
Tumour histological thickness*mm	
Invasion beyond subcutaneous fat	<input type="checkbox"/> No <input type="checkbox"/> Yes	
Perineural invasion	<input type="checkbox"/> No <input type="checkbox"/> Yes	
Lymphatic/vascular invasion	<input type="checkbox"/> No <input type="checkbox"/> Yes	
Complete excision:	<input type="checkbox"/> No <input type="checkbox"/> Yes	
Minimum lateral margin:mm	
Minimum deep margin:mm	

* Tumour thickness measured from the granular layer of adjacent normal epidermis to the base of the tumour (per 8th TNM classification for carcinomas of the skin).

Box 3 Pathology report.

Pathology report	Consensus-based statement
GPP	<p>If invasive SCC is suspected, a histopathological diagnosis shall be made.</p> <p>The following histological characteristics shall be included in the pathology report: type of specimen (e.g. shave, punch, excisional), histological thickness or depth of invasion, grade of differentiation, presence of perineural invasion, desmoplastic type and margins status.</p> <p>It may also include histologic subtype, lymphovascular invasion and caliber of affected nerves with PNI if ≥ 0.1 mm.</p> <p>Strength of consensus: 100%.</p>

6. Prognostic factors for high-risk cSCC

High-risk cSCC is defined as invasive cSCC without locoregional (in transit or nodal) or distant metastasis (staged as N0 and M0), that has features associated with a higher risk for local recurrence and metastasis (Box 4) [117]. The assessment of the prognostic risk is particularly relevant for common cSCC to identify the few with a high-risk of local recurrence, metastasis, or death, among all the other low-risk tumours. The ascertainment of high-risk prognostic factors defining high-risk cSCC has an impact on further management, with more aggressive surgical treatment and more regular follow up recommendations.

Studies reported various prognostic high-risk factors including the maximum clinical diameter (mm) of the tumour [42,43,118–120], histological thickness [43,57,119,120], tumour invasion level [42,118–120], the presence of desmoplasia [43,57,115,118,121,122], poor differentiation [120,123], PNI [120], location [42,43,120], or immunosuppression [43,57,122]. The variability of high-risk factors proposed in current guidelines is due to the variability of reported evidence [1,3,4,124]. Nevertheless, similar risk factors are proposed in the British Association of Dermatologists (BAD) guidelines, the NCCN guidelines and the European guidelines, regarding the highest risk associated with local recurrence and nodal metastasis (Table 5). Retrospective studies usually include a small number and/or heterogeneous groups of patients and investigate different prognostic outcomes.

A list of high-risk factors with evidence-based data portending a higher risk of local recurrence or nodal metastasis was proposed in the previous European guidelines 2020 and is shown in Box 4. The risk factors may be classified as intrinsic (tumour-related) or extrinsic (patient- and treatment- related). These proposed high-risk factors include clinical features (tumour diameter, location, symptomatic PNI), histological features (thickness or deep invasion, poor differentiation, desmoplasia, PNI), radiologic features (radiological PNI, bone erosion) and immunosuppression. In their recent prospective study, Haug et al., found that PNI occurs exclusively in desmoplastic cSCC. Tumour thickness ≥ 6 mm, size ≥ 20 mm, immunosuppression, PNI and

Table 5
Similarity of highest risk factors in current guidelines.

Present European Guideline 2023 - High-risk for local recurrence or metastasis	NCCN 2023 [3] – Very high-risk for local recurrence, metastasis, or disease-specific death	BAD Guideline 2020 [4] - Very high-risk for local recurrence, nodal metastasis, or disease-specific death
Diameter > 20 mm	Diameter > 40 mm	Diameter > 40 mm
Localization on lip/ear/temple	-	-
Thickness > 6 mm	Thickness > 6 mm	Thickness > 6 mm
Invasion beyond subcutaneous fat	Invasion beyond subcutaneous fat	Invasion beyond subcutaneous fat
Bone erosion	-	Bone invasion
Histological type: desmoplastic	Desmoplastic	Histological subtype: desmoplastic, adenosquamous, spindle/sarcomatoid/metaplastic
Poor differentiation	Lymphatic or vascular involvement	In-transit metastasis
Immunosuppression	Poor differentiation	Immunosuppression
PNI (microscopic, symptomatic or radiological)	-	Histological PNI in named nerve, nerve ≥ 0.1 mm or beyond dermis
Positive histological margins	Histological PNI of a nerve deeper than the dermis or ≥ 0.1 mm	One or more involved or close (< 1 mm) histological margin in a high-risk tumour

BAD, British Association of Dermatologists; NCCN, National Comprehensive Cancer Network; PNI, perineural invasion.

desmoplasia were independently associated with cSCC prognosis (local recurrence or metastasis) [115]. Regarding the risk factors for disease-specific death, immunosuppression was independently associated with a higher risk of disease-specific death in meta-analyses [7,50]. A prospective study in 1400 patients with localized cSCC at diagnosis also reported an independent association of immunosuppression with disease-specific death [122]. On the other hand, a retrospective study reported that immunosuppression was not associated with disease-specific death, however there were only 25 deaths in the immunosuppressed groups [125]. Additional risk factors reported for disease-specific death are shown in [Supplementary Table 3](#).

The role of extrinsic risk factors is more difficult to study, but it is clear in clinical practice, that many compromises in the management of early SCC, whether linked to patient requests to limit extent of surgery or to the physician's wish to simplify treatment, are responsible for a number of complications. Positive margins correspond to residual tumour, which a priori has potential for recurrence. When initial removal is incomplete, cSCC is more likely to recur, mostly locally and less frequently in regional lymph nodes [43,44]. A retrospective study in patients with high-risk cSCC reported that the accuracy of risk factors for staging systems may be compromised by inadequate excision rather than intrinsic high-risk factors. In patients treated with Mohs surgery, only poor differentiation and invasion beyond the subcutaneous fat were associated with worse prognostic outcomes [126]. Recurrence is not included as a high-risk factor for subsequent recurrence, considering that primary recurrence was a result of another underlying high-risk factor.

In the current update, a breakdown of these risk factors associated with different prognostic outcomes has been added based on available evidence from prospective studies and updated meta-analyses ([Supplementary Table 1](#)). Current meta-analyses have shown that each risk factor for the primary cSCC differentially affects the risk of subsequent local recurrence, or nodal metastasis or disease-specific death ([Supplementary Tables 2 and 3](#)) [7]. This is particularly relevant for the choice of treatment, as local recurrence may often be amenable to surgical excision, while nodal metastasis may require extensive surgery and/or systemic treatment, and disease-specific death is a rare but fatal outcome. (**Box 4**) Future studies reporting individual prognostic outcomes may add additional evidence to modify this list. In addition, as shown in the Brigham and Women's hospital (BWH) staging system, the combination of two or more high-risk factors (among poor differentiation, PNI, clinical diameter and invasion beyond subcutaneous tissue), significantly increases the risk of negative outcomes. In view of current gaps of knowledge on the precise risk of each factor individually, as well as on additional factors influencing this risk, it is recommended to consider the variations of patient- and tumour-related characteristics when assessing the level of overall prognostic risk.

A 40-gene expression profile (GEP) test was developed and validated for predicting risk for metastasis in localized, high-risk cSCC [127]. The combination of 40-GEP results with clinicopathological risk factors improved the metastatic risk classification of cSCCs [128].

Box 4 A proposed list of indicative prognostic high-risk factors for local recurrence or nodal metastasis of cSCC.

A list of intrinsic (tumour-related) and extrinsic and patient- and treatment-related) high-risk factors for local recurrence or nodal metastasis	
Grade of recommendation: B	<ol style="list-style-type: none"> 1. tumour diameter (> 20 mm) 2. localization on lip/ear/temple 3. thickness > 6 mm or invasion beyond subcutaneous fat 4. poor grade of differentiation 5. desmoplasia^a 6. microscopic, symptomatic, or radiological PNI 7. bone erosion 8. immunosuppression^b 9. positive surgical margins
Level of evidence: 2	<p>Systematic review and meta-analysis of 36 studies (of which only five prospective). Quality of evidence low to moderate [16]. Meta-analysis [7].</p> <p>Retrospective study in patients treated with microscopically controlled surgery [116,126]. Retrospective studies [48,112,116,119,120,123,125,129–131]. Prospective studies [43,115].</p> <p>Systematic review showing worse prognosis with clinical PNI compared to histological PNI [132].</p> <p>Systematic review on cSCC with bone invasion [133].</p> <p>Strength of consensus: 100%.</p>
cSCC, cutaneous squamous cell carcinoma; PNI, perineural invasion.	
^a Other histologic types have been reported to portend a higher recurrence risk, such as acantholytic or adenosquamous type, but with less supportive evidence.	
^b Immunosuppression defined in the study of Eigentler et al.: organ transplantation, HIV, chronic lymphatic leukaemia or another hematologic malignancy [57]; Immunosuppression not specifically defined in the meta-analyses [7,16]. Zakhem et al., reported higher risk of organ transplantation and of HIV for local recurrence and of organ transplantation for nodal metastasis (Supplementary Table 2).	

7. Staging systems for cSCC

There are currently four available staging systems worldwide: the UICC 8th edition (Union for International Cancer Control) [14], the AJCC 8th edition (American Joint Committee on Cancer) [15], the BWH [134] and the Breuninger/Tübingen staging system [135]. Furthermore, there are two additional staging systems for nodal disease of the head and neck (NIS3 [136] and immunosuppression, treatment, extranodal spread, and margin status [ITEM] [137]) (Tables 6–8).

The T stage of the UICC and the AJCC staging system are traditionally based upon the size of the tumour, including only tumour depth and perineural

invasion as additional risk factors. They differ on two items in the T-staging: Tumours of 2 cm are staged T2 in the UICC whereas they are staged in the AJCC staging system as T1 tumours. Secondly, the UICC defines PNI as clinical or radiographic involvement of named nerves without foramen or skull base invasion or transgression, whereas the AJCC includes nerves with PNI when a nerve lies deeper than the dermis or measures ≥ 0.1 mm in calibre. The BWH staging system is built up of the following risk factors: tumour diameter ≥ 2 cm, poorly differentiated histology, perineural invasion of nerve(s) ≥ 0.1 mm in caliber, or tumour invasion beyond subcutaneous fat (Table 6). The T-stage increases with the number of risk factors. Both the BWH and Breuninger staging system do not include a N or M classification system (Table 6).

The few past years many groups have studied the validity of the various systems for predicting the risk of recurrence or metastasis. Ruiz et al. compared AJCC and BWH in a population of 680 head and neck cSCC [138]. High risk cSCC (AJCC8 [T3/T4] and BWH [T2b/T3]) accounted for 121 (18%) versus 63 (9%) of total cases, 17 (71%) versus 16 (70%) of metastases, and 11 (85%) versus 12 (92%) of deaths. The AJCC8 T2 and T3 comprised 23% of cases and had statistically indistinguishable outcomes. The authors report a higher specificity (93%) and positive predictive value (30%) for identifying cases at risk for metastasis or death by BWH. There was no difference for local recurrence (LR) and overall survival (OS) [138]. Conde-Ferreiros et al., proposed a prognostic subclassification of the T3 of AJCC8 staging (Salamanca's refinement) [139]. However, Venables et al. did not confirm any improvement in AJCC8 T3 staging with this subclassification in their validation study on 1774 cSCC [140]. The validation study of Venables et al., investigated the performance of AJCC8, BWH, Tübingen staging systems and Salamanca T3 refinement in predicting metastasis on 887 metastatic cSCC and 887 non-metastatic cSCC. The BWH system showed the highest specificity (92.8%, 95% CI 90.8–94.3%) and c-index (0.84, 95% CI 0.82–0.86) [140]. They concluded that although BWH showed the highest overall discriminative ability, positive predictive value was low for all staging systems. However, the study does have some limitations like the fact that the authors assume that the diameter criterion of ≥ 0.1 mm must have been met if PNI was reported, so a currently included T3 tumour might be a T1 tumour if PNI is in a nerve < 0.1 mm. In another study Roscher et al. compared AJCC 7, AJCC 8, BWH and Breuninger's staging system [141]. They found that in the systems used by Breuninger et al. and the BWH system gave the best result in predicting the risk of metastasis. Using the system by Breuninger et al., the risk of metastasis was 3-fold for the high co-risk factors (OR: 3.27; 95% CI:1.54–6.96). The BWH staging system gave ORs for metastasis at 6.58 (95% CI: 2.90–14.90) for the T2a

Table 6
T classification systems (T-primary tumour).

UICC	AJCC	BWH ^a	Breuninger
cT Primary tumour	cT Primary tumor	T1 0 High-risk factors	cT: Tumour size (clinical; two classes) Low risk ≤ 2 cm
TX Primary tumour cannot be assessed	T1 ≤ 2 cm in greatest diameter	T2a 1 High-risk factor	High risk > 2 cm
T0 no evidence of primary tumour	T2 > 2 cm and ≤ 4 cm in greatest diameter	T2b 2–3 High-risk factors	pT: Tumour thickness (histological) (three classes) Rates of metastasis No risk ≤ 2 mm
Tis Carcinoma in situ	T3 Tumor ≥ 4 cm in greatest diameter or minor bone invasion or perineural invasion or deep invasion ^c	T3 4 High-risk factors or bone invasion	Low risk > 2 –6 mm High risk > 6 mm
T1 Tumour ≤ 2 cm in greatest dimension	T4a Tumour with gross cortical bone and/or marrow invasion		Higher risk of metastasis: 1. Immunosuppression 2. Desmoplastic type or poor differentiation 3. Localization ear
T2 Tumour > 2 cm and ≤ 4 cm in greatest dimension	T4b Tumour with skull bone invasion and/or skull base foramen involvement		
T3 Tumour > 4 cm in greatest dimension or minor bone erosion or PNI or deep invasion ^b			
T4a Tumour with gross cortical /marrow invasion			
T4b Tumour with axial skeleton/skull base/foraminal involvement			

Clinical T classification for invasive cSCC used by the Union for International Cancer Control (UICC) 8th edition (for skin excluding eyelid, perianal, vulva and penis) [UICC], AJCC 8th edition (for head and neck) [15], BWH [134] and Breuninger/Tübingen [135]. In the case of multiple simultaneous cSCC, the tumour with the highest T category is classified and the number of separate tumours is indicated in parentheses, e.g., T2(5).

AJCC, American joint committee on cancer; BWH, Brigham and women's hospital; PNI, perineural invasion.

^a BWH high-risk factors include tumour diameter ≥ 2 cm, poorly differentiated histology, perineural invasion of nerve(s) ≥ 0.1 mm in caliber, or tumour invasion beyond subcutaneous fat (excluding bone invasion, which upgrades tumour to BWH stage T3).

^b Deep invasion defined as invasion beyond the subcutaneous fat and/or tumour depth/thickness > 6 mm (as measured from the granular layer of adjacent normal epidermis to the base of the tumour); PNI for T3 classification is defined as clinical or radiographic involvement of named nerves without foramen or skull base invasion or transgression.

^c Deep invasion defined as invasion beyond the subcutaneous fat or > 6 mm (as measured from the granular layer of adjacent normal epidermis to the base of the tumour), perineural invasion defined as tumour cells in the nerve sheath of a nerve lying deeper than the dermis or measuring 0.1 mm or larger in caliber or presenting with clinical or radiographic involvement of named nerves without skull base invasion or transgression.

category and 35.34 (95% CI: 9.76–128.06) for the T2b category. They also state that current staging systems for cSCC are unsatisfactory in identifying non-selected patients with cSCC at high risk for metastasis [141].

The AJCC8 pathological lymph node (pN) classification is also used for mucosal head and neck cancers. Extra-nodal extension (ENE) is as well a known risk factor in mucosal head and neck cancer. For cSCC of the head and neck, Ebrahimi et al. showed that ENE has a poor predictive performance and patient distribution in their population because of the high amount of ENE [142]. He compared the AJCC staging system for nodal diseases with two alternative staging systems. The N1S3 system stratifies patients into only 3 stages (I–III) based on the size (≤ 3 versus > 3 cm) and number (single versus multiple) of nodal metastases. (Table 7) The ITEM prognostic score classifies patients with nodal metastasis of the head and neck into low-, moderate-, and high-risk groups based on a risk score derived from the presence of immunosuppression, treatment (surgery alone versus surgery and adjuvant radiotherapy), ENE and surgical margin status. In comparison with the N1S3 and ITEM score, N1S3 performed best (disease-specific survival: C-index 0.62, proportion of variation explained 10.9%; OS: C-index 0.59, proportion of variation explained 4.5%), although

still with a relatively poor predictive value [142]. In another study studied Ebrahimi et al. studied the impact of the number of lymph nodes on disease specific survival [143]. The study cohort included 1128 patients with lymph node metastasis in the head and neck. The number of nodal metastases was classified as 1–2 (N = 816), 3–4 (N = 162) and ≥ 5 (N = 150) nodes. In multivariate analyses, the risk of disease-specific mortality progressively increased with 3–4 nodes (Hazard ratio [HR], 1.58; 95% CI: 1.03–2.42; $p = 0.036$) and ≥ 5 nodes (HR, 2.91; 95% CI: 1.99–4.25; $p < 0.001$) with similar results for all-cause mortality. They concluded that this categorical variable provided superior prognostic information to the TNM stage [143].

Whereas the staging systems for Merkel Cell Carcinoma and melanoma include satellitosis or in-transit metastasis (S-ITM) in the TNM staging, none of the abovementioned staging systems for cSCC includes S-ITM. In a multi-institutional cohort study of 518 patients with cSCC, Smile et al., included 72 patients with S-ITM who were node-negative [144]. Sub-cohorts of patients with T3N0 tumours, T4N0 tumours (bone invasive), N1 to 3, and M1 disease were identified for comparison. Recurrence of cSCC included any local, regional, or distant disease. The 2-year cumulative incidence of cSCC recurrence rates were 18.8% (95% CI,

Table 7

Pathological classification for nodal disease used by the AJCC 8th edition (head and neck) [15], NIS3 [136] and ITEM (head and neck) [137].

AJCC8	NIS3 Stage	ITEM score	
pT Primary Tumour the same as cT classification used by UICC/ AJCC in Table 6			Variable weight
pN Regional Lymph Nodes	I Single lymph node ≤3 cm	Immunosuppression: Yes/ no	Score*
NX Regional lymph nodes cannot be assessed	II Single lymph node > 3 cm or multiple lymph nodes ≤3 cm	Treatment: Sx + RT/ Sx only	1.8/0
N0 No regional lymph node metastasis	III Multiple lymph nodes measuring > 3 cm	Extracapsular spread: Yes/ no	-1.8/0
N1 Metastasis in a single ipsilateral lymph node ≤3 cm in greatest dimension, ENE (-)		Margin status: Involved/ clear	4.8/0
N2a Metastasis in single, ipsilateral lymph nodes ≤ 3 cm and ENE (+) or, > 3 cm and ≤6 cm in greatest dimension, ENE (-)		<i>Risk group according to score</i>	<i>HR</i>
N2b Metastasis in multiple ipsilateral lymph nodes, all ≤6 cm in greatest dimension, ENE (-)		Low ≤2.6 score	1.00
N2c Metastasis in bilateral or contralateral lymph node(s), all ≤6 cm in greatest dimension, ENE (-)		Moderate > 2.6-3 score	4.56
N3a Metastasis in a lymph node > 6 cm in greatest dimension, ENE (-)		High > 3 score	9.46
N3b Metastasis in a lymph node > 3 cm in greatest dimension, ENE (+) or multiple ipsilateral, or any contralateral or bilateral node(s), ENE (+)			
M Distant Metastasis			
M0 No distant metastasis			
M1 Distant metastasis			

AJCC, American joint committee on cancer; ENE, extranodal extension; HR, Hazard ratio; ITEM, immunosuppression, treatment, extranodal spread, and margin status; RT, radiotherapy; Sx, surgery.

* The ITEM score was based on the four variables (immunosuppression, treatment, extracapsular spread, and margin status) that were significant in multivariate analysis as important predictors of prognosis. For instance, a patient with nodal disease who uses immunosuppression, is treated with Sx alone, presence of ENE and involved margins has an ITEM score of 7.6, meaning a HR of 9.46 to die from disease compared to a low risk patient.

Table 8

Staging based on UICC TNM classification 8th edition (2017) for all locations of cSCC excluding eyelid, perianal, vulva and penis, and based on AJCC TNM classification 8th edition (2017) for cSCC of the head and neck [14,15].

Stage 0	Tis	N0	M0
Stage I	T1	N0	M0
Stage II	T2	N0	M0
Stage III	T3	N0	M0
	T1, T2, T3	N1	M0
Stage IVA	T1,T2,T3	N2, N3	M0
	T4	Any N	M0
Stage IVB	Any T	Any N	M1

AJCC, American joint committee on cancer

18.7–18.9%) for T3N0, 28.6% (95% CI, 27.5–29.8%) for T4N0, 53.2% (95% CI, 52.4–54.0%) for N1 to 3%, and 56.6% (95% CI, 55.9–57.3%) for S-ITM. Disease-specific survival in the S-ITM cohort was comparable to those who are node-positive. They proposed that satellite/in-transit metastases should be incorporated into staging systems [144].

8. Staging work-up

Recommendations for the staging work-up of cSCC are shown in Fig. 1. Staging for recurrent cSCC is the same as for primary cSCC.

8.1. Physical examination

The diagnosis of cSCC should prompt a complete and careful physical examination including primary tumour, total-body skin examination for the presence of other skin disorders as dermatoheliosis, AK, other skin cancers, chronic inflammatory diseases or signs of diseases with increased risk of cSCC (albinism, xeroderma pigmentosum, etc.) and evaluation of the skin surface of the primary site to rule out in-transit metastasis [145].

Although the overall risk of lymph node involvement is relatively low (up to 5%) in invasive cSCC [42], all patients should undergo a careful physical examination and palpation of the regional lymphatic basins [43,146]. This approach is sufficient in most low-risk cSCC. In case of a clinically or radiologically detected regional node, a fine needle aspiration cytology (FNAC) is recommended [147]. As an alternative to FNAC, ultrasound-guided core biopsy can be done [147]. (Fig. 1).

8.2. Nodal imaging

The need for staging procedures is not well established due to limited data for cSCC from the literature. In patients with common primary cSCC but without palpable lymph nodes imaging for staging is recommended only in patients with high-risk cSCC according to EADO risk factors (Box 4) (Fig. 1). Imaging

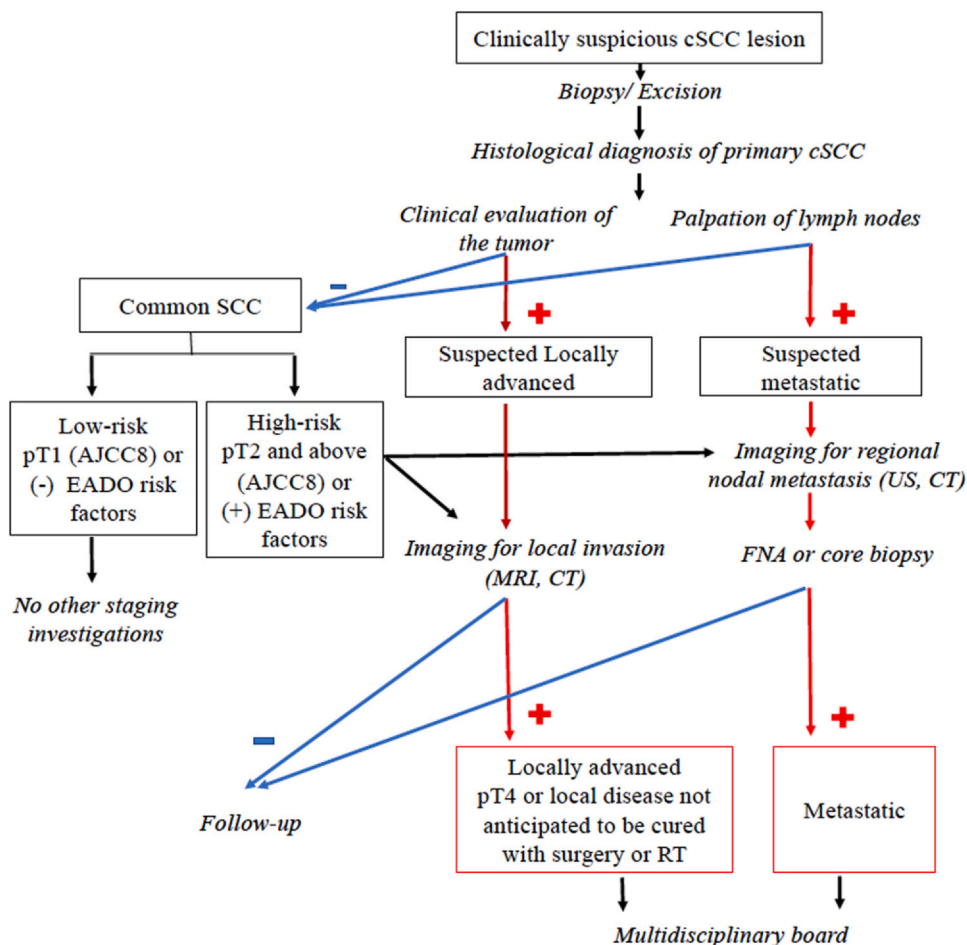


Fig. 1. Algorithm for the diagnostic approach and staging in patients with cSCC. Strength of consensus: 100%. EADO risk factors listed in Box 4. AJCC, American joint committee on cancer; EADO, European Association of Dermato-Oncology.

methods such as ultrasonography (US), computed tomography scan (CT) or positron emission tomography computed scan (PET-CT) are more sensitive than clinical examination [146–148]. There are limited data on the use of US for nodal metastasis for cSCC. There is some evidence in patients with vulvar cSCC or head/neck SCC. A study of 44 patients with vulvar cSCC and suspected inguinal lymph node metastases reported that US had a higher sensitivity and negative predictive value than CT, but lower specificity and positive predictive value [149]. A meta-analysis (17 studies) in patients with head and neck squamous cell carcinoma (HNSCC) (not cSCC) evaluated radiological imaging modalities including US, US-guided FNAC (USgFNAC), CT, and magnetic resonance imaging (MRI) for the detection of lymph node metastases. USgFNAC showed the highest diagnostic odds ratios. US performed significantly better than MRI. Mean sensitivity of 87% was highest for US and specificity of 98% was highest for USgFNAC. However, there were only two studies addressing the evaluation of clinically N0 necks [148]. In a retrospective study of baseline and surveillance imaging in 87 high-risk cSCC, disease was detected in 26 (30%)

of cases of which 18 were subclinical [150]. In a larger retrospective study in 246 high-risk HNSCC, who underwent baseline ultrasonographic imaging of their lymph nodes (cervical and parotid), this was more sensitive (sensitivity 91%, specificity 78%) than clinical examination alone (sensitivity 50%, specificity 96%) for the detection of lymph node metastasis. The authors concluded that the high sensitivity of ultrasound for surveillance detection of nodal metastases should be evaluated against the high rate of false-positive findings, as explored with FNAC biopsy [151].

As lymph node metastases from cSCC may be more superficial and easier to detect on US than those from mucosal SCC, US performed by experienced physicians may be a cost-effective minimally invasive staging modality for lymph nodes [146].

8.3. Imaging for lacSCC and distant metastasis

For staging of advanced cSCC, consultation in a multidisciplinary tumour board including a radiologist is mandatory to optimize the use of imaging modalities. In large cSCC or those with possible involvement of

underlying structures (orbital invasion, PNI), additional imaging tests, such as CT or MRI may be required to accurately assess the extent of the tumour and the presence of metastatic spread [132,152–154]. MRI is indicated for subtle intracranial disease, perineural spread¹¹⁹, and imaging of tumour invasion in surrounding soft tissue [152,154]. CT scan and PET-CT are excellent techniques for the detection of metastatic involvement in distant organs [154] (Fig. 1).

One critical question is how these radiological investigations help the therapeutic choice with an impact on the course of the disease. A retrospective study of radiologic imaging for high-stage BWH T2b and T3 cSCC in 45 patients reported mainly CT (79%), PET/CT or MRI, while there was no patient in this cohort that underwent imaging with ultrasound. Imaging changed management in 16 (33%) patients [155].

Box 5 Imaging for staging.

Imaging for staging of cSCC	Evidence-based recommendation
GPP	<p>Patients with low-risk cSCC should undergo physical examination only with no need for imaging studies unless indicated by physical examination.</p> <p>Patients with primary common cSCC with high-risk factors* should be staged for non-palpable lymph node involvement, preferably by US or by CT scan.</p> <p>For suspected underlying tissue involvement (bone or soft tissue), CT or MRI should be done to determine extent of local infiltration. LacSCC should undergo imaging to rule out metastasis.</p> <p>cSCC with nodal involvement should undergo a full skin examination and imaging studies to rule out distant metastatic disease.</p>
Level of evidence: 3	<p>There are no precise clinical guidelines for radiologic evaluation for cSCC [152].</p> <p>Meta-analysis of studies for the detection of lymph nodes metastases in HNSCC (only two studies addressing the evaluation of clinically N0 necks) [148].</p> <p>Retrospective studies [149,151,155–158].</p> <p>Review of studies on nodal staging of high-risk cSCC [146].</p> <p>Strength of consensus: 100%.</p>
<p>AJCC, American joint committee on cancer; BWH, Brigham and women's hospital; cSCC, cutaneous squamous cell carcinoma; GPP, good clinical practice point.</p> <p>* Specification of high-risk factors for imaging for non-palpable regional nodal metastasis cannot be given, as the independent effect of high-risk factors has not been consistently reported. cSCC at higher risk for nodal metastasis according to staging systems include (but are not restricted to) AJCC8 T3/T4 and BWH T2b/T3 stages.</p>	

8.4. Sentinel lymph node biopsy (SLNB)

SLNB for patients with cSCC aims at the detection of occult nodal metastasis with the hope that their early management may improve prognosis (Stratigos et al. Guidelines. Part 2. Eur J Cancer 2023). The systematic review of Tejera-Vaquero et al., in 2018 (23 studies), reported positive SLNB in 8% of patients with cSCC, and found no studies reporting on predictors of SLN involvement or on the prognostic utility of SLN following adjustment for confounders [159]. The systematic review of Navarrete-Dechent et al., reported an overall positive rate of SLNB of 13.9% (32 of 231 patients) and false-negative rate of 4.6% in cSCC [160]. However, published studies include small number of patients and are heterogeneous [161–165]. The meta-analysis of Schmitt et al., (19 studies, 130 patients with non-anogenital cSCC) investigated the possibility of staging as a predictor of SLNB results. It identified microscopical involvement of the sentinel lymph node in 12.3% of patients, with all cases having tumours larger than 2 cm [166]. The risk of having a positive sentinel lymph node increased with the tumour stage and varied from 0% in AJCC T1 tumours to 60% in AJCC T4 tumours, and reached 7.1% (6/85) in BWH T2a, 29.4% (5/17) in BWH T2b and 50% (3/6) in BWH T3 stages [166]. A recent retrospective study in 720 patients with cSCCs with a thickness of at least 6 mm (all considered as high risk SCC according to German guidelines) compared SLNB (150 patients) with observation (570 patients). A positive sentinel node was detected in 3.96% of patients in the sentinel lymph node biopsy group. The rate of lymph node metastasis did not significantly differ between groups (11.9% and 11.4%, respectively) after a median follow-up of 3 years. Similarly, differences in tumour-specific deaths (7.14% in sentinel lymph node group versus 4.74% in observation group) were not statistically significant [167]. A cost-effectiveness model study based on the change in quality-adjusted life years (QALYs) and costs, reported that the most cost-effective strategy was not to perform SLNB, regardless of the patient's stage. The authors mentioned that this was attributed to the low rates of nodal metastasis in addition to low disease-specific death [168]. The systematic review by Costantino et al., included 705 patients from 20 studies. The pooled SLN identification rate was 98.8%, suggesting SLNB feasibility. However, the authors suggested that the low pooled SLNB positivity rate of 5.6% and the relatively high cumulative regional recurrence rate in negative SLNB (2.9%) raise doubts concerning its clinical utility [169]. In summary, SLNB cannot be currently recommended in invasive cSCC as a standard of care, since evidence is lacking about the real prognostic impact [160] and the characteristics of patients that could eventually benefit from this procedure are not well defined [170–172].

Box 6 Sentinel lymph node biopsy (SLNB).

SLNB for cSCC	Evidence-based recommendation
Grade of recommendation: X Level of evidence: 3	SLNB is currently not recommended in the management of cSCC as a standard of care. No evidence of prognostic advantage in the detection of occult metastatic disease by SLNBs [159,160,168]. Meta-analysis [159,173]. Systematic review [169,170]. Strength of consensus: 100%.

9. Primary and secondary prevention

Increased ambient UV exposure, both chronic or intermittent, professional or recreational sun exposure, in childhood and adulthood is associated with an increased risk for cSCC. Public health interventions aiming to reduce UV exposure in the general population can be cost-effective in reducing the incidence and the associated medical costs of skin cancers, including cSCC [174–176]. Behavioural interventions have been shown to be effective in increasing sun-protection measures, yet there is limited evidence on their effects on reducing sunburns and on improving skin cancer outcomes [177]. Multi-component strategies are considered as most effective for inducing changes in sun exposure behaviour, such as mass media campaigns, environments offering shaded areas, family-oriented behavioural counselling for the early childhood interventions and increasingly, digitally delivered interventions [175,177–180]. Messages of sun avoidance between 10 am and 4 pm, wearing long-sleeved clothing, applying broad-spectrum sunscreen and avoiding sunbed use are useful but these interventions are struggling with strong social trends valuing pleasure associated with sunbathing and seaside vacations, and perception of suntan considered as aesthetic as well as a false marker of good health.

Regular use of sunscreen has been reported to be effective in reducing the incidence of AK and cSCC in four randomized controlled trials and several non-randomized experimental prospective studies, in the general population and organ transplant recipients [181–184]. However, in two meta-analyses there was no significant effectiveness of sunscreen for preventing either melanoma or nonmelanoma skin cancers, but these included also retrospective studies and studies that analysed use of only UVB filters [185,186]. Thus, recommendation for regular sunscreen use remains as a third measure for effective sun protection if sun exposure cannot be avoided, along with seeking shade and the wearing of

clothing to cover the skin, which are the main measures for effective sun protection. A clear message of strict photoprotection measures should be given to all patients who have already developed cSCC.

Specific situations may require specific preventive and screening measures: In 2010, the International Commission on non-ionizing radiation published a statement on necessary protection of workers against ultraviolet radiation, and in several countries keratinocyte cancer is officially recognized as an occupational disease in outdoor workers [187,188]. Risk-tailored screening procedures were developed for organ transplant recipients in Australia and the UK and similar efforts are under way in the USA [35,189,190].

Box 7 Prevention.

Prevention	Evidence-based recommendation
GPP	Education about sun protection measures including avoidance of sun bathing, use of protective clothing, regular use of sunscreens and avoidance of artificial UVR tanning, shall be recommended.
Level of evidence 1	Behavioural counselling interventions shall be recommended. Systematic review of randomized controlled trials, four RCT [174,175,177–180,191–193].
Level of evidence 1	Regular use of sunscreens shall be recommended. Systematic search of the literature de-novo. Four prospective RCT confirmed reduction in SCC rate [181–184].
Level of evidence 2	Public health interventions to reduce UV exposure in general population. Two RCT and five before and after trials [174,175,177,178,194–197]. Strength of consensus: 100%
GPP, good clinical practice point; UVR, ultraviolet radiation; RCT: randomized controlled trials.	

10. Chemoprevention

Chemoprevention aims to reduce the risk of the development of new cSCC, especially for patients at risk of developing numerous and/or aggressive cSCC [198]. Systemic agents studied for the chemoprevention of cSCC include retinoids, nicotinamide and non-steroidal anti-inflammatory drugs (NSAIDs). Oral retinoids studied include acitretin and isotretinoin [198–201], which were shown to be effective in reducing the incidence of new cSCC at least during the

duration of treatment in high-risk patients. They are, however, not routinely recommended, due to risk of teratogenicity and the dose-related toxicities that are not well tolerated by patients [202,203]. Nicotinamide is a water-soluble form of vitamin B₃ (niacin). It may enhance repair of photodamaged DNA and prevent the immune-inhibitory effects of UVR [204]. A meta-analysis of nicotinamide in skin cancer reported that nicotinamide for 6–12 months significantly reduced the rate of new cSCC, compared with placebo-controls in high-risk patients and SOTRs (rate ratio 0.48 (95% CI, 0.26–0.88) [205]. There is only one randomized controlled trial in 386 immunocompetent patients with a history of at least two nonmelanoma skin cancers. At 12 months, there was a lower rate of new cSCCs with nicotinamide 500 mg twice daily (reduction by 30% compared to placebo, $p = 0.05$) The positive effect was limited to the active treatment period [206]. Nicotinamide was safe and well tolerated [206]. An increased risk of digestive adverse events with nicotinamide compared to control, has been reported, that resolved upon dose reduction or withdrawal [205].

NSAIDS use was associated with a reduced risk of cSCC in a meta-analysis (2015), with significant study heterogeneity [207]. In a UK population-based case-control analysis in patients with incident cSCC, there was a slightly decreased risk of cSCC in regular users of any NSAIDS (OR: 0.89, 95% CI: 0.82–0.97) [208]. An Australian cohort study reported inconsistent patterns of association of NSAID use that did not provide convincing evidence that NSAID may reduce subsequent cSCC risk [209]. For anti-oxidants, phytochemicals and selenium, the current evidence is inconclusive. Vitamin D3 plus calcium had no statistically significant effect in reducing new self-reported nonmelanoma skin cancers in a randomized controlled trial (RCT) in 36,282 postmenopausal women [210]. Vitamin D supplementation alone had no significant effect on reduction of cSCC in a RCT of 2259 men and women [211].

Topical treatments for chemoprevention include 5% 5-fluorouracil (5-FU) [198] that was shown to be effective in reducing the risk of cSCC requiring surgery by 75% in one RCT. A 2–4 weeks course appeared to have a protective effect for one year, with non-significant effect thereafter. 92% of participants in the fluorouracil group reported erythema and 61% had mild-to-moderate crusting [212] Addition of calcipotriol to 5-FU has been shown to increase the benefit [213]. Topical tretinoin has no significant effect in preventing cSCC [214].

Box 8 Nicotinamide for chemoprevention in immunocompetent patients with a history of multiple cSCC.

Nicotinamide chemoprevention in immunocompetent patients	Evidence-based recommendation
Grade of recommendation C	Nicotinamide 500 mg twice daily may be offered to immunocompetent patients with a history of multiple cSCC, considering the favourable safety profile.
Level of evidence 3	One randomized controlled trial showed significantly lower risk of new cSCC with nicotinamide at 12 months (by 30%), $p = 0.05$ [206]. Systematic review [205]. Strength of consensus: 100%.

11. Prevention in immunocompromised patients

cSCCs represent a significant and growing burden of disease in immunocompromised patients. Health education, risk-stratified surveillance, targeted implementation of preventative strategies and rapid access to diagnosis and treatment may all contribute to reducing the impact of cSCC in this high-risk population and is increasingly being delivered in specialist clinics [215–219]. Current evidence and expert consensus guidelines for prevention of cSCC in immunocompromised individuals has mainly focused on organ transplant recipients (OTRs). However, the evidence base for guiding decision-making is limited, particularly in terms of selecting the most effective treatments and the thresholds at which to initiate and sequence each strategy [220–222].

11.1. Primary prevention in immunocompromised patients

Strict photoprotection (including sunscreen, appropriate clothing and behavioural measures) is usually recommended considering the literature on the prevention of carcinoma in immunocompetent patients [181,222–224]. However, evidence that sunscreen is effective in cSCC prevention in immunosuppressed individuals is limited to a non-randomized, open-label trial of sunscreen which showed a significant reduction in cSCC at 24 months [184]. Vitamin D levels were lower in the sunscreen group and monitoring is advisable [225]. In view of UVA-photo-sensitivity associated with azathioprine, sunscreen with significant UVA protection should be used all-year round

[226]. There is evidence that photoprotection advice is better recalled and implemented if provided in a specialist clinical setting [217,218]. The advice provided should be individualised in order to improve adherence [221,227] and photoprotection advice, in particular, should be tailored to skin type [228]. Behavioural interventions (written material, text messages, mobile apps and videos) in OTRs improve sun protection behaviour, knowledge, attitudes and biologic measures of UV exposure, but whether this translates into cSCC prevention has not been confirmed [221].

11.2. Secondary prevention in immunocompromised patients

11.2.1. Systemic chemoprevention

11.2.1.1. Retinoids

Three RCTs in OTRs confirm that retinoids confer a significant reduction in AK and/or cSCC [229–231], with an estimated 54% reduction in cSCC overall [232]. Adverse effects may be dose limiting and include cheilitis, xerosis, alopecia, headache, musculoskeletal complaints and hyperlipidaemia [232–235] and approximately 14% discontinuation as a result [232]. Laboratory monitoring is required (liver function tests, lipids). A rebound increase in cSCCs 3–4 months after discontinuation is common [202,233]. There are few data relating to use in non-OTR immunocompromised patients and whether isotretinoin has similar chemopreventive properties in OTRs is unclear. Despite widespread use, there is no Food and Drug Administration (FDA) or EMA approval for their use in cSCC chemoprevention. Consensus opinion recommends starting at low dose (e.g. 10 mg/day acitretin) and escalating as tolerated to an effective maintenance dose (e.g., up to 30 mg/day acitretin) [236]. Further research is needed to clarify indications for their initiation, as well as the tolerability and efficacy of optimal dosing regimens [222]. Because of potential rebound cSCC development, when discussing initiation with patients, retinoid chemoprevention should be viewed as long term strategy requiring laboratory monitoring (liver function tests, lipids) [202].

11.2.1.2. Nicotinamide

In comparison to systemic retinoids, nicotinamide had few adverse effects in clinical trials and does not require laboratory monitoring [235]. However, chemoprevention of keratinocyte cancers has not been confirmed in prospective RCTs in immunocompromised patients [222]. Two small RCTs in OTRs have provided a signal of efficacy but were underpowered [237,238]. A recent phase 3 RCT evaluated nicotinamide 500 mg or placebo twice daily for 12 months in 158 OTRs with a history of at least two keratinocyte cancers during the past 5 years. There was no significant between-group difference in the number of new cSCCs and the adverse event profile was similar between nicotinamide and placebo. The trial was

limited by poor recruitment and it was underpowered. Another possible explanation provided by the authors is that, in OTRs, nicotinamide may not be able to overcome the additional suppression of both antitumor immunity and DNA-repair enzymes conferred by the immunosuppressive treatments [239].

11.2.1.3. Capecitabine

Capecitabine is an oral 5-fluorouracil prodrug [240]. Limited observational data suggest it has a cSCC chemopreventive effect in OTRs [241–243]. However, it has significant dose-limiting side-effects (fatigue, hand-foot syndrome, diarrhoea, nausea/vomiting, mucositis, anaemia, hyperuricemia/gout) resulting in discontinuation in 43% of patients [243]. It is not FDA/EMA approved for cSCC chemoprevention and optimal dosing regimens are not established [243,244]. Further clinical trials are required to establish optimal patient selection, dosing, safety and long-term efficacy [243,244].

11.2.2. Modification of immunosuppression

This is a potential approach to secondary cSCC prevention, but there is limited evidence regarding when and how exactly it should be undertaken and factors such as the type of allograft, the risk status of individual tumours and the rate of accrual of tumours should all be considered [222,234,245].

Minimisation of immunosuppression and conversion to alternative immunosuppressive drugs

The overall intensity of immunosuppression may be as important as the role of individual drugs, but there is no robust measure for immunosuppressive intensity to guide decision-making [222]. There is also relatively limited evidence to guide which specific drugs should be reduced or discontinued, although there is evidence that azathioprine confers a particularly high cSCC risk compared to mycophenolate mofetil [246,247]. However, there is less evidence for significant differences between the calcineurin inhibitors (CNIs) [246,247]. Conversion from calcineurin inhibitor to the selective T-cell costimulatory blockade agent, belatacept, may be associated with a lower risk of cSCC [248].

Conversion to mTOR inhibitors

Several RCTs have now demonstrated that conversion from CNIs to mTOR inhibitors after a first cSCC reduces risk of subsequent cSCC, with a non-significant reduction of subsequent cSCCs with conversion after more than one cSCC [249–252]. mTOR inhibitors do not appear to have a primary protective effect against post-transplant cSCC [253,254]. A reduction of 56% in keratinocyte cancers with mTORi use was confirmed in a meta-analysis of 5876 OTR from 21 RCTs, but an overall increase in mortality was also reported [255], although this may reflect the

higher doses of mTORi used in early trials [256]. However, the adverse effect profile of mTORi (including delayed wound healing, diarrhoea, mucositis and peripheral oedema), leads to high rates of discontinuation [257].

11.3. Sequencing of cSCC prevention approaches

There are considerable gaps in the evidence base to guide selection and thresholds for initiation of appropriate chemo preventive approaches in immunocompromised patients [245]. In an e-Delphi study of cSCC prevention in OTRs, although consensus was reached on photoprotection and treatment of AK, no consensus was reached for prevention strategies after the first invasive cSCC. Despite RCT evidence for mTORi conversion, there was no consensus on this approach, because of concerns regarding adverse effects. For OTRs with multiple cSCC at low rates of accrual, modification of immunosuppression was recommended together with systemic chemoprevention, although no agreement as to which chemoprevention: perceived lack of evidence around nicotinamide in OTRs was cited as a barrier for its routine use. With higher rates of cSCC accrual (> 10/year), acitretin was recommended and was similarly first choice for high-risk cSCC [222]. However, optimal sequencing of cSCC prevention approaches remains to be established in prospective clinical trials [258].

11.4. Surveillance

Many post-transplant Clinical Practice Guidelines advise that all OTRs should be offered skin cancer surveillance at least annually [259], but there is limited evidence regarding effectiveness of this approach on cSCC prevention [215,260] and more risk-stratified approaches to surveillance have been proposed [190,261]. Potential risk reduction strategies such as educational advice on photoprotection and treatment of AK may be most effective if initiated in the pretransplant period [221], but the cost-effectiveness of pre-transplantation screening strategies has yet to be validated. Following transplantation, baseline assessment of skin cancer risk and health educational advice focusing on photoprotection, self-skin examination and early detection of

suspicious lesions is recommended, based on age, gender, skin phototype and organ type. Intervals for subsequent surveillance will depend on this initial risk assessment [190,260]. Several clinical risk prediction models have been used to inform risk-stratified surveillance programmes [190,261,262]. Most evidence on risk stratification, screening and surveillance in immunocompromised patient cohorts has focused on OTR, but other immunocompromised groups may also potentially benefit, and this has been particularly promoted in patients with CLL and inflammatory bowel disease [263–265].

Box 9 Prevention of cSCC in solid organ transplant recipients.

Prevention of cSCC in solid organ transplant recipients	Evidence-based recommendation
GPP	Education about routine skin surveillance, sun protection measures and use of sunscreen should be recommended. Oral retinoids should be considered in OTRs with one or more cSCC. Conversion to mTOR inhibitors in OTRs with one or more cSCC can be discussed with transplant physicians. Modification of immunosuppression in OTRs with one or more cSCC can be discussed with transplant physicians.
Level of evidence: 4	Sunscreen: one non-randomised case-control study of sunscreen in OTRs showed a reduction of cSCC [184].
Level of evidence: 3	Oral retinoids: RCTs and systematic reviews confirm cSCC prevention in small numbers of OTRs [229–232].
Level of evidence: 3	Conversion to mTOR inhibitors: cSCC prevention shown in RCTs and systematic reviews [249–257].
Level of evidence: 3	Modification of immunosuppression: non-randomised evidence that cSCC may be reduced in OTRs by modification of immunosuppression [222,246–248].

Summarizing box of recommendations

Practice points	Recommendation	GOR
1. Definitions and classifications of invasive cSCC	<p>Common primary cSCC shall be classified as high-risk or low-risk.</p> <p>High-risk cSCC is defined as invasive cSCC without locoregional (in transit or regional nodal metastasis) or distant metastasis (staged as N0 and M0), that has features associated with a higher risk for local recurrence and metastasis (Box 4).</p> <p>Advanced cSCC shall be classified as locally advanced (LacSCC), locoregional metastatic or distant metastatic cSCC.</p> <p>LacSCC shall be defined as non-metastatic cSCC, not amenable to either surgery or radiotherapy with reasonable hope for cure, because of multiple recurrences, large size, bone erosion or invasion, or deep infiltration beyond subcutaneous tissue into muscle or along nerves, or else tumours in which curative resection would result in unacceptable complications, morbidity or deformity.</p>	A
2. Clinical and non-invasive diagnosis of the primary cSCC	<p>Clinical diagnosis of the primary cSCC includes description of the lesion, recording of symptoms and location and measurement of the diameter.</p> <p>Photographic documentation is strongly recommended.</p> <p>Dermatoscopy can help in the differential diagnosis of cSCC pre-operatively.</p> <p>Confocal microscopy or OCT if available, can help in the differential diagnosis of cSCC pre-operatively.</p>	GPP
3. Pathology report	<p>If invasive SCC is suspected, a histopathological diagnosis shall be made.</p> <p>The following histological characteristics shall be included in the pathology report: type of specimen (e.g. shave, punch, excisional), histological thickness or depth of invasion, grade of differentiation, presence of perineural invasion, desmoplastic type and margins status.</p> <p>It may also include histologic subtype, lymphovascular invasion and caliber of affected nerves with PNI if ≥ 0.1 mm.</p>	GPP
4. High-risk factors for local recurrence or nodal metastasis	<ol style="list-style-type: none"> 1. tumour diameter (> 20 mm) 2. localization on lip/ear/temple 3. thickness > 6 mm or invasion beyond subcutaneous fat 4. poor grade of differentiation 5. desmoplasia 6. microscopic, symptomatic, or radiological PNI 7. bone erosion 8. immunosuppression 9. positive surgical margins 	B
5. Imaging for staging	<p>Patients with low-risk cSCC should undergo physical examination only with no need for imaging studies unless indicated by physical examination.</p> <p>Patients with primary common cSCC with high-risk factors* should be staged for non-palpable lymph node involvement, preferably by US or by CT scan.</p> <p>For suspected underlying tissue involvement (bone or soft tissue), CT or MRI should be done to determine extent of local infiltration. LacSCC should undergo imaging to rule out metastasis. cSCC with nodal involvement should undergo a full skin examination and imaging studies to rule out distant metastatic disease.</p>	GPP
6. SLNB	SLNB is currently not recommended in the management of cSCC as a standard of care.	X
7. Prevention	Education about sun protection measures including avoidance of sun bathing, use of protective clothing, regular use of sunscreens and avoidance of artificial UVR tanning, shall be recommended.	GPP
8. Nicotinamide chemoprevention in immunocompetent patients	Nicotinamide 500 mg twice daily may be offered to immunocompetent patients with a history of multiple cSCC, considering the favourable safety profile.	C
9. Prevention of cSCC in solid organ transplant recipients	<p>Education about routine skin surveillance, sun protection measures and use of sunscreen should be recommended.</p> <p>Oral retinoids should be considered in OTRs with one or more cSCC.</p> <p>Conversion to mTOR inhibitors in OTRs with one or more cSCC can be discussed with transplant physicians.</p> <p>Modification of immunosuppression in OTRs with one or more cSCC can be discussed with transplant physicians.</p>	GPP

GOR, grade of recommendation; GPP, good clinical practice point; SLNB, sentinel lymph node biopsy

Funding sources

The development of the current set of guidelines was supported solely by funds of the EADO which were used to mainly support the consensus meeting without honoraria and without reimbursement of travel costs.

CRediT authorship contribution statement

Alexander J. Stratigos: Conceptualization; Writing - Review & Editing, Writing - Original Draft, Supervision. **Claus Garbe:** Conceptualization; Writing - Review & Editing, Writing - Original Draft, Supervision. **Clio Dessinioti:** Conceptualization; Writing - Review & Editing, Writing - Original Draft, Supervision. **Celeste Lebbe:** Conceptualization; Writing - Review & Editing, Supervision. **Alexander van Akkooi:** Conceptualization; Writing - Review & Editing, Supervision. **Veronique Bataille:** Conceptualization; Writing - Review & Editing, Supervision. **Lars Bastholt:** Conceptualization; Writing - Review & Editing, Supervision. **Brigitte Dreno:** Conceptualization; Writing - Review & Editing, Supervision. **Reinhard Dummer:** Conceptualization; Writing - Review & Editing, Supervision. **Maria Concetta Fagnoli:** Conceptualization; Writing - Review & Editing, Supervision. **Ana Maria Forsea:** Conceptualization; Writing - Review & Editing, Supervision. **Catherine A. Harwood:** Conceptualization; Writing - Review & Editing, Supervision. **Axel Hauschild:** Conceptualization; Writing - Review & Editing, Supervision. **Christoph Hoeller:** Conceptualization; Writing - Review & Editing, Supervision. **Lidija Kandolf-Sekulovic:** Conceptualization; Writing - Review & Editing, Supervision. **Roland Kaufmann:** Conceptualization; Writing - Review & Editing, Supervision. **Nicole WJ Kelleners-Smeets:** Conceptualization; Writing - Review & Editing, Supervision. **Aimilios Lallas:** Conceptualization; Writing - Review & Editing, Supervision. **Ulrike Leiter:** Conceptualization; Writing - Review & Editing, Supervision. **Josep Malvehy:** Conceptualization; Writing - Review & Editing, Supervision. **Veronique del Marmol:** Conceptualization; Writing - Review & Editing, Supervision. **David Moreno-Ramirez:** Conceptualization; Writing - Review & Editing, Supervision. **Giovanni Pellacani:** Conceptualization; Writing - Review & Editing, Supervision. **Ketty Peris:** Conceptualization; Writing - Review & Editing, Supervision. **Philippe Saiag:** Conceptualization; Writing - Review & Editing, Supervision. **Luca Tagliaferri:** Conceptualization; Writing - Review & Editing, Supervision. **Myrto Trakatelli:** Conceptualization; Writing - Review & Editing, Supervision. **Dimitrios Ioannides:** Conceptualization; Writing - Review & Editing, Supervision. **Ricardo Vieira:** Conceptualization; Writing - Review & Editing, Supervision. **Iris Zalaudek:** Conceptualization; Writing - Review & Editing, Supervision. **Petr Arenberger:** Conceptualization; Writing - Review & Editing, Supervision. **Alexander M. M Eggermont:** Conceptualization; Writing - Review & Editing, Supervision. **Martin Röcken:**

Conceptualization; Writing - Review & Editing, Supervision. **Jean-Jacques Grob:** Conceptualization; Writing - Review & Editing, Supervision. **Paul Lorigan:** Conceptualization; Writing - Review & Editing, Writing - Original Draft, Supervision.

Declaration of Competing Interest

The authors declare the following financial interests/personal relationships which may be considered as potential competing interests: **Dr. Stratigos** reports personal fees and/or research support from Novartis, Roche, BMS, Abbvie, Sanofi, Regeneron, Genesis Pharma, outside the submitted work. **Dr. Garbe** reports personal fees from Amgen, personal fees from MSD, grants and personal fees from Novartis, grants and personal fees from NeraCare, grants and personal fees from BMS, personal fees from Pierre Fabre, personal fees from Philogen, grants and personal fees from Roche, grants and personal fees from Sanofi, outside the submitted work. **Dr. Dessinioti** has nothing to disclose. **Dr. Lebbe** reports grants and personal fees from Bristol-Myers Squibb, personal fees from MSD, personal fees from Novartis, personal fees from Amgen, grants and personal fees from Roche, personal fees from Avantis Medical Systems, personal fees from Pierre Fabre, personal fees from Pfizer, personal fees from Incyte, outside the submitted work. **Dr. Bataille** reports personal fees from Novartis, personal fees from Merck MSD, outside the submitted work. **Dr. Bastholt** reports personal fees for advisory board activity: BMS, Roche, Novartis, Pierre-Fabre, Astra Zeneca, InCyte, MSD/Merck, Bayer, outside the submitted work. **Dr. Dréno** reports grants and personal fees from BMS, personal fees from MSD, grants and personal fees from Roche, grants and personal fees from Fabre, grants and personal fees from Sanofi, outside the submitted work. **Dr. Dummer** reports intermittent, project focused consulting and/or advisory relationships with Novartis, Merck Sharp & Dhome (MSD), Bristol-Myers Squibb (BMS), Roche, Amgen, Takeda, Pierre Fabre, Sun Pharma, Sanofi, Catalym, Second Genome, Regeneron, Alligator, T3 Pharma, MaxiVAX SA, Pfizer, Simcere and touchIME outside the submitted work. **Dr. Fagnoli** reports personal consulting fees from Almirall, honoraria from Sanofi-Regeneron and participation in Advisory Board for Sanofi-Regeneron, outside the submitted work. **Dr. Forsea** reports scientific consultant/speaker fee from Novartis, Merck, outside the submitted work. **Dr. Harwood** reports institutional research grants and honoraria from Sanofi, Novartis, Merck, Pfizer, Galderma, MEDA, Almirall, Pellepharm, Leo Pharma, CERIES, outside the submitted work. **Dr. Hauschild** reports grants and personal fees from Amgen, grants and personal fees from BMS, grants and personal fees from Merck/Pfizer, grants and personal fees from MSD/Merck, grants and

personal fees from Philogen, grants and personal fees from Pierre Fabre, grants and personal fees from Regeneron, grants and personal fees from Roche, grants and personal fees from Sanofi-Genzyme, grants and personal fees from Novartis Pharma, grants and personal fees from Eisai, personal fees from Immunocore, grants and personal fees from Replimune, personal fees from Seagen, personal fees from IO Biotech, personal fees from Dermagnostix, personal fees from Incyte, grants and personal fees from NeraCare, personal fees from Highlight Therapeutics, grants from Huya Biosciences, personal fees from Kyowa Kirin, outside the submitted work. **Dr. Hoeller** reports personal fees from BMS, personal fees from Novartis, grants and personal fees from Amgen, personal fees from Almirall, personal fees from Pierre Fabre, personal fees from Sanofi, personal fees from MSD, outside the submitted work. **Dr. Kandolf-Sekulovic** reports speakers' honoraria for Roche, Novartis, MSD, BMS, Janssen outside the submitted work. **Dr. Kaufmann** reports institutional research grants (clinical trials) from: AbbVie, Amgen, Biontech, BMS, Celgene, Galderma, Janssen, Leo, Lilly, Merck, MSD, Novartis, Pierre Fabre, Pfizer, Regeneron, Roche, Wyeth. Advisory Board and Honoraria from Merz, Roche, Novartis, outside the submitted work. **Dr. Kelleners-Smeets** reports grants from Netherlands Organization for Health Research and Development, other from Janssen-Cilag, other from AbbVie, other from Galderma, outside the submitted work. **Dr. Malvey** reports research grants from Almirall, ISDIN, Leo Pharma, Galderma, GSK, Cantabria; participation in advisory board meetings for Almirall, Sunpharma, BMS, Roche, Novartis, Pierre-Fabre, outside the submitted work. **Dr. del Marmol** reports personal fees from MSD, from BMS, personal fees from Sanofi, grants and personal fees from ABVIE, grants from Jansen, outside the submitted work. **Dr. Moreno-Ramírez** has nothing to disclose. **Dr. Pellecani** reports grants from university of Modena and Reggio Emilia, during the conduct of the study; grants from Novartis, grants and personal fees from Almirall, grants from Leo Pharma, from null, outside the submitted work. **Dr. Peris** reports honoraria for advisory board and grants from AbbVie, Almirall, Biogen Celgene, Lilly, Galderma, Leo Pharma, Novartis, Roche, Sanofi, Sun Pharma, Sandoz outside the submitted work. **Dr. Saiag** reports honoraria for advisory board and grants from Amgen, Bristol-Myers Squibb, MSD, Merck-Serono, Novartis, Pfizer, Roche-Genentech, Pierre Fabre, and Sanofi, outside the submitted work. **Dr. Vieira** has nothing to disclose. **Dr. Zalaudek** reports honoraria and advisory board and grants from Sanofi, Sun Pharma, Novartis, Galderma, Roche, Celgene, Almirall, Leofarma, Mylan, Difa Cooper, Cieffe Labs, La Roche Posay, Pierre Fabre. **Dr. Eggermont** reports over the last 5 years personal fees as a consultant advisor for Biocad, BioInvent, Bristol Myers Squibb

(BMS), CatalYm, Ellipses, Glaxo Smith Kline (GSK), HalioDX, Incyte, IO Biotech, ISA Pharmaceuticals, Merck Sharpe & Dohme (MSD), Novartis, Pfizer, Polynoma, Regeneron, Sanofi, Sellas, SkylineDx. Alexander M.M. EGGERMONT: Honoraria, consultancy, SAB, IDMC, lectures for the last 2 years: Agenus, BioInvent, BioNTech, BMS, Brenus, CatalYm, Clover Pharmaceuticals, Ellipses, Galecto, GenOway, GSK, IO Biotech, IQVIA, ISA Pharmaceuticals, Merck &Co/MSD, Pierre Fabre, Pfizer, Sairopa, Sellas, SkylineDx, TigaTx, Trained Therapeutics,. Equity : IO Biotech, Sairopa, SkylineDX. **Dr. Grob** reports personal fees for advisory board and as speaker from Amgen, Roche, GSK, Novartis, BMS, Pierre Fabre, Merck, Sanofi, Merck, Pfizer outside the submitted work. **Alexander van Akkooi**: Advisory Board / Consultancy Honoraria: Amgen, Bristol-Myers Squibb, Novartis, MSD-Merck, Merck-Pfizer, Pierre Fabre, Provectus, Sanofi, Sirius Medical, 4SC. **Dr Lallas** has nothing to disclose. **Dr Ioannides** reports support from Sanofi in a phase III clinical trial, outside the submitted work. **Dr Lorigan** reports honoraria (consulting/advisory/speakers' bureau) from BMS, Merck/MSD, Nektar, NeraCare, Amgen, Novartis, Oncology Education Canada, Pierre Fabre, Roche, outside the submitted work. **Dr Rocken** reports study grants from AB Science, Abbott, Abbvie, Alcedis, Almirall Hermal, Amgen, AnaptysBio, argenx, AstraZeneca, Bayer, Biogen idec, Boehringer Ingelheim, Bristol-Myers Squibb, Celgene, CureVac, DelArrivo, Dynavax Technologies, Eli Lilly, Galderma, Genentech, GSK, Hoffman-La Roche, Hokusai, Idera Pharmaceuticals, Ilkos Therapeutic, Immatics Biotechnologies, Incyte, Iovance Biotherapeutics, Janssen-Cilag, Johnson & Johnson, LEO Pharma, Merck, MSD Sharp & Dome, Novartis Pharmaceuticals, PellePharma, Pfizer, Philogen, Regeneron Pharmaceuticals, Sanofi-Aventis, Schering-Plough, Sun Pharma, Technische Universitat Dresden, Topaz Therapeutics, UCB, Universitätsklinikum Essen, Universitätsklinik Köln, 4SC, grants for research projects from Deutsche Forschungsgemeinschaft, Deutsche Krebshilfe, Wilhelm Sander-Stiftung, consulting fees from Galderma, support for attending meetings/travel from EADV, International League of Dermatological Societies, patent PCT/EP2020/072203, stock or stock options from Bristol-Myers Squibb, CureVac, Merck, Pfizer, outside the submitted work. **Dr Arenberger** has nothing to disclose. **Dr Tagliaferri** reports honoraria from Elekta, Igea Medical, SunPharma, Sanofi, Roche, Molipharma, Nanobiotix, Novartis, outside the submitted work. **Dr Leiter** reports personal fees from MSD, honoraria from MSD, Novartis, Sun Pharma, Sanofi, Almiral Hermal, support for attending meetings/travel from Pierre Fabre, Sun Pharma, participation in Advisory Board for MSD, Novartis, Sun Pharma, Sanofi, Almiral Hermal, outside the submitted work. **Dr Trakatelli** reports travel grants from Janssen, UCB,

Abbvie, honoraria from UCB, Genesis Pharma, Pierre Fabre Greece, EADV courses, travel expenses for congresses from Abbvie, Pierre Fabre Greece, Genesis Pharma, outside the submitted work.

Acknowledgements

Marieke H.J van den Beuken-van Everdingen.

Appendix A. Supporting material

Supplementary data associated with this article can be found in the online version at [doi:10.1016/j.ejca.2023.113251](https://doi.org/10.1016/j.ejca.2023.113251).

References

- [1] Stratigos AJ, Garbe C, Dessinioti C, Lebbe C, Bataille V, Bastholt L, et al. European interdisciplinary guideline on invasive squamous cell carcinoma of the skin: part 1. epidemiology, diagnostics and prevention. *Eur J Cancer* 2020;128:60–82.
- [2] Stratigos AJ, Garbe C, Dessinioti C, Lebbe C, Bataille V, Bastholt L, et al. European interdisciplinary guideline on invasive squamous cell carcinoma of the skin: part 2. Treatment. *Eur J Cancer* 2020;128:83–102.
- [3] Schmults C, Blitzblau R, Aasi SZ, Alam M, Amini A, Baumann BC, et al. National comprehensive cancer network (NCCN) clinical practice guidelines in oncology. Squamous Cell Skin Cancer 2023;version 1:ed2023.
- [4] Keohane SG, Botting J, Budny PG, Dolan OM, Fife K, Harwood CA, et al. British association of dermatologists guidelines for the management of people with cutaneous squamous cell carcinoma 2020. *Br J Dermatol* 2021;184:401–14.
- [5] Brouwers MC, Kho ME, Browman GP, Burgers JS, Cluzeau F, Feder G, et al. AGREE II: advancing guideline development, reporting and evaluation in health care. *CMAJ* 2010;182:E839–42.
- [6] Howick J., Chalmers I., Glasziou P., Greenhalgh T., Heneghan C., Liberati A., et al. The Oxford levels of evidence 2, Available at: <https://www.cebm.ox.ac.uk/resources/levels-of-evidence/ocebml-levels-of-evidence> Accessed on July 17, 2022: Oxford center for evidence-based medicine.
- [7] Zakhem GA, Pulavarty AN, Carucci J, Stevenson ML. Association of patient risk factors, tumor characteristics, and treatment modality with poor outcomes in primary cutaneous squamous cell carcinoma: a systematic review and meta-analysis. *JAMA Dermatol* 2023;159:160–71.
- [8] Nagarajan P, Asgari MM, Green AC, Guhan SM, Arron ST, Proby CM, et al. Keratinocyte carcinomas: current concepts and future research priorities. *Clin Cancer Res* 2019;25:2379–91.
- [9] Schmitz L, Gambichler T, Kost C, Gupta G, Stucker M, Stockfleth E, et al. Cutaneous squamous cell carcinomas are associated with basal proliferating actinic keratoses. *Br J Dermatol* 2019;180:916–21.
- [10] Fernandez-Figueras MT, Carrato C, Saenz X, Puig L, Musulen E, Ferrandiz C, et al. Actinic keratosis with atypical basal cells (AK I) is the most common lesion associated with invasive squamous cell carcinoma of the skin. *J Eur Acad Dermatol Venereol* 2015;29:991–7.
- [11] FDA. Libtayo (cemiplimab-rwlc) full prescribing information. Available at: https://www.accessdata.fda.gov/drugsatfda_docs/label/2018/761097s0001bl.pdf Access date: 15 July 2019.
- [12] European Medicines Agency. Libtayo. Summary of product characteristics. Available at: https://www.ema.europa.eu/en/documents/product-information/libtayo-epar-product-information_en.pdf Access date: 17 July 2019.
- [13] Migden MR, Rischin D, Schmults CD, Guminski A, Hauschild A, Lewis KD, et al. PD-1 blockade with cemiplimab in advanced cutaneous squamous-cell carcinoma. *N Engl J Med* 2018;379:341–51.
- [14] Union for International Cancer Control. TNM Classification of Malignant Tumours. Eighth edition., Oxford, UK: John Wiley and Sons.; 2017.
- [15] Amin MB, Edge S, Greene F, Byrd DR, Brookland RK, Washington MK, Gershenwald JE, Compton CC, Hess KR, Sullivan DC, Jessup JM, Brierley JD, Gaspar LE, Schilsky RL, Balch CM, Winchester DP, Asare EA, Madera M, Gress DM, Meyer LR, editors. *AJCC Cancer Staging Manual*. Eighth edition., Chicago, USA: Springer Nature, Springer International Publishing AG; 2017.
- [16] Thompson AK, Kelley BF, Prokop LJ, Murad MH, Baum CL. Risk factors for cutaneous squamous cell carcinoma recurrence, metastasis, and disease-specific death: a systematic review and meta-analysis. *JAMA Dermatol* 2016;152:419–28.
- [17] Que SKT, Zwald FO, Schmults CD. Cutaneous squamous cell carcinoma: incidence, risk factors, diagnosis, and staging. *J Am Acad Dermatol* 2018;78:237–47.
- [18] Green AC, Olsen CM. Cutaneous squamous cell carcinoma: an epidemiological review. *Br J Dermatol* 2017;177:373–81.
- [19] Alam M, Ratner D. Cutaneous squamous-cell carcinoma. *N Engl J Med* 2001;344:975–83.
- [20] Lomas A, Leonardi-Bee J, Bath-Hextall F. A systematic review of worldwide incidence of non-melanoma skin cancer. *Br J Dermatol* 2012;166:1069–80.
- [21] Goon PKC, Greenberg DC, Igali L, Levell NJ. Predicted cases of United Kingdom skin squamous cell carcinoma and basal cell carcinoma in 2020 and 2025: horizon planning for National Health Service dermatology and dermatopathology. *Br J Dermatol* 2017;176:1351–3.
- [22] Glass AG, Hoover RN. The emerging epidemic of melanoma and squamous cell skin cancer. *JAMA* 1989;262:2097–100.
- [23] Gray DT, Suman VJ, Su WP, Clay RP, Harmsen WS, Roenigk RK. Trends in the population-based incidence of squamous cell carcinoma of the skin first diagnosed between 1984 and 1992. *Arch Dermatol* 1997;133:735–40.
- [24] Pandeya N, Olsen CM, Whiteman DC. The incidence and multiplicity rates of keratinocyte cancers in Australia. *Med J Aust* 2017;207:339–43.
- [25] Deady S, Sharp L, Comber H. Increasing skin cancer incidence in young, affluent, urban populations: a challenge for prevention. *Br J Dermatol* 2014;171:324–31.
- [26] Venables ZC, Autier P, Nijsten T, Wong KF, Langan SM, Rous B, et al. Nationwide incidence of metastatic cutaneous squamous cell carcinoma in England. *JAMA Dermatol* 2019;155:298–306.
- [27] Venables ZC, Nijsten T, Wong KF, Autier P, Broggio J, Deas A, et al. Epidemiology of basal and cutaneous squamous cell carcinoma in the UK 2013–15: a cohort study. *Br J Dermatol* 2019;181:474–82.
- [28] Røsbahm TE, Helsing P, Veierød MB. Cutaneous squamous cell carcinoma in Norway 1963–2011: increasing incidence and stable mortality. *Cancer Med* 2015;4:472–80.
- [29] Umezono Y, Sato Y, Noto M, Yamada K, Noguchi N, Hasunuma N, et al. Incidence rate of cutaneous squamous cell carcinoma is rapidly increasing in Akita Prefecture: urgent alert for super-aged society. *J Dermatol* 2019;46:259–62.
- [30] Karia PS, Han J, Schmults CD. Cutaneous squamous cell carcinoma: estimated incidence of disease, nodal metastasis, and deaths from disease in the United States, 2012. *J Am Acad Dermatol* 2013;68:957–66.

- [31] Muzic JG, Schmitt AR, Wright AC, Alniemi DT, Zubair AS, Olazagasti Lourido JM, et al. Incidence and trends of basal cell carcinoma and cutaneous squamous cell carcinoma: a population-based study in Olmsted County, Minnesota, 2000 to 2010. *Mayo Clin Proc* 2017;92:890–8.
- [32] Czarnecki D. Non-melanoma skin cancer mortality rising in susceptible Australians. *J Eur Acad Dermatol Venereol* 2017;31:e286–7.
- [33] Andersson EM, Paoli J, Wastensson G. Incidence of cutaneous squamous cell carcinoma in coastal and inland areas of Western Sweden. *Cancer Epidemiol* 2011;35:e69–74.
- [34] Carucci JA. Press for an underestimated nemesis. *JAMA Dermatol* 2013;149:1147–8.
- [35] Garrett GL, Blanc PD, Boscardin J, Lloyd AA, Ahmed RL, Anthony T, et al. Incidence of and risk factors for skin cancer in organ transplant recipients in the US. *JAMA Dermatol* 2017;153:296–303.
- [36] Brewer JD, Shanafelt TD, Khezri F, Sosa Seda IM, Zubair AS, Baum CL, et al. Increased incidence and recurrence rates of non-melanoma skin cancer in patients with non-Hodgkin lymphoma: a Rochester Epidemiology Project population-based study in Minnesota. *J Am Acad Dermatol* 2015;72:302–9.
- [37] Omland SH, Ahlstrom MG, Gerstoft J, Pedersen G, Mohey R, Pedersen C, et al. Risk of skin cancer in patients with HIV: a Danish nationwide cohort study. *J Am Acad Dermatol* 2018;79:689–95.
- [38] Wu PA, Stern RS, Huang V, Liu KX, Chen CA, Tzachanis D, et al. Reduced-intensity conditioning regimens, prior chronic lymphocytic leukemia, and graft-versus-host disease are associated with higher rates of skin cancer after allogeneic hematopoietic stem cell transplantation. *J Invest Dermatol* 2019;139:591–9.
- [39] Omland SH, Gniadecki R, Haedersdal M, Helweg-Larsen J, Omland LH. Skin cancer risk in hematopoietic stem-cell transplant recipients compared with background population and renal transplant recipients: a population-based cohort study. *JAMA Dermatol* 2016;152:177–83.
- [40] Asgari MM, Ray GT, Quesenberry Jr. CP, Katz KA, Silverberg MJ. Association of multiple primary skin cancers with human immunodeficiency virus infection, CD4 count, and viral load. *JAMA Dermatol* 2017;153:892–6.
- [41] Brougham ND, Dennett ER, Cameron R, Tan ST. The incidence of metastasis from cutaneous squamous cell carcinoma and the impact of its risk factors. *J Surg Oncol* 2012;106:811–5.
- [42] Schmults CD, Karia PS, Carter JB, Han J, Qureshi AA. Factors predictive of recurrence and death from cutaneous squamous cell carcinoma: a 10-year, single-institution cohort study. *JAMA Dermatol* 2013;149:541–7.
- [43] Brantsch KD, Meisner C, Schonfisch B, Trilling B, Wehner-Caroli J, Rocken M, et al. Analysis of risk factors determining prognosis of cutaneous squamous-cell carcinoma: a prospective study. *Lancet Oncol* 2008;9:713–20.
- [44] Nelson TG, Ashton RE. Low incidence of metastasis and recurrence from cutaneous squamous cell carcinoma found in a UK population: do we need to adjust our thinking on this rare but potentially fatal event? *J Surg Oncol* 2017;116:783–8.
- [45] Dessinioti C, Pitoulias M, Stratigos AJ. Epidemiology of advanced cutaneous squamous cell carcinoma. *J Eur Acad Dermatol Venereol* 2022;36:39–50.
- [46] Eisemann N, Jansen L, Castro FA, Chen T, Eberle A, Nennecke A, et al. Survival with non-melanoma skin cancer in Germany. *Br J Dermatol* 2016;174:778–85.
- [47] Tokez S, Wakkee M, Kan W, Venables ZC, Mooyaart AL, Louwman M, et al. Cumulative incidence and disease-specific survival of metastatic cutaneous squamous cell carcinoma: a nationwide cancer registry study. *J Am Acad Dermatol* 2022;86:331–8.
- [48] Manyam BV, Garsa AA, Chin RI, Reddy CA, Gastman B, Thorstad W, et al. A multi-institutional comparison of outcomes of immunosuppressed and immunocompetent patients treated with surgery and radiation therapy for cutaneous squamous cell carcinoma of the head and neck. *Cancer* 2017;123:2054–60.
- [49] Rabinovics N, Mizrachi A, Hadar T, Ad-El D, Feinmesser R, Guttman D, et al. Cancer of the head and neck region in solid organ transplant recipients. *Head Neck* 2014;36:181–6.
- [50] Dessinioti C, Platsidaki E, Stratigos AJ. A sensitivity meta-analysis of disease-specific death in localized cutaneous squamous cell carcinoma. *Dermatology* 2022;238:1026–35.
- [51] Sahovaler A, Krishnan RJ, Yeh DH, Zhou Q, Palma D, Fung K, et al. Outcomes of cutaneous squamous cell carcinoma in the head and neck region with regional lymph node metastasis: a systematic review and meta-analysis. *JAMA Otolaryngol Head Neck Surg* 2019;145:352–60.
- [52] Lam JKS, Sundaresan P, Gebiski V, Veness MJ. Immunocompromised patients with metastatic cutaneous nodal squamous cell carcinoma of the head and neck: poor outcome unrelated to the index lesion. *Head Neck* 2018;40:985–92.
- [53] Garrett GL, Lowenstein SE, Singer JP, He SY, Arron ST. Trends of skin cancer mortality after transplantation in the US: 1987 to 2013. *J Am Acad Dermatol* 2016;75:106–12.
- [54] Mehrany K, Weenig RH, Lee KK, Pittelkow MR, Otley CC. Increased metastasis and mortality from cutaneous squamous cell carcinoma in patients with chronic lymphocytic leukemia. *J Am Acad Dermatol* 2005;53:1067–71.
- [55] Velez NF, Karia PS, Vartanov AR, Davids MS, Brown JR, Schmults CD. Association of advanced leukemic stage and skin cancer tumor stage with poor skin cancer outcomes in patients with chronic lymphocytic leukemia. *JAMA Dermatol* 2014;150:280–7.
- [56] Robertson SJ, Orrin E, Lakhan MK, O'Sullivan G, Felton J, Robson A, et al. Cutaneous squamous cell carcinoma in Epidermolysis Bullosa: a 28-year retrospective study. *Acta Derm Venereol* 2021;101:adv00523.
- [57] Eigentler TK, Leiter U, Hafner HM, Garbe C, Rocken M, Breuninger H. Survival of patients with cutaneous squamous cell carcinoma: results of a prospective cohort study. *J Invest Dermatol* 2017;137:2309–15.
- [58] Morris KL, Luke MC, Perna FM. Prevalence of skin cancer examination among users of indoor tanning beds. *JAMA Dermatol* 2018;154:840–2.
- [59] Harwood CA, Arron ST, Proby CM, Asgari MM, Bouwes Bavinck JN, Green AC, et al. Organ transplantation and cutaneous squamous cell carcinoma: progress, pitfalls and priorities in immunosuppression-associated keratinocyte carcinoma. *Br J Dermatol* 2017;177:1150–1.
- [60] Chahoud J, Semaan A, Chen Y, Cao M, Rieber AG, Rady P, et al. Association between beta-genus human papillomavirus and cutaneous squamous cell carcinoma in immunocompetent individuals—a meta-analysis. *JAMA Dermatol* 2016;152:1354–64.
- [61] Conforti C, Paolini F, Venuti A, Dianzani C, Zalaudek I. The detection rate of human papillomavirus in well-differentiated squamous cell carcinoma and keratoacanthoma: is there new evidence for a viral pathogenesis of keratoacanthoma? *Br J Dermatol* 2019;181:1309–11.
- [62] Pirie K, Beral V, Heath AK, Green J, Reeves GK, Peto R, et al. Heterogeneous relationships of squamous and basal cell carcinomas of the skin with smoking: the UK Million Women Study and meta-analysis of prospective studies. *Br J Cancer* 2018;119:114–20.
- [63] Dusingize JC, Olsen CM, Pandeya NP, Subramaniam P, Thompson BS, Neale RE, et al. Cigarette smoking and the risks of basal cell carcinoma and squamous cell carcinoma. *J Invest Dermatol* 2017;137:1700–8.

- [64] Dotto GP, Rustgi AK. Squamous cell cancers: a unified perspective on biology and genetics. *Cancer cell* 2016;29:622–37.
- [65] Marks R, Rennie G, Selwood TS. Malignant transformation of solar keratoses to squamous cell carcinoma. *Lancet (London, England)* 1988;1:795–7.
- [66] Werner RN, Sammain A, Erdmann R, Hartmann V, Stockfleth E, Nast A. The natural history of actinic keratosis: a systematic review. *Br J Dermatol* 2013;169:502–18.
- [67] Peng L, Wang Y, Hong Y, Ye X, Shi P, Zhang J, et al. Incidence and relative risk of cutaneous squamous cell carcinoma with single-agent BRAF inhibitor and dual BRAF/MEK inhibitors in cancer patients: a meta-analysis. *Oncotarget* 2017;8:83280–91.
- [68] Heidorn SJ, Milagre C, Whittaker S, Nourry A, Niculescu-Duvas I, Dhomen N, et al. Kinase-dead BRAF and oncogenic RAS cooperate to drive tumor progression through CRAF. *Cell* 2010;140:209–21.
- [69] Poulidakos PI, Zhang C, Bollag G, Shokat KM, Rosen N. RAF inhibitors transactivate RAF dimers and ERK signalling in cells with wild-type BRAF. *Nature* 2010;464:427–30.
- [70] Su F, Viros A, Milagre C, Trunzer K, Bollag G, Spleiss O, et al. RAS mutations in cutaneous squamous-cell carcinomas in patients treated with BRAF inhibitors. *N Engl J Med* 2012;366:207–15.
- [71] Mohan SV, Chang J, Li S, Henry AS, Wood DJ, Chang AL. Increased risk of cutaneous squamous cell carcinoma after vismodegib therapy for basal cell carcinoma. *JAMA Dermatol* 2016;152:527–32.
- [72] Jacobsen AA, Aldahan AS, Hughes OB, Shah VV, Strasswimmer J. Hedgehog pathway inhibitor therapy for locally advanced and metastatic basal cell carcinoma: a systematic review and pooled analysis of interventional studies. *JAMA Dermatol* 2016;152:816–24.
- [73] Su KA, Habel LA, Achacoso NS, Friedman GD, Asgari MM. Photosensitizing antihypertensive drug use and risk of cutaneous squamous cell carcinoma. *Br J Dermatol* 2018;179:1088–94.
- [74] Pedersen SA, Gaist D, Schmidt SAJ, Holmich LR, Friis S, Pottgard A. Hydrochlorothiazide use and risk of non-melanoma skin cancer: a nationwide case-control study from Denmark. *J Am Acad Dermatol* 2018;78:673–81 e9.
- [75] Pottgard A, Pedersen SA, Schmidt SAJ, Holmich LR, Friis S, Gaist D. Association of hydrochlorothiazide use and risk of malignant melanoma. *JAMA Intern Med* 2018;178:1120–2.
- [76] de Macedo Andrade AC, Felix FA, Franca GM, Ribeiro ILA, Barboza CAG, de Castro RD, et al. Hydrochlorothiazide use is associated with the risk of cutaneous and lip squamous cell carcinoma: a systematic review and meta-analysis. *Eur J Clin Pharmacol* 2022;78:919–30.
- [77] European Medicines Agency. PRAC recommendation on signals.
- [78] Schneider R, Reinau D, Stoffel S, Jick SS, Meier CR, Spoendlin J. Risk of skin cancer in new users of thiazides and thiazide-like diuretics: a cohort study using an active comparator group. *Br J Dermatol* 2021;185:343–52.
- [79] South AP, Purdie KJ, Watt SA, Haldenby S, den Breems N, Dimon M, et al. NOTCH1 mutations occur early during cutaneous squamous cell carcinogenesis. *J Invest Dermatol* 2014;134:2630–8.
- [80] Inman GJ, Wang J, Nagano A, Alexandrov LB, Purdie KJ, Taylor RG, et al. The genomic landscape of cutaneous SCC reveals drivers and a novel azathioprine associated mutational signature. *Nat Commun* 2018;9:3667.
- [81] Chitsazzadeh V, Coarfa C, Drummond JA, Nguyen T, Joseph A, Chilukuri S, et al. Cross-species identification of genomic drivers of squamous cell carcinoma development across pre-neoplastic intermediates. *Nat Commun* 2016;7:12601.
- [82] Chalmers ZR, Connelly CF, Fabrizio D, Gay L, Ali SM, Ennis R, et al. Analysis of 100,000 human cancer genomes reveals the landscape of tumor mutational burden. *Genome Med* 2017;9:34.
- [83] Alexandrov LB, Nik-Zainal S, Wedge DC, Aparicio SA, Behjati S, Biankin AV, et al. Signatures of mutational processes in human cancer. *Nature* 2013;500:415–21.
- [84] Kim YS, Shin S, Jung SH, Park YM, Park GS, Lee SH, et al. Genomic progression of precancerous actinic keratosis to squamous cell carcinoma. *J Invest Dermatol* 2022;142:528–538 e8.
- [85] Cammareri P, Rose AM, Vincent DF, Wang J, Nagano A, Libertini S, et al. Inactivation of TGFbeta receptors in stem cells drives cutaneous squamous cell carcinoma. *Nat Commun* 2016;7:12493.
- [86] Al-Rohil RN, Tarasen AJ, Carlson JA, Wang K, Johnson A, Yelensky R, et al. Evaluation of 122 advanced-stage cutaneous squamous cell carcinomas by comprehensive genomic profiling opens the door for new routes to targeted therapies. *Cancer* 2016;122:249–57.
- [87] Chang D, Shain AH. The landscape of driver mutations in cutaneous squamous cell carcinoma. *NPJ Genom Med* 2021;6:61.
- [88] Cho RJ, Alexandrov LB, den Breems NY, Atanasova VS, Farschian M, Purdom E, et al. APOBEC mutation drives early-onset squamous cell carcinomas in recessive dystrophic epidermolysis bullosa. *Sci Trans Med* 2018;10:eaas9668.
- [89] Chahal HS, Lin Y, Ransohoff KJ, Hinds DA, Wu W, Dai HJ, et al. Genome-wide association study identifies novel susceptibility loci for cutaneous squamous cell carcinoma. *Nat Commun* 2016;7:12048.
- [90] Wang W, Jorgenson E, Whittemore AS, Asgari MM. Susceptibility loci-associated cutaneous squamous cell carcinoma invasiveness. *J Invest Dermatol* 2018;138:557–61.
- [91] Ioannidis NM, Wang W, Furlotte NA, Hinds DA, Me Research T, Bustamante CD, et al. Gene expression imputation identifies candidate genes and susceptibility loci associated with cutaneous squamous cell carcinoma. *Nat Commun* 2018;9:4264.
- [92] Sordillo JE, Kraft P, Wu AC, Asgari MM. Quantifying the polygenic contribution to cutaneous squamous cell carcinoma risk. *J Invest Dermatol* 2018;138:1507–10.
- [93] Sarin KY, Lin Y, Daneshjou R, Ziyatdinov A, Thorleifsson G, Rubin A, et al. Genome-wide meta-analysis identifies eight new susceptibility loci for cutaneous squamous cell carcinoma. *Nat Commun* 2020;11:820.
- [94] Ferguson AL, Sharman AR, Allen RO, Ye T, Lee JH, Low TH, et al. High-dimensional and spatial analysis reveals immune landscape-dependent progression in cutaneous squamous cell carcinoma. *Clin Cancer Res* 2022;28:4677–88.
- [95] Varki V, Ioffe OB, Bentzen SM, Heath J, Cellini A, Feliciano J, et al. PD-L1, B7-H3, and PD-1 expression in immunocompetent versus immunosuppressed patients with cutaneous squamous cell carcinoma. *Cancer Immunol Immunother* 2018;67:805–14.
- [96] Schaper K, Kother B, Hesse K, Satzger I, Gutzmer R. The pattern and clinicopathological correlates of programmed death-ligand 1 expression in cutaneous squamous cell carcinoma. *Br J Dermatol* 2017;176:1354–6.
- [97] Garcia-Diez I, Hernandez-Ruiz E, Andrades E, Gimeno J, Ferrandiz-Pulido C, Yebenes M, et al. PD-L1 expression is increased in metastasizing squamous cell carcinomas and their metastases. *Am J Dermatopathol* 2018;40:647–54.
- [98] Murphy GF, Beer TW, Cerio R, Kao GF, Nagore E, Pulitzer MP. Squamous cell carcinoma. In: Elder DM, Scolyer D, Willemze RA, R.editors. WHO Classification of Skin Tumours. 4th ed., France: International Agency of Research on Cancer (IARC); 2018. p. 35–44.
- [99] Savage JA, Maize Sr. JC. Keratoacanthoma clinical behavior: a systematic review. *Am J Dermatopathol* 2014;36:422–9.

- [100] Rosendahl C, Cameron A, Argenziano G, Zalaudek I, Tschandl P, Kittler H. Dermoscopy of squamous cell carcinoma and keratoacanthoma. *Arch Dermatol* 2012;148:1386–92.
- [101] Lallas A, Pyne J, Kyrgidis A, Andreani S, Argenziano G, Cavaller A, et al. The clinical and dermoscopic features of invasive cutaneous squamous cell carcinoma depend on the histopathological grade of differentiation. *Br J Dermatol* 2015;172:1308–15.
- [102] Zalaudek I, Giacomel J, Schmid K, Bondino S, Rosendahl C, Cavicchini S, et al. Dermoscopy of facial actinic keratosis, intraepidermal carcinoma, and invasive squamous cell carcinoma: a progression model. *J Am Acad Dermatol* 2012;66:589–97.
- [103] Rishpon A, Kim N, Scope A, Porges L, Oliviero MC, Braun RP, et al. Reflectance confocal microscopy criteria for squamous cell carcinomas and actinic keratoses. *Arch Dermatol* 2009;145:766–72.
- [104] Manfredini M, Longo C, Ferrari B, Piana S, Benati E, Casari A, et al. Dermoscopic and reflectance confocal microscopy features of cutaneous squamous cell carcinoma. *J Eur Acad Dermatol Venereol* 2017;31:1828–33.
- [105] Dinnes J, Deeks JJ, Chuchu N, Saleh D, Bayliss SE, Takwoingyi Y, et al. Reflectance confocal microscopy for diagnosing keratinocyte skin cancers in adults. *Cochrane Database Syst Rev* 2018;12:CD013191.
- [106] Boone MA, Marneffe A, Suppa M, Miyamoto M, Alarcon I, Hofmann-Wellenhof R, et al. High-definition optical coherence tomography algorithm for the discrimination of actinic keratosis from normal skin and from squamous cell carcinoma. *J Eur Acad Dermatol Venereol* 2015;29:1606–15.
- [107] Themstrup L, Pellacani G, Welzel J, Holmes J, Jemec GBE, Ulrich M. *In vivo* microvascular imaging of cutaneous actinic keratosis, Bowen's disease and squamous cell carcinoma using dynamic optical coherence tomography. *J Eur Acad Dermatol Venereol* 2017;31:1655–62.
- [108] Ferrante di Ruffano L, Dinnes J, Deeks JJ, Chuchu N, Bayliss SE, Davenport C, et al. Optical coherence tomography for diagnosing skin cancer in adults. *Cochrane Database Syst Rev* 2018;12:CD013189.
- [109] Cheng JY, Li FY, Ko CJ, Colegio OR. Cutaneous squamous cell carcinomas in solid organ transplant recipients compared with immunocompetent patients. *JAMA Dermatol* 2018;154:60–6.
- [110] Kallini JR, Hamed N, Khachemoune A. Squamous cell carcinoma of the skin: epidemiology, classification, management, and novel trends. *Int J Dermatol* 2015;54:130–40.
- [111] Beer TW, Shepherd P, Theaker JM, Ber EP4 and epithelial membrane antigen aid distinction of basal cell, squamous cell and basosquamous carcinomas of the skin. *Histopathology* 2000;37:218–23.
- [112] Breuninger H, Schaumburg-Lever G, Holzschuh J, Horny HP. Desmoplastic squamous cell carcinoma of skin and vermilion surface: a highly malignant subtype of skin cancer. *Cancer* 1997;79:915–9.
- [113] Califano JA, Lydiatt WM, Nehal K, O'Sullivan B, Schmults C, Seethala RR, et al. Cutaneous carcinoma of the head and neck. In: Amin MB, Edge S, Byrd DR, Brookland RK, Washington MK, Gershenwald JE, editors. *AJCC Cancer Staging Manual*. Eighth edition. Chicago, IL: Springer; 2017. p. 171–81.
- [114] Carter JB, Johnson MM, Chua TL, Karia PS, Schmults CD. Outcomes of primary cutaneous squamous cell carcinoma with perineural invasion: an 11-year cohort study. *JAMA Dermatol* 2013;149:35–41.
- [115] Haug K, Breuninger H, Metzler G, Eigentler T, Eichner M, Hafner HM, et al. Prognostic impact of perineural invasion in cutaneous squamous cell carcinoma: results of a prospective study of 1399 tumors. *J Invest Dermatol* 2020;140:1968–75.
- [116] Kofler K, Breuninger H, Eigentler T, Kofler L, Schaefer V, Blumenstock G, et al. Local tumor infiltration and locoregional recurrence in desmoplastic cutaneous squamous cell carcinoma. *Dermatol Surg* 2022;48:283–9.
- [117] Dessinioti C, Stratigos AJ. Recent advances in the diagnosis and management of high-risk cutaneous squamous cell carcinoma. *Cancers (Basel)* 2022;14:3556.
- [118] Quaedvlieg PJ, Creyten DH, Epping GG, Peutz-Kootstra CJ, Nieman FH, Thissen MR, et al. Histopathological characteristics of metastasizing squamous cell carcinoma of the skin and lips. *Histopathology* 2006;49:256–64.
- [119] Saito Y, Fujikawa H, Takatsuka S, Abe R, Takenouchi T. Risk factors for lymph node metastasis in cutaneous squamous cell carcinoma: a long-term retrospective study of Japanese patients. *Int J Clin Oncol* 2021;26:606–12.
- [120] Tokez S, Venables ZC, Hollestein LM, Qi H, Bramer EM, Rentroia-Pacheco B, et al. Risk factors for metastatic cutaneous squamous cell carcinoma: refinement and replication based on two nationwide nested case-control studies. *J Am Acad Dermatol* 2022;87:64–71.
- [121] Kofler K, Helmut B, Thomas E, Lukas K, Viola S, Gunnar B, et al. Local tumor infiltration and locoregional recurrence in desmoplastic cutaneous squamous cell carcinoma. *Dermatol Surg* 2022;48:283–9.
- [122] Eigentler TK, Dietz K, Leiter U, Hafner HM, Breuninger H. What causes the death of patients with cutaneous squamous cell carcinoma? A prospective analysis in 1400 patients. *Eur J Cancer* 2022;172:182–90.
- [123] Stefanovic N, Fitzmaurice CJ, Ormond P, Irvine AD, Barry RB. Risk factors for distant metastasis in cutaneous squamous cell carcinoma. *Br J Dermatol* 2022;187:435–6.
- [124] Dessinioti C, Stratigos AJ. Overview of guideline recommendations for the management of high-risk and advanced cutaneous squamous cell carcinoma. *J Eur Acad Dermatol Venereol* 2022;36(Suppl 1):11–8.
- [125] O'Connor DM, Murad F, Danesh MJ, Butler W, Smile TD, Ilori EO, et al. Immune status does not independently influence cutaneous squamous cell carcinoma metastasis and death when stratified by tumor stage: a dual center retrospective cohort analysis of primary N0 disease. *J Am Acad Dermatol* 2022;87:1295–302.
- [126] Marrazzo G, Zitelli JA, Brodland D. Clinical outcomes in high-risk squamous cell carcinoma patients treated with Mohs micrographic surgery alone. *J Am Acad Dermatol* 2019;80:633–8.
- [127] Wysong A, Newman JG, Covington KR, Kurley SJ, Ibrahim SF, Farberg AS, et al. Validation of a 40-gene expression profile test to predict metastatic risk in localized high-risk cutaneous squamous cell carcinoma. *J Am Acad Dermatol* 2021;84:361–9.
- [128] Ibrahim SF, Kasprzak JM, Hall MA, Fitzgerald AL, Siegel JJ, Kurley SJ, et al. Enhanced metastatic risk assessment in cutaneous squamous cell carcinoma with the 40-gene expression profile test. *Future Oncol (London, England)* 2022;18:833–47.
- [129] Cherpelis BS, Marcusen C, Lang PG. Prognostic factors for metastasis in squamous cell carcinoma of the skin. *Dermatol Surg* 2002;28:268–73.
- [130] Petter G, Hausteiner UF. Squamous cell carcinoma of the skin: histopathological features and their significance for the clinical outcome. *J Eur Acad Dermatol Venereol* 1998;11:37–44.
- [131] Kus KJB, Murad F, Smile TD, Chang M, Ashrafzadeh S, Zhou G, et al. Higher metastasis and death rates in cutaneous squamous cell carcinomas with lymphovascular invasion. *J Am Acad Dermatol* 2022;86:766–73.
- [132] Karia PS, Morgan FC, Ruiz ES, Schmults CD. Clinical and incidental perineural invasion of cutaneous squamous cell carcinoma: a systematic review and pooled analysis of outcomes data. *JAMA Dermatol* 2017;153:781–8.

- [133] Russell E, Udkoff J, Knackstedt T. Squamous cell carcinoma with bone invasion: a systematic review and pooled survival analysis. *Dermatol Surg* 2022;48:1025–8.
- [134] Jambusaria-Pahlajani A, Kanetsky PA, Karia PS, Hwang WT, Gelfand JM, Whalen FM, et al. Evaluation of AJCC tumor staging for cutaneous squamous cell carcinoma and a proposed alternative tumor staging system. *JAMA Dermatol* 2013;149:402–10.
- [135] Breuninger H, Brantsch K, Eigentler T, Hafner HM. Comparison and evaluation of the current staging of cutaneous carcinomas. *J Ger Soc Dermatol: JDDG* 2012;10:579–86.
- [136] Forest VI, Clark JJ, Veness MJ, Milross C. N1S3: a revised staging system for head and neck cutaneous squamous cell carcinoma with lymph node metastases: results of two Australian. 2010;116:1298–304.
- [137] Oddone N, Morgan GJ, Palme CE, Perera L, Shannon J, Wong E, et al. Metastatic cutaneous squamous cell carcinoma of the head and neck: the Immunosuppression, treatment, extranodal spread, and margin status (ITEM) prognostic score to predict outcome and the need to improve survival. *Cancer* 2009;115:1883–91.
- [138] Ruiz ES, Karia PS, Besaw R, Schmults CD. Performance of the American joint committee on cancer staging manual, 8th edition versus the Brigham and women's hospital tumor classification system for cutaneous squamous cell carcinoma. *JAMA Dermatol* 2019;155:819–25.
- [139] Conde-Ferreiros A, Corchete LA, Puebla-Tornero L, Corchado-Cobos R, Garcia-Sancha N, Roman-Curto C, et al. Definition of prognostic subgroups in the T3 stage of the eighth edition of the American joint committee on cancer staging system for cutaneous squamous cell carcinoma: tentative T3 stage subclassification. *J Am Acad Dermatol* 2021;85:1168–77.
- [140] Venables ZC, Tokez S, Hollestein LM, Mooyaart AL, van den Bos RR, Rous B, et al. Validation of four cutaneous squamous cell carcinoma staging systems using nationwide data. *Br J Dermatol* 2022;186:835–42.
- [141] Roscher I, Falk RS, Vos L, Clausen OPF, Helsing P, Gjersvik P, et al. Validating four staging systems for cutaneous squamous cell carcinoma using population-based data: a nested case-control study. *JAMA Dermatol* 2018;154:428–34.
- [142] Ebrahimi A, Luk PP, Low H, McDowell L, Magarey MJR, Smith PN, et al. A critical analysis of the 8th edition TNM staging for head and neck cutaneous squamous cell carcinoma with lymph node metastases and comparison to N1S3 stage and ITEM risk score: a multicenter study. *J Surg Oncol* 2021;123:1531–9.
- [143] Ebrahimi A, Gupta R, Luk P, Low TH, McDowell L, Magarey MJR, et al. Number of nodal metastases and the American joint committee on cancer staging of head and neck cutaneous squamous cell carcinoma: a multicenter study. *Oral Oncol* 2020;111:104855.
- [144] Smile TD, Ruiz ES, Kus KJB, Murad F, Wei W, Xiong DD, et al. Implications of satellitosis or in-transit metastasis in cutaneous squamous cell carcinoma: a prognostic omission in cancer staging systems. *JAMA Dermatol* 2022;158:390–4.
- [145] Maubec E. Update of the management of cutaneous squamous-cell carcinoma. *Acta Derm Venereol* 2020;100:adv00143.
- [146] Fox M, Brown M, Golda N, Goldberg D, Miller C, Pugliano-Mauro M, et al. Nodal staging of high-risk cutaneous squamous cell carcinoma. *J Am Acad Dermatol* 2019;81:548–57.
- [147] Gurney B, Newlands C. Management of regional metastatic disease in head and neck cutaneous malignancy. 1. Cutaneous squamous cell carcinoma. *Br J Oral Maxillofac Surg* 2014;52:294–300.
- [148] de Bondt RB, Nelemans PJ, Hofman PA, Casselman JW, Kremer B, van Engelshoven JM, et al. Detection of lymph node metastases in head and neck cancer: a meta-analysis comparing US, USgFNAC, CT and MR imaging. *Eur J Radiol* 2007;64:266–72.
- [149] Land R, Herod J, Moskovic E, King M, Sohaib SA, Trott P, et al. Routine computerized tomography scanning, groin ultrasound with or without fine needle aspiration cytology in the surgical management of primary squamous cell carcinoma of the vulva. *Int J Gynecol Cancer* 2006;16:312–7.
- [150] Maher JM, Schmults CD, Murad F, Karia PS, Benson CB, Ruiz ES. Detection of subclinical disease with baseline and surveillance imaging in high-risk cutaneous squamous cell carcinomas. *J Am Acad Dermatol* 2020;82:920–6.
- [151] Tokez S, Koelkoren FHJ, Baatenburg de Jong RJ, Grunhagen DJ, Mooyaart AL, Nijsten T, et al. Assessment of the diagnostic accuracy of baseline clinical examination and ultrasonographic imaging for the detection of lymph node metastasis in patients with high-risk cutaneous squamous cell carcinoma of the head and neck. *JAMA Dermatol* 2022;158:151–9.
- [152] Humphreys TR, Shah K, Wysong A, Lexa F, MacFarlane D. The role of imaging in the management of patients with non-melanoma skin cancer: when is imaging necessary? *J Am Acad Dermatol* 2017;76:591–607.
- [153] Williams LS, Mancuso AA, Mendenhall WM. Perineural spread of cutaneous squamous and basal cell carcinoma: CT and MR detection and its impact on patient management and prognosis. *Int J Radiat Oncol Biol Phys* 2001;49:1061–9.
- [154] MacFarlane D, Shah K, Wysong A, Wortsman X, Humphreys TR. The role of imaging in the management of patients with non-melanoma skin cancer: diagnostic modalities and applications. *J Am Acad Dermatol* 2017;76:579–88.
- [155] Ruiz ES, Karia PS, Morgan FC, Schmults CD. The positive impact of radiologic imaging on high-stage cutaneous squamous cell carcinoma management. *J Am Acad Dermatol* 2017;76:217–25.
- [156] Warren TA, Panizza B, Porceddu SV, Gandhi M, Patel P, Wood M, et al. Outcomes after surgery and postoperative radiotherapy for perineural spread of head and neck cutaneous squamous cell carcinoma. *Head Neck* 2016;38:824–31.
- [157] Gandhi MR, Panizza B, Kennedy D. Detecting and defining the anatomic extent of large nerve perineural spread of malignancy: comparing 'targeted' MRI with the histologic findings following surgery. *Head Neck* 2011;33:469–75.
- [158] Panizza B, Solares CA, Redmond M, Parmar P, O'Rourke P. Surgical resection for clinical perineural invasion from cutaneous squamous cell carcinoma of the head and neck. *Head Neck* 2012;34:1622–7.
- [159] Tejera-Vaquerizo A, Garcia-Doval I, Lombart B, Canueto J, Martorell-Calatayud A, Descalzo-Gallego MA, et al. Systematic review of the prevalence of nodal metastases and the prognostic utility of sentinel lymph node biopsy in cutaneous squamous cell carcinoma. *J Dermatol* 2018;45:781–90.
- [160] Navarrete-Dechent C, Veness MJ, Droppelmann N, Uribe P. High-risk cutaneous squamous cell carcinoma and the emerging role of sentinel lymph node biopsy: a literature review. *J Am Acad Dermatol* 2015;73:127–37.
- [161] Sahn RE, Lang PG. Sentinel lymph node biopsy for high-risk non-melanoma skin cancers. *Dermatol Surg* 2007;33:786–92.
- [162] Krediet JT, Beyer M, Lenz K, Ulrich C, Lange-Asschenfeldt B, Stockfleth E, et al. Sentinel lymph node biopsy and risk factors for predicting metastasis in cutaneous squamous cell carcinoma. *Br J Dermatol* 2015;172:1029–36.
- [163] Gore SM, Shaw D, Martin RC, Kelder W, Roth K, Uren R, et al. Prospective study of sentinel node biopsy for high-risk cutaneous squamous cell carcinoma of the head and neck. *Head Neck* 2016;38(Suppl 1):E884–9.
- [164] Fukushima S, Masuguchi S, Igata T, Harada M, Aoi J, Miyashita A, et al. Evaluation of sentinel node biopsy for cutaneous squamous cell carcinoma. *J Dermatol* 2014;41:539–41.

- [165] Reschly MJ, Messina JL, Zauyanov LL, Cruse W, Fenske NA. Utility of sentinel lymphadenectomy in the management of patients with high-risk cutaneous squamous cell carcinoma. *Dermatol Surg* 2003;29:135–40.
- [166] Schmitt AR, Brewer JD, Bordeaux JS, Baum CL. Staging for cutaneous squamous cell carcinoma as a predictor of sentinel lymph node biopsy results: meta-analysis of American joint committee on cancer criteria and a proposed alternative system. *JAMA Dermatol* 2014;150:19–24.
- [167] Kofler L, Kofler K, Schulz C, Breuninger H, Hafner HM. Sentinel lymph node biopsy for high-thickness cutaneous squamous cell carcinoma. *Arch Dermatol Res* 2021;313:119–26.
- [168] Quinn PL, Oliver JB, Mahmoud OM, Chokshi RJ. Cost-effectiveness of sentinel lymph node biopsy for head and neck cutaneous squamous cell carcinoma. *J Surg Res* 2019;241:15–23.
- [169] Costantino A, Canali L, Festa BM, Spriano G, Mercante G, De Virgilio A. Sentinel lymph node biopsy in high-risk cutaneous squamous cell carcinoma of the head and neck: systematic review and meta-analysis. *Head Neck* 2022;44:2288–300.
- [170] Ross AS, Schmults CD. Sentinel lymph node biopsy in cutaneous squamous cell carcinoma: a systematic review of the English literature. *Dermatol Surg* 2006;32:1309–21.
- [171] Renzi C, Caggiati A, Mannooranparampil TJ, Passarelli F, Tartaglione G, Pennasilico GM, et al. Sentinel lymph node biopsy for high risk cutaneous squamous cell carcinoma: case series and review of the literature. *Eur J Surg Oncol* 2007;33:364–9.
- [172] Allen JE, Stolle LB. Utility of sentinel node biopsy in patients with high-risk cutaneous squamous cell carcinoma. *Eur J Surg Oncol* 2015;41:197–200.
- [173] Lhote R, Lambert J, Lejeune J, Gottlieb J, Badaoui A, Battistella M, et al. Sentinel lymph node biopsy in cutaneous squamous cell carcinoma series of 37 cases and systematic review of the literature. *Acta Derm Venereol* 2018;98:671–6.
- [174] Saraiya M, Glanz K, Briss PA, Nichols P, White C, Das D, et al. Interventions to prevent skin cancer by reducing exposure to ultraviolet radiation: a systematic review. *Am J Prev Med* 2004;27:422–66.
- [175] Jackson KM, Aiken LS. Evaluation of a multicomponent appearance-based sun-protective intervention for young women: uncovering the mechanisms of program efficacy. *Health Psychol* 2006;25:34–46.
- [176] Gordon LG, Rowell D. Health system costs of skin cancer and cost-effectiveness of skin cancer prevention and screening: a systematic review. *Eur J Cancer Prev* 2015;24:141–9.
- [177] Henrikson NB, Morrison CC, Blasi PR, Nguyen M, Shibuya KC, Patnode CD. Behavioral counseling for skin cancer prevention: evidence report and systematic review for the US preventive services task force. *JAMA* 2018;319:1143–57.
- [178] Sandhu PK, Elder R, Patel M, Saraiya M, Holman DM, Perna F, et al. Community-wide interventions to prevent skin cancer: two community guide systematic reviews. *Am J Prev Med* 2016;51:531–9.
- [179] Glanz K, Steffen AD, Schoenfeld E, Tappe KA. Randomized trial of tailored skin cancer prevention for children: the Project SCAPE family study. *J Health Commun* 2013;18:1368–83.
- [180] Youl PH, Soyer HP, Baade PD, Marshall AL, Finch L, Janda M. Can skin cancer prevention and early detection be improved via mobile phone text messaging? A randomised, attention control trial. *Prev Med* 2015;71:50–6.
- [181] Green A, Williams G, Neale R, Hart V, Leslie D, Parsons P, et al. Daily sunscreen application and betacarotene supplementation in prevention of basal-cell and squamous-cell carcinomas of the skin: a randomised controlled trial. *Lancet* (London, England) 1999;354:723–9.
- [182] van der Pols JC, Williams GM, Pandeya N, Logan V, Green AC. Prolonged prevention of squamous cell carcinoma of the skin by regular sunscreen use. *Cancer Epidemiol Biomarkers Prev* 2006;15:2546–8.
- [183] Thompson SC, Jolley D, Marks R. Reduction of solar keratoses by regular sunscreen use. *N Engl J Med* 1993;329:1147–51.
- [184] Ulrich C, Jurgensen JS, Degen A, Hackethal M, Ulrich M, Patel MJ, et al. Prevention of non-melanoma skin cancer in organ transplant patients by regular use of a sunscreen: a 24 months, prospective, case-control study. *Br J Dermatol* 2009;161(Suppl 3):78–84.
- [185] Silva ESD, Tavares R, Paulitsch FDS, Zhang L. Use of sunscreen and risk of melanoma and non-melanoma skin cancer: a systematic review and meta-analysis. *Eur J Dermatol* 2018;28:186–201.
- [186] Rueegg CS, Stenehjem JS, Egger M, Ghiasvand R, Cho E, Lund E, et al. Challenges in assessing the sunscreen-melanoma association. *Int J Cancer* 2019;144:2651–68.
- [187] Diepgen TL. New developments in occupational dermatology. *J Ger Soc Dermatol: JDDG* 2016;14:875–89.
- [188] International Commission on Non-Ionizing Radiation P. ICNIRP statement—protection of workers against ultraviolet radiation. *Health Phys* 2010;99:66–87.
- [189] Kim C, Cheng J, Colegio OR. Cutaneous squamous cell carcinomas in solid organ transplant recipients: emerging strategies for surveillance, staging, and treatment. *Semin Oncol* 2016;43:390–4.
- [190] Harwood CA, Mesher D, McGregor JM, Mitchell L, Leedham-Green M, Raftery M, et al. A surveillance model for skin cancer in organ transplant recipients: a 22-year prospective study in an ethnically diverse population. *Am J Transplant* 2013;13:119–29.
- [191] Crane LA, Deas A, Mokrohisky ST, Ehrsam G, Jones RH, Dellavalle R, et al. A randomized intervention study of sun protection promotion in well-child care. *Prev Med* 2006;42:162–70.
- [192] Glasser A, Shaheen M, Glenn BA, Bastani R. The sun sense study: an intervention to improve sun protection in children. *Am J Health Behav* 2010;34:500–10.
- [193] Norman GJ, Adams MA, Calfas KJ, Covin J, Sallis JF, Rossi JS, et al. A randomized trial of a multicomponent intervention for adolescent sun protection behaviors. *Arch Pediatr Adolesc Med* 2007;161:146–52.
- [194] Montague M, Borland R, Sinclair C. Slip! Slop! Slap! and SunSmart, 1980–2000: skin cancer control and 20 years of population-based campaigning. *Health Educ Behav* 2001;28:290–305.
- [195] Aulbert W, Parpart C, Schulz-Hornbostel R, Hinrichs B, Kruger-Corcoran D, Stockfleth E. Certification of sun protection practices in a German child day-care centre improves children's sun protection—the 'SunPass' pilot study. *Br J Dermatol* 2009;161(Suppl 3):5–12.
- [196] Hewitt M, Denman S, Hayes L, Pearson J, Wallbanks C. Evaluation of 'Sun-safe': a health education resource for primary schools. *Health Educ Res* 2001;16:623–33.
- [197] Miller DR, Geller AC, Wood MC, Lew RA, Koh HK. The Falmouth Safe Skin Project: evaluation of a community program to promote sun protection in youth. *Health Educ Behav* 1999;26:369–84.
- [198] Nemer KM, Council ML. Topical and systemic modalities for chemoprevention of non-melanoma skin cancer. *Dermatol Clin* 2019;37:287–95.
- [199] Kadakia KC, Barton DL, Loprinzi CL, Sloan JA, Otley CC, Diekmann BB, et al. Randomized controlled trial of acitretin versus placebo in patients at high-risk for basal cell or squamous cell carcinoma of the skin (North Central Cancer Treatment Group Study 969251). *Cancer* 2012;118:2128–37.
- [200] Nijsten TE, Stern RS. Oral retinoid use reduces cutaneous squamous cell carcinoma risk in patients with psoriasis treated

- with psoralen-UVA: a nested cohort study. *J Am Acad Dermatol* 2003;49:644–50.
- [201] Anforth R, Blumetti TC, Clements A, Kefford R, Long GV, Fernandez-Penas P. Systemic retinoids for the chemoprevention of cutaneous squamous cell carcinoma and verrucal keratosis in a cohort of patients on BRAF inhibitors. *Br J Dermatol* 2013;169:1310–3.
- [202] Harwood CA, Leedham-Green M, Leigh IM, Proby CM. Low-dose retinoids in the prevention of cutaneous squamous cell carcinomas in organ transplant recipients: a 16-year retrospective study. *Arch Dermatol* 2005;141:456–64.
- [203] Chen K, Craig JC, Shumack S. Oral retinoids for the prevention of skin cancers in solid organ transplant recipients: a systematic review of randomized controlled trials. *Br J Dermatol* 2005;152:518–23.
- [204] Damian DL, Patterson CR, Stapelberg M, Park J, Barnetson RS, Halliday GM. UV radiation-induced immunosuppression is greater in men and prevented by topical nicotinamide. *J Invest Dermatol* 2008;128:447–54.
- [205] Mainville L, Smilga AS, Fortin PR. Effect of nicotinamide in skin cancer and actinic keratoses chemoprophylaxis, and adverse effects related to nicotinamide: a systematic review and meta-analysis. *J Cutan Med Surg* 2022;26:297–308.
- [206] Chen AC, Martin AJ, Choy B, Fernandez-Penas P, Dalziel RA, McKenzie CA, et al. A phase 3 randomized trial of nicotinamide for skin-cancer chemoprevention. *N Engl J Med* 2015;373:1618–26.
- [207] Muranushi C, Olsen CM, Pandeya N, Green AC. Aspirin and non-steroidal anti-inflammatory drugs can prevent cutaneous squamous cell carcinoma: a systematic review and meta-analysis. *J Invest Dermatol* 2015;135:975–83.
- [208] Reinau D, Surber C, Jick SS, Meier CR. Non-steroidal anti-inflammatory drugs and the risk of non-melanoma skin cancer. *Int J Cancer* 2015;137:144–53.
- [209] Pandeya N, Olsen CM, Thompson BS, Dusingize JC, Neale RE, Green AC, et al. Aspirin and non-steroidal anti-inflammatory drug use and keratinocyte cancers: a large population-based cohort study of skin cancer in Australia. *Br J Dermatol* 2019;181:749–60.
- [210] Tang JY, Fu T, Leblanc E, Manson JE, Feldman D, Linos E, et al. Calcium plus vitamin D supplementation and the risk of non-melanoma and melanoma skin cancer: post hoc analyses of the women's health initiative randomized controlled trial. *J Clin Oncol* 2011;29:3078–84.
- [211] Passarelli MN, Karagas MR, Mott LA, Rees JR, Barry EL, Baron JA. Risk of keratinocyte carcinomas with vitamin D and calcium supplementation: a secondary analysis of a randomized clinical trial. *Am J Clin Nutr* 2020;112:1532–9.
- [212] Weinstock MA, Thwin SS, Siegel JA, Marcolivio K, Means AD, Leader NF, et al. Chemoprevention of basal and squamous cell carcinoma with a single course of fluorouracil, 5%, cream: a randomized clinical trial. *JAMA Dermatol* 2018;154:167–74.
- [213] Rosenberg AR, Tabacchi M, Ngo KH, Wallendorf M, Rosman IS, Cornelius LA, et al. Skin cancer precursor immunotherapy for squamous cell carcinoma prevention. *JCI Insight* 2019;4:e125476.
- [214] Weinstock MA, Bingham SF, Digiovanna JJ, Rizzo AE, Marcolivio K, Hall R, et al. Tretinoin and the prevention of keratinocyte carcinoma (Basal and squamous cell carcinoma of the skin): a veterans affairs randomized chemoprevention trial. *J Invest Dermatol* 2012;132:1583–90.
- [215] Chan AW, Fung K, Austin PC, Kim SJ, Singer LG, Baxter NN, et al. Improved keratinocyte carcinoma outcomes with annual dermatology assessment after solid organ transplantation: population-based cohort study. *Am J Transplant* 2019;19:522–31.
- [216] Christenson LJ, Geusau A, Ferrandiz C, Brown CD, Ulrich C, Stockfleth E, et al. Specialty clinics for the dermatologic care of solid-organ transplant recipients. *Dermatol Surg* 2004;30:598–603.
- [217] Ismail F, Mitchell L, Casabonne D, Gulati A, Newton R, Proby CM, et al. Specialist dermatology clinics for organ transplant recipients significantly improve compliance with photoprotection and levels of skin cancer awareness. *Br J Dermatol* 2006;155:916–25.
- [218] Papier K, Gordon LG, Khosrotehrani K, Isbel N, Campbell S, Griffin A, et al. Increase in preventive behaviour by organ transplant recipients after sun protection information in a skin cancer surveillance clinic. *Br J Dermatol* 2018;179:1195–6.
- [219] Hartman RI, Green AC, Gordon LG, Skin T, Allograft Recipients S. Sun protection among organ transplant recipients after participation in a skin cancer research study. *JAMA Dermatol* 2018;154:842–4.
- [220] Chung EYM, Palmer SC, Strippoli GFM. Interventions to prevent non-melanoma skin cancers in recipients of a solid organ transplant: systematic review of randomized controlled trials. *Transplantation* 2019;103:1206–15.
- [221] James LJ, Saglimbene V, Wong G, Tong A, Luu LDW, Craig J, et al. Behavioural and pharmaceutical interventions for the prevention of skin cancers in solid organ transplant recipients: a systematic review of randomised controlled trials. *BMJ Open* 2020;10:e029265.
- [222] Massey PR, Schmults CD, Li SJ, Arron ST, Asgari MM, Bouwes Bavinck JN, et al. Consensus-based recommendations on the prevention of squamous cell carcinoma in solid organ transplant recipients: a Delphi consensus statement. *JAMA Dermatol* 2021;157:1219–26.
- [223] Kidney Disease: Improving Global Outcomes Transplant Work G.. KDIGO clinical practice guideline for the care of kidney transplant recipients. *Am J Transplant* 2009;9(Suppl 3):S1–155.
- [224] Stasko T, Brown MD, Carucci JA, Euvrard S, Johnson TM, Sengelmann RD, et al. Guidelines for the management of squamous cell carcinoma in organ transplant recipients. *Dermatol Surg* 2004;30:642–50.
- [225] Reichrath J. Dermatologic management, sun avoidance and vitamin D status in organ transplant recipients (OTR). *J Photochem Photobiol B* 2010;101:150–9.
- [226] Transplantation EGoR. European best practice guidelines for renal transplantation. Section IV: long-term management of the transplant recipient. IV.3.1 Long-term immunosuppression. Late steroid or cyclosporine withdrawal. *Nephrol Dial Transplant* 2002;17(Suppl 4):19–20.
- [227] Basset Seguin N, Malvey J, Nadal F, Creancier L, Rauly-Lestienne I, Beauchamp R, et al. Risk behaviour and patient preferences for an improved non-melanoma skin cancer prevention modality for organ-transplanted patients: a European, multi-country, online patient community study. *Eur J Dermatol* 2019;29:518–23.
- [228] Kentley J, Allawh R, Rao S, Doyle A, Ahmad A, Nadhan K, et al. The burden of cutaneous disease in solid organ transplant recipients of color. *Am J Transplant* 2021;21:1215–26.
- [229] Bavinck JN, Tieben LM, Van der Woude FJ, Tegzess AM, Hermans J, ter Schegget J, et al. Prevention of skin cancer and reduction of keratotic skin lesions during acitretin therapy in renal transplant recipients: a double-blind, placebo-controlled study. *J Clin Oncol* 1995;13(8):1933.
- [230] George R, Weightman W, Russ GR, Bannister KM, Mathew TH. Acitretin for chemoprevention of non-melanoma skin cancers in renal transplant recipients. *Aust J Dermatol* 2002;43:269–73.
- [231] de Sevaux RG, Smit JV, de Jong EM, van de Kerkhof PC, Hoitsma AJ. Acitretin treatment of premalignant and malignant skin disorders in renal transplant recipients: clinical effects of a randomized trial comparing two doses of acitretin. *J Am Acad Dermatol* 2003;49:407–12.

- [232] Badri O, Schmults CD, Karia PS, Ruiz ES. Efficacy and cost analysis for acitretin for basal and squamous cell carcinoma prophylaxis in renal transplant recipients. *Dermatol Surg* 2021;47:125–6.
- [233] Martinez JC, Otley CC, Euvrard S, Arpey CJ, Stasko T, International Transplant-Skin Cancer C. Complications of systemic retinoid therapy in organ transplant recipients with squamous cell carcinoma. *Dermatol Surg* 2004;30:662–6.
- [234] Otley CC, Stasko T, Tope WD, Lebwohl M. Chemoprevention of non-melanoma skin cancer with systemic retinoids: practical dosing and management of adverse effects. *Dermatol Surg* 2006;32:562–8.
- [235] Hoegler KM, Khachemoune A. Is the first-line systemic chemoprevention of non-melanoma skin cancer nicotinamide or acitretin? *Int J Dermatol* 2021;60:749–50.
- [236] Otley CC, Berg D, Ulrich C, Stasko T, Murphy GM, Salasche SJ, et al. Reduction of immunosuppression for transplant-associated skin cancer: expert consensus survey. *Br J Dermatol* 2006;154:395–400.
- [237] Chen AC, Martin AJ, Dalziel RA, McKenzie CA, Lowe PM, Eris JM, et al. A phase II randomized controlled trial of nicotinamide for skin cancer chemoprevention in renal transplant recipients. *Br J Dermatol* 2016;175:1073–5.
- [238] Drago F, Ciccarese G, Cogorno L, Calvi C, Marsano LA, Parodi A. Prevention of non-melanoma skin cancers with nicotinamide in transplant recipients: a case-control study. *Eur J Dermatol* 2017;27:382–5.
- [239] Allen NC, Martin AJ, Snaidr VA, Eggins R, Chong AH, Fernandez-Penas P, et al. Nicotinamide for skin-cancer chemoprevention in transplant recipients. *N Engl J Med* 2023;388:804–12.
- [240] Saif MW, Katirtzoglou NA, Syrigos KN. Capecitabine: an overview of the side-effects and their management. *Anticancer Drugs* 2008;19:447–64.
- [241] Jirakulaporn T, Endrizzi B, Lindgren B, Mathew J, Lee PK, Dudek AZ. Capecitabine for skin cancer prevention in solid organ transplant recipients. *Clin Transplant* 2011;25:541–8.
- [242] Endrizzi B, Ahmed RL, Ray T, Dudek A, Lee P. Capecitabine to reduce non-melanoma skin carcinoma burden in solid organ transplant recipients. *Dermatol Surg* 2013;39:634–45.
- [243] Schauder DM, Kim J, Nijhawan RI. Evaluation of the use of capecitabine for the treatment and prevention of actinic keratoses, squamous cell carcinoma, and basal cell carcinoma: a systematic review. *JAMA Dermatol* 2020;156:1117–24.
- [244] Cornejo CM, Jambusaria-Pahlajani A, Willenbrink TJ, Schmults CD, Arron ST, Ruiz ES. Field cancerization: treatment. *J Am Acad Dermatol* 2020;83:719–30.
- [245] Blomberg M, He SY, Harwood C, Arron ST, Demehri S, Green A, et al. Research gaps in the management and prevention of cutaneous squamous cell carcinoma in organ transplant recipients. *Br J Dermatol* 2017;177:1225–33.
- [246] Coghill AE, Johnson LG, Berg D, Resler AJ, Leca N, Madeleine MM. Immunosuppressive medications and squamous cell skin carcinoma: nested case-control study within the skin cancer after organ transplant (SCOT) cohort. *Am J Transplant* 2016;16:565–73.
- [247] Vos M, Plasmeijer EI, van Bommel BC, van der Bij W, Klaver NS, Erasmus ME, et al. Azathioprine to mycophenolate mofetil transition and risk of squamous cell carcinoma after lung transplantation. *J Heart Lung Transplant* 2018;37:853–9.
- [248] Wang M, Mittal A, Colegio OR. Belatacept reduces skin cancer risk in kidney transplant recipients. *J Am Acad Dermatol* 2020;82:996–8.
- [249] Salgo R, Gossman J, Schofer H, Kachel HG, Kuck J, Geiger H, et al. Switch to a sirolimus-based immunosuppression in long-term renal transplant recipients: reduced rate of (pre-)malignancies and non-melanoma skin cancer in a prospective, randomized, assessor-blinded, controlled clinical trial. *Am J Transplant* 2010;10:1385–93.
- [250] Euvrard S, Morelon E, Rostaing L, Goffin E, Brocard A, Tromme I, et al. Sirolimus and secondary skin-cancer prevention in kidney transplantation. *N Engl J Med* 2012;367:329–39.
- [251] Hoogendijk-van den Akker JM, Harden PN, Hoitsma AJ, Proby CM, Wolterbeek R, Bouwes Bavinck JN, et al. Two-year randomized controlled prospective trial converting treatment of stable renal transplant recipients with cutaneous invasive squamous cell carcinomas to sirolimus. *J Clin Oncol* 2013;31:1317–23.
- [252] Campbell SB, Walker R, Tai SS, Jiang Q, Russ GR. Randomized controlled trial of sirolimus for renal transplant recipients at high risk for non-melanoma skin cancer. *Am J Transplant* 2012;12:1146–56.
- [253] Asgari MM, Arron ST, Warton EM, Quesenberry Jr. CP, Weisshaar D. Sirolimus use and risk of cutaneous squamous cell carcinoma (SCC) in solid organ transplant recipients (SOTRs). *J Am Acad Dermatol* 2015;73:444–50.
- [254] Phan K, Moloney FJ, Hogarty DT, Lenane P, McColl D, Yazdabadi A. Mammalian target of rapamycin (mTOR) inhibitors and skin cancer risk in non-renal solid organ transplant recipients: systematic review and meta-analysis. *Int J Dermatol* 2020;59:91–8.
- [255] Knoll GA, Kokolo MB, Mallick R, Beck A, Buenaventura CD, Ducharme R, et al. Effect of sirolimus on malignancy and survival after kidney transplantation: systematic review and meta-analysis of individual patient data. *BMJ* 2014;349:g6679.
- [256] Karia PS, Azzi JR, Heher EC, Hills VM, Schmults CD. Association of sirolimus use with risk for skin cancer in a mixed-organ cohort of solid-organ transplant recipients with a history of cancer. *JAMA Dermatol* 2016;152:533–40.
- [257] Krisl JC, Doan VP. Chemotherapy and Transplantation: the role of immunosuppression in malignancy and a review of antineoplastic agents in solid organ transplant recipients. *Am J Transplant* 2017;17:1974–91.
- [258] Bottomley MJ, Massey PR, Thuraisingham R, Doyle A, Rao S, Bibee KP, et al. Interventions after first post-transplant cutaneous squamous cell carcinoma: a proposed decision framework. *Transpl Int* 2022;35:10880.
- [259] Acuna SA, Huang JW, Scott AL, Micic S, Daly C, Brezden-Masley C, et al. Cancer screening recommendations for solid organ transplant recipients: a systematic review of clinical practice guidelines. *Am J Transplant* 2017;17:103–14.
- [260] Crow LD, Jambusaria-Pahlajani A, Chung CL, Baran DA, Lowenstein SE, Abdelmalek M, et al. Initial skin cancer screening for solid organ transplant recipients in the US: Delphi method development of expert consensus guidelines. *Transpl Int* 2019;32:1268–76.
- [261] Jambusaria-Pahlajani A, Crow LD, Lowenstein S, Garrett GL, Melcher ML, Chan AW, et al. Predicting skin cancer in organ transplant recipients: development of the SUNTRAC screening tool using data from a multicenter cohort study. *Transpl Int* 2019;32:1259–67.
- [262] Lowenstein SE, Garrett G, Toland AE, Jambusaria-Pahlajani A, Asgari MM, Green A, et al. Risk prediction tools for keratinocyte carcinoma after solid organ transplantation: a review of the literature. *Br J Dermatol* 2017;177:1202–7.
- [263] Mansfield AS, Rabe KG, Slager SL, Schwager SM, Call TG, Brewer JD, et al. Skin cancer surveillance and malignancies of the skin in a community-dwelling cohort of patients with newly diagnosed chronic lymphocytic leukemia. *J Oncol Pract* 2014;10:e1–4.
- [264] Ishdorj G, Beiggi S, Nugent Z, Streu E, Banerji V, Dhaliwal D, et al. Risk factors for skin cancer and solid tumors in newly diagnosed patients with chronic lymphocytic leukemia and the impact of skin surveillance on survival. *Leuk Lymphoma* 2019;60:3204–13.

- [265] Anderson A, Ferris LK, Click B, Ramos-Rivers C, Koutroubakis IE, Hashash JG, et al. Low rates of dermatologic care and skin cancer screening among inflammatory bowel disease patients. *Dig Dis Sci* 2018;63:2729–39.
- [266] Bonerandi JJ, Beauvillain C, Caquant L, Chassagne JF, Chaussade V, Clavere P, et al. Guidelines for the diagnosis and treatment of cutaneous squamous cell carcinoma and precursor lesions. *J Eur Acad Dermatol Venereol* 2011;25(Suppl 5):1–51.