



HAL
open science

European consensus-based interdisciplinary guideline for invasive cutaneous squamous cell carcinoma: Part 2. Treatment–Update 2023

Alexander Stratigos, Claus Garbe, Clio Dessinioti, Celeste Lebbe, Alexander van Akkooi, Veronique Bataille, Lars Bastholt, Brigitte Dreno, Reinhard Dummer, Maria Concetta Fargnoli, et al.

► To cite this version:

Alexander Stratigos, Claus Garbe, Clio Dessinioti, Celeste Lebbe, Alexander van Akkooi, et al.. European consensus-based interdisciplinary guideline for invasive cutaneous squamous cell carcinoma: Part 2. Treatment–Update 2023. *European Journal of Cancer*, 2023, 193, pp.113252. 10.1016/j.ejca.2023.113252 . inserm-04209605

HAL Id: inserm-04209605

<https://inserm.hal.science/inserm-04209605>

Submitted on 18 Sep 2023

HAL is a multi-disciplinary open access archive for the deposit and dissemination of scientific research documents, whether they are published or not. The documents may come from teaching and research institutions in France or abroad, or from public or private research centers.

L'archive ouverte pluridisciplinaire **HAL**, est destinée au dépôt et à la diffusion de documents scientifiques de niveau recherche, publiés ou non, émanant des établissements d'enseignement et de recherche français ou étrangers, des laboratoires publics ou privés.



Distributed under a Creative Commons Attribution 4.0 International License



Original Research

European consensus-based interdisciplinary guideline for invasive cutaneous squamous cell carcinoma: Part 2. Treatment–Update 2023



Alexander J. Stratigos^{a,*}, Claus Garbe^b, Clio Dessinioti^a, Celeste Lebbe^c, Alexander van Akkooi^{d,e,f}, Veronique Bataille^g, Lars Bastholt^h, Brigitte Drenoⁱ, Reinhard Dummer^j, Maria Concetta Fargnoli^k, Ana Maria Forsea^l, Catherine A. Harwood^m, Axel Hauschildⁿ, Christoph Hoeller^o, Lidija Kandolf-Sekulovic^p, Roland Kaufmann^q, Nicole WJ Kelleners-Smeets^{r,s}, Aimilios Lallas^t, Ulrike Leiter^b, Josep Malvehy^u, Veronique del Marmol^v, David Moreno-Ramirez^w, Giovanni Pellacani^x, Ketty Peris^{y,z}, Philippe Saiag^{aa}, Luca Tagliaferri^{ab}, Myrto Trakatelli^{ac}, Dimitrios Ioannides^t, Ricardo Vieira^{ad}, Iris Zalaudek^{ae}, Petr Arenberger^{af}, Alexander M.M. Eggermont^{ag,ah}, Martin Röcken^b, Jean-Jacques Grob^{ai}, Paul Lorigan^{aj,ak}, On behalf of EADO, EDF, ESTRO, UEMS, EADV and EORTC^l

^a First Department of Dermatology-Venereology, National and Kapodistrian University of Athens, Andreas Sygros Hospital, Athens, Greece

^b Centre for Dermatooncology, Department of Dermatology, Eberhard Karls University, Tuebingen, Germany

^c Université Paris Cite, Dermato-Oncology AP-HP Hôpital Saint Louis, Cancer Institute APHP. Nord-Université Paris Cite, INSERM U976, Paris, France

^d Department of Melanoma and Surgical Oncology, Royal Prince Alfred Hospital, Sydney, New South Wales, Australia

^e Faculty of Medicine and Health, University of Sydney, Sydney, New South Wales, Australia

^f Melanoma Institute Australia, Sydney, New South Wales, Australia

^g Mount Vernon Cancer Centre, East and North NHS Trust, Northwood, UK

^h Department of Oncology, Odense University Hospital, Odense, Denmark

* Corresponding author: First Department of Dermatology-Venereology, National and Kapodistrian University of Athens, Andreas Sygros Hospital, Athens, Greece.

E-mail address: alstrat2@gmail.com (A.J. Stratigos).

^l EADO, European Association of Dermato-Oncology; EDF, European Dermatology Forum; ESTRO, European Society for Radiotherapy and Oncology; UEMS, European Union of Medical Specialists (Union Européenne des Médecins Spécialistes); EADV, European Academy of Dermatology and Venereology; EORTC, European Organization for Research and Treatment of Cancer.

- ⁱ Nantes Université, INSERM, CNRS, Immunology and New Concepts in ImmunoTherapy, INCIT, UMR 13021 EMR6001, Nantes, France
- ^j Skin Cancer Centre at University Hospital, Zurich, Switzerland
- ^k Dermatology Department of Biotechnological and Applied Clinical Sciences, University of L'Aquila, L'Aquila, Italy
- ^l Carol Davila University of Medicine and Pharmacy Bucharest, Department of Oncologic Dermatology, Elias University Hospital Bucharest, Bucharest, Romania
- ^m Centre for Cell Biology and Cutaneous Research, Blizard Institute, Barts and the London School of Medicine and Dentistry, Queen Mary University of London, London, UK
- ⁿ Department of Dermatology, University Hospital (UKSH), Kiel, Germany
- ^o Department of Dermatology, Medical University of Vienna, Vienna, Austria
- ^p Department of Dermatology, Medical Faculty, Military Medical Academy, Belgrade, Serbia
- ^q Department of Dermatology, Venereology and Allergology, Frankfurt University Hospital, Frankfurt, Germany
- ^r GROW-School for Oncology and Reproduction, Maastricht University, Maastricht, the Netherlands
- ^s Department of Dermatology, Maastricht University Medical Centre+, Maastricht University, Maastricht, the Netherlands
- ^t First Department of Dermatology, Aristotle University, Thessaloniki, Greece
- ^u Dermatology Department of Hospital Clinic of Barcelona, University of Barcelona, IDIBAPS, CIBER de enfermedades raras, Instituto Carlos III, Barcelona, Spain
- ^v Department of Dermatology, University Hospital Erasme, Université Libre de Bruxelles, Brussels, Belgium
- ^w Department of Medical and Surgical Dermatology Service, Hospital Universitario Virgen Macarena, Sevilla, Spain
- ^x Dermatology Unit, University of Rome La Sapienza, Rome, Italy
- ^y UOC di Dermatologia, Dipartimento di Scienze Mediche e Chirurgiche Addominali ed Endocrino Metaboliche, Fondazione Policlinico Universitario A. Gemelli-IRCCS, Rome, Italy
- ^z Dermatologia, Università Cattolica del Sacro Cuore, Rome, Italy
- ^{aa} Department of General and Oncologic Dermatology, Ambroise-Paré hospital, APHP, and EA 4340 'Biomarkers in Cancerology and Hemato-oncology', UVSQ, Université Paris-Saclay, Boulogne-Billancourt, France
- ^{ab} UOC Radioterapia Oncologica, Dipartimento di Diagnostica per Immagini, Radioterapia Oncologica ed Ematologia, Fondazione Policlinico Universitario A. Gemelli IRCCS, Rome, Italy
- ^{ac} Department of Dermatology, Papageorgiou Hospital, Aristotle University Department of Medicine, Thessaloniki, Greece
- ^{ad} Department of Dermatology, Coimbra Hospital and University Centre, Coimbra, Portugal
- ^{ae} Department of Dermatology, University of Trieste, Trieste, Italy
- ^{af} Department of Dermatovenereology, Third Faculty of Medicine, Charles University, Prague, Czech Republic
- ^{ag} University Medical Center Utrecht and Princess Máxima Center, Utrecht, the Netherlands
- ^{ah} Comprehensive Cancer Center Munich, Technical University Munich and Ludwig Maximilian University, Munich, Germany
- ^{ai} Aix Marseille University, APHM Hospital, Marseille, France
- ^{aj} Division of Cancer Sciences, University of Manchester, Manchester, UK
- ^{ak} Department of Medical Oncology, Christie NHS Foundation Trust, Manchester, UK

Received 18 July 2023; Accepted 18 July 2023

Available online 28 July 2023

KEYWORDS

Cutaneous squamous cell carcinoma;
Locally advanced;
Metastatic;
Treatment;
Surgical excision;
Radiotherapy;
Adjuvant;
Anti-PD-1 antibody;
Cemiplimab;
Follow-up

Abstract In order to update recommendations on treatment, supportive care, education, and follow-up of patients with invasive cutaneous squamous cell carcinoma (cSCC), a multidisciplinary panel of experts from the European Association of Dermato-Oncology (EADO), the European Dermatology Forum (EDF), the European Society for Radiotherapy and Oncology (ESTRO), the European Union of Medical Specialists (UEMS), the European Academy of Dermatology and Venereology (EADV), and the European Organisation of Research and Treatment of Cancer (EORTC) was formed. Recommendations were based on an evidence-based literature review, guidelines, and expert consensus. Treatment recommendations are presented for common primary cSCC (low risk, high risk), locally advanced cSCC, regional metastatic cSCC (operable or inoperable), and distant metastatic cSCC. For common primary cSCC, the first-line treatment is surgical excision with post-operative margin assessment or micrographically controlled surgery. Achieving clear surgical margins is the most important treatment consideration for patients with cSCCs amenable to surgery. Regarding adjuvant radiotherapy for patients with high-risk localised cSCC with clear surgical margins, current evidence has not shown significant benefit for those with at least one high-risk factor. Radiotherapy should be considered as the primary treatment for non-surgical candidates/tumours. For cSCC with cytologically or histologically confirmed regional nodal metastasis, lymph node dissection is recommended. For patients with metastatic or locally advanced cSCC who are not candidates for curative surgery or radiotherapy, anti-PD-1 agents are the first-line systemic treatment, with cemiplimab being the first

approved systemic agent for advanced cSCC by the Food and Drugs Administration/European Medicines Agency. Second-line systemic treatments for advanced cSCC, include epidermal growth factor receptor inhibitors (cetuximab) combined with chemotherapy or radiotherapy. Multidisciplinary board decisions are mandatory for all patients with advanced cSCC, considering the risks of toxicity, the age and frailty of patients, and co-morbidities, including immunosuppression. Patients should be engaged in informed, shared decision-making on management and be provided with the best supportive care to improve symptom management and quality of life. The frequency of follow-up visits and investigations for subsequent new cSCC depends on underlying risk characteristics.

© 2023 The Author(s). Published by Elsevier Ltd. This is an open access article under the CC BY-NC-ND license (<http://creativecommons.org/licenses/by-nc-nd/4.0/>).

1. Information about the guideline

The European Interdisciplinary Guidelines on invasive squamous cell carcinoma of the skin were written as a uniform text and then published in two separate but integral parts: part 1 on definitions, epidemiology, etiopathogenesis, diagnosis, risk classification, staging, and prevention and part 2 on treatments, supportive care, communication with the patient, and follow-up. Information about the Guidelines is detailed in Stratigos et al. Part 1. 2023., including the information about societies in charge, financing of the guidelines, scope, target population, objectives, and formulation of sections, audience and period of validity, and methodology.

Recommendations were based on the level of best-quality available evidence and good practice points (GPP). Expert consensus was provided wherever adequate evidence is not available. The levels of evidence were graded according to the Oxford classification [1]. In brief, level 1 indicates the strongest evidence based on a systematic review of randomized controlled trials or high-quality studies, level 2 is based on randomised or well-designed cohort or cross-sectional studies, level 3 is based on non-randomised adequately designed studies, and levels 4 and 5 indicate the weakest evidence based on a smaller number of patients or poor quality. The level may be graded down based on study quality, imprecision, indirectness, because of inconsistency between studies, or because the absolute effect size is very small. The level may be graded up if there is a large or very large effect size. (detailed in Stratigos et al. Part 1. 2023).

The grades of recommendation were classified as follows:

- A: Strong recommendation. Syntax: ‘shall.’
- B: Recommendation. Syntax: ‘should.’
- C: Weak recommendation. Syntax: ‘may/can.’
- X: Should not be recommended.

0: Recommendation pending. Currently, not available or sufficient evidence to make a recommendation in favour or against.

The guideline manuscripts were additionally reviewed by reviewers from each participating society, who were not included as authors of the guidelines.

1.1. Consensus building process

The meeting was held in Rome, Italy, on 25th November 2022. A structured consensus process was used to discuss and agree upon, with final outcomes: (1) the approval of the text and (2) a consensus rate of agreement of at least 80%, for recommendations provided in structured boxes and the figure. Voting of the recommendations included the selection of ‘Agree,’ ‘Disagree,’ or ‘Abstention,’ and the possibility of providing comments in the case of disagree/abstention. Twenty-four experts were present in the consensus meeting. The final literature search update was performed on 10th March 2023, and did not result in changes in the recommendation boxes; new references were added in the texts. The finalisation of the draft and recommendations was conducted through emailing among all co-authors in the first semester of 2023.

Compared with the guideline 2020 recommendations, in this update, the following recommendation boxes were kept the same: **Box 1.** Surgical excision of primary cutaneous squamous cell carcinoma (cSCC), **Box 2.** Surgery and safety margins, **Box 3.** Wound closure, **Box 4.** Therapeutic lymph node dissection, **Box 5.** Elective lymph node dissection, **Box 6.** Elective neck lymph node dissection for mcSCC to the parotid, and **Box 8.** Primary Radiotherapy (RT). The following recommendation boxes were updated: **Box 7.** Destructive modalities for cSCC, **Box 9.** Postoperative RT, **Box 12.** Immunotherapy for advanced cSCC, **Box 13.** EGFR inhibitors, and **Box 14.** Follow-up. The following new boxes were added: **Box 10.** Adjuvant RT for resected nodal metastatic cSCC, and **Box 11.** Adjuvant RT for high-risk cSCC.

A summarising box of recommendations is provided at the end of the article containing the practice-oriented statements.

1.2. Disclaimer

Medicine is subject to a continuous development process. This entails that all statements, especially with regard to diagnostic and therapeutic procedures, can only reflect scientific knowledge current at the time of printing of these guidelines. Utmost care was applied with respect to stated therapeutic recommendations and the selection as well as the dosage of drugs. Nevertheless, users are prompted to use package inserts and expert information by the manufacturers as backup and, in case of doubt, consult a specialist. Pursuant to the public interest, questionable discrepancies shall be communicated to the Guideline Program in Oncology (GPO) editors. The user himself/herself remains responsible for all diagnostic and therapeutic applications, medications, and doses. Registered trademarks (protected product names) are not specified in these guidelines. In the absence of respective indications, it may thus not be inferred that product names are unprotected.

This work is protected by copyright in all its parts. Any utilisation outside the provision of the copyright act without the written permission by the GPO of the European Association of Dermato-Oncology (EADO) is prohibited and punishable by law. No part of this work may be reproduced in any way without written permission by the GPO. This applies in particular to duplications, translations, microfilming, and the storage, application, and utilisation in electronic systems, intranets, and internet.

2. General considerations for the treatment of cSCC

The primary treatment of cSCC is surgery, aiming at the clinical and microscopic clearance of the tumour (R0 surgery). The preservation of function and cosmesis are additional objectives of treatment. Achieving clear surgical margins is the most important treatment consideration for patients with cSCCs amenable to surgery. Radiotherapy may be considered as a primary treatment in patients who are not candidates for surgery (e.g. locally infiltrating tumour, comorbidities, or declined surgery) or in cases when curative surgery is not possible or could be disfiguring. The very low risk of radiation-induced, in-field malignancy in the future, in patients younger than 60 years old with cSCC, should be considered during the decision-making [2].

Adjuvant therapy is defined as an additional treatment, either systemic or radiotherapy, given after complete resection at the primary surgical treatment (R0), with the aim to reduce the risk of recurrence. While there are ongoing clinical trials investigating the potential benefit of adjuvant systemic therapy for cSCC, currently only adjuvant RT has been used in routine clinical practice. The benefit of adjuvant RT to the nodal basin has been shown after lymph node dissection for cSCC with nodal metastasis. However, current evidence has not

shown a clear benefit for adjuvant RT in patients with primary cSCCs with clear surgical margins.

Systemic treatment options used for advanced cSCC include immunotherapy with programmed death receptor-1 (PD-1) blocking antibodies, epidermal growth factor receptor (EGFR) inhibitors, chemotherapy, and electrochemotherapy. Currently, the anti-PD-1 agent cemiplimab is the only approved systemic treatment for cSCC in Europe. Cemiplimab is approved for the treatment of patients with metastatic cSCC (mcSCC) or locally advanced cSCC (lacSCC) who are not candidates for curative surgery or radiotherapy,

A multidisciplinary approach is mandatory for all patients with advanced disease, considering the risks of toxicity, age, and frailty of patients, in addition to comorbidities, including immunosuppression [3]. The systematic review by Leus et al. reported that the age of elderly patients did not significantly affect surgery outcomes, including recurrence rate, complication rate, and disease-specific survival [4]. However, frailty may be a more relevant issue. Frail patients (Eastern Cooperative Oncology Group performance status 2 or higher) have not been included in pivotal clinical trials for cSCC. Real-world studies report some encouraging results for response and toxicity with anti-PD-1 agents in frail patients with cSCC, although the number of such included patients is currently small [5–7].

All treatment considerations are based on the informed consent of the patient (or an appointee having the legal authority to decide on the patient's behalf in the case of a patient lacking the mental capacity of informed consent, according to national legal requirements) and on offering a shared decision-making. The treating physician will inform the patient about the first and other lines of treatment based on current best evidence and guidelines, explain the expected benefit and risks, and involve the preferences and priorities of the individual patient in the decision process.

3. Surgery for common primary cSCC

Surgical excision is considered the primary treatment of primary cSCC, regardless of the age of the patient or the anatomic location. Surgery provides a high rate of clinical and microscopic complete resection (R0 surgery).

Two different approaches may be offered: (1) Excision with standardised safety margins and post-operative margin assessment (where only part of the actual resection margin is being examined), or (2) micrographically controlled surgery (3D) with a mapping of the entire circumferential and deep tumour borders followed by step-wise re-excisions in case of any residual tumour nests [8,9]. Frequently, a reconstructive procedure (i.e. flap or graft closure) is necessary to repair the surgical defect resulting from tumour resection, but final reconstruction is strongly discouraged before histological confirmation of clear margins [10]. The surgical management of tumours requiring extensive excisions should be performed by surgeons (dermato-surgeons,

Box 1 Surgical excision of primary cSCC.

Surgical treatment of primary cSCC	Evidence-based recommendation
Grade of recommendation A	Surgical excision with histological control shall be performed as standard treatment. The aim of cSCC surgery shall be a complete excision (R0) with histological confirmation of peripheral and deep excision margins. Large tumours or tumours on the head and neck can undergo a punch or incisional biopsy for histological confirmation and planning of a subsequent complete excision. In cases of positive margins, a re-excision shall be done, for operable cases.
Level of evidence 2	Guideline adaptation [13,21]. Systematic review [31,46]. Retrospective study [39]. Strength of consensus: 100%.

Box 2 Surgery and safety margins.

Surgery and safety margins	Evidence-based recommendation
Grade of recommendation B	Low-risk cSCC should be excised with a clinical safety margin of 5 mm. cSCC with high-risk factors should be excised with a clinical safety margin of 6–10 mm or by micrographically controlled surgery. Micrographically controlled surgery should be considered for cSCC in functional/cosmetical sensitive areas.
Level of evidence 2–3	Guideline adaptation [19–21,25,27]. Strength of consensus: 100%.

Box 3 Wound closure.

GPP	As long as an R0 resection is not histologically confirmed, wound closure with local tissue movements (flaps) should be avoided. Strength of consensus: 100%.
-----	--

plastic surgeons or head, and neck surgeons) with appropriate expertise in reconstructive procedures.

3.1. Standard excision

Surgical excision including all visible tumour borders together with a risk-adapted adjacent safety margin of clinically normal-appearing skin is the standard treatment of invasive cSCC [11]. Conventional excision should be followed by postoperative pathologic assessment of resection margins to ensure an appropriate lateral and deep tumour-free margin and thus minimise the risk of local recurrence and metastases [2,12,13]. Routinely, histological examination of the excised tumour bed is performed in a cross-sectional fashion with vertical sample cuts (bread-loaf sections for 2D histology) obtained from formalin-fixed, paraffin-embedded tissue [9,14].

Clinical safety excision margins should be adapted to the likelihood of subclinical extensions and recurrence [15], as defined by high-risk factors including clinical (tumour diameter > 2 cm, high-risk sites), histological (thickness > 6 mm or invasion beyond subcutaneous fat, perineural invasion, poor differentiation, desmoplasia), and patient-related criteria (immunosuppression) (EADO list of

high-risk criteria (listed in Guideline Part 1). There are no randomised studies investigating optimal clinical safety margins for excision. In clinically well-defined low-risk cSCCs with a diameter of less than 2 cm, a clinical safety margin of 4 mm has achieved cure rates of 95–97% in prospective studies [16,17]. Nevertheless, diameter is only an approximate reflection of the actual degree of tumour aggressiveness, and additional histological features may increase the risk of margin involvement, even in smaller tumours [18]. Therefore, several national guidelines discuss margins between 4 and 6 mm for tumours lacking high-risk features [2,13,19–22]. The European consensus group suggests a 5 mm clinical safety margin for low-risk lesions (Fig. 1). A recent prospective study reported a 98% complete excision in T1 tumours excised with a 5 mm margin versus 91% of T2 tumours and 81% of T3 tumours excised with 1 cm. Most of the residual tumour involved the deep margin [23]. In the event, that a cSCC thought to be a low risk at biopsy is proven to be a high risk after excision with a 5 mm clinical safety margins, a re-excision with a histological clear margin can be discussed.

For high-risk cSCC, however, even though wider margins are recommended, there is currently no unified recommendation on appropriate safety margins [24]. Some recent guidelines discuss the need for complete

excision without further specifying margins or emphasise the value of micrographically controlled surgery in high-risk and very high-risk cSCC, primarily due to the wide variability of characteristics that may define cSCC at higher risk [10,13,14]. According to an early work from Brodland et al., for larger cSCCs (>2 cm in maximum clinical diameter) and/or other high-risk factors, an excision margin of at least 6 mm is required [16]. The British guideline recommends ≥ 6 mm for high-risk, and ≥ 10 mm for very high-risk cSCC [2]. Additional recommendations from reviews or guidelines also vary from a lower limit of six up to ≥ 10 mm, or favour micrographically controlled excisions as a first-line treatment instead [20,22,25–27]. As the independent prognostic effect of high-risk factors has not been consistently reported, a specific recommendation on the clinical safety margins cannot be given but should fall within the 6–10 mm range and be based on individual risk assessment and tumour- and patient-related characteristics (Fig. 1). In addition to the European consensus group, the Japanese Dermatology Society suggests 6–10 mm safety margins for cSCC with high-risk factors [21,22]. A retrospective study from Japan has challenged the need for wider excision margins in high-risk and very-high-risk (according to National Comprehensive Cancer Network [NCCN] guidelines) cSCC patients. They compared two cohorts excised either with safety margins adherent to national guidelines (6–10 mm) or with narrower margins (≤ 5 mm). Though there was a significantly higher incomplete excision rate in the narrow-margin-group of very-high-risk tumours, the authors did not find significant differences between both groups with regard to a cumulative incidence of local relapse, cSCC relapse (local, regional nodal, or distant relapse), or cSCC death [28].

In patients with skin areas covered by a cluster of multiple invasive cSCCs (e.g. on the dorsal hands or scalp), en bloc excision of the involved field with subsequent skin grafting can be offered as an effective treatment.

The depth of excision should include the subcutaneous tissue (together with the underlying galea-aponeurosis in scalp locations) while sparing the perichondrium or periosteum, provided these structures are not affected by the tumour [19].

In the case of positive margins, a re-excision shall be done for operable cases. Wider excision should be considered when margins appear more limited than the recommended safety margins, as described in the pathology report, after considering the tissue shrinkage during the process (Fig. 1).

Instead of extended standard margins, micrographically controlled surgery should be considered in selected cases of high-risk cSCC, though evidence of the superiority of the method over standard excisions is based only on retrospective studies [29,30].

3.2. Micrographically controlled surgery

Micrographically controlled surgery is used as a collective term for a range of surgical techniques used to remove skin cancer with complete margin control. These stepwise procedures allow for peritumoural examination that is repeated until all circumferential and deep borders are completely free of tumour. Micrographically controlled surgery thus provides complete margin assessment, enables histological clearance prior to reconstruction, and minimises the removal of uninvolved tissue [31]. Two techniques are mainly being used in Europe with diverse modification of sectioning the tissue specimen: Mohs micrographic surgery (MMS) and 3D histology [32], the first one making use of intra-operative frozen sections whereas the second one uses paraffin sections [33] (https://esms-mohs.eu/fileadmin/user_upload/ESMS_Position_Paper_-_WEB.pdf). The NCCN Guidelines on cSCC use the descriptive term ‘Peripheral and deep en face margin assessment (PDEMA)’, instead of the previous term ‘complete circumferential peripheral and deep margin assessment (CCPDMA),’ referring to the techniques, in which the entire marginal surface of the surgical specimen (including the complete deep and peripheral margin) is microscopically visualised and histopathologically analysed for the presence of SCC [13]. Among the available techniques and modifications of micrographically controlled surgery achieving this purpose of en face margin assessment are MMS with frozen sectioning, or the Tübingen Muffin (Supplementary Fig. 1) and Tübingen Torte techniques, both employing formalin fixation and paraffin embedding and complete margin assessment [13,34] (https://esms-mohs.eu/fileadmin/user_upload/ESMS_Position_Paper_-_WEB.pdf). Furthermore, the NCCN guidelines include a checklist to apply before naming a technique PDEMA as many other surgical techniques exist such as square technique, perimeter technique, moat technique, and quadrant technique where the deep margin is examined in vertical sections and therefore a complete visualisation of the deep margin is not given [13]. An advantage of MMS is that the tumour can be removed and on the same day a reconstruction can be performed shortly after. There have been attempts to replace the traditional MMS frozen tissue with the use of fresh-tissue sections examined intra-operatively by ex-vivo confocal microscopy [35], but in cSCC, this approach has yet failed at reliably detecting small areas of residual tumour or more specific morphological features such as perineural growth.

There is no randomised trial that compares micrographically controlled surgery techniques with conventional surgical excision for cSCC [11,31]. Micrographically controlled surgery provides the highest rate of R0 resection, above 90%, and lower recurrence rates (0–4%) compared to conventional surgery (recurrence rates: 3.1–8.0%) [11,29,31,36–43].

The systematic review and meta-analysis of Fraga et al. compared recurrence for complete margin assessment versus excision with sectional assessment in high-risk keratinocyte carcinomas. They reported significantly lower locoregional recurrences with complete margin assessment versus sectional assessment for all keratinocyte carcinomas (3.9% versus 13.5%, $p = 0.001$) and for cSCC with PNI (9.8% versus 32%, $p < 0.001$) [44]. The value of MMS has been documented, especially for head and neck tumours [11,36–38]. The value of MMS in the prevention of local recurrence has been reported in retrospective studies. In one study, including 647 high-risk cSCC there were 19 local recurrences (LR) (2.9%), 31 nodal metastases (4.8%), seven distant metastases (1.1%), and seven disease-specific deaths (DSD) (1.1%) [39]. The other retrospective study including 579 patients with 672 cSCCs of the head and neck (380 treated with MMS and 292 with standard excision) concluded that MMS might be superior to standard excision for cSCCs of the head and neck because of a lower recurrence rate after adjustment for tumour size and deep tumour invasion (3% versus 8%) [29].

When modelling the expenses of MMS under theoretical assumptions based on the data from previous studies on intermediate risk cSCC, MMS was more cost-effective than wide local excision in an outpatient setting [45]. The higher complexity of this multistep procedure usually limits its use to patients with high-risk tumours, in whom micrographically controlled surgery provides the best guarantee for complete tumour resection with optimal anatomic, aesthetic, and functional preservation. In conclusion, the various modifications of micrographically controlled surgery are tissue conservative and effective treatments in cases of high-risk cSCC, particularly in the head and neck area.

4. Surgery for regional nodal disease

The evidence about the management of regional nodal disease in patients with cSCC is limited and largely based on studies performed in head and neck mucosal SCC [47,48]. It is likely that patients with nodal metastases from cSCC should be managed surgically in a similar way to patients with other skin cancers (melanoma or Merkel cell carcinoma). For all tumours not amenable to surgery (due to patient-related factors or when the intention of a R0-resectability cannot be achieved), radiotherapy should be considered based on a multidisciplinary tumour board decision. Appropriate staging to determine the extent of disease is detailed in Stratigos et al. Part 1. 2023.

Therapeutic regional lymph node dissection for lymph nodes clinically detected or following imaging is the preferred surgical treatment [13,27,49–58]. A radical lymph node dissection of the affected areas is still considered the standard of care for patients with resectable nodal disease. However, in view of the lack of overall survival benefits from radical dissections, the extent of surgical resection, that is, the levels of axillary nodes, whether to remove deep inguinal nodes, should always be determined for each patient by the interdisciplinary tumour board. Neck dissection in addition to superficial parotidectomy should be performed if the parotid gland is affected, since a lower disease-specific survival was observed with radiation therapy alone [59]. It is unclear whether a more selective procedure will affect the disease-free survival and the overall survival. Accordingly, over the last decade, a trend towards the consideration and offer of less extensive and more selective lymph node dissections has developed, particularly with head-and-neck cSCC patients, where this approach has shown regional control and survival rates of 85–100%, similar to those reported for conventional radical neck

Box 4 Therapeutic lymph node dissection.

Therapeutic lymph node dissection	Evidence-based recommendation
Grade of recommendation: B	A regional therapeutic lymph node dissection should be performed in patients with lymph node metastasis detected clinically or by imaging tests and confirmed with cytology or biopsy. The extent of surgical resection is determined by the surgeon in collaboration with the multidisciplinary tumour board.
Level of evidence: 3	Review [49,50]. Prospective study [51]. Retrospective study [52–56,58]. Guidelines [13,27,57]. Strength of consensus: 100%.

Box 5 Elective lymph node dissection for N0 cSCC.

Elective lymph node dissection for cSCC	Evidence-based recommendation
Grade of recommendation: X	Elective lymph node dissection shall not be performed for N0 cSCC.
Level of evidence: 4	Evidence for elective lymph node dissection for N0 cSCC is lacking [49]. Strength of consensus: 100%.

Box 6 Elective neck lymph node dissection for mcSCC to the parotid.

Elective neck lymph node dissection for metastatic cSCC to the parotid	Evidence-based recommendation
Grade of recommendation: C	Elective neck dissection may be discussed and offered for metastatic cSCC within the parotid.
Level of evidence: 3	Meta-analysis [63]. Strength of consensus: 100%.

dissections [56,60,61]. Thus, the extent of lymph node dissections should be discussed in the context of the interdisciplinary tumour board and after a thorough assessment of tumour-related (aggressiveness, involved regional basin, tumour burden, etc.), surgical (potential complications, morbidity, etc.), and patient-related features (overall condition, performance status, preferences, expectations, etc.).

Also, the current approach to lymph node disease, particularly for those patients with large-burden nodal disease, will be revisited if/when neoadjuvant therapy becomes available. A recently published phase II clinical trial of neoadjuvant cemiplimab reporting pathological complete response in 50% of the patients favours this future approach [62] (see Section 8. Neoadjuvant therapy).

5. Treatment alternatives

5.1. Curettage & electrodesiccation (C&E)

There are no prospective studies comparing curettage alone or C&E with other treatments. In a retrospective series of 89 mostly well differentiated and smaller cSCC (mean pretreatment size 0.9 cm) removed by curettage alone, Yakish et al. reported an overall cure rate of 97% after a median follow-up of 6 years [64]. A systemic review and pooled analysis of observational studies on combined C&E reported low recurrence rates for small cSCC (<2 cm) [11], which was confirmed by a recent meta-analysis for *in situ* and invasive cSCC, studied together [65]. Updated NCCN guidelines 2023 and an expert consensus in the American Academy of Dermatology (AAD) guidelines state that C&E may be considered for small, low-risk primary cSCC (based on NCCN risk stratification) [10,13]. C&E (two cycles) in experienced hands can be performed in small, low-risk tumours, and in selected cases (patients with multiple cSCCs), but surgery is always to be preferred to this blind method.

Box 7 Destructive modalities for cSCC.

Destructive modalities	Consensus-based recommendation
GPP	Destructive modalities such as ED and C, cryotherapy, PDT, and lasers should not be performed in the treatment of primary invasive cSCC. Exceptions can be considered in small-sized and/or multiple cSCCs in low-risk areas where surgery and/or RT are not possible or have unacceptable consequences. Strength of consensus: 100%.

5.2. Other destructive treatments: Cryosurgery, lasers, PDT

Cryosurgery, superficial skin ablation (laser, dermabrasion), or photodynamic therapy share the lack of histological control and thus may increase the risk of recurrences, eventually leading to surgery in even poorer conditions. NCCN guidelines on cSCC list laser ablation among therapeutic options in field cancerization or actinic cheilitis [13], but there is no evidence to consider the use of lasers in invasive cSCC [11,66]. PDT is only approved in Bowen's disease (*in situ* cSCC), but there is inadequate evidence regarding its efficacy for invasive cSCC. Also, when used in field cancerization, the effect of PDT to prevent the development of new SCC remains limited [67,68]. A systematic review and pooled analysis of observational studies reported low recurrence rates after cryotherapy, but most cSCC included were small and low-risk tumours, and the quality of evidence was low [11]. AAD guidelines state that cryosurgery may be considered for low-risk cSCC when more effective therapies are contraindicated or impractical, which is rather uncommon [66]. Nevertheless, in selected cases of low-risk cSCC, particularly in patients with extensive field cancerization, cryotherapy can be offered [13,69].

Surgery should be discussed and considered with preference to any destructive and 'blind' options.

5.3. Intralesional cytostatic drugs

Minimal invasive intralesional treatments could be alternatives in select patients for whom surgical excision is not acceptable and are particularly among non-surgical options suggested in those with keratoacanthomas (KA). In cSCC, the injection of 5-fluorouracil has been recently analysed in a retrospective cohort with a total

of 172 lesions (majority <2 cm in diameter, predominantly located on legs, including seven KA). Treatment was well tolerated and followed by clinical resolution in 92% of cases [70]. In KA, when a suggestive history of a rapid development together with clinical and histological features are typical, intralesional injection of several cytostatic drugs (methotrexate, 5-fluorouracil, or bleomycin) may be considered to reduce scarring in a potentially self-healing lesion. However, an advantageous benefit-risk ratio has not yet been demonstrated, particularly when compared with surgery [71–73]. If complete regression is not achieved, the lesion should be surgically removed to exclude the risk that this lesion is a more aggressive SCC.

6. Radiotherapy

6.1. Primary definitive radiotherapy

Definitive primary radiotherapy represents a valid alternative and curative treatment strategy to surgery for small cSCCs. RT should be considered as the primary treatment option in patients who are not candidates for surgery (e.g. locally infiltrating cSCC not amenable to surgery, presence of comorbidities, or when patients decline surgery) or in cases when curative surgery is not possible or could be disfiguring or burdened by the poor functional outcome, especially cSCCs located on the face (i.e. eyelid, nose, lip) or large lesions on the ear, forehead, or scalp (Fig. 1).

Prospective randomised trials comparing the effectiveness of primary radiotherapy in terms of local tumour control and patient survival compared to other local therapy modalities are not available. A meta-analysis (2013) of 14 observational studies of radiotherapy for 1018 primary cSCCs reported a pooled average local recurrence rate of 6.4% [11].

Modern radiotherapy represents a versatile treatment modality and depending on tumour and/or patient factors can be delivered as an external beam technique or via brachytherapy (Interventional Radiotherapy, BT, IRT). External beam RT (EBRT) may involve electron

beams or photons. Treatment can be delivered to a small superficial area (e.g. nasal ala) or a large complex volume (e.g. whole scalp or skull base).

The total prescribed dose and fractionation should reflect the differences in radiobiological effectiveness between different radiation modalities. Doses of 60–64 Gy in fractions of 2 Gy for tumours of < 2 cm (or other schedules with equivalent radiobiological dose) and 60–70 Gy in fractions of 2 Gy for tumours of ≥ 2 cm (or other schedules with equivalent radiobiological dose) are recommended. Hypo-fractionated RT (larger dose per fraction) has been shown to have equally high efficacy and could result in better patients' compliance (fewer fractions) [74]. Interventional radiotherapy could also be proposed based on the tumour size and location as an alternative to EBRT.

Radiotherapy is an overall safe procedure, although it may be associated with complications such as an acute radiation-induced dermatitis and chronic onset of depigmentation and telangiectasias. The latter will become more visible over the years, and this must be considered when offering treatment for younger patients. Higher doses per fraction lead to higher rates of late toxicity [75]. Therefore, hypofractionation schedules should be proposed for the elderly, especially frail patients, or when the long-term cosmetic outcome is of lesser importance.

Prescribed doses must encompass all visible tumour plus an appropriate variable margin (clinical target volume), sparing as much as possible of the surrounding healthy structures [76–78]. Irrespective of treatment intent (definitive, adjuvant, palliative), dosimetry and technical considerations should be surveyed by a certified radiation oncologist.

RT may be combined with systemic therapies including immunotherapy, chemotherapy, or targeted therapies (i.e. cetuximab) in more advanced cases.

6.2. Postoperative RT

6.2.1. Definitive postoperative radiotherapy

Definitive postoperative RT should be considered after surgical excision for cSCC with positive margins

Box 8 Primary RT.

Definitive primary RT	Evidence-based recommendation
Grade of recommendation B	Primary radiotherapy should be considered as an alternative to surgery for inoperable or difficult-to-operate tumours or in the absence of consent to surgical excision.
Level of evidence 3	Systematic review/meta-analysis, high risk of bias [11]. Retrospective studies in small numbers and heterogeneous group of patients [79,80]. Strength of consensus: 100%.

RT, radiotherapy.

Box 9 Postoperative RT.

Postoperative RT	Evidence-based recommendation
Grade of recommendation B	Postoperative radiotherapy should be considered after surgical excision for cSCC with positive margins and for which re-excision is not possible.
Level of evidence 3	Meta-analysis (20 observational studies and one randomized phase III study) [48]. Randomized phase III study [96]. Retrospective studies [47,81,97,98]. Guidelines [95]. Strength of consensus: 100%.

(residual microscopic [R1] or macroscopic [R2] tumour) where re-excision is not possible [13,27,81,82]. The recommended dose for postoperative RT is 60–66 Gy in 30–33 fractions, five fractions per week [27,81–83], but in the case of R2, specific considerations should be made according to the size of residual disease.

The majority of studies defining risk factors for local recurrence are restricted to the head and neck area. An international consensus guideline by the Head and Neck Cancer International Group (HNCIG) for the delivery of postoperative RT in the head and neck region was published in 2020 [78]. The guideline from HNCIG also includes a detailed description of the recommended radiotherapy techniques to be used.

6.2.2. Adjuvant radiotherapy

Adjuvant RT refers to RT performed after complete surgical resection of the tumour (R0). Adjuvant RT is offered as part of clinical practice in many medical centres for patients with high-risk cSCC, particularly for tumours with PNI. Current practice is influenced by the standard use of adjuvant RT for mucosal SCC

of the head and neck. However, there is a lack of significant evidence, including randomised controlled trial data, showing a clear benefit of adjuvant RT in this setting [46,79,81,84–88]. An important limitation of most studies on the use of adjuvant RT for primary common cSCC is the fact that they do not specify the results of histological margin assessment or include patients treated with RT for cSCC with positive margins as well as those with negative margins. Recent studies have shown no benefit for adjuvant RT focusing on cSCC with clear surgical margins [89–92]. The meta-analysis of Kim et al. in high-risk non-metastatic cSCC (any high-risk factor present) treated with margin-negative resection (29 retrospective, two prospective, two case series), reported no statistically significant differences in poor outcomes between surgery alone and surgery with adjuvant RT [90]. On the other hand, the meta-analysis of Zhang et al. reported lower recurrence, longer disease-free survival, and longer overall survival with adjuvant radiotherapy, but included primary as well as metastatic cSCC, and the benefit of adjuvant RT may have concerned nodal

Box 10 Adjuvant RT for resected nodal metastatic cSCC.

Adjuvant RT for resected nodal cSCC	Evidence-based recommendation
Grade of recommendation B	Adjuvant radiotherapy following therapeutic lymphadenectomy should be considered in cSCC of the head and neck with regional nodal metastases and extracapsular extension.
Level of evidence 3	Meta-analysis (20 observational studies and 1 randomized phase III study) [48]. Randomized phase III study [96]. Retrospective studies [47,81,97]. Guideline [95]. Strength of consensus: 100%.

Box 11 Adjuvant RT for high-risk cSCC.

Adjuvant RT	Evidence-based recommendation
Grade of recommendation C	Adjuvant radiotherapy may not be offered as standard of care for cSCC with clear surgical margins, as a clear benefit has not been shown.
Level of evidence 3	Retrospective studies [89,91,92]. Meta-analysis [90]. Strength of consensus: 100%.
Grade of recommendation C	Adjuvant radiotherapy may be discussed for cSCC with multiple high-risk factors (BWH T2b/T3) and with clear surgical margins.
Level of evidence: 4	Retrospective study [94]. Strength of consensus: 97%.

metastatic cSCC [93]. Adjuvant RT was associated with a lower risk for locoregional recurrence compared to surgery alone, for cSCC with multiple high-risk factors (at least 2 BWH risk factors) in the study of Ruiz et al. There was no significant effect on the risk for disease-specific death [94].

Regarding nodal metastatic cSCC, adjuvant RT has been recommended for cSCC of the head and neck following lymph node dissection, although it may not be necessary in immunocompetent patients with a single, small cervical lymph node metastasis (< 3 cm) without extracapsular extension. Adjuvant RT can be considered for surgically treated cSCC of the trunk with nodal metastasis following lymph node dissection, although the evidence is less robust compared to cSCC of the head and neck [13,48,95].

7. Adjuvant systemic therapy

There are no solid data to support the use of adjuvant systemic treatment in localised cSCC after R0 resection (clear surgical margins) [96,99–103]. There was no improvement in time to recurrence or time to second primary tumours with adjuvant 13-cis-retinoic acid plus interferon alpha [101]. Adjuvant chemotherapy (oral capecitabine and other systemic cytotoxic drugs) or targeted therapies (EGFR inhibitors) should not be recommended, since robust evidence about efficacy based on survival data is lacking [102]. A small retrospective study in patients with resected high-risk cSCC (majority with clear margins) investigated RT combined with cetuximab (n = 29) or RT alone (n = 39). There were better progression-free survival (PFS) rates for the combination therapy than with RT alone (2-year: 72% versus 53%, 5-year: 66% versus 29%, respectively) [103]. In a recent prospective phase II trial of adjuvant radiotherapy with concomitant cetuximab for high-risk cSCC (T3–4 or ≥N1) of the head and neck after definitive resection (R0 or R1), the 2-year loco-regional control rate was 91.1% and the disease-free survival was 70.8%. These results compared favourably to historical retrospective data of adjuvant radiation alone, holding promise for the treatment of patients at high risk for disease recurrence [104].

Currently, randomised clinical trials in the adjuvant setting with radiotherapy, cemiplimab, and pembrolizumab are ongoing.

8. Neoadjuvant therapy

Neoadjuvant therapy aims to reduce the size of a tumour prior to surgery, so that there is a smaller surgical defect and easier reconstruction. There are a limited number of small studies of neoadjuvant EGFRi therapy [105–108]. A pilot phase 2 study of neoadjuvant cemiplimab in 20 patients reported 70% complete or major pathological responses [109]. A phase 2, multicentre,

non-randomised study in 79 patients with resectable stage II, III, or IV (M0) cSCC evaluated neoadjuvant cemiplimab 350 mg every 3 weeks for up to four doses, before undergoing surgery with curative intent. A pathological complete response was observed in 40 patients (51%), and a pathological major response in 10 patients (13%). The second part of this study allowed for optional adjuvant cemiplimab therapy, adjuvant RT, or observation only and will be reported in the future [62]. A recommendation cannot yet be given on the use of neoadjuvant therapy due to the relatively small sample size and immature follow-up to date. The NCCN version 1.2023 guidelines recommended that neoadjuvant cemiplimab may be considered in patients with nodal metastasis who are considered borderline resectable, unresectable, or for whom surgery may carry a high morbidity [13]. Clinical trials in the neoadjuvant setting are ongoing.

9. Treatment for in-transit metastases

Satellite or in-transit metastases should be removed surgically if the number, size, and location allow complete removal of the metastatic sites. According to a case series, adjuvant radiation therapy can be helpful in such cases [110]. For multiple unresectable metastases on the limbs, amputation used to be a common option; however, currently it is no longer performed as it has no proven impact on the prognosis and several local and systemic alternatives are available to prevent mutilation [110]. Local options include radiotherapy, intralesional chemotherapy (5-fluorouracil, bleomycin, or methotrexate), intralesional recombinant interferon alpha, electrochemotherapy, or isolated limb perfusion [110–114]. Systemic options include oral retinoids, chemotherapy (platin-based regimens), EGFR inhibitors, and anti-PD1 immunotherapy [110,111]. The only systemic drug approved in this setting is the anti-PD1 agent cemiplimab [115] (Fig. 1). Reduction or withdrawal of immunosuppressive drugs should be considered in iatrogenic immunosuppressed patients [110].

10. Systemic treatments for advanced cSCC

10.1. Immunotherapy with checkpoint inhibitors

cSCCs are known to be UV-radiation-driven skin cancers with the highest rate of somatic tumour mutations. The tumour mutational burden (TMB) refers to the number of genetic changes in a cancer cell [116]. The immune system can identify cancer cells and activate an immune response by detecting altered cellular proteins – so called neoantigens – based on these mutations. Therefore, cSCC is of great interest for treatment with immune checkpoint inhibitors. The TMB rate in cancer has been correlated to the response rate of PD1

Box 12 Immunotherapy for advanced cSCC.

Immunotherapy for locally advanced or metastatic cSCC	Evidence-based recommendation
Grade of recommendation B	Patients with metastatic cSCC or locally advanced cSCC, who are not candidates for curative surgery or curative radiation, should receive first-line treatment with a PD-1 antibody*.
Level of evidence 2	Phase 1 and 2 study of cemiplimab. [115,119–121]. Phase 1 and 2 of pembrolizumab. [124,125,127,130]. Strength of consensus: 100%.
* In Europe, cemiplimab is currently the only approved medication, while pembrolizumab and nivolumab are investigated in clinical studies.	

antibody treatment [117]. A relatively high expression of PD-ligand 1 (PD-L1) with immunohistochemistry staining has been reported for cSCC [118]. This high PD-L1 expression may also correlate to the tumour response of PD1-antibodies.

A pivotal clinical trial for cSCC with cemiplimab, a PD-1 antibody, has been reported by Migden and co-workers [115]. In this phase 2 non-randomised clinical trial ('EMPOWER-CSCC-1'), 59 adult cSCC patients with metastases and 78 patients with locally advanced disease who were not candidates for curative surgery or irradiation were treated with 3 mg/kg body weight cemiplimab every 2 weeks for up to 2 years. Another 56 adult patients with metastatic cSCC received cemiplimab with a flat dose of 350 mg every 3 weeks intravenously for up to 1 year. 33.7% of the whole study population had received prior systemic therapy. The end-point of the clinical trial was the response rate assessed by an independent review committee per Response Evaluation Criteria in Solid Tumors (RECIST) 1.1 (for scans) and modified World Health Organisation (WHO) criteria (for photos). This clinical trial was presented at many meetings and received several updates [119–121]. (Table 1). In the final analyses from September 2022 (European Society of Medical Oncology (ESMO) 2022) [122], with a median follow-up of 15.3 months, the following results were obtained for the three groups of the EMPOWER-cSCC-1 trial: Response rate (overall response rate [ORR], complete response [CR], partial response [PR]): group 1 (50.8%, 20.3%, 30.5%), group 2 (44.9%, 12.8%, 32.1%), group 3 (46.4%, 19.6%, 26.8%). Summarising the results of the three groups (n = 193), the response rate is 47.2% including 17.1% complete responses and 30.1% partial responses. The median duration of response is 41.3 months, the progression-free survival is 22.1 months, and the median of the overall survival has not been reached at the data cut-off. A total of 10.4% of patients needed to discontinue the treatment due to adverse events. Most of the adverse events were fatigue, diarrhoea, nausea, and pruritus. There were no new treatment-related adverse events leading to death [122].

Cemiplimab was approved for metastatic and locally advanced cSCC patients, who are not candidates for curative surgery or curative radiation therapy, by the

Food and Drugs Administration (FDA) in September 2018 and by the European Medicines Agency (EMA) in July 2019 (Fig. 1). Later, the EMA requested a confirmatory study for the approved dose of 350 mg cemiplimab. The latest results of this trial (EMPOWER-CSCC-1; group 6) have been presented at the ESMO conference in September 2022 as well [123]. A total of 167 patients with metastatic or locally advanced disease have been treated. 59.9% were metastatic, whereas 40.4% had a locally advanced disease. The median duration of exposure to cemiplimab was 35.7 weeks. After a relatively short follow-up of only 8.7 months, the following results have been released. Overall response rate: 45.1% including 5.5% complete responses. The median progression-free survival was 14.7 months, whereas the duration of response and overall survival have not reached the median yet. 13.9% of the patients discontinued the treatment due to adverse events, and none of the observed deaths were considered to be related to cemiplimab by the investigators. The most frequent adverse events were fatigue (26.1%), diarrhoea (21.2%), and pruritus (21.2%) [123].

Another PD-1 antibody, pembrolizumab, has been investigated in a phase 2 trial (KEYNOTE-629) [124]. However, in this clinical trial, the vast majority of patients have been pretreated with chemotherapy and only a small subgroup was treatment-naïve. One hundred and five locally advanced and metastatic cSCC patients have been included. The objective response rate was 34.3% including 3.8% complete responses. The median progression-free survival was 6.9 months, the median overall survival has not been reached. At 12 months, 60.3% of the patients were still alive. The tolerability was very similar to the phase 2 trial on cemiplimab. The treatment discontinuation rate accounted for 12.1% [124]. A subsequent update on KEYNOTE-629 [125] confirmed the antitumour activity of pembrolizumab in both locally advanced and metastatic cSCC patients and demonstrated no unexpected new safety signals. However, pembrolizumab has not been approved by EMA in Europe, whereas it is FDA-approved since June 2020 for locally advanced and metastatic cSCC patients [125]. Thus, cemiplimab remains the only approved medication in Europe at this point of time (January 2023).

In a systematic review, Keeping et al. performed an indirect comparison on the efficacy of cemiplimab versus other systemic treatments for advanced cSCC in 11 studies (phase 2 study of cemiplimab NCT02760498 (n = 193), seven studies on EGFRi, two trials on pembrolizumab, one trial on platinum chemotherapy [126]). In indirect comparison, cemiplimab versus EGFRi was associated with benefits in overall survival (OS) (hazard ratio (HR) range: 0.07–0.47) and PFS (HR range: 0.30–0.67 in various studies). Cemiplimab versus pembrolizumab showed more benefit in OS (HR range: 0.17–0.52), and in PFS (HR range: 0.49–0.55) with data from KEYNOTE-629 [124], but PFS was not different versus pembrolizumab in the study of Maubec et al. [127]. Cemiplimab was more efficacious in OS versus platinum-based chemotherapy (HR: 0.19, 95% confidence interval (CI): 0.10–0.39), while not statistically different in PFS (HR: 0.66, 95% CI: 0.38–1.16) [128].

Another systematic review and non-randomised comparison analysis by Petzold et al. included 22 studies investigating chemotherapy, targeted therapy to EGF, immune checkpoint blockade (ICB) (cemiplimab, pembrolizumab, nivolumab), and combination therapies. They reported that ICB showed the highest median PFS (9.9 months [8.1–19.9]) and median OS (not reached, [95% CI: 31.5 months-not reached]), compared to chemotherapy (PFS: 3 months, OS: 12.6 months), targeted therapy to EGF (PFS: 4.9 months, OS: 12.7 months), and combination therapies without ICB (PFS: 9.1 months, OS: 18.1 months). The survival benchmark with ICB after 26 months for metastatic cSCC was 70.8% (95% CI: 61.5–81.5) versus 17.1% (9.5–30.8) for chemotherapy and 37.9% (29.5–48.8) for the combination group [129].

10.2. EGFR inhibitors

Overexpression of EGFR has been demonstrated in advanced cSCC [131]. In addition, genetic activation of EGFR by mutations was reported in a small subset of cSCC (2.5%) [132]. Available targeted EGFR inhibitors (EGFRi) include antibody-based inhibitors of the extracellular domain of EGFR (cetuximab, panitumumab) and

small molecule tyrosine kinase inhibitors (TKI), including erlotinib, gefitinib, and lapatinib.

Cetuximab is a chimeric monoclonal antibody that inhibits EGFR by targeting the extracellular domain of the EGFR and by blocking the intracellular signalling via the RAS/MAPK kinase pathway. Cetuximab is the EGFRi mainly investigated for advanced cSCC, while panitumumab has been assessed in a small number of patients [133–135]. Panitumumab alone or in association with radiotherapy in 25 patients, demonstrated a best overall response of 52% in unresectable cSCC, although the prognosis was overall very poor with a median PFS of 6.9 months and a median OS of 10.5 months [135]. The evidence for erlotinib, gefitinib, and lapatinib is very limited [107,136,137].

10.2.1. Cetuximab, chemotherapy, or combination of treatments

Cetuximab is approved for the treatment of locally advanced or metastatic head and neck SCC, in combination with RT for locally advanced disease and with platinum-based chemotherapy for recurrent and/or metastatic disease. Cetuximab has been used off-label, either alone [138–141], or combined with RT or cisplatin, for advanced cSCC in small trials or case series [142–148]. Cetuximab is considered a radiosensitizer, with a synergistic effect in combination with RT [99,149]. A prospective study of 20 patients with lacSCC compared cetuximab alone versus cetuximab combined with cisplatin or RT (60–70 Gy). Combination therapy had higher response rates versus cetuximab alone (disease control rate: 92% versus 50% and response rates 53% versus 33%, respectively). However, there was a short duration of response (OS 11.1 months, PFS 5.7 months) [150]. Prospective studies of treatment with EGFRi are detailed in Table 2. EGFR inhibitors are generally well tolerated compared to standard cytotoxic agents. Most adverse events are cutaneous, dose-dependent and affect aesthetically sensitive areas with a great impact on patient's quality of life. They include a papulopustular/acneiform rash, which usually appears within the first 1–2 weeks of initiating treatment, xerosis, pruritus, and hand/nail toxicity [138].

Box 13 EGFR inhibitors.

Evidence-based recommendation	
Grade of recommendation: C	Cetuximab may be used for patients with locally advanced and metastatic cSCC, who have failed to respond or are intolerant to immunotherapy. Cetuximab combined with RT is favoured over cetuximab monotherapy.
Level of evidence: 3	Small number of patients in prospective studies [141,150]. A small number of patients with metastatic cSCC treated [138,142,143,150,157,158]. Only two prospective non-randomized study in a small number of patients [147,150]. Small number of patients from retrospective studies [143,144,148,158]. Strength of consensus: 100%.

Cetuximab may be used in patients with contraindications or non-responders to anti-PD-1 (cemiplimab), favouring its combination with chemotherapy or RT (Fig. 1). Ongoing clinical trials are investigating the combination of EGFRi and immunotherapy or different EGFRi to re-stimulate the antitumour immune response in patients with cSCC refractory to PD-1 inhibitor therapy [151].

Currently, there are no systemic chemotherapies approved for advanced cSCC patients. Data on chemotherapeutic agents (e.g. platinum agents, 5-fluorouracil, bleomycin, methotrexate), used either as monotherapy or polychemotherapy for the treatment of advanced cSCC, are weak and inconsistent and are limited by the small number of treated patients, heterogeneity of treatment regimens, and different outcome assessments [148,152–157]. Platinum-based therapy has been used as one of the standard chemotherapeutic options in the management of advanced cSCC [126,138]. A systematic review of mcSCC reported 60 cases treated with cisplatin monotherapy published from 1989 to 2014, underlying the paucity of data [138]. A complete response was described in 22% and partial response in 23% of patients, resulting in an overall response of 45%. The median disease-free survival for patients who attained a complete response was 14.6 (range 3–112) months [138]. Polychemotherapies

seem more effective than monochemotherapy but result in more side-effects and poor tolerance, particularly in the elderly population that characterises advanced cSCC. In general, responses are mostly short-lived, are followed by rapid recurrence, and do not lead to a curative effect. In general, monochemotherapy should be preferred while polychemotherapy should be reserved for cases requiring more aggressive management. A German retrospective study investigated chemotherapy and EGFRi for advanced cSCC in 59 patients with metastatic or locally advanced cSCC. During median follow-up of 52 weeks, the overall response rate was 14.3%, and the disease control rate was 53.6%. Median progression-free survival was 15 weeks. The authors concluded that although chemotherapy and/or cetuximab showed limited outcomes in advanced cSCC, such therapy may be an option when anti-PD-1 treatment is contraindicated [158].

10.3. Electrochemotherapy

Electrochemotherapy (ECT) exerts its antitumour effect through the ability of high-voltage electric pulses to increase the permeability (electroporation) of the cell membrane allowing intracellular access of chemotherapeutic drugs (bleomycin or cisplatin) that otherwise would not be able to penetrate the cell effectively [159,160]. ECT has

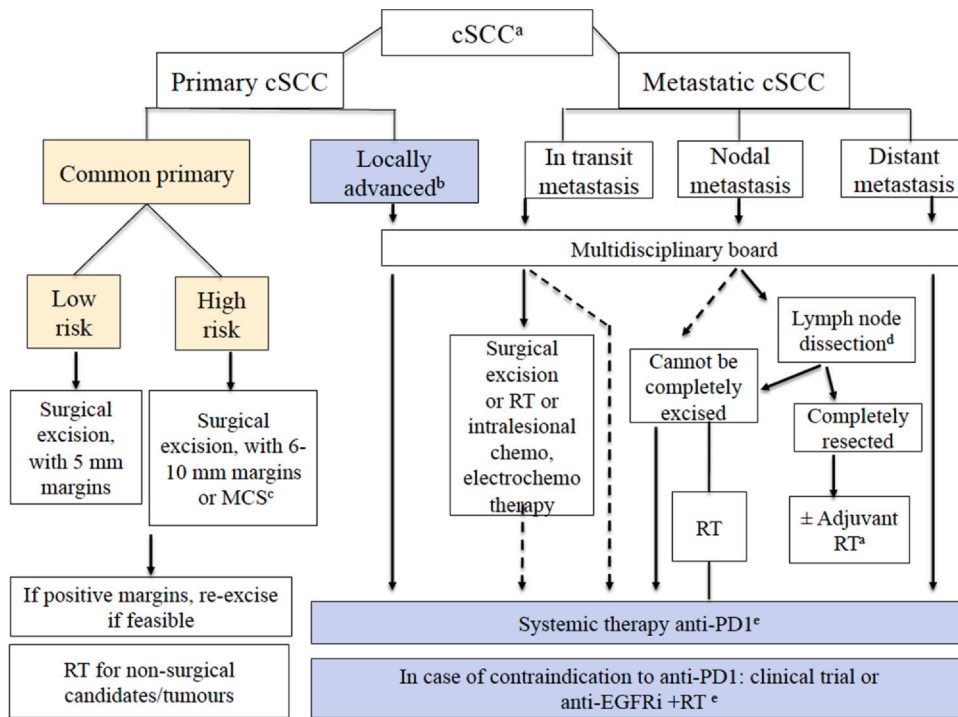


Fig. 1. Proposed treatment algorithm for patients with cSCC. Strength of consensus: 90%. ^aFor detailed indications and recommendations of treatment, refer to the relevant section text in the Guidelines. ^bLocally advanced by definition not amenable to curative surgery or RT. ^cMicrographically controlled surgery instead of sectional assessment is advised, when available. ^dLymph node dissection as indicated. ^eIn Europe, all systemic treatments are off-label, except for the anti-PD-1 agent cemiplimab that is approved by EMA for patients with locally advanced or metastatic cSCC who are not candidates for curative surgery or curative radiotherapy. cSCC, cutaneous squamous cell carcinoma; MCS, micrographically controlled surgery; RT, radiotherapy.

been used in patients with lacSCC, or with persistent or recurrent primary cSCC lesions when all other treatment options, including surgery and radiotherapy, failed or were not feasible, if the patient refused any other treatments, and as palliative care to relieve symptoms. Advantages include a favourable response, particularly in small (<3 cm) and non-ulcerated tumours [161], low toxicity, and preservation/improvement of quality of life. However, there is limited evidence on the duration of local control and progression-free survival, as a short follow-up is reported. In a European study of ECT with bleomycin, the overall response rate in 156 patients with cSCC was 80%, and the complete response was 63%. The limitation of this study was a short follow-up of 45 days due to the palliative treatment setting [162]. In the InsPECT registry study, 162 patients with primary, recurrent, or lacSCCs, were treated with ECT with bleomycin. Local response after 45–90 days of follow-up, included CR in 62% of patients, PR in 21%. At a mean follow-up of 8.6 months, 48.1% had no evidence of disease. The progression-free survival was significantly lower for locally advanced compared to primary patients [163]. Another study from the InsPECT registry evaluated the ECT for skin cancers or cutaneous metastases in 61 elderly patients (>90 years), who represent a very frail population. After ECT, the objective response in patients >90 years was comparable to that observed in younger patients. These elderly patients were managed with local/locoregional rather than general anaesthesia [164].

11. Clinical trials

11.1. Trials with cemiplimab or pembrolizumab

11.1.1. Neoadjuvant trials

A neoadjuvant trial on cemiplimab for stage II–IV cSCC patients (REGN-ONC-1901) was presented for the first time at ESMO 2022 and subsequently published [165]. In this clinical trial, 79 patients from Australia, Germany, and the US with a median age of 73 years received four cycles of cemiplimab with a conventional dose (350 mg every 3 weeks intravenously) followed by conventional surgery. The end-point of the clinical trial was the number of pathologically confirmed complete responses (pCR) after a full resection of the tumour-containing area. Fifty-six percent of the patients showed no viable tumour cells, another 12.7% a major pathological response with 1–10% viable tumour cells. The pCR rate is clearly different compared to the radiological response rates (ORR: 68.4%, CR: 6.3%), which underestimate the magnitude of the cemiplimab benefit. There was one treatment discontinuation and four deaths (three unrelated to treatment by the investigator) during the trial. There was no correlation between the tumour mutational burden and the pathological response rate. There was a strong correlation between PD-L1 expression ($\geq 1\%$) with pCR. 3/15 patients with PD-

L1 < 1% demonstrated a pCR in contrast to 22/41 patients with PD-L1 $\geq 1\%$. However, these results did not reach statistical significance.

Neoadjuvant cemiplimab appears as a very attractive alternative to immediate surgery. However, neoadjuvant cemiplimab treatment is not yet approved by FDA or EMA.

11.1.2. Adjuvant trials

Cemiplimab is currently tested in an adjuvant clinical trial (REGN-1788, NCT03969004) in patients with cSCC at high risk of relapse. This trial ('C-POST') is a randomised, placebo-controlled, double-blind, multicentric phase 3 trial comparing cemiplimab to placebo after surgery and postoperative radiation. Cemiplimab is initially used with the dose of 350 mg 3-weekly for 12 weeks followed by 700 mg 6-weekly for 36 additional weeks. The end-point of the trial is disease-free survival.

A very similar clinical trial of pembrolizumab in the adjuvant setting (KEYNOTE-630, NCT03833167) is still actively recruiting patients. Patients with cSCC at high risk for recurrence are randomised after conventional surgery and postoperative radiation to either pembrolizumab with 400 mg intravenously every 6 weeks or matching placebo for 1 year. The end-point of this clinical trial is also disease-free survival.

11.1.3. Intralesional cemiplimab

A pilot phase 1 study on the intralesional use of cemiplimab was presented in May 2022 (Migden MR et al., 54th Annual Meeting of the American College of Mohs Surgery, Philadelphia, May 2022; NCT03889912). In this dose-finding study on cSCC patients with mainly skin metastases, 250 μ L per lesion with doses of 5–44 mg of cemiplimab were intratumorally applied for consecutive 12 weeks, before definitive surgery was scheduled. A total of 17 patients with a median age of 76 years and a predominance of primary cSCC on the head and neck region (76%) have been included. Responses have been found at all dose levels. 13/17 cSCC patients (76.5%) showed a complete response (pCR). Only one patient on the highest cemiplimab dose level needed to discontinue the study treatment due to adverse events. There was no treatment-related death. Pruritus (23.5%) and fatigue (17.6%) were the most common observed adverse events. The intralesional use of cemiplimab appears as an attractive alternative to conventional intravenous cemiplimab in selected patients, although it is not yet approved by the FDA or EMA.

11.1.4. Oncolytic vaccines

A new field of immunotherapies for advanced cSCC is the introduction of oncolytic vaccines with or without immune checkpoint inhibitors. Most oncolytic vaccines are administered intratumorally to superficial and/or deep cutaneous, subcutaneous, or visceral lesions, many via ultrasound or computer tomography guidance. They

have been shown to be potent drugs acting by direct local killing of tumour cells and/or altering the tumour microenvironment. They aim to turn immunologically 'cold' tumours with low numbers of tumour-infiltrating lymphocytes into 'hot' tumours, which are more sensitive to a systemic antitumour immune response. A randomised phase 3 trial used an oncolytic, genetically modified herpes simplex type I virus (CERPASS, RPL-002–18, NCT04050436) in 180 advanced cSCC patients fully recruited by August 2022. This trial on a head-to-head comparison of conventional cemiplimab to cemiplimab plus RP1 (oncolytic vaccine) has not released data, as of September 2022.

The same oncolytic virus (RP1) is currently being used in anti-PD-1-naïve non-melanoma skin cancers (NMSC) including cSCC and also PD-1-failed patients (IGNYTE, RPL-002–16, NCT03767348) [166]. In PD-1-refractory patients, RP1 is combined with the PD-1 antibody nivolumab, and the first data were released at ASCO 2022. Of 15 patients with cSCC who have been treated with this combination 46.6% (n = 7) demonstrated a complete response and two (13.2%) a partial response. The median duration of response has not been reached.

11.1.5. Combination of immunotherapy with EGFRi

Two trials focus on the combination of PD-1/PD-L1 antibodies and EGF-receptor inhibitors. The I-TACKLE trial (NCT03666325) included 43 patients with an advanced SCC. 16% of patients had received prior chemotherapy and 49% prior radiotherapy [167]. The patients received pembrolizumab 200 mg every 3 weeks as first-line immune therapy and were switched upon progression to a combination of pembrolizumab with weekly cetuximab 250 mg/m². 44% of patients had an objective response to pembrolizumab (CR: 12, PR: seven) of which four (21%) had a subsequent relapse. Two of these patients were treated with pembrolizumab/cetuximab and both patients achieved a partial response. 56% did not achieve an objective response on first-line pembrolizumab (eight SD, 15 PD) and 21/23 patients received subsequent treatment with pembrolizumab/cetuximab. Eight patients (38%) achieved an objective response (CR: three, PR: five) while 61% did not (SD: eight, PD: five).

A clinical trial of the Alliance for Clinical Trials in Oncology in collaboration with the National Cancer Institute (NCI) is currently treating advanced cSCC patients with the PD-Ligand 1 antibody avelumab with and without cetuximab (NCT03944941). No data have been reported from this trial, as of September 2022.

11.1.6. Other trials

The cemiplimab survivorship and epidemiology (CASE, NCT03836105 [168]) trial is a prospective study on the safety and efficacy of cemiplimab in patients with advanced cSCC in the real-world setting. An interim result

on 196 patients with a median age of 76 years has been released at ESMO 2022 [169]. Most patients suffered from locally advanced cSCC (63.3%), and the others from metastatic cSCC (36.7%). 42.9% received prior radiation therapy, 75% prior surgery, and 45.4% prior systemic therapy, before they were included in the CASE study. The response rate of 37.4% included 9.8% complete responses. The disease control rate (DCR) was 54.6%. Only five patients (2.6%) needed to discontinue the treatment due to serious adverse events, one patient died due to treatment-related pneumonitis.

An international, observational, two-cohort, multi-centre study ('CEMISKIN') with a prospective and retrospective cohort is currently ongoing in Germany, Austria, and Switzerland. Roughly 70 study centres are including patients with cemiplimab treatment for advanced cSCC. This non-interventional study (NIS) has a target of a total of 400 patients (200/cohort). The goal is to assess the efficacy and tolerability of cemiplimab in a real-world setting.

Rigosertib, a polo-like kinase 1 (PLK1) inhibitor, is being assessed in a phase II, open study in patients with recessive dystrophic epidermolysis bullosa associated with locally advanced/metastatic cSCC. (EudraCT No.:2016-003832-19).

12. Considerations of treatment in immunocompromised patients

There is limited evidence from randomized controlled trials and non-randomised studies to guide the management of cSCC in immunocompromised patients. Close dialogue and multidisciplinary decision-making shared between patients, dermatologists, oncologists, surgeons, transplant clinicians, and other relevant health care professionals are essential [170,171].

12.1. Primary cSCC

There is little prospective, randomised evidence to suggest that primary cSCC in immunocompromised patients requires significantly different management approaches to the general population [172,173]. However, given the increased risk and potentially atypical presentation and worse outcomes in immunocompromised patients, the index of suspicion for possible cSCC should be high, thresholds for biopsy correspondingly low [170,174,175] and confirmed cSCC should be considered 'high risk' for the purposes of management decisions (Stratigos 2023 part 1) [2,176,177].

Surgery: It is usually recommended that high-risk cSCC in immunocompromised patients requires more aggressive surgery, but optimal excision margins and the role of MMS/intraoperative margin assessment are not clearly established [170,173,178,179]. Few data exist on postoperative complications rates, including infection

and the need for prophylactic antibiotics [180]. Sir-olimus appears to be associated with more frequent surgical dehiscence, but this does not usually justify its discontinuation before surgery [178,181].

Radiotherapy: Although radiotherapy is not the first therapeutic option for most primary cSCC, particularly as immunocompromised patients are often younger and may develop multiple primary cSCC within an anatomic site, precluding its subsequent use at that site, it nonetheless remains an important option when surgery is not appropriate [178].

12.2. Locally advanced (LA) and metastatic cSCC (mSCC)

In immunocompromised patients with advanced cSCC, there are specific considerations regarding the use of checkpoint inhibitors, chemotherapy, and EGFR inhibitors compared with immunocompetent patients and the additional strategy of immunosuppression modification in some cases [170,178,182]. Regarding conventional chemotherapy, transplant-directed dosage adjustment, close monitoring of allograft function, and potential interactions with drugs such as calcineurin inhibitors and antiretroviral medications are important considerations in immunocompromised patients [182]. Information on the use of anti-EGFR inhibitors such as cetuximab is limited to case reports [183–185]. Relevant complications include neutropenia, infection, liver dysfunction [182], and fatal pulmonary toxicity has been reported in lung transplant recipients treated with cetuximab [186].

Pivotal clinical trials of anti-PD1 immune checkpoint inhibitor immunotherapy (ICI) excluded immunocompromised individuals [115,124] and information on their safety and efficacy in these patients is restricted to case reports and retrospective series and a single phase I study [187]. Experience to date has been mainly in immunocompromised patients with melanoma, but increasing data are now available for cSCC [188–197]. No consensus guidelines exist for the use of ICI in immunosuppressed patients, and this should be considered on a case-by-case basis in multidisciplinary consultation with the patient and their healthcare team. Key considerations include the high risk of allograft rejection in organ transplant recipients (OTRs), the type of allograft and the options for replacement therapy should the allograft fail, and the possibility that treatment efficacy may be reduced by immune compromise. However, based on current knowledge, it has been proposed that ICIs should be offered to kidney transplant recipients with advanced cSCC if surgery and/or radiotherapy have failed and should be first-line ahead of chemotherapy and targeted therapies [198].

The PD1 pathway is critical in maintaining allograft tolerance. In OTRs and PD1-blockade increases the risk of allograft rejection [188]. ICI immune-related adverse

events may affect graft function and immunosuppressive drugs may reduce the effectiveness of ICI therapy [198]. Data from approximately 40 OTRs with metastatic cSCC have been reported to date: disease control rates range from 30% to 50%, with graft rejection in approximately 40% [188–193,195–202]. In all cases, parallel management of immunosuppression is likely to play an important role in ICI responsiveness [198]. Reducing the risk of rejection by reducing or discontinuing immunosuppression or converting to mTOR inhibitors is uncertain and has been questioned in melanoma [203]. There is some evidence that in metastatic cSCC it could be considered, as could the use of peri-infusional steroids [197,201,204,205] and on the basis of current evidence, it has recently been proposed that a dual immunosuppressive regimen is maintained before ICI initiation by combining mTOR-inhibitors and either corticosteroids or calcineurin-inhibitors [198]. This must be considered in the context of allograft risk (rejection and its subsequent treatment) and risk of tumour progression. Ultimately, a multidisciplinary approach should underpin all such clinical decision-making. Encouragingly, even after graft rejection due to ICI therapy, successful re-transplantation has been reported [206]. PD1 blockade for metastatic cSCC has also been reported in people living with HIV and in patients with haematological malignancies, although in the latter group, disease control rates appear to be lower [194].

Prospective trials are now critically important to further establish the efficacy and safety of ICIs in immunocompromised patients and several are underway (NCT04339062; NCT03816332). Further challenges for the future include understanding how to uncouple alloreactive immunity from anti-tumour immunity, biomarker identification for immunocompromised patients likely to benefit from ICI therapy, and biomarkers for early detection of allograft rejection [198].

12.3. Pre-transplant cSCC and re-transplantation after cSCC

Patients with a history of pre-transplant cSCC are increasingly common [174]. Consensus guidelines from the International Transplant Skin Cancer Collaborative based on risk and kinetics of cSCC metastasis recommend that no waiting time is required for transplantation after a low-risk cSCC and 2–4 years for high-risk cSCC, depending on the status of perineural invasion and other risk factors; 5 years waiting time is recommended for cSCC with nodal metastasis and transplantation is almost always contraindicated for distant metastasis [170,174]. However, this is a rapidly changing landscape as more effective treatments for advanced cSCC become available [206]. The time to first cSCC is much shorter in OTRs with pre-transplant cSCC and similar to the interval between first and second cancers in those without pre-transplant cSCC [207]. The role of

mTOR inhibitor-based maintenance immunosuppression and chemoprevention with systemic retinoids in reducing this risk is uncertain, but close surveillance is indicated [207]. For OTRs with a history of post-transplant cSCC being considered for re-transplantation, the observed increased risk of developing aggressive cSCC after a second transplant also needs to be considered [208].

13. Best supportive care

Although treatment options continue to expand for cSCC, there is still a group of patients that cannot be cured and is often left with a growing, ulcerated tumour. Initially, palliative treatments like local surgery, RT, or electrochemotherapy can be deployed to try to control tumour extension and relieve symptoms [209]. RT is often used to relieve pain, stop haemorrhage, and to confine tumour expansion in functional areas like the eye or the facial nerve [210]. Hypo-fractionated schemes (24–35 Gy in 3–6 fractions) or single dose (16–20 Gy) can be applied depending on the location of the tumour, the performance status (physical and mental fitness) of the patient [210,211].

If no further (palliative) treatments are desired or possible, the focus of care is on quality of life. The patient should be consulted about his/her individual wishes, needs, and values. Supportive care includes wound care and pain management, nutritional, and psychological support. Consultation with a palliative care team is advised [212].

Quality of life can seriously be affected by pain and should therefore be thoroughly tackled [213]. The ladder of the World Health Organisation is a helpful tool for adequate pain management [214]. Paracetamol or non-steroidal anti-inflammatory drugs are first-step pain relievers, followed by opioids. Application of morphine gel can be of help in smaller wounds [215,216].

To prevent malodour, the tumour should be rinsed daily with tap water or a disinfectant solution that contains sodium chloride solution of 0.9% or povidone iodine in a 2% or 10% solution [217]. Silver and honey dressings are effective in reducing malignant fungating wound discharge and malodour [218]. Topical metronidazole or oral metronidazole (250 mg, three times a day for 7–10 days) may also be considered [219]. Maceration of the surrounding skin of the tumour because of exudate can be prevented by

applying zinc oxide paste or silicone gel on the surrounding skin. Slight bleeding can temporarily be stopped by the application of calcium alginate dressings, dressings with xylometazoline or adrenaline (1:1000) or silver nitrate [219].

The Society of Integrative Oncology-ASCO guideline 2022 has provided evidence-based recommendations on integrative approaches to managing pain in patients with cancer, including massage, acupuncture, reflexology, or acupressure [220].

14. Follow-up

The prediction and identification of high-risk cSCC patients that require strict surveillance are major issues in cSCC management due to the lack of clinically relevant biomarkers or a staging system with a reliable high predictive value [221,222]. A recent systematic review revealed significant inconsistency in the guidelines on follow-up of patients with cSCC and pointed towards the need of randomised clinical trials [223].

cSCC typically affects elderly patients with multiple co-morbidities, Eastern Cooperative Oncology Group status commonly > 1 and often associated with multiple tumours at different stages in the progression of keratinocyte skin cancer. Thus, the aims of follow-up in this special cohort of geriatric-oncologic patients differ in some aspects from other types of cancers [7]. Certainly, aims of follow-up of patients affected by high-risk cSCC included early detection of recurrence (both locally and distant) and secondary cancers, clinically and radiographic assessment of response to treatment, evaluation of side-effects of medical treatment and education of patients and relatives. However, it should additionally include the validation of the need of alternative, contemporary treatments especially for patients with severe field cancerization and multiple primary cSCCs or for OTRs [224,225], and assessment of frailty, quality of life and life expectancy [226].

14.1. Definition of high-risk tumours/patients

Different staging systems and criteria have been employed to define high-risk cSCCs, and are detailed in Part 1 of the guideline.

Box 14 Follow-up.

Consensus-based recommendation

- GPP
- cSCC patients shall be followed up for recurrences and development of new NMSC and melanoma.
 - Follow-up in all patients shall include regular clinical examination, including inspection of the entire skin and inspection and palpation of the excision site, the in-transit route and the regional lymph nodes, and advice on self-skin examination.
 - Frequency of follow-up visits and imaging depends on underlying risk characteristics for cSCC patient: low-risk or high-risk common primary, advanced or regional disease, immunosuppression setting (detailed in Table 3).
- Strength of consensus: 100%.

Table 1

Response outcomes of prospective trials of anti-PD-1 therapy currently approved in Europe for the treatment in curative intent for advanced cSCC published from 2000 till 1 November 2022: Anti-PD-1 agent cemiplimab.

Study	Trial design, median follow-up	Patients N	cSCC type	Treatment schema	Response	Survival
Migden, 2018 [115]	Phase 1, open-label, multicentre 11 months	26	10 La 8 regional metastasis 8 distant metastasis	Cemiplimab 3 mg/kg IV every 2 weeks	Best ORR 50% 13 PR	Not reported Median duration of response: not reached
Migden, 2018 [115]	Phase 2, non-randomised, global, pivotal study (Group 1) 7.9 months	59	14 regional metastasis 45 distant metastasis	Cemiplimab 3 mg/kg intravenously every 2 weeks	Best ORR 47.5% 4 CR 24 PR	1-year OS: not reached (estimated 81%) 1-year PFS: not reached (estimated 53%) Median duration of response: not reached
Rischin, 2020 [119]	16.5 months				Best ORR 49% 10 CR 19 PR	Median PFS not reached Median duration of response: not reached
Rischin, 2021 [120]	18.5 months				ORR: 51% 12 CR 18 PR	Median duration of response: not reached
Rischin, 2020 [119]	Phase 2, non-randomised study of the approved fixed-dose regimen (Group 3) 8.1 months	56	12 regional metastasis 43 distant metastasis	Cemiplimab 350 mg intravenously every 3 weeks	Best ORR 41% 3 CR 20 PR	Median PFS not reached Median duration of response: not reached
Rischin, 2021 [120]	17.3 months				ORR: 42.9% 9 CR 15 PR	Median duration of response: not reached
Migden, 2020 [121]	Phase 2, non-randomised, global, pivotal study (Group 2) 9.3 months	78	78 La	Cemiplimab 3 mg/kg intravenously every 2 weeks	ORR 44% CR 13% PR 31%	1-year DFS: 87.8% Median duration of response: not reached
Rischin, 2021 [120]	15.5 months				ORR: 44.9% 10 CR 25 PR	Median duration of response: not reached

CR, complete response; DCR, disease control rate (CR + PR + SD); DSS, disease-specific survival; m, months; ORR, overall response rate (CR + PR); OS, overall survival; PD, progressive disease; PFS, progression-free survival; PR, partial response; SD, stable disease; w, weeks.

Table 2

Response outcomes and dosing regimens of prospective studies of EGFRi for treatment of advanced cSCC published from 2000 till 1 November 2022.

Reference	Trial design	Patients N	cSCC type	Treatment regimens	Response	Survival
Anti-EGFR antibodies						
Maubec, 2011	Phase II open-label, uncontrolled, multicentre trial	36	33 unresectable 3 metastatic	Cetuximab Initial dose of 400 mg/m ² followed by weekly doses of 250 mg/m ² for at least 6 w	ORR: 28% DCR: 69% 2 CR 8 PR	Mean OS: 8.1 m Median PFS: 4.1 m
Preneau, 2014	Open label, single-centre, non-randomised	20	La	6 Cetuximab Initial dose of 400 mg/m ² followed by weekly doses of 250 mg/m ² 9 Cetuximab as above + Carboplatin 300 mg/m ² monthly 5 Cetuximab + RT Cetuximab as above, RT: 60–70 grey	ORR: C: 33% C-C: 37.5% C-RT: 80% DCR: C: 50% C-C: 87.5% C-RT: 100%	OS: 11.1 m C: 2.5 C-C: 5.6 C-RT: 3 PFS: 5.7 m C: 1.3 C-C: 2.8 C-RT: 1.6
Joseph, 2018	Single-centre	8	Inoperable	Cetuximab + RT Cetuximab at Initial dose of 400 mg/m ² 7 days prior to RT, followed by weekly doses of 250 mg/m ² for the duration of RT	6 CR 1 PR 1 PD	2-y PFS: 83.3% 2-y SSS: 87.5%
Foote, 2014	Phase II, uncontrolled, single-centre trial	16	14 la 2 metastatic	Panitumumab 6 mg/kg every 2 weeks for a maximum of 9 cycles	ORR: 31%	Median OS: 11 m Median PFS: 8 m
EGFR tyrosine kinase inhibitors						
William, 2017	Phase II, uncontrolled	40/37 evaluable	27 locoregionally recurrent 4 la 9 metastatic	Gefitinib 250 mg/day orally	ORR 16% ORR in mcSCC: 0 DCR 51%	Median OS: 12.9 m Median PFS: 3.8 m
Gold, 2018	Phase II, uncontrolled, single-centre	29	Locoregionally recurrent or metastatic cSCC	Erlotinib 150 mg/day orally (dose reduction management specified in the study)	ORR 10% DCR 72% 3 PR, 18 SD, 8 PD	Median OS: 13 m Median PFS: 4.7 m

C, cetuximab monotherapy; C-C, cetuximab combined with carboplatin; CR, complete response; C-RT, cetuximab combined with radiotherapy; cSCC, cutaneous SCC; DCR, disease control rate (CR+PR+SD); la, locally advanced; m, months; mcSCC, metastatic cSCC; ORR, overall response rate (CR+PR); OS, overall survival; PD, progressive disease; PFS, progression-free survival; PR, partial response; SD, stable disease; SSS, scc-specific survival; w, weeks.

14.1.1. Risk assessment for local recurrence

Based on current available literature, the highest risk for local and distant recurrence appears within the first 2 years after diagnosis of a primary cSCC [227]. First site of metastatic spread appears in the lymph node, thus follow-up both clinically and radiologically should focus on these sites. Special attention is required for patients with immunosuppression such as haematological comorbidities or iatrogenic immunosuppression (OTR or others), who were reported to develop regional lymph node metastases 6.7 months after diagnosis of the primary tumour [228].

14.1.2. Risk assessment for distant metastases

In a large study evaluating 3455 tumours in 2522 patients, 116 (4.5%) patients developed nodal metastasis and 26 patients with nodal disease developed radiologically confirmed distant metastasis. The mean time to first nodal metastasis were 0.83 (1.29) and 0.98 (1.18) years, and 26 of 105 (24.8%) and eight of 26 (31%) patients were immunosuppressed. In total, 103 of 105

patients (98.1%) with nodal disease received therapy (surgery, radiotherapy and/or chemotherapy) aimed at treating nodal disease. Eighteen of 26 patients (69%) developed distant metastases following previously adjuvant treated isolated nodal disease surveillance, while eight of 26 (31%) had concomitant nodal and distant metastatic disease at follow-up, with subsequent confirmation of cSCC as the metastasis source [227].

14.1.3. Risk assessment for multiple tumours

Patients with multiple cSCCs are at higher risk for nodal disease and local recurrence. Thus, patients with multiple tumours (> 2–10 tumours) would benefit from close surveillance programs, especially when associated with immunosuppression [229].

14.1.4. Risk assessment in immunocompromised patients

Solid organ transplant recipients (SOTRs) have a 100-fold increased risk of cSCC, and they may develop more aggressive cSCCs compared with immunocompetent individuals. It has been shown that close dermatological

surveillance along with field-related treatments may reduce an aggressive course of disease [230].

The dilemma in providing clinically relevant and reliable evidence-based follow-up guidelines for cSCC are related to the lack of studies evaluating the heterogeneous characteristics of patients affected by cSCC.

15. Communication with the patient

When diagnosing common primary cSCC, the clinician will need to give information about the type of cSCC diagnosed and the risk of relapse or metastasis. Patients should be reminded that most cSCCs are well-differentiated tumours, which have a low risk of recurrence and/or metastasis. Patients may need support from clinical nurse specialists in cases of disfiguring surgery or the delivery of bad news and need to be offered access to support services when deemed necessary. Self-examination should be discussed for the diagnosis of new primaries and detection of lymph nodes in the draining basins.

Patients with SCCs should also be informed of different treatment modalities, and these need to be discussed when appropriate with the patient/family/caregiver. The potential consequences of foregoing treatment should also be explained. Patients should be made aware that radiotherapy could not be the best treatment option in young age groups as radiotherapy scars could worsen over time and there is a risk of secondary malignancies, although it is very low.

Surgery for high-risk tumours should not be less than optimal in elderly patients as the consequences of not offering optimal treatments in a timely manner may lead to difficult tumours to manage with subsequent morbidity and possible impact on mortality. However, it is important to consider the patient's morbidities and treatments options are always discussed with the patient, their family, or carers even after multidisciplinary discussions.

An information leaflet should be provided giving facts about SCCs and these tumours are the second most common skin cancer after basal cell carcinomas. Risk factors should be explained such as chronic sun exposure, genetic and host factors such as fair skin, immunosuppression, or the presence of syndromes with increased susceptibility to skin cancers such as xeroderma pigmentosum and albinism. In patients with cSCCs and family history of uterus and/or bowel cancer, clinicians should discuss genetic counselling and testing for DNA mismatch repair genes to rule out Lynch or Hereditary Non-Polyposis Colon Cancer (HNPCC) syndrome. If the gene mutation is confirmed, the patient will be offered colon and uterus cancer screening, and it is important that these patients are managed by cancer geneticists and other specialists.

Patients may have different types of follow-up schedules depending on age, location of tumour, histological subtype, previous primaries, recurrences, and other host

Table 3
Consensus-based proposal for follow-up schedule for patients with history of cSCC proposed by EADO-EDF-ESTRO-UEMS-EORTC.

Year of follow-up	Clinical/physical examination					Ultrasound of lymph nodes or parotid gland					CT, MRI, PET/CT				
	1	2	3-5	6+		1	2	3-5	6+		1	2	3	4+	
cSCC	12 m	12 m	-	-	-	-	-	-	-	-	-	-	-	-	-
Low risk	3-6 m	3-6 m	12 m ^b	12 m ^b	3-6 m	3-6 m	3-6 m	3-6 m	3-6 m	3-6 m	3-6 m	3-6 m	3-6 m	3-6 m	3-6 m
High risk ^a	3 m	3 m	3 m	6-12 m	3-6 m	3-6 m	3-6 m	6-12 m	6-12 m	6-12 m	3-6 m	3-6 m	3-6 m	3-6 m	3-6 m
lacSCC or mcSCC															
IS ^c															
	Every 3-6 m lifelong + according to the characteristics of cSCC					According to the characteristics of individual cSCC					According to the characteristics of individual cSCC				

Follow-up will also depend on individual symptoms and response to treatment. Consensus: 100%.

CT, computed tomography; EADO, European Association of Dermato-Oncology; EDF, European Dermatology Forum; ESTRO, European Society for Radiotherapy and Oncology; EORTC, European Organisation for Research and Treatment of Cancer; IS, immunosuppressed; lacSCC, locally advanced cutaneous squamous cell carcinoma; mcSCC, metastatic cSCC; m, months; MRI, magnetic resonance imaging; PET, positron emission tomography; UEMS, European Union of Medical Specialists.

^a High-risk cSCC patient as defined by EADO guidelines (Stratigos et al. Part 1). As the independent prognostic effect of high-risk factors has not been consistently studied, an individual risk assessment is advised to guide follow-up decisions.

^b Based on individual risk factor profile.

^c OTR, chronic lymphocytic leukaemia or with xeroderma pigmentosum.

factors such as immunosuppression. The risk of recurrence should be discussed taking account of the tumour characteristics and other risk factors. Patients should be advised how to perform self-examination. For immunosuppressed patients, it is recommended that patients are followed up for life, ideally in dedicated clinics with experience in the management of these complex patients. Patients will also need advice about sun protection and how to use treatments for field cancerization at home with topical products if appropriate.

A qualitative study looked at the needs and preferences of patients with cSCC regarding treatment and follow-up care: Patients mentioned that clear information on self-inspection would reduce the need for follow-up visits and that they wished information preferably on paper. Patients preferred periodic follow-up visits with a possibility to come in-between visits in case of suspicious new lesions and believed it was too hard to self-detect cancer or make self-skin examination of the whole body [231].

Summarising box of recommendations

Practice points	Recommendation	GOR
1. Surgical excision of primary cSCC	Surgical excision with histological control shall be performed as standard treatment. The aim of cSCC surgery shall be a complete excision (R0) with histological confirmation of peripheral and deep excision margins. Large tumours or tumours on the head and neck can undergo a punch or incisional biopsy for histological confirmation and planning of a subsequent complete excision. In cases of positive margins, a re-excision shall be done, for operable cases.	A
2. Surgery and safety margins	Low-risk cSCC should be excised with a clinical safety margin of 5 mm. cSCC with high-risk factors should be excised with a clinical safety margin of 6–10 mm or by micrographically controlled surgery. Micrographically controlled surgery should be considered for cSCC in functional/cosmetical sensitive areas.	B
3. Wound closure	As long as an R0 resection is not histologically confirmed, wound closure with local tissue movements (flaps) should be avoided.	GPP
4. Therapeutic lymph node dissection	A regional therapeutic lymph node dissection should be performed in patients with lymph node metastasis detected clinically or by imaging tests and confirmed with cytology or biopsy. The extent of surgical resection is determined by the surgeon in collaboration with the multidisciplinary tumour board.	B
5. Elective lymph node dissection for N0 cSCC	Elective lymph node dissection shall not be performed for N0 cSCC.	X
6. Elective neck lymph node dissection for mcSCC to the parotid	Elective neck dissection may be discussed and offered for metastatic cSCC within the parotid.	C
7. Destructive modalities for cSCC	Destructive modalities such as ED & C, cryotherapy, PDT, and lasers should not be performed in the treatment of primary invasive cSCC. Exceptions can be considered in small-sized and/or multiple cSCCs in low-risk areas where surgery and/or RT are not possible or have unacceptable consequences.	GPP
8. Definitive primary RT	Primary radiotherapy should be considered as an alternative to surgery for inoperable or difficult-to-operate tumours or in the absence of consent to surgical excision.	B
9. Postoperative RT	Postoperative radiotherapy should be considered after surgical excision for cSCC with positive margins and for which re-excision is not possible.	B
10. Adjuvant RT for resected nodal metastatic cSCC	Adjuvant radiotherapy following therapeutic lymphadenectomy should be considered in cSCC of the head and neck with regional nodal metastases and extracapsular extension.	B
11. Adjuvant RT for high-risk cSCC	Adjuvant radiotherapy may not be offered as standard of care for cSCC with clear surgical margins, as a clear benefit has not been shown.	C
12. Immunotherapy for advanced cSCC	Patients with metastatic cSCC or locally advanced cSCC, who are not candidates for curative surgery or curative radiation, should receive first-line treatment with a PD-1 antibody*.	B
13. EGFR inhibitors	Cetuximab may be used for patients with locally advanced and metastatic cSCC, who have failed to respond or are intolerant to immunotherapy. Cetuximab combined with RT is favoured over cetuximab monotherapy.	C
14. Follow-up	cSCC patients shall be followed up for recurrences and development of new NMSC and melanoma. Follow-up in all patients shall include regular clinical examination, including inspection of the entire skin and inspection and palpation of the excision site, the in-transit route and the regional lymph nodes, and advice on self-skin examination. Frequency of follow-up visits and imaging depend on underlying risk characteristics for cSCC patient: low-risk or high-risk common primary, advanced or regional disease, immunosuppression setting (detailed in Table 3).	GPP

cSCC, cutaneous squamous cell carcinoma; GOR, grade of recommendation; GPP, good practice point; NMSC, non-melanoma skin cancer; RT, radiotherapy.

*In Europe, cemiplimab is currently the only approved medication, while pembrolizumab and nivolumab are investigated in clinical trials

Funding sources

The development of the current set of guidelines was supported solely by funds of the EADO which were used to mainly support the consensus meeting without honoraria and without reimbursement of travel costs.

CRedit authorship contribution statement

Alexander J. Stratigos: Conceptualization; Writing - Review & Editing, Writing - Original Draft, Supervision. Claus Garbe: Conceptualization; Writing - Review & Editing, Writing - Original Draft, Supervision. Clio Dessinioti: Conceptualization; Writing - Review & Editing, Writing - Original Draft, Supervision. Celeste Lebbe: Conceptualization; Writing - Review & Editing, Supervision. Alexander van Akkooi: Conceptualization; Writing - Review & Editing, Supervision. Veronique Bataille: Conceptualization; Writing - Review & Editing, Supervision. Lars Bastholt: Conceptualization; Writing - Review & Editing, Supervision. Brigitte Dreno: Conceptualization; Writing - Review & Editing, Supervision. Reinhard Dummer: Conceptualization; Writing - Review & Editing, Supervision. Maria Concetta Fagnoli: Conceptualization; Writing - Review & Editing, Supervision. Ana Maria Forsea: Conceptualization; Writing - Review & Editing, Supervision. Catherine A. Harwood: Conceptualization; Writing - Review & Editing, Supervision. Axel Hauschild: Conceptualization; Writing - Review & Editing, Supervision. Christoph Hoeller: Conceptualization; Writing - Review & Editing, Supervision. Lidija Kandolf-Sekulovic: Conceptualization; Writing - Review & Editing, Supervision. Roland Kaufmann: Conceptualization; Writing - Review & Editing, Supervision. Nicole WJ Kelleners-Smeets: Conceptualization; Writing - Review & Editing, Supervision. Aimilios Lallas: Conceptualization; Writing - Review & Editing, Supervision. Ulrike Leiter: Conceptualization; Writing - Review & Editing, Supervision. Josep Malvehy: Conceptualization; Writing - Review & Editing, Supervision. Veronique del Marmol: Conceptualization; Writing - Review & Editing, Supervision. David Moreno-Ramirez: Conceptualization; Writing - Review & Editing, Supervision. Giovanni Pellacani: Conceptualization; Writing - Review & Editing, Supervision. Ketty Peris: Conceptualization; Writing - Review & Editing, Supervision. Philippe Saiag: Conceptualization; Writing - Review & Editing, Supervision. Luca Tagliaferri: Conceptualization; Writing - Review & Editing, Supervision. Myrto Trakatelli: Conceptualization; Writing - Review & Editing, Supervision. Dimitrios Ioannides: Conceptualization; Writing - Review & Editing, Supervision. Ricardo Vieira: Conceptualization; Writing - Review & Editing, Supervision. Iris Zalaudek: Conceptualization; Writing -

Review & Editing, Supervision. Petr Arenberger: Conceptualization; Writing - Review & Editing, Supervision. Alexander M. M Eggermont : Conceptualization; Writing - Review & Editing, Supervision. Martin Rocken: Conceptualization; Writing - Review & Editing, Supervision. Jean-Jacques Grob: Conceptualization; Writing - Review & Editing, Supervision. Paul Lorigan: Conceptualization; Writing - Review & Editing, Writing - Original Draft, Supervision.

Declaration of Competing Interest

The authors declare the following financial interests/personal relationships which may be considered as potential competing interests:

1. **Dr. Stratigos** reports personal fees and/or research support from Novartis, Roche, BMS, Abbvie, Sanofi, Regeneron, Genesis Pharma, outside the submitted work.
2. **Dr. Garbe** reports personal fees from Amgen, personal fees from MSD, grants and personal fees from Novartis, grants and personal fees from NeraCare, grants and personal fees from BMS, personal fees from Pierre Fabre, personal fees from Philogen, grants and personal fees from Roche, grants and personal fees from Sanofi, outside the submitted work.
3. **Dr. Dessinioti** has nothing to disclose.
4. **Dr. Lebbe** reports grants and personal fees from Bristol-Myers Squibb, personal fees from MSD, personal fees from Novartis, personal fees from Amgen, grants and personal fees from Roche, personal fees from Avantis Medical Systems, personal fees from Pierre Fabre, personal fees from Pfizer, personal fees from Incyte, outside the submitted work.
5. **Dr. Bataille** reports personal fees from Novartis, personal fees from Merck MSD, outside the submitted work.
6. **Dr. Bastholt** reports personal fees for advisory board activity: BMS, Roche, Novartis, Pierre-Fabre, Astra Zeneca, Incyte, MSD/Merck, Bayer, outside the submitted work.
7. **Dr. Dréno** reports grants and personal fees from BMS, personal fees from MSD, grants and personal fees from Roche, grants and personal fees from Fabre, grants and personal fees from Sanofi, outside the submitted work.
8. **Dr Dummer** reports intermittent, project focused consulting and/or advisory relationships with Novartis, Merck Sharp & Dhome (MSD), Bristol-Myers Squibb (BMS), Roche, Amgen, Takeda, Pierre Fabre, Sun Pharma, Sanofi, Catalym, Second Genome, Regeneron, Alligator, T3 Pharma, MaxiVAX SA, Pfizer, Simcere and touchIME outside the submitted work.
9. **Dr. Fagnoli** reports personal consulting fees from Almirall, honoraria from Sanofi-Regeneron and participation in Advisory Board for Sanofi-Regeneron, outside the submitted work.
10. **Dr. Forsea** reports scientific consultant/speaker fee from Novartis, Merck, outside the submitted work.
11. **Dr. Harwood** reports institutional research grants and honoraria from Sanofi, Novartis, Merck, Pfizer, Galderma, MEDA, Almirall, Pellepharm, Leo Pharma, CERIES, outside the submitted work.

12. **Dr. Hauschild** reports grants and personal fees from Amgen, grants and personal fees from BMS, grants and personal fees from MerckPfizer, grants and personal fees from MSD/Merck, grants and personal fees from Philogen, grants and personal fees from Pierre Fabre, grants and personal fees from Regeneron, grants and personal fees from Roche, grants and personal fees from Sanofi-Genzyme, grants and personal fees from Novartis Pharma, grants and personal fees from Eisai, personal fees from Immunocore, grants and personal fees from Replimune, personal fees from Seagen, personal fees from IO Biotech, personal fees from Dermagnostix, personal fees from Incyte, grants and personal fees from NeraCare, personal fees from Highlight Therapeutics, grants from Huya Biosciences, personal fees from Kyowa Kirin, outside the submitted work.
13. **Dr. Hoeller** reports personal fees from BMS, personal fees from Novartis, grants and personal fees from Amgen, personal fees from Almirall, personal fees from Pierre Fabre, personal fees from Sanofi, personal fees from MSD, outside the submitted work.
14. **Dr. Kandolf-Sekulovic** reports speakers' honoraria for Roche, Novartis, MSD, BMS, Janssen outside the submitted work.
15. **Dr. Kaufmann** reports institutional research grants (clinical trials) from: AbbVie, Amgen, Biontech, BMS, Celgene, Galderma, Janssen, Leo, Lilly, Merck, MSD, Novartis, Pierre Fabre, Pfizer, Regeneron, Roche, Wyeth. Advisory Board and Honoraria from Merz, Roche, Novartis, outside the submitted work.
16. **Dr. Kelleners-Smeets** reports grants from Netherlands Organization for Health Research and Development, other from Janssen-Cilag, other from AbbVie, other from Galderma, outside the submitted work.
17. **Dr. Malvey** reports research grants from Almirall, ISDIN, Leo Pharma, Galderma, GSK, Cantabria; participation in advisory board meetings for Almirall, Sunpharma, BMS, Roche, Novartis, Pierre-Fabre, outside the submitted work.
18. **Dr. del Marmol** reports personal fees from MSD, from BMS, personal fees from Sanofi, grants and personal fees from ABVIE, grants from Jansen, outside the submitted work.
19. **Dr. Moreno-Ramirez** has nothing to disclose.
20. **Dr. Pellicani** reports grants from university of Modena and Reggio Emilia, during the conduct of the study; grants from Novartis, grants and personal fees from Almirall, grants from Leo Pharma, from null, outside the submitted work.
21. **Dr. Peris** reports honoraria for advisory board and grants from AbbVie, Almirall, Biogen Celgene, Lilly, Galderma, Leo Pharma, Novartis, Roche, Sanofi, Sun Pharma, Sandoz outside the submitted work.
22. **Dr. Saiag** reports honoraria for advisory board and grants from Amgen, Bristol-Myers Squibb, MSD, Merck-Serono, Novartis, Pfizer, Roche-Genentech, Pierre Fabre, and Sanofi, outside the submitted work.
23. **Dr. Vieira** has nothing to disclose.
24. **Dr. Zalaudek** reports honoraria and advisory board and grants from Sanofi, Sun Pharma, Novartis, Galderma, Roche, Celgene, Almirall, Leofarma, Mylan, Difa Cooper, Cieffe Labs, La Roche Posay, Pierre Fabre.
25. **Dr. Eggermont** reports over the last 5 years personal fees as a consultant advisor for Biocad, BioInvent, Bristol Myers Squibb (BMS), CatalYm, Ellipses, Glaxo Smith Kline (GSK), HalioDX, Incyte, IO Biotech, ISA Pharmaceuticals, Merck Sharpe & Dohme (MSD), Novartis, Pfizer, Polynoma, Regeneron, Sanofi, Sellas, SkylineDx. Alexander M.M. EGGERMONT: Honoraria, consultancy, SAB, IDMC, lectures for the last 2 years: Agenus, BioInvent, BioNTech, BMS, Brenus, CatalYm, Clover Pharmaceuticals, Ellipses, Galecto, GenOway, GSK, IO Biotech, IQVIA, ISA Pharmaceuticals, Merck&Co/MSD, Pierre Fabre, Pfizer, Sairopa, Sellas, SkylineDx, TigaTx, Trained Therapeutics,. Equity: IO Biotech, Sairopa, SkylineDX.
26. **Dr. Grob** reports personal fees for advisory board and as speaker from Amgen, Roche, GSK, Novartis, BMS, Pierre Fabre, Merck, Sanofi, Merck, Pfizer outside the submitted work.
27. **Alexander van Akkooi**: Advisory Board / Consultancy Honoraria: Amgen, Bristol-Myers Squibb, Novartis, MSD-Merck, Merck-Pfizer, Pierre Fabre, Provectus, Sanofi, Sirius Medical, 4SC.
28. **Dr Lallas** has nothing to disclose.
29. **Dr Ioannides** reports support from Sanofi in a phase III clinical trial, outside the submitted work.
30. **Dr Lorigan** reports honoraria (consulting/advisory/ speakers' bureau) from BMS, Merck/MSD, Nektar, NeraCare, Amgen, Novartis, Oncology Education Canada, Pierre Fabre, Roche, outside the submitted work.
31. **Dr Rocken** reports study grants from AB Science, Abbott, Abbvie, Alcedis, Almirall Hermal, Amgen, AnaptysBio, argenx, AstraZeneca, Bayer, Biogen idec, Boehringer Ingelheim, Bristol-Myers Squibb, Celgene, CureVac, DelArrivo, Dynavax Technologies, Eli Lilly, Galderma, Genentech, GSK, Hoffman-La Roche, Hokusai, Idera Pharmaceuticals, Ilkos Therapeutic, Immatics Biotechnologies, Incyte, Iovance Biotherapeutics, Janssen-Cilag, Johnson & Johnson, LEO Pharma, Merck, MSD Sharp & Dome, Novartis Pharmaceuticals, PellePharma, Pfizer, Philogen, Regeneron Pharmaceuticals, Sanofi-Aventis, Schering-Plough, Sun Pharma, Technische Universitat Dresden, Topaz Therapeutics, UCB, Universitätsklinikum Essen, Universitätsklinik Koln, 4SC, grants for research projects from Deutsche Forschungsgemeinschaft, Deutsche Krebshilfe, Wilhelm Sander-Stiftung, consulting fees from Galderma, support for attending meetings/travel from EADV, International League of Dermatological Societies, patent PCT/EP2020/072203, stock or stock options from Bristol-Myers Squibb, CureVac, Merck, Pfizer, outside the submitted work.
32. **Dr Arenberger** has nothing to disclose.
33. **Dr Tagliaferri** reports honoraria from Elekta, Igea Medical, SunPharma, Sanofi, Roche, Molipharma, Nanobiotix, Novartis, outside the submitted work.
34. **Dr Leiter** reports personal fees from MSD, honoraria from MSD, Novartis, Sun Pharma, Sanofi, Almiral Hermal, support for attending meetings/travel from Pierre Fabre, Sun Pharma, participation in Advisory Board for MSD, Novartis, Sun Pharma, Sanofi, Almiral Hermal, outside the submitted work.
35. **Dr Trakatelli** reports travel grants from Janssen, UCB, Abbvie, honoraria from UCB, Genesis Pharma, Pierre Fabre Greece, EADV courses, travel expenses for congresses from Abbvie, Pierre Fabre Greece, Genesis Pharma, outside the submitted work.

Acknowledgements

Jørgen Johansen, MD, Associate Professor, Department of Oncology, Odense University Hospital for assistance with the section on radiotherapy.

Appendix A. Supporting material

Supplementary data associated with this article can be found in the online version at doi:10.1016/j.ejca.2023.113252.

References

- [1] Howick J, Chalmers I, Glasziou P, Greenhalgh T, Heneghan C, Liberati A, et al. The Oxford levels of evidence 2. <https://www.cebm.ox.ac.uk/resources/levels-of-evidence/ocbm-levels-of-evidence> [accessed July 17, 2022]: Oxford center for evidence-based medicine.
- [2] Keohane SG, Botting J, Budny PG, Dolan OM, Fife K, Harwood CA, et al. British Association of Dermatologists guidelines for the management of people with cutaneous squamous cell carcinoma 2020. *Br J Dermatol* 2021;184:401–14.
- [3] Dessinioti C, Platsidaki E, Stratigos AJ. A sensitivity meta-analysis of disease-specific death in localized cutaneous squamous cell carcinoma. *Dermatology* 2022;238:1026–35.
- [4] Leus AJG, Frie M, Haisma MS, Terra JB, Plaat BEC, Steenbakkers R, et al. Treatment of keratinocyte carcinoma in elderly patients—a review of the current literature. *J Eur Acad Dermatol Venereol* 2020;34:1932–43.
- [5] Baggi A, Quaglini P, Rubatto M, Depenni R, Guida M, Ascierto PA, et al. Real world data of cemiplimab in locally advanced and metastatic cutaneous squamous cell carcinoma. *Eur J Cancer* 2021;157:250–8.
- [6] Strippoli S, Fanizzi A, Quaresmini D, Nardone A, Armenio A, Figliuolo F, et al. Cemiplimab in an elderly frail population of patients with locally advanced or metastatic cutaneous squamous cell carcinoma: a single-center real-life experience from Italy. *Front Oncol* 2021;11:686308.
- [7] Samaran Q, Samaran R, Ferreira E, Haddad N, Fottorino A, Maillard H, et al. Anti-PD-1 for the treatment of advanced cutaneous squamous cell carcinoma in elderly patients: a French multicenter retrospective survey. *J Cancer Res Clin Oncol* 2023;149:3549–62.
- [8] Breuninger H, Eigentler T, Hafner HM, Leiter U. Local surgical treatment of cutaneous squamous cell carcinoma: deficits and controversies in the literature. *J Ger Soc Dermatol: JDDG* 2019;17:999–1004.
- [9] van Delft LCJ, Nelemans PJ, van Loo E, Abdul Hamid M, Kelleners-Smeets NWJ. The illusion of conventional histological resection margin control. *Br J Dermatol* 2019;180:1240–1.
- [10] Alam M, Armstrong A, Baum C, Bordeaux J, Brown M, Busam K, et al. Guidelines of care for the management of cutaneous squamous cell carcinoma. *J Am Acad Dermatol* 2018;78:560–78.
- [11] Lansbury L, Bath-Hextall F, Perkins W, Stanton W, Leonard-Bee J. Interventions for non-metastatic squamous cell carcinoma of the skin: systematic review and pooled analysis of observational studies. *BMJ* 2013;347:f6153.
- [12] Stewart TJ, Saunders A. Risk factors for positive margins after wide local excision of cutaneous squamous cell carcinoma. *J Dermatol Treat* 2018;29:706–8.
- [13] Schmultz C, Blitzblau R, Aasi SZ, Alam M, Amini A, Baumann BC, et al. National Comprehensive Cancer Network (NCCN) clinical practice guidelines in oncology. Squamous Cell Skin Cancer 2023;version 1:ed2023.
- [14] Leiter U, Heppt MV, Steeb T, Amaral T, Bauer A, Becker JC, et al. S3 guideline for actinic keratosis and cutaneous squamous cell carcinoma (cSCC) - short version, part 2: epidemiology, surgical and systemic treatment of cSCC, follow-up, prevention and occupational disease. *J Ger Soc Dermatol: JDDG* 2020;18:400–13.
- [15] Motaparthy K, Kapil JP, Velazquez EF. Cutaneous squamous cell carcinoma: review of the eighth edition of the American Joint Committee on cancer staging guidelines, prognostic factors, and histopathologic variants. *Adv Anat Pathol* 2017;24:171–94.
- [16] Brodland DG, Zitelli JA. Surgical margins for excision of primary cutaneous squamous cell carcinoma. *J Am Acad Dermatol* 1992;27:241–8.
- [17] Thomas DJ, King AR, Peat BG. Excision margins for non-melanotic skin cancer. *Plast Reconstr Surg* 2003;112:57–63.
- [18] Ribero S, Osella Abate S, Di Capua C, Dika E, Balagna E, Senetta R, et al. Squamocellular carcinoma of the skin: clinicopathological features predicting the involvement of the surgical margins and review of the literature. *Dermatology* 2016;232:279–84.
- [19] Bonerandi JJ, Beauvillain C, Caquant L, Chassagne JF, Chaussade V, Clavere P, et al. Guidelines for the diagnosis and treatment of cutaneous squamous cell carcinoma and precursor lesions. *J Eur Acad Dermatol Venereol* 2011;25(Suppl 5):1–51.
- [20] Sapijaszko M, Zloty D, Bourcier M, Poulin Y, Janiszewski P, Ashkenas J, et al. Non-melanoma skin cancer in Canada chapter 5: management of squamous cell carcinoma. *J Cutan Med Surg* 2015;19:249–59.
- [21] Stratigos AJ, Garbe C, Dessinioti C, Lebbe C, Bataille V, Bastholt L, et al. European interdisciplinary guideline on invasive squamous cell carcinoma of the skin: part 2. Treatment. *Eur J Cancer* 2020;128:83–102.
- [22] Ansai SI, Umebayashi Y, Katsumata N, Kato H, Kadono T, Takai T, et al. Japanese dermatological association guidelines: outlines of guidelines for cutaneous squamous cell carcinoma 2020. *J Dermatol* 2021;48:e288–311.
- [23] van Lee CB, Kouloubis N, Wakkee M, Kelleners-Smeets NWJ, Nellen RGL, van Rengen A, et al. Rate and characteristics of incompletely excised cutaneous squamous cell carcinoma: a dermatological daily practice multicenter prospective cohort study. *Dermatol Surg* 2022;48:1269–73.
- [24] Dessinioti C, Stratigos AJ. Overview of guideline recommendations for the management of high-risk and advanced cutaneous squamous cell carcinoma. *J Eur Acad Dermatol Venereol* 2022;36(Suppl 1):11–8.
- [25] Motley R, Kersey P, Lawrence C, British Association of D, British Association of Plastic S. Multiprofessional guidelines for the management of the patient with primary cutaneous squamous cell carcinoma. *Br J Plast Surg* 2003;56:85–91.
- [26] Khan AA, Potter M, Cubitt JJ, Khoda BJ, Smith J, Wright EH, et al. Guidelines for the excision of cutaneous squamous cell cancers in the United Kingdom: the best cut is the deepest. *J Plast Reconstr Aesthet Surg* 2013;66:467–71.
- [27] Newlands C, Currie R, Memon A, Whitaker S, Woolford T. Non-melanoma skin cancer: United Kingdom National Multidisciplinary Guidelines. *J Laryngol Otol* 2016;130:S125–32.
- [28] Baba N, Kato H, Nakamura M, Matsushita S, Aoki M, Fujimoto N, et al. Narrower clinical margin in high or very high-risk squamous cell carcinoma: a retrospective, multicenter study of 1,000 patients. *J Ger Soc Dermatol: JDDG* 2022;20:1088–99.
- [29] van Lee CB, Roorda BM, Wakkee M, Voorham Q, Mooyaart AL, de Vijlder HC, et al. Recurrence rates of cutaneous squamous cell carcinoma of the head and neck after Mohs micrographic surgery versus standard excision: a retrospective cohort study. *Br J Dermatol* 2019;181:338–43.

- [30] Rowe DE, Carroll RJ, Day Jr. CL. Prognostic factors for local recurrence, metastasis, and survival rates in squamous cell carcinoma of the skin, ear, and lip. Implications for treatment modality selection. *J Am Acad Dermatol* 1992;26:976–90.
- [31] Hunt WTN, Earp E, Brown AC, Veitch D, Wernham AGH. A review of Mohs micrographic surgery for skin cancer. Part 3: squamous cell carcinoma. *Clin Exp Dermatol* 2022;47:1765–73.
- [32] Moehrle M, Breuninger H, Rocken M. A confusing world: what to call histology of three-dimensional tumour margins? *J Eur Acad Dermatol Venereol* 2007;21:591–5.
- [33] Loser CR, Rompel R, Mohrle M, Hafner HM, Kunte C, Hassel J, et al. S1 guideline: microscopically controlled surgery (MCS). *J Ger Soc Dermatol: JDDG* 2015;13:942–51.
- [34] Mohrle M, Breuninger H. The Muffin technique—an alternative to Mohs’ micrographic surgery. *J Ger Soc Dermatol: JDDG* 2006;4:1080–4.
- [35] Longo C, Ragazzi M, Gardini S, Piana S, Moscarella E, Lallas A, et al. Ex vivo fluorescence confocal microscopy in conjunction with Mohs micrographic surgery for cutaneous squamous cell carcinoma. *J Am Acad Dermatol* 2015;73(2):321.
- [36] Leibovitch I, Huilgol SC, Selva D, Hill D, Richards S, Paver R. Cutaneous squamous cell carcinoma treated with Mohs micrographic surgery in Australia I. Experience over 10 years. *J Am Acad Dermatol* 2005;53:253–60.
- [37] Pugliano-Mauro M, Goldman G. Mohs surgery is effective for high-risk cutaneous squamous cell carcinoma. *Dermatol Surg* 2010;36:1544–53.
- [38] Chren MM, Linos E, Torres JS, Stuart SE, Parvataneni R, Boscardin WJ. Tumour recurrence 5 years after treatment of cutaneous basal cell carcinoma and squamous cell carcinoma. *J Invest Dermatol* 2013;133:1188–96.
- [39] Marrazzo G, Zitelli JA, Brodland D. Clinical outcomes in high-risk squamous cell carcinoma patients treated with Mohs micrographic surgery alone. *J Am Acad Dermatol* 2019;80:633–8.
- [40] Tschetter AJ, Campoli MR, Zitelli JA, Brodland DG. Long-term clinical outcomes of patients with invasive cutaneous squamous cell carcinoma treated with Mohs micrographic surgery: a 5-year, multicenter, prospective cohort study. *J Am Acad Dermatol* 2020;82:139–48.
- [41] Xiong DD, Beal BT, Varra V, Rodriguez M, Cundall H, Woody NM, et al. Outcomes in intermediate-risk squamous cell carcinomas treated with Mohs micrographic surgery compared with wide local excision. *J Am Acad Dermatol* 2020;82:1195–204.
- [42] Soleymani T, Brodland DG, Arzeno J, Sharon DJ, Zitelli JA. Clinical outcomes of high-risk cutaneous squamous cell carcinomas treated with Mohs micrographic surgery alone: an analysis of local recurrence, regional nodal metastases, progression-free survival, and disease-specific death. *J Am Acad Dermatol* 2023;88:109–17.
- [43] Yung AE, Crouch G, Varey AHR, Lo S, Elliott MS, Lee J, et al. Benchmarking survival outcomes following surgical management of pT3 and pT4 cutaneous squamous cell carcinoma of the head and neck. *Ann Surg Oncol* 2022;29:5124–38.
- [44] Fraga SD, Besaw RJ, Murad F, Schmults CD, Waldman A. Complete margin assessment versus sectional assessment in surgically excised high-risk keratinocyte carcinomas: a systematic review and meta-analysis. *Dermatol Surg* 2022;48:704–10.
- [45] Udkoff J, Beal BT, Brodland DG, Knackstedt T. Cost-effectiveness of intermediate-risk squamous cell carcinoma treated with Mohs micrographic surgery compared with wide local excision. *J Am Acad Dermatol* 2022;86:303–11.
- [46] Jambusaria-Pahlajani A, Miller CJ, Quon H, Smith N, Klein RQ, Schmults CD. Surgical monotherapy versus surgery plus adjuvant radiotherapy in high-risk cutaneous squamous cell carcinoma: a systematic review of outcomes. *Dermatol Surg* 2009;35:574–85.
- [47] Veness MJ, Morgan GJ, Palme CE, GebSKI V. Surgery and adjuvant radiotherapy in patients with cutaneous head and neck squamous cell carcinoma metastatic to lymph nodes: combined treatment should be considered best practice. *Laryngoscope* 2005;115(5):870.
- [48] Sahovaler A, Krishnan RJ, Yeh DH, Zhou Q, Palma D, Fung K, et al. Outcomes of cutaneous squamous cell carcinoma in the head and neck region with regional lymph node metastasis: a systematic review and meta-analysis. *JAMA Otolaryngol Head Neck Surg* 2019;145:352–60.
- [49] Gurney B, Newlands C. Management of regional metastatic disease in head and neck cutaneous malignancy. 1. Cutaneous squamous cell carcinoma. *Br J Oral Maxillofac Surg* 2014;52:294–300.
- [50] D’Souza J, Clark J. Management of the neck in metastatic cutaneous squamous cell carcinoma of the head and neck. *Curr Opin Otolaryngol Head Neck Surg* 2011;19:99–105.
- [51] O’Brien CJ, McNeil EB, McMahon JD, Pathak I, Lauer CS, Jackson MA. Significance of clinical stage, extent of surgery, and pathologic findings in metastatic cutaneous squamous carcinoma of the parotid gland. *Head Neck* 2002;24:417–22.
- [52] Vauterin TJ, Veness MJ, Morgan GJ, Poulsen MG, O’Brien CJ. Patterns of lymph node spread of cutaneous squamous cell carcinoma of the head and neck. *Head Neck* 2006;28:785–91.
- [53] Givi B, Andersen PE, Diggs BS, Wax MK, Gross ND. Outcome of patients treated surgically for lymph node metastases from cutaneous squamous cell carcinoma of the head and neck. *Head Neck* 2011;33:999–1004.
- [54] Ebrahimi A, Moncrieff MD, Clark JR, Shannon KF, Gao K, Milross CG, et al. Predicting the pattern of regional metastases from cutaneous squamous cell carcinoma of the head and neck based on location of the primary. *Head Neck* 2010;32:1288–94.
- [55] Jol JA, van Velthuisen ML, Hilgers FJ, Keus RB, Neering H, Balm AJ. Treatment results of regional metastasis from cutaneous head and neck squamous cell carcinoma. *Eur J Surg Oncol* 2003;29:81–6.
- [56] Wang JT, Palme CE, Wang AY, Morgan GJ, GebSKI V, Veness MJ. In patients with metastatic cutaneous head and neck squamous cell carcinoma to cervical lymph nodes, the extent of neck dissection does not influence outcome. *J Laryngol Otol* 2013;127(Suppl 1):S2–7.
- [57] Work G, Invited R, Kim JYS, Kozlow JH, Mittal B, Moyer J, et al. Guidelines of care for the management of cutaneous squamous cell carcinoma. *J Am Acad Dermatol* 2018;78:560–78.
- [58] Schmidt C, Martin JM, Khoo E, Plank A, Grigg R. Outcomes of nodal metastatic cutaneous squamous cell carcinoma of the head and neck treated in a regional center. *Head Neck* 2015;37:1808–15.
- [59] Audet N, Palme CE, Gullane PJ, Gilbert RW, Brown DH, Irish hJ, et al. Cutaneous metastatic squamous cell carcinoma to the parotid gland: analysis and outcome. *Head Neck* 2004;26:727–732.
- [60] Rodrigo JP, Grilli G, Shah JP, Medina JE, Robbins KT, Takes RP, et al. Selective neck dissection in surgically treated head and neck squamous cell carcinoma patients with a clinically positive neck: systematic review. *Eur J Surg Oncol* 2018;44:395–403.
- [61] Moreno-Ramirez D, Silva-Claveria F, Fernandez-Orland A, Eiris N, Ruiz de Casas A, Ferrandiz L. Surgery for cutaneous squamous cell carcinoma and its limits in advanced disease. *Dermatol Pract Concept* 2021;11:e2021167S.
- [62] Gross ND, Miller DM, Khushalani NI, Divi V, Ruiz ES, Lipson EJ, et al. Neoadjuvant cemiplimab for stage II to IV cutaneous squamous-cell carcinoma. *N Engl J Med* 2022;387:1557–68.
- [63] Rotman A, Kerr SJ, Giddings CEB. Elective neck dissection in metastatic cutaneous squamous cell carcinoma to the parotid gland: a systematic review and meta-analysis. *Head Neck* 2019;41:1131–9.
- [64] Yakish K, Graham J, Hossler EW. Efficacy of curettage alone for invasive cutaneous squamous cell carcinoma: a retrospective cohort study. *J Am Acad Dermatol* 2017;77:582–4.

- [65] Stewart JR, Lang ME, Brewer JD. Efficacy of non-excisional treatment modalities for superficially invasive and in situ squamous cell carcinoma: a systematic review and meta-analysis. *J Am Acad Dermatol* 2022;87:131–7.
- [66] Alam M, Armstrong A, Baum C, Bordeaux J, Brown M, Busam K, et al. Guidelines of care for the management of basal cell carcinoma. *J Am Acad Dermatol* 2018;78:540–59.
- [67] Morton CA, Szeimies RM, Basset-Seguín N, Calzavara-Pinton P, Gilaberte Y, Haedersdal M, et al. European Dermatology Forum guidelines on topical photodynamic therapy 2019 part 1: treatment delivery and established indications - actinic keratoses, Bowen's disease and basal cell carcinomas. *J Eur Acad Dermatol Venereol* 2019;33:2225–38.
- [68] Morton CA, Szeimies RM, Basset-Seguín N, Calzavara-Pinton PG, Gilaberte Y, Haedersdal M, et al. European Dermatology Forum guidelines on topical photodynamic therapy 2019 part 2: emerging indications - field cancerization, photorejuvenation and inflammatory/infective dermatoses. *J Eur Acad Dermatol Venereol* 2020;34:17–29.
- [69] Potenza C, Bernardini N, Balduzzi V, Losco L, Mambrin A, Marchesiello A, et al. A review of the literature of surgical and non-surgical treatments of invasive squamous cells carcinoma. *BioMed Res Int* 2018;2018:9489163.
- [70] Maxfield L, Shah M, Schwartz C, Tanner LS, Appel J. Intralesional 5-fluorouracil for the treatment of squamous cell carcinomas. *J Am Acad Dermatol* 2021;84:1696–7.
- [71] Goette DK, Odom RB. Successful treatment of keratoacanthoma with intralesional fluorouracil. *J Am Acad Dermatol* 1980;2:212–6.
- [72] Annest NM, VanBeek MJ, Arpey CJ, Whitaker DC. Intralesional methotrexate treatment for keratoacanthoma tumours: a retrospective study and review of the literature. *J Am Acad Dermatol* 2007;56:989–93.
- [73] Tran DC, Li S, Henry S, Wood DJ, Chang ALS. An 18-year retrospective study on the outcomes of keratoacanthomas with different treatment modalities at a single academic centre. *Br J Dermatol* 2017;177:1749–51.
- [74] Gunaratne DA, Veness MJ. Efficacy of hypofractionated radiotherapy in patients with non-melanoma skin cancer: results of a systematic review. *J Med Imaging Radiat Oncol* 2018;62:401–11.
- [75] Cuperus E, Leguit R, Albrechts M, Toonstra J. Post radiation skin tumours: basal cell carcinomas, squamous cell carcinomas and angiosarcomas. A review of this late effect of radiotherapy. *Eur J Dermatol* 2013;23:749–57.
- [76] Mierzwa ML. Radiotherapy for skin cancers of the face, head, and neck. *Facial Plast Surg Clin North Am* 2019;27:131–8.
- [77] Garbutcheon-Singh KB, Veness MJ. The role of radiotherapy in the management of non-melanoma skin cancer. *Australas J Dermatol* 2019;60:265–72.
- [78] Porceddu SV, Daniels C, Yom SS, Liu H, Waldron J, Gregoire V, et al. Head and Neck Cancer International Group (HNCIG) consensus guidelines for the delivery of postoperative radiation therapy in complex Cutaneous Squamous Cell Carcinoma of the Head and Neck (cSCCHN). *Int J Radiat Oncol Biol Phys* 2020;107:641–51.
- [79] Kim SK, Barker CA. Outcomes of radiation therapy for advanced T3/T4 non-melanoma cutaneous squamous cell and basal cell carcinoma. *Br J Dermatol* 2018;178:e30–2.
- [80] Terra JB, Gaster MB, Halmos GB, Roodenburg JL, van der Vegt B, Romeijn TR, et al. Local control of 151 head and neck cutaneous squamous cell carcinoma after radiotherapy: a retrospective study on efficacy and prognostic factors. *Clin Otolaryngol* 2017;42:851–5.
- [81] Harris BN, Pipkorn P, Nguyen KNB, Jackson RS, Rao S, Moore MG, et al. Association of adjuvant radiation therapy with survival in patients with advanced cutaneous squamous cell carcinoma of the head and neck. *JAMA Otolaryngol Head Neck Surg* 2019;145:153–8.
- [82] Stratigos A, Garbe C, Lebbe C, Malvey J, del Marmol V, Pehamberger H, et al. Diagnosis and treatment of invasive squamous cell carcinoma of the skin: European consensus-based interdisciplinary guideline. *Eur J Cancer* 2015;51:1989–2007.
- [83] Schmults C, Blitzblau R, Aasi SZ, Alam M, Andersen JS, Baumann BC, et al. National Comprehensive Cancer Network (NCCN) clinical practice guidelines in oncology. Squamous Cell Skin Cancer. version 2 2022:ed2022.
- [84] Miller J, Chang T, Schwartz D, Peters M, Baum C. Outcomes of adjuvant radiotherapy following negative surgical margins for cutaneous squamous cell carcinoma. *Dermatol Surg* 2019;45:1111–6.
- [85] Yan BY, Kim SK, Ma J, Barker CA. Local recurrence and quality of life after adjuvant radiation therapy in high-risk squamous cell carcinoma. *Br J Dermatol* 2019;180:417–8.
- [86] Geohas J, Roholt NS, Robinson JK. Adjuvant radiotherapy after excision of cutaneous squamous cell carcinoma. *J Am Acad Dermatol* 1994;30:633–6.
- [87] Veness MJ, Palme CE, Morgan GJ. High-risk cutaneous squamous cell carcinoma of the head and neck: results from 266 treated patients with metastatic lymph node disease. *Cancer* 2006;106:2389–96.
- [88] Han A, Ratner D. What is the role of adjuvant radiotherapy in the treatment of cutaneous squamous cell carcinoma with perineural invasion? *Cancer* 2007;109:1053–9.
- [89] Canueto J, Jaka A, Corchete LA, Gonzalez-Perez AM, Garcia-Castro R, Fuente MJ, et al. Postoperative radiotherapy provides better local control and long-term outcome in selective cases of cutaneous squamous cell carcinoma with perineural invasion. *J Eur Acad Dermatol Venereol* 2020;34:1080–91.
- [90] Kim Y, Lehrer EJ, Wirth PJ, Khesroh EA, Brewer JD, Billingsley EM, et al. Adjuvant radiotherapy may not significantly change outcomes in high-risk cutaneous squamous cell carcinomas with clear surgical margins: a systematic review and meta-analysis. *J Am Acad Dermatol* 2022;86:1246–57.
- [91] Matsumoto A, Li JN, Matsumoto M, Pineider J, Nijhawan RI, Srivastava D. Factors predicting outcomes of patients with high-risk squamous cell carcinoma treated with Mohs micrographic surgery. *J Am Acad Dermatol* 2021;85:588–95.
- [92] Ruiz ES, Koyfman SA, Que SKT, Kass J, Schmults CD. Evaluation of the utility of localized adjuvant radiation for node-negative primary cutaneous squamous cell carcinoma with clear histologic margins. *J Am Acad Dermatol* 2020;82:420–9.
- [93] Zhang J, Wang Y, Wijaya WA, Liang Z, Chen J. Efficacy and prognostic factors of adjuvant radiotherapy for cutaneous squamous cell carcinoma: a systematic review and meta-analysis. *J Eur Acad Dermatol Venereol* 2021;35:1777–87.
- [94] Ruiz ES, Kus KJB, Smile TD, Murad F, Zhou G, Ilori EO, et al. Adjuvant radiation following clear margin resection of high T-stage cutaneous squamous cell carcinoma halves the risk of local and locoregional recurrence: a dual-center retrospective study. *J Am Acad Dermatol* 2022;87:87–94.
- [95] Likhacheva A, Awan M, Barker CA, Bhatnagar A, Bradfield L, Brady MS, et al. Definitive and postoperative radiation therapy for basal and squamous cell cancers of the skin: executive summary of an American society for radiation oncology clinical practice guideline. *Pract Radiat Oncol* 2020;10:8–20.
- [96] Porceddu SV, Bressel M, Poulsen MG, Stoneley A, Veness MJ, Kenny LM, et al. Postoperative concurrent chemoradiotherapy versus postoperative radiotherapy in high-risk cutaneous squamous cell carcinoma of the head and neck: the randomized phase III TROG 05.01 trial. *J Clin Oncol* 2018;36:1275–83.
- [97] Wang JT, Palme CE, Morgan GJ, GebSKI V, Wang AY, Veness MJ. Predictors of outcome in patients with metastatic cutaneous head and neck squamous cell carcinoma involving cervical lymph nodes: improved survival with the addition of adjuvant radiotherapy. *Head Neck* 2012;34:1524–8.

- [98] Revelles-Penas L, Revilla-Nebreda D, Becerril S, Corchete LA, Dominguez-Rullan I, Martins-Lopes M, et al. Outcome of cutaneous squamous cell carcinoma with microscopic residual disease after surgery and usefulness of postoperative radiotherapy: a retrospective cohort study. *J Eur Acad Dermatol Venereol* 2022;36:846–54.
- [99] Bonner JA, Harari PM, Giralt J, Azarnia N, Shin DM, Cohen RB, et al. Radiotherapy plus cetuximab for squamous-cell carcinoma of the head and neck. *N Engl J Med* 2006;354:567–78.
- [100] Heath CH, Deep NL, Nabell L, Carroll WR, Desmond R, Clemons L, et al. Phase I study of erlotinib plus radiation therapy in patients with advanced cutaneous squamous cell carcinoma. *Int J Radiat Oncol Biol Phys* 2013;85:1275–81.
- [101] Brewster AM, Lee JJ, Clayman GL, Clifford JL, Reyes MJ, Zhou X, et al. Randomized trial of adjuvant 13-cis-retinoic acid and interferon alfa for patients with aggressive skin squamous cell carcinoma. *J Clin Oncol* 2007;25:1974–8.
- [102] Goyal U, Prabhakar NK, Davuluri R, Morrison CM, Yi SK. Role of concurrent systemic therapy with adjuvant radiation therapy for locally advanced cutaneous head and neck squamous cell carcinoma. *Cureus* 2017;9:e1784.
- [103] Palmer JD, Schneider CJ, Hockstein N, Hanlon AL, Silberg J, Strasser J, et al. Combination of post-operative radiotherapy and cetuximab for high-risk cutaneous squamous cell cancer of the head and neck: a propensity score analysis. *Oral Oncol* 2018;78:102–7.
- [104] Kreinbrink PJ, Mierzwa ML, Huth B, Redmond KP, Wise-Draper TM, Casper K, et al. Adjuvant radiation and cetuximab improves local control in head and neck cutaneous squamous cell carcinoma: phase II study. *Head Neck* 2021;43:3408–16.
- [105] Salido-Vallejo R, Cuevas-Asencio I, Garnacho-Sucedo G, Gonzalez-Menchen A, Alcantara-Reifs C, De la Corte-Sanchez S, et al. Neoadjuvant intralesional methotrexate in cutaneous squamous cell carcinoma: a comparative cohort study. *J Eur Acad Dermatol Venereol* 2016;30:1120–4.
- [106] Reigneau M, Robert C, Routier E, Mamelle G, Moya-Plana A, Tomasic G, et al. Efficacy of neoadjuvant cetuximab alone or with platinum salt for the treatment of unresectable advanced non-metastatic cutaneous squamous cell carcinomas. *Br J Dermatol* 2015;173:527–34.
- [107] Jenni D, Karpova MB, Muhleisen B, Mangana J, Dreier J, Hafner J, et al. A prospective clinical trial to assess lapatinib effects on cutaneous squamous cell carcinoma and actinic keratosis. *ESMO Open* 2016;1:e000003.
- [108] Lewis CM, Glisson BS, Feng L, Wan F, Tang X, Wistuba II, et al. A phase II study of gefitinib for aggressive cutaneous squamous cell carcinoma of the head and neck. *Clin Cancer Res* 2012;18:1435–46.
- [109] Ferrarotto R, Amit M, Nagarajan P, Rubin ML, Yuan Y, Bell D, et al. Pilot phase II trial of neoadjuvant immunotherapy in locoregionally advanced, resectable cutaneous squamous cell carcinoma of the head and neck. *Clin Cancer Res* 2021;27:4557–65.
- [110] Ma JH, Wu A, Veness M, Estall V, Hong A, Borg M, et al. In-transit metastasis from squamous cell carcinoma. *Dermatol Surg* 2016;42:1285–92.
- [111] Carucci JA, Martinez JC, Zeitouni NC, Christenson L, Coldiron B, Zweibel S, et al. In-transit metastasis from primary cutaneous squamous cell carcinoma in organ transplant recipients and non-immunosuppressed patients: clinical characteristics, management, and outcome in a series of 21 patients. *Dermatol Surg* 2004;30:651–5.
- [112] Solari N, Spagnolo F, Ponte E, Quaglia A, Lillini R, Battista M, et al. Electrochemotherapy for the management of cutaneous and subcutaneous metastasis: a series of 39 patients treated with palliative intent. *J Surg Oncol* 2014;109:270–4.
- [113] Huis In 't Veld EA, Grunhagen DJ, Deroose JP, Nijsten TEC, Wouters M, Verhoef C, et al. Isolated limb perfusion for unresectable extremity cutaneous squamous cell carcinoma: an effective limb saving strategy. *Br J Cancer* 2018;119:429–34.
- [114] Belgrano V, Ben-Shabat I, Bergh P, Olofsson Bagge R. Isolated limb perfusion as a treatment option for rare types of tumours. *Int J Hyperthermia* 2016;32:595–9.
- [115] Migden MR, Rischin D, Schmults CD, Guminski A, Hauschild A, Lewis KD, et al. PD-1 blockade with cemiplimab in advanced cutaneous squamous-cell carcinoma. *N Engl J Med* 2018;379:341–51.
- [116] Pickering CR, Zhou JH, Lee JJ, Drummond JA, Peng SA, Saade RE, et al. Mutational landscape of aggressive cutaneous squamous cell carcinoma. *Clin Cancer Res* 2014;20:6582–92.
- [117] Yarchoan M, Hopkins A, Jaffee EM. Tumour mutational burden and response rate to PD-1 inhibition. *N Engl J Med* 2017;377:2500–1.
- [118] Stevenson ML, Wang CQ, Abikhair M, Roudiani N, Felsen D, Krueger JG, et al. Expression of programmed cell death ligand in cutaneous squamous cell carcinoma and treatment of locally advanced disease with pembrolizumab. *JAMA Dermatol* 2017;153:299–303.
- [119] Rischin D, Migden MR, Lim AM, Schmults CD, Khushalani NI, Hughes BGM, et al. Phase 2 study of cemiplimab in patients with metastatic cutaneous squamous cell carcinoma: primary analysis of fixed-dosing, long-term outcome of weight-based dosing. *J Immunother Cancer* 2020;8:e000775.
- [120] Rischin D, Khushalani NI, Schmults CD, Guminski A, Chang ALS, Lewis KD, et al. Integrated analysis of a phase 2 study of cemiplimab in advanced cutaneous squamous cell carcinoma: extended follow-up of outcomes and quality of life analysis. *J Immunother Cancer* 2021;9:e002757.
- [121] Migden MR, Khushalani NI, Chang ALS, Lewis KD, Schmults CD, Hernandez-Aya L, et al. Cemiplimab in locally advanced cutaneous squamous cell carcinoma: results from an open-label, phase 2, single-arm trial. *Lancet Oncol* 2020;21:294–305.
- [122] Migden M, Schmults C, Khushalani NI, Guminski A, Chang AL, Lewis K, et al. Phase II study of cemiplimab in patients with advanced cutaneous squamous cell carcinoma (CSCC): final analysis from EMPOWER-CSCC-1 groups 1, 2 and 3. Abstract 814P. *Ann Oncol* 2022;33(Supplement 7):S918–9.
- [123] Hughes BGM, Grob J, Bowyer SE, D'ay FL, Ladwa R, Stein B, et al. Phase II confirmatory study of cemiplimab (350mg IV Q3W) in patients with locally advanced or metastatic cutaneous squamous cell carcinoma (CSCC): study 1540 group 6. Abstract 818P. *Ann Oncol* 2022;33(Supplement 7):S921.
- [124] Grob JJ, Gonzalez R, Basset-Seguín N, Vornicova O, Schachter J, Joshi A, et al. Pembrolizumab monotherapy for recurrent or metastatic cutaneous squamous cell carcinoma: a single-arm phase II trial (KEYNOTE-629). *J Clin Oncol* 2020;38:2916–25.
- [125] Hughes BGM, Munoz-Couselo E, Mortier L, Bratland A, Gutzmer R, Roshdy O, et al. Pembrolizumab for locally advanced and recurrent/metastatic cutaneous squamous cell carcinoma (KEYNOTE-629 study): an open-label, non-randomized, multicenter, phase II trial. *Ann Oncol* 2021;32:1276–85.
- [126] Jarkowski III A, Hare R, Loud P, Skitzki JJ, Kane III JM, May KS, et al. Systemic therapy in advanced cutaneous squamous cell carcinoma (CSCC): the Roswell Park experience and a review of the literature. *Am J Clin Oncol* 2016;39:545–8.
- [127] Maubec E, Boubaya M, Petrow P, Beylot-Barry M, Basset-Seguín N, Deschamps L, et al. Phase II study of pembrolizumab as first-line, single-drug therapy for patients with unresectable cutaneous squamous cell carcinomas. *J Clin Oncol* 2020;38:3051–61.
- [128] Keeping S, Xu Y, Chen CI, Cope S, Mojebi A, Kuznik A, et al. Comparative efficacy of cemiplimab versus other systemic treatments for advanced cutaneous squamous cell carcinoma. *Future Oncol (London, England)* 2021;17:611–27.

- [129] Petzold A, Steeb T, Wessely A, Schatton T, Berking C, Heppt MV. Comparative efficacy analysis identifies immune checkpoint blockade as a new survival benchmark in advanced cutaneous squamous cell carcinoma. *Eur J Cancer* 2022;170:42–53.
- [130] Hughes BGM, Mendoza RG, Basset-Seguín N, Vornicova O, Schachter J, Joshi A, et al. Health-related quality of life of patients with recurrent or metastatic cutaneous squamous cell carcinoma treated with pembrolizumab in KEYNOTE-629. *Dermatol Ther (Heidelb)* 2021;11:1777–90.
- [131] Canueto J, Cardenoso E, Garcia JL, Santos-Briz A, Castellanos-Martin A, Fernandez-Lopez E, et al. Epidermal growth factor receptor expression is associated with poor outcome in cutaneous squamous cell carcinoma. *Br J Dermatol* 2017;176:1279–87.
- [132] Ridd K, Bastian BC. Somatic mutation of epidermal growth factor receptor in a small subset of cutaneous squamous cell carcinoma. *J Invest Dermatol* 2010;130(3):901.
- [133] Foote MC, McGrath M, Guminski A, Hughes BG, Meakin J, Thomson D, et al. Phase II study of single-agent panitumumab in patients with incurable cutaneous squamous cell carcinoma. *Ann Oncol* 2014;25:2047–52.
- [134] Marti A, Fauconneau A, Ouhabrache N, Beylot-Barry M, Pham-Ledard A. Complete remission of squamous cell carcinoma after treatment with panitumumab in a patient with cetuximab-induced anaphylaxis. *JAMA Dermatol* 2016;152:343–5.
- [135] Hourbeigt K, Ehret M, Visseaux L, Durlach A, Petit A, Sanchez J, et al. Efficacy and safety of panitumumab alone or in association with radiotherapy in unresectable cutaneous squamous cell carcinoma. *J Eur Acad Dermatol Venereol* 2020;34:2789–94.
- [136] William Jr. WN, Feng L, Ferrarotto R, Ginsberg L, Kies M, Lippman S, et al. Gefitinib for patients with incurable cutaneous squamous cell carcinoma: a single-arm phase II clinical trial. *J Am Acad Dermatol* 2017;77:1110–1113 e2.
- [137] Gold KA, Kies MS, William Jr. WN, Johnson FM, Lee JJ, Glisson BS. Erlotinib in the treatment of recurrent or metastatic cutaneous squamous cell carcinoma: a single-arm phase 2 clinical trial. *Cancer* 2018;124:2169–73.
- [138] Trodello C, Pepper JP, Wong M, Wysong A. Cisplatin and cetuximab treatment for metastatic cutaneous squamous cell carcinoma: a systematic review. *Dermatol Surg* 2017;43:40–9.
- [139] Picard A, Pedeutour F, Peyrade F, Saudes L, Duranton-Tanneur V, Chamorey E, et al. Association of oncogenic mutations in patients with advanced cutaneous squamous cell carcinomas treated with cetuximab. *JAMA Dermatol* 2017;153:291–8.
- [140] Conen KL, Fischer N, Hofbauer GF, Shafaeddin-Schreve B, Winterhalder R, Rochlitz C, et al. Cetuximab in metastatic squamous cell cancer of the skin: a Swiss case series. *Dermatology* 2014;229:97–101.
- [141] Maubec E, Petrow P, Scheer-Senyarich I, Duvillard P, Lacroix L, Gelly J, et al. Phase II study of cetuximab as first-line single-drug therapy in patients with unresectable squamous cell carcinoma of the skin. *J Clin Oncol* 2011;29:3419–26.
- [142] Dereure O, Missan H, Girard C, Costes V, Guillot B. Efficacy and tolerance of cetuximab alone or combined with chemotherapy in locally advanced or metastatic cutaneous squamous cell carcinoma: an open study of 14 patients. *Dermatology* 2016;232:721–30.
- [143] Giacchero D, Barriere J, Benezery K, Guillot B, Dutriaux C, Mortier L, et al. Efficacy of cetuximab for unresectable or advanced cutaneous squamous cell carcinoma—a report of eight cases. *Clin Oncol (R Coll Radiol)* 2011;23:716–8.
- [144] Samstein RM, Ho AL, Lee NY, Barker CA. Locally advanced and unresectable cutaneous squamous cell carcinoma: outcomes of concurrent cetuximab and radiotherapy. *J Skin Cancer* 2014;2014:284582.
- [145] Trodello C, Higgins S, Ahadiat O, Ragab O, In G, Hawkins M, et al. Cetuximab as a component of multimodality treatment of high-risk cutaneous squamous cell carcinoma: a retrospective analysis from a single tertiary academic medical center. *Dermatol Surg* 2019;45:254–67.
- [146] Berliner JG, Schulman JM, Lazarova Z, Olsaz E, Arron ST. Response of cutaneous squamous cell carcinoma to treatment with cetuximab. *Dermatol Surg* 2019;45:313–6.
- [147] Joseph K, Alkaabi K, Warkentin H, Ghosh S, Jha N, Smylie M, et al. Cetuximab-radiotherapy combination in the management of locally advanced cutaneous squamous cell carcinoma. *J Med Imaging Radiat Oncol* 2019;63:257–63.
- [148] Cowey CL, Robert NJ, Espirito JL, Davies K, Frytak J, Lowy I, et al. Clinical outcomes among unresectable, locally advanced, and metastatic cutaneous squamous cell carcinoma patients treated with systemic therapy. *Cancer Med* 2020;9:7381–7.
- [149] Huang SM, Bock JM, Harari PM. Epidermal growth factor receptor blockade with C225 modulates proliferation, apoptosis, and radiosensitivity in squamous cell carcinomas of the head and neck. *Cancer Res* 1999;59:1935–40.
- [150] Preneau S, Rio E, Brocard A, Peuvrel L, Nguyen JM, Quereux G, et al. Efficacy of cetuximab in the treatment of squamous cell carcinoma. *J Dermatolog Treat* 2014;25:424–7.
- [151] Jansen P, Lodde GC, Griewank KG, Hadaschik E, Roesch A, Ugurel S, et al. Management of partial and non-responding cutaneous squamous cell carcinoma. *J Eur Acad Dermatol Venereol* 2022;36(Suppl 1):29–34.
- [152] Ribero S, Stucci LS, Daniels GA, Borradori L. Drug therapy of advanced cutaneous squamous cell carcinoma: is there any evidence? *Curr Opin Oncol* 2017;29:129–35.
- [153] Guthrie Jr. TH, Porubsky ES, Luxenberg MN, Shah KJ, Wurtz KL, Watson PR. Cisplatin-based chemotherapy in advanced basal and squamous cell carcinomas of the skin: results in 28 patients including 13 patients receiving multimodality therapy. *J Clin Oncol* 1990;8:342–6.
- [154] Wollina U, Hansel G, Koch A, Kostler E. Oral capecitabine plus subcutaneous interferon alpha in advanced squamous cell carcinoma of the skin. *J Cancer Res Clin Oncol* 2005;131:300–4.
- [155] Cartei G, Cartei F, Interlandi G, Meneghini G, Jop A, Zingone G, et al. Oral 5-fluorouracil in squamous cell carcinoma of the skin in the aged. *Am J Clin Oncol* 2000;23:181–4.
- [156] Shin DM, Glisson BS, Khuri FR, Clifford JL, Clayman G, Benner SE, et al. Phase II and biologic study of interferon alfa, retinoic acid, and cisplatin in advanced squamous skin cancer. *J Clin Oncol* 2002;20:364–70.
- [157] Mecca C, Ponzetti A, Caliendo V, Ciuffreda L, Lista P. Complete response of metastatic cutaneous squamous cell carcinoma to cetuximab plus paclitaxel. *Eur J Dermatol* 2012;22:758–61.
- [158] Kramb F, Doerfer C, Meiwes A, Ramakrishnan K, Eigentler T, Garbe C, et al. Real-world treatment patterns and outcomes with systemic therapies in unresectable locally advanced and metastatic cutaneous squamous cell carcinoma in Germany. *Acta Derm Venereol* 2022;102:adv00637.
- [159] Gehl J, Sersa G, Matthiessen LW, Muir T, Soden D, Occhini A, et al. Updated standard operating procedures for electrochemotherapy of cutaneous tumours and skin metastases. *Acta Oncol* 2018;57:874–82.
- [160] De Giorgi V, Scarfi F, Saqer E, Gori A, Tomassini GM, Covarelli P. The use of cisplatin electrochemotherapy in non-melanoma skin cancers: a single-center study. *Dermatol Ther* 2020;33:e13547.
- [161] Claussen CS, Moir G, Bechara FG, Orlando A, Matteucci P, Mowatt D, et al. Prospective cohort study by InSpECT on safety and efficacy of electrochemotherapy for cutaneous tumours and metastases depending on ulceration. *J Ger Soc Dermatol: JDDG* 2022;20:470–81.
- [162] Clover AJP, de Terlizzi F, Bertino G, Curatolo P, Odili J, Campana LG, et al. Electrochemotherapy in the treatment of cutaneous malignancy: outcomes and subgroup analysis from the cumulative results from the pan-European International

- Network for Sharing Practice in Electrochemotherapy database for 2482 lesions in 987 patients (2008–2019). *Eur J Cancer* 2020;138:30–40.
- [163] Bertino G, Grosej A, Campana LG, Kunte C, Schepler H, Gehl J, et al. Electrochemotherapy for the treatment of cutaneous squamous cell carcinoma: the INSPECT experience (2008–2020). *Front Oncol* 2022;12:951662.
- [164] Sersa G, Mascherini M, Di Prata C, Odili J, de Terlizzi F, McKenzie GAG, et al. Outcomes of older adults aged 90 and over with cutaneous malignancies after electrochemotherapy with bleomycin: a matched cohort analysis from the InspECT registry. *Eur J Surg Oncol* 2021;47:902–12.
- [165] Gross ND, Miller DM, Khushalani NI, Divi V, Ruiz ES, Lipson EJ, et al. Neoadjuvant cemiplimab for stage II to IV cutaneous squamous-cell carcinoma. *N Engl J Med* 2022;387:1557–68.
- [166] Mihem MM, Vanderwalde AM, Bowles T, Sacco JJ, Niu J, Tsai KK, et al. Updated results from the skin cancer cohorts from an ongoing phase 1/2 multicohort study of RPI, an enhanced potency oncolytic HSV, combined with nivolumab (IGNYTE). Abstract 9553. *J Clin Oncol* 2022;40.
- [167] Bossi P, Alberti A, Bergamini C, Resteghini C, Locati L, Alfieri S, et al. Immunotherapy followed by cetuximab in locally advanced/metastatic (LA/M) cutaneous squamous cell carcinomas (cSCC): the I-TACKLE trial. Abstract 9520. *J Clin Oncol* 2022;40.
- [168] Migden MR, Chandra S, Rabinowits G, Chen CI, Desai J, Seluzhitsky A, et al. CASE (CemiplimAb-rwlc survivorship and epidemiology) study in advanced cutaneous squamous cell carcinoma. *Future Oncol* 2020;16:11–9.
- [169] Rabinowits G, Homsj J, Park SJ, Khushalani N, Panella T, Ellison DM, et al. CemiplimAb-rwlc survivorship and epidemiology (CASE): a prospective study of the safety and efficacy of cemiplimab in patients (pts) with advanced cutaneous squamous cell carcinoma (CSCC) in a real-world setting 825P. *Ann Oncol* 2022;33:S356–409.
- [170] Collins L, Quinn A, Stasko T. Skin cancer and immunosuppression. *Dermatol Clin* 2019;37:83–94.
- [171] James LJ, Saglimbene V, Wong G, Tong A, Luu LDW, Craig J, et al. Behavioural and pharmaceutical interventions for the prevention of skin cancers in solid organ transplant recipients: a systematic review of randomised controlled trials. *BMJ Open* 2020;10:e029265.
- [172] Harwood CA, Arron ST, Proby CM, Asgari MM, Bouwes Bavinck JN, Green AC, et al. Organ transplantation and cutaneous squamous cell carcinoma: progress, pitfalls and priorities in immunosuppression-associated keratinocyte carcinoma. *Br J Dermatol* 2017;177:1150–1.
- [173] Blomberg M, He SY, Harwood C, Arron ST, Demehri S, Green A, et al. Research gaps in the management and prevention of cutaneous squamous cell carcinoma in organ transplant recipients. *Br J Dermatol* 2017;177:1225–33.
- [174] Zwald F, Leitenberger J, Zeitouni N, Soon S, Brewer J, Arron S, et al. Recommendations for solid organ transplantation for transplant candidates with a pretransplant diagnosis of cutaneous squamous cell carcinoma, merkel cell carcinoma and melanoma: a consensus opinion from the international transplant skin cancer collaborative (ITSCC). *Am J Transplant* 2016;16:407–13.
- [175] Bangash HK, Colegio OR. Management of non-melanoma skin cancer in immunocompromised solid organ transplant recipients. *Curr Treat Options Oncol* 2012;13:354–76.
- [176] Tremblay-Abel V, Poulin MA, Blouin MM, Parent F, Perron E. Sentinel lymph node biopsy in high-risk cutaneous squamous cell carcinoma: analysis of a large size retrospective series. *Dermatol Surg* 2021;47:908–13.
- [177] Tomaszewski JM, Lau E, Corry J. Utility of positron emission tomography/computed tomography for nodal staging of cutaneous squamous cell carcinoma in patients with chronic lymphocytic leukemia. *Am J Otolaryngol* 2014;35:66–9.
- [178] Willenbrink TJ, Jambusaria-Pahlajani A, Arron S, Seckin D, Harwood CA, Proby CM. Treatment approaches in immunosuppressed patients with advanced cutaneous squamous cell carcinoma. *J Eur Acad Dermatol Venereol* 2019;33(Suppl 8):57–60.
- [179] Stasko T, Brown MD, Carucci JA, Euvrard S, Johnson TM, Sengelmann RD, et al. Guidelines for the management of squamous cell carcinoma in organ transplant recipients. *Dermatol Surg* 2004;30:642–50.
- [180] Levin EC, Chow C, Makhzoumi Z, Jin C, Shiboski SC, Arron ST. Association of postoperative antibiotics with surgical site infection in Mohs micrographic surgery. *Dermatol Surg* 2019;45:52–7.
- [181] Brewer JD, Otley CC, Christenson LJ, Phillips PK, Roenigk RK, Weaver AL. The effects of sirolimus on wound healing in dermatologic surgery. *Dermatol Surg* 2008;34:216–23.
- [182] Krisl JC, Doan VP. Chemotherapy and transplantation: the role of immunosuppression in malignancy and a review of anti-neoplastic agents in solid organ transplant recipients. *Am J Transplant* 2017;17:1974–91.
- [183] Boyd K, Shea SM, Patterson J. Cetuximab for treatment of advanced squamous cell carcinoma in solid organ transplant recipients. *Wien Med Wochenschr* 2013;163:372–5.
- [184] Lipson EJ, Bodell MA, Kraus ES, Sharfman WH. Successful administration of ipilimumab to two kidney transplantation patients with metastatic melanoma. *J Clin Oncol* 2014;32:e69–71.
- [185] Hillen U, Leiter U, Haase S, Kaufmann R, Becker J, Gutzmer R, et al. Advanced cutaneous squamous cell carcinoma: a retrospective analysis of patient profiles and treatment patterns—Results of a non-interventional study of the DeCOG. *Eur J Cancer* 2018;96:34–43.
- [186] Leard LE, Cho BK, Jones KD, Hays SR, Tope WD, Golden JA, et al. Fatal diffuse alveolar damage in two lung transplant patients treated with cetuximab. *J Heart Lung Transplant* 2007;26:1340–4.
- [187] Carroll RP, Boyer M, GebSKI V, Hockley B, Johnston JK, Kireta S, et al. Immune checkpoint inhibitors in kidney transplant recipients: a multicentre, single-arm, phase 1 study. *Lancet Oncol* 2022;23:1078–86.
- [188] Lipson EJ, Bagnasco SM, Moore Jr. J, Jang S, Patel MJ, Zachary AA, et al. Tumour regression and allograft rejection after administration of anti-PD-1. *N Engl J Med* 2016;374:896–8.
- [189] Tio M, Rai R, Ezeoke OM, McQuade JL, Zimmer L, Khoo C, et al. Anti-PD-1/PD-L1 immunotherapy in patients with solid organ transplant, HIV or hepatitis B/C infection. *Eur J Cancer* 2018;104:137–44.
- [190] De Bruyn P, Van Gestel D, Ost P, Kruse V, Brochez L, Van Vlierbergh H, et al. Immune checkpoint blockade for organ transplant patients with advanced cancer: how far can we go? *Curr Opin Oncol* 2019;31:54–64.
- [191] Abdel-Wahab N, Safa H, Abudayyeh A, Johnson DH, Trinh VA, Zobniw CM, et al. Checkpoint inhibitor therapy for cancer in solid organ transplantation recipients: an institutional experience and a systematic review of the literature. *J Immunother Cancer* 2019;7:106.
- [192] Fisher J, Zeitouni N, Fan W, Samie FH. Immune checkpoint inhibitor therapy in solid organ transplant recipients: a patient-centered systematic review. *J Am Acad Dermatol* 2020;82:1490–500.
- [193] d'Zarny-Gargas T, Durrbach A, Zaidan M. Efficacy and tolerance of immune checkpoint inhibitors in transplant patients with cancer: a systematic review. *Am J Transplant* 2020;20:2457–65.
- [194] Leiter U, Loquai C, Reinhardt L, Rafei-Shamsabadi D, Gutzmer R, Kaehler K, et al. Immune checkpoint inhibition therapy for advanced skin cancer in patients with concomitant hematological malignancy: a retrospective multicenter DeCOG study of 84 patients. *J Immunother Cancer* 2020;8:e000897.

- [195] Hanna GJ, Ruiz ES, LeBoeuf NR, Thakuria M, Schmults CD, Decaprio JA, et al. Real-world outcomes treating patients with advanced cutaneous squamous cell carcinoma with immune checkpoint inhibitors (CPI). *Br J Cancer* 2020;123:1535–42.
- [196] Kumar V, Shinagare AB, Renneke HG, Ghai S, Lorch JH, Ott PA, et al. The safety and efficacy of checkpoint inhibitors in transplant recipients: a case series and systematic review of literature. *Oncologist* 2020;25:505–14.
- [197] O'Connell KA, Schmults CD. Treatment of metastatic cutaneous squamous cell carcinoma in a solid organ transplant recipient with programmed death-1 checkpoint inhibitor therapy. *J Eur Acad Dermatol Venereol* 2022;36(Suppl 1):45–8.
- [198] Ferrandiz-Pulido C, Leiter U, Harwood C, Proby CM, Guthoff M, Scheel CH, et al. Immune checkpoint inhibitors in solid organ transplant recipients with advanced skin cancers-emerging strategies for clinical management. *Transplantation* 2023;107:1452–62.
- [199] Aguirre LE, Guzman ME, Lopes G, Hurley J. Immune checkpoint inhibitors and the risk of allograft rejection: a comprehensive analysis on an emerging issue. *Oncologist* 2019;24:394–401.
- [200] Ali SA, Arman HE, Patel AA, Birhiray RE. Successful administration of cemiplimab to a patient with advanced cutaneous squamous cell carcinoma after renal transplantation. *JCO Oncol Pract* 2020;16:137–8.
- [201] Tsung I, Worden FP, Fontana RJ. A pilot study of checkpoint inhibitors in solid organ transplant recipients with metastatic cutaneous squamous cell carcinoma. *Oncologist* 2021;26:133–8.
- [202] Paoluzzi L, Ow TJ. Safe administration of cemiplimab to a kidney transplant patient with locally advanced squamous cell carcinoma of the scalp. *Curr Oncol* 2021;28:574–80.
- [203] Zehou O, Leibler C, Arnault JP, Sayegh J, Montaudie H, Remy P, et al. Ipilimumab for the treatment of advanced melanoma in six kidney transplant patients. *Am J Transplant* 2018;18:3065–71.
- [204] Barnett R, Barta VS, Jhaveri KD. Preserved renal-allograft function and the PD-1 pathway inhibitor nivolumab. *N Engl J Med* 2017;376(2):191.
- [205] Esfahani K, Al-Aubodah TA, Thebault P, Lapointe R, Hudson M, Johnson NA, et al. Targeting the mTOR pathway uncouples the efficacy and toxicity of PD-1 blockade in renal transplantation. *Nat Commun* 2019;10:4712.
- [206] Lipson EJ, Naqvi FF, Loss MJ, Schollenberger MD, Pardoll DM, Moore Jr. J, et al. Kidney retransplantation after anti-programmed cell death-1 (PD-1)-related allograft rejection. *Am J Transplant* 2020;20:2264–8.
- [207] Harwood CA, Mesher D, McGregor JM, Mitchell L, Leedham-Green M, Raftery M, et al. A surveillance model for skin cancer in organ transplant recipients: a 22-year prospective study in an ethnically diverse population. *Am J Transplant* 2013;13:119–29.
- [208] Ducroux E, Martin C, Bouwes Bavinck JN, Decullier E, Brocard A, Westhuis-van Elsacker ME, et al. Risk of aggressive skin cancers after kidney retransplantation in patients with previous posttransplant cutaneous squamous cell carcinomas: a retrospective study of 53 cases. *Transplantation* 2017;101:e133–41.
- [209] Bertino G, Sersa G, De Terlizzi F, Occhini A, Plaschke CC, Groselj A, et al. European research on electrochemotherapy in head and neck cancer (EURECA) project: results of the treatment of skin cancer. *Eur J Cancer* 2016;63:41–52.
- [210] Vuong W, Lin J, Wei RL. Palliative radiotherapy for skin malignancies. *Ann Palliat Med* 2017;6:165–72.
- [211] McLaughlin C, Russell MA. Single-fraction high-dose palliative radiotherapy for facial cutaneous squamous cell carcinoma: a case report. *Ann Palliat Med* 2022;11:3337–40.
- [212] World Health Organization (WHO). Palliative care. <https://www.who.int/health-topics/palliative-care> [accessed 10 October, 2022].
- [213] Haumann J, Joosten EBA, Everdingen M. Pain prevalence in cancer patients: status quo or opportunities for improvement? *Curr Opin Support Palliat Care* 2017;11:99–104.
- [214] Carlson CL. Effectiveness of the World Health Organization cancer pain relief guidelines: an integrative review. *J Pain Res* 2016;9:515–34.
- [215] Cialkowska-Rysz A, Dzierzanowski T. Topical morphine for treatment of cancer-related painful mucosal and cutaneous lesions: a double-blind, placebo-controlled cross-over clinical trial. *Arch Med Sci* 2019;15:146–51.
- [216] Herms F, Lambert J, Grob JJ, Haudebourg L, Bagot M, Dalac S, et al. Follow-up of patients with complete remission of locally advanced basal cell carcinoma after vismodegib discontinuation: a multicenter french study of 116 patients. *J Clin Oncol* 2019;37:3275–82.
- [217] van Leeuwen BL, Houwerzijl M, Hoekstra HJ. Educational tips in the treatment of malignant ulcerating tumours of the skin. *Eur J Surg Oncol* 2000;26:506–8.
- [218] Furka A, Simko C, Kostyal L, Szabo I, Valikovics A, Fekete G, et al. Treatment algorithm for cancerous wounds: a systematic review. *Cancers (Basel)* 2022;14:1203.
- [219] Woo KY, Sibbald RG. Local wound care for malignant and palliative wounds. *Adv Skin Wound Care* 2010;23:417–28.
- [220] Mao JJ, Ismaila N, Bao T, Barton D, Ben-Arye E, Garland EL, et al. Integrative medicine for pain management in oncology: society for integrative oncology-ASCO guideline. *J Clin Oncol* 2022;40:3998–4024.
- [221] Oh Y, Zheng Z, Kim KY, Xu X, Pei M, Oh B, et al. A nomogram combining clinical factors and biomarkers for predicting the recurrence of high-risk cutaneous squamous cell carcinoma. *BMC Cancer* 2022;22:1126.
- [222] Girardi FM, Wagner VP, Martins MD, Abentroth AL, Hauth LA. Impact of AJCC 8 pT staging in cutaneous head and neck squamous cell carcinoma in a non-selected real-world patient sample. *Head Neck* 2023;45:337–46.
- [223] Mirali S, Tang E, Drucker AM, Turchin I, Gooderham M, Levell N, et al. Follow-up of patients with keratinocyte carcinoma: a systematic review of clinical practice guidelines. *JAMA Dermatol* 2023;159:87–94.
- [224] Hasan ZU, Ahmed I, Matin RN, Homer V, Lear JT, Ismail F, et al. Topical treatment of actinic keratoses in organ transplant recipients: a feasibility study for SPOT (Squamous cell carcinoma Prevention in Organ transplant recipients using Topical treatments). *Br J Dermatol* 2022;187:324–37.
- [225] Ahmady S, Jansen MHE, Nelemans PJ, Kessels J, Arits A, de Rooij MJM, et al. Risk of invasive cutaneous squamous cell carcinoma after different treatments for actinic keratosis: a secondary analysis of a randomized clinical trial. *JAMA Dermatol* 2022;158:634–40.
- [226] Leus AJG, Haisma MS, Terra JB, Sidorenkov G, Festen S, Plaat BEC, et al. Influence of frailty and life expectancy on guideline adherence and outcomes in cutaneous squamous cell carcinoma of the head and neck: a prospective pilot study. *Dermatology* 2023;239:148–57.
- [227] Stefanovic N, Fitzmaurice CJ, Ormond P, Irvine AD, Barry RB. Risk factors for distant metastasis in cutaneous squamous cell carcinoma. *Br J Dermatol* 2022;187:435–6.
- [228] McLaughlin EJ, Miller L, Shin TM, Sobanko JF, Cannady SB, Miller CJ, et al. Rate of regional nodal metastases of cutaneous squamous cell carcinoma in the immunosuppressed patient. *Am J Otolaryngol* 2017;38:325–8.
- [229] Levine DE, Karia PS, Schmults CD. Outcomes of patients with multiple cutaneous squamous cell carcinomas: a 10-year single-institution cohort study. *JAMA Dermatol* 2015;151:1220–5.
- [230] Cheng JY, Li FY, Ko CJ, Colegio OR. Cutaneous squamous cell carcinomas in solid organ transplant recipients compared with immunocompetent patients. *JAMA Dermatol* 2018;154:60–6.
- [231] van Egmond S, Wakkee M, Droger M, Bastiaens MT, van Rengen A, de Roos KP, et al. Needs and preferences of patients regarding basal cell carcinoma and cutaneous squamous cell carcinoma care: a qualitative focus group study. *Br J Dermatol* 2019;180:122–9.