



HAL
open science

Hypomorphic mutation in SFTPb leads to adult pulmonary fibrosis

Tifenn Desroziers, Grégoire Prévot, Aurore Coulomb, Valérie Nau, Florence Dastot-Le Moal, Philippe Duquesnoy, Mélanie Héry, Aurélie Le Borgne, Serge Anselem, Marie Legendre, et al.

► **To cite this version:**

Tifenn Desroziers, Grégoire Prévot, Aurore Coulomb, Valérie Nau, Florence Dastot-Le Moal, et al.. Hypomorphic mutation in SFTPb leads to adult pulmonary fibrosis. European Respiratory Society, Sep 2023, Milan (Italie), Italy. inserm-04208358

HAL Id: inserm-04208358

<https://inserm.hal.science/inserm-04208358>

Submitted on 15 Sep 2023

HAL is a multi-disciplinary open access archive for the deposit and dissemination of scientific research documents, whether they are published or not. The documents may come from teaching and research institutions in France or abroad, or from public or private research centers.

L'archive ouverte pluridisciplinaire **HAL**, est destinée au dépôt et à la diffusion de documents scientifiques de niveau recherche, publiés ou non, émanant des établissements d'enseignement et de recherche français ou étrangers, des laboratoires publics ou privés.

Hypomorphic mutation in *SFTPB* leads to adult pulmonary fibrosis

Tifenn Desroziers¹, Grégoire Prévot², Aurore Coulomb³, Valérie Nau⁴, Florence Dastot-Le Moal⁴, Philippe Duquesnoy¹, Mélanie Héry¹, Aurélie Le Borgne², Serge Amselem^{1,4}, Marie Legendre^{1,4,*}, Nadia Nathan^{1,5,*}

(1) Laboratory of childhood genetic diseases, Armand Trousseau Hospital, Sorbonne University and Inserm UMR_S933, Paris, France (2)Respiratory Medicine, Toulouse University Hospital, Toulouse, France. (3)Sorbonne University, Assistance Publique – Hôpitaux de Paris, Pathology department, Armand Trousseau Hospital, Paris, France. (4) Molecular Genetics unit, Laboratory of Childhood genetic diseases, Armand Trousseau Hospital, Sorbonne University, Assistance Publique – Hôpitaux de Paris and Inserm UMS_S933, Paris, France. (5) Pediatric pulmonology department, Reference center for rare lung diseases RespiRare, Laboratory of childhood genetic diseases Inserm UMR_S933, Armand Trousseau Hospital, Sorbonne University and AHP, Paris, France

Introduction

- Surfactant protein (SP)-B deficiency due to bi-allelic pathogenic variation has been associated with fatal forms of interstitial lung diseases (ILD) in newborns and exceptional survival in young children.
- We herein report for the first time two related adults with pulmonary fibrosis due to a homozygous *SFTPB* variation.
- The aim of the study was to investigate the pathogenicity effect of the variation c.582G>A p.(Gln194=)

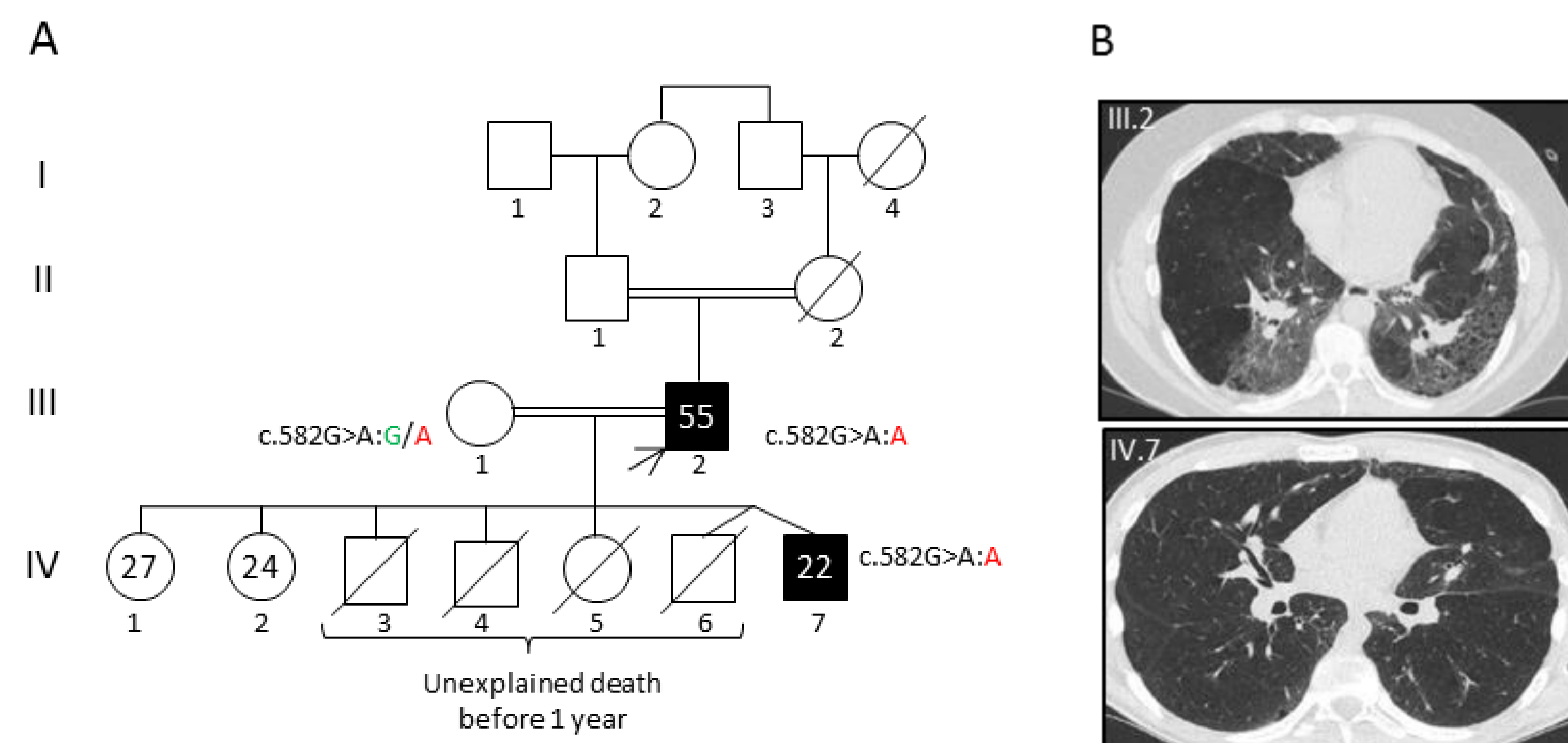
Methods

- *In vitro* transcription analysis of the variation c.582G>A : overexpression of *SFTPB* genomic constructs spanning exon 4 to 6 (NM_000542.5), WT or mutated in A549 cells. Analysis by electrophoresis and Sanger sequencing of the cDNA obtained by RT-PCR.
- *Ex vivo* studies : Haematoxylin & eosin (HE) stainings and immunostaining targeting SP-B and SP-C assessed on biopsy of native lung explant of the proband.

Results

Case presentation

- The proband, homozygous for the variation (Fig.1A), presented a fibrosing ILD at 34 years. His thoracic CT-scan showed ground glass opacities and fibrosis. He received a bi-pulmonary transplantation at 51 years (Fig.1B).
- Proband's son, also homozygous for the variation (Fig.1A) presented alveolo-interstitial opacities and mild alveolar hemorrhage at 10 months. His thoracic CT-scan at 16 years showed mild ground glass opacities and mild ILD at 22 years (Fig.1B).



Impact of the variation c.582G>A p.(Gln194=)

- *In vitro* transcription analysis of the variation revealed an abnormal splicing with a persistence of correct spliced amplicons as observed for the WT (Fig.2).
- HE staining of lung proband showed fibroblastic foci with an usual interstitial pneumonia pattern. Lung neonate presented thickened septa and normal healthy controls presented normal parenchyma (Fig.3).
- Both SP-B and SP-C expression were altered for the proband. SP-B staining showed an almost complete loss of SP-B expression for the proband, an absence of expression for the SP-B-deficient neonate and normal expression for controls. SP-C/proSP-C was highly detected for the proband and neonate as compared to the controls (Fig.3).

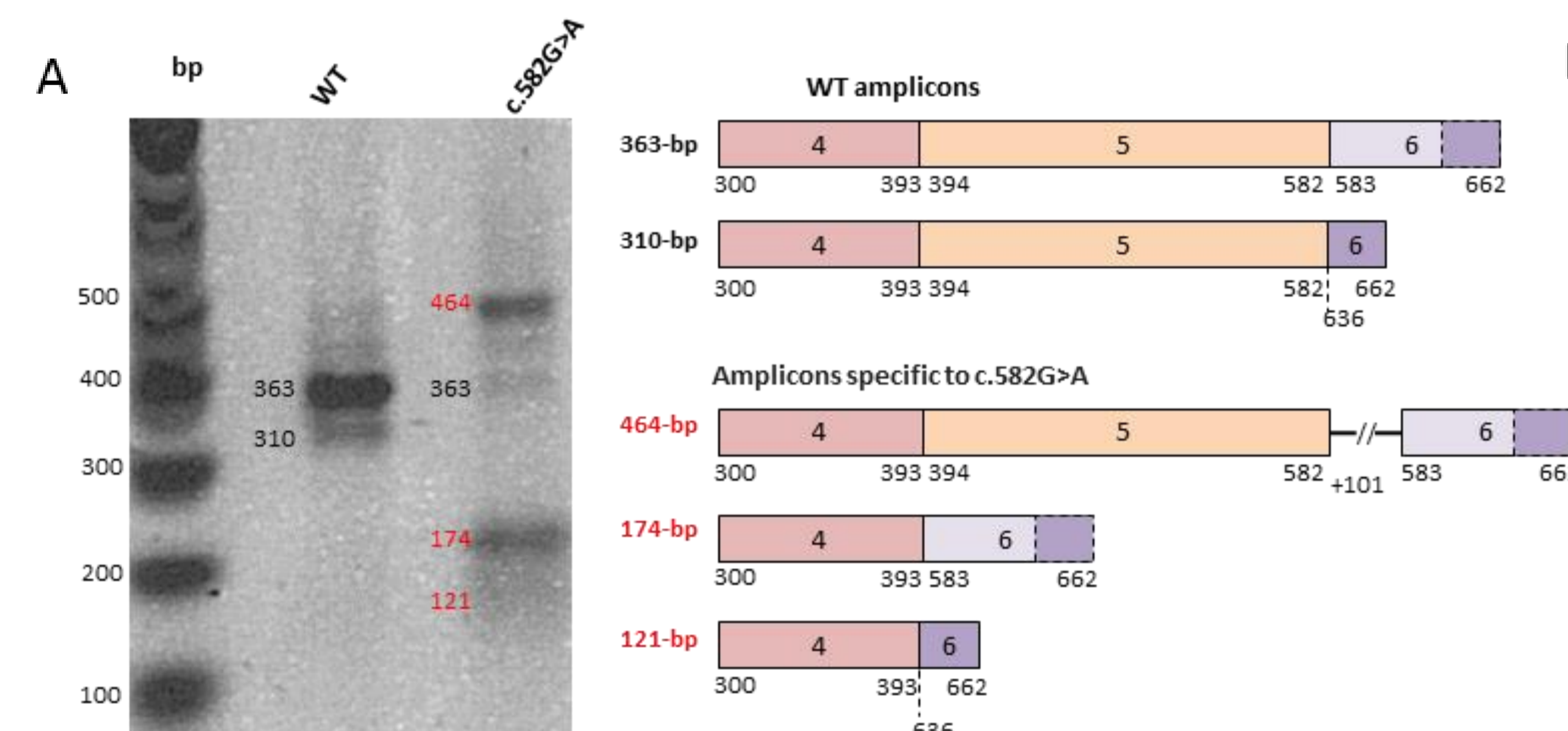


Figure 2 : (A) Agarose-BET gel of amplicons obtained by RT-PCR on RNAs from normal and mutant constructs expression. (B) Schematic representation of amplicons characterized by Sanger sequencing and corresponding to the fragments observed on agarose gel.

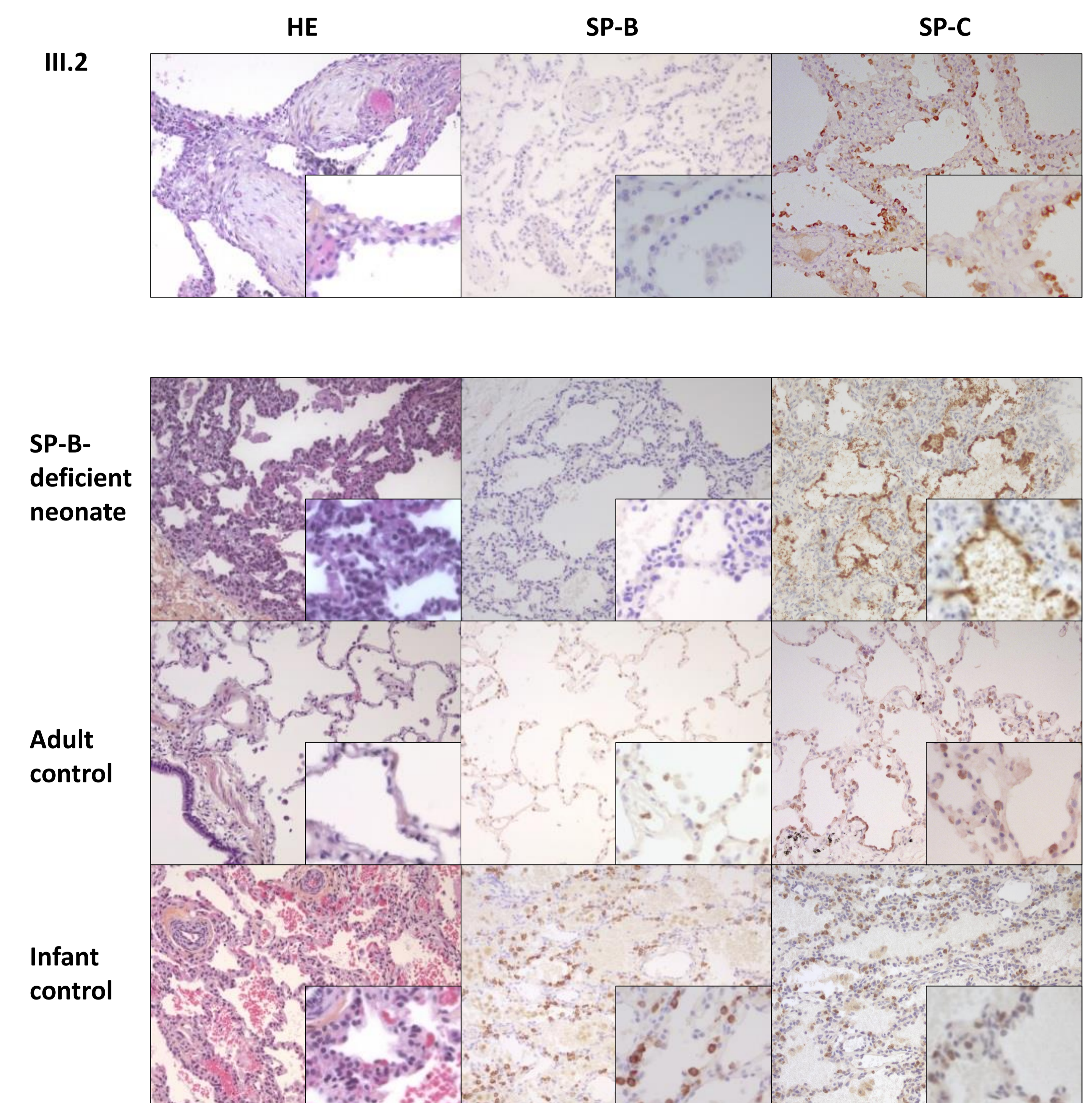


Figure 3 : The native lung explant examination of the proband (III.2) using Haematoxylin and eosin (HE) staining, SP-B and SP-C staining (magnification x20 and x40).

Conclusion and perspectives

- The pathogenic variation c.582G>A p.(Gln194=) affected drastically splicing as well as SP-B and SP-C expression. However an hypomorphic effect, illustrated by the persistence of correct splicing and leading to a residual SP-B expression, could explain the long-term survival with fibrosing ILD in the two related adults.
- These findings lead to considered *SFTPB* variants in atypical presentations of ILD particularly in a familial context.

