



HAL
open science

Persistent retro-orbital pain after acute otitis media

Romain Tournegros, Stéphane Tringali, Maxime Fieux

► **To cite this version:**

Romain Tournegros, Stéphane Tringali, Maxime Fieux. Persistent retro-orbital pain after acute otitis media. *European Annals of Otorhinolaryngology, Head and Neck Diseases*, 2023, 140 (5), pp.247-249. <10.1016/j.anorl.2023.03.005>. <inserm-04169656>

HAL Id: inserm-04169656

<https://inserm.hal.science/inserm-04169656v1>

Submitted on 24 Jul 2023

HAL is a multi-disciplinary open access archive for the deposit and dissemination of scientific research documents, whether they are published or not. The documents may come from teaching and research institutions in France or abroad, or from public or private research centers.

L'archive ouverte pluridisciplinaire HAL, est destinée au dépôt et à la diffusion de documents scientifiques de niveau recherche, publiés ou non, émanant des établissements d'enseignement et de recherche français ou étrangers, des laboratoires publics ou privés.



HAL Authorization



HAL
open science

Persistent retro-orbital pain after acute otitis media

R. Tournegros, S. Tringali, M. Fieux

► **To cite this version:**

R. Tournegros, S. Tringali, M. Fieux. Persistent retro-orbital pain after acute otitis media. *European Annals of Otorhinolaryngology, Head and Neck Diseases*, 2023, 10.1016/j.anorl.2023.03.005 . inserm-04169656

HAL Id: inserm-04169656

<https://inserm.hal.science/inserm-04169656>

Submitted on 24 Jul 2023

HAL is a multi-disciplinary open access archive for the deposit and dissemination of scientific research documents, whether they are published or not. The documents may come from teaching and research institutions in France or abroad, or from public or private research centers.

L'archive ouverte pluridisciplinaire **HAL**, est destinée au dépôt et à la diffusion de documents scientifiques de niveau recherche, publiés ou non, émanant des établissements d'enseignement et de recherche français ou étrangers, des laboratoires publics ou privés.

Persistent retro-orbital pain after acute otitis media

Romain Tournegros ¹; Stephane Tringali ^{1,2,3}; Maxime Fieux ^{1,2,4,5*}

1. Hospices Civils de Lyon, Centre Hospitalier Lyon Sud, Service d'ORL, d'Otoneurochirurgie et de Chirurgie Cervico-Faciale, 69310 Pierre Bénite, France

2. Université de Lyon, Université Lyon 1, 69003 Lyon, France

3. UMR 5305, Laboratoire de Biologie Tissulaire et d'Ingénierie Thérapeutique, Institut de Biologie et Chimie des Protéines, CNRS/Université Claude Bernard Lyon 1, 7 Passage du Vercors, cedex 07, 69367 Lyon, France

4. Univ Paris Est Créteil, INSERM, IMRB, 94010 Créteil, France

5. CNRS EMR 7000, 94010 Créteil, France

*** Corresponding author.**

E-mail: maxime.fieux@chu-lyon.fr (Maxime Fieux)

Service d'Otologie et d'Otoneurologie, Hospices Civils Lyon, Centre Hospitalier Lyon Sud, 165 Chemin du Grand Revoyet, 69310 Pierre-Bénite, France

1. Description

A 36 year-old woman presented in ENT with progressive left retro-orbital pain without fever. She had no relevant medical history, except for a recent episode of left acute otitis media treated with pristinamycin 3g daily for 5 days; no rationale could be found for this specific treatment, reserved for cases in which beta-lactam is contraindicated. As intense left retro-orbital pain persisted, an ENT consultation was set up. There were no associated otologic or neurologic functional signs, or fever; cranial nerve examination was normal. Pure-tone audiometry was normal in the right ear; the left ear showed slight sensorineural hearing loss specifically at high frequency (40dB and 25dB thresholds: 4,000Hz and 8,000Hz, respectively) and correspondingly impaired speech audiometry. Given persistent pain despite well-conducted treatment and the unilateral hearing loss, contrast-enhanced brain MRI centered on the inner auditory canals was requested. Two gadolinium-enhanced T1 axial slices are shown in figure 1A and 1B, at the inner auditory canal and the petrous apex, respectively. Figures 1C and 1D respectively show axial and coronal CT slices at the left temporal bone. Treatment is shown in the accompanying video.

2. Question

What is your diagnosis?

3. Reply

This was a case of left petrous apicitis with abscess secondary to acute otitis media (AOM) with effusion, associated with incidental discovery of a right vestibular schwannoma. Symptomatology may be insidious or may progress to the classical if rare Gradenigo's syndrome (1), a triad associating AOM with effusion, ipsilateral abducens palsy and facial pain in the trigeminal region. Pathophysiology depends on the degree of temporal bone pneumatization, either by direct contiguity secondary to middle ear infection, with the temporal bone pneumatized as in the present case, or by hematogenic propagation, with the bone less severely pneumatized. Clinical abnormalities other than AOM, which may be absent, are rare, especially in the early phase of infection. Fever is found in 18% of cases, but pain is more frequent and suggests diagnosis: 55% trigeminal pain and 66% diffuse headache (2). Imaging is thus essential for diagnosis and treatment of petrous apicitis, with MRI in first line. Inner auditory canal MRI found a lesion in T1 hyposignal with cockade contrast uptake at the left petrous apex, and nodular uptake at the fundus of the right inner auditory canal. Subsequent temporal bone CT to analyze bone involvement and contribute to preoperative work-up confirmed the absence of retrotympanic effusion and revealed left petrous apex opacity without signs of osteolysis or labyrinthine capsule involvement. Given the absence of AOM, a transmastoid approach to the left petrous abscess was performed. After skeletonization of the bony labyrinth, reaming behind the superior semicircular canal and above the posterior semicircular canal achieved abscess drainage, and pus was sampled for bacteriology (see video). The samples revealed multi-sensitive *Streptococcus pneumoniae*, and oral amoxicillin therapy was conducted for 10 days, with complete pain relief. Complementary screening for underlying immune deficiency proved negative, and control CT showed complete disappearance of apicitis.

Diagnosis is made difficult by the high prevalence of this entity and its asymptomatic or weakly symptomatic forms. At diagnosis, 38% of patients show no AOM, although it is present in recent history (2). Our patient had been treated by antibiotic therapy for AOM 3 weeks previously, but her retro-orbital pain was isolated. Normal clinical findings, notably for the cranial nerves, can be misleading and delay diagnosis if MRI is not performed. MRI shows T1 hyposignal, T2 hypersignal and peripheral gadolinium uptake (3). It also screens for intracranial or sinus/dural complications. CT without enhancement provides good assessment of petrous apex bone involvement, and guides the choice of surgical approach, as apicitis shows as an expansive lesion without contrast-medium uptake. Imaging is essential for diagnosis and treatment of petrous apicitis. Management is controversial; in case of apical abscess without otitis media, however, surgery is mandatory, the approach depending on pneumatization.

The imaging aspect may suggest other diagnoses, to be ruled out clinically, biologically and possibly by intraoperative sampling: e.g., certain petrous apex tumors (squamous cell carcinoma, lymphoma, metastasis), inflammatory pseudo-tumor, cholesterol granuloma, tuberculosis or sarcoidosis (2). It is important to take several intraoperative samples, to prevent misdiagnosis.

Bacteriology uses either paracentesis in case of associated AOM or else abscess drainage, preferably ahead of antibiotic therapy. Broad-spectrum probabilistic antibiotic therapy is recommended, with secondary targeting according to the antibiogram. The most frequent bacteria are *Pseudomonas aeruginosa*, *Staphylococcus aureus* and *Streptococcus pneumoniae* (4). Petrous apicitis is rare but life-threatening, associated with an acute or chronic inflammatory process in the temporal bone (1). Gradenigo's syndrome is now rare, thanks to early diagnosis on imaging and widespread use of antibiotics (5). The most frequent clinical symptoms are severe retro-orbital pain (55%) and AOM with effusion (62%); abducens palsy (16%) and the complete Gradenigo triad (14%) are much rarer (1).

Disclosure of interest

The authors have no conflicts of interest to disclose.

References

1. Savasta S, Canzi P, Aprile F, et al. Gradenigo's syndrome with abscess of the petrous apex in pediatric patients: what is the best treatment? *Childs Nerv Syst.* 2019;35(12):2265- 72.
2. Gadre AK, Chole RA. The changing face of petrous apicitis-a 40-year experience: The Changing Face of Petrous Apicitis. *The Laryngoscope.* 2018;128(1):195- 201.
3. Karkas A, Righini CA, Spinato L, et al. Lésions de l'apex pétreux. *Ann Otolaryngol Chir Cervico-Faciale.* 2009;126(5- 6):283- 93.
4. Talmor G, Vakil M, Tseng C, et al. Petrous Apicitis: A Systematic Review and Case Presentation. *Otol Neurotol.* 2022;43(7):753- 65.
5. McLaren J, Cohen MS, El Saleeby CM. How well do we know Gradenigo? A comprehensive literature review and proposal for novel diagnostic categories of Gradenigo's syndrome. *Int J Pediatr Otorhinolaryngol.* 2020;132:109942.

Figure 1. Contrast-enhanced inner auditory canal MRI, T1 sequence (A and B); and left temporal bone CT, axial (A) and coronal slice (B).

Video 1. Surgical drainage via transmastoid retrolabyrinthine approach

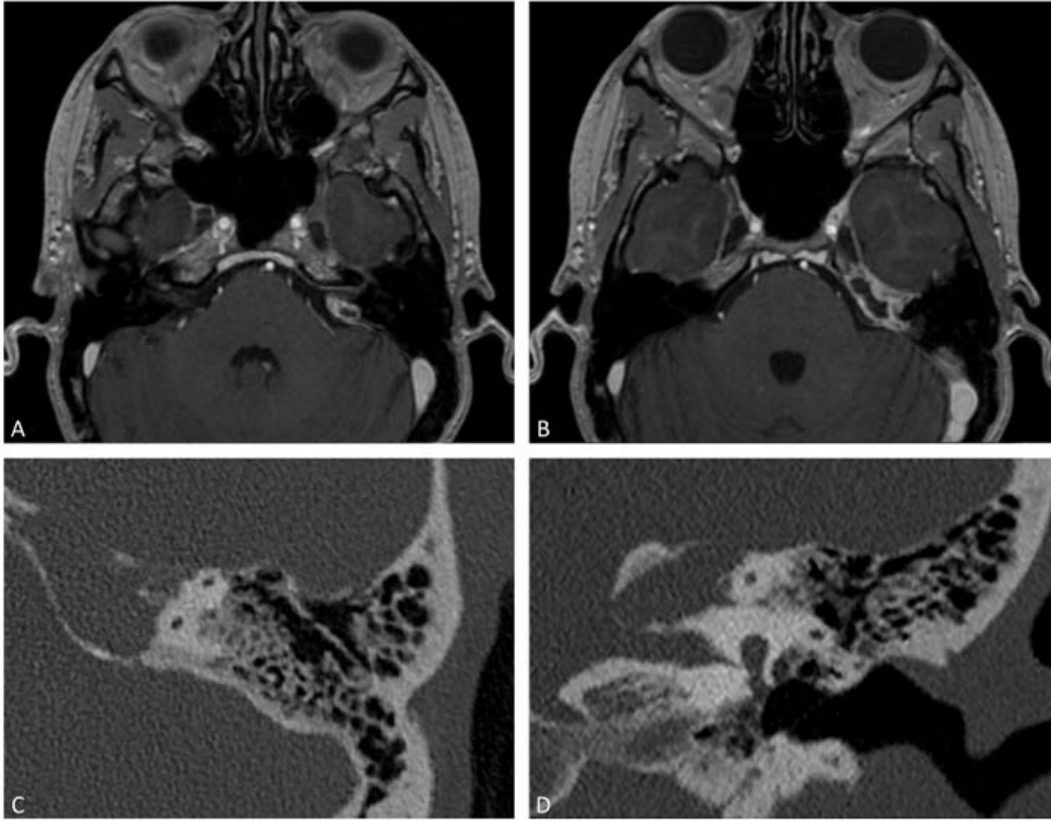


Fig. 1. Contrast-enhanced inner auditory canal MRI, T1 sequence (A and B); and left temporal bone CT, axial (A) and coronal slice (B).