



HAL
open science

Incomplete Hippocampal Inversion and hippocampal subfield volumes: Implementation and inter-reliability of automatic segmentation

Agustina Fragueiro, Giorgia Committeri, Claire Cury

► To cite this version:

Agustina Fragueiro, Giorgia Committeri, Claire Cury. Incomplete Hippocampal Inversion and hippocampal subfield volumes: Implementation and inter-reliability of automatic segmentation. ISBI 2023 - IEEE International Symposium on Biomedical Imaging, Apr 2023, Carthagène des Indes, Colombia. IEEE, pp.1, 2023. inserm-04085099

HAL Id: inserm-04085099

<https://inserm.hal.science/inserm-04085099v1>

Submitted on 28 Apr 2023

HAL is a multi-disciplinary open access archive for the deposit and dissemination of scientific research documents, whether they are published or not. The documents may come from teaching and research institutions in France or abroad, or from public or private research centers.

L'archive ouverte pluridisciplinaire **HAL**, est destinée au dépôt et à la diffusion de documents scientifiques de niveau recherche, publiés ou non, émanant des établissements d'enseignement et de recherche français ou étrangers, des laboratoires publics ou privés.

Incomplete Hippocampal Inversion and hippocampal subfield volumes: Implementation and inter-reliability of automatic segmentation

INTRODUCTION

The incomplete hippocampal inversion (IHI) is an atypical anatomical pattern [1], that is more prevalent in epilepsy and it is a factor of susceptibility for hippocampal sclerosis [2]. However, the hippocampus consists of distinct and functionally segregated subfields. Although their segmentation is challenging due to the small size and lack of contrast, there are algorithms allowing their automatic segmentation.

Aims

→ Testing the inter-method (i.e. ASHS and FreeSurfer) reliability for volumetric analysis using automatic segmentation of hippocampal subfields.

→ Exploring the relationship between IHI scores and hippocampal subfields' volumes extracted with both ASHS and FreeSurfer methods.

METHOD AND MATERIALS

Participants. Preprocessed 3T T1w-MRI scans belonging to a total of 390 healthy young adults (age=26-30, 217 F) have been downloaded from the Human Connectome Dataset WU-Minn [3].

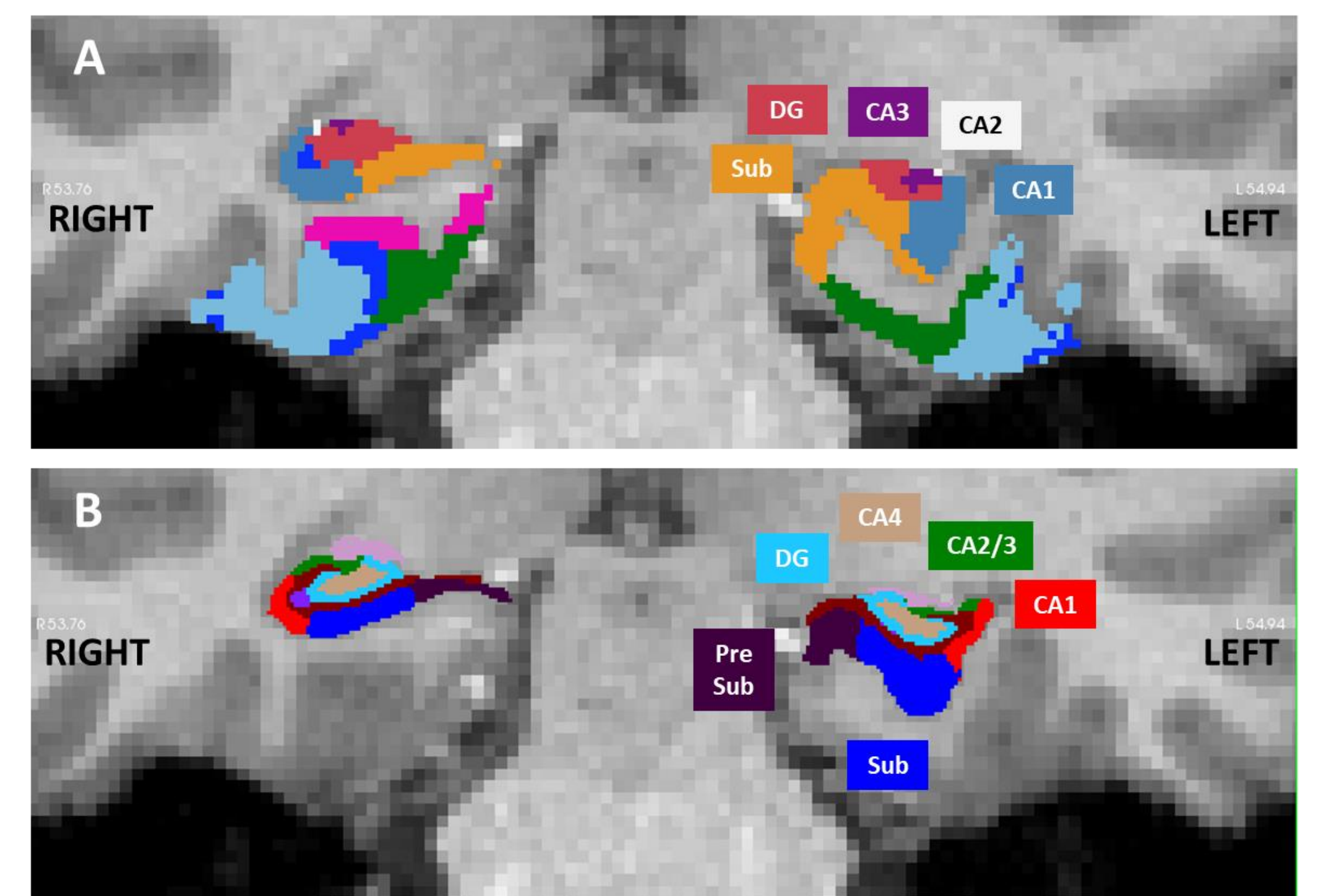
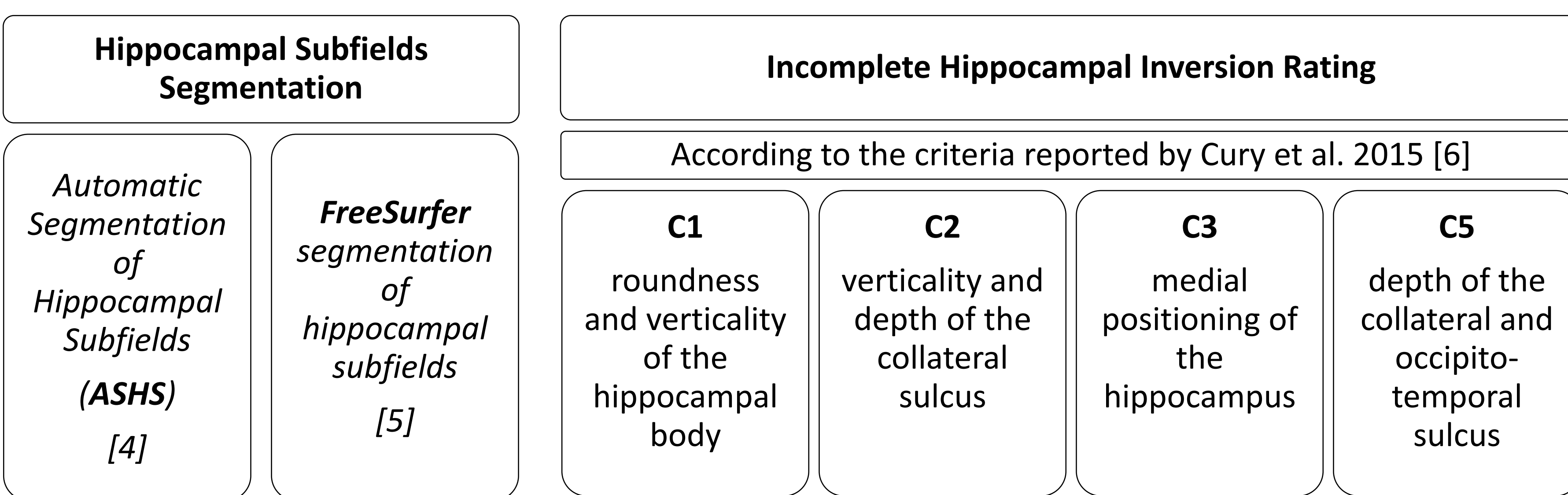


Figure 1. Coronal view of segmentations obtained with: A) ASHS, and B) FreeSurfer at the hippocampal body level. The left hippocampus was classified as IHI while the right as no IHI.

As subfields definition differed among methods, we first combined the subfields by summing their volumes to obtain four common subfields: CA1, CA2/3, subiculum (including presubiculum and parasubiculum), tail.

RESULTS

- Correlations between volumes obtained through both segmentation methods were significant for all common subfields and whole hippocampus (all $p < 0.001$).
- Significant differences between volumes extracted with ASHS vs FreeSurfer (all $p < 0.001$).

- Subiculum volumes were higher for IHI comparing to not IHI hippocampi bilaterally (Left: $U=8442$, $p < 0.001$; Right: $U=3112$, $p < 0.001$).

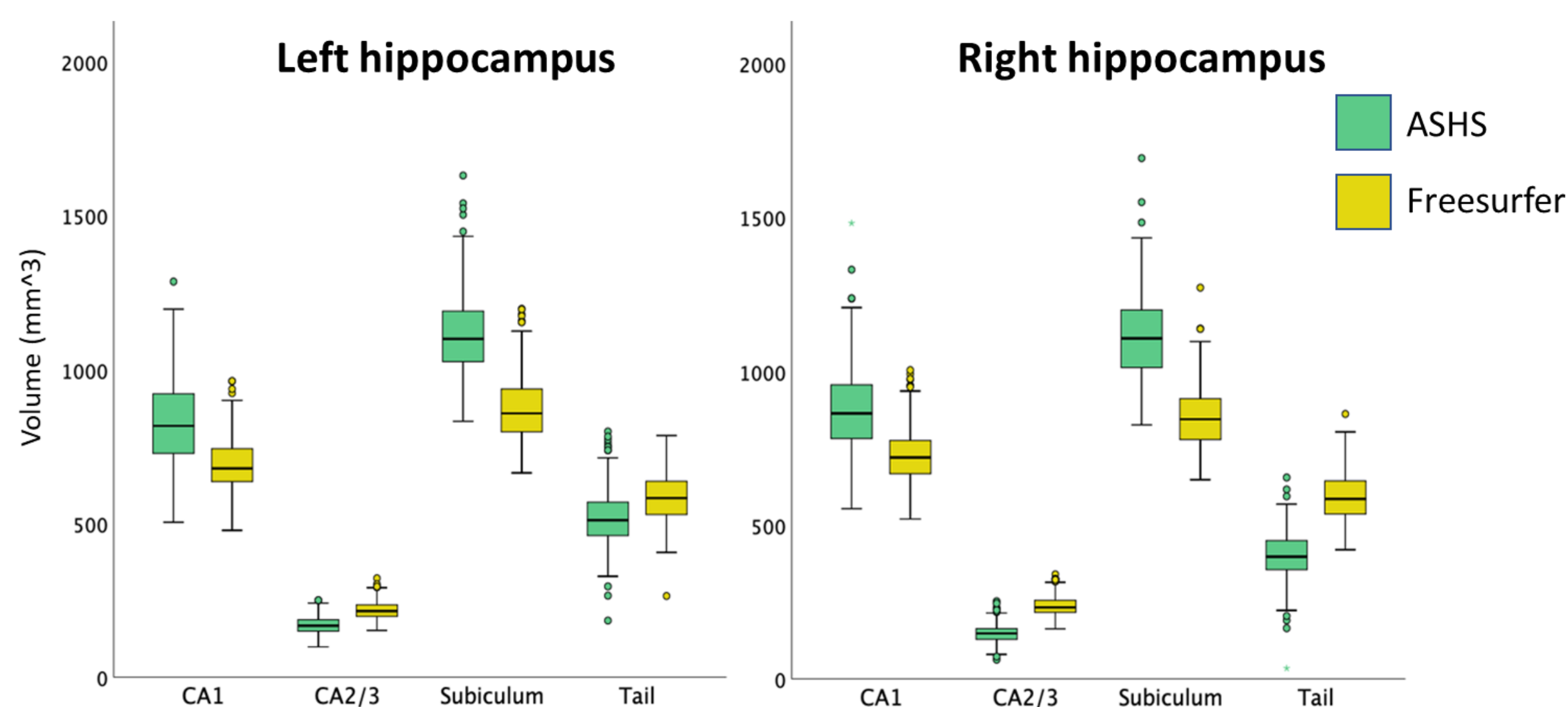


Figure 2. Boxplot comparing subfield volumes segmented with ASHS vs. FreeSurfer.

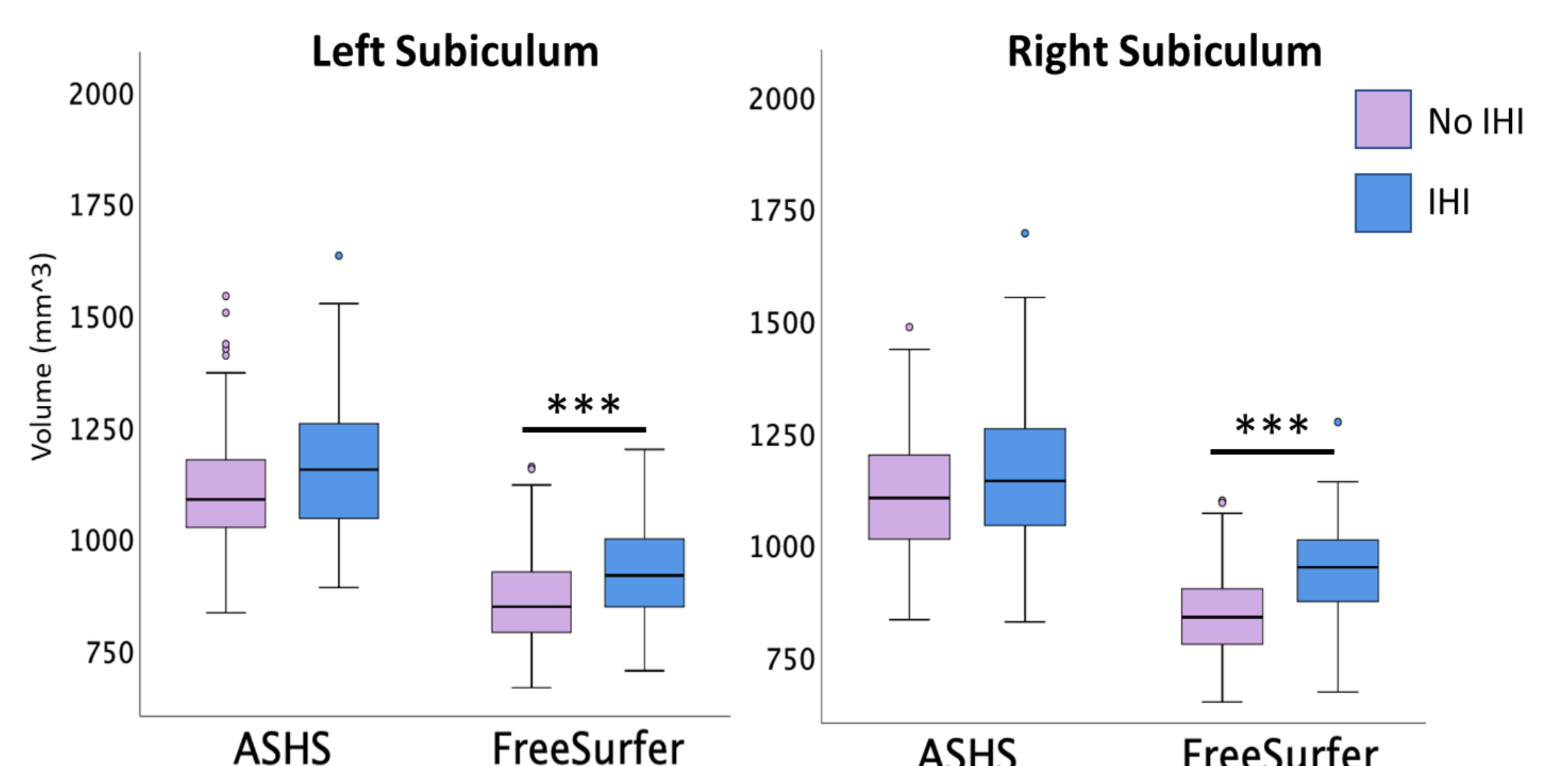


Figure 3.

Boxplot comparing subiculum volumes between IHI and no IHI hippocampus for both ASHS and FreeSurfer methods.

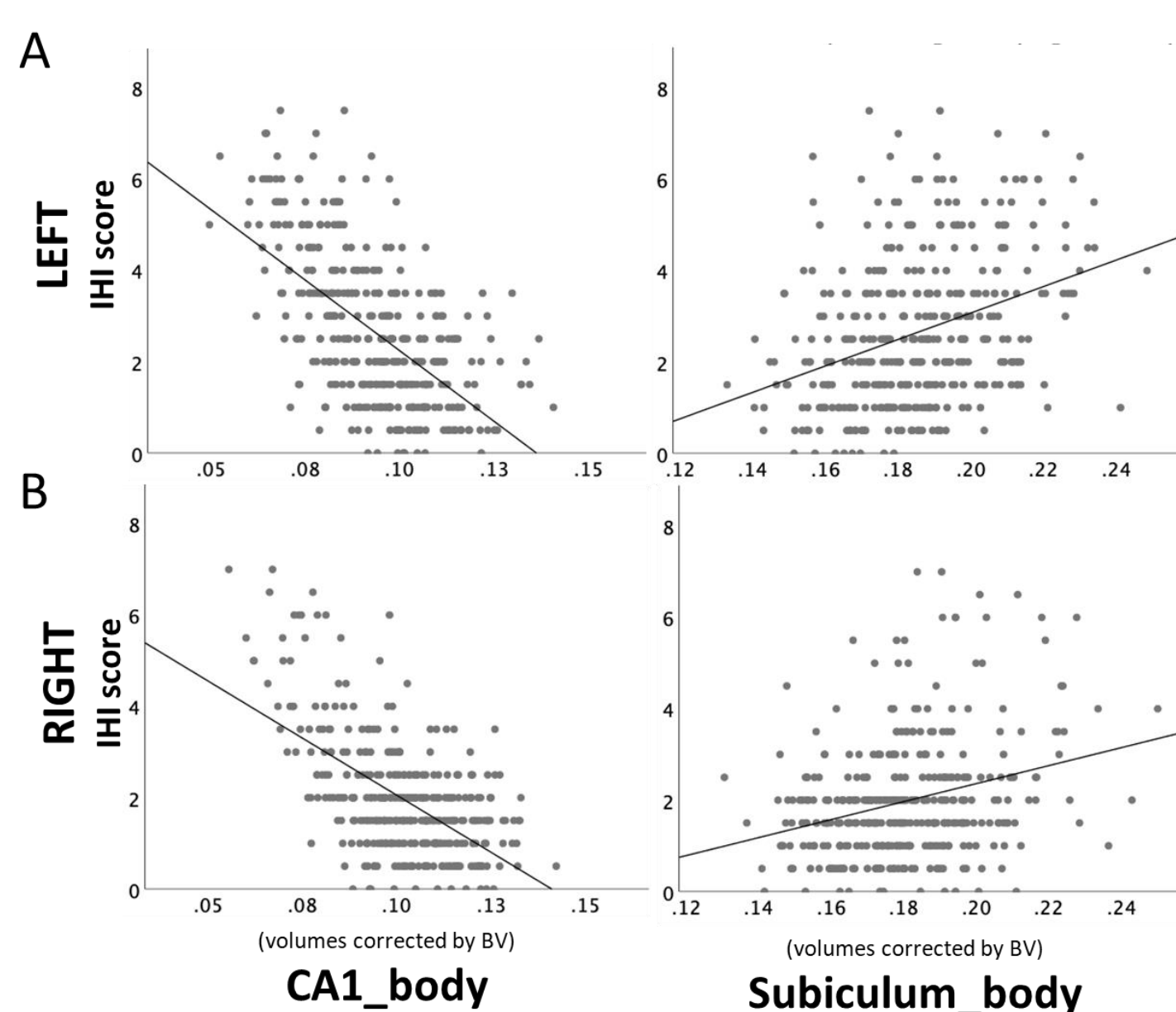


Figure 4. Scatterplot of CA1 and subiculum volumes at the level of the hippocampal body, extracted with FreeSurfer, in relationship to IHI scores for left (A) and right (B) hemispheres.

Two regression models including IHI scores as dependent variable and subfield volumes as independent variables:

Volumes extracted with ASHS:

- Model significant bilaterally (Left: $R^2=0.23$, $p=0.005$; Right: $R^2=0.168$, $p=0.025$).
- Smaller CA2** (Left: $\beta = -0.398$, $p < 0.001$; Right: $\beta = -0.26$, $p < 0.001$) and **CA1** (Left: $\beta = -0.174$, $p=0.094$; Right: $\beta = -0.254$, $p < 0.001$) volumes were associated to IHI severity.

Volumes extracted with FreeSurfer:

- Model significant bilaterally (Left: $R^2=0.537$, $p=0.014$; Right: $R^2=0.508$, $p=0.027$).
- Smaller CA1** (Left: $\beta = -0.477$, $p < 0.001$; Right: $\beta = -0.435$, $p < 0.001$) and **bigger subiculum** (Left: $\beta = 0.441$, $p < 0.001$; Right: $\beta = 0.398$, $p < 0.001$) volumes, both of them exclusively at the level of the hippocampal body, were associated to higher IHI scores.

Although volumes extracted from common subfields differed among methods due to the different atlas used, they highly correlated between methods. Higher IHI scores were associated to bigger subiculum and smaller CA volumes.

References

[1] D. Bajic et al., "Incomplete inversion of the hippocampus—a common developmental anomaly," *Eur Radiol*, vol. 18, no. 1, pp. 138–142, Jan. 2008.

[2] N. Bernasconi, D. Kinay, F. Andermann, S. Antel, and A. Bernasconi, "Analysis of shape and positioning of the hippocampal formation: an MRI study in patients with partial epilepsy and healthy controls," *Brain*, vol. 128, no. 10, pp. 2442–2452, Oct. 2005.

[3] D. C. Van Essen, S. M. Smith, D. M. Barch, T. E. J. Behrens, E. Yacoub, and K. Ugurbil, "The WU-Minn Human Connectome Project: An overview," *NeuroImage*, vol. 80, pp. 62–79, Oct. 2013.

[4] P. A. Yushkevich et al., "Automated volumetry and regional thickness analysis of hippocampal subfields and medial temporal cortical structures in mild cognitive impairment: Automatic Morphometry of MTL Subfields in MCI," *Hum. Brain Mapp.*, vol. 36, no. 1, pp. 258–287, Jan. 2015.

[5] J. E. Iglesias et al., "A computational atlas of the hippocampal formation using ex vivo, ultra-high resolution MRI: Application to adaptive segmentation of in vivo MRI," *NeuroImage*, vol. 115, pp. 117–137, Jul. 2015.

[6] C. Cury et al., "Incomplete Hippocampal Inversion: A Comprehensive MRI Study of Over 2000 Subjects," *Front. Neuroanat.*, vol. 9, Dec. 2015.