



HAL
open science

Infections and AA amyloidosis: An overview

Samuel Deshayes, Achille Aouba, Gilles Grateau, Sophie Georgin-lavialle

► **To cite this version:**

Samuel Deshayes, Achille Aouba, Gilles Grateau, Sophie Georgin-lavialle. Infections and AA amyloidosis: An overview. *International Journal of Clinical Practice*, 2021, 75 (6), pp.e13966. 10.1111/ijcp.13966 . inserm-04050338

HAL Id: inserm-04050338

<https://inserm.hal.science/inserm-04050338v1>

Submitted on 12 May 2023

HAL is a multi-disciplinary open access archive for the deposit and dissemination of scientific research documents, whether they are published or not. The documents may come from teaching and research institutions in France or abroad, or from public or private research centers.

L'archive ouverte pluridisciplinaire **HAL**, est destinée au dépôt et à la diffusion de documents scientifiques de niveau recherche, publiés ou non, émanant des établissements d'enseignement et de recherche français ou étrangers, des laboratoires publics ou privés.



Distributed under a Creative Commons Attribution 4.0 International License

NON-SYSTEMATIC REVIEW
INFECTIOUS DISEASES

Infections and AA amyloidosis: An overview

Samuel Deshayes¹  | Achille Aouba¹  | Gilles Grateau²  | Sophie Georjin-Lavialle² 

¹Service de médecine interne, Normandie University, UNICAEN, CHU de Caen Normandie, Caen, France

²Sorbonne Université, Service de médecine interne, GRC-28 (GRAASU), Centre national de référence des maladies autoinflammatoires et des amyloses inflammatoires (CEREMAIA), hôpital Tenon, AP-HP, Paris, France

Correspondence

Sophie Georjin-Lavialle, Service de médecine interne, Sorbonne Université, GRC-28 (GRAASU), Centre national de référence des maladies autoinflammatoires et des amyloses inflammatoires (CEREMAIA), hôpital Tenon, AP-HP, 75020 Paris, France. Email: sophie.georjin-lavialle@aphp.fr

Abstract

Background: Amyloidoses are a heterogeneous group of systemic diseases characterised by extracellular accumulation of insoluble amyloid fibrils derived from unfolded proteins. Inflammatory (AA) amyloidosis can complicate various inflammatory disorders that are associated with a sustained acute phase response and serum amyloid A (SAA) protein overproduction. Chronic infections were the first recognised cause of amyloidoses. However, with the better management of underlying diseases, the frequency of AA amyloidosis is decreasing.

Purpose: The aim of this overview was to discuss the several infections associated with AA amyloidosis and the relative frequency of infections as aetiological factors.

Methods: A search of the literature was performed using the PubMed database using the MeSH terms “Amyloidosis” and “Infections,” from inception to December 31st, 2019. Articles written in other languages than English or French were excluded.

Results: The frequency of AA amyloidosis secondary to infections decreased from more than 50% to less than 20% after the 2000s, with a parallel increase in the frequency of AA amyloidosis secondary to inflammatory diseases and to an unknown cause.

Conclusion: Whereas new antibiotics have been developed and sanitary conditions are better, infections still represent 5%-30% of the causes of AA amyloidosis, including in developed countries. These data argue for better screening of chronic infections to prevent AA amyloidosis and the development of new strategies to manage recurrent infections.

1 | INTRODUCTION

AA amyloidosis is characterised by the deposits of an amorphous substance including fragments of the serum amyloid-associated (SAA) protein. As SAA is an acute-phase reactant, several diseases with long-standing inflammation may be complicated by AA amyloidosis, such as chronic idiopathic inflammatory diseases, autoinflammatory diseases, cancers, and chronic infections.¹⁻³

The first described cases of amyloidosis were of the AA type, secondary to chronic infections.⁴ However, with the better management of underlying diseases, the frequency of AA amyloidosis is decreasing in favour of AL and ATTR amyloidosis.⁵⁻⁷

The aim of this overview was to discuss the several infections associated with AA amyloidosis and the relative frequency of infections as aetiological factors.

2 | METHODS

Material for this narrative review was found by searching the PubMed database using the MeSH terms “Amyloidosis” and “Infections,” from inception to December 31st, 2019. Articles were included if they reported patients suffering from AA amyloidosis or presumed reactive amyloidosis and an identified infection or a situation associated with recurrent infections, as well as the

main case series with more than 100 patients. Articles written in other languages than English or French were excluded. Relevant articles within the reference lists of the retrieved articles were also included.

3 | INFECTIONS ASSOCIATED WITH AA AMYLOIDOSIS

3.1 | Mycobacteria

Most cases of AA amyloidosis secondary to infections are, or at least were, secondary to mycobacteria (Figure 1).

Indeed, before the introduction of efficient tuberculosis therapy, tuberculosis accounted for more than half of the cases of secondary amyloidosis.⁸⁻¹¹ In addition, tuberculosis can be complicated by secondary amyloidosis in 5% of cases.¹² Tuberculosis remains an important cause of AA amyloidosis in endemic countries; therefore, more than one-third of renal amyloidosis in a Turkish study published in 1995 is secondary to tuberculosis.¹³ Nontuberculous mycobacterial infections are exceptionally reported.^{14,15}

Similarly, leprosy could be complicated by amyloidosis in 2%-55% of patients, especially in cases of lepromatous leprosy,¹⁶⁻²⁰ but this cause is currently exceptional.

3.2 | Bacteria

Before the mid-19th century, syphilis was a classic cause of amyloidosis.^{9,21-26}

Several cases of amyloidosis secondary to Whipple disease have been published, including recently.²⁷⁻³³

More commonly, focal chronic infection with any bacteria can be complicated by amyloidosis, such as chronic osteomyelitis,³⁴⁻³⁸ chronic pyelonephritis, untreated abscess in any location, prosthetic infections or endocarditis.^{22-24,39-49}

Review criteria

- Infections associated with AA amyloidosis were reviewed following the retrieval of relevant articles from PubMed.

Message for the clinic

- The frequency of AA amyloidosis secondary to infections is decreasing.
- However, infections still represent 5%-30% of the causes of AA amyloidosis.
- Better screening of chronic infections and the development of strategies to manage recurrent infections are needed.

More anecdotally, other chronic infections have rarely been associated with secondary amyloidosis, such as Q fever^{50,51} and brucellosis.^{52,53}

3.3 | Parasites

The most frequently reported parasitic cause of AA amyloidosis is schistosomiasis,⁵⁴⁻⁵⁹ but evidence of this remains highly anecdotal.

Other parasitic infections are much less frequently reported, such as echinococcosis,^{5,60-63} giardiasis,⁶⁴ leishmaniasis,^{65,66} malaria,^{67,68} and filariasis.⁶⁹

3.4 | Viruses

Very few viruses have been associated with AA amyloidosis. Human immunodeficiency virus (HIV) is the most frequently

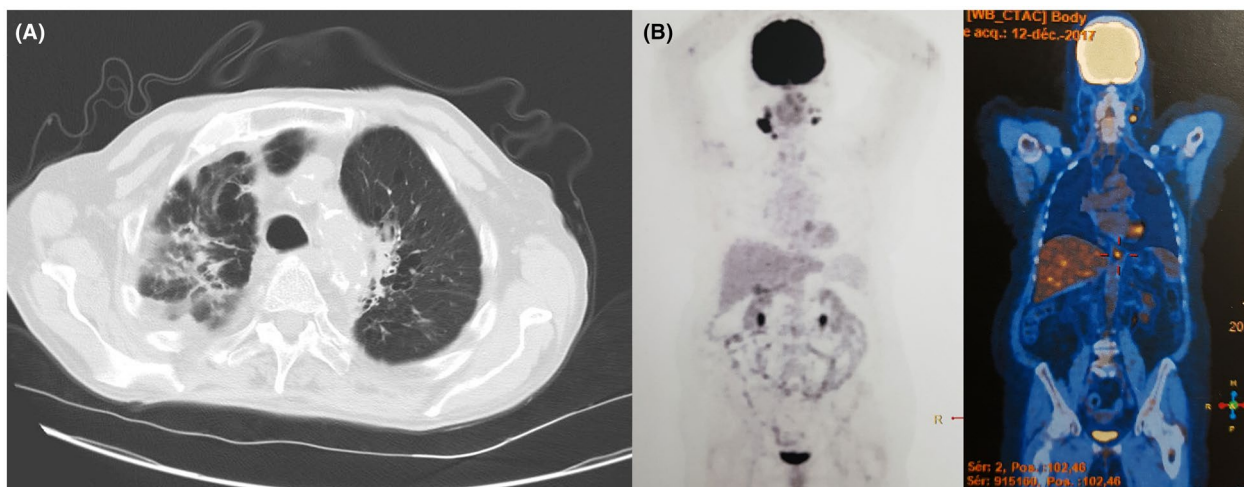


FIGURE 1 Illustrative cases of pulmonary tuberculosis with bronchiectasis on chest computed tomography scans (A) and lymph node tuberculosis on ¹⁸F-fluorodeoxyglucose coupled with computed tomography scans (B) responsible for AA amyloidosis

reported.^{42,65,70-76} Therefore, amyloidosis can be responsible for up to 10% of kidney diseases in HIV,⁷⁷ but whether this association is secondary to infections induced by immunodeficiency or coinfections or to the virus that is responsible for the chronic inflammation remains to be determined.

Few cases of AA amyloidosis associated with hepatitis B infection have been published.⁷⁸⁻⁸¹ Regarding cases of AA amyloidosis associated with hepatitis C, patients often have coinfections and/or are drug addicts, making it difficult to ascertain the specific role of hepatitis C.⁸²

3.5 | Fungi

Regarding fungi, most of the data are related to aspergillosis,⁸³⁻⁸⁸ but several of these amyloidosis cases could be secondary to bronchiectasis induced by aspergillosis rather than aspergillosis itself. AA amyloidosis has also, seldomly, been associated with coccidioidomycosis,⁴⁵ actinomycosis,^{21,89,90} and mucormycosis.⁹¹

3.6 | Other situations associated with recurrent infections

Apart from chronic infections, several situations associated with recurrent infections can also be complicated by AA amyloidosis. Indeed, drug abuse is responsible for recurrent infections, especially in patients with skin infections because of subcutaneous injection (known as "skin popping").⁹²⁻⁹⁸ Therefore, as many as 14% of subcutaneous drug users have reactive amyloidosis,⁹⁹ 100% of cases of renal AA amyloidosis in a hospital from San Francisco

from 1998 to 2013 were secondary to skin popping,⁸² and 30%-50% of renal diseases in heroin abusers were secondary to amyloidosis.^{70,95} These patients are also frequently hepatitis C or HIV positive.^{70,96,97}

Another situation frequently associated with infections, especially decubitus ulcers and urinary tract infections, is paraplegia.^{23,100-102} Amyloidosis can be found in more than 20% of paraplegic patients at autopsy.^{103,104}

Several diseases predispose patients to recurrent pulmonary infections. Amongst them, bronchiectasis, because of any cause, is the leading cause and represents a substantial percentage of causes of AA amyloidosis,^{105,106} up to 40% of AA amyloidosis in hemodialysis patients in a case series.¹⁰⁷ Regarding other causes, some genetic diseases responsible for recurrent pulmonary infections can be complicated by AA amyloidosis, in part because of secondary bronchiectasis. Therefore, more than 50 cases of AA amyloidosis associated with cystic fibrosis have been reported.¹⁰⁸⁻¹¹⁵ Amyloidosis was found in 0.5% of patients with cystic fibrosis in an Italian study in 1985,¹¹⁶ accounting for approximately one-quarter of the causes of kidney diseases¹¹² and for 1.3% of the causes of death in cystic fibrosis in Italy.¹¹⁷ Kartagener syndrome has also been associated with AA amyloidosis.¹¹⁸⁻¹²⁰

Similarly, several primary immunodeficiencies have been associated with AA amyloidosis, including common variable immunodeficiency,¹²¹⁻¹³⁰ X-linked agammaglobulinemia,¹³¹⁻¹³⁴ cyclic neutropenia,¹³⁵ chronic granulomatous disease,^{84,136,137} hyperimmunoglobulin E syndrome,¹³⁸ and leucocyte adhesion deficiency.¹³⁹

We can also mention recurrent skin infections^{39,45,140-145} and recurrent exacerbation of chronic pulmonary obstructive disease.¹⁴⁶⁻¹⁴⁸

TABLE 1 Frequencies of different causes of secondary amyloidosis in the main case series from the literature with more than 100 patients

First author [Ref.]	Country	Sample size	Period	Infections	Inflammatory diseases	Hereditary fevers	Cancers	Unknown	Unspecified miscellaneous
Auerbach ⁹	USA	379	Unknown	379 (100%)	0	0	0	0	0
Brownstein ⁴⁵	USA	100	1945-1968	63 (63%)	19 (19%)	0	18 (18%)	0	0
Rizvi ¹⁰	India	198	Unknown	178 (90%)	16 (8%)	0	4 (2%)	0	0
Chugh ¹¹	India	203	1957-1979	182 (90%)	13 (6%)	NA	NA	NA	8 (4%)
Tuglular ¹⁴⁸	Turkey	287	Unknown	53 (19%)	30 (10%)	183 (64%)	0	21 (7%)	0
Ensari ¹⁴⁹	Turkey	101	Unknown	12 (12%)	8 (8%)	81 (80%)	0	0	0
Bergesio ¹⁵⁰	Italy	104	1995-2000	16 (15%)	58 (56%)	4 (4%)	3 (3%)	23 (22%)	0
Lachmann ¹⁵¹	England	374	1990-2005	56 (15%)	245 (65%)	32 (9%)	11 (3%)	23 (6%)	7 (2%)
Ahbap ¹⁴⁷	Turkey	121	2001-2013	38 (31%)	10 (8%)	45 (37%)	NA	24 (20%)	4 (4%)
Lane ⁴³	England	635	1990-2016	123 (19%)	330 (52%)	57 (9%)	4 (1%)	121 (19%)	0
Palladini ¹⁴²	Italy	200	1991-2015	20 (10%)	87 (44%)	16 (8%)	8 (4%)	64 (32%)	5 (2%)
Okuda ⁴⁴	Japan	199	2012-2014	9 (5%)	164 (82%)	4 (2%)	22 (11%)	0	0

Note: Values are displayed as absolute numbers (%). Some of these data are rederived from available percentages.

Abbreviations: NA, not available; USA, United States of America.

4 | FREQUENCY OF INFECTIONS AS AN AETIOLOGICAL FACTOR IN AA AMYLOIDOSIS

The frequency of infections as an aetiological factor of AA amyloidosis varies over time (better management of chronic infections with the advent of antibiotics and better sanitary conditions) and according to the country (developing vs developed countries) and the method of recruitment (autopsy series, positive renal biopsy or any type of tissue).

In addition, several limitations must be taken into account to analyse these data: (1) the diagnosis of some infections, such as Whipple disease or even tuberculosis, is probably more accurate currently than before; (2) similarly, the diagnosis of amyloidosis, and, a fortiori, the typing of amyloidosis in old articles is questionable, as many papers have diagnosed AA amyloidosis by treatment with KMnO_4 ; (3) as patients for whom no underlying disease could be found were diagnosed with primary amyloidosis, it is impossible to determine whether these patients had AL amyloidosis or AA amyloidosis without an identified known cause, and this may account, at least in part, in the increase in the frequency of AA amyloidosis of unknown cause currently; (4) causes of AA amyloidosis may be entangled and/or associated, either several associated infections or infectious and noninfectious causes. Typically, subcutaneous drug users are at increased risk of associated HIV, hepatitis C or tuberculosis infections or endocarditis^{70,96}; (5) some countries may have an overrepresentation of a specific aetiology, such as familial Mediterranean fever in Mediterranean countries or tuberculosis in endemic countries; (6) some rare associations with only a few cases described may be doubtful and be only a coincidental association,³ although from a pathophysiological point of view, any disease responsible, directly or indirectly, for a chronic or recurrent increase in SAA levels may theoretically cause AA amyloidosis.

With these limitations in mind, the respective frequencies of causes of reactive amyloidosis in the main case series and the respective frequencies of infectious causes in the main case series with more than 100 patients are depicted in Tables 1 and 2, respectively, and Figure 2.^{9-11,43-45,142,147-151} Therefore, the frequency of AA amyloidosis secondary to infections decreased from more than 50% to less than 20% after the 2000s, with a parallel increase in the frequency of AA amyloidosis secondary to inflammatory diseases and to an unknown cause.

Several cases of nephrotic syndrome disappeared under appropriate treatment of the causal infection, but relapse can occur with reinfection.^{4,34,54,100,106,152-155} In rare cases, a decrease or even the disappearance of amyloid deposits on repeated biopsies has been shown.^{11,55,69,154-156}

Of note, it could be possible that some factors favour the development of AA amyloidosis in patients exposed to infections, such as diet and physical activity¹⁸ or genetic cofactors, including variants in the SAA gene.¹⁵⁷

TABLE 2 Specific infectious causes responsible for secondary amyloidosis in the main case series from the literature

First author [Ref.]	Mycobacteria (tuberculosis)	Bacteria	Fungi	Lung infections	Bone infections	Skin infections	Urinary infections	Paraplegia	Drug abuse	Cystic fibrosis	Other chronic or recurrent infections
Auerbach ⁹	374 (374)	1	0	4	0	0	0	0	0	0	0
Brownstein ⁴⁵	27 (24)	0	1	6	2	3	23	0	0	0	1
Rizvi ¹⁰	152 (150)	0	0	26	0	0	0	0	0	0	0
Chugh ¹¹	125 (120)	NA	NA	49	8	NA	NA	NA	NA	NA	NA
Tuglular ¹⁴⁸	28 (28)	0	0	18	7	0	0	0	0	0	0
Ensari ¹⁴⁹	8 (8)	0	0	4	0	0	0	0	0	0	0
Bergesio ¹⁵⁰	6 (6)	0	0	4	2	0	2	0	0	2	0
Lachmann ¹⁵¹	3 (3)	NA	NA	20	5	NA	NA	8	13	NA	7
Ahbap ¹⁴⁷	30 (30)	NA	NA	8	NA	NA	NA	NA	NA	NA	NA
Lane ⁴³	0	0	0	0	0	0	0	0	15	0	72
Palladini ¹⁴²	0	0	0	4	0	8	0	0	0	8	0
Okuda ⁴⁴	6 (2)	NA	NA	NA	2	NA	NA	NA	NA	NA	1

Note: Values are displayed as absolute numbers. Some of these data are rederived from available percentages. Abbreviation: NA, not available.

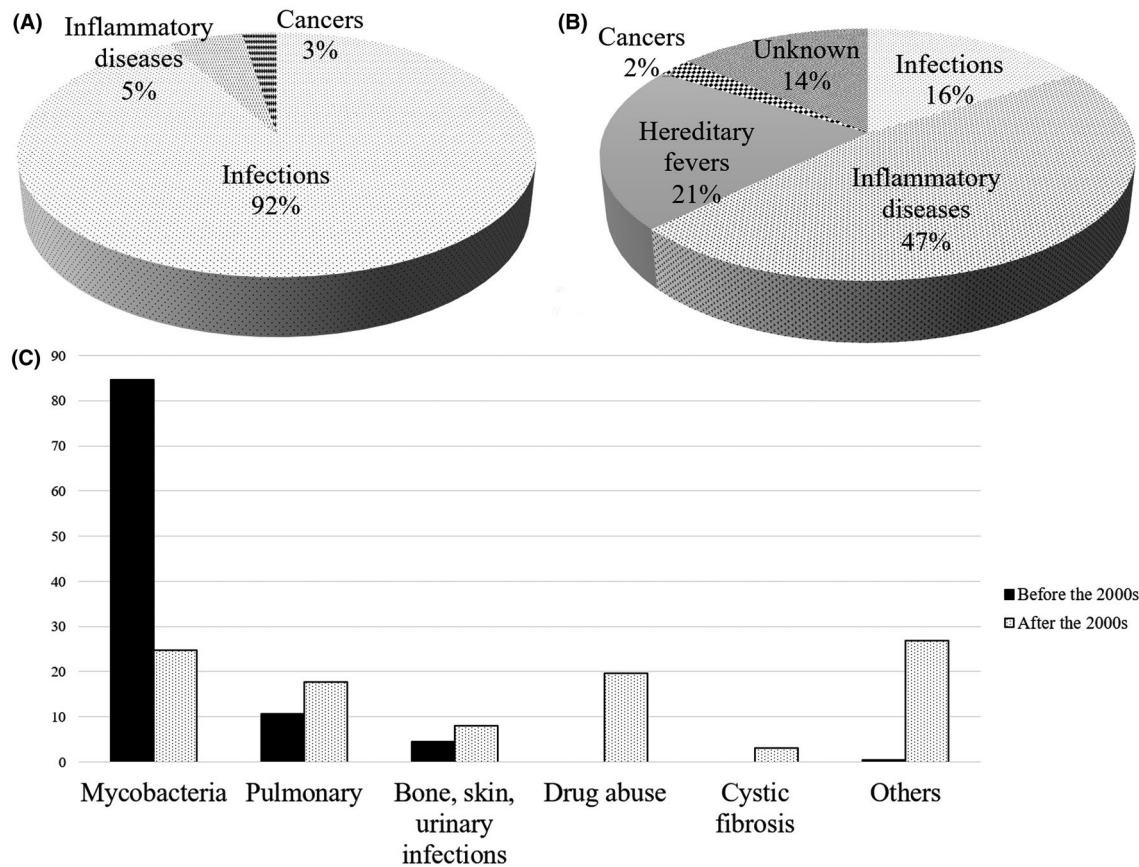


FIGURE 2 Respective frequencies of causes of inflammatory amyloidosis in the main case series from the literature with more than 100 patients before (A) and after (B) the 2000s and respective frequencies of infections (C)

5 | CONCLUSION

Whereas new antibiotics have been developed and sanitary conditions are better, infections still represent 5%-30% of the causes of AA amyloidosis, including in developed countries. These data argue for better screening of chronic infections to prevent AA amyloidosis and the development of new strategies to manage recurrent infections.

DISCLOSURE

The authors have no conflict of interest to declare.

DATA AVAILABILITY STATEMENT

Data sharing not applicable to this article as no datasets were generated or analysed during the current study.

ORCID

Samuel Deshayes <https://orcid.org/0000-0001-8887-3233>

Achille Aouba <https://orcid.org/0000-0003-1726-3811>

Gilles Grateau <https://orcid.org/0000-0002-8767-7385>

Sophie Georgin-Lavialle <https://orcid.org/0000-0001-6668-8854>

[org/0000-0001-6668-8854](https://orcid.org/0000-0001-6668-8854)

REFERENCES

1. Westermark GT, Fändrich M, Westermark P. AA amyloidosis: pathogenesis and targeted therapy. *Annu Rev Pathol*. 2015; 10:321-344. <https://doi.org/10.1146/annurev-pathol-020712-163913>.
2. Stojanovic KS, Georgin-Lavialle S, Grateau G. AA amyloidosis. *Nephrol Ther*. 2017;13:258-264. <https://doi.org/10.1016/j.nephro.2017.03.001>.
3. Brunger AF, Nienhuis HLA, Bijzet J, Hazenberg BPC. Causes of AA amyloidosis: a systematic review. *Amyloid*. 2020;27:1-12. <https://doi.org/10.1080/13506129.2019.1693359>.
4. Gertz MA, Kyle RA. Secondary systemic amyloidosis: response and survival in 64 patients. *Medicine (Baltimore)*. 1991;70: 246-256.
5. Ben Maïz H, Abderrahim E, Ben Moussa F, Goucha R, Karoui C. Epidemiology of glomerular diseases in Tunisia from 1975 to 2005. Influence of changes in healthcare and society. *Bull Acad Natl Med*. 2006;190:403-416; discussion 416-418.
6. Kebbel A, Röcken C. Immunohistochemical classification of amyloid in surgical pathology revisited. *Am J Surg Pathol*. 2006;30:673-683. <https://doi.org/10.1097/00000478-200606000-00002>.
7. Wechalekar AD, Gillmore JD, Hawkins PN. Systemic amyloidosis. *Lancet*. 2016;387:2641-2654. [https://doi.org/10.1016/S0140-6736\(15\)01274-X](https://doi.org/10.1016/S0140-6736(15)01274-X).
8. Kennedy AC, Burton JA, Allison ME. Tuberculosis as a continuing cause of renal amyloidosis. *Br Med J*. 1974;3:795-797. <https://doi.org/10.1136/bmj.3.5934.795>.

9. Auerbach O, Stemmerman M. Renal amyloidosis. *Arch Intern Med (Chic)*. 1944;74:244. <https://doi.org/10.1001/archinte.1944.00210220011002>.
10. Rizvi SN, Gulati PD, Vaishnava H. Letter: tuberculosis and renal amyloidosis. *Br Med J*. 1974;4:657. <https://doi.org/10.1136/bmj.4.5945.657-a>.
11. Chugh KS, Datta BN, Singhal PC, Jain SK, Sakhuja V, Dash SC. Pattern of renal amyloidosis in Indian patients. *Postgrad Med J*. 1981;57:31-35. <https://doi.org/10.1136/pgmj.57.663.31>.
12. Mengistu M. Incidence of renal amyloidosis in adult Ethiopian tuberculosis patients. *East Afr Med J*. 1983;60:773-777.
13. Erk O, Turfanda T, Uysal V. Frequency of renal amyloidosis secondary to tuberculosis. *Nephron*. 1995;71:367. <https://doi.org/10.1159/000188751>.
14. Tsuji K, Arai H, Furusu A, et al. A case of membranoproliferative glomerulonephritis and AA amyloidosis complicated with pulmonary nontuberculous mycobacterial infection. *CEN Case Rep*. 2015;4:24-30. <https://doi.org/10.1007/s13730-014-0134-1>.
15. Aharon A, Langevitz P, Maran R, Blank-Porat D, Shtratsburg S, Livneh A. Reactive amyloidosis in a patient with Mycobacterium simiae pulmonary infection. *Respir Med*. 1998;92:123-124. [https://doi.org/10.1016/s0954-6111\(98\)90044-0](https://doi.org/10.1016/s0954-6111(98)90044-0).
16. Amyloidosis and leprosy. *Lancet*. 1975;2:589-590.
17. Ahsan N, Wheeler DE, Palmer BF. Leprosy-associated renal disease: case report and review of the literature. *J Am Soc Nephrol*. 1995;5:1546-1552.
18. Williams RC, Cathcart ES, Calkins E, Fite GL, Rubio JB, Cohen AS. Secondary amyloidosis in lepromatous leprosy. Possible relationships of diet and environment. *Ann Intern Med*. 1965;62:1000-1007. <https://doi.org/10.7326/0003-4819-62-5-1000>.
19. Powell CS, Swan LL. Leprosy: pathologic changes observed in fifty consecutive necropsies. *Am J Pathol*. 1955;31:1131-1147.
20. Nakayama EE, Ura S, Fleury RN, Soares V. Renal lesions in leprosy: a retrospective study of 199 autopsies. *Am J Kidney Dis*. 2001;38:26-30. <https://doi.org/10.1053/ajkd.2001.25177>.
21. Dahlin DC. Secondary amyloidosis. *Ann Intern Med*. 1949;31:105-119. <https://doi.org/10.7326/0003-4819-31-1-105>.
22. Moschcowitz E. The clinical aspects of amyloidosis. *Ann Intern Med*. 1936;10:73. <https://doi.org/10.7326/0003-4819-10-1-73>.
23. Briggs GW. Amyloidosis. *Ann Intern Med*. 1961;55:943-957. <https://doi.org/10.7326/0003-4819-55-6-943>.
24. James PD, Owor R. Systemic amyloidosis in Uganda. An autopsy study. *Trans R Soc Trop Med Hyg*. 1975;69:480-483. [https://doi.org/10.1016/0035-9203\(75\)90103-0](https://doi.org/10.1016/0035-9203(75)90103-0).
25. Masterton G. Cardiovascular syphilis with amyloidosis and periods of alternating heart block. *Br J Vener Dis*. 1965;41:181-185. <https://doi.org/10.1136/sti.41.3.181>.
26. Nakagawa S, Suzue K. Amyloidosis in Japan. *Pathol Microbiol (Basel)*. 1964;27:850-854. <https://doi.org/10.1159/000161539>.
27. Niemczyk S, Filipowicz E, Wozniacki L, et al. Renal amyloidosis in Whipple disease: a case report. *Cases J*. 2009;2:8444. <https://doi.org/10.4076/1757-1626-2-8444>.
28. Sander S. Whipple's disease associated with amyloidosis. *Acta Pathol Microbiol Scand*. 1964;61:530-536. <https://doi.org/10.1111/apm.1964.61.4.530>.
29. Farr M, Morris C, Hollywell CA, Scott DL, Walton KW, Bacon PA. Amyloidosis in Whipple's arthritis. *J R Soc Med*. 1983;76:963-965.
30. Rocha S, Lobato L, Carvalho MJ, et al. Renal transplantation in AA amyloidosis associated with Whipple's disease. *Amyloid*. 2011;18:240-244. <https://doi.org/10.3109/13506129.2011.614651>.
31. Kramer LC, Manschot TAJM, Barendregt JNM, Smit JM. Whipple's disease: often a late diagnosis and a rare cause of nephropathy. *NDT Plus*. 2009;2:55-58. <https://doi.org/10.1093/ndtplus/sfn143>.
32. Pianko S, Wells C. Whipple's disease: unusual presentations. *Aust N Z J Med*. 1997;27:592-593. <https://doi.org/10.1111/j.1445-5994.1997.tb00970.x>.
33. Cruz I, Oliveira AP, Lopes JM, Ricardo JL, de Freitas J. Whipple's disease and renal amyloidosis. *Am J Gastroenterol*. 1993;88:1954-1956.
34. Kuhlback B, Wegelius O. Secondary amyloidosis; a study of clinical and pathological findings. *Acta Med Scand*. 1966;180:737-745.
35. Mazzochi L, Disdier P, Harlé J, et al. L'amylose secondaire, complication tardive de la chirurgie orthopédique. *Presse Med*. 1992;21:1823.
36. Hornbaker S, Brungardt G, Dunn M. An apparent cure of secondary amyloidosis due to osteomyelitis. *Arch Intern Med*. 1986;146:191-192.
37. Luke RG, Allison ME, Davidson JF, Duguid WP. Hyperkalemia and renal tubular acidosis due to renal amyloidosis. *Ann Intern Med*. 1969;70:1211-1217. <https://doi.org/10.7326/0003-4819-70-6-1211>.
38. Alabi ZO, Ojo OS, Odesanmi WO. Secondary amyloidosis in chronic osteomyelitis. *Int Orthop*. 1991;15:21-22. <https://doi.org/10.1007/BF00210527>.
39. Mody G, Bowen R, Meyers OL. Amyloidosis at Groote Schuur Hospital. *Cape Town. S Afr Med J*. 1984;66:47-49.
40. Hoshii Y, Takahashi M, Ishihara T, Uchino F. Immunohistochemical classification of 140 autopsycases with systemic amyloidosis. *Pathol Int*. 1994;44:352-358. <https://doi.org/10.1111/j.1440-1827.1994.tb02935.x>.
41. Blank N, Hegenbart U, Lohse P, et al. Risk factors for AA amyloidosis in Germany. *Amyloid*. 2015;22:1-7. <https://doi.org/10.3109/13506129.2014.980942>.
42. Hassen M, Bates W, Moosa MR. Pattern of renal amyloidosis in South Africa. *BMC Nephrol*. 2019;20:406. <https://doi.org/10.1186/s12882-019-1601-x>.
43. Lane T, Pinney JH, Gilbertson JA, et al. Changing epidemiology of AA amyloidosis: clinical observations over 25 years at a single national referral centre. *Amyloid*. 2017;24:162-166. <https://doi.org/10.1080/13506129.2017.1342235>.
44. Okuda Y, Yamada T, Ueda M, Ando Y. First nationwide survey of 199 patients with amyloid A amyloidosis in Japan. *Intern Med*. 2018;57:3351-3355. <https://doi.org/10.2169/internalmedicine.1099-18>.
45. Brownstein MH, Helwig EB. Secondary systemic amyloidosis: analysis of underlying disorders. *South Med J*. 1971;64:491-496. <https://doi.org/10.1097/00007611-197104000-00024>.
46. Gedda PO. On amyloidosis and other causes of death in rheumatoid arthritis. *Acta Med Scand*. 1955;150:443-452. <https://doi.org/10.1111/j.0954-6820.1955.tb15728.x>.
47. Herbert MA, Milford DV, Silove ED, Raafat F. Secondary amyloidosis from long-standing bacterial endocarditis. *Pediatr Nephrol*. 1995;9:33-35. <https://doi.org/10.1007/BF00858963>.
48. Punia RS, Dhingra N, Mohan H, D'Cruz S. Amyloidosis secondary to xanthogranulomatous pyelonephritis: a rare association. *Saudi J Kidney Dis Transpl*. 2010;21:720-723.
49. Tsuchiya Y, Ubara Y, Suwabe T, et al. AA-amyloidosis in autosomal dominant polycystic kidney disease caused by chronic cyst infections lasting for 30 years. *Intern Med*. 2013;52:791-794. <https://doi.org/10.2169/internalmedicine.52.9277>.
50. Kayser K, Wiebel M, Schulz V, Gabius HJ. Necrotizing bronchitis, angitis, and amyloidosis associated with chronic Q fever. *Respiration*. 1995;62:114-116. <https://doi.org/10.1159/000196404>.
51. Vanderbeke L, Peetermans WE, Saegeman V, De Munter P. Q fever: a contemporary case series from a Belgian hospital. *Acta Clin Belg*. 2016;71:290-296. <https://doi.org/10.1080/17843286.2016.1165397>.

52. Martinez-Vea A, García C, Carreras M, Revert L, Oliver JA. End-stage renal disease in systemic amyloidosis: clinical course and outcome on dialysis. *Am J Nephrol*. 1990;10:283-289. <https://doi.org/10.1159/000168121>.
53. Kollabathula A, Vishwajeet V, Gupta K, et al. Chronic brucellosis with hepatic brucella and AA amyloidosis in a patient with autosomal dominant polycystic kidney disease. *Autops Case Rep*. 2020;10:e2019128. <https://doi.org/10.4322/acr.2019.128>.
54. Omer HO, Abdel Wahab SM. Secondary amyloidosis due to *Schistosoma mansoni* infection. *Br Med J*. 1976;1:375-377. <https://doi.org/10.1136/bmj.1.6006.375>.
55. Veress B, Musa AR, Osman H, Asha A, Saddig EW, El Hassan AM. The nephrotic syndrome in the Sudan with special reference to schistosomal nephropathy. A preliminary morphological study. *Ann Trop Med Parasitol*. 1978;72:357-361. <https://doi.org/10.1080/00034983.1978.11719329>.
56. Gold CH. Hepatic and renal amyloidosis in association with schistosomiasis. A case report. *S Afr Med J*. 1978;53:681-682.
57. Gold CH. Renal amyloidosis in blacks. *S Afr Med J*. 1979;56:715-718.
58. Barsoum RS, Bassily S, Soliman M, Milad M, Hassaballa AM. Amyloidosis in hepatosplenic schistosomiasis. *Trans R Soc Trop Med Hyg*. 1978;72:215-216. [https://doi.org/10.1016/0035-9203\(78\)90077-9](https://doi.org/10.1016/0035-9203(78)90077-9).
59. Verine J, Mourad N, Desseaux K, et al. Clinical and histological characteristics of renal AA amyloidosis: a retrospective study of 68 cases with a special interest to amyloid-associated inflammatory response. *Hum Pathol*. 2007;38:1798-1809. <https://doi.org/10.1016/j.humphath.2007.04.013>.
60. Israel-Asselain R, Legrain M, Chapman A, Chebat J, Sosters-Ferrès R. L'anurie de l'amylose rénale, à propos d'un cas au cours d'une échinococcose. *Cahiers Coll Med*. 1964;5:585-590.
61. Kaaroud H, Ben Moussa F, Béji S, Kheder A, Ben Maïz H. Renal amyloidosis secondary to hydatid cyst of the liver. Clinical remission after surgical excision. *Nephrologie*. 2002;23:213-217.
62. Altiparmak MR, Pamuk GE, Pamuk ON. Secondary renal involvement in human cystic echinococcosis: a review of the literature and report of another case. *Ann Trop Med Parasitol*. 2002;96:745-748. <https://doi.org/10.1179/000349802125001852>.
63. Ali-Khan Z, Rausch RL. Demonstration of amyloid and immune complex deposits in renal and hepatic parenchyma of Alaskan alveolar hydatid disease patients. *Ann Trop Med Parasitol*. 1987;81:381-392. <https://doi.org/10.1080/00034983.1987.11812136>.
64. von Hutten H, Mihatsch M, Lobeck H, Rudolph B, Eriksson M, Röcken C. Prevalence and origin of amyloid in kidney biopsies. *Am J Surg Pathol*. 2009;33:1198-1205. <https://doi.org/10.1097/PAS.0b013e3181abdafa7>.
65. Bullani R, Buffet PA, Mary C, et al. AA-amyloidosis caused by visceral leishmaniasis in a human immunodeficiency virus-infected patient. *Am J Trop Med Hyg*. 2009;81:209-212.
66. Wright MI. Kala-azar of unusual duration, associated with agammaglobulinaemia. *Br Med J*. 1959;1:1218-1221. <https://doi.org/10.1136/bmj.1.5131.1218>.
67. Westermarck P, Review WGT. Reflections on amyloidosis in Papua New Guinea. *Philos Trans R Soc Lond B Biol Sci*. 2008;363:3701-3705. <https://doi.org/10.1098/rstb.2008.0073>.
68. Rhodes KM. Amyloidosis in Vanuatu. *Trans R Soc Trop Med Hyg*. 1987;81:297-298. [https://doi.org/10.1016/0035-9203\(87\)90246-x](https://doi.org/10.1016/0035-9203(87)90246-x).
69. Nayak HK, Daga MK, Garg SK, et al. A rare case of reversible acquired AA-type renal amyloidosis in a chronic filariasis patient receiving antifilarial therapy. *Clin Exp Nephrol*. 2011;15:591-595. <https://doi.org/10.1007/s10157-011-0448-7>.
70. Jung O, Haack HS, Buettner M, et al. Renal AA-amyloidosis in intravenous drug users—a role for HIV-infection? *BMC Nephrol*. 2012;13:151. <https://doi.org/10.1186/1471-2369-13-151>.
71. Newey C, Odedra BJ, Standish RA, Furlani R, Edwards SG, Miller RF. Renal and gastrointestinal amyloidosis in an HIV-infected injection drug user. *Int J STD AIDS*. 2007;18:357-358. <https://doi.org/10.1258/095646207780749691>.
72. Cozzi PJ, Abu-Jawdeh GM, Green RM, Green D. Amyloidosis in association with human immunodeficiency virus infection. *Clin Infect Dis*. 1992;14:189-191. <https://doi.org/10.1093/clinids/14.1.189>.
73. Longo-Mbenza B, Seghers LV, Vita EK, Tondouangu K, Bayekula M. Assessment of ventricular diastolic function in AIDS patients from Congo: a Doppler echocardiographic study. *Heart*. 1998;80:184-189. <https://doi.org/10.1136/hrt.80.2.184>.
74. Atta MG, Choi MJ, Longenecker JC, et al. Nephrotic range proteinuria and CD4 count as noninvasive indicators of HIV-associated nephropathy. *Am J Med*. 2005;118:1288. <https://doi.org/10.1016/j.amjmed.2005.05.027>.
75. Chan-Tack KM, Uche A, Greisman LA, et al. Acute renal failure and nephrotic range proteinuria due to amyloidosis in an HIV-infected patient. *Am J Med Sci*. 2006;332:364-367. <https://doi.org/10.1097/00000441-200612000-00012>.
76. Méry JP, Delahousse M, Nochy D. Amyloidosis and infection due to human immunodeficiency virus. *Clin Infect Dis*. 1993;16:733-734. <https://doi.org/10.1093/clind/16.5.733>.
77. Vali PS, Ismal K, Gowrishankar S, Sahay M. Renal disease in human immunodeficiency virus—not just HIV-associated nephropathy. *Indian J Nephrol*. 2012;22:98-102. <https://doi.org/10.4103/0971-4065.97117>.
78. Saha A, Theis JD, Vrana JA, Dubey NK, Batra VV, Sethi S. AA amyloidosis associated with hepatitis B. *Nephrol Dial Transplant*. 2011;26:2407-2412. <https://doi.org/10.1093/ndt/gfr224>.
79. Röcken C, Schwotzer EB, Linke RP, Saeger W. The classification of amyloid deposits in clinicopathological practice. *Histopathology*. 1996;29:325-335. <https://doi.org/10.1111/j.1365-2559.1996.tb01416.x>.
80. Girnius S, Dember L, Doros G, Skinner M. The changing face of AA amyloidosis: a single center experience. *Amyloid*. 2011;18:226-228. <https://doi.org/10.3109/13506129.2011.574354085>.
81. Jiang W, Xu Y, Guan G, Ma R, Dong H. Renal amyloidosis and hepatitis B virus-associated glomerulonephritis in a patient with nephrotic syndrome. *Chin Med J*. 2014;127:1199.
82. Lejmi H, Jen K-Y, Olson JL, James SH, Sam R. Characteristics of AA amyloidosis patients in San Francisco. *Nephrology*. 2016;21:308-313. <https://doi.org/10.1111/nep.12616>.
83. Jacquot C, d'Auzac C, Loirat P, Bariety J. Dramatic aggravation of renal amyloidosis after surgery. Three cases (author's transl). *Nouv Presse Med*. 1981;10:3389-3390, 3395.
84. Kaltenis P, Mudenie V, Maknavicius S, Sein D. Renal amyloidosis in a child with chronic granulomatous disease and invasive aspergillosis. *Pediatr Nephrol*. 2008;23:831-834. <https://doi.org/10.1007/s00467-007-0702-0>.
85. Patel D, Agarwal R, Dhooria S, Hedge U, Patel H, Singh SI. Amyloidosis secondary to chronic pulmonary aspergillosis: case report and a systematic review of literature. *J Mycol Med*. 2019;29:372-374. <https://doi.org/10.1016/j.mycmed.2019.100898>.
86. Bal A, Agarwal AN, Das A, Suri V, Varma SC. Chronic necrotizing pulmonary aspergillosis in a marijuana addict: a new cause of amyloidosis. *Pathology*. 2010;42:197-200. <https://doi.org/10.3109/00313020903493997>.
87. Winter JH, Milroy R, Stevenson RD, Hunter J. Secondary amyloidosis in association with Aspergillus lung disease. *Br J Dis Chest*. 1986;80:400-403. [https://doi.org/10.1016/0007-0971\(86\)90095-1](https://doi.org/10.1016/0007-0971(86)90095-1).
88. Muthu V, Sehgal IS, Dhooria S, Bal A, Agarwal R. Allergic bronchopulmonary aspergillosis presenting as nephrotic syndrome due to secondary amyloidosis: case report and systematic review of the literature. *Lung India*. 2018;35:332-335. https://doi.org/10.4103/lungindia.lungindia_180_17.

89. Clinicopathological conference: a case of unsuspected chronic inflammatory disease. *Br Med J*. 1973;4:149-154. <https://doi.org/10.1136/bmj.4.5885.149>.
90. Symmers WS. Letter: Amyloidosis complicating actinomycosis. *Br Med J*. 1973;4:423-424. <https://doi.org/10.1136/bmj.4.5889.423-b>.
91. Berns JS, Rapalino O, Fenves AZ, El Khoury JB, Klepeis VE, Anahtar MN. Case 11-2020: a 37-year-old man with facial droop, dysarthria, and kidney failure. *N Engl J Med*. 2020;382:1457-1466. <https://doi.org/10.1056/NEJMcpc1916252>.
92. Neugarten J, Gallo GR, Buxbaum J, Katz LA, Rubenstein J, Baldwin DS. Amyloidosis in subcutaneous heroin abusers ("skin poppers' amyloidosis"). *Am J Med*. 1986;81:635-640. [https://doi.org/10.1016/0002-9343\(86\)90550-4](https://doi.org/10.1016/0002-9343(86)90550-4).
93. Miranda BH, Connolly JO, Burns AP. Secondary amyloidosis in a needle phobic intra-venous drug user. *Amyloid*. 2007;14:255-258. <https://doi.org/10.1080/13506120701456293>.
94. Scholes J, Derosena R, Appel GB, Jao W, Boyd MT, Pirani CL. Amyloidosis in chronic heroin addicts with the nephrotic syndrome. *Ann Intern Med*. 1979;91:26-29. <https://doi.org/10.7326/0003-4819-91-1-26>.
95. Dubrow A, Mittman N, Ghali V, Flamenbaum W. The changing spectrum of heroin-associated nephropathy. *Am J Kidney Dis*. 1985;5:36-41. [https://doi.org/10.1016/s0272-6386\(85\)80133-5](https://doi.org/10.1016/s0272-6386(85)80133-5).
96. Connolly JO, Gillmore JD, Lachmann HJ, Davenport A, Hawkins PN, Woolfson RG. Renal amyloidosis in intravenous drug users. *QJM*. 2006;99:737-742. <https://doi.org/10.1093/qjmed/hcl092>.
97. Osick LA, Lee T-P, Pedemonte MB, et al. Hepatic amyloidosis in intravenous drug abusers and AIDS patients. *J Hepatol*. 1993;19:79-84. [https://doi.org/10.1016/s0168-8278\(05\)80179-5](https://doi.org/10.1016/s0168-8278(05)80179-5).
98. Manner I, Sagedal S, Røger M, Os I. Renal amyloidosis in intravenous heroin addicts with nephrotic syndrome and renal failure. *Clin Nephrol*. 2009;72:224-228. <https://doi.org/10.5414/cnp72224>.
99. Menchel S, Cohen D, Gross E, Frangione B, Gallo G. AA protein-related renal amyloidosis in drug addicts. *Am J Pathol*. 1983;112:195-199.
100. Cengiz K. Uncommon aetiology in renal amyloidosis. *Acta Clin Belg*. 2005;60:109-113. <https://doi.org/10.1179/acb.2005.021>.
101. Newman W, Jacobson AS. Paraplegia and secondary amyloidosis; report of six cases. *Am J Med*. 1953;15:216-222. [https://doi.org/10.1016/0002-9343\(53\)90073-4](https://doi.org/10.1016/0002-9343(53)90073-4).
102. Thompson CE, Rice ML. Secondary amyloidosis in spinal cord injury. *Ann Intern Med*. 1949;31:1057-1065. <https://doi.org/10.7326/0003-4819-31-6-1057>.
103. Dietrick RB, Russi S. Tabulation and review of autopsy findings in fifty-five paraplegics. *J Am Med Assoc*. 1958;166:41-44. <https://doi.org/10.1001/jama.1958.02990010043009>.
104. Dalton JJ, Hackler RH, Bunts RC. Amyloidosis in the paraplegic; incidence and significance. *J Urol*. 1965;93:553-555. [https://doi.org/10.1016/s0022-5347\(17\)63826-6](https://doi.org/10.1016/s0022-5347(17)63826-6).
105. Youakim C, Cottin V, Juillard L, Fouque D, MacGregor B, Cordier J-F. Renal AA amyloidosis secondary to bronchiectasis: a report of two cases (including one with Mounier-Kuhn syndrome). *Rev Mal Respir*. 2004;21:821-824. [https://doi.org/10.1016/s0761-8425\(04\)71426-6](https://doi.org/10.1016/s0761-8425(04)71426-6).
106. Goldsmith DJ, Roberts IS, Short CD, Mallick NP. Complete clinical remission and subsequent relapse of bronchiectasis-related (AA) amyloid induced nephrotic syndrome. *Nephron*. 1996;74:572-576. <https://doi.org/10.1159/000189454>.
107. Akçay S, Akman B, Ozdemir H, Eyüboğlu FO, Karacan O, Ozdemir N. Bronchiectasis-related amyloidosis as a cause of chronic renal failure. *Ren Fail*. 2002;24:815-823. <https://doi.org/10.1081/jdi-120015683>.
108. Stankovic Stojanovic K, Hubert D, Leroy S, et al. Cystic fibrosis and AA amyloidosis: a survey in the French cystic fibrosis network. *Amyloid*. 2014;21:231-237. <https://doi.org/10.3109/13506129.2014.943834>.
109. Travis WD, Castile R, Vawter G, et al. Secondary (AA) amyloidosis in cystic fibrosis. A report of three cases. *Am J Clin Pathol*. 1986;85:419-424. <https://doi.org/10.1093/ajcp/85.4.419>.
110. Castile R, Shwachman H, Travis W, Hadley CA, Warwick W, Missmahl HP. Amyloidosis as a complication of cystic fibrosis. *Am J Dis Child*. 1985;139:728-732. <https://doi.org/10.1001/archpedi.1985.02140090090040>.
111. Mc Laughlin AM, Crotty TB, Egan JJ, Watson AJ, Gallagher CG. Amyloidosis in cystic fibrosis: a case series. *J Cyst Fibros*. 2006;5:59-61. <https://doi.org/10.1016/j.jcf.2005.09.010>.
112. Yahiaoui Y, Jablonski M, Hubert D, et al. Renal involvement in cystic fibrosis: diseases spectrum and clinical relevance. *Clin J Am Soc Nephrol*. 2009;4:921-928. <https://doi.org/10.2215/CJN.00750209>.
113. Ristow SC, Condemi JJ, Stuard ID, Schwartz RH, Bryson MF. Systemic amyloidosis in cystic fibrosis. *Am J Dis Child*. 1977;131:886-888. <https://doi.org/10.1001/archpedi.1977.02120210064013>.
114. Melzi ML, Costantini D, Giani M, Appiani AC, Giunta AM. Severe nephropathy in three adolescents with cystic fibrosis. *Arch Dis Child*. 1991;66:1444-1447. <https://doi.org/10.1136/adc.66.12.1444>.
115. Simpson T, Elston C, Macedo P, Perrin F. Amyloidosis in cystic fibrosis. *Paediatr Respir Rev*. 2019;31:32-34. <https://doi.org/10.1016/j.prrv.2019.04.007>.
116. Canciani M, Pederzini F, Mastella G, Boccato P. Systemic amyloidosis in cystic fibrosis. *Acta Paediatr Scand*. 1985;74:613-614. <https://doi.org/10.1111/j.1651-2227.1985.tb11043.x>.
117. Alicandro G, Frova L, Di Fraia G, Colombo C. Cystic fibrosis mortality trend in Italy from 1970 to 2011. *J Cyst Fibros*. 2015;14:267-274. <https://doi.org/10.1016/j.jcf.2014.07.010>.
118. El Houssni S, Laine M, Bziz A, Alhamany Z, Eddine Bourkadi J, Bayahia R. Renal amyloidosis revealing a Kartagener's syndrome. *Nephrol Ther*. 2015;11:50-52. <https://doi.org/10.1016/j.nephro.2014.09.003>.
119. Demir M, Kutlucan A, Sezer MT. Renal amyloidosis in a patient with Kartagener syndrome. *Ren Fail*. 2007;29:117. <https://doi.org/10.1080/08860220601039569>.
120. Osman EM, Abboud OI, Sulaiman SM, Musa AR, Beleil OM, Sharfi AA. End-stage renal failure in Kartagener's syndrome. *Nephrol Dial Transplant*. 1991;6:747. <https://doi.org/10.1093/ndt/6.10.747>.
121. Esenboga S, Çağdas Ayvaz D, Sağlam Ayhan A, Peynircioglu B, Sanal O, Tezcan I. CVID associated with systemic amyloidosis. *Case Reports Immunol*. 2015;2015:879179. <https://doi.org/10.1155/2015/879179>.
122. Firinu D, Serusi L, Lorrain MM, et al. Systemic reactive (AA) amyloidosis in the course of common variable immunodeficiency. *Amyloid*. 2011;18:214-216. <https://doi.org/10.3109/13506129.2011.574354080>.
123. Kadiroğlu AK, Yıldırım Y, Yılmaz Z, et al. A rare cause of secondary amyloidosis: common variable immunodeficiency disease. *Case Rep Nephrol*. 2012;2012:860208. <https://doi.org/10.1155/2012/860208>.
124. Arslan S, Ucar R, Yavsan DM, et al. Common variable immunodeficiency and pulmonary amyloidosis: a case report. *J Clin Immunol*. 2015;35:344-347. <https://doi.org/10.1007/s10875-015-0151-7>.
125. Turkmen K, Anil M, Solak Y, Atalay H, Esen H, Tonbul HZ. A hepatitis C-positive patient with new onset of nephrotic syndrome and systemic amyloidosis secondary to common variable immunodeficiency. *Ann Saudi Med*. 2010;30:401-403. <https://doi.org/10.4103/0256-4947.67085>.
126. Meira T, Sousa R, Cordeiro A, Ilgenfritz R, Borralho P. Intestinal amyloidosis in common variable immunodeficiency and rheumatoid arthritis. *Case Rep Gastrointest Med*. 2015;2015:405695. <https://doi.org/10.1155/2015/405695>.

127. Balwani MR, Kute VB, Shah PR, Wakhare P, Trivedi HL. Secondary renal amyloidosis in a patient of pulmonary tuberculosis and common variable immunodeficiency. *J Nephropharmacol*. 2015;4:69-71.
128. Aydin Z, Gursu M, Ozturk S, Kilicaslan I, Kazancioglu R. A case of primary immune deficiency presenting with nephrotic syndrome. *NDT Plus*. 2010;3:456-458. <https://doi.org/10.1093/ndtplus/sfq083>.
129. Borte S, Celiksoy MH, Menzel V, et al. Novel NLRP12 mutations associated with intestinal amyloidosis in a patient diagnosed with common variable immunodeficiency. *Clin Immunol*. 2014;154:105-111. <https://doi.org/10.1016/j.clim.2014.07.003>.
130. Aghamohammadi A, Shafie A, Abolhassani H, Sherkat R, Mahjoub F, Rezaei N. Renal amyloidosis in common variable immunodeficiency. *Nefrologia*. 2010;30:474-476. <https://doi.org/10.3265/Nefrologia.pre2010.May.10280>.
131. Gonzalo-Garjito MA, Sánchez-Vega S, Pérez-Calderón R, et al. Renal amyloidosis in a patient with X-linked agammaglobulinemia (Bruton's disease) and bronchiectasis. *J Clin Immunol*. 2014;34:119-122. <https://doi.org/10.1007/s10875-013-9972-4>.
132. Tezcan I, Ersoy F, Sanal O, Gönc EN, Arici M, Berkel I. A case of X linked agammaglobulinaemia complicated with systemic amyloidosis. *Arch Dis Child*. 1998;79:94. <https://doi.org/10.1136/adc.79.1.94>.
133. Gupta K, Rawat A, Agrawal P, et al. Infectious and non-infectious complications in primary immunodeficiency disorders: an autopsy study from North India. *J Clin Pathol*. 2018;71:425-435. <https://doi.org/10.1136/jclinpath-2017-204708>.
134. Ziegler JB, Penny R. Fatal echo 30 virus infection and amyloidosis in X-linked hypogammaglobulinemia. *Clin Immunol Immunopathol*. 1975;3:347-352. [https://doi.org/10.1016/0090-1229\(75\)90021-5](https://doi.org/10.1016/0090-1229(75)90021-5).
135. Shiomura T, Ishida Y, Matsumoto N, Sasaki K, Ishihara T, Miwa S. A case of generalized amyloidosis associated with cyclic neutropenia. *Blood*. 1979;54:628-635.
136. De Seigneux R, Kanfer A, Terrioux P, Sraer JD, Whitworth JA. Letter: Renal amyloidosis in chronic granulomatous disease. *Br Med J*. 1974;4:230. <https://doi.org/10.1136/bmj.4.5938.230-a>.
137. Darougar S, Rashid Farokhi F, Tajik S, et al. Amyloidosis as a renal complication of chronic granulomatous disease. *Iran J Kidney Dis*. 2016;10:228-232.
138. González Sanchidrián S, Davin Carrero E, Gallego DS. AA amyloidosis associated with recurrent infections in the hyperimmunoglobulin E syndrome. *Med Clin (Barc)*. 2017;149:274-275. <https://doi.org/10.1016/j.medcli.2017.03.043>.
139. Rawat A, Singh S, Sharma D, Suri D, Rajwanshi A, Etzioni A. Amyloidosis in a child with leucocyte adhesion deficiency type-1: an unusual association. *Indian J Pediatr*. 2011;78:1546-1548. <https://doi.org/10.1007/s12098-011-0417-x>.
140. Hoffman S, Simon BE, Fischel RA, Gribetz D. Renal amyloidosis resulting from a chronically infected burn. *Pediatrics*. 1963;32:888-894.
141. Kofman T, Grimbert P, Canoui-Poitrine F, et al. Renal transplantation in patients with AA amyloidosis nephropathy: results from a French multicenter study. *Am J Transplant*. 2011;11:2423-2431. <https://doi.org/10.1111/j.1600-6143.2011.03620.x>.
142. Palladini G, Riva E, Basset M, et al. Prognostication of survival and progression to dialysis in AA amyloidosis. *Amyloid*. 2017;24:136-137. <https://doi.org/10.1080/13506129.2017.1289917>.
143. Lindeman RD, Scheer RL, Raisz LG. Renal amyloidosis. *Ann Intern Med*. 1961;54:883-898. <https://doi.org/10.7326/0003-4819-54-5-883>.
144. Prakash J, Brojen T, Rathore SS, Choudhury TA, Gupta T. The changing pattern of renal amyloidosis in Indian subcontinent: two decades of experience from a single center. *Ren Fail*. 2012;34:1212-1216. <https://doi.org/10.3109/0886022X.2012.723514>.
145. Waton J, Fays-Michel S, Chandeclerc ML, et al. AA amyloidosis: a little-known complication of chronic leg ulcer. *Ann Dermatol Venereol*. 2008;135:119-122. <https://doi.org/10.1016/j.annder.2007.01.003>.
146. Yilmaz M, Unsal A, Sokmen M, et al. Renal involvement in AA amyloidosis: clinical outcomes and survival. *Kidney Blood Press Res*. 2013;37:33-42. <https://doi.org/10.1159/000343398>.
147. Ahabap E, Kara E, Sahutoglu T, et al. Outcome of 121 patients with renal amyloid a amyloidosis. *J Res Med Sci*. 2014;19:644-649.
148. Tuglular S, Yalcinkaya F, Paydas S, et al. A retrospective analysis for aetiology and clinical findings of 287 secondary amyloidosis cases in Turkey. *Nephrol Dial Transplant*. 2002;17:2003-2005. <https://doi.org/10.1093/ndt/17.11.2003>.
149. Ensari C, Ensari A, Tümer N, Ertug E. Clinicopathological and epidemiological analysis of amyloidosis in Turkish patients. *Nephrol Dial Transplant*. 2005;20:1721-1725. <https://doi.org/10.1093/ndt/gfh890>.
150. Bergesio F, Ciciani AM, Santostefano M, et al. Renal involvement in systemic amyloidosis—an Italian retrospective study on epidemiological and clinical data at diagnosis. *Nephrol Dial Transplant*. 2007;22:1608--1618. <https://doi.org/10.1093/ndt/gfm041>.
151. Lachmann HJ, Goodman HJB, Gilbertson JA, et al. Natural history and outcome in systemic AA amyloidosis. *N Engl J Med*. 2007;356:2361-2371. <https://doi.org/10.1056/NEJMoa070265>.
152. Dikman SH, Kahn T, Gribetz D, Churg J. Resolution of renal amyloidosis. *Am J Med*. 1977;63:430-433. [https://doi.org/10.1016/0002-9343\(77\)90281-9](https://doi.org/10.1016/0002-9343(77)90281-9).
153. Gillmore JD, Lovat LB, Persey MR, Pepys MB, Hawkins PN. Amyloid load and clinical outcome in AA amyloidosis in relation to circulating concentration of serum amyloid A protein. *Lancet*. 2001;358:24-29. [https://doi.org/10.1016/S0140-6736\(00\)05252-1](https://doi.org/10.1016/S0140-6736(00)05252-1).
154. Lowenstein J, Gallo G. Remission of the nephrotic syndrome in renal amyloidosis. *N Engl J Med*. 1970;282:128-132. <https://doi.org/10.1056/NEJM197001152820304>.
155. Triger DR, Joekes AM. Renal amyloidosis—a fourteen-year follow-up. *Q J Med*. 1973;42:15-40.
156. Sunga MN, Reyes CV, Zvetina J, Kim TW. Resolution of secondary amyloidosis 14 years after adequate chemotherapy for skeletal tuberculosis. *South Med J*. 1989;82:92-93. <https://doi.org/10.1097/00007611-198901000-00024>.
157. Westermark P, Sletten K, Westermark GT, Raynes J, McAdam KP. A protein AA-variant derived from a novel serum AA protein, SAA1 delta, in an individual from Papua New Guinea. *Biochem Biophys Res Commun*. 1996;223:320-323. <https://doi.org/10.1006/bbrc.1996.0892>.

How to cite this article: Deshayes S, Aouba A, Grateau G, Georjin-Lavialle S. Infections and AA amyloidosis: An overview. *Int J Clin Pract*. 2021;75:e13966. <https://doi.org/10.1111/ijcp.13966>