



HAL
open science

Saw-Tooth Cardiomyopathy: Clinical Presentation and Genetic Analysis

Julie Proukhnitzky, Jérôme Garot, Céline Bordet, Lise Legrand, Flavie Ader, Pascale Richard, Philippe Charron

► **To cite this version:**

Julie Proukhnitzky, Jérôme Garot, Céline Bordet, Lise Legrand, Flavie Ader, et al.. Saw-Tooth Cardiomyopathy: Clinical Presentation and Genetic Analysis. *JACC: Case Reports*, 2020, 2 (8), pp.1205-1209. 10.1016/j.jaccas.2020.05.072 . inserm-03996698

HAL Id: inserm-03996698

<https://inserm.hal.science/inserm-03996698>

Submitted on 20 Feb 2023

HAL is a multi-disciplinary open access archive for the deposit and dissemination of scientific research documents, whether they are published or not. The documents may come from teaching and research institutions in France or abroad, or from public or private research centers.

L'archive ouverte pluridisciplinaire **HAL**, est destinée au dépôt et à la diffusion de documents scientifiques de niveau recherche, publiés ou non, émanant des établissements d'enseignement et de recherche français ou étrangers, des laboratoires publics ou privés.

CASE REPORT

INTERMEDIATE

CLINICAL CASE

Saw-Tooth Cardiomyopathy

Clinical Presentation and Genetic Analysis



Julie Proukhnitzky, MD,^a Jérôme Garot, MD, PhD,^b Céline Bordet, MSc,^a Lise Legrand, MD,^a Flavie Ader, MD,^{c,d} Pascale Richard, MD, PhD,^{a,c,d} Philippe Charron, MD, PhD^{a,c}

ABSTRACT

Saw-tooth cardiomyopathy is a very rare disease, and only few cases have been published since its first description 10 years ago. We report the clinical presentation, imaging features and genetic analysis of a saw-tooth cardiomyopathy and argues that it should not be confused with left-ventricular noncompaction. (**Level of Difficulty: Intermediate.**) (J Am Coll Cardiol Case Rep 2020;2:1205-9) © 2020 The Authors. Published by Elsevier on behalf of the American College of Cardiology Foundation. This is an open access article under the CC BY-NC-ND license (<http://creativecommons.org/licenses/by-nc-nd/4.0/>).

A 33-year-old man presented with atypical chest pain for 6 months in a context of stress. Clinical examination was unremarkable and without signs of heart failure. The

electrocardiogram (ECG) showed sinus rhythm at 60 beats/min, PR interval 110 ms; QRS duration was 120 ms with left posterior fascicular block. T waves were negative on DIII and AvF derivations (Figure 1).

LEARNING OBJECTIVES

- Saw-tooth cardiomyopathy has a characteristic appearance in CMR and/or echocardiography, which is distinct from LVNC.
- Natural history is unclear, as are potential complications, but conduction abnormalities are described in previously reported cases.
- The pathophysiology is unknown, but family screening and genetic analyses may be reasonable options, given the frequent genetic background in the various cardiomyopathies.
- Additional cases are needed to better describe the disease and clarify the management.

MEDICAL HISTORY

Past history was characterized by a cardiac murmur during infancy that was not investigated.

DIFFERENTIAL DIAGNOSIS

The diagnosis of left-ventricular noncompaction (LVNC) was suspected. Adenosine perfusion stress cardiac magnetic resonance (CMR) was performed and did not find any ischemic features or myocardial infarction. There was no left-ventricular (LV) segmental asynergy or LV dilation (end-diastolic

From the ^aAPHP, Département de Génétique & Département de Cardiologie, Centre de Référence des Maladies Cardiaques Héritaires ou Rares, Hôpital Pitié-Salpêtrière, Paris, France; ^bInstitut Cardiovasculaire Paris Sud, Hôpital Privé Jacques Cartier, Ramsay Santé Massy, France; ^cSorbonne Université, INSERM, UMR_S 1166 and ICAN Institute for Cardiometabolism and Nutrition, Paris, France; and the ^dAPHP, UF Cardiogénétique et Myogénétique Moléculaire et Cellulaire, Service de Biochimie Métabolique, Hôpitaux Universitaires de la Pitié-Salpêtrière-Charles Foix, Paris, France. The authors have reported that they have no relationships relevant to the contents of this paper to disclose.

The authors attest they are in compliance with human studies committees and animal welfare regulations of the authors' institutions and Food and Drug Administration guidelines, including patient consent where appropriate. For more information, visit the *JACC: Case Reports* [author instructions page](#).

Manuscript received April 21, 2020; accepted May 6, 2020.

ABBREVIATIONS AND ACRONYMS

ACMG = American College of Medical Genetics

BNP = brain natriuretic peptide

CMR = cardiac magnetic resonance

ECG = electrocardiogram

LV = left ventricle

LVNC = left ventricular noncompaction

volume index 72 ml/m²). Index LV mass was 72 g/m², and left-ventricular ejection fraction was 55%. No LV hypertrophy was noticed, but very particular features were observed with protrusion of muscular bridges in the LV (Videos 1, 2, 3, and 4). Myocardium was dense and compacted, leading to the diagnosis of saw-tooth cardiomyopathy (Figure 2). There were no criteria for LVNC. Linear intramyocardial late enhancement was present in the basal wall of the LV, showing nonischemic pattern with sparing of the subendocardium (Figure 3).

INVESTIGATIONS

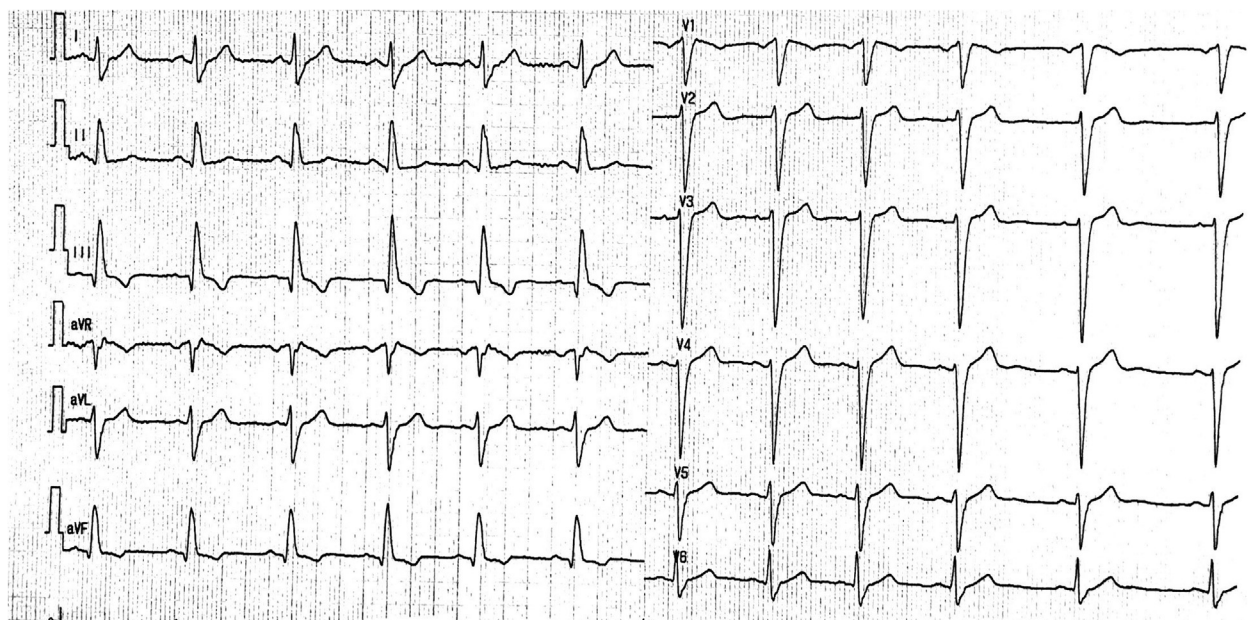
N-terminal pro-brain natriuretic peptide (BNP) level was 27 pg/ml (normal <450 pg/ml). Troponin levels were 6.5 ng/l (normal <14.0 ng/l). Eosinophils were low 17/mm³ (normal 100 to 400/mm³). The results of the rest of blood chemistry and thyroid function tests were normal. Echocardiography showed akinesia of the inferior and inferoseptal wall regions with aneurysms and trabecular abnormalities (Figure 4). A 24-h ECG Holter monitor was performed, without ventricular events or conduction defect.

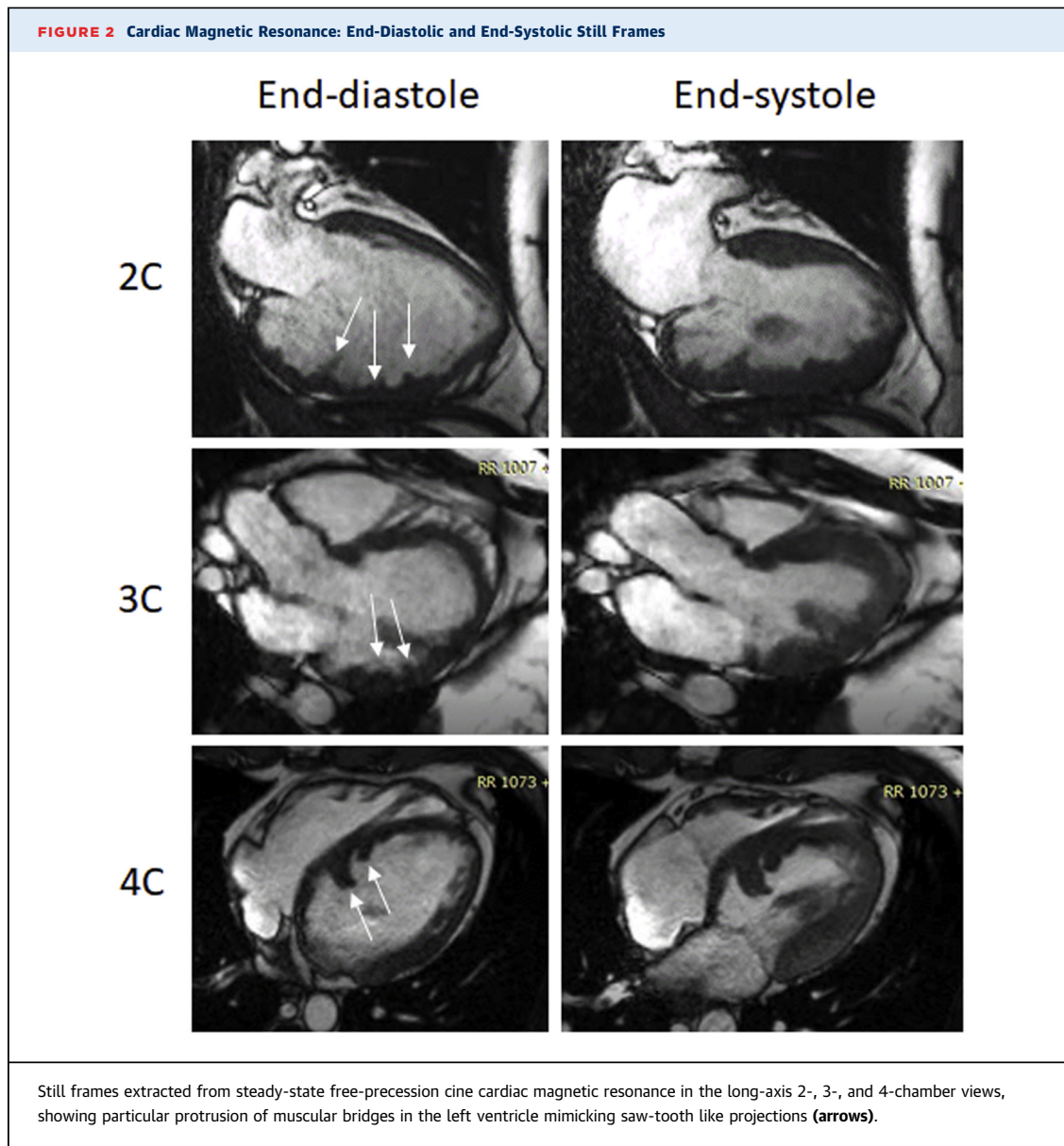
MANAGEMENT

Aspirin and proton pump inhibitor were started after the diagnosis. Because of this very rare diagnosis, the patient was referred to the Reference Centre for Rare Cardiac Diseases in Pitié-Salpêtrière Hospital in Paris, France. Familial cardiac screening found no other relatives suspected to have cardiomyopathy or who experienced sudden death. His father, a 61-year-old man, was followed for ischemic cardiopathy. The echocardiography did not find any aspect of the saw-tooth cardiomyopathy; his mother died of suicide at the age of 30 years. He has 2 children who will benefit from a systematic echocardiographic examination. The patient's family is originated from Portugal; parents are not consanguineous.

We performed genetic analysis by sequencing a large panel of 71 genes (including titin, exonic, and flanking region \pm 20 bp, Roche NimbleGen capture probes, sequencing on Miseq [Illumina, San Diego, California]), commonly associated with various cardiomyopathies (1). No pathogenic variant was found according to American College of Medical Genetics (ACMG) criteria adapted to the cardiomyopathy context.

FIGURE 1 12-Lead Electrocardiogram Showing a Left-Posterior Fascicular Block





DISCUSSION

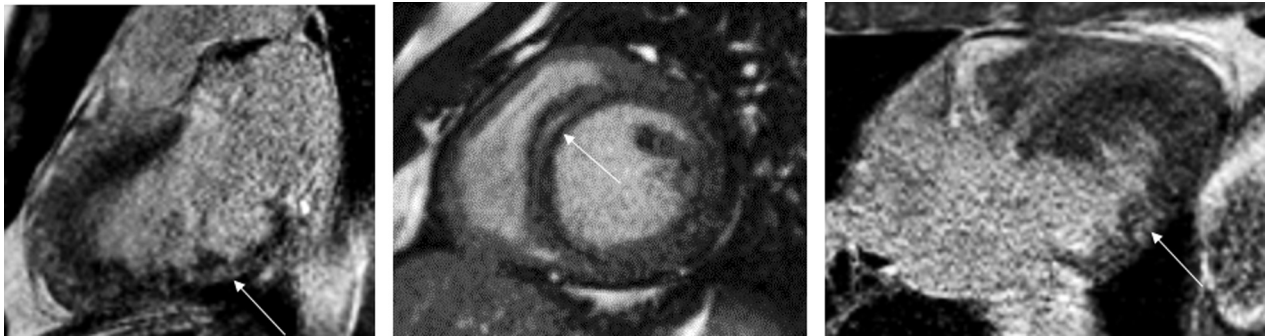
Saw-tooth cardiomyopathy is a very rare disease that was initially falsely reported as a variant of LVNC (2-5). Only 3 cases are reported in the literature with this specific entity (2-4). They report the presence of septal dysplasia and muscular bridges between the inferior and lateral walls. These myocardial features are very different from LVNC, and, in none of these cases, were LVNC criteria met.

Even though saw-tooth cardiomyopathy has been described in adults, the first case reported 10 years ago by Davlourous et al. (2), was in a 2-month-old

infant, suggesting a very early and probably prenatal development similar to LVNC.

Our case is the first to report on genetic testing and familial investigations. We did not identify any pathogenic mutation in the regions analyzed, even though a large panel of genes was studied, including all genes known as responsible for LVNC (1). This result may suggest a specific genetic cause outside the genes usually related to LVNC and may therefore suggest the search for a new gene associated with cardiomyopathies through exome or genome sequencing. On the other hand, it may also suggest a nongenetic cause, in agreement with

FIGURE 3 Cardiac Magnetic Resonance: Still Frames of the Left Ventricle



Still frames extracted from 3-dimensional inversion recovery gradient echo sequences in the 2-chamber, short-axis, and 4-chamber views showing mild intramyocardial and subepicardial late enhancement 10 min after injection of 0.1 mM of gadolinium chelates (arrows).

the absence of family history, but neither the negative genetic result nor the family history can exclude a genetic basis. Indeed, in LVNC, mutations are found in only 43% of the patients in our cohort (1).

FOLLOW-UP

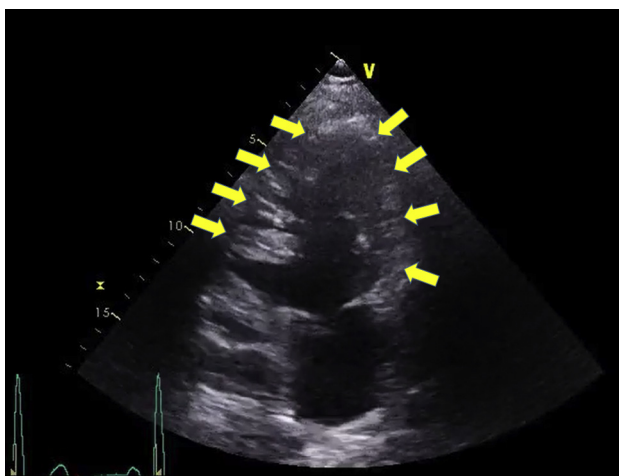Our patient in this case had few symptoms and did not develop major cardiac complications, but the follow-up is still limited (25 months without clinical event since the initial diagnosis by magnetic

resonance imaging). In the literature, 1 patient had experienced heart failure at 1 month of age (4), and the patient in the first case reported by Davlourous et al. (2) had high BNP levels, which could suggest myocardial dysfunction. No thromboembolic events occurred. Electric abnormalities, such as conductive disorders, are also described in a previous case (3). Arrhythmic events—such as premature ventricular complex, ventricular tachycardia, or sudden death—were not reported and need to be investigated. Clinical series are not available, and one therefore cannot stratify the risk and prevent complications that are common for other cardiomyopathies such as heart failure or arrhythmic and thromboembolic events.

CONCLUSIONS

We report the clinical presentation, imaging features, and genetic analysis of a saw-tooth cardiomyopathy, which should not be confused with LVNC. We did not identify any pathogenic mutation in a large panel of genes known to be responsible for various cardiomyopathies, suggesting a specific genetic cause outside the cardiomyopathy genes, even though we cannot exclude a nongenetic cause.

FIGURE 4 Echocardiographic Images




End-diastolic apical 4-chamber view showing muscular protrusions in the left cavity (arrows).

ADDRESS FOR CORRESPONDENCE: Prof. Philippe Charron, Hôpital Pitié-Salpêtrière, Département de Génétique, Bâtiment Rééducation, 47 Blvd de l'Hôpital Paris, 75856 Cedex 13, France. E-mail: philippe.charron@aphp.fr.

REFERENCES

1. Richard P, Ader F, Roux M, Donal E, Eicher J-C, Aoutil N, et al. Targeted panel sequencing in adult patients with left ventricular non-compaction reveals a large genetic heterogeneity. *Clin Genet* 2019;95:356-67.
2. Davlouros PA, Danias PG, Karatza AA, Kiaffas MG, Alexopoulos D. Saw-tooth cardiomyopathy. *J Cardiovasc Magn Reson* 2009;11:54.
3. Rafiq I, Ghosh-Ray S, Curtin J, Williams I. A previously undescribed variant of isolated left ventricular noncompaction. *J Am Coll Cardiol* 2010;56:741.
4. de Pinho Cardoso B, Trigo C, Jalles Tavares N, Pinto F. Sawtooth cardiomyopathy: a rare cause of heart failure. *Rev Port Cardiol* 2017;36:875-6.
5. Dawson DK, Davlouros PA, Kilner PJ. A saw-tooth rather than noncompacted variant of left ventricular structure. *J Am Coll Cardiol* 2011;57:999.

KEY WORDS cardiomyopathy, left-ventricular noncompaction, muscular bridges, saw-tooth cardiomyopathy, ventricular protrusions

 **APPENDIX** For supplemental videos, please see the online version of this paper.