



Crescentic glomerulonephritis with anti-PR3 ANCA associated with *Bartonella henselae* infective endocarditis

T. Andrian, E. Novel-Catin, C. Triffault-Fillit, M. Rabeyrin, C. Barba, L. Koppe, D. Fouque

► To cite this version:

T. Andrian, E. Novel-Catin, C. Triffault-Fillit, M. Rabeyrin, C. Barba, et al.. Crescentic glomerulonephritis with anti-PR3 ANCA associated with *Bartonella henselae* infective endocarditis. *Clinical Kidney Journal*, 2022, 15 (10), pp.1966-1968. 10.1093/ckj/sfac117 . inserm-03987310

HAL Id: inserm-03987310

<https://inserm.hal.science/inserm-03987310>





Submitted on 14 Feb 2023

HAL is a multi-disciplinary open access archive for the deposit and dissemination of scientific research documents, whether they are published or not. The documents may come from teaching and research institutions in France or abroad, or from public or private research centers.

L'archive ouverte pluridisciplinaire **HAL**, est destinée au dépôt et à la diffusion de documents scientifiques de niveau recherche, publiés ou non, émanant des établissements d'enseignement et de recherche français ou étrangers, des laboratoires publics ou privés.

LETTER TO THE EDITOR

Crescentic glomerulonephritis with anti-PR3 ANCA associated with *Bartonella henselae* infective endocarditis

Titus Andrian ^{1,2}, Etienne Novel-Catin ¹, Claire Triffault-Fillit³,
Maud Rabeyrin⁴, Christophe Barba¹, Laetitia Koppe ¹ and Denis Fouque ¹

¹Department of Nephrology Dialysis and Nutrition, Hôpital Lyon-Sud, Hospices Civils de Lyon, Pierre-Bénite, France, ²Grigore T. Popa University of Medicine and Pharmacy, Iași, Romania, ³Department of Infectious Diseases, Hospices Civils de Lyon, Pierre-Bénite, France and ⁴Department of Anatomopathology, Hospices Civils de Lyon, Pierre-Bénite, France

Correspondence to: Etienne Novel-Catin; E-mail: etienne.novel-catin@chu-lyon.fr

Glomerulonephritis associated with infective endocarditis is a form of immune-mediated glomerular injury and frequently presents with acute kidney injury (AKI) and kidney failure [1]. *Bartonella henselae* is a less common cause of endocarditis and occurs in patients with pre-existing valvular disease and cat-exposure. Antineutrophil cytoplasmic antibodies (ANCA) positivity and complement pathway activation in infective endocarditis make diagnosis challenging and treatment choices depend on the autoimmune or infectious origin of the glomerulonephritis [2].

Here we report a case of *B. henselae* infective endocarditis with crescentic glomerulonephritis and the presence of ANCA-PR3.

A 52-year-old male was admitted to the intensive care unit due to acute heart failure. Valvular heart disease was diagnosed with mitral stenosis and aortic regurgitation. Past medical history reported acute rheumatic fever during childhood. He described progressive weight loss, night sweating and low-grade fever. There was a history of travel to Mayotte Island, France and contact with cats.

Physical examination revealed a moderate mitral systolic murmur and complete remission of leg oedema. There was no rash or other systemic signs. On admission, laboratory tests showed stage 3 AKI, proteinuria and haematuria. Results of laboratory investigations are disclosed in Table 1. Repeated samples of blood cultures were negative.

Due to the positive result of ANCA-PR3, cortico-therapy was administered under the suspicion of rapidly progressive glomerulonephritis.

Kidney biopsy showed proliferative glomerulonephritis with C3, C1q and C4d deposits and crescents. Immunofluorescence study revealed diffuse mesangial Immunoglobulin M (IgM) deposits. Cortico-therapy was suspended (Fig. 1).

A transoesophageal-echocardiography showed a 3 mm image of the aortic valve. Positron emission tomography/computed tomography reported spleen enlargement without contrast-uptaking lesions. *Bartonella henselae* serology was positive and polymerase chain reaction test confirmed this infection. A cerebral magnetic resonance imaging (MRI) angiography displayed a frontal lobe microbleed area without evidence of an actual septic emboli.

Doxycycline (6 weeks) and gentamycin (2 weeks) were administered. After sepsis control, cortico-therapy was reintroduced. Kidney function slowly recovered and the patient was dismissed in a good health state. Long-term follow-up showed the same vibratile image on the aortic valve. The last estimated glomerular filtration rate (eGFR) was 39 mL/min/1.73 m² and proteinuria lowered to 0.8 g/24 h.

In a large cohort of patients with biopsy-proven glomerulonephritis associated with infective endocarditis, acute kidney failure was the most common clinical condition and 12% of

Received: 24.3.2022; Editorial decision: 25.4.2022

© The Author(s) 2022. Published by Oxford University Press on behalf of the ERA. This is an Open Access article distributed under the terms of the Creative Commons Attribution-NonCommercial License (<https://creativecommons.org/licenses/by-nc/4.0/>), which permits non-commercial re-use, distribution, and reproduction in any medium, provided the original work is properly cited. For commercial re-use, please contact journals.permissions@oup.com

Table 1. Laboratory tests

Creatinine ($\mu\text{mol/L}$)	346 $\mu\text{mol/L}$
eGFR CKD-EPI 2021 (mL/min/1.73 m^2)	15 mL/min/1.73 m^2
Proteinuria (g/24 h)	1.8 g/24 h
Haematuria (RBC per HPF)	45
Haemoglobin	7.9 g/dL
HIV, hepatitis C, hepatitis B serologies	Negative
Complement factor 3 (g/L)	0.7 g/L
Anti-nuclear antibody	Negative
Anti-double stranded DNA	Negative
Anti-glomerular basement membrane	Negative
Anti-neutrophil cytoplasmic antibody (ANCA) MPO	Negative
Anti-neutrophil cytoplasmic antibody (ANCA) PR3 ^a	Positive
Cryoglobulin	Positive (mixed)

^a ANCA PR-3 were determined by immunofluorescence testing and flow flurometry (Biorad reactive). CKD-EPI, Chronic kidney disease epidemiology collaboration; RBC, red blood cells; HPF, high-power field.

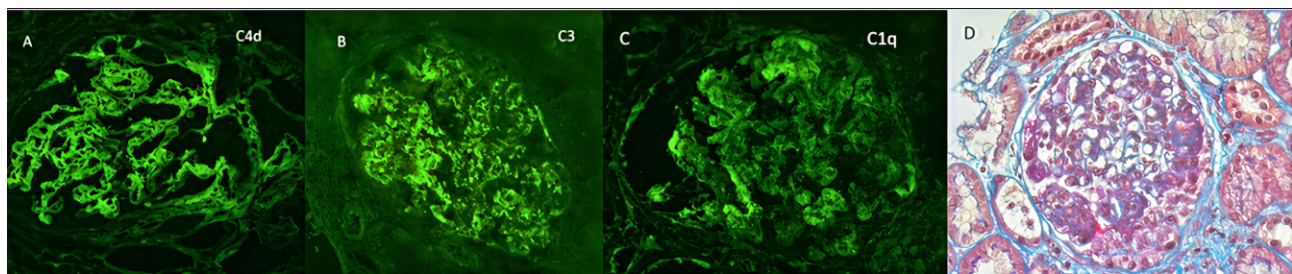


FIGURE 1: Kidney biopsy. (A) C4d deposits on immunofluorescence (IF). (B) C3 deposits on IF. (C) C1q deposits on IF. (D) Masson-Trichrome staining, $\times 400$. Mesangial and endocapillary proliferation with cellular crescent and fibrinoid necrosis.

patients had prior valvular disease. *Bartonella henselae* was found in 4/49 patients. More than half of the patients (53%) had a crescentic pattern and C3 deposits were present in 94% of biopsies. Immunoglobulin deposition was heterogenous: IgM staining appeared to be dominant (37%). However, 6% of biopsies were negative for all deposits and only 4% had a pattern of simultaneous IgG, IgM and IgA positivity. Interestingly, immunosuppressive treatment was added to antibiotics in 33% of patients [1]. In another series of 24 patients infected with *Bartonella*, ANCA-PR3 was positive in 83% and glomerulonephritis was found in 92%. [3] Thus, *Bartonella* infection induces a heterogenous auto-immune response and differential diagnosis in this setting may be puzzling. It has been reported that concomitant markers of auto-immunity (e.g. cryoglobulins or low complement) may be more suggestive of bacterial-induced endocarditis [4].

Moreover, in a series of 27 patients with ANCA-positive infective endocarditis with kidney injury, authors reported that *Bartonella* sp. was the most common pathogen (30%) [5].

The main diagnosis to exclude in infectious endocarditis-associated glomerulonephritis is an ANCA pauci-immune necrotizing glomerulonephritis. In order to attempt kidney salvage therapy, particularly in non-responsive patients, immunosuppressive treatment can be offered only after septic control [6].

This case highlights the complexity of diagnosis in the setting of crescentic glomerulonephritis associated with *B. henselae* endocarditis and ANCA-PR3 positivity. Necrotizing

glomerulonephritis required corticosteroid therapy that was added after infection control and favourable patient outcome was achieved.

CONFLICT OF INTEREST STATEMENT

All authors declare that they have no conflicts of interest.

PATIENT CONSENT

The patient consented to the use of his medical record in order to publish respecting his privacy.

REFERENCES

- Boils CL, Nasr SH, Walker PD et al. Update on endocarditis-associated glomerulonephritis. *Kidney Int* 2015; 87: 1241–9
- Satoskar AA, Parikh SV, Nadasdy T. Epidemiology, pathogenesis, treatment and outcomes of infection-associated glomerulonephritis. *Nat Rev Nephrol* 2020; 16: 32–50
- Beydon M, Rodriguez C, Karras A et al. *Bartonella* and *Coxiella* infections presenting as systemic vasculitis: case series and review of literature. *Rheumatology (Oxford)* 2022; 61: 2609

4. Bannon L, Choshen G, Giladi M et al. *Bartonella* endocarditis masquerading as systemic vasculitis with rapidly progressive glomerulonephritis (aka 'Löhleins nephritis'). *BMJ Case Rep* 2019; **12**: e231413
5. Zhang W, Zhang H, Wu D et al. Antineutrophil cytoplasmic antibody-positive infective endocarditis complicated by acute kidney injury: a case report and literature review. *J Int Med Res* 2020; **48**: 030006052096399. doi: 10.1177/0300060520963990.
6. Nasr SH, Radhakrishnan J, D'Agati VD. Bacterial infection-related glomerulonephritis in adults. *Kidney Int* 2013; **83**: 792–803