



**HAL**  
open science

## Imaging biomarker discovery in major depressive disorder with diffusion MRI multi-compartment models

Renaud Hedouin, Olivier Commowick, Julie Coloigner

### ► To cite this version:

Renaud Hedouin, Olivier Commowick, Julie Coloigner. Imaging biomarker discovery in major depressive disorder with diffusion MRI multi-compartment models. OHBM 2022 - 28th Annual Meeting of the Organization for Human Brain Mapping, Jun 2022, Glasgow, United Kingdom. inserm-03934869

**HAL Id: inserm-03934869**

**<https://inserm.hal.science/inserm-03934869v1>**

Submitted on 11 Jan 2023

**HAL** is a multi-disciplinary open access archive for the deposit and dissemination of scientific research documents, whether they are published or not. The documents may come from teaching and research institutions in France or abroad, or from public or private research centers.

L'archive ouverte pluridisciplinaire **HAL**, est destinée au dépôt et à la diffusion de documents scientifiques de niveau recherche, publiés ou non, émanant des établissements d'enseignement et de recherche français ou étrangers, des laboratoires publics ou privés.

# Imaging biomarker discovery in major depressive disorder with diffusion MRI multi-compartment models

Poster No:

1937

Submission Type:

Abstract Submission

Authors:

[renaud hedouin](#)<sup>1</sup>, Olivier Commowick<sup>1</sup>, Julie Coloigner<sup>1</sup>

Institutions:

<sup>1</sup>INRIA, Rennes, Bretagne

First Author:

*renaud hedouin*

INRIA

Rennes, Bretagne

Co-Author(s):

*Olivier Commowick*

INRIA

Rennes, Bretagne

*Julie Coloigner*

INRIA

Rennes, Bretagne

Introduction:

Major depressive disorder (MDD) is a disease widespread all over the world associated with a large and increasing economic, societal, and personal burden [Ferrari 2013]. Yet, the pathophysiology underlying MDD is not well understood, and rates of either non-response to treatment or MDD recurrence remain high. Many studies have already demonstrated impaired WM integrity, which corresponds to a FA decrease in the patient group compared to control subjects, with significant results found in several brain regions [Coloigner 2019]. Yet, the comparison between treatment-resistant and non-treatment-resistant populations has never been addressed. The FA at the voxel level provided by the classic diffusion tensor imaging (DTI) does not accurately describe the underlying microstructure. We propose a tract-based pipeline analysis using multi-compartment models (MCM) that allows to model water diffusion under the voxel resolution.

Methods:

We used the AMYNET database, constituted of 20 depressed unipolar resistant (TRD), 9 depressed unipolar in remission (nTRD) and 19 healthy subjects between 18 and 35 years. Half-noddi DWI sequences (similar

to the noddif sequence [Zhang 2012] while avoiding the redundancy of information) were acquired with 2 mm isotropic resolution, 97 gradient orientations distributed on 2 spheres ( $b = 700$  and  $b = 3000$  s.mm<sup>-1</sup>) and 7  $b_0$ . 3D MP2RAGE sequences were used to reconstruct a bias-free T1-weighted image for registration purposes [Marques 2010]. The data were processed with an open-source medical imaging toolbox *Anima* including eddy current correction, brain extraction, block-matching distortion correction [Hedouin 2017], NL-means denoising.

The DTI model comports limitation, in particular, to disentangle complex sources of water diffusion, as crossing fiber. To tackle this issue, a MCM that decomposes the water diffusion as a weighted sum of 3 anisotropic tensors which represent fiber bundles in different directions along with 2 isotropic compartments for free water (FW), and iso-restricted water was estimated [Stamm 2016]. To perform group comparison, all data were registered on the MNI152 atlas (an average of 152 T1-weighted MRI scans) [Grabner 2006] using dense transformation [Commowick 2012] estimated between the T1-weighted subject and T1-weighted atlas images. The transformations were directly applied to the MCMs using a specific registration framework [Hedouin 2020].

A deterministic tractography was performed on the entire brain atlas and filtered using *TractSeg* [Wasserthal 2018] resulting in 72 identified fiber bundles. For all MCMs on the MNI atlas, each fiber bundle was used to extract microstructure properties for all patients using the closest anisotropic compartment (FA, MD, axial, radial) and the isotropic compartments (FW, iso-restricted) of the MCM. Finally, a two-sample t-test (Student's test) statistic analysis was performed along the tracts between the two groups.

## Results:

We tested this entire pipeline on the AMYNET database. We compare in Figure 1, the FW weight difference between the TRD group (19 subjects) and the healthy group (19 subjects) along the left parieto-occipital pontine (POPT) tract. We can notice an increase of the FW within the TRD group compared with the healthy group with a significant p-value. This is consistent with previous studies linking degradation of WM, expected within the TRD population, with an increase of the FW weight [Jacobs 2015]. Let notice that those MCM parameters offer an interpretation of the brain structure at a microscopic level than cannot provide DTI parameters.

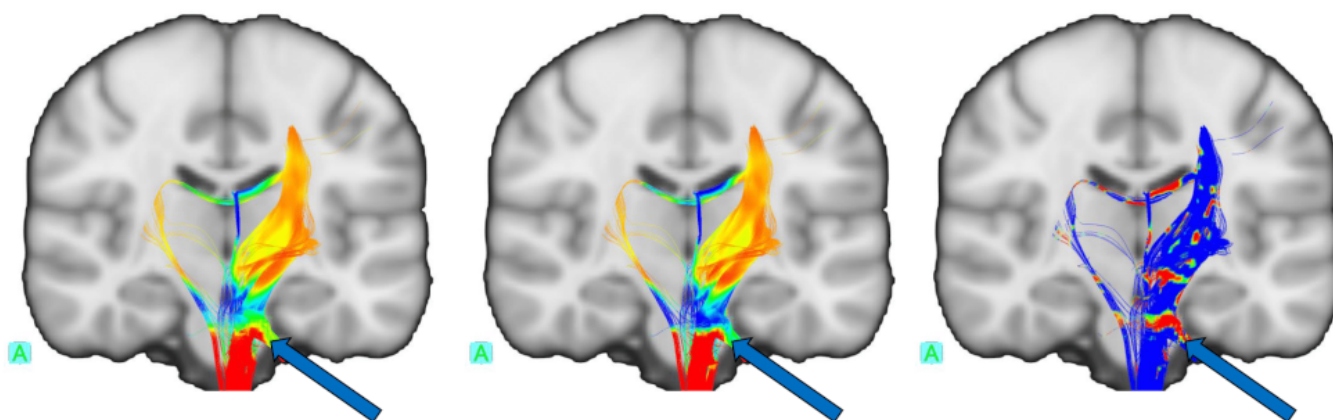


Figure 1: Statistic on the FW weight along left POPT tract. Left: Average controls groups, Middle: Average TRD group, Right: P-Value of the Student's test

([https://files.aievolution.com/prd/hbm2201/abstracts/abs\\_1814/OHBM\\_Fig1.png](https://files.aievolution.com/prd/hbm2201/abstracts/abs_1814/OHBM_Fig1.png))

## Conclusions:

We proposed a method to treat high-quality data that can reveal subtle microstructure change using MCM. We showed an example of microstructure parameters tracts unavailable using the standard DTI. Further studies with larger populations including nTRD will be conducted. We will do so using MCM and quantitative MRI (relaxometry) in addition to clinical data using these multiple modalities as a whole.

## Disorders of the Nervous System:

Psychiatric (eg. Depression, Anxiety, Schizophrenia) <sup>2</sup>

## Modeling and Analysis Methods:

Diffusion MRI Modeling and Analysis <sup>1</sup>

Image Registration and Computational Anatomy

## Keywords:

MRI

Psychiatric Disorders

WHITE MATTER IMAGING - DTI, HARDI, DSI, ETC

Other - Multi-compartment-model

<sup>1</sup><sup>2</sup>Indicates the priority used for review

My abstract is being submitted as a Software Demonstration.

No

Please indicate below if your study was a "resting state" or "task-activation" study.

Other

Healthy subjects only or patients (note that patient studies may also involve healthy subjects):

Patients

Was any human subjects research approved by the relevant Institutional Review Board or ethics panel? NOTE: Any human subjects studies without IRB approval will be automatically rejected.

Yes

Was any animal research approved by the relevant IACUC or other animal research panel? NOTE: Any animal studies without IACUC approval will be automatically rejected.

Not applicable

Please indicate which methods were used in your research:

Structural MRI

Diffusion MRI

For human MRI, what field strength scanner do you use?

3.0T

Which processing packages did you use for your study?

Other, Please list - Anima

Provide references using author date format

Coloigner (2019) White matter abnormalities in depression: A categorical and phenotypic diffusion MRI study, *Neuroimage*

Commowick (2012) Automated diffeomorphic registration of anatomical structures with rigid parts: Application

to dynamic cervical MRI, *MICCAI*

Ferrari (2013) Burden of depressive disorders by country, sex, age, and year: findings from the global burden of disease study 2010, *PLoS medicine*

Jacobs (2015) Characterization of the Wallerian degeneration process in the rat spinal cord with DIAMOND and NODDI: comparison with histological observations, *Proc. Intl. Soc. Mag. Reson. Med*

Grabner (2006) Symmetric atlasing and model based segmentation: an application to the hippocampus in older adults, *MICCAI*

Hédouin (2017) Block-matching distortion correction of echo-planar images with opposite phase encoding directions, *Transactions on Medical Imaging*

Hédouin (2020) Interpolation and averaging of diffusion MRI multi-compartment models, *Transactions on Medical Imaging*

Stamm (2016) Comprehensive maximum likelihood estimation of diffusion compartment models towards reliable mapping of brain microstructure, *MICCAI*

Wasserthal (2018) TractSeg-Fast and accurate white matter tract segmentation, *NeuroImage*

Zhang (2012) NODDI: practical in vivo neurite orientation dispersion and density imaging of the human brain. *Neuroimage*