



HAL
open science

MRI Spot Sign In Acute Intracerebral Hemorrhage: An Independent Biomarker of Hematoma Expansion and Poor Functional Outcome

Nefeli Valyraki, Adrien Goujon, Marjorie Mateos, Adrien Lecoeuvre, Augustin Lecler, Igor Raynouard, Candice Sabben, Michael Obadia, Julien Savatovsky, Pierre Seners

► **To cite this version:**

Nefeli Valyraki, Adrien Goujon, Marjorie Mateos, Adrien Lecoeuvre, Augustin Lecler, et al.. MRI Spot Sign In Acute Intracerebral Hemorrhage: An Independent Biomarker of Hematoma Expansion and Poor Functional Outcome. *Journal of Neurology*, 2022, Online ahead of print. 10.1007/s00415-022-11498-w . inserm-03878769

HAL Id: inserm-03878769

<https://inserm.hal.science/inserm-03878769>

Submitted on 30 Nov 2022

HAL is a multi-disciplinary open access archive for the deposit and dissemination of scientific research documents, whether they are published or not. The documents may come from teaching and research institutions in France or abroad, or from public or private research centers.

L'archive ouverte pluridisciplinaire **HAL**, est destinée au dépôt et à la diffusion de documents scientifiques de niveau recherche, publiés ou non, émanant des établissements d'enseignement et de recherche français ou étrangers, des laboratoires publics ou privés.

MRI Spot Sign In Acute Intracerebral Hemorrhage: An Independent Biomarker of Hematoma Expansion and Poor Functional Outcome

Nefeli Valyraki,¹ MD; Adrien Goujon,² MD; Marjorie Mateos,³ MD; Adrien Lecoeuvre,⁴ MD-MSc; Augustin Lecler,² MD, PhD; Igor Raynouard,¹ MD; Candice Sabben,¹ MD; Michael Obadia,¹ MD; Julien Savatovsky,² MD; Pierre Seners,^{1,5} MD, PhD

1: Neurology Department, A. de Rothschild Foundation Hospital, Paris, France.

2: Radiology Department, A. de Rothschild Foundation Hospital, Paris, France.

3: CHU de Lille, Department of Neuroradiology, Lille, France.

4: Clinical Research Department, A. de Rothschild Foundation Hospital, Paris, France.

5: Institut de Psychiatrie et Neurosciences de Paris (IPNP), UMR_S1266, INSERM, Université de Paris, Paris.

Correspondence to Dr. Pierre Seners, Neurology Department, Hospital Foundation A. de Rothschild; 29, rue Manin, 75019 Paris, France. E-mail: pierre.seners@gmail.com
Phone: 33-1-48-03-68-52.

Key words: Cerebral Hemorrhage, Magnetic Resonance Imaging, Stroke, Prognosis

Statements and Declarations: the authors declare that they have no conflict of interest.

Acknowledgements: Sophie Rushton-Smith, PhD (MedLink Healthcare Communications) provided editorial assistance and was funded by the authors.

Source of funding: none.

ABSTRACT

BACKGROUND: In acute intracerebral hemorrhage (ICH), the prognostic value of the MRI spot sign on hematoma expansion (HE) and poor functional outcome is poorly known.

METHODS: We retrospectively included patients admitted over a 4-year period for an acute ICH in a single institution using MRI as the first-line imaging tool. The presence and number of MRI spot signs on contrast-enhanced T1-weighted imaging was evaluated by one neuroradiologist, blinded from outcomes. The primary outcome was HE, defined as >6mL or >33% ICH volume growth from initial MRI to 24–48 h follow-up imaging; the secondary outcome was poor 3-month modified Rankin score (4–6).

RESULTS: Overall, 147 patients were included, and 62% had a spot sign. Among the 130 patients with follow-up imaging, 24% experienced HE. HE occurred in 6%, 21% and 43% patients with 0, 1 and ≥ 2 spots, respectively ($P < 0.001$). The MRI spot sign was independently associated with HE (adjusted OR, 6.15 [95%CI 1.60–23.65]; $P = 0.008$), with a dose-dependent effect. The negative and positive predictive values of the spot sign for HE were 0.94 and 0.35, respectively. Poor functional outcome occurred in 27%, 32% and 71% patients with 0, 1 and ≥ 2 spots, respectively ($P < 0.001$). In multivariable analysis, the presence of ≥ 2 spots was independently associated with poor functional outcome (adjusted OR, 3.67 [95%CI 1.21–11.10]; $P = 0.024$).

CONCLUSION: The MRI spot sign is an independent biomarker of HE, and the presence of ≥ 2 spots is independently associated with poor 3-month outcome. The lack of spot sign is highly predictive of a favorable evolution.

INTRODUCTION

Acute intracerebral hemorrhage (ICH) represents 10–20% of all strokes, and leads to high mortality rates and severe disability in most survivors [1, 2]. Hematoma expansion (HE) is common in the acute phase of ICH, occurring in 20–40% of patients, and is strongly associated with poor clinical outcome [3-6]. Although the benefits of therapies targeting HE have currently not been demonstrated, stratification of HE risk following initial imaging could influence the triage and intensity of monitoring of ICH patients and improve their prognosis [7]. Moreover, accurate prediction of HE may be useful to inform relatives about the patient's prognosis, and could help in the design of randomized trials testing interventions to limit HE.

The spot sign, defined as enhancing foci on imaging within acute ICH corresponding to active bleeding, is an important predictor of HE [3, 8]. Using computed tomography angiography (CTA), an independent association between spot sign and HE has been consistently found in several studies, regardless of the spot sign definition, the timing of CTA acquisition (arterial, venous or parenchymal phase) and the definition used for HE [3, 4, 9-12]. Consequently, the recent guidelines from the American Heart Association/American Stroke Association state that CTA may be reasonable to identify patients at risk for subsequent HE [7]. However, few data exist regarding the predictive value of the spot sign evaluated on MRI [13, 14], which is the first-line imaging tool in some countries for acute neurological deficits. In the modern era, only one small-scaled, single-center study has shown an association between MRI spot sign and discharge modified Rankin Scale (mRS) score [13], but its association with functional outcome assessed at a later time-point and with HE is still unknown.

Here, we tested the hypothesis that the presence of a spot sign evaluated on contrast-enhanced T1-weighted imaging is an independent biomarker of HE and poor functional outcome in patients with acute ICH.

METHODS

Study Design and Data Sources

We retrospectively collected the data from all consecutive patients with acute ICH admitted within 24 h from last seen well in our institution between January 2018 and December 2021, a comprehensive stroke center in Paris, with available baseline MRI including a contrast-enhanced T1-weighted sequence. Acute phase management was done according to European guidelines, including blood pressure target below 140/90 mmHg [15, 16]. Patients with secondary ICH such as trauma, underlying neoplasm, or hemorrhagic venous infarct were excluded. Patients who underwent surgery for hematoma evacuation before 24 h follow-up imaging were excluded from the primary outcome analysis (HE) but were included in the secondary outcome analysis (3-month mRS). Conversely, patients without an available 3-month mRS score were excluded from the secondary analysis, but were included in the primary outcome analysis. Our analysis was conducted according to the Strengthening the Reporting of Observational Studies in Epidemiology criteria for observational studies [17]. The research was approved by the Rothschild Foundation Hospital review board. Formal informed consent was waived by the ethics committee owing to the retrospective design.

Clinical Data

The following variables were collected: age, sex, vascular risk factors, prior vascular events, pre-stroke antithrombotic medication, National Institute of Health Stroke Scale (NIHSS) score on admission and at 24 h, systolic and diastolic blood pressures on admission and hourly during the first 24hrs, and pre-stroke and 3-month modified Rankin Scale (mRS) score. We also collected the date and time of last seen without neurological deficit, time of symptoms onset (or symptoms discovery in case of unwitnessed stroke onset) and baseline MRI. On admission blood sample, we collected platelets count, prothrombin ratio, international normalized ratio (INR), activated partial thromboplastin time ratio and fibrinogen level.

Radiological Data

Imaging Protocol

MRI is systematically implemented as the first-line imaging tool in acute stroke suspicions in our center, except in the case of MRI contraindication or severe agitation. The acute stroke protocol, which is similar for all patients, is performed on a 3T MRI scanner (Philips 3T Ingenia Elition, Best, the Netherlands) included diffusion-weighted imaging, intracranial T1-weighted time-of-flight magnetic resonance angiography, 3D fluid-attenuated inversion recovery, susceptibility-weighted imaging (SWI), and a contrast-enhanced turbo spin echo T1-weighted imaging. The MRI parameters were as follows: 3D turbo spin echo T1 postcontrast (repetition time/echo time/turbo spin echo factor=450 ms/27 ms/25; field of view 230×203 mm, matrix 232×203, slice thickness 1.3 mm, compress sense factor 10; acquisition duration 56 s), 3-dimensional SWI (repetition time/echo time=30/7, 13.5, 20, 26.5 ms; field of view 235×174mm, matrix 336×194, slice thickness 2 mm, compress sense factor 8; acquisition duration 54 s). The gadolinium injection was done with a bolus of Gadobutrol 0.1 mL/kg. The delay between contrast agent injection and the beginning of the T1-weighted imaging was between 150 and 180 seconds. Noncontrast CT was regularly performed immediately after MRI to obtain a reference CT at baseline, and this subset of patients was used to compare ICH volume between the two imaging modalities (see below). Follow-up imaging (CT or MRI) was routinely scheduled ≈24 h from baseline imaging to evaluate HE.

Imaging Analysis

To optimize homogeneity in radiological evaluation, one neuroradiologist (AG) reviewed all baseline MRI using a structured form, blinded to clinical and radiological outcomes. The following variables were collected: (1) hematoma topography, categorized as deep, lobar or infratentorial; (2) associated intraventricular hemorrhage; (3) microbleed presence and location; (4) extent of white matter hyperintensities, using the Fazekas classification; and (5) presence of the spot sign and the number of spots on contrast-enhanced T1-weighted imaging. The spot sign was defined according to 2 criteria: (1) spot-like or serpiginous high signal intensity >1.5 mm in at least one dimension located within the

margin of the hematoma and without connection to an outside vessel; and (2) no hyperintensity at the corresponding location on nonenhanced T1-weighted time-of-flight magnetic resonance angiography. Typical cases with and without the spot sign are shown in **Figure 1**. To assess reproducibility of spot sign evaluation, another neuroradiologist (MM) reviewed a random subset (n=50) of baseline MRIs, and a consensus was made for discrepant cases. Three months apart from spot-sign evaluation, the second neuroradiologist performed the volumetric hematoma measurements on baseline MRI (SWI), acute noncontrast CT (in the subset of patients with acute CT acquired immediately after MRI), and 24 h CT or MRI (SWI), using the Carestream Vue PACS software, blinded from clinical outcomes and spot sign status.

Study Outcomes

The primary outcome was substantial HE, defined as an absolute ICH volume growth >6 mL or a relative growth >33% from initial MRI to 24 h follow-up imaging [3]. In patients for whom HE was evaluated from baseline MRI to 24 h CT, a 11% correction of baseline MRI ICH volume was applied to account for the MRI-to-CT volumetric overestimation observed in the subset of patients with both acute MRI and CT (see Results). The secondary outcome was poor functional outcome, defined as a mRS score of 4–6 at 3 months considering the overall poor functional outcome in patients with acute ICH.

Statistical Analysis

Continuous variables are described as mean±standard deviation or median (interquartile range [IQR]), as appropriate, and categorical variables as numbers and percentages. Interobserver agreement for spot sign presence and number of spots was measured using Kappa and overall weighted Kappa statistics, respectively. Univariable relationships between HE and baseline characteristics were assessed using Student's *t* test or the Mann-Whitney U test for continuous variables, and the Chi-square test or Fisher's exact test for categorical variables, as appropriate. To adjust for potential confounders, multivariable binary logistic regression analysis was performed using a forward stepwise selection procedure with HE as the dependent variable. Covariates candidates into the multivariable regression

model were significant at a threshold of $P < 0.20$ in the univariable analysis. Covariates were assessed for collinearity and interaction effects. The same procedure was repeated with poor functional outcome (mRS 4–6) as the dependent variable. Last, sensitivity, specificity, and positive and negative predictive values of the MRI spot sign to predict outcomes were calculated. All tests were 2-tailed, and the threshold for statistical significance was set to $P < 0.05$. Statistical analyses were conducted using SPSS 28.0 (IBM, Armonk, NY) and R version 4.0.4 (R Project for Statistical Computing).

RESULTS

Study Population

During the study period, 194 patients with acute ICH were admitted in our institution. Among these, 147 fulfilled the inclusion criteria (see **Figure 2** for exclusion reasons). The comparison of included vs excluded patients is provided in **Table 1**. Excluded patients had higher rates of atrial fibrillation and pre-stroke anticoagulant therapy, and higher baseline NIHSS than included patients, but the two populations were otherwise similar. Included patients had a median age of 66 (IQR, 53–80) years, 50 (34%) were female, median NIHSS was 13 (IQR, 8–19) and 33 (22%) patients had unwitnessed symptoms onset. Median last seen well-to-imaging time was 136 min (IQR, 100–289), symptoms discovery-to-imaging time was 111 min (IQR, 85–169), 99 (67%) patients had a deep ICH, and median ICH volume was 14 mL (IQR, 6–30). A spot sign was present in 91 (62%) patients. The number of spots was 0, 1 and ≥ 2 in 56/147 (38%), 31/147 (21%) and 60/147 (41%), respectively. The comparison of the spot-sign positive and negative patients is provided in **Table 2**. Patients with vs those without the spot sign were older, more frequently had antiplatelet therapy, had more severe NIHSS, earlier last seen well-to-imaging delay, and larger ICH volume. There was an excellent interobserver concordance for the presence of the spot sign (Kappa, 0.96 [95% CI, 0.88–1.00]) and the number of spots (overall weighted Kappa, 0.95 [95% CI, 0.90–1.00]).

Primary Outcome Analysis (HE)

One-hundred and thirty patients were included in the primary outcome analysis (see **Figure 2** for exclusion reasons). Follow-up imaging was CT in 128 patients and MRI in 2 patients; median

baseline-to-24 h follow-up imaging time was 23 h (IQR, 18–28). Fifty-nine patients had a noncontrast CT acquired immediately following the acute MRI (median MRI-to-CT delay, 25 min [IQR, 16–32]), with a median absolute ICH volume difference between CT and MRI of –1 mL (IQR, –2, 0) and a median relative ICH volume difference of –11% (IQR, –22, –3). Consequently, in an attempt to compensate for such ICH volume difference between MRI and CT, a –11% correction of baseline MRI ICH volume was applied for the HE evaluation in patients with a 24 h follow-up CT, with 31 (24%) patients experiencing HE. Poor 3-month functional outcome was significantly more frequent in patients with, as compared to those without, HE (22/31 [71%] vs 39/97 [41%], respectively; $P=0.003$).

Univariable Analysis

The univariable comparison of patients with vs without HE is presented in **Table 3**. HE was associated with older age, higher NIHSS, larger ICH volume and presence of the spot sign. HE occurred in 3/50 (6%), 6/29 (21%) and 22/51 (43%) patients with 0, 1 and ≥ 2 spots, respectively ($P<0.001$; **Figure 3A**). HE volume increased with the number of spots, being 0 mL (IQR, –1, 1), 1 mL (IQR, 0, 3) and 3 mL (IQR, 1, 9) in patients with 0, 1 and ≥ 2 spots, respectively ($P<0.001$). The sensitivity, specificity, and negative and positive predictive values of the spot sign for HE were 0.90 (95% CI, 0.74–0.98), 0.47 (0.37–0.58), 0.94 (0.83–0.99) and 0.35 (0.25–0.46), respectively. The mean systolic and diastolic blood pressure over the first 24hrs was similar in both groups (systolic blood pressure: median= 138 mmHg [IQR, 132-144] vs 140 mmHg [IQR, 136-145] in the no HE vs HE groups, respectively, $P=0.34$; diastolic blood pressure: median= 78 mmHg [IQR, 71-85] vs 80 mmHg [IQR, 65-85], respectively, $P=0.88$).

Multivariable Analysis

After stepwise variable selection into the multivariable model using the variables with $P<0.20$ from **Table 3**, the presence of the spot sign was independently associated with HE (OR, 6.15 [95% CI, 1.60–23.65]; $P=0.008$; adjusted on NIHSS and ICH volume; **Table 4**, Model 1). The odds of HE increased with the number of spots (**Table 4**, Model 2).

Secondary Outcome Analysis (3-Month mRS 4–6)

One-hundred and forty-five patients were included in the secondary outcome analysis (see **Figure 2** for exclusion reasons), of whom 67 (46%) had a poor 3-month functional outcome.

Univariable Analysis

The univariable comparison of patients with vs without poor functional outcome is presented in **Table 5**. Patients with poor functional outcome were older, had more vascular risk factors and previous stroke, higher NIHSS, higher fibrinogen level, larger ICH volume, more frequently intraventricular hemorrhage, microbleeds and a spot sign. The 3-month mRS range according to the number of spots is presented in **Figure 3B**. Poor functional outcome occurred in 15/55 (27%), 10/31 (32%), and 42/59 (71%) patients with 0, 1 and ≥ 2 spots, respectively ($P < 0.001$). The sensitivity, specificity, and negative and positive predictive values of the spot sign for poor functional outcome were 0.78 (95% CI, 0.66–0.87), 0.51 (0.40–0.63), 0.73 (0.59–0.84) and 0.58 (0.47–0.68), respectively.

Multivariable Analysis

After stepwise variable selection into the multivariable model using the variables with $P < 0.20$ from **Table 5**, there was a nonsignificant trend towards an independent association between the presence of the spot sign and poor 3-month functional outcome (**Table 4**, Model 1). However, there was a significant independent association between number of spots and 3-month poor functional outcome, after adjustment on age, NIHSS, diabetes, microbleeds and previous stroke (**Table 4**, Model 2). The results were very similar if ICH volume was forced into the multivariable models (data not shown).

DISCUSSION

This novel study aimed to evaluate the association between the MRI spot sign evaluated on a contrast-enhanced T1-weighted sequence and HE and poor functional outcome in patients with acute ICH.

Three salient findings emerged. First, the MRI spot sign was associated with an increased risk of HE. Second, the risk of HE increased with higher spot-sign burden. Third, the presence of 2 or more MRI spots was independently associated with poor 3-month functional outcome.

The prevalence of the spot sign was 62% in our cohort, which is higher than in the two previous single-center studies reporting spot sign on contrast-enhanced T1-weighted MRI in patients with acute ICH (33% and 49%, respectively) [13, 14]. The discrepancy may be explained by the use of a very low-field magnet in the former study (0.2T vs 3T) [14], the different types of contrast-enhanced T1-weighted sequence used [13, 14], and by an unusual low baseline NIHSS (median 6.5 vs 13 in our dataset) and long symptoms onset-to-imaging delay (7.2 h vs 2.3 h) for an acute ICH population in the latter study [13]. The prevalence of the CTA spot sign is also highly variable across studies (range, 18–60%) [3, 4, 9-12], the most influential factors likely being variability in the time from ICH onset to imaging and variations in time to CTA acquisition after administration of the contrast bolus [10, 12, 18]. Indeed, several CT studies have shown that the spot sign is a dynamic entity, being more prevalent in CTA acquired at the venous or parenchymal phase than in CTA acquired at the arterial phase [10, 12, 18].

To our knowledge, ours is the first study to show an independent association between the MRI spot sign and HE or poor functional outcome. In the 1990s, Murai *et al.* described a similar association using a 0.2T MRI, yet their results were not adjusted on important confounders such as baseline clinical severity or ICH volume, limiting their conclusions [14]. More recently, another group did not find an association between MRI spot sign and HE, likely due to the small sample size (n=25) [13]. They reported, however, a significant association with discharge mRS, but did not adjust the results on potential confounders [13]. In our study, the negative predictive value of the spot sign was high for both HE and poor functional outcome (0.94 and 0.73, respectively), but the positive predictive value

was low (0.35 and 0.58), indicating that a good radiological or clinical evolution is highly likely in the absence of the MRI spot sign, yet its presence does not reliably predict either HE or poor clinical outcome. The high sensitivity and low specificity are consistent with CTA studies evaluating spot sign at the venous phase or later, as done here on contrast-enhanced T1-weighted MRI. Using earlier, such as arterial, CTA acquisitions significantly reduces the sensitivity of spot sign but increases its specificity for HE prediction [10, 12]. The precise pathophysiological processes underlying the MRI spot sign are uncertain and may differ for CT, since MRI and CT are based on entirely different physical principles. In contrast to CTA, there is no contrast enhancement within the vessel in contrast-enhanced T1-weighted MRI. Hence, contrast-enhanced T1-weighted can only detect leakage of the contrast agent from an injured vessel, which may correspond to leakage from an active arterial source but also venous stasis or blood-brain barrier disruption [13, 19]. As far as we know, the MRI spot sign has never been studied on post-contrast arterial magnetic resonance angiography, and a direct comparison between CTA and MRI spot sign is lacking. Further studies are warranted.

Importantly, we found that the risk of HE was higher in the case of high spot sign burden (≥ 2 spots), in line with previous studies using the CTA spot sign [9, 20]. This dose-dependent relationship may help further to stratify the patients at risk of poor radiological evolution. However, while the presence of 2 or more spots was associated with a poor 3-month functional outcome, there was little difference in the prevalence of a poor functional outcome when comparing 0 and 1 spot sign, which might be due to a lack of power.

Our findings expand the clinical interest of the spot sign to the MRI population, which is the first-line imaging tool in some countries for suspicion of acute stroke. Stratifying the patients at high risk of HE or poor functional outcome using clinical and radiological biomarkers has several potential interests. First, it may help the triage and intensity of monitoring of ICH patients in centers where MRI is used as first-line imaging tool. For example, the clinical management of acute ICH patients without the spot sign (i.e., at very low risk of further deterioration) may reasonably be done in a primary stroke center without an on-site neurosurgery, whereas the monitoring of patients with ≥ 2 spots may be more

reasonable in comprehensive centers. Second, it is valuable to inform relatives about the patient's prognosis on admission. Last, it may have potential implications for clinical trial design in patients with acute ICH because the success of future treatments aiming to prevent HE may depend on accurate determination of patients at risk of HE (*e.g.*, selecting the patients with ≥ 2 MRI spots). For these reasons, adding a contrast-enhanced T1-weighted sequence to the standard MRI protocol may be of interest for centers using MRI to measure acute neurological deficits. The guidelines from the American Heart Association/American Stroke Association state that CTA may be reasonable to identify patients at risk for subsequent HE, and some centers with MRI as first-line imaging tool routinely perform a CT/CTA immediately following the acute MRI. As our results suggest that the MRI spot sign has a good predictive value for HE, repeating CT/CTA following an acute post-contrast MRI may not be warranted.

Our study has several limitations. First, roughly one-quarter of the patients with acute ICH admitted during the study were excluded, mainly because of the lack of a contrast-enhanced T1-weighted sequence. The contrast-enhanced T1-weighted sequence was mostly withheld to shorten the MRI duration in patients with severe condition or agitation, which induced a selection bias towards less severely affected patients. Second, our study is single center and had a moderate sample size. An external validation in a larger dataset is warranted. Third, we compared ICH volume on baseline MRI baseline with follow-up CT in most patients. However, the CT-to-MRI absolute difference in ICH volume measurement evaluated in the subset of patients with both CT and MRI on admission was small (median of -1 mL), and was taken into account in our analyses of HE. Last, the precise ICH topography (*i.e.*, according to brain regions eloquence) was not retrieved in our dataset, while it may be a relevant predictor of 3-month functional outcome. However, eloquent brain region evaluation is not always straightforward on visual imaging analysis. Moreover, the involvement of eloquent brain region is well captured by the admission NIHSS, which was included in our multivariable models.

CONCLUSION

The spot-sign evaluated on a contrast-enhanced T1-weighted MRI sequence is independently associated with HE, and the presence of ≥ 2 spots is an independent predictor of poor 3-month outcome. Given its high negative but low positive predictive values, the MRI spot sign may be of particular clinical interest when absent, being predictive of a good evolution.

REFERENCES

- [1]. Feigin VL, Lawes CM, Bennett DA, Barker-Collo SL, Parag V. Worldwide stroke incidence and early case fatality reported in 56 population-based studies: a systematic review. *Lancet Neurol.* 2009 **8**: 355-369.
- [2]. van Asch CJ, Luitse MJ, Rinkel GJ, van der Tweel I, Algra A, Klijn CJ. Incidence, case fatality, and functional outcome of intracerebral haemorrhage over time, according to age, sex, and ethnic origin: a systematic review and meta-analysis. *Lancet Neurol.* 2010 **9**: 167-176.
- [3]. Demchuk AM, Dowlatshahi D, Rodriguez-Luna D, *et al.* Prediction of haematoma growth and outcome in patients with intracerebral haemorrhage using the CT-angiography spot sign (PREDICT): a prospective observational study. *Lancet Neurol.* 2012 **11**: 307-314.
- [4]. Al-Shahi Salman R, Frantziadis J, Lee RJ, *et al.* Absolute risk and predictors of the growth of acute spontaneous intracerebral haemorrhage: a systematic review and meta-analysis of individual patient data. *Lancet Neurol.* 2018 **17**: 885-894.
- [5]. Davis SM, Broderick J, Hennerici M, *et al.* Hematoma growth is a determinant of mortality and poor outcome after intracerebral hemorrhage. *Neurology.* 2006 **66**: 1175-1181.
- [6]. Dowlatshahi D, Demchuk AM, Flaherty ML, Ali M, Lyden PL, Smith EE. Defining hematoma expansion in intracerebral hemorrhage: relationship with patient outcomes. *Neurology.* 2011 **76**: 1238-1244.
- [7]. Greenberg SM, Ziai WC, Cordonnier C, *et al.* 2022 Guideline for the Management of Patients With Spontaneous Intracerebral Hemorrhage: A Guideline From the American Heart Association/American Stroke Association. *Stroke.* 2022 **53**: e282-e361.
- [8]. Dowlatshahi D, Wasserman JK, Momoli F, *et al.* Evolution of computed tomography angiography spot sign is consistent with a site of active hemorrhage in acute intracerebral hemorrhage. *Stroke.* 2014 **45**: 277-280.
- [9]. Romero JM, Brouwers HB, Lu J, *et al.* Prospective validation of the computed tomographic angiography spot sign score for intracerebral hemorrhage. *Stroke.* 2013 **44**: 3097-3102.

- [10]. Ciura VA, Brouwers HB, Pizzolato R, *et al.* Spot sign on 90-second delayed computed tomography angiography improves sensitivity for hematoma expansion and mortality: prospective study. *Stroke*. 2014 **45**: 3293-3297.
- [11]. Brouwers HB, Goldstein JN, Romero JM, Rosand J. Clinical applications of the computed tomography angiography spot sign in acute intracerebral hemorrhage: a review. *Stroke*. 2012 **43**: 3427-3432.
- [12]. Rodriguez-Luna D, Dowlatshahi D, Aviv RI, *et al.* Venous phase of computed tomography angiography increases spot sign detection, but intracerebral hemorrhage expansion is greater in spot signs detected in arterial phase. *Stroke*. 2014 **45**: 734-739.
- [13]. Schindlbeck KA, Santaella A, Galinovic I, *et al.* Spot Sign in Acute Intracerebral Hemorrhage in Dynamic T1-Weighted Magnetic Resonance Imaging. *Stroke*. 2016 **47**: 417-423.
- [14]. Murai Y, Ikeda Y, Teramoto A, Tsuji Y. Magnetic resonance imaging-documented extravasation as an indicator of acute hypertensive intracerebral hemorrhage. *J Neurosurg*. 1998 **88**: 650-655.
- [15]. Steiner T, Al-Shahi Salman R, Beer R, *et al.* European Stroke Organisation (ESO) guidelines for the management of spontaneous intracerebral hemorrhage. *Int J Stroke*. 2014 **9**: 840-855.
- [16]. Sandset EC, Anderson CS, Bath PM, *et al.* European Stroke Organisation (ESO) guidelines on blood pressure management in acute ischaemic stroke and intracerebral haemorrhage. *Eur Stroke J*. 2021 **6**: Xlviii-lxxxix.
- [17]. von Elm E, Altman DG, Egger M, Pocock SJ, Gotsche PC, Vandenbroucke JP. The Strengthening the Reporting of Observational Studies in Epidemiology (STROBE) Statement: guidelines for reporting observational studies. *Int J Surg*. 2014 **12**: 1495-1499.
- [18]. Hallevi H, Abraham AT, Barreto AD, Grotta JC, Savitz SI. The spot sign in intracerebral hemorrhage: the importance of looking for contrast extravasation. *Cerebrovasc Dis*. 2010 **29**: 217-220.
- [19]. Murai Y, Ikeda Y, Morita A. Letter by Murai et al Regarding Article, "Spot Sign in Acute Intracerebral Hemorrhage in Dynamic T1-Weighted Magnetic Resonance Imaging". *Stroke*. 2016 **47**: e84.

[20]. Delgado Almandoz JE, Yoo AJ, Stone MJ, *et al.* The spot sign score in primary intracerebral hemorrhage identifies patients at highest risk of in-hospital mortality and poor outcome among survivors. *Stroke*. 2010 **41**: 54-60.

Table 1. Comparison of Included and Excluded Patients.

	Included N=147	Excluded N=47	P value
Age	66 (53-80)	64 (49-78)	0.25
Female gender	50 (34%)	16 (34%)	0.99
Vascular risk factors			
Hypertension	91 (62%)	28 (60%)	0.78
Diabetes	25 (17%)	11 (23%)	0.33
Dyslipidemia	26 (18%)	9 (19%)	0.42
Active smoking	21 (14%)	9 (19%)	0.42
Prior stroke	24 (16%)	10 (21%)	0.37
Prior atrial fibrillation	10 (7%)	10 (22%)	0.01
Pre-stroke medication			
Antiplatelets	24 (16%)	7 (15%)	0.82
Anticoagulant	19 (13%)	14 (30%)	<0.01
Systolic blood pressure, ^a mmHg	154 (138-171)	151 (133-171)	0.36
Diastolic blood pressure, ^a mmHg	86 (74-104)	81 (72-96)	0.19
NIHSS	13 (8-19)	18 (13-23)	<0.01
Last seen well-to-imaging time, min	136 (100-293)	127 (94-170)	0.47

Categorical variables are expressed as numbers (%) and continuous variables as median (IQR) or mean (SD). NIHSS indicates National Institute of Health Stroke Scale.

The reasons for exclusion are presented in Figure 2.

a: first blood pressure measured after arrival, in the imaging room.

Table 2. Comparison of Patients With and Without Spot Sign.

	Spot sign negative N=56	Spot sign positive N=91	P value
Age	62 (49-74)	69 (56-83)	0.01
Female gender	19 (34%)	31 (34%)	0.99
Medical history			
Vascular risk factors			
Hypertension	31 (55%)	60 (66%)	0.20
Diabetes	8 (14%)	17 (19%)	0.49
Dyslipidemia	11 (20%)	15 (17%)	0.63
Active smoking	5 (9%)	16 (18%)	0.15
Previous stroke	9 (16%)	15 (17%)	0.95
Previous atrial fibrillation	2 (4%)	8 (9%)	0.32
Pre-stroke medication			
Antiplatelets	4 (7%)	20 (22%)	0.02
Anticoagulant	4 (7%)	15 (17%)	0.10
Baseline clinical characteristics			
Systolic blood pressure, ^a mmHg	154 (141-172)	154 (136-170)	0.56
Diastolic blood pressure, ^a mmHg	87 (75-104)	89 (73-101)	0.53
NIHSS	8 (5-16)	16 (11-21)	<0.01
Baseline biological characteristics			
Platelets count, G/L	221 (186-274)	245 (192-289)	0.21
Prothrombin ratio, %	98 (88-100)	98 (88-100)	0.56
INR ≥ 1.20	6 (11%)	5 (6%)	0.33
Activated partial thromboplastin time ratio	0.97 (0.88-1.05)	0.99 (0.90-1.04)	0.61
Fibrinogen, g/L	3.7 (3.1-4.2)	3.9 (3.2-4.4)	0.46
Imaging characteristics			
Last seen well-to-imaging time, min	225 (126-445)	118 (90-185)	<0.01
Unwitnessed stroke onset	15 (27%)	18 (20%)	0.32
ICH location			
Deep	34 (61%)	65 (71%)	
Lobar	18 (32%)	24 (26%)	
Infratentorial	4 (7%)	2 (2%)	
Associated intraventricular hemorrhage	10 (18%)	30 (33%)	0.05
Microbleeds	21 (38%)	38 (42%)	0.61
ICH volume, ml	8 (4-19)	17 (9-34)	<0.01

Categorical variables are expressed as numbers (%) and continuous variables as median (IQR) or mean (SD). ICH indicates intracerebral hemorrhage, NIHSS, National Institute of Health Stroke Scale.

a: first blood pressure measured after arrival, in the imaging room.

Table 3. Univariable Associations Between Baseline Characteristics and Hematoma Expansion[†]

	Hematoma expansion (n=31)	No hematoma expansion (n=99)	P value
Age	75 (63–83)	65 (52–79)	0.03
Female sex	6 (19%)	36 (36%)	0.08
Medical history			
Vascular risk factors			
Hypertension	24 (77%)	59 (60%)	0.07
Diabetes	6 (19%)	14 (14%)	0.57
Dyslipidemia	5 (16%)	19 (19%)	0.70
Active smoking	6 (19%)	12 (12%)	0.37
Previous stroke	8 (26%)	14 (14%)	0.13
Previous atrial fibrillation	2 (7%)	6 (6%)	0.99
Pre-stroke medication			
Antiplatelets	7 (23%)	15 (15%)	0.34
Anticoagulant	6 (19%)	12 (12%)	0.37
Baseline clinical characteristics			
Systolic blood pressure ^a (mmHg)	154 (138–169)	153 (138–172)	0.82
Diastolic blood pressure ^a (mmHg)	91 (75–108)	84 (74–101)	0.53
NIHSS	19 (16–22)	11 (7–18)	<0.01
Baseline biological characteristics			
Platelets count, G/L	234 (191–284)	238 (191–277)	0.64
Prothrombin ratio, %	98 (89–100)	98 (89–100)	0.94
INR ≥ 1.20	2 (7%)	7 (7%)	1.0
Activated partial thromboplastin time ratio	0.98 (0.89–1.04)	0.99 (0.92–1.07)	0.50
Fibrinogen, g/L	3.8 (3.2–4.3)	3.9 (3.4–4.4)	0.44
Imaging characteristics			
Last seen well-to-imaging time (min)	113 (92–199)	148 (101–338)	0.18
Unwitnessed stroke onset	4 (13%)	23 (23%)	0.22
ICH location			
Deep	17 (55%)	70 (71%)	
Lobar	12 (39%)	25 (25%)	
Infratentorial	2 (7%)	4 (4%)	
Associated intraventricular hemorrhage	7 (23%)	27 (27%)	0.60
Microbleeds	14 (45%)	38 (38%)	0.50
ICH volume	24 (13–48)	11 (6–22)	<0.01
Spot sign	28 (90%)	52 (53%)	<0.01

Categorical variables are expressed as numbers (%) and continuous variables as median (interquartile range) or mean (standard deviation). ICH indicates intracerebral hemorrhage, and NIHSS, National Institute of Health Stroke Scale.

[†] Hematoma expansion was defined as an absolute ICH volume growth >6 mL or a relative growth >33% from initial MRI to 24 h follow-up imaging. In patients for whom HE was evaluated from baseline MRI to 24 h CT, a 11% correction of baseline MRI hematoma volume was applied, based on the median volume overestimation on susceptibility-weighted imaging observed in the subset of patients with both acute MRI and CT (see results).

a: first blood pressure measured after arrival, in the imaging room.

Table 4. Logistic Regression Models Showing Variables Independently Associated With Hematoma Expansion (Upper Part) and Poor Functional Outcome (Lower Part)

Primary outcome: Hematoma expansion at 24 h				
	Model 1		Model 2	
	Adjusted OR (95% CI)	P value	Adjusted OR (95% CI)	P value
NIHSS	1.10 (1.01–1.19) per each additional point	0.021	1.10 (1.01–1.19) per each additional point	0.028
ICH volume	1.03 (1.01–1.19) per each additional mL	0.028	1.03 (1.00–1.05) per each additional mL	0.047
Spot sign present	6.15 (1.60–23.65)	0.008	–	–
Number of spots	–	–	–	0.021
0	–	–	Ref.	
1	–	–	4.49 (0.94–21.60)	
≥2	–	–	7.03 (1.78–27.85)	
Secondary outcome: Poor 3-month functional outcome (mRS 4 to 6)				
	Model 1		Model 2	
	Adjusted OR (95% CI)	P value	Adjusted OR (95% CI)	P value
Age	1.03 (1.00–1.06) per each additional year	0.053	1.03 (1.00–1.07) per each additional year	0.027
NIHSS	1.24 (1.14–1.35) per each additional point	<0.001	1.23 (1.13–1.34) per each additional point	<0.001
Previous stroke	11.33 (2.67–48.03)	<0.001	9.77 (2.36–50.39)	0.002
Diabetes	3.83 (1.09–13.52)	0.037	3.47 (0.98–12.28)	0.054
Microbleeds	2.40 (0.94–6.11)	0.067	2.27 (0.87–5.90)	0.092
Spot sign present	2.29 (0.82–6.39)	0.114	–	–
Number of spots	–	–	–	0.024
0	–	–	Ref.	
1	–	–	0.94 (0.26–3.43)	
≥2	–	–	3.67 (1.21–11.10)	

CI indicates confidence interval; ICH, intracerebral hemorrhage, NIHSS, National Institute of Health Stroke Scale; and OR, odds ratio.

Table 5. Univariable Associations Between Baseline Characteristics and Poor 3-month Functional Outcome

	mRS 0–3 (n=78)	mRS 4–6 (n=67)	P value
Age	62 (49–75)	75 (62–83)	<0.01
Female sex	29 (37%)	20 (30%)	0.35
Medical history			
Vascular risk factors			
Hypertension	42 (54%)	48 (72%)	0.03
Diabetes	7 (9%)	18 (27%)	<0.01
Dyslipidemia	13 (17%)	12 (18%)	0.84
Active smoking	11 (14%)	10 (15%)	0.88
Previous stroke	4 (5%)	20 (30%)	<0.01
Previous atrial fibrillation	3 (4%)	7 (10%)	0.19
Pre-stroke medication			
Antiplatelets	6 (8%)	17 (25%)	<0.01
Anticoagulant	9 (12%)	10 (15%)	0.55
Baseline clinical characteristics			
Systolic blood pressure ^a (mmHg)	154 (139–167)	154 (138–181)	0.84
Diastolic blood pressure ^a (mmHg)	84 (73–98)	89 (75–106)	0.52
NIHSS	10 (5–14)	18 (15–22)	<0.01
Baseline biological characteristics			
Platelets count, G/L	241 (195-289)	227 (187-273)	0.24
Prothrombin ratio, %	98 (90-100)	98 (85-100)	0.25
INR ≥ 1.20	4 (5%)	7 (10%)	0.23
Activated partial thromboplastin time ratio	0.99 (0.90-1.05)	0.96 (0.90-1.03)	0.44
Fibrinogen, g/L	3.7 (2.9-4.1)	3.9 (3.4-4.5)	0.04
Imaging characteristics			
Last seen well-to-imaging time (min)	130 (92–253)	150 (103–304)	0.25
Unwitnessed stroke onset	17 (22%)	16 (24%)	0.77
Left ICH side ^b	42 (56%)	39 (60%)	0.63
ICH location			
Deep	54 (69%)	44 (66%)	
Lobar	21 (27%)	21 (31%)	
Infratentorial	3 (4%)	2 (3%)	
Associated intraventricular hemorrhage	14 (18%)	26 (39%)	<0.01
Microbleeds	25 (32%)	34 (51%)	0.02
ICH volume	9 (5–19)	23 (13–40)	<0.01
Spot sign	38 (49%)	52 (78%)	<0.01

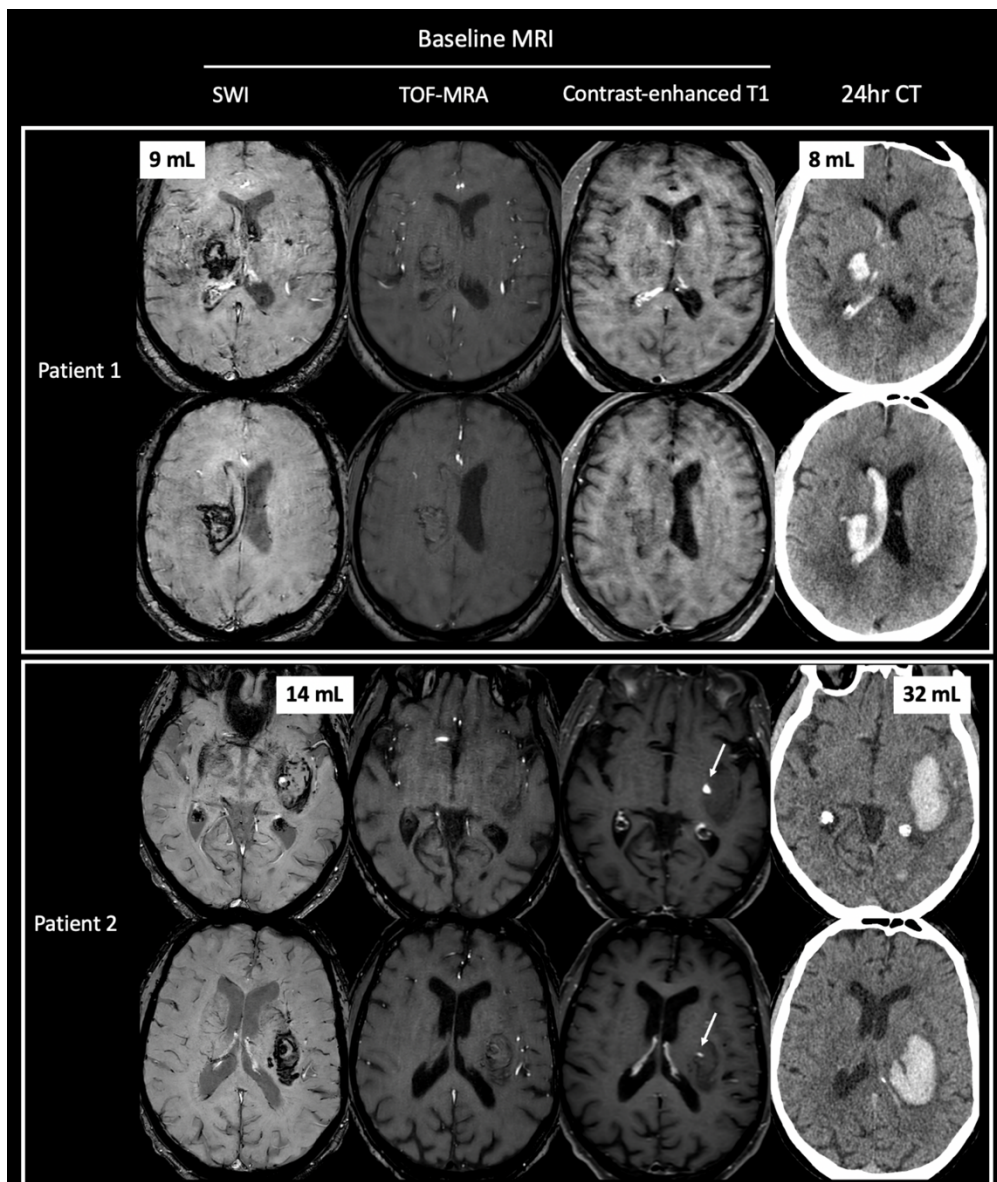
Categorical variables are expressed as numbers (%) and continuous variables as median (IQR) or mean (SD).

ICH indicates intracerebral hemorrhage, and NIHSS, National Institute of Health Stroke Scale.

a: first blood pressure measured after arrival, in the imaging room.

b: for supra-tentorial ICH only.

Figure 1. Illustrative Cases With and Without the MRI Spot Sign

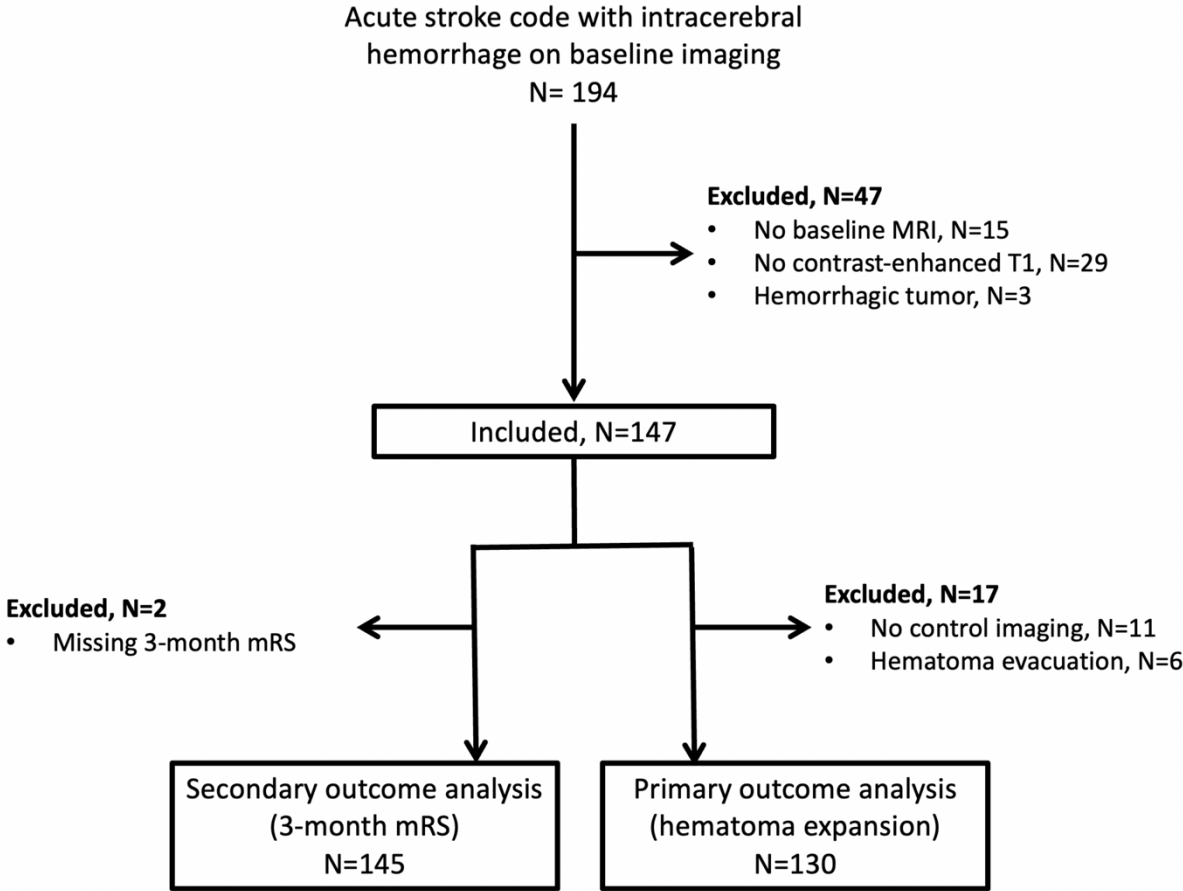


Patient 1: Baseline MRI, performed 150 min following onset of a left hemiplegia in a 60-year-old woman (NIHSS 12), showing a deep left ICH on susceptibility-weighted imaging (9 mL) associated with intraventricular hemorrhage. No spot sign was found on contrast-enhanced T1-weighted sequence. ICH volume was stable on 24 h follow-up CT (8 mL). Three-month mRS score was 2.

Patient 2: Baseline MRI, performed 101 min following onset of a right hemiplegia in a 76-year-old man (NIHSS 16), showing a deep left ICH on susceptibility-weighted imaging (14 mL). Two spots were found on contrast-enhanced T1-weighted sequence, with no corresponding hyperintensities on the nonenhanced T1-weighted TOF-MRA. Hematoma expansion occurred on 24 h follow-up CT (24 h volume, 32 mL). Three-month mRS score was 6.

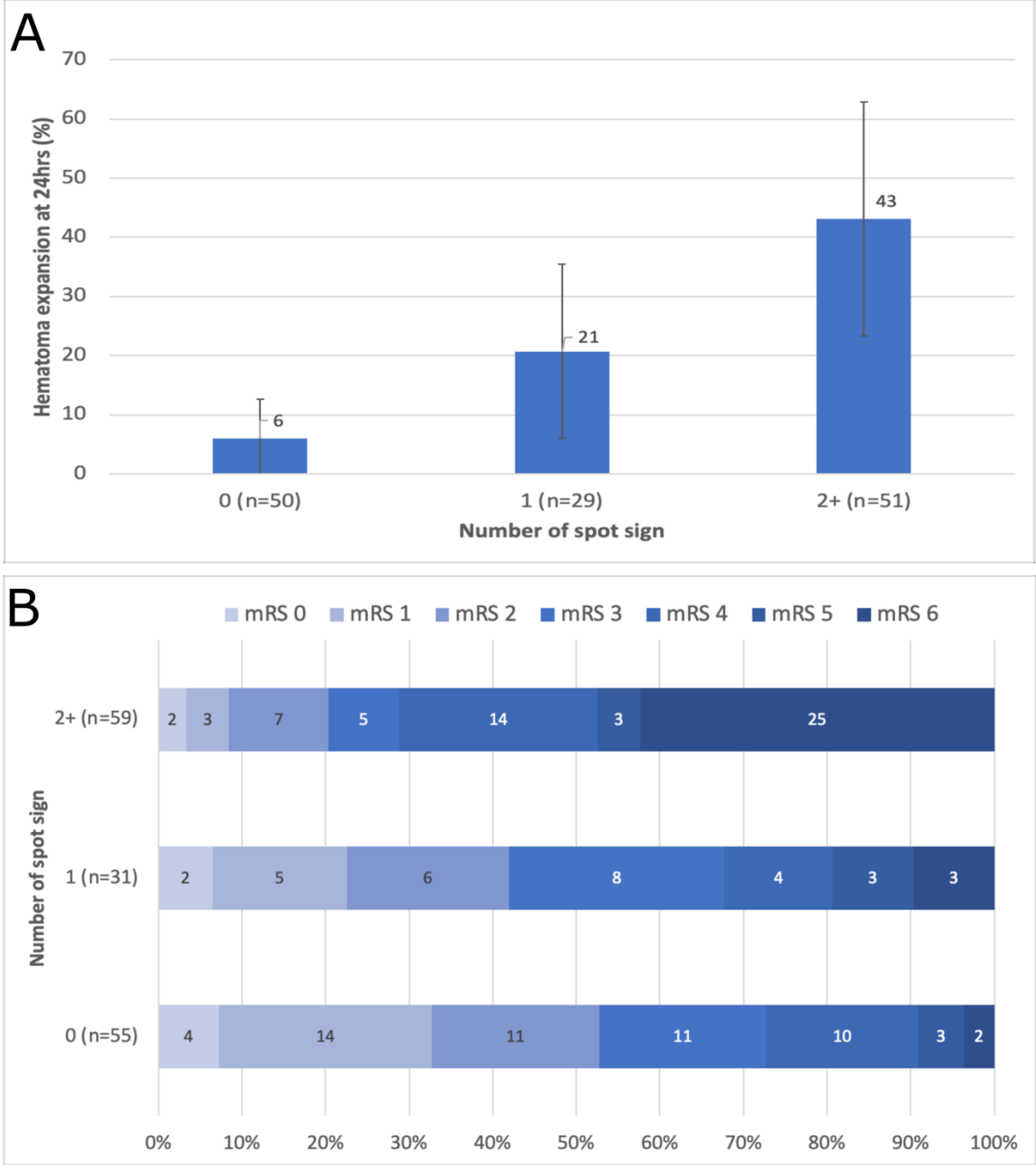
CT indicates computed tomography; ICH, intracerebral hemorrhage; MRI, magnetic resonance imaging; mRS, modified Rankin scale; NIHSS, National Institute of Health Stroke Scale; and TOF-MRA, time-of-flight magnetic resonance angiography.

Figure 2. Study Flow Chart



MRI indicates magnetic resonance imaging; and mRS, modified Rankin scale score.

Figure 3. Hematoma Expansion and 3-month Modified Rankin Scale Score and According to Number of Spots



Panel A represents the prevalence of hematoma expansion according to the number of spots. Error bars indicate 95% confidence intervals.

Panel B represents 3-month modified Rankin scale score according to the number of spots. mRS indicates modified Rankin scale.