



**HAL**  
open science

## **Clinical and technical challenges of cancer reirradiation: Words of wisdom**

Arnaud Beddok, Valentin Calugaru, Ludovic de Marzi, Pierre Graff, Jean-Luc Dumas, Farid Goudjil, Rémi Dendale, Mathieu Minsat, Pierre Verrelle, Irène Buvat, et al.

### ► **To cite this version:**

Arnaud Beddok, Valentin Calugaru, Ludovic de Marzi, Pierre Graff, Jean-Luc Dumas, et al.. Clinical and technical challenges of cancer reirradiation: Words of wisdom. *Critical Reviews in Oncology/Hematology*, 2022, 174, pp.103655. 10.1016/j.critrevonc.2022.103655 . inserm-03873571

**HAL Id: inserm-03873571**

**<https://inserm.hal.science/inserm-03873571v1>**

Submitted on 26 Nov 2022

**HAL** is a multi-disciplinary open access archive for the deposit and dissemination of scientific research documents, whether they are published or not. The documents may come from teaching and research institutions in France or abroad, or from public or private research centers.

L'archive ouverte pluridisciplinaire **HAL**, est destinée au dépôt et à la diffusion de documents scientifiques de niveau recherche, publiés ou non, émanant des établissements d'enseignement et de recherche français ou étrangers, des laboratoires publics ou privés.

**Clinical and technical challenges of cancer reirradiation: Words of wisdom**

*Short running title: Challenges in reirradiation*

Arnaud Beddok<sup>1,2</sup> M.D., M.Sc., Valentin Calugaru<sup>1,3</sup> M.D., Ph.D., Ludovic de Marzi<sup>3</sup> Ph.D., Pierre Graff<sup>1</sup> M.D., Ph.D. Jean-Luc Dumas<sup>1</sup> Ph.D., Farid Goudjil<sup>3</sup> M.Sc., Rémi Dendale<sup>1,3</sup> M.D., Mathieu Minsat M.D.<sup>1</sup>, Pierre Verrelle<sup>1</sup> M.D., Ph.D., Irène Buvat<sup>2</sup> Ph.D., Gilles Créhange<sup>1</sup> M.D., Ph.D.

1. Department of Radiation Oncology. Institut Curie. Paris - Saint Cloud-Orsay. France
2. Laboratoire d'Imagerie Translationnelle en Oncologie (LITO), U1288 Université Paris Saclay/Inserm/Institut Curie. Orsay. France
3. Proton Therapy Center. Institut Curie. Orsay. France
4. Department of Radiation Oncology. Institut Curie. Saint-Cloud. France

**Corresponding author:** Arnaud Beddok: 25 rue d'Ulm, 75005, Paris. France.

arnaud.beddok@curie.fr, [a.beddok@gmail.com](mailto:a.beddok@gmail.com). +33144324504.

**Funding:** None

**Conflict of interests:** None

**Abstract**

Since the development of new radiotherapy techniques that have improved healthy tissue sparing, reirradiation (reRT) has become possible. The selection of patients eligible for reRT is complex given that it can induce severe or even fatal side effects. The first step should therefore be to assess, in the context of multidisciplinary staff meeting, the patient's physical status, the presence of sequelae resulting from the first irradiation and the best treatment option available. ReRT can be performed either curatively or palliatively to treat a cancer-related symptom that is detrimental to the patient's quality of life. The selected techniques for reRT should provide the best protection of healthy tissue. The construction of target volumes and the evaluation of constraints regarding the doses that can be used in this context have not yet been fully codified. These points raised in the literature suggest that randomized studies should be undertaken to answer pending questions.

## Introduction

In the early 2000 s, following a meeting on reirradiation (reRT), the British Journal of Radiology published a commentary encouraging radiation oncologists to provide international guidelines for the management of patients likely to undergo reRT (Jones and Blake, 1999). Special workflow processes, such as the reRT special medical physics consult (ReRT-SMPC) process, have recently been introduced in an attempt to standardize the management of these patients (Paradis et al., 2019). However, to our knowledge, there are still no specific guidelines for reRT management, despite the fact that many cohorts of patients have undergone reirradiation at various cancer sites (Supplementary data 1) (Wells et al., 2000, Myrehaug et al., 2017, Nieder et al., 2006, Kawashiro et al., 2016, Loi et al., 2020, Straube et al., 2016, Kazmi et al., 2019, Montagne et al., 2020, Boimel et al., 2017, McDuff et al., 2018, Berman et al., 2014, Fernandes et al., 2016, Wild et al., 2013, Owens, 2018, Haque et al., 2009, Svajdova et al, Rulach et al., 2018, Nicosia et al., 2020, Tsang and Laperriere, 2019, Baty et al., 2019, Sadozye, 2018, Straube et al., 2019). Yet, the vast majority of these studies did not include data from simultaneous control groups with primary irradiation at the same site. Given the risk of life-threatening complications after reRT (or at least those that significantly affect the quality of life), patients with locoregional recurrences are more generally treated with surgery or systemic treatments alone, either chemotherapy or, increasingly, immunotherapy. However, the risk of second recurrence and toxicity after these treatments remains high, especially for head and neck cancers (Shetty et al., 2021), and re-irradiation in this context could be a useful additional therapeutic modality. This study aimed to review the literature to identify the clinical and technical challenges of reRT, to propose criteria for patient selection, technical choice and target volume delineation, and organ-at-risk constraint definition.

## Clinical challenges

**Patient selection: Risk/benefit balance**

The indication for reRT must weigh the expected efficacy of this salvage treatment against the risk of acute or late toxicity that could be fatal or impair quality of life, keeping in mind the adage "primum non nocere". The outcomes and toxicities experienced by patients reirradiated for curative purposes differ enormously depending on the cancer site reirradiated (Table 1). In pelvic cancer, severe toxicities of reRT can include fistula, bowel obstruction, abscess, general tissue necrosis, gastrointestinal bleeding, urinary strictures, skin ulcers, and pain (Kamran et al., 2020). Retrospective studies on rectal cancer indicated that toxicity was notable, with 13 out of 50 (26%) patients experiencing grade 3 or 4 late toxicities. In lung cancer, severe pulmonary toxicity was observed in up to 21% of patients. This was usually radiation pneumonitis requiring oxygen or even respiratory support (De Ruyscher et al., 2014). In locally recurrent gliomas, reRT may lead to a higher incidence and greater severity of adverse events, such as necrosis, cognitive disturbance and secondary malignancies, especially in the youngest patients. In a recent study, Liu et al. have prospectively compared endoscopic surgery and reRT for the treatment of resectable locally recurrent nasopharyngeal carcinoma. Twenty of the 101 patients who underwent reRT died due to late toxic effects specific to radiotherapy (Liu et al., 2021). Moreover, Tanvetyanon et al. studied the prognostic factors for survival after salvage reRT in 109 patients with HNC (Tanvetyanon et al., 2009). They highlighted the profound negative effect of co-morbidity and organ dysfunction on survival. In this series, acute and late toxicities of grade 3 or higher occurred in 45 patients (43.7%) and 49 patients (47.5%), respectively. Nonetheless, toxicities observed after reirradiation are not necessarily greater than those observed after a first irradiation. For example, Arthur et al. showed that reirradiation of patients with recurrent breast cancer did not result in a very high rate of radiation-induced fibrosis (Arthur et al., 2020). Moreover, salvage surgery can sometimes induce more complications than reRT. For prostate carcinoma, a recent meta-analysis of 150 studies showed that reRT with high-dose-rate (HDR) brachytherapy, low-dose-rate (LDR) brachytherapy, or stereotactic body RT (SBRT) resulted in significantly lower rates of severe genitourinary toxicity than did salvage radical

prostatectomy, and rates of severe gastrointestinal toxicity were significantly lower following HDR brachytherapy than following surgery (Valle et al., 2020). In addition, postoperative complications are more frequent and more severe when surgery is performed in a previously irradiated field (Locatello et al., 2021).

Therefore, all patients being considered for curative reirradiation (reRT) must be evaluated by a multidisciplinary team, including at least surgical oncologists, medical oncologists, radiation oncologists, pathologists, and radiologists specializing in oncology. If the patient has no surgical history, regardless of the time between initial irradiation and recurrence, salvage surgery should always be the first salvage option to be discussed in the light of the likelihood of harmful sequelae (Goodwin, 2000). If the histological and immunohistochemical analyses of the surgical specimen show unfavorable characteristics, such as incomplete resection, peritumoral vascular emboli, and lymph node invasion with capsular rupture, postoperative reRT and/or systemic therapy, including immunotherapy (Plavc et al., 2020), should be considered, especially for head and neck cancers (HNC) (Foster et al., 2020). For brain tumors, a neurosurgical evaluation is always essential, as surgery may increase survival (Azoulay et al., 2017). Surgery would also allow a histological evaluation for progressing glioblastoma. Systemic treatment must be included in the salvage treatment to enhance the effect of the RT or to take into account a possible although yet undetected metastatic recurrence. However, caution should again guide the choice of treatment. A recent study showed that unexpected lethal lung events may occur in patients receiving systemic therapy following thoracic re-irradiation (Yang et al., 2020).

Time is a significant factor in reRT. Cancer-related life expectancy may be longer without reRT, which carries the risk of irreversible sequelae such as respiratory insufficiency, myelitis, necrosis or fistula, even though, in the short term, reRT may alleviate symptoms and impede local tumor progression. The likelihood of a high-risk of radiation-related cancers should be discussed only in patients with long life-expectancy even after local relapse.

Concerning the interval between RT courses, there is no proven correlation with reRT toxicities (see below). Some data suggested that reRT to the prostate area within 4.5 years of prior RT

could be associated with a higher risk of grade 4 toxicity (Nguyen et al., 2007). Conversely, if the progression-free interval is shortened, the reRT should be maximally aggressive (McAvoy et al., 2014). Early local recurrence may be a sign of underdosing during the first irradiation, for example, after prostate brachytherapy (Crehange et al., 2013), or a sign of radioresistance. In the latter case, the reRT could allow to consecutively increase the dose at the target volume and therefore potentially improve the local control. In this perspective, for external beam RT, it could be useful to use other particles than those used in the first irradiation, such as proton versus photon, or to choose another dose rate (see below the section "techniques for reRT").

The selection of patients eligible for reRT therefore remains challenging (Shi et al., 2018). The assessment by the clinician in charge of reRT and the multidisciplinary approach are essential before clear guidelines can be drawn up from randomized trials.

Several authors have proposed nomograms and algorithms to help radiation oncologists choose the best option for patients with local recurrence after a first irradiation, particularly in HNC (Tanvetyanon et al., 2009; Strojjan et al., 2015; Boustani et al., 2020). The main prognostic factors included in these nomograms were: comorbidity, organ dysfunction, isolated neck recurrence, location of the recurrence, tumor bulk before reRT, dose of reRT and time since the first irradiation. More recently and more generally, Do'rr et al. suggested that a decision on reRT should systematically take into account: (Jones and Blake, 1999) the location of the recurrence (or second tumor) in relation to the primary tumor, (Paradis et al., 2019) the dosimetric parameters of the initial radiation therapy (RT), (Wells et al., 2000) the use of concomitant treatment, such as surgery, chemotherapy and targeted therapy for the first tumor and for recurrence, and (Myrehaug et al., 2017) the time since treatment of the first tumor (Do'rr and Gabry's, 2018). Machine learning-based models for predicting and classifying RT-induced complications, or for rapid dose predictions, are also evolving and could play an important role in the management of reRT (Isaksson et al., 2020).

### **Techniques for reirradiation**

Historically, reRT was limited to simple techniques, such as three-dimensional conformal radiation therapy (3D-CRT), and palliative doses. These led to a limited improvement in long-term survival, for instance, in locally recurrent non-small cell lung carcinoma (NSCLC) (Green and Melbye, 1982). Technological innovations over the past 20 years have made high-dose re-irradiation a possible treatment option. Indeed, as previously mentioned, healthy tissues are far better protected, especially in reRT. The technique used should limit as much as possible doses to organs-at-risk (OAR). Table 1 summarizes the main results of recent high-level prospective studies using different reRT techniques at different sites.

#### *Intensity-modulated radiation therapy (IMRT)*

IMRT with IGRT was the first step in improving OAR sparing (Chen et al., 2011). Nevertheless, the incidence of severe late toxicity remains high with IMRT in reRT. Takiar et al. retrospectively studied outcomes and toxicities in 201 patients reirradiated for HNC, and reported 2-year and 5-year grade 3 toxicity in 32% and 48% of the patients, respectively (Takiar et al., 2016). Similarly, in rectal carcinoma, Tao et al. recently evaluated outcomes and toxicity in 101 patients treated with hyper-fractionated pelvic reRT with IMRT. They found 34% of grade 3–4 late toxicity at 3 years (Tao et al., 2017).

#### *Proton therapy*

PT, as compared with photon therapy, has the potential to optimize locoregional control while significantly reducing toxicity. The physical properties of protons allow energy to be deposited at a specific depth, called a Bragg peak, with a rapid drop in energy beyond this point (Beddok et al., 2020). These physical properties of protons are particularly important in reRT, because they allow definitive, rather than palliative doses of reRT (Verma et al., 2017). Retrospective (McAvoy et al., 2014) and prospective (Chao et al., 2017) data have also emerged showing an advantage of protons in reRT, with some severe toxicities but at a fairly low incidence. For instance, Chao et al. reported the results of 57 patients treated at three



proton centers for recurrent NSCLC in or near their prior radiation field. Overall, grade 3 or higher acute and/or late toxicity developed in 24 (42%) patients, acute toxicity developed in 22 (39%) patients, and late toxicity developed in seven (12%) patients (Chao et al., 2017). PT can also be an optimal choice for the treatment of HNC, and particularly nasopharyngeal and sinonasal cancer, as intensity-modulated proton therapy (IMPT) has proved to be superior to intensity-modulated radiation therapy (IMRT) from a biological and physical standpoint. PT also shows improved sparing (especially in terms of the integral dose) of critical healthy structures at the skull base (which are numerous, e.g., optic nerves, optic chiasm, pituitary gland, brainstem, temporal lobes, cochlea, cranial nerves, pterygoid muscles...) (Blanchard et al., 2018). Such sparing is particularly important in the reRT setting (Phan et al., 2016). PT can be useful for rectal cancer recurrence, particularly in the case of inoperable isolated local recurrence in the presacral region, to better spare the bowel and bladder without having to sacrifice the hip joints and pelvic bones (Simone et al., 2020). PT can help reduce acute and late toxicities in reRT for gastrointestinal malignancies (Verma et al., 2016), and can be very useful in reRT for esophageal (DeCesaris et al., 2020), pancreatic (Boimel et al., 2017), anal, and rectal recurrences (Moningi et al., 2019).

#### *Stereotactic body radiation therapy (SBRT)*

SBRT makes use of extreme hypofractionation, up to a session of 20 Gy in the brain, and allows a very steep dose gradient—by definition. It delivers at least 50% of the prescribed dose 2 cm around the target volume (Benedict et al., 2010). It is therefore a technique of choice for reRT, especially for the brain (Sanders et al., 2019; Møller et al., 2017), lung (Milano et al., 2018), prostate (Jereczek-Fossa et al., 2021), spinal metastases (Myrehaug et al., 2017; Garg et al., 2011), head and neck cancer (Vargo et al., 2015) and pancreatic carcinomas (Wild et al., 2013). This technique again poses the problem of the risk/benefit ratio: a biologically higher dose per fraction is disadvantageous when considering OAR, especially in patients with a greater potential for late lethal complications. However, if the primary tumor

has already demonstrated resilience to the initial course of RT, SBRT allows biological doses much higher than IMRT.

### *Brachytherapy*

Brachytherapy allows the desired dose to be very precisely delivered to the chosen location, because it involves putting a radioactive element in contact with the target. This technique therefore appears very useful in the setting of reRT, particularly in prostate cancer reRT, as a very high biological dose can be delivered to the area where the recurrence is located (Murgic et al., 2018; Crook et al., 2019). Brachytherapy is particularly useful in the management of local recurrence of breast cancer. A second breast conserving treatment could be possible if surgery is followed by re-irradiation using multi-catheter pulse dose rate (PDR) BT. The reported toxicities were mild (Montagne et al., 2020; Kauer-Dorner et al., 2012). It should be noted that in case of salvage BT after a first BT, it would be useful to use a different source or dose rate from those used the first time.

## **Technical challenges**

### ***Target volume definition***

No consensus has been reached regarding the target volume definition in the context of reRT. Target volume definition thus varies considerably and depends on the target organ irradiated and the center in which the patient is treated. To limit the risk of radiation-induced toxicity, the target volume should nevertheless be as small as possible. This is particularly true if the target is adjacent to OAR, with a risk of life-threatening acute toxicity in patients with a short life expectancy, or late sequelae in other patients whose quality of life may be irreversibly impaired. Therefore, contrary to the usual approach for a first irradiation, in reRT, the target volume is often limited to the macroscopically visible part of the tumor (the so-called gross tumor volume [GTV]). Delineation of this GTV for local recurrence after prior RT can be particularly challenging, considering the often-significant degree of radiofibrosis in

this zone. Multimodal imaging, especially dual energy CT (Ng et al., 2020), MRI and PET/CT, can significantly improve target delineation and should be used in this case to help define the GTV (Fig. 1). For instance, in their prospective study in glioma, Miwa et al. planned the reRT using  $^{11}\text{C}$ -methionine positron emission tomography (MET-PET)/computed tomography (CT)/magnetic resonance imaging (MRI) fusion. The region of increased amino acid tracer uptake on MET-PET was defined as the GTV (Miwa et al., 2014). In the near future, radiomics for reRT will certainly also help to delineate the GTV (Akram et al., 2020). In addition, the GTV should not include doubtful structures of suspected malignancy. This is even more true than in the case of a first irradiation, and confirmation by cytological sampling or biopsy should not be delayed. For instance, in NSCLC, the patient could be referred to interventional pneumology for endobronchial ultrasound to resample the mediastinal and hilar lymph nodes, after which only those lymph nodes that have been found to be pathologically implicated should be included in the GTV. In this context, it is also suggested to work closely with the surgeon to define the GTV. In addition, the margin that takes into account microscopic invasion (clinical target volume [CTV]) should be very small, as described by Popovtzer et al. in HNC (Popovtzer et al., 2009). Similarly, modern IGRT techniques, such as daily CBCT or even better, MR-LINAC (Doty et al., 2021), can be used to reduce as much as possible the margin that usually takes into account set-up uncertainties (the provisional target volume [PTV]) (Intven et al., 2020).

### ***Organ-at-risk sparing***

Currently, there are no international recommendations regarding dose constraints to organs at risk (OAR) in reRT. However, it can be expected that reRT to an OAR that has already received a high or low dose in the first irradiation can induce high-grade toxicities. The radiation-induced toxicities of OAR with serial functional subunits (FSU) (i.e.: such as arteries, spinal cord, gastrointestinal tract etc....) are potentially very different from those in parallel FSU (liver, kidneys, lung etc. ...).

### *OAR organized in serial FSU*

Very high cumulative doses could be catastrophic in OAR organized in serial FSU (Crane, 2020) (Table 2). McDonald et al. reported 41 cases of carotid blowout (CB) among 1554 (2.6%) patients receiving salvage reRT for HNC, of which 76% were fatal (McDonald et al., 2012). No significant difference was observed between patients with or without salvage surgery prior to reRT or between those with or without concurrent chemotherapy during reRT. Carotid blowout is also frequent in patients reirradiated with SBRT for relapsed HNC (Yamazaki et al., 2016). The risk of carotid rupture is higher if the tumor has invaded the vessel, if there is ulceration, or if the patient has had neck lymph node dissection (Yamazaki et al., 2013). As yet, there is no consensus on dose constraints for large vessels (e.g. carotid and aorta) in this specific context of reRT. Nevertheless, a cumulative dose greater than 120 Gy is related to a significant increase in the risk of vessel blowout (Evans et al., 2013; Dionisi et al., 2019; Alterio et al., 2020). The time between the first RT and reRT (30 months [1– 185]) was not associated with the risk of serious toxicity induced by reRT.

One of the main issues in reRT, especially when the local recurrence is close to the spinal cord, is the risk of radiation myelitis. An extensive study of spinal reRT in rhesus monkeys showed that the risk of radiation myelopathy decreased over time, suggesting a forgetting factor at least for this organ, and nervous tissue in general (Ang et al., 2001). However, caution should be exercised in the transfer of these experimental data to humans, as the duration of follow-up in these experiments was limited to 2–2.5 years after reRT, whereas cases of human myelopathy sometimes occur after a longer latency. Increasing time between the initial irradiation and reRT is probably an important factor, although there is currently no consensus on a “time–dose factor” (Nieder et al., 2006). Moreover, the kinetics of brachial plexus recovery seems to be similar to that of the spinal cord. In retrospective studies, the one-year freedom from brachial plexus-related neuropathy rates were 67% and 86% for patients who were treated with a maximum cumulative dose greater than and less than 95.0 Gy, respectively. The one-year complication-free rates were 66% and 87% for patients re-irradiated within two years of initial treatment, respectively (Chen et al., 2017).

A high cumulative dose could also induce many gastrointestinal tract complications including perforation, fistula, stricture, and adhesions, particularly when the reRT is administered near luminal structures, given the low recovery of bowel after multiple courses of RT. For the esophagus, previous dose escalation studies and limited reRT data suggest that the fistula threshold occurs at approximately 85–90 Gy of cumulative equivalent dose (EQD2) (Meijneke et al., 2013).

#### *OAR organized in parallel FSU*

Although potentially less affected by a new irradiation than organs arranged in serial FSU, organs arranged in parallel FSU must also be spared during this second phase, in particular, to avoid organ insufficiencies. While De Ruyschser et al. did not provide lung dose constraints, the combined cumulative lung V20 < 40% should be limited, as recommended, to reduce the risk of grade 3 or higher toxicity (Fischer-Valuck et al., 2020).

Moreover, there are few data on the tolerance of the liver to repeated doses of radiation. Massachusetts General Hospital reported their results for 49 patients who were re-irradiated for liver lesion. Reirradiation appeared to be feasible, with only 4.1% of patients experiencing radiation-induced liver toxicity. They proposed to limit the volume of unirradiated liver to at least 800 cc under 15 Gy, a constraint similar to that used in primary liver radiotherapy (McDuff et al., 2018). As for large vessels, the time between the first RT and reRT (9 months (Straube et al., 2016; Kazmi et al., 2019; Montagne et al., 2020; Boimel et al., 2017; McDuff et al., 2018; Berman et al., 2014; Fernandes et al., 2016; Wild et al., 2013)) was not associated with the risk of serious RT-induced toxicity. A protocol using indocyanine green would make it possible to assess baseline liver function to determine dose prescription (Suresh et al., 2018). In this case, liver dose constraints can follow the model that titrates the mean liver dose (MLD) to indocyanine green, adjusted for the risk of decompensation. For patients off trial, constraints could be V19Gy < 700 cc and MLD < 15 Gy (Benedict et al., 2010). For reRT cases, the same constraints can be used for a plan sum, considering the prior liver dose but with a 50% discount, assuming repair in the interval between treatment courses (Owen et al., 2020).

Functional imaging of normal tissues might be an elegant approach to optimizing the beam arrangement in reRT (De Bari et al., 2016).

Finally, no internationally defined guidelines are available for organ dose limits in reRT.

Nevertheless, the American Radium Society and American College of Radiology recently proposed composite dose constraints in 2 Gy equivalent doses: esophagus,  $V_{60} < 40\%$  and  $DMax < 100\text{--}110$  Gy; lung,  $V_{20} < 40\%$ ; heart,  $V_{40} < 50\%$ ; aorta/great vessels,  $DMax < 120$  Gy; trachea and proximal bronchial tree,  $DMax < 110$  Gy; spinal cord,  $DMax < 57$  Gy; and brachial plexus,  $DMax < 85$  Gy (Simone et al., 2020). We summarized in Table 2 the main OAR constraints proposed in the different published studies.

### ***Dose and fractionation***

In view of what has been presented in the previous sections, one of the most important aspects of the initial evaluation of the patient for whom reRT is being considered would be to determine the dose that could be safely administered on the basis of the first irradiation. This requires an assessment of normal tissue tolerance doses for OARs, as well as of the potential consequences of late complications that may arise. This should be the basis for a fractionation choice to obtain an optimal bioequivalent dose. For instance, in brain tumor recurrences, no standard of care fractionation scheme exists, but some possibilities for reRT could be 7.7–20 Gy in one fraction (SBRT), or a hypofractionated regimen with doses ranging from 18 Gy to 37.5 Gy in 3–15 fractions (Shanker et al., 2019). Fractionation must be considered with regard to the risk of cerebral radionecrosis. Individual radiosensitivity should also be considered in the decision to treat using reRT. Indeed, except for certain known syndromes that induce very high radiosensitivity and a high risk of serious radiation-induced toxicities (so called "over reactors") (Bentzen, 1997), such as Fanconi's anemia syndrome (Beddok et al., 2020), each patient treated with radiation has individual radiosensitivity. Several tests exist and could be useful to determine radiosensitivity before reRT. However, none of them are currently accepted as a reference test (Ferlazzo et al., 2017). A history of severe acute or late radiation-induced toxicities during a first irradiation remains, for the

moment, the best objective endpoint in the decision to reirradiate, and in the choice of the dose and the fractionation of reRT (Cosset et al., 2019). Conversely, it should also be kept in mind that an early or late recurrence in the irradiated field results in radioresistance of the tumor (on the somatic level) and/or the patient (on the constitutional level). The dose used for curative reRT should therefore be at least as high (in biological equivalent if the particle or fractionation is changed) as the dose used for the first irradiation. For example, in HNC, the dose used in the first reRT protocols was 60 Gy (lower than the dose prescribed for the first exclusive irradiation) (De Crevoisier et al., 2001). Recent studies have shown that increasing the dose beyond 66 Gy improved outcomes (Caudell et al., 2018).

## Conclusion

In conclusion, innovative techniques such as PT, SBRT or HDR- brachytherapy, which allow better OAR sparing than do more conventional techniques, are placing reRT back in the forefront. The selection of patients remains the critical point. The patient's general condition (WHO performance status) and the sequelae of the previous irradiation should always be taken into account. Decision-making on reRT based solely on dosimetric criteria is not an option, and a consultation with a radiation oncologist and a multidisciplinary approach should always be planned as soon as this therapeutic option is considered. Recommendations on target volume delineation and OAR dose constraints also remain unclear, and the use of IGRT and other techniques allowing PTV margin reduction should always be considered. This work emphasizes the urgent need for randomized clinical trials in this setting (Case Comprehensive Cancer Center, 2020).

## References

Akram, F., Koh, P.E., Wang, F., et al., 2020. Exploring MRI based radiomics analysis of intratumoral spatial heterogeneity in locally advanced nasopharyngeal carcinoma treated with intensity modulated radiotherapy. *PLoS One* 15.

Alterio, D., Turturici, I., Volpe, S., Ferrari, A., Russell-Edu, S.W., Vischioni, B., Mardighian, D., Preda, L., Gandini, S., Marvaso, G., Augugliaro, M., Durante, S., Arculeo, S., Patti, F., Boccuzzi,

- D., Casbarra, A., Starzynska, A., Santoni, R., Jereczek-Fossa, B.A., 2020. Carotid blowout syndrome after reirradiation for head and neck malignancies: a comprehensive systematic review for a pragmatic multidisciplinary approach. *Crit. Rev. Oncol. Hematol.* 155, 103088.
- Ang, K.K., Jiang, G.L., Feng, Y., Stephens, L.C., Tucker, S.L., Price, R.E., 2001. Extent and kinetics of recovery of occult spinal cord injury. *Int. J. Radiat. Oncol. Biol. Phys.* 50, 1013–1020.
- Arthur, D.W., Winter, K.A., Kuerer, H.M., Haffty, B., Cuttino, L., Todor, D.A., Anne, P.R., Anderson, P., Woodward, W.A., McCormick, B., Cheston, S., Sahijdak, W.M., Canaday, D., Brown, D.R., Currey, A., Fisher, C.M., Jagsi, R., Moughan, J., White, J. R., 2020. Effectiveness of breast-conserving surgery and 3-dimensional conformal partial breast reirradiation for recurrence of breast cancer in the ipsilateral breast. *JAMA Oncol.* 6, 75–82.
- Azoulay, M., Santos, F., Shenouda, G., Petrecca, K., Oweida, A., Guiot, M.C., Owen, S., Panet-Raymond, V., Souhami, L., Abdulkarim, B.S., 2017. Benefit of re-operation and salvage therapies for recurrent glioblastoma multiforme: results from a single institution. *J. Neurooncol.* 132, 419–426.
- Baty, M., Créhanche, G., Pasquier, D., Palard, X., Deleuze, A., Gnep, K., Key, S., Beuzit, L., Castelli, J., de Crevoisier, R., 2019. Salvage reirradiation for local prostate cancer recurrence after radiation therapy. For who? When? How? *Cancer Radiother.* 23, 541–558.
- Beddok, A., Vela, A., Calugaru, V., Tessonier, T., Kubes, J., Dutheil, P., Gerard, A., Vidal, M., Goudjil, F., Florescu, C., Kammerer, E., Benezery, K., Herault, J., Poortmans, P., Bourhis, J., Thariat, J., 2020. Proton therapy for head and neck squamous cell carcinomas: a review of the physical and clinical challenges. *Radiother. Oncol.* 147, 30–39.
- Beddok, A., Krieger, S., Castera, L., Stoppa-Lyonnet, D., Thariat, J., 2020. Management of fanconi anemia patients with head and neck carcinoma: diagnosis and treatment adaptation. *Oral Oncol* 108, 104816.
- Benedict, S.H., Yenice, K.M., Followill, D., Galvin, J.M., Hinson, W., Kavanagh, B., Keall, P., Lovelock, M., Meeks, S., Papiez, L., Purdie, T., Sadagopan, R., Schell, M.C., Salter, B., Schlesinger, D.J., Shiu, A.S., Solberg, T., Song, D.Y., Stieber, V., Timmerman, R., Tomé, W.A., Verellen, D., Wang, L., Yin, F.F., 2010. Stereotactic body radiation therapy: the report of AAPM Task Group 101. *Med. Phys.* 37, 4078–4101.
- Bentzen, S.M., 1997. Potential clinical impact of normal-tissue intrinsic radiosensitivity testing. *Radiother. Oncol.* 43, 121–131.
- Berman, A.T., Both, S., Sharkoski, T., Goldrath, K., Tochner, Z., Apisarnthanarax, S., Metz, J.M., Plastaras, J.P., 2014. Proton reirradiation of recurrent rectal cancer: dosimetric comparison, toxicities, and preliminary outcomes. *Int. J. Part. Ther.* 1, 2–13.
- Blanchard, P., Gunn, G.B., Lin, A., Foote, R.L., Lee, N.Y., Frank, S.J., 2018. Proton therapy for head and neck cancers. *Semin. Radiat. Oncol.* 28, 53–63.
- Boimel, P.J., Berman, A.T., Li, J., Apisarnthanarax, S., Both, S., Lelionis, K., Larson, G.L., Teitelbaum, U., Lukens, J.N., Ben-Josef, E., Metz, J.M., Plastaras, J.P., 2017. Proton beam reirradiation for locally recurrent pancreatic adenocarcinoma. *J. Gastrointest. Oncol.* 8, 665–674.
- Boustani J., Ruffier A., Moya-Plana A., et al. 2020. Long-term outcomes and safety after reirradiation in locally recurrent nasopharyngeal carcinoma in a non-endemic area. *Strahlenther. Onkol. Organ Dtsch. Rontgengesellschaft AI.* 2020.



Case Comprehensive Cancer Center. 2020. *Partial Breast Re-Irradiation for Patients With Ipsilateral Breast Tumor Recurrence, After First Being Treated With Breast Conservation for Early Stage Breast Cancer: An Efficacy Trial Comparing Mammosite® and Intraoperative Radiation*. clinicaltrials.gov; 2020.

Caudell, J.J., Ward, M.C., Riaz, N., Zakem, S.J., Awan, M.J., Dunlap, N.E., Isrow, D., Hassanzadeh, C., Vargo, J.A., Heron, D.E., Marcrom, S., Boggs, D.H., Reddy, C.A., Dault, J., Bonner, J.A., Higgins, K.A., Beitler, J.J., Koyfman, S.A., Machtay, M., Yao, M., Trotti, A.M., Siddiqui, F., Lee, N.Y., Multi-Institution Reirradiation (MIRI), C., 2018. Volume, dose, and fractionation considerations for IMRT-based reirradiation in head and neck cancer: a multi-institution analysis. *Int. J. Radiat. Oncol.* 100, 606–617.

Chao, H.-H., Berman, A.T., Simone, C.B., Ciunci, C., Gabriel, P., Lin, H., Both, S., Langer, C., Lelionis, K., Rengan, R., Hahn, S.M., Prabhu, K., Fagundes, M., Hartsell, W., Mick, R., Plastaras, J.P., 2017. Multi-institutional prospective study of reirradiation with proton beam radiotherapy for locoregionally recurrent non-small cell lung cancer. *J. Thorac. Oncol. Off. Publ. Int. Assoc. Study Lung Cancer* 12, 281–292.

Chen, A.M., Farwell, D.G., Luu, Q., Cheng, S., Donald, P.J., Purdy, J.A., 2011. Prospective trial of high-dose reirradiation using daily image guidance with intensity-modulated radiotherapy for recurrent and second primary head-and-neck cancer. *Int. J. Radiat. Oncol.* 80, 669–676.

Chen, A.M., Yoshizaki, T., Velez, M.A., Mikaeilian, A.G., Hsu, S., Cao, M., 2017. Tolerance of the brachial plexus to high-dose reirradiation. *Int. J. Radiat. Oncol. Biol. Phys.* 98, 83–90.

Cosset, J.-M., Chargari, C., Créange, G., 2019. Reirradiations: quels critères décisionnels ? *Cancer Radiother.* 23, 526–530.

Crane, C.H., 2020. Balancing fractionation and advanced technology in consideration of reirradiation. *Semin. Radiat. Oncol.* 30, 201–203.

Crehange, G., Krishnamurthy, D., Cunha, J.A., Pickett, B., Kurhanewicz, J., Hsu, I.C., Gottschalk, A.R., Shinohara, K., Roach, M., Pouliot, J., 2013. Cold spot mapping inferred from MRI at time of failure predicts biopsy-proven local failure after permanent seed brachytherapy in prostate cancer patients: implications for focal salvage brachytherapy. *Radiother. Oncol.* 109, 246–250.

Crook, J.M., Zhang, P., Pisansky, T.M., Trabulsi, E.J., Amin, M.B., Bice, W., Morton, G., Pervez, N., Vigneault, E., Catton, C., Michalski, J., Roach, M., Beyer, D., Jani, A., Horwitz, E., Donavanik, V., Sandler, H., 2019. A prospective phase 2 trial of transperineal ultrasound-guided brachytherapy for locally recurrent prostate cancer after external beam radiation therapy (nrg oncology/RTOG-0526). *Int. J. Radiat. Oncol.* 103, 335–343.

De Bari, B., Deantonio, L., Bourhis, J., Prior, J.O., Ozsahin, M., 2016. Should we include SPECT lung perfusion in radiotherapy treatment plans of thoracic targets? Evidences from the literature. *Crit. Rev. Oncol. Hematol.* 102, 111–117.

De Crevoisier, R., Dometge, C., Wibault, P., Koscielny, S., Lusinchi, A., Janot, F., Bobin, S., Luboinski, B., Eschwege, F., Bourhis, J., 2001. Full dose reirradiation combined with chemotherapy after salvage surgery in head and neck carcinoma. *Cancer.* 91, 2071–2076.

De Ruysscher, D., Faivre-Finn, C., Le Pechoux, C., Peeters, S., Belderbos, J., 2014. High-dose re-irradiation following radical radiotherapy for non-small-cell lung cancer. *Lancet Oncol.* 15, e620–e624.

DeCesaris, C.M., McCarroll, R., Mishra, M.V., Glass, E., Greenwald, B.D., Carr, S., Burrows, W., Mehra, R., Regine, W.F., Simone, C.B., Choi, J.I., Molitoris, J.K., 2020. Assessing outcomes of patients treated with re-irradiation utilizing proton pencil-beam scanning for primary or recurrent malignancies of the esophagus and gastroesophageal junction. *J. Thorac. Oncol.* 15, 1054–1064.

Dionisi, F., Fiorica, F., D'Angelo, E., Maddalo, M., Giacomelli, I., Tornari, E., Rosca, A., Vigo, F., Romanello, D., Cianchetti, M., Tommasino, F., Massaccesi, M., Orlandi, E., 2019. Organs at risk's tolerance and dose limits for head and neck cancer re-irradiation: a literature review. *Oral Oncol.* 98, 35–47.

Do'rr, W., Gabry's, D., 2018. The principles and practice of re-irradiation in clinical oncology: an overview. *Clin. Oncol.* 30, 67–72.

Doty, D.G., Chuong, M.D., Gomez, A.G., Bryant, J., Contreras, J., Romaguera, T., Alvarez, D., Kotecha, R., Mehta, M.P., Gutierrez, A.N., Mittauer, K.E., 2021. Stereotactic MR-guided online adaptive radiotherapy reirradiation (SMART reRT) for locally recurrent pancreatic adenocarcinoma: a case report. *Med. Dosim.* 46, 384–388. S0958394721000479.

Evans, J.D., Gomez, D.R., Amini, A., Rebuena, N., Allen, P.K., Martel, M.K., Rineer, J.M., Ang, K.K., McAvoy, S., Cox, J.D., Komaki, R., Welsh, J.W., 2013. Aortic dose constraints when reirradiating thoracic tumors. *Radiother. Oncol. J. Eur. Soc. Ther. Radiol. Oncol.* 106, 327–332.

Favaudon, V., Caplier, L., Monceau, V., Pouzoulet, F., Sayarath, M., Fouillade, C., Poupon, M.F., Brito, I., Hup'e, P., Bourhis, J., Hall, J., Fontaine, J.J., Vozenin, M.C., 2014. Ultrahigh dose-rate FLASH irradiation increases the differential response between normal and tumor tissue in mice. *Sci. Transl. Med.* 6, 245ra93-245ra93.

Ferlazzo, M.L., Bourguignon, M., Foray, N., 2017. Functional assays for individual radiosensitivity: a critical review. *Semin. Radiat. Oncol.* 27, 310–315.

Fernandes, A., Berman, A.T., Mick, R., Both, S., Lelionis, K., Lukens, J.N., Ben-Josef, E., Metz, J.M., Plastaras, J.P., 2016. A prospective study of proton beam reirradiation for esophageal cancer. *Int. J. Radiat. Oncol. Biol. Phys.* 95, 483–487.

Fischer-Valuck, B.W., Robinson, C.G., Simone, C.B., Gomez, D.R., Bradley, J.D., 2020. Challenges in re-irradiation in the thorax: managing patients with locally recurrent non-small cell lung cancer. *Semin. Radiat. Oncol.* 30, 223–231.

Foster, C.C., Fan, M., Lee, N.Y., Yom, S.S., Heaton, C.M., Deraniyagala, R., Amdur, R., Weichselbaum, R.R., Haraf, D.J., 2020. Is it worth It? Consequences of definitive head and neck reirradiation. *Semin. Radiat. Oncol.* 30, 212–217.

Garg, A.K., Wang, X.-S., Shiu, A.S., Allen, P., Yang, J., McAleer, M.F., Azeem, S., Rhines, L.D., Chang, E.L., 2011. Prospective evaluation of spinal reirradiation by using stereotactic body radiation therapy. *Cancer* 117, 3509–3516.

Goodwin, W.J., 2000. Salvage surgery for patients with recurrent squamous cell carcinoma of the upper aerodigestive tract: when do the ends justify the means? *Laryngoscope* 110, 1–18.

Green, N., Melbye, R.W., 1982. Lung cancer: retreatment of local recurrence after definitive irradiation. *Cancer* 49, 865–868.

Haque, W., Crane, C.H., Krishnan, S., Delclos, M.E., Javle, M., Garrett, C.R., Wolff, R.A., Das, P., 2009. Reirradiation to the abdomen for gastrointestinal malignancies. *Radiat. Oncol.* 4, 55.

Intven, M.P.W., de Mol van Otterloo, S.R., Mook, S., Doornaert, P., de Groot-van Breugel, E.N., Sikkes, G.G., Willemsen-Bosman, M.E., van Zijp, H.M., Tijssen, R., 2020. Online adaptive MR-guided radiotherapy for rectal cancer; feasibility of the workflow on a 1.5T MR-linac: clinical implementation and initial experience. *Radiother. Oncol. J. Eur. Soc. Ther. Radiol. Oncol.* 154, 172–178.

Isaksson, L.J., Pepa, M., Zaffaroni, M., Marvaso, G., Alterio, D., Volpe, S., Corrao, G., Augugliaro, M., Starzyn´ska, A., Leonardi, M.C., Orecchia, R., Jereczek-Fossa, B.A., 2020. Machine learning-based models for prediction of toxicity outcomes in radiotherapy. *Front. Oncol.* 10, 790.

Jereczek-Fossa, B.A., Marvaso, G., Zaffaroni, M., Gugliandolo, S.G., Zerini, D., Corso, F., Gandini, S., Alongi, F., Bossi, A., Cornford, P., De Bari, B., Fonteyne, V., Hoskin, P., Pieters, B.R., Tree, A.C., Arcangeli, S., Fuller, D.B., Franzese, C., Hannoun-Levi, J.M., Janoray, G., Kerkmeijer, L., Kwok, Y., Livi, L., Loi, M., Miralbell, R., Pasquier, D., Pinkawa, M., Scher, N., Scorsetti, M., Shelan, M., Toledano, A., van As, N., Vavassori, A., Zilli, T., Pepa, M., Ost, P., on the behalf of the European Society for Radiotherapy, Oncology Advisory Committee on Radiation Oncology Practice (ESTRO, 2021). Salvage stereotactic body radiotherapy (SBRT) for intraprostatic relapse after prostate cancer radiotherapy: An ESTRO ACROP Delphi consensus. *Cancer Treat. Rev.* 98, 102206.

Jones, B., Blake, P.R., 1999. Retreatment of cancer after radical radiotherapy. *Br. J. Radiol.* 72, 1037–1039.

Kamran, S.C., Zelefsky, M., Nguyen, P.L., Lawton, C., 2020. To radiate or not to radiate- the challenges of Pelvic Reirradiation. *Semin. Radiat. Oncol.* 30, 238–241.

Kauer-Dorner, D., Po'tter, R., Resch, A., Handl-Zeller, L., Kirchheiner, K., Meyer-Schell, K., Do'rr, W., 2012. Partial breast irradiation for locally recurrent breast cancer within a second breast conserving treatment: alternative to mastectomy? results from a prospective trial. *Radiother. Oncol.* 102, 96–101.

Kawashiro, S., Harada, H., Katagiri, H., Asakura, H., Ogawa, H., Onoe, T., Sumita, K., Murayama, S., Murata, H., Nemoto, K., Takahashi, M., Nishimura, T., 2016. Reirradiation of spinal metastases with intensity-modulated radiation therapy: an analysis of 23 patients. *J. Radiat. Res* 57, 150–156.

Kazmi, F., Soon, Y.Y., Leong, Y.H., Koh, W.Y., Vellayappan, B., 2019. Re-irradiation for recurrent glioblastoma (GBM): a systematic review and meta-analysis. *J. Neurooncol.* 142, 79–90.

Liu, Y.-P., Wen, Y.-H., Tang, J., Wei, Y., You, R., Zhu, X.L., Li, J., Chen, L., Ling, L., Zhang, N., Zou, X., Hua, Y.J., Chen, Y.M., Chen, L., Lu, L.X., Chen, M.Y., Wen, W.P., 2021. Endoscopic surgery compared with intensity-modulated radiotherapy in resectable locally recurrent nasopharyngeal carcinoma: a multicentre, open-label, randomised, controlled, phase 3 trial. *Lancet Oncol.* 22, 381–390.

Locatello, L.G., Mastronicola, R., Cortese, S., Beulque, E., Salleron, J., Gallo, O., Dolivet, G., 2021. Estimating the risks and benefits before salvage surgery for recurrent head and neck squamous cell carcinoma. *Eur. J. Surg. Oncol.* 47, 1718–1726. S0748798321000524.

Loi, M., Caini, S., Scoccianti, S., Bonomo, P., De Vries, K., Francolini, G., Simontacchi, G., Greto, D., Desideri, I., Meattini, I., Nuyttens, J., Livi, L., 2020. Stereotactic reirradiation for local failure of brain metastases following previous radiosurgery: Systematic review and meta-analysis. *Crit. Rev. Oncol. Hematol.* 153, 103043.

Mazal, A., Prezado, Y., Ares, C., de Marzi, L., Patriarca, A., Miralbell, R., Favaudon, V., 2020. FLASH and minibeam radiation therapy: the effect of microstructures on time and space and their potential application to proton therapy. *Br. J. Radiol.* 93, 20190807.

McAvoy, S., Ciura, K., Wei, C., Rineer, J., Liao, Z., Chang, J.Y., Palmer, M.B., Cox, J.D., Komaki, R., Gomez, D.R., 2014. Definitive reirradiation for locoregionally recurrent non-small cell lung cancer with proton beam therapy or intensity modulated radiation therapy: predictors of high-grade toxicity and survival outcomes. *Int. J. Radiat. Oncol. Biol. Phys.* 90, 819–827.

McDonald, M.W., Moore, M.G., Johnstone, P.A.S., 2012. Risk of carotid blowout after reirradiation of the head and neck: a systematic review. *Int. J. Radiat. Oncol.* 82, 1083–1089.

McDuff, S.G.R., Remillard, K.A., Zheng, H., Raldow, A.C., Wo, J.Y., Eyler, C.E., Drapek, L. C., Goyal, L., Blaszkowsky, L.S., Clark, J.W., Allen, J.N., Parikh, A.R., Ryan, D.P., Ferrone, C.R., Tanabe, K.K., Wolfgang, J.A., Zhu, A.X., Hong, T.S., 2018. Liver reirradiation for patients with hepatocellular carcinoma and liver metastasis. *Pract. Radiat. Oncol.* 8, 414–421.

Meijneke, T.R., Petit, S.F., Wentzler, D., Hoogeman, M., Nuyttens, J.J., 2013. Reirradiation and stereotactic radiotherapy for tumors in the lung: dose summation and toxicity. *Radiother. Oncol. J. Eur. Soc. Ther. Radiol. Oncol.* 107, 423–427.

Milano, M.T., Mihai, A., Kong, M.S., F., 2018. Review of thoracic reirradiation with stereotactic body radiation therapy: A focus on toxicity risks. *Pract. Radiat. Oncol.* 8, 251–265.

Miwa, K., Matsuo, M., Ogawa, S., Shinoda, J., Yokoyama, K., Yamada, J., Yano, H., Iwama, T., 2014. Re-irradiation of recurrent glioblastoma multiforme using <sup>11</sup>C-methionine PET/CT/MRI image fusion for hypofractionated stereotactic radiotherapy by intensity modulated radiation therapy. *Radiat. Oncol. Lond. Engl.* 9, 9.

Møller, S., Munck Af Rosenscho'ld, P., Costa J., J., Law, I., Poulsen, H.S., Engelholm, S.A., Engelholm, S., 2017. Toxicity and efficacy of re-irradiation of high-grade glioma in a phase I dose- and volume escalation trial. *Radiother. Oncol.* 125, 223–227.

Moningi, S., Ludmir, E.B., Polamraju, P., Williamson, T., Melkun, M.M., Herman, J.D., Krishnan, S., Koay, E.J., Koong, A.C., Minsky, B.D., Smith, G.L., Taniguchi, C., Das, P., Holliday, E.B., 2019. Definitive hyperfractionated, accelerated proton reirradiation for patients with pelvic malignancies. *Clin. Transl. Radiat. Oncol.* 19, 59–65.

Montagne, L., Hannoun, A., Hannoun-Levi, J.-M., 2020. Second conservative treatment for second ipsilateral breast tumor event: A systematic review of the different re-irradiation techniques. *Breast* 49, 274–280.

Murgic, J., Morton, G., Loblaw, A., D'Alimonte, L., Ravi, A., Wronski, M., Davidson, M., Haider, M., Commisso, K., Zhang, L., Chung, H.T., 2018. Focal salvage high dose-rate brachytherapy for locally recurrent prostate cancer after primary radiation therapy failure: results from a prospective clinical trial. *Int. J. Radiat. Oncol.* 102, 561–567.

Myrehaug, S., Sahgal, A., Hayashi, M., Levivier, M., Ma, L., Martinez, R., Paddick, I., Régis, J., Ryu, S., Slotman, B., De Salles, A., 2017. Reirradiation spine stereotactic body radiation

therapy for spinal metastases: systematic review: International Stereotactic Radiosurgery Society practice guidelines. *J. Neurosurg. Spine* 27, 428–435.

Ng, S.P., Cardenas, C.E., Elhalawani, H., Pollard, C., Elgohari, B., Fang, P., Meheissen, M., Guha-Thakurta, N., Bahig, H., Johnson, J.M., Kamal, M., Garden, A. S., Reddy, J.P., Su, S.Y., Ferrarotto, R., Frank, S.J., Brandon Gunn, G., Moreno, A.C., Rosenthal, D.I., Fuller, C.D., Phan, J., 2020. Comparison of tumor delineation using dual energy computed tomography versus magnetic resonance imaging in head and neck cancer re-irradiation cases. *Phys. Imaging Radiat. Oncol.* 14, 1–5.

Nguyen, P.L., Chen, M.-H., D'amico, A.V., Tempany, C.M., Steele, G.S., Albert, M., Cormack, R.A., Carr-Locke, D.L., Bleday, R., Suh, W.W., 2007. Magnetic resonance image-guided salvage brachytherapy after radiation in select men who initially presented with favorable-risk prostate cancer: a prospective phase 2 study. *Cancer.* 110, 1485–1492.

Nicosia, L., Di Muzio, J., Agolli, L., Alongi, F., Mazzola, R., Valeriani, M., Badellino, S., Osti, M.F., Ricardi, U., 2020. What is the role of reirradiation in the management of locoregionally relapsed non small-cell lung cancer? *Lung Cancer* 146, 263–275.

Nieder, C., Grosu, A.L., Andratschke, N.H., Molls, M., 2006. Update of human spinal cord reirradiation tolerance based on additional data from 38 patients. *Int. J. Radiat. Oncol. Biol. Phys.* 66, 1446–1449.

Owen, D., Lukovic, J., Hosni, A., Crane, C.H., Hong, T.S., Dawson, L.A., Velec, M., Lawrence, T.S., 2020. Challenges in reirradiation of intrahepatic tumors. *Semin. Radiat. Oncol.* 30, 242–252.

Owens, R., 2018. External beam re-irradiation in rectal cancer. *Clin. Oncol.* 30, 8–123. Paradis, K.C., Mayo, C., Owen, D., Spratt, D.E., Hearn, J., Rosen, B., Kashani, R., Moran, J., Tatro, D.S., Beeler, W., Vineberg, K., Smith, D.C., Matuszak, M.M., 2019. The special medical physics consult process for reirradiation patients. *Adv. Radiat. Oncol.* 4, 559–565.

Phan, J., Sio, T.T., Nguyen, T.P., Takiar, V., Gunn, G.B., Garden, A.S., Rosenthal, D.I., Fuller, C.D., Morrison, W.H., Beadle, B., Ma, D., Zafereo, M.E., Hutcheson, K.A., Kupferman, M.E., William, W.N., Frank, S.J., 2016. Reirradiation of head and neck cancers with proton therapy: outcomes and analyses. *Int. J. Radiat. Oncol.* 96, 30–41.

Plavc, G., Jesenko, T., Oražem, M., Strojjan, P., 2020. Challenges in combining immunotherapy with radiotherapy in recurrent/metastatic head and neck cancer. *Cancers* 12, 3197.

Popovtzer, A., Gluck, I., Chepeha, D.B., Teknos, T.N., Moyer, J.S., Prince, M.E., Bradford, C.R., Eisbruch, A., 2009. The pattern of failure after reirradiation of recurrent squamous cell head and neck cancer: implications for defining the targets. *Int. J. Radiat. Oncol. Biol. Phys.* 74, 1342–1347.

Rulach, R., Hanna, G.G., Franks, K., McAleese, J., Harrow, S., 2018. Re-irradiation for locally recurrent lung cancer: evidence, risks and benefits. *Clin. Oncol.* 30, 101–109.

Sadozye, A.H., 2018. Re-irradiation in gynaecological malignancies: a review. *Clin. Oncol.* 30, 110–115.

Sanders, J., Nordström, H., Sheehan, J., Schlesinger, D., 2019. Gamma Knife radiosurgery: scenarios and support for re-irradiation. *Phys. Med.* 68, 75–82.

Shanker, M., Chua, B., Bettington, C., Foote, M.C., Pinkham, M.B., 2019. Re-irradiation for recurrent high-grade gliomas: a systematic review and analysis of treatment technique with respect to survival and risk of radionecrosis. *Neuro-Oncol. Pract.* 6, 144–155.

Shetty, K.S.R., Kurle, V., Greeshma, P., Ganga, V.B., Murthy, S.P., Thammaiah, S.K., Prasad, P.K., Chavan, P., Halkud, R., Krishnappa, R., 2021. Salvage surgery in recurrent oral squamous cell carcinoma. *Front. Oral Health* 2, 815606.

Shi, W., Scannell Bryan, M., Gilbert, M.R., Mehta, M.P., Blumenthal, D.T., Brown, P.D., Valeinis, E., Hopkins, K., Souhami, L., Andrews, D.W., Tzuk-Shina, T., Howard, S.P., Youssef, E.F., Lessard, N., Dignam, J.J., Werner-Wasik, M., 2018. Investigating the effect of reirradiation or systemic therapy in patients with glioblastoma after tumor progression: a secondary analysis of nrg oncology/radiation therapy oncology group trial 0525. *Int. J. Radiat. Oncol. Biol. Phys.* 100, 38–44.

Simone, C., Amini, A., Chetty, I., Choi, J.I., Chun, S., Donington, J., Edelman, M., Higgins, K., Kestin, L., Mohindra, P., Movsas, B., Rodrigues, G., Rosenzweig, K., Rybkin, I., Shepherd, A., Slotman, B., Wolf, A., Chang, J., 2020. American Radium Society (ARS) and American College of Radiology (ACR) appropriate use criteria systematic review and guidelines on reirradiation for Non-small Cell Lung Cancer (NSCLC). *Int. J. Radiat. Oncol. Biol. Phys.* 108, E48–E49.

Simone, C.B., Plastaras, J.P., Jabbour, S.K., Lee, A., Lee, N.Y., Choi, J.I., Frank, S.J., Chang, J.Y., Bradley, J., 2020. Proton reirradiation: expert recommendations for reducing toxicities and offering new chances of cure in patients with challenging recurrence malignancies. *Semin. Radiat. Oncol.* 30, 253–261.

Straube, C., Pigorsch, S.U., Scherb, H., Wilkens, J.J., Bier, H., Combs, S.E., 2016. Reduced volume SIB-IMRT/IGRT to head and neck cancer in elderly and frail patients: outcome and toxicity. *Radiat. Oncol.* 11, 133.

Straube, C., Kessel, K.A., Zimmer, C., Schmidt-Graf, F., Schlegel, J., Gempt, J., Meyer, B., Combs, S.E., 2019. A second course of radiotherapy in patients with recurrent malignant gliomas: clinical data on re-irradiation, prognostic factors, and usefulness of digital biomarkers. *Curr. Treat. Options Oncol.* 20, 71.

Strojan, P., Corry, J., Eisbruch, A., Vermorken, J.B., Mendenhall, W.M., Lee, A.W., Haigentz M, Jr, Beitler, J.J., de Bree, R., Takes, R.P., Paleri, V., Kelly, C.G., Genden, E.M., Bradford, C.R., Harrison, L.B., Rinaldo, A., Ferrito, A., 2015. Recurrent and second primary squamous cell carcinoma of the head and neck: When and how to reirradiate. *Head Neck* 37, 134–150.

Suresh, K., Owen, D., Bazzi, L., Jackson, W., Ten Haken, R.K., Cuneo, K., Feng, M., Lawrence, T.S., Schipper, M.J., 2018. Using indocyanine green extraction to predict liver function after stereotactic body radiation therapy for hepatocellular carcinoma. *Int. J. Radiat. Oncol. Biol. Phys.* 100, 131–137.

Svajdova M., Dubinsky P., Kazda T. Radical external beam re-irradiation in the treatment of recurrent head and neck cancer: Critical review. *Head Neck.* n/a.

Takiar, V., Garden, A.S., Ma, D., Morrison, W.H., Edson, M., Zafereo, M.E., Gunn, G.B., Fuller, C.D., Beadle, B., Frank, S.J., William WN, Jr, Kies, M., El-Naggar, A.K., Weber, R., Rosenthal, D.I., Phan, J., 2016. Reirradiation of head and neck cancers with intensity modulated radiation therapy: outcomes and analyses. *Int. J. Radiat. Oncol.* 95, 1117–1131.

- Tanvetyanon, T., Padhya, T., McCaffrey, J., Zhu, W., Boulware, D., Deconti, R., Trotti, A., 2009. Prognostic factors for survival after salvage reirradiation of head and neck cancer. *J. Clin. Oncol.* 27, 1983–1991.
- Tao, R., Tsai, C.J., Jensen, G., Eng, C., Kopetz, S., Overman, M.J., Skibber, J.M., Rodriguez-Bigas, M., Chang, G.J., You, Y.N., Bednarski, B.K., Minsky, B.D., Delclos, M.E., Koay, E., Krishnan, S., Crane, C.H., Das, P., 2017. Hyperfractionated accelerated reirradiation for rectal cancer: an analysis of outcomes and toxicity. *Radiother. Oncol. J. Eur. Soc. Ther. Radiol. Oncol.* 122, 146–151.
- Tsang, D.S., Laperriere, N.J., 2019. Re-irradiation for paediatric tumours. *Clin. Oncol.* 31, 191–198.
- Valle, L.F., Lehrer, E.J., Markovic, D., Elashoff, D., Levin-Epstein, R., Karnes, R.J., Reiter, R.E., Rettig, M., Calais, J., Nickols, N.G., Dess, R.T., Spratt, D.E., Steinberg, M.L., Nguyen, P.L., Davis, B.J., Zaorsky, N.G., Kishan, A.U., 2020. A systematic review and meta-analysis of local salvage therapies after radiotherapy for prostate cancer (MASTER). *Eur. Urol.* 80, 280–292. S0302283820308745.
- Vargo, J.A., Ferris, R.L., Ohr, J., Clump, D.A., Davis, K.S., Duvvuri, U., Kim, S., Johnson, J.T., Bauman, J.E., Gibson, M.K., Branstetter, B.F., Heron, D.E., 2015. A prospective phase 2 trial of reirradiation with stereotactic body radiation therapy plus cetuximab in patients with previously irradiated recurrent squamous cell carcinoma of the head and neck. *Int. J. Radiat. Oncol.* 91, 480–488.
- Verma, V., Lin, S.H., Simone, C.B., Mehta, M.P., 2016. Clinical outcomes and toxicities of proton radiotherapy for gastrointestinal neoplasms: a systematic review. *J. Gastrointest. Oncol.* 7, 644–664.
- Verma, V., Rwigema, J.M., Malyapa, R.S., Regine, W.F., Simone, C.B., 2017. Systematic assessment of clinical outcomes and toxicities of proton radiotherapy for reirradiation. *Radiother. Oncol. J. Eur. Soc. Ther. Radiol. Oncol.* 125, 21–30.
- Wells G., Shea B., O'Connell D., et al. 2000. The Newcastle–Ottawa Scale (NOS) for Assessing the Quality of Non-Randomized Studies in Meta-Analysis. 2000.
- Wild, A.T., Hiniker, S.M., Chang, D.T., 2013. Re-irradiation with stereotactic body radiation therapy as a novel treatment option for isolated local recurrence of pancreatic cancer after multimodality therapy: experience from two institutions. *J. Gastrointest. Oncol.* 4, 343–351.
- Yamazaki, H., Ogita, M., Kodani, N., Nakamura, S., Inoue, H., Himei, K., Kotsuma, T., Yoshida, K., Yoshioka, Y., Yamashita, K., Udono, H., 2013. Frequency, outcome and prognostic factors of carotid blowout syndrome after hypofractionated re-irradiation of head and neck cancer using CyberKnife: a multi-institutional study. *Radiother. Oncol.* 107, 305–309.
- Yamazaki, H., Ogita, M., Himei, K., Nakamura, S., Suzuki, G., Yoshida, K., Kotsuma, T., Yoshioka, Y., 2016. Reirradiation using robotic image-guided stereotactic radiotherapy of recurrent head and neck cancer. *J. Radiat. Res.* 57, 288–293.
- Yang, W.-C., Hsu, F.-M., Chen, Y.-H., Shih, J.Y., Yu, C.J., Lin, Z.Z., Lu, S.H., Yang, J.C., Cheng, A.L., Kuo, S.H., 2020. Clinical outcomes and toxicity predictors of thoracic re-irradiation for locoregionally recurrent lung cancer. *Clin. Transl. Radiat. Oncol.* 22, 76–82.

Table 1

Selected recent (> 2010) prospective studies from [Supplementary data 1](#).

| Name / Date                               | Type of study   | Organ             | No. of patients    | Technique                | Median time before reRT | Outcomes  | Late toxicity (patients)                         |
|---|---|-------------------|--------------------|--------------------------|-------------------------|---|--|
| <a href="#">Garg et al., 2011</a>         | Single-institution, prospective, phase I/II                       | Bone (Spine)      | 59                 | SBRT                     | 12.8 – 19.8 months      | LRC: 1 yr, 76%<br>OS: 1 yr, 76%                             | 2 ≥ grade 3 (lumbar plexopathy)                  |
| <a href="#">Møller et al., 2017</a>       | Single-institution, prospective, phase I (NCT02025231)            | Brain (GBM)       | 31                 | SBRT                     | > 6 months              | Median PFS: 2.8 m.<br>Median OS: 7 m.                       | 3 ≥ grade 3 (radionecrosis)                      |
| <a href="#">Shi et al., 2018</a>          | Multi-institution, prospective, phase III (RTOG 0525)             | Brain (GBM)       | 88 (24 reRT alone) | Various (IMRT, SBRT, BT) | nr                      | Median OS: 8.2 m.   | nr   |
| <a href="#">Kauer-Dorner et al., 2012</a> | Single-institution, prospective, phase I                          | Breast            | 39                 | BT                       | ~ 11 years              | LRC: 5 yr. 93%<br>OS: 5 y. 87%                              | 20 grade 1–2, 4 ≥ grade 3 (fibrosis and pain)    |
| <a href="#">Arthur et al., 2020</a>       | Multi-institution, prospective, phase II (NRG oncology RTOG 1014) | Breast            | 58                 | 3D-CRT                   | 13.4 years              | LRC: 5 yr, 95%<br>OS: 5 yr. 95%                             | 4 ≥ grade 3 (fibrosis, breast atrophy)           |
| <a href="#">Fernandes et al., 2016</a>    | Single-institution, prospective, phase I                          | Gut (Esophagus)   | 14                 | PT                       | 32 months               | OS: 1 y. 70.7%  | 2 ≥ grade 3 (esophageal ulceration)              |
| <a href="#">Chen et al., 2011</a>         | Single-institution, prospective, phase I                          | Head and Neck     | 21                 | IMRT                     | 14 months               | LRC: 1 yr. 72%,<br>2 yr. 65%<br>OS: 1 yr. 65%,<br>2 yr. 40% | 3, grade nr (trismus and brachial plexopathy)    |
| <a href="#">Vargo et al., 2015</a>        | Single-institution, prospective, phase I (NCT 01104922)           | Head and Neck     | 50                 | SBRT (with cetuximab)    | 18 months               | LRC: 1 yr. 37%<br>OS: 1 yr. 40%                             | 5 ≥ grade 3 (dysphagia aerodigestive fistulas)   |
| <a href="#">Chao et al., 2017</a>         | Multi-institution, prospective, phase II (NCT01126476)            | Lung              | 57                 | PT                       | 19 months               | OS: 1 yr. 59%<br>PFS: 1 yr. 58%                             | 24 ≥ grade 3 (5 deaths)                          |
| <a href="#">Crook et al., 2019</a>        | Multi-institution, prospective, phase II (NRG Oncology/RTOG-0526) | Pelvis (prostate) | 92                 | BT                       | 85 months               | nr  | 6 ≥ grade 3 (rectal bleed, retention, frequency) |

Abbreviations: SBRT: stereotactic body radiation therapy, FU: follow-up, LRC: local relapse-free rate, OS: overall survival, GBM: glioblastoma, PFS: progression free survival, OS: overall survival, CT: chemotherapy, m.: months, IMRT: intensity modulated radiation therapy, BT: brachytherapy, nr not reported, 3D-CRT: 3-dimensional conformal technique, PT: proton therapy, BRFR: biochemical relapse-free rate, GI: gastrointestinal, GU: genitourinary



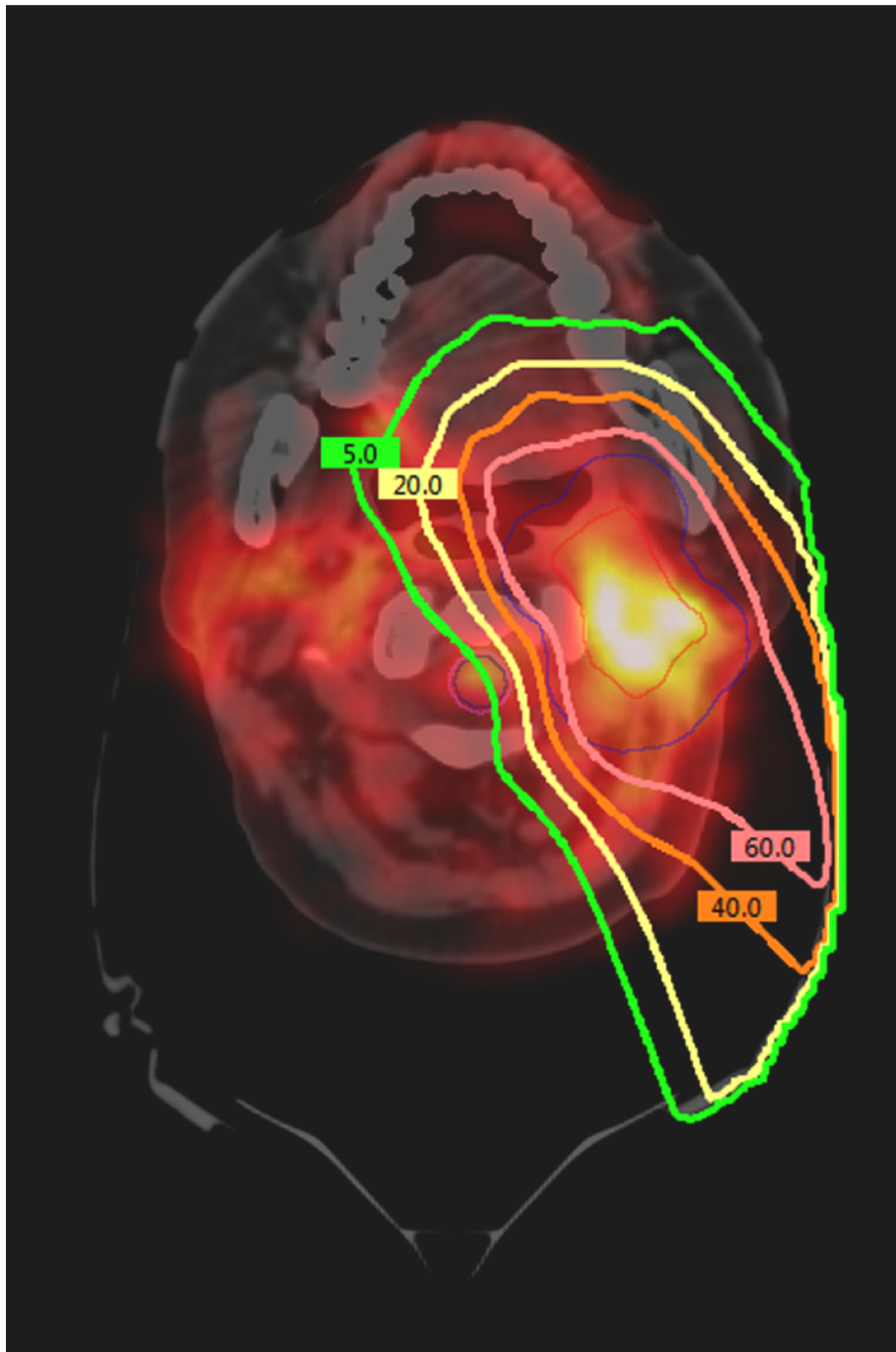
Table 2

## Dose constraints in reirradiation setting.

| Organ                               | Constraints<br>(composite EQD2<br>dose)                       | References   |
|-------------------------------------|---|--|
| Organs arranged in serial FSU       |   |  |
| Carotid/Aorta/ great vessels        | Dmax < 120 Gy   | (Evans et al., 2013; Dionisi et al., 2019; Alterio et al., 2020) |
| Esophagus                           | Dmax < 85 – 90 Gy<br>V60Gy < 40%                              | (Meijneke et al., 2013)<br>(Simone et al., 2020)                 |
| Trachea and proximal bronchial tree | Dmax < 100 – 110 Gy<br>Dmax < 110 Gy                          | (Simone et al., 2020)  |
| Bowel                               | < 90 – 98 Gy  | (Berman et al., 2014)  |
| Ducts                               | < 100 Gy (BED)  | (Valle et al., 2020)   |
| Spinal cord                         | Dmax < 57 Gy<br>(Recovery ?)                                  | (Simone et al., 2020)  |
| Brachial plexus                     | Dmax < 85 Gy<br>(Recovery ?)                                  | (Simone et al., 2020)  |
| Organs arranged in parallel FSU     |   |  |
| Lung                                | V20 < 40%   | (Simone et al., 2020)  |
| Liver                               | V15Gy < 800cc<br>(Recovery ?)<br>V19Gy < 700cc<br>MLD < 15 Gy | (McDuff et al., 2018)<br>(Benedict et al., 2010)                 |
| Heart                               | V40Gy < 50%   | (Simone et al., 2020)  |

Abbreviations: MLD: mean liver dose, Dmax: maximum dose, V60Gy < 40%: the volume receiving 60 Gy does not exceed 40%.

Figure 1



Metabolic imaging for target volume definition and treatment planning in reirradiation. This figure shows the example of a patient reirradiated by proton therapy at the Institut Curie for a local recurrence of oropharyngeal cancer. To define the target volume, a registration was performed between the dosimetry scan and the PET scan showing the recurrence. The isodoses (green line: 5 Gy, yellow line: 20 Gy, orange line: 40 Gy, and pink line: 60 Gy) show that protons allow to considerably limit the irradiation of healthy tissues by focusing on the irradiation of the target volume (red line) defined using the PET hypermetabolism.