



HAL
open science

Meningioma in patients exposed to progestin drugs: results from a real-life screening program

Thomas Samoyeau, Corentin Provost, Alexandre Roux, Laurence Legrand,
Edouard Dezamis, Geneviève Plu-Bureau, Johan Pallud, Catherine
Oppenheim, Joseph Benzakoun

► **To cite this version:**

Thomas Samoyeau, Corentin Provost, Alexandre Roux, Laurence Legrand, Edouard Dezamis, et al..
Meningioma in patients exposed to progestin drugs: results from a real-life screening program. *Journal
of Neuro-Oncology*, 2022, 160 (1), pp.127 - 136. 10.1007/s11060-022-04124-2 . inserm-03854767

HAL Id: inserm-03854767

<https://inserm.hal.science/inserm-03854767>

Submitted on 16 Nov 2022

HAL is a multi-disciplinary open access archive for the deposit and dissemination of scientific research documents, whether they are published or not. The documents may come from teaching and research institutions in France or abroad, or from public or private research centers.

L'archive ouverte pluridisciplinaire **HAL**, est destinée au dépôt et à la diffusion de documents scientifiques de niveau recherche, publiés ou non, émanant des établissements d'enseignement et de recherche français ou étrangers, des laboratoires publics ou privés.

Meningioma in patients exposed to progestin drugs: results from a real-life screening program

Submitted to *Journal of Neuro-Oncology*, received: 4 August 2022 / accepted: 26 August 2022
<https://doi.org/10.1007/s11060-022-04124-2>

Thomas Samoyeau^{1,2,3} • Corentin Provost^{1,2,3} • Alexandre Roux^{1,2,4} • Laurence Legrand^{1,3} • Edouard Dezamis^{1,2,4} • Geneviève Plu-Bureau^{2,5,6} • Johan Pallud^{1,2,4} • Catherine Oppenheim^{1,2,3*} • Joseph Benzakoun^{1,3*}

1. Institut de Psychiatrie et Neurosciences de Paris (IPNP), INSERM U 1266, IMA-BRAIN, Paris, France
2. Université de Paris, Paris, France
3. Service de Neuroradiologie, GHU Paris Psychiatrie et Neurosciences, Hôpital Sainte-Anne, Paris, France
4. Service de Neurochirurgie, GHU Paris Psychiatrie et Neurosciences, Hôpital Sainte-Anne, Paris, France.
5. Unité de gynécologie endocrinienne, Hôpital Cochin-Port-Royal, 123 boulevard Port-Royal, Paris, France
6. Obstetrical Perinatal and Pediatric Epidemiology Research Team, EPOPé, Centre for Epidemiology and Statistics Sorbonne Paris Cité (CRESS), INSERM U1153, Paris, France.

* *These authors contributed equally to the study*

Corresponding author: Joseph Benzakoun, MD PhD, Imaging Department, Sainte-Anne Hospital, 1 rue Cabanis, 75014 Paris, France.

Email: j.benzakoun@ghu-paris.fr

Phone: +33-145658242

ORCID

- Thomas Samoyeau (MD): 0000-0002-7259-7876
- Corentin Provost (MD): 0000-0002-0200-4027
- Alexandre Roux (MD-PhD): 0000-0002-9597-673X
- Laurence Legrand (MD): 0000-0003-3951-7405
- Geneviève Plu-Bureau (MD-PhD): 0000-0002-1020-8142
- Johan Pallud (MD-PhD): 0000-0002-1652-9844
- Catherine Oppenheim (MD-PhD): 0000-0003-3410-0862
- Joseph Benzakoun (MD-PhD): 0000-0002-0733-0104

Acknowledgment: M. Thomas Boulliung (Paris, France) kindly provided statistical advice for this manuscript.

Keywords: Cyproterone acetate • Chlormadinone acetate • Nomegestrol acetate • Meningioma • Mass screening

Abstract

Purpose: To report the results of systematic meningioma screening program implemented by French authorities in patients exposed to progestin therapies (cyproterone (CPA), nomegestrol (NA), and chlormadinone (CMA) acetate).

Methods: We conducted a prospective monocentric study on patients who, between September 2018 and April 2021, underwent standardized MRI (injection of gadolinium, then a T2 axial FLAIR and a 3D-T1 gradient-echo sequence) for meningioma screening.

Results: Of the 210 included patients, 15 (7.1%) had at least one meningioma; seven (7/15, 47%) had multiple meningiomas. Meningiomas were more frequent in older patients and after exposure to CPA (13/103, 13%) compared to NA (1/22, 4%) or CMA (1/85, 1%; $P=0.005$). After CPA exposure, meningiomas were associated with longer treatment duration (median=20 vs 7 years, $P=0.001$) and higher cumulative dose (median=91 g vs. 62 g, $P=0.014$). Similarly, their multiplicity was associated with higher dose of CPA (median=244 g vs 61 g, $P=0.027$). Most meningiomas were $\leq 1 \text{ cm}^3$ (44/58, 76%) and were convexity meningiomas (36/58, 62%). At diagnosis, patients were non-symptomatic, and all were managed conservatively. Among 14 patients with meningioma who stopped progestin exposure, meningioma burden decreased in 11 (79%) cases with no case of progression during MR follow-up.

Conclusion: Systematic MR screening in progestin-exposed patients uncovers small and multiple meningiomas, which can be managed conservatively, decreasing in size after progestin discontinuation. The high rate of meningiomas after CPA exposure reinforces the need for systematic screening. For NA and CMA, further studies are needed to identify patients most likely to benefit from screening.

Introduction

Meningiomas are the most common primary tumors of the central nervous system[1]. Risk factors for meningioma include age, female sex, personal history of cranial radiation, family history of meningiomas, and type II neurofibromatosis[2]. The relationship between meningiomas and sex hormones is supported by female predominance, tumor enlargement during pregnancy and shrinkage after delivery, associations with breast cancer[3], and the expression of progesterone-receptors in two thirds of meningiomas[4].

Progestins are synthetic drugs with antiandrogenic and progesterone-like activity. They include cyproterone acetate (CPA), chlormadinone acetate (CMA) and norgestrol acetate (NA). CPA is at the same time a strong antagonist for androgen and an agonist for progesterone receptor (1000 times the potency of native progesterone)[5]. CMA then NA, with both weaker antiandrogenic and progestin properties, were marketed later[5, 6]. Those are used in various indications, mostly against major female hirsutism[5] (CPA), endometriosis, menopausal disorder[7] (CMA, NA), and hyperandrogenic symptoms of polycystic ovary syndrome[8] (CPA). Progestin use has long been suspected to promote meningioma formation and growth[9–24]. Tumor volume reduction after progestin withdrawal has also been reported for CMA[10], CPA[11, 19, 20, 25, 26], and NA[27, 28], suggesting that progestin discontinuation and conservative management could be the first-line strategy for progestin-related meningiomas[29]. Several epidemiological studies highlighted a high risk of developing a meningioma needing an invasive treatment. This risk was higher risk for CPA than CMA and NA, was dose-dependent, and a decreased after progestin discontinuation[30, 31]. Recently, a meta-analysis confirmed the association between CPA and meningioma and validated the imaging-requirement before undergoing CPA-treatment[32]. These studies led to French recommendations of systematic MR

screening in patients exposed to progestin[33]: from September 2018 for CPA, and June 2020 for CMA and NA[34].

This national systematic screening as well as the information given to clinicians and patients resulted in a sudden increase of MRI examinations in asymptomatic patients. However, these screened patients were not targeted in previous studies that investigated mainly symptomatic, often surgically-treated meningiomas. Therefore, the percentage of asymptomatic meningiomas in the screened population and their type of management, as well as the possibility to detect other brain lesions (incidental or associated to progestin) is still uncertain. Hence, our aim is to report the yield of the real-life screening of meningioma in such population, in particular their prevalence, MRI characteristics and the care they received in our neurosurgical center.

Methods

Study design and population

We conducted a prospective monocentric cohort study including consecutive progestin-exposed patients referred between September 2018 and April 2021 for MRI screening for meningioma. During this period, through a dedicated e-mail address, we implemented a fast-track MRI procedure coupled with neurosurgeon expertise whenever a meningioma or other incidental lesion was uncovered. Patients' associations, ambulatory practitioners, and hospital departments were informed of the procedure. All individual patients received an online form collecting clinical and hormonal history, and written informed consent to participate in the study was obtained. Inclusion criteria were: age ≥ 18 years, a history of progestin drug therapy (i.e. CPA, CMA, or NA), a brain MRI scheduled as part of systematic screening, and written informed consent. Exclusion criteria were: refusal to participate in the study, previous diagnosis of meningioma, contraindication of

gadolinium use and/or MRI, MRI referral before treatment initiation, exposure to low dose of CPA (2 mg/day) associated with estrogens, not targeted by the systematic screening.

Clinical data

We collected the following data: type of progestin used, hormonal drug history, indication for treatment, date of initiation and treatment duration, rate and dose of intake, and, where appropriate, date of treatment discontinuation. The cumulative progestin dose was calculated by multiplying the dose, the rate of medication, and the duration of exposure. In the case of multiple progestin exposure, patients were grouped based on the most recent treatment. Incidence by person-year was obtained by dividing the number of meningiomas by the product of the total exposure duration and the number of patients exposed to progestin. We also collected other known risk factors of meningioma (personal history of cranial irradiation, type II neurofibromatosis, pregnancy, and family history of meningioma). Although theoretically asymptomatic, patients were invited to report on recent (<12 months) clinical complaints, such as headaches, nausea, epileptic seizures, and visual impairment.

Screening MRI

Brain MRI was performed on a 1.5 Tesla (Explorer, General Electric Healthcare) or a 3 Tesla (MR 750, General Electric Healthcare) with a standardized protocol: injection of 0.2 mL/kg of Dotarem® (gadoteric acid, Guerbet) 5 minutes before an axial T2 fluid-attenuated inversion recovery (FLAIR) sequence and a 3D T1-weighted gradient-echo sequence (\approx 6 min total acquisition time) (see Supplementary Table 1). MR images were analyzed in consensus by two radiologists (with respectively 5 years and 1 year of experience), who searched for meningiomas and incidental findings.

Meningioma was defined as a well-circumscribed extra-axial and dural-based mass, with strong and homogeneous enhancement after contrast injection[35], confirmed in consensus by both readers. The following imaging characteristics were collected: number of meningiomas, location, volume, venous sinus obstruction, enhancement, severe mass effect (i.e. leading to obstructive hydrocephalus or brain herniation), brain edema, bone reaction, and extracranial extension.

Volumes were calculated on 3D T1-weighted enhanced sequence. Using a threshold-based semi-automated segmentation in Vue PACS (Philips Healthcare), we obtained a Volume Of Interest (VOI) surrounding the tumors and manually corrected it whenever necessary. Volume was automatically computed by summing the individual volume of each voxel in the VOI. For each patient, tumor burden was computed by summing the volume of each meningioma.

Patient management and MRI follow-up

Patients diagnosed with meningioma or incidental findings were referred to a senior neurosurgeon (14 years of experience). Whenever feasible, progestin was discontinued by the referring clinician. In the case of conservative management, a follow-up MRI was scheduled every six months for one year and yearly thereafter. Volumetric analysis was repeated on each follow-up MRI. A >15% change in tumor volume or tumor burden was considered meaningful, as proposed by others[36].

Statistical analyses

Contingency tables were analyzed using Fisher's exact test. Continuous variables (age, treatment duration, and cumulative CPA dose) were compared with Mann-Whitney U test. Data were expressed as median and interquartile range (IQR). Meningioma characteristics were expressed with mean \pm standard deviation (SD), for comparison with previous studies. Correlation between tumor burden, cumulative dose and CPA exposure duration was evaluated using Spearman

correlation coefficient (Rho). The significance threshold used was $P=0.05$. Statistical analyses were performed using Python 3.6.5.

Results

Population and prevalence of meningioma

Among 243 patients referred during the study period, 210 fulfilled the inclusion criteria (Fig. 1). Clinical characteristics at baseline are summarized in Table 1. Most patients ($n=114$, 54%) were referred by gynecologists. There were 209 women and one transgender male-to-female. The median (IQR) age was 38 (30-46) years. No patient had a history of cranial radiation or type II neurofibromatosis. Fifteen (7.1%) of the 210 patients had at least one meningioma, with multiple meningiomas in seven (47%) patients. As shown in Table 1, patients with meningioma were significantly older than those without but did not significantly differ in number of pregnancies, family history of meningioma, indication for progestin therapy, or clinical complaints. None of the meningiomas was considered symptomatic.

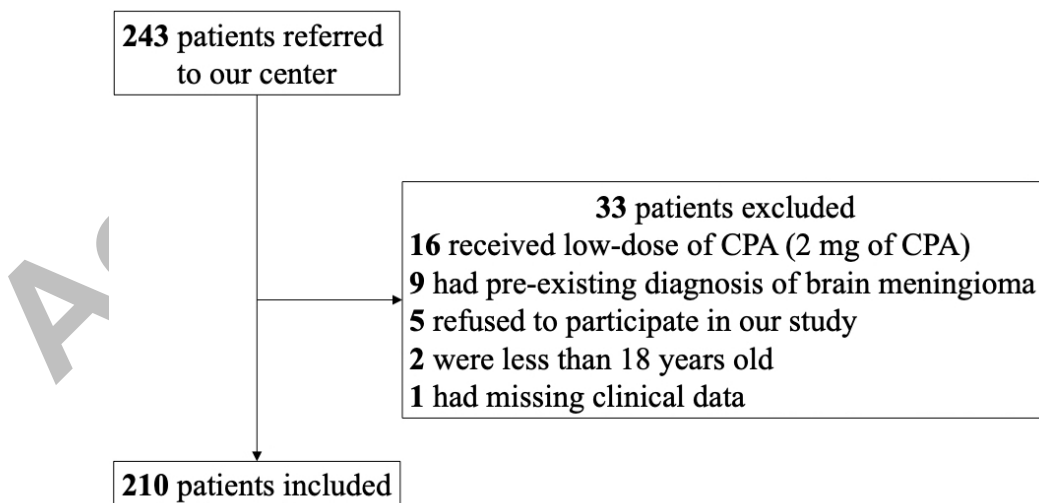


Fig. 1 Patient inclusion flow chart

	No meningioma 195 patients	Meningioma 15 patients	P-value
Female, n (%)	194 (99.5)	15 (100)	1
Age, median (IQR)	38 (29-46)	47 (45-52)	0.003
Last progestin drug intake, n (%)*			
CPA (n=103)	90 (87)	13 (13)	
CMA (n=85)	84 (99)	1 (1)	0.005
NA (n=22)	21 (95)	1 (5)	
Family history of meningioma, n (%)	10 (5)	0	-
Previous pregnancy[§], n (%)	49 (25)	3 (21)	1
Referring physician, n (%)			
Gynecologist	102 (52)	12 (80)	0.057
General practitioner	25 (13)	1 (7)	0.700
Endocrinologist	22 (11)	2 (13)	0.683
Dermatologist	3 (1)	0	-
Psychiatrist	3 (1)	0	-
Other	3 (2)	0	-
Not available	37 (18)	0	-
Indication for progestin drug, n (%)			
Contraception/anti-gonadotropin therapy	88 (45)	4 (27)	0.188
Endometriosis	52 (27)	5 (33)	0.557
Hirsutism	38 (19)	3 (20)	1
Polycystic ovarian syndrome	37 (19)	4 (27)	0.500
Acne	36 (18)	4 (27)	0.493
Alopecia	9 (5)	0	-
Trans-gender hormone therapy	1 (1)	0	-
Other (<i>mastodynia, severe dysmenorrhea, ovarian cyst, fibromas, menorrhagia</i>)	14 (7)	0	-
Clinical symptoms, n (%)	69 (35)	6 (40)	0.782
Unusual headache	45 (23)	2 (13)	0.529
Morning nausea	22 (11)	3 (20)	0.397
Neurological complaints			
Visual complaints	31 (15)	2 (13)	1
Dizziness	6 (3)	1 (7)	0.409
Paresthesia	3 (1)	0	-
Hearing loss	2 (1)	0	-
Other (<i>e.g. asthenia, drop in libido, mild cognitive impairment</i>)	7 (4)	1 (7)	-

Table 1: Characteristics of the population

*IQR, interquartile range; CPA, cyproterone acetate; CMA, chlormadinone acetate; NA, nomegestrol acetate. *For this line, percentages are calculated depending on the last progestin drug intake. §For this analysis, one transgender male-to-female was excluded.*

Treatment associated with meningioma occurrence

As shown in Table 1, the occurrence of at least one meningioma was significantly more frequent in the CPA group (13/103, 13%) than in the NA (1/22, 4%) and CMA (1/85, 1%) groups ($P=0.014$). Detailed drug history is available in Supplementary Table 2. The incidence of meningioma was 13.2 per 100 000 person-years in the CPA group (not computed for NA and CMA groups due to a single case of meningioma in each group).

In the CPA group, patients with at least one meningioma had a longer treatment duration (median: 20 (8-24) years vs. 7 (3-12) years, $P=0.001$) and received a greater cumulative dose of CPA (91 g (61-244) vs. 62 g (37-97), $P=0.014$) than patients without meningioma (Fig. 2). Among the 13 patients with meningioma in the CPA group, the six patients with multiple meningiomas received a greater cumulative dose of CPA than those with a single meningioma (244 g (192-286) vs. 61 g (49-88), $P=0.027$). A greater cumulative dose and a longer treatment duration were observed in the single patient with meningioma in each of the CMA and NA groups.

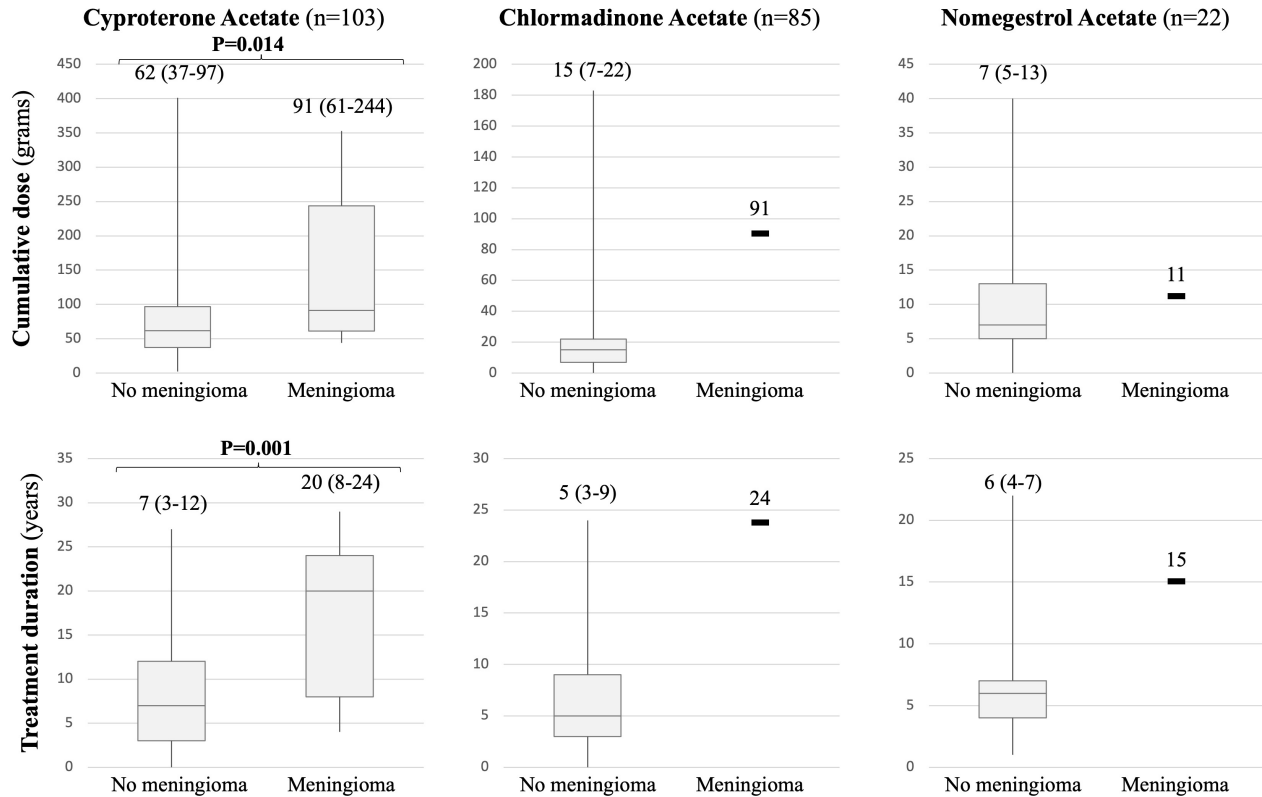


Fig. 2 Relationship between treatment exposure and meningioma occurrence

Results are expressed as median (IQR). No statistical analysis was performed in the Chlormadinone acetate and Nomegestrol acetate groups, a single case of meningioma having occurred in each group

Imaging characteristics of meningioma at MR screening

Detailed and illustrative cases are provided in Fig. 3 and Supplementary Table 3. Among the 15 patients with meningioma, there was a mean of 3.9 ± 5.0 tumors per patient, with a maximum of 17. The mean tumor burden was 2.66 ± 4.39 cm³. Among the 13 meningioma cases exposed to CPA, tumor burden was not significantly correlated to cumulative dose ($Rho=0.38$, $P=0.20$) nor to CPA exposure duration ($Rho=0.49$, $P=0.09$). At diagnosis, meningiomas were in most cases ≤ 1 cm³ (44/58, 76%) and they had a mean volume of 0.68 ± 0.83 cm³ (range 0.01-3.66). Apart from one meningioma located in the cerebellopontine angle, all were supratentorial: 36 (62%) on the

convexity, 12 (21%) on the middle skull base, and 9 (16%) on the anterior skull base; 13 (22%) were in contact with dural sinuses without venous obstruction. All meningiomas homogeneously enhanced after contrast injection and none was responsible for brain edema or severe mass effect. Fifteen (26%) were associated with skull hyperostosis. An extracranial extension through the skull base (Fig. 2f) and a sheet-like appearance (“en plaque” meningioma) (Fig. 2g) were observed, each in one case (2%).

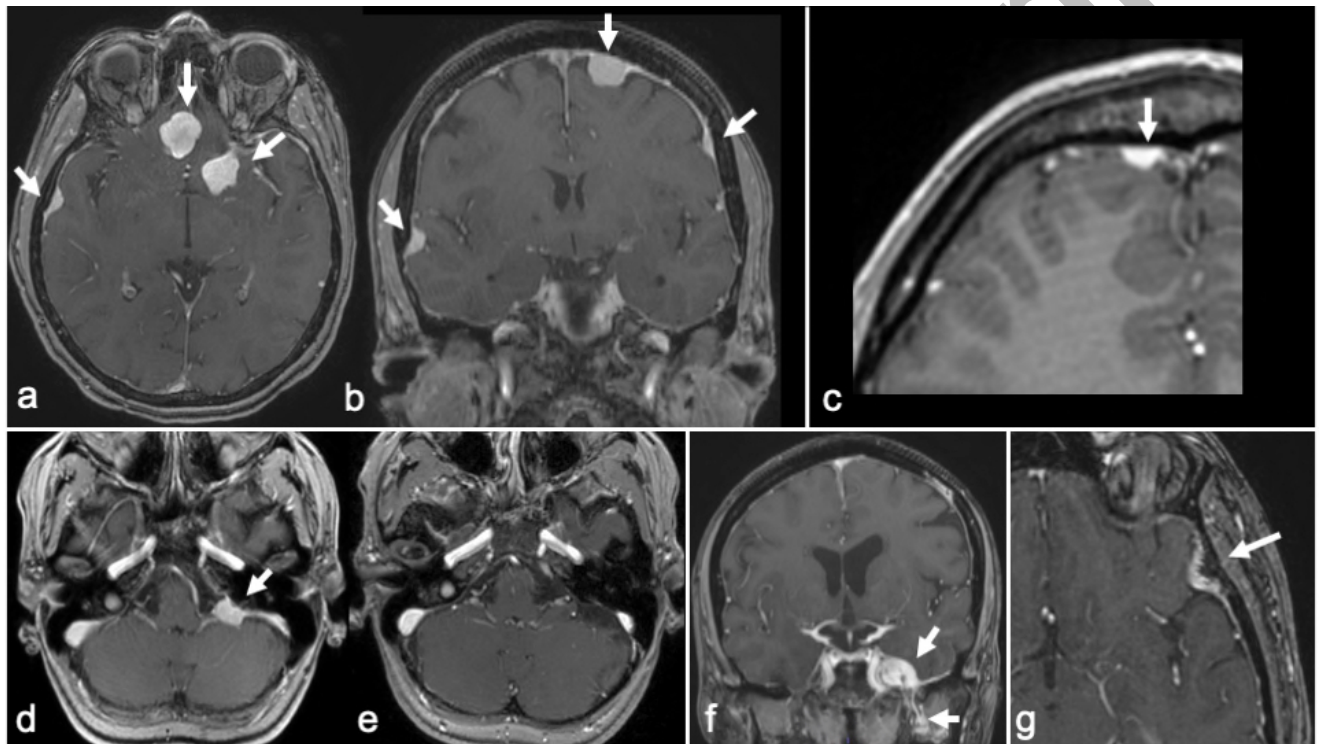


Fig. 3 MR imaging of illustrative cases in patients exposed to progestin drugs

All images are 3D T1-weighted after contrast injection

(a, b) Multiple meningiomas in a 58-year-old woman (Case 6)

(c) Small focal dural thickening in a 23-year-old woman (Case 3)

(d) Left pontocerebellar meningioma in a 48-year-old woman, who had a with normal MRI (e) 4 years before study inclusion (Case 10)

(f) Left cavernous sinus meningioma with extracranial extension following the left trigeminal nerve in a 54-year-old woman (Case 8)

(g) “En plaque” meningioma in a 46-year-old woman (Case 11)

Patient management and MRI follow-up

All meningiomas were considered asymptomatic, even in the six patients with clinical complaints (Table 1). Consequently, a conservative approach with MRI follow-up was proposed to the 15 patients with meningioma. Of these, seven had discontinued progestin at the time of MRI screening and seven stopped a few days after screening; in these 14 patients, the median MR follow-up was 18 (10.5-25) months. Tumor burden decreased in 11 (79%) cases (Fig. 4). In the remaining case (case 9, Table 2), a multidisciplinary team recommended continuing CPA; the 0.15 cm³ meningioma slightly grew, but remained below the 15% predefined threshold over the 24 months of follow-up. Overall, no case showed an increase in tumor burden or a new meningioma.

Similar results were observed on the per-meningioma analysis after cessation of progestin (n=57): 40 (70%) regressed during follow-up, 17 (30%) remained stable, and none progressed. The mean tumor reduction rate was 0.44 ± 0.64 mm³/day, i.e. 0.16 ± 0.23 cm³/year.

Accepted Manuscript

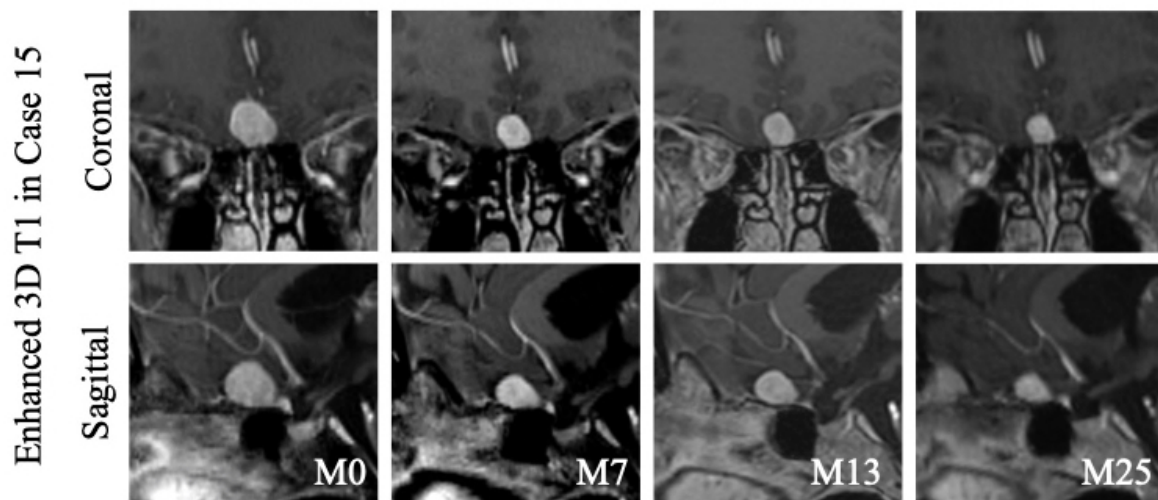
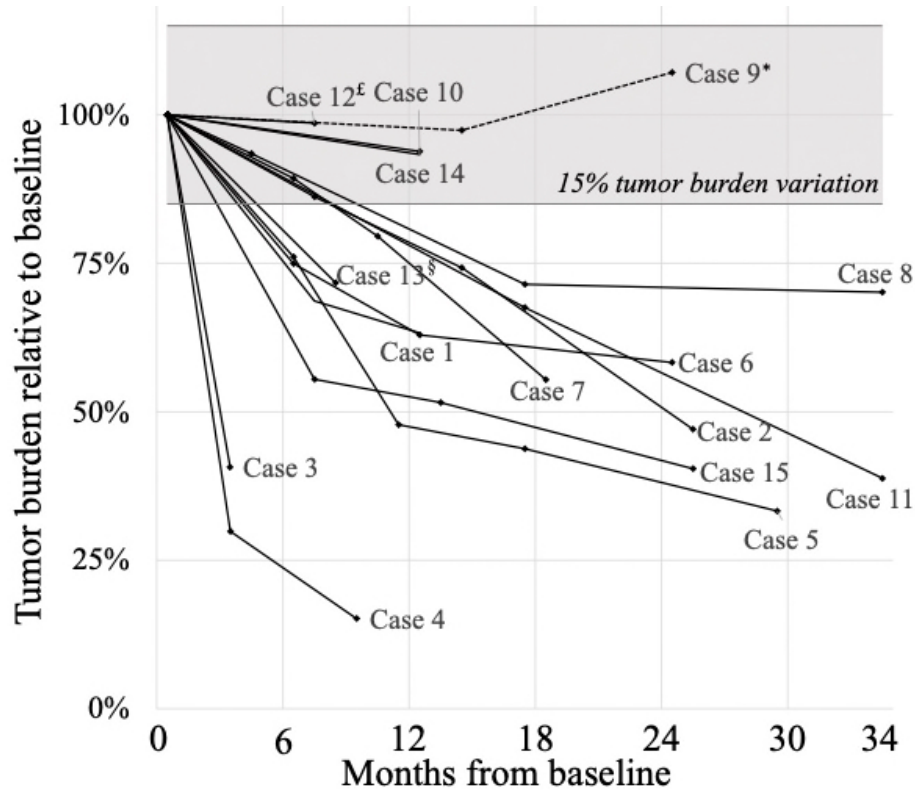


Fig. 4 Tumor burden kinetic after screening

Time course of tumor burden relative to baseline volume at screening. Case 12^f exposed to CMA and Case 13^s to NA. All other cases were exposed to CPA. Case 9* kept on using CPA and meningioma increased slightly during follow-up. Among the 14 patients who stopped progestin drug therapy, 11 presented at least a 15% decrease in tumor burden in their last MRI follow-up (light gray area). Bottom panel: Illustrative example of a decreasing meningioma at 7, 13 and 25 months after CPA discontinuation (Case 15)

Incidental findings

Ten patients (4.7%) had incidentalomas that required dedicated care: 4 intracranial aneurisms (one treated by surgical clipping), 2 pituitary non-secreting microadenomas (both exposed to CPA, conservative management), a probable diffuse low-grade glioma (exposed to CMA, currently under MRI follow-up), 2 cavernomas (one exposed to CPA, the other to CMA, conservative management), and a single case of idiopathic intracranial hypertension (exposed to CMA, conservative management).

Discussion

In this prospective monocentric study, initiated after the French recommendations of systematic MRI screening for meningiomas in patients exposed to progestin therapy, 15 patients out of 210 (7.1%) had at least one meningioma. We observed that: 1) meningiomas were more frequent in patients whose last progestin exposure was to CPA (13%) than in those exposed to NA (5%), or CMA (1%); 2) In the CPA group, the occurrence of meningiomas was associated with both treatment duration and cumulative dose, the latter being higher in multiple meningiomas; 3) meningiomas were typically small and multiple, preferentially located on the convexity, and none of them were symptomatic; 4) after progestin withdrawal, the meningioma tumor burden decreased in 79% of patients and remained stable in the others.

This is the first study evaluating the yield of systematic MRI screening for meningioma in patients exposed to progestin, as per French national recommendations. The incidence rate of meningiomas in our study (13% under CPA treatment) was much higher than that in the general population, as incidental meningiomas were found in only 2.3% subjects at autopsy[37] and 1% in two other large cohorts[38, 39]. The rate we report does not reflect all meningiomas associated

with CPA, since most symptomatic meningiomas were likely diagnosed before the launching of systematic MR screening. Our study complements the previous large nationwide cohort study focusing on high dose CPA-associated meningiomas referred for neurosurgical resection or radiation[30]. Despite the small size of CMA and NA groups (with a single case of meningioma in each), the prevalence among CMA (1%) and NA (5%) users is consistent with a lower risk of meningioma under these drugs than in CPA users, as reported in the large epidemiological cohort focusing on surgically-treated meningioma[31].

The main strength of this study lies in its "real-life" approach. Indeed, numerous retrospective cohorts and one meta-analysis already established the link between progestins and meningioma[30–32]. However, the yield of MR screening proposed by the French authorities was unknown, especially regarding the expected detection rate, and imaging characteristics of uncovered meningioma in a pauci/asymptomatic population. Another distinctive point is the prospective inclusion of patients, that ensures no missing MR at screening. Overall, progestin-associated meningiomas uncovered by systematic MR screening were all asymptomatic, small, and none of them had mass effect or edema. A salient finding of the systematic screening is the high rate (47%) of multiple meningiomas in this study as compared to a 1-10% rate in general population [40, 41]. This confirms the results of previous studies that also found a multiple meningioma rate as high as 48%[29, 42, 43] in progestin-induced meningioma. The association between multiple meningiomas and the cumulative dose of CPA is consistent with recent findings in surgical meningiomas, based on the French nationwide health record database[44]. Taken together, this reinforces the hypothesis of a critical role of progestin intake in inducing tumoral initiation of multiple specific meningeal cells in several locations[43]. It also strengthens the view that previous exposure to progestin should be thoroughly searched for when faced with multiple meningiomas[24, 43], even if small and asymptomatic. As opposed to the large nationwide cohort

and previous series of neurosurgically treated CPA-associated meningiomas[30, 44], the most common location in our series was the convexity and not the skull base. This difference may be explained by the fact that meningiomas of the convexity remain silent until they become sizeable whereas skull base meningiomas are more likely to be symptomatic due to the vicinity of cranial nerves.

After progestin withdrawal, the tumor burden decreased over time in 79% of patients while it remained stable in the others. Overall, this evolution of tumors is strikingly different from the natural history of incidental meningiomas without exposure to progestin, which exhibit growth over time in more than 60% of cases[36, 45] and do not decrease. The absolute growth velocity we report here per meningioma is, however, 10 times lower than that previously found among progestin users (mean, 0.44 vs 5.8 mm³/day in [42]). This apparent discrepancy may be explained by the much smaller size of meningioma in our series.

Another strength of this study is that all patients underwent a 6-minute standardized protocol at screening and during MR follow-up. Gadolinium administration in the preparation room optimizes patient workflow and increases the sensitivity of the T2-FLAIR sequence for the detection of extra-axial lesions. Due to concerns about gadolinium deposition in the brain[46], the use of non-contrast MRI is often preferred. Although it could be appropriate for the follow-up of untreated meningioma[47], further studies are needed to assess whether a non-enhanced MR is sufficient for the detection of small-sized meningiomas.

All systematic screening exposes patients to the risk of unexpected incidental lesions. Their rate and type were within the range of other cohorts[39]. Among them, none was presumably linked to progestin. Although pituitary adenomas have been reported in transgender male-to-female exposed to CPA[22], in these cases CPA was coupled with estrogens, known to promote pituitary adenoma.

Our study has several limitations. First, it is a monocenter study with a limited sample size. However, patients were referred from multiple sources. The screened population is therefore likely representative of a wide range of progestin-exposed patients. Second, we chose to group patients according to the last progestin received. This practical approach was intended to limit the recall bias inherent in studies focused on hormonal treatments. This led to an underestimation of hormonal exposure in three patients with meningioma, as detailed in Table 2. Third, some patients referred by their practitioner, were not strictly targeted by the systematic MR screening, given that they had recently ceased treatment. Indeed, the pharmacovigilance alert undoubtedly raised the level of anxiety and of non-focal diffuse neurological complaints in patients exposed to progestin. This real-life experience might have lowered the rate of uncovered meningiomas. Fourth, patients were more frequently exposed to CPA than to CMA and NA, since the French health care recommendations for systematic screening initially focused on CPA, before being extended to NA and CMA[33, 34]. Fifth, all dural-based lesions on MRI with typical imaging features were considered as meningioma, without histopathological confirmation. However, in a previous study, all surgically removed dural-based lesions corresponded to meningiomas on histopathological analysis[29]. Sixth, the time course of meningiomas after treatment withdrawal should be interpreted with caution given that the initial kinetic was truncated in patients who ceased treatment before screening, and we cannot exclude that these meningiomas had already partially shrunk. Moreover, the follow-up duration was relatively short and some meningiomas will likely keep decreasing in size. At last, our observational study did not evaluate blood progestin activity nor the presence of estrogen and progesterone receptors on uncovered meningiomas. Indeed, previous pathological study reported that meningioma expressed progesterone receptors in more than two-thirds of the cases, supporting a causality between progestin intake and meningioma growth[4].

The relationship between blood progestin activity and expression of hormonal receptors in progestin-induced meningiomas may be of interest for future studies.

In conclusion, the high rate of meningioma reinforces the need for systematic MR screening, especially for patients exposed to CPA. From our real-life experience, meningiomas detected by the systematic screening program are mostly small, multiple, asymptomatic and susceptible to decrease after progestin cessation. The lower rate of meningiomas in patients exposed to NA and CMA calls for further studies to determine how to target patients most likely to benefit from the screening.

Accepted manuscript

References

1. Ostrom QT, Gittleman H, Truitt G, et al (2018) CBTRUS Statistical Report: Primary Brain and Other Central Nervous System Tumors Diagnosed in the United States in 2011–2015. *Neuro-Oncol* 20:iv1–iv86. <https://doi.org/10.1093/neuonc/noy131>
2. Wiemels J, Wrensch M, Claus EB (2010) Epidemiology and etiology of meningioma. *J Neurooncol* 99:307–314. <https://doi.org/10.1007/s11060-010-0386-3>
3. Baldi I, Engelhardt J, Bonnet C, et al (2018) Epidemiology of meningiomas. *Neurochirurgie* 64:5–14. <https://doi.org/10.1016/j.neuchi.2014.05.006>
4. Pravdenkova S, Husain M (2006) Progesterone and estrogen receptors: opposing prognostic indicators in meningiomas. *J Neurosurg* 105:163–173. <https://doi.org/doi:10.3171/jns.2006.105.2.163>
5. Neumann F (1986) Pharmacology of antiandrogens. *J Steroid Biochem* 25:885–895. [https://doi.org/doi:10.1016/0022-4731\(86\)90320-1](https://doi.org/doi:10.1016/0022-4731(86)90320-1)
6. Mueck AO, Sitruk-Ware R (2011) Norgestrel acetate, a novel progestogen for oral contraception. *Steroids* 76:531–539. <https://doi.org/10.1016/j.steroids.2011.02.002>
7. Druckmann R (2009) Profile of the progesterone derivative chlormadinone acetate — Pharmacodynamic properties and therapeutic applications. *Contraception* 79:272–281. <https://doi.org/10.1016/j.contraception.2008.10.017>
8. Catteau-Jonard S, Richard-Proust C (2012) Hyperandrogenism in Adolescent Girls. *Endocr Dev* 181–193
9. Gazzeri R, Galarza M, Gazzeri G (2007) Growth of a Meningioma in a Transsexual Patient after Estrogen–Progesterin Therapy. *N Engl J Med* 357:2411–2412. <https://doi.org/10.1056/NEJMc071938>

10. Shimizu J, Matsumoto M, Yamazaki E, Yasue M (2008) Spontaneous Regression of an Asymptomatic Meningioma Associated With Discontinuation of Progesterone Agonist Administration. *Neurol Med Chir (Tokyo)* 48:227–230. <https://doi.org/10.2176/nmc.48.227>
11. Gonçalves AMG, Page P, Domigo V, et al (2010) Abrupt Regression of a Meningioma after Discontinuation of Cyproterone Treatment: Fig 1. *Am J Neuroradiol* 31:1504–1505. <https://doi.org/10.3174/ajnr.A1978>
12. Gil M, Oliva B, Timoner J, et al (2011) Risk of meningioma among users of high doses of cyproterone acetate as compared with the general population: evidence from a population-based cohort study: Risk of meningioma among users of high doses of cyproterone acetate. *Br J Clin Pharmacol* 72:965–968. <https://doi.org/10.1111/j.1365-2125.2011.04031.x>
13. Cea-Soriano L, Blenk T, Wallander M-A, Rodríguez LAG (2012) Hormonal therapies and meningioma: Is there a link? *Cancer Epidemiol* 36:198–205. <https://doi.org/10.1016/j.canep.2011.08.003>
14. Knight EJ, McDonald MJ (2013) Recurrence and Progression of Meningioma in Male-to-Female Transgender Individuals During Exogenous Hormone Use. *Int J Transgenderism* 14:18–23. <https://doi.org/10.1080/15532739.2012.725563>
15. Bergoglio MT, Gómez-Balaguer M, Almonacid Folch E, et al (2013) Symptomatic meningioma induced by cross-sex hormone treatment in a male-to-female transsexual. *Endocrinol Nutr* 60:264–267. <https://doi.org/10.1016/j.endonu.2012.07.004>
16. Razavi HB (2014) Meningioma: The Unusual Growth in a Transsexual Patient after Estrogen-Progesterone Therapy. *SOJ Neurol* 1:1–3. <https://doi.org/10.15226/2374-6858/1/2/00109>
17. Papadopoulou S, Chambre C, Baudry C, et al (2015) Une complication rare de l'acétate de cyprotérone chez une patiente acromégale. *Ann Endocrinol* 76:388–389.

<https://doi.org/10.1016/j.ando.2015.07.276>

18. Supartoto A, Mahayana IT, Christine RN (2016) Exposure to Exogenous Female Sex Hormones is Associated with Increased Risk of Orbito-Cranial Meningioma in Females: A Case-Control Study. *Int J Ophthalmic Pathol* 5:1–6. <https://doi.org/10.4172/2324-8599.1000183>
19. Bernat A, Bonnin S, Labidi M, et al (2018) Regression of giant olfactory groove meningioma and complete visual acuity recovery after discontinuation of cyproterone acetate. *J Ophthalmic Vis Res* 13:355. https://doi.org/10.4103/jovr.jovr_21_17
20. Boer M, Moernaut L, Van Calenbergh F, et al (2018) Variation of meningioma in response to cyproterone acetate in a trans woman. *Int J Transgenderism* 19:92–94. <https://doi.org/10.1080/15532739.2017.1413615>
21. Mancini I, Rotilio A, Coati I, et al (2018) Presentation of a meningioma in a transwoman after nine years of cyproterone acetate and estradiol intake: case report and literature review. *Gynecol Endocrinol* 34:456–459. <https://doi.org/10.1080/09513590.2017.1395839>
22. Nota NM, Wiepjes CM, de Blok CJM, et al (2018) The occurrence of benign brain tumours in transgender individuals during cross-sex hormone treatment. *Brain* 141:2047–2054. <https://doi.org/10.1093/brain/awy108>
23. Roux A, Tauziède-Espariat A, Zanello M, et al (2020) Symptomatic progestin-associated atypical grade II meningioma. A first case report. *Neurochirurgie* 66:174–178. <https://doi.org/10.1016/j.neuchi.2019.12.013>
24. Froelich S, Dali-Youcef N, Boyer P, et al (2008) Does cyproterone acetate promote multiple meningiomas? *Endocr Abstr* 158–161
25. Botella C, Coll G, Lemaire J-J, Irthum B (2015) Méningiomes intracrâniens et utilisation prolongée d'acétate de cyprotérone à dose conventionnelle chez la femme : à propos de deux cas de régression tumorale après arrêt du traitement. *Neurochirurgie* 61:339–342.

<https://doi.org/10.1016/j.neuchi.2015.05.002>

26. Kalamarides M, Peyre M (2017) Dramatic Shrinkage with Reduced Vascularization of Large Meningiomas After Cessation of Progestin Treatment. *World Neurosurg* 101:814.e7-814.e10. <https://doi.org/10.1016/j.wneu.2017.03.013>
27. Champagne P-O, Passeri T, Froelich S (2019) Combined hormonal influence of cyproterone acetate and nomegestrol acetate on meningioma: a case report. *Acta Neurochir (Wien)* 161:589–592. <https://doi.org/10.1007/s00701-018-03782-4>
28. Passeri T, Champagne P-O, Bernat A-L, et al (2019) Spontaneous regression of meningiomas after interruption of nomegestrol acetate: a series of three patients. *Acta Neurochir (Wien)* 161:761–765. <https://doi.org/10.1007/s00701-019-03848-x>
29. Malaize H, Samoyeau T, Zanella M, et al (2021) Evolution of the neurosurgical management of progestin-associated meningiomas: a 23-year single-center experience. *J Neurooncol* 152:279–288. <https://doi.org/10.1007/s11060-021-03696-9>
30. Weill A, Nguyen P, Labidi M, et al (2021) Use of high dose cyproterone acetate and risk of intracranial meningioma in women: cohort study. *Br Med J* 37:1–13. <https://doi.org/10.1136/bmj.n37>
31. Hoisnard L, Laanani M, Passeri T, et al (2022) Risk of intracranial meningioma with three potent progestogens: A population-based case–control study. *Eur J Neurol* ene.15423. <https://doi.org/10.1111/ene.15423>
32. Lee KS, Zhang JJY, Kirollos R, et al (2022) A systematic review and meta-analysis of the association between cyproterone acetate and intracranial meningiomas. *Sci Rep* 12:1942. <https://doi.org/10.1038/s41598-022-05773-z>
33. ANSM (2018) CSST « Acetate de cyproterone et risque de meningiomes ». In: <https://ansm.sante.fr/>. <https://ansm.sante.fr/actualites/androcur-et-generiques-acetate-de->

cyproterone-50-mg-et-100-mg-et-risque-de-meningiome-lansm-publie-des-recommandations-pour-la-prise-en-charge-des-patients

34. ANSM (2020) CSST « Macroprogestatifs et risque de méningiomes ». In: <https://ansm.sante.fr/>. <https://ansm.sante.fr/evenements/comite-macroprogestatifs-et-risque-de-meningiome>
35. Huang RY, Bi WL, Griffith B, et al (2019) Imaging and diagnostic advances for intracranial meningiomas. *Neuro-Oncol* 21:i44–i61. <https://doi.org/10.1093/neuonc/noy143>
36. Hashiba T, Suzuki T, Kato A (2009) Serial volumetric assessment of the natural history and growth pattern of incidentally discovered meningiomas. *J Neurosurg* 110:675–684. <https://doi.org/doi:10.3171/2008.8.JNS08481>
37. Nakasu S, Hirano A, Shimura T, Llena JF (1987) Incidental meningiomas in autopsy study. *Surg Neurol* 27:319–322. [https://doi.org/10.1016/0090-3019\(87\)90005-X](https://doi.org/10.1016/0090-3019(87)90005-X)
38. Håberg AK, Hammer TA, Kvistad KA, et al (2016) Incidental Intracranial Findings and Their Clinical Impact; The HUNT MRI Study in a General Population of 1006 Participants between 50-66 Years. *PLOS ONE* 11:1–20. <https://doi.org/10.1371/journal.pone.0151080>
39. Vernooij MW (2007) Incidental Findings on Brain MRI in the General Population. *N Engl J Med* 1821–1828. <https://doi.org/DOI:10.1056/NEJMoa070972>
40. Nahser HC, Grote W, Löhr E, Gerhard L (1981) Multiple meningiomas. Clinical and computed tomographic observations. *Neuroradiology* 21:259–263. <https://doi.org/10.1007/BF02100156>
41. Lusins JO, Nakagawa H (1981) Multiple Meningiomas Evaluated by Computed Tomography. *Neurosurgery* 9:137–141. <https://doi.org/10.1227/00006123-198108000-00004>
42. Voormolen EHJ, Champagne PO, Roca E, et al (2021) Intracranial Meningiomas Decrease in Volume on Magnetic Resonance Imaging After Discontinuing Progestin.

Neurosurgery 89:308–314. <https://doi.org/10.1093/neuros/nyab175>

43. Peyre M, Gaillard S, de Marcellus C, et al (2018) Progesterin-associated shift of meningioma mutational landscape. *Ann Oncol* 29:681–686.

<https://doi.org/10.1093/annonc/mdx763>

44. Champeaux-Depond C, Weller J, Froelich S, Sartor A (2021) Cyproterone acetate and meningioma: a nationwide-wide population based study. *J Neurooncol* 151:331–338.

<https://doi.org/10.1007/s11060-020-03672-9>

45. Behbahani M, Skeie GO, Eide GE, et al (2019) A prospective study of the natural history of incidental meningioma—Hold your horses! *Neuro-Oncol Pract* 6:438–450.

<https://doi.org/10.1093/nop/npz011>

46. McDonald RJ, Levine D, Weinreb J, et al (2018) Gadolinium Retention: A Research Roadmap from the 2018 NIH/ACR/RSNA Workshop on Gadolinium Chelates. *Radiology* 289:517–534. <https://doi.org/10.1148/radiol.2018181151>

47. Boto J, Guatta R, Fitsiori A, et al (2021) Is Contrast Medium Really Needed for Follow-up MRI of Untreated Intracranial Meningiomas? *Am J Neuroradiol* 42:1421–1428.

<https://doi.org/10.3174/ajnr.A7170>

Statements and declarations

Funding

The authors declare that no funds, grants, or other support were received during the preparation of this manuscript.

Competing Interests

The authors have no relevant financial or non-financial interests to disclose.

Author Contributions

All authors contributed to the study conception and design. Study design was established in collaboration of Catherine Oppenheim, Johan Pallud, and Joseph Benzakoun. Material preparation, data collection and analysis were performed by Thomas Samoyeau, Joseph Benzakoun and Catherine Oppenheim. The first draft of the manuscript was written by Thomas Samoyeau and all authors critically revised the manuscript. All authors read and approved the final manuscript.

Data Availability

The datasets generated during and/or analyzed during the current study are available from the corresponding author on reasonable request.

Ethics approval

In accordance with French legislation, formal approval by an Ethics Committee was not required and commitment to compliance rules was fulfilled in respect to the General Data Protection Regulation (reference TDCP-GEST-16, University of Paris).