



HAL
open science

Unravelling a case of 46,XY DSD due to 17 β -Hydroxysteroid Dehydrogenase type 3 mutations at the age of 49

Aubin Garcia, Marie Legendre, Sandra Chantot-Bastaraud, Jean Pierre Siffroi, Sophie Christin-Maitre

► To cite this version:

Aubin Garcia, Marie Legendre, Sandra Chantot-Bastaraud, Jean Pierre Siffroi, Sophie Christin-Maitre. Unravelling a case of 46,XY DSD due to 17 β -Hydroxysteroid Dehydrogenase type 3 mutations at the age of 49. *Annales d'Endocrinologie = Annals of Endocrinology*, 2022, pp.S0003-4266(22)00005-1. <10.1016/j.ando.2022.01.003>. <inserm-03798449>

HAL Id: inserm-03798449

<https://inserm.hal.science/inserm-03798449v1>

Submitted on 20 Feb 2023

HAL is a multi-disciplinary open access archive for the deposit and dissemination of scientific research documents, whether they are published or not. The documents may come from teaching and research institutions in France or abroad, or from public or private research centers.

L'archive ouverte pluridisciplinaire HAL, est destinée au dépôt et à la diffusion de documents scientifiques de niveau recherche, publiés ou non, émanant des établissements d'enseignement et de recherche français ou étrangers, des laboratoires publics ou privés.



HAL Authorization



Available online at
ScienceDirect
www.sciencedirect.com

Elsevier Masson France
EM|consulte
www.em-consulte.com/en



Original article

Unraveling a case of 46,XY DSD due to 17 β -Hydroxysteroid Dehydrogenase type 3 mutations at the age of 49

Un cas complexe de DSD 46,XY dû à des mutations de la 17 β -Hydroxystéroïde Déshydrogénase de type 3 à l'âge de 49 ans

Aubin Garcia^{a,*}, Marie Legendre^{b,c}, Sandra Chantot-Bastarud^{c,d}, Jean-Pierre Siffroi^{c,d},
Sophie Christin-Maitre^{a,c}

^a Service d'endocrinologie diabétologie et médecine de la reproduction, centre constitutif des maladies endocriniennes rares de la croissance, hôpital Saint-Antoine, AP-HP, 75012 Paris, France

^b U.F. de génétique moléculaire, département de génétique médicale, Sorbonne Université, hôpital Trousseau, AP-HP, Paris, France

^c Inserm, Childhood genetic disorders, UMRS 933, Sorbonne Université, hôpital Trousseau, 75012 Paris, France

^d U.F. de génétique chromosomique, département de génétique médicale, Sorbonne Université, hôpital Trousseau, AP-HP, Paris, France

ARTICLE INFO

Keywords:

46,XY DSD
Difference of sexual development
Variation of sexual development
17- β Hydroxysteroid Dehydrogenase type 3
Primary amenorrhea

Mots clés :

46,XY DSD
Différence du développement sexuel
Variations du développement génital
17- β hydroxystéroïde déshydrogénase de type 3
Aménorrhée primaire

ABSTRACT

17- β Hydroxysteroid dehydrogenase type 3 (17 β -HSD3) is an enzyme transforming Delta 4 androstenedione into testosterone. It is involved in the early development of the male genital tract. In this case report, we describe a 46,XY Difference of Sexual Development (DSD) individual with a female phenotype, primary amenorrhea, facial dysmorphism and mental retardation. Gene sequencing using a panel of genes involved in DSD revealed two heterozygous loss-of-function mutations in the HSD17B3 enzyme. Furthermore, a microarray analysis revealed a 37Mb segmental 3p duplication and a recurrent 16p13.11 microduplication. The large 3p duplication is responsible for her mental retardation and her facial dysmorphism. Interestingly, HSD17B3 mutations were identified only in adulthood, at the age of 49. Furthermore, the patient's severe mental retardation and facial dysmorphism are due to genetic abnormalities different from the ones involved in her DSD.

© 2022 Elsevier Masson SAS. All rights reserved.

R É S U M É

La 17- β Hydroxystéroïde déshydrogénase de type 3 (17 β -HSD3) est une enzyme transformant la Delta 4-androsténone en testostérone. Elle est impliquée dans le développement précoce de l'appareil génital masculin. Dans cet article, nous rapportons le cas d'un individu 46,XY présentant une Variation du développement sexuel/génital (VDG) avec un phénotype féminin, une aménorrhée primaire, une dysmorphie faciale et un retard mental. Le séquençage utilisant un panel de gènes impliqués dans les VDG a mis en évidence deux mutations hétérozygotes avec perte de fonction de l'enzyme issue du gène HSD17B3. Dans un deuxième temps, une analyse par puce à ADN a révélé une duplication 3p segmentaire de 37Mb et une microduplication récurrente 16p13.11. La grande duplication 3p est responsable du retard mental et de la dysmorphie faciale. Il est intéressant de noter que les mutations de HSD17B3 n'ont été identifiées qu'à l'âge adulte, à 49 ans. De plus, le retard mental sévère et la dysmorphie de la patiente sont liées à d'autres anomalies génétiques que celles impliquées dans les VDG.

© 2022 Elsevier Masson SAS. Tous droits réservés.

1. Introduction

Male sex determination notably relies on the presence of the SRY gene located on the short arm of the Y chromosome [1]. It is involved in the transformation of the undifferentiated gonads into

* Corresponding author.

E-mail addresses: aubin.garcia@aphp.fr (A. Garcia), marie.legendre@aphp.fr (M. Legendre), sandra.chantot-bastarud@aphp.fr (S. Chantot-Bastarud), jean-pierre.siffroi@aphp.fr (J.-P. Siffroi).

<https://doi.org/10.1016/j.ando.2022.01.003>

0003-4266/© 2022 Elsevier Masson SAS. All rights reserved.

Table 1
Hormonal investigations in the patient.

Hormonal values	Normal female adult values	31-years-old	33-years-old	49-years-old
FSH (IU/L)		46	37	35.8
LH (IU/L)		5	5.6	20.5
Estradiol (pmol/L)	73–440	47.7	25.7	195
Androstenedione (nmol/L)	0.50–1.50		1.01	1.82
Testosterone (nmol/L)	0.30–1.70		0.87	0.52
17 hydroxyprogesterone (nmol/L)	0.10–0.90			0.55
SDHEA (μ mol/L)	2–13			4.43

testis, which produces two major hormones: anti-Müllerian hormone (AMH) and testosterone. AMH induces the regression of the Müllerian ducts and testosterone allows the development of the male genital tract [2]. An international classification is currently used in order to characterize Differences of Sexual development (DSD) [3]. It includes sex chromosome DSD, 46,XY DSD and 46,XX DSD. 46,XY DSD include disorders of gonadal (testicular) development and anomalies in androgen synthesis and/or action. Some 46,XY individuals having a full Y sex chromosome including the SRY gene, may present with a female phenotype [4]. The most well-known causes of this type of DSD are loss-of-function mutations in the androgen receptor, leading to complete androgen insensitivity syndrome (CAIS) [5]. Its prevalence is approximately 1:20,000 births. Less frequently, loss-of-function mutations in the 5 α -reductase have been reported [6]. This enzyme transforms testosterone into dihydrotestosterone. Other causes are exceptional. In the literature, few cases of 17 β -Hydroxysteroid Dehydrogenase type 3 (17 β -HSD3) loss-of-function mutations have been reported [7]. We report the exceptional case of a patient with a 46,XY DSD due to a complete loss of function of 17 β -HSD3 enzyme. Furthermore, this patient had associated genetic abnormalities with a partial trisomy of chromosome 3 and a recurrent 16p13.11 microduplication.

2. Case report

Our patient was born from non-consanguineous Caucasian parents. In her family history, two brothers died respectively at the age of 4 months and 2 days of life, both from heart malformations. At birth, the patient presented with a female phenotype but abnormal genitalia were observed with a clitoris enlargement, a blind vaginal cavity and gonads palpated at the inguinal level. In addition, she had a facial dysmorphism including a large mouth, a small chin and protruding frontal bumps. Her karyotype, performed on day 2 of life was XY and it revealed an abnormal chromosome 3 with a large short arm. Gonadal biopsies performed at one year of life revealed normal testicular tissue. A bilateral gonadectomy was performed at the age of two years. The patient was lost to follow-up during childhood.

At the age of 31, she was referred for the first time to our Endocrinology Department by her attending physician. The patient had an intellectual deficit with aphasia and abnormal movements. She lived in an institution and was under guardianship. Clinically, her height was 175 cm with a body mass index (BMI) of 17 kg/m². Breast development was graded S1 according to Prader stages. She had very poor axillary and pubic hair. A breast ultrasound revealed a fibroglandular frame of dystrophic tissue located predominantly in the retro-mammary region without any identifiable breast tissue. An absence of gonads was checked by ultrasound. Those findings were confirmed by a pelvic scanner and a pelvic magnetic resonance imaging (MRI). Given her familial history, electrocardiogram and a cardiac ultrasound were performed. They were normal.

The patient's hormonal evaluation is presented in Table 1. At the age of 31, estradiol level was low and her gonadotropins were elevated. Due to her low E2 level, hormone replacement therapy

(HRT) including estrogens and progestins was initially given with a second generation contraceptive pill containing 30 micrograms of ethinylestradiol and levonorgestrel (Adepal®). After 2 years, this treatment was switched to transdermal 17 beta-estradiol (2 pulses per day) associated with natural oral progesterone, 10 days per month. The patient was then lost to follow-up until 49-year-old when she was referred to the Center of Rare Endocrine Diseases of Growth and Development (CMERC: *Centre des maladies endocriniennes rares et de la croissance et du développement*), located in the Endocrinology department of Saint Antoine Hospital (Paris). Her BMI was 17 kg/m². Her spinal bone densitometry found a T-score of -5 SD. Unfortunately, the patient died few months later, at the age of 51 years of an unknown etiology.

2.1. Genetic analyses

At the age of 49 years, after authorization from the patient's guardian and the guardianship judge, DNA was extracted from peripheral blood leucocytes on a QiaSymphony (Qiagen) automate.

In order to investigate the abnormal sexual phenotype of our patient, a panel of genes involved in DSD were sequenced by Next Generation Sequencing (NGS) in Trousseau Hospital, AP-HP, Paris. It uses a custom targeted-capture panel (SeqCap EZ Choice, Roche Diagnostics, Hg19) that encompasses 32 genes implicated in DSD (*AMH, AMHR2, AR, ARX, ATRX, CBX2, CYP17A1, DHH, DMRT1, DMRT2, EMX2, FGF9, FGFR2, FOXL2, GATA4, HSD17B3, INSL3, LHCGR, MAMLD1, MAP3K1, NR0B1, NR5A1, RSP01, RXFP2, SOX10, SOX8, SOX9, SRD5A2, SRY, WNT4, WT1, ZFPM2*). The library was prepared following the manufacturer's instructions and sequenced on a MiSeq sequencing platform (Illumina). Data were analyzed through an in-house double pipeline based on Bowtie2 and BWA tools [8]. Reads were visualized with the IGV viewer (Broad Institute). Copy number variation analysis was performed with a depth-ratio comparison between subjects sequenced in the same run. The patient was also genotyped using HumanOmniExpress-24 microarrays (Illumina, San Diego, CA, USA). Automated Illumina microarray experiments were performed according to the manufacturer's instructions. Images were acquired using an iScan System (Illumina). Image analysis and automated CNV calling were performed using GenomeStudio v.2.0 and CNV Partition v.3.1.6. SNP profiles were analysed by examination of signal intensity (Log R ratio, i.e. ln (sample copy number/reference copy number)) and allelic composition (BAF, i.e. B Allele Frequency).

Using NGS, two heterozygous mutations have been identified in the *HSD17B3* gene (NM.000197.2): c.277+4A>T or p.? and c.645A>T or p.(Glu215Asp) (Fig. 1). Microarrays analysis identified an interlayer heterozygous duplication of the 3p26.2 band to the 3p22.1 band of the short arm of chromosome 3 of around 37Mb (Fig. 2). This band involves 153 genes referenced in the OMIM database (genomic coordinates: chr3:3158485-39924901, GRCh37/hg19 (Feb. 2009)). It does not encompass any gene implicated in differences of sexual development. Furthermore, SNP array identified a 1.2Mb recurrent duplication at 16p13.11 (genomic coordinates: chr16:15129940-16363239, GRCh37/hg19 (Feb. 2009)) involving 8 OMIM referenced gene including *MYH11*

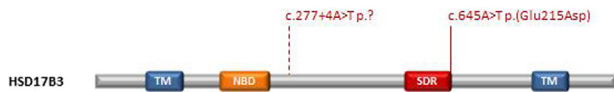

Fig. 1. Location of the mutations in the 17 β -HSD3 protein. Dashed line shows intron 3 c.277+4A>T splice mutation that probably lead to nonsense-mediated mRNA decay and lower/absence of protein production. Domain prediction based on SMART, Uniprot and InterPro tools. TM: transmembrane domain; NBD: NADP binding domain; SDR: short-chain dehydrogenase/reductase domain.

gene. Unfortunately, metaphase chromosomes were no more available for Fluorescent in situ analysis of the 3p duplicated segment. A genetic analysis of the parents is not available as the patient's father was deceased and the mother declined any genetic analysis.

3. Discussion

We report a complex case of a 46,XY DSD with a large segmental duplication of chromosome 3, a recurrent 16p13.11 duplication, and two heterozygous loss-of-function mutations in *HSD17B3*, identified at the age of 49.

17 β -Hydroxysteroid dehydrogenase type 3 is a 310 amino acid enzyme allowing the transformation of delta-4 androstenedione into testosterone, preferentially using NADPH co-factor. It is mainly expressed in the testis [7]. The gene encoding this protein is located in chromosome 9q22 and contains 11 exons. The 17 β -hydroxysteroid dehydrogenase type 3 protein was first described by Saez et al. [7]. Loss of function of the enzyme leads to decreased serum testosterone level and elevated delta 4-androstenedione level. In some cases, after stimulation with hCG, a testosterone/delta 4-androstenedione ratio below 0.8 has been reported [9]. The incidence of 17 β -hydroxysteroid dehydrogenase type 3 deficit is extremely low, reaching from 1/147,000 births [10]. It is more frequent in patients from North of Africa. Its main differential diagnosis are complete androgen insensitivity syndrome and 5 alpha reductase deficiency [5].

In most cases, a deficit in 17 β -HSD3 is revealed in neonates in front of a female phenotype, fusion of labia majora, blind vagina and clitoridomegaly [11]. Rare cases of microphallus associated to hypospadias have been described. In such patients, Müller's structures are absent due to the secretion of AMH for the foetal testis. Internal genital organs are phenotypically male with epididymis, vas deferens and seminal vesicles. The gonads are often located in the inguinal region. Few histological studies have reported the presence of Leydig and Sertoli cells in the testicular tissue, in the absence of germ cells [12]. Some cases have been diagnosed at puberty with primary amenorrhea. Furthermore, cases of progressive virilization during adolescence have been reported [10]. During this period, androstenedione levels increase and CYP 19 in peripheral tissues aromatizes androstenedione into testosterone, inducing patients' virilization. 17 β -HSD3 is not only expressed in the gonads but also in peripheral tissues, such as adipose tissue, brain, bone marrow and sebaceous glands [11]. Finally, testosterone can also be partially synthesized by the testis, as another isoform of 17 β -HSD called 17 β -HSD type 5 is expressed in Leydig cells [11]. There is a wide

range of phenotypic features of 17 β -HSD3 deficiency with variable hormonal profiles. There are no genotype phenotype correlation but in null mutation, testes are with normal architecture, there is an atrophy of the deferens, no uterus and a female phenotype. At puberty, there is a virilization due to the other HSD17 [13]. To our knowledge, no case of DSD involving 17 β -HSD3 mutations has been reported in adults at such an advanced age (49-years-old).

Clinically, our patient did not present signs of virilization during adolescence as she had bilateral gonadectomy at the age of 2 years. Unfortunately, hormonal evaluations at birth and during infancy are not available. Furthermore, an hCG test was not available. Her serum estradiol level measured at the age of 49 was normal reaching 195 pmol/L, as she was taking HRT. However, the patient had severe osteoporosis. It is probably related to her past gonadectomy as well as her HRT poor compliance, as she had severe mental retardation. Nowadays, a gonadectomy would be discussed in a multidisciplinary meeting and potentially delayed. In the discussion, one should take into account the fact that there are virilization at puberty and that female to male gender changes generally occur in late adolescence to early adulthood.

Concerning her genetic evaluation, the splice mutation c.277+4A>T or p.? has been described in few cases of gonadal dysgenesis [10]. When present in a homozygous state, this mutation leads to a complete loss of enzyme function [14]. It is rare in control populations (94 out of 282,304 control alleles in gnomAD). It alters the donor splice site of intron 3 (MaxEntScan score: 5.93 vs. 11.11 for the usual site; SpliceAI score: 66% probability to alter intron 3 splicing) which probably causes a decrease in protein production through nonsense-mediated mRNA decay or the production of a non-functional truncated protein. Functional studies have not been performed but this mutation is highly suspected to be deleterious on prediction software and previous reported cases [7,15]. The second mutation of our patient, c.645A>T or p.(Glu215Asp) is a pathogenic missense mutation. It has previously been described [9,16–18] and is rare in the gnomAD control populations (14 out of 282,866 alleles). It has no predicted effect on splicing (MaxEntScan, SpliceAI). It targets an amino acid that is highly conserved in vertebrates (UCSC 100 vertebrate's alignment) and is located within the catalytic domain of the enzyme. *In vitro* functional assessment showed a loss of enzymatic activity [7]. Therefore, the two *HSD17B3* mutations identified in our patient induce a total loss of function and therefore explain her DSD.

In addition, our patient presented a partial duplication of chromosome 3p. To our knowledge, large exclusive duplications localized exclusively in the segments 3p26.2p22.1 have never been reported. Few cases of partial trisomy 3p syndrome have been described, with variable phenotypes including craniofacial dysmorphism (hypertelorism, telecanthus, large nose) associated with psychomotor delay, moderate to severe intellectual disability, cardiac, genitourinary, gastrointestinal, skeletal and brain anomalies [19,20]. However, most cases are not fully characterized with High-resolution molecular cytogenetic techniques such as microarray hybridization. Our patient's duplication arose probably *de novo* but the hypothesis of an unbalanced transmission of a parental insertion cannot be ruled out. In our patient, facial dysmorphism is

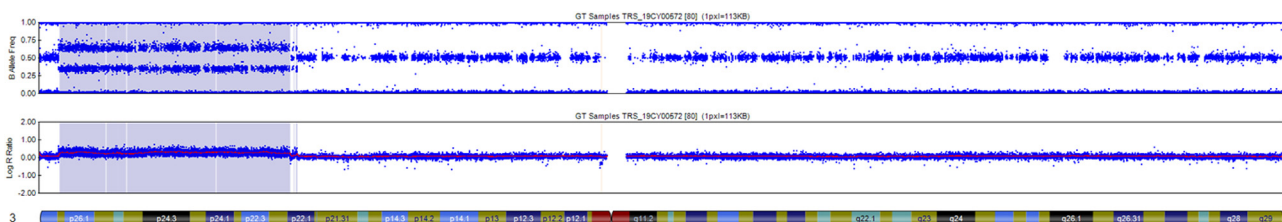


Fig. 2. SNP array profile of patient's chromosome 3. The 3p segmental duplication is highlighted in blue.

probably due to the duplication of chromosome 3 and is not related to her DSD.

Finally, recurrent 16p13.1 duplications have also been associated with mental retardation. In some cases, an autistic spectrum has been reported. The expression of this genetic defect is variable according to its degree of penetrance [21]. Some cases of cardiac malformations have been reported in patients carrying such a duplication. As both her brothers died early in their life, one can make the hypothesis that they had cardiac malformation. However, this duplication is still considered a susceptibility factor for neurodevelopmental disorders. Its involvement in our patient's phenotype of mental retardation is certainly minor compared to the large 3p duplication. A genetic study of the parents would have been interesting to better understand the respective pathogenicity of those abnormalities.

4. Conclusion

To our knowledge, we report the first case of *HSD17B3* mutations in a 46,XY DSD adult patient, carrying a complex karyotype, associating a partial trisomy of chromosome 3 and an interstitial duplication of chromosome 16. The etiology of this 46,XY DSD was identified only at the age of 49. The patient's several different genetic abnormalities explain her complex phenotype including 46 XY DSD, facial dysmorphism as well as severe mental retardation. Interestingly, thorough genetic evaluations have shown that her facial dysmorphism and her severe mental retardation are not related to 17 β -HSD3 mutations. This case report illustrates the added value of performing CGH array as well as NGS. Nowadays, thanks to hormonal evaluation by LC/MS-MS and Next generation sequencing of genes involved in DSD, the diagnosis would be made during infancy. A genetic diagnosis identifying *HSD17B3* loss-of-function performed during infancy or at puberty would improve the patient's care.

Credit author statement

Aubin Garcia: writing original draft.
Marie Legendre: writing original draft.
Sandra Chantot-Bastaraut: writing original draft.
Jean Pierre Siffroi: writing original draft.
Sophie Christin-Maitre: conceptualization, writing, validation, supervision.

Human and animal rights

Not applicable.

Informed consent and patient details

The authors declare that this report does not contain any personal information that could lead to the identification of the patient(s).

Not applicable.

Disclosure of interest

The authors declare that they have no competing interest.

Funding

This work did not receive any grant from funding agencies in the public, commercial, or not-for-profit sectors.

Author contributions

All authors attest that they meet the current International Committee of Medical Journal Editors (ICMJE) criteria for Authorship.

Appendix A. Supplementary data

Supplementary data associated with this article can be found, in the online version, at <https://doi.org/10.1016/j.ando.2022.01.003>.

References

- [1] Nef S, Stevant I, Greenfield A. Characterizing the bipotential mammalian gonad. *Curr Top Dev Biol* 2019;134:167–94, <http://dx.doi.org/10.1016/bs.ctdb.2019.01.002>.
- [2] Josso N. Women in reproductive science: anti-Müllerian hormone: a look back and ahead. *Reproduction* 2019;158:F81–9, <http://dx.doi.org/10.1530/REP-18-0602>.
- [3] Lee PA, Houk CP, Ahmed SF, Hughes IA. International Consensus Conference on Intersex organized by the Lawson Wilkins Pediatric Endocrine Society and the European Society for Paediatric Endocrinology. Consensus statement on management of intersex disorders. *International Consensus Conference on Intersex. Pediatrics* 2006;118:e488–500, <http://dx.doi.org/10.1542/peds.2006-0738>.
- [4] Bertelloni S, Tyutyusheva N, Valiani M, D'Alberton F, Baldinotti F, Caligo MA, et al. Disorders/differences of sex development presenting in the newborn with 46,XY Karyotype. *Front Pediatr* 2021;9:627281, <http://dx.doi.org/10.3389/fped.2021.627281>.
- [5] Hughes IA, Davies JD, Bunch TI, Pasterski V, Mastroiannopoulou K, MacDougall J. Androgen insensitivity syndrome. *Lancet* 2012;380:1419–28, [http://dx.doi.org/10.1016/S0140-6736\(12\)60071-3](http://dx.doi.org/10.1016/S0140-6736(12)60071-3).
- [6] Mendonca BB, Batista RL, Domenice S, Costa EM, Arnhold IJ, Russell DW, et al. Steroid 5 α -reductase 2 deficiency. *J Steroid Biochem Mol Biol* 2016;163:206–11, <http://dx.doi.org/10.1016/j.jsbmb.2016.05.020>.
- [7] Boehmer AL, Brinkmann AO, Sandkuijl LA, Halley DJ, Niermeijer MF, Andersson S, et al. 17 β -hydroxysteroid dehydrogenase-3 deficiency: diagnosis, phenotypic variability, population genetics, and worldwide distribution of ancient and de novo mutations. *J Clin Endocrinol Metab* 1999;84:4713–21, <http://dx.doi.org/10.1210/jcem.84.12.6174>.
- [8] Jeanson L, Thomas L, Copin B, Coste A, Sermet-Gaudelus I, Dastot-Le Moal F, et al. Mutations in GAS8, a gene encoding a nexin-dynein regulatory complex subunit, cause primary ciliary dyskinesia with axonemal disorganization. *Hum Mutat* 2016;37:776–85, <http://dx.doi.org/10.1002/humu.23005>.
- [9] Faisal Ahmed S, Iqbal A, Hughes IA. The testosterone:androstenedione ratio in male undermasculinization. *Clin Endocrinol (Oxf)* 2000;53:697–702, <http://dx.doi.org/10.1046/j.1365-2265.2000.01166.x>.
- [10] Sullivan CA, Hoffman JD, Safer JD. 17- β -hydroxysteroid dehydrogenase type 3 deficiency: identifying a rare cause of 46, XY female phenotype in adulthood. *J Clin Transl Endocrinol Case Rep* 2018;7:5–7, <http://dx.doi.org/10.1016/j.jecr.2017.10.002>.
- [11] Lee YS, Kirk JM, Stanhope RG, Johnston DI, Harland S, Auchus RJ, et al. Phenotypic variability in 17 β -hydroxysteroid dehydrogenase-3 deficiency and diagnostic pitfalls. *Clin Endocrinol (Oxf)* 2007;67:20–8, <http://dx.doi.org/10.1111/j.1365-2265.2007.02829.x>.
- [12] Yang Z, Ye L, Wang W, Zhao Y, Wang W, Jia H, et al. 17 β -Hydroxysteroid dehydrogenase 3 deficiency: three case reports and a systematic review. *J Steroid Biochem Mol Biol* 2017;174:141–5, <http://dx.doi.org/10.1016/j.jsbmb.2017.08.012>.
- [13] George MM, New MI, Ten S, Sultan C, Bhangoo A. The clinical and molecular heterogeneity of 17 β HSD-3 enzyme deficiency. *Horm Res Paediatr* 2010;74:229–40, <http://dx.doi.org/10.1159/000318004>.
- [14] Hiort O, Marshall L, Birnbaum W, Wünsch L, Holterhus PM, Döhnert U, et al. Pubertal development in 17 β -hydroxysteroid dehydrogenase type 3 deficiency. *Horm Res Paediatr* 2017;87:354–8, <http://dx.doi.org/10.1159/000453613>.
- [15] Castro CC, Guaragna-Filho G, Calais FL, Coeli FB, Leal IR, Cavalcante-Junior EF, et al. Clinical and molecular spectrum of patients with 17 β -hydroxysteroid dehydrogenase type 3 (17- β -HSD3) deficiency. *Arq Bras Endocrinol Metabol* 2012;56:533–9, <http://dx.doi.org/10.1590/s0004-27302012000800012>.
- [16] Costa C, Castro-Correia C, Mira-Coelho A, Monteiro B, Monteiro J, Hughes I, et al. The dilemma of the gender assignment in a Portuguese adolescent with disorder of sex development due to 17 β -hydroxysteroid-dehydrogenase type 3 enzyme deficiency. *Endocrinol Diabetes Metab Case Rep* 2014;2014:140064, <http://dx.doi.org/10.1530/EDM-14-0064>.
- [17] Mendonca BB, Inacio M, Arnhold IJ, Costa EM, Bloise W, Martin RM, et al. Male pseudohermaphroditism due to 17 β -hydroxysteroid dehydrogenase 3 deficiency. Diagnosis, psychological evaluation, and management. *Medicine (Baltimore)* 2000;79:299–309, <http://dx.doi.org/10.1097/00005792-200009000-00003>.
- [18] Andersson S, Geissler WM, Wu L, Davis DL, Grumbach MM, New MI, et al. Molecular genetics and pathophysiology of 17 β -hydroxysteroid dehydrogenase 3 deficiency. *J Clin Endocrinol Metab* 1996;81:130–6, <http://dx.doi.org/10.1210/jcem.81.1.8550739>.

- [19] Natera-de Benito D, García-Pérez MA, Martínez-Granero MÁ, Izquierdo-López L. A patient with a duplication of chromosome 3p (p24.1p26.2): a comparison with other partial 3p trisomies. *Am J Med Genet A* 2014;164A:548–50, <http://dx.doi.org/10.1002/ajmg.a.36164>.
- [20] Reiss JA, Sheffield LJ, Sutherland GR. Partial trisomy 3p syndrome. *Clin Genet* 1986;30:50–8, <http://dx.doi.org/10.1111/j.1399-0004.1986.tb00568.x>.
- [21] Allach El Khattabi L, Heide S, Caberg JH, Andrieux J, Doco Fenzy M, Vincent-Delorme C, et al. 16p13.11 microduplication in 45 new patients: refined clinical significance and genotype-phenotype correlations. *J Med Genet* 2020;57:301–7, <http://dx.doi.org/10.1136/jmedgenet-2018-105389>.