

Supplemental data 1

Proband I, a 50-year-old female of French origin, presented with chronic recurrent urticaria since early infancy. The chronic rash was associated with fever, splenomegaly, adenopathy and arthralgia. No triggering factors were reported. Additionally, the patient had clubbing fingers and her life quality was largely affected by chronic asthenia. At the age of 28 she developed bilateral papilledema and sensorineural hearing loss. A monoclonal gammopathy of undetermined significance was detected (IgG kappa 26 g/L). Amyloidosis was not detected. Extensive autoimmune, hematological, malignant and infectious analyses were all negative. At the age of 40, the biological profile revealed the presence of chronically elevated CRP levels (190 mg/mL), SAA levels (378 mg/L), hyperleukocytosis (11.4 Giga/L with 85% neutrophils), anemia (hemoglobin 10,6 g/dL). The association of chronic urticaria and monoclonal gammopathy evoked Schnitzler syndrome but the whole phenotype is consistent with the diagnosis of MWS (**Table 1**).

Proband II, a 50-year-old female of French origin, presented with chronic recurrent non-pruritic urticarial skin rash since three months of life. The urticarial rash was associated with recurrent attacks of fever, diffuse arthralgia, polyarthritits, nausea and diarrhea. She also presented auxiliary lymphadenopathy, clubbing fingers, and microcytic anemia. During her clinical course, at the age of 30, she developed bilateral sensorineural hearing loss. No amyloidosis was reported. The biological profile showed elevated CRP levels (77 mg/L), SAA levels (300 mg/L) and low hemoglobin levels (9.7 g/dl). The clinical presentation of the patient is suggestive of MWS (**Table 1**).

Proband III, a four-year-old boy was born from a Tunisian non-consanguineous couple. Shortly after birth, he presented recurrent chronic non-pruritic urticarial skin rash. The lesions were migratory erythematous plaques with central swelling on a daily basis. The patient was noticed to have dysmorphic facial features including long philtrum and mild frontal bossing. At the age of 4 months, he had an episode of right orchitis and at age of 9 months a febrile attack with right hip pain. Later on, the patient developed chronic aseptic meningitis with lymphocytic infiltration. The clinical examination revealed the presence of generalized adenopathies. Ophthalmological examination revealed the presence of papilledema. At the age of 4, the audiogram was normal with no hearing loss. Extensive analysis including allergic tests, autoimmune markers and infectious profile were all negative. Skin biopsy showed very mild lymphocytic perivascular infiltration. The biological profile revealed

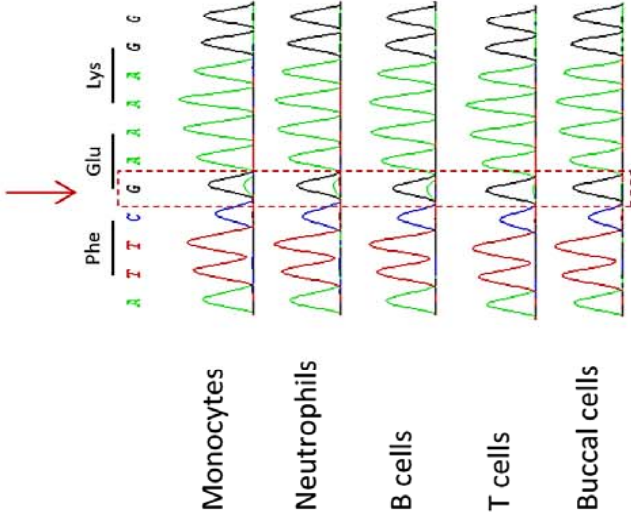
elevated levels of C-reactive protein and serum amyloid (51 mg/L and 128 mg/L, respectively) and polynuclear leukocytosis (16 Giga/L). The clinical presentation of the patient is suggestive of a CINCA syndrome (**Table 1**).

Efficacy of anti-IL1 treatment

Recombinant IL1 receptor antagonist treatment (Anakinra), the treatment of choice in NLRP3-AIDs, was started at the age of 40 in Proband I, but only after the NLRP3 molecular study in Probands II and III (50 and 4 years old respectively). As expected in case of NLRP3 inflammasome activation, all the patients showed a complete remission with this treatment.

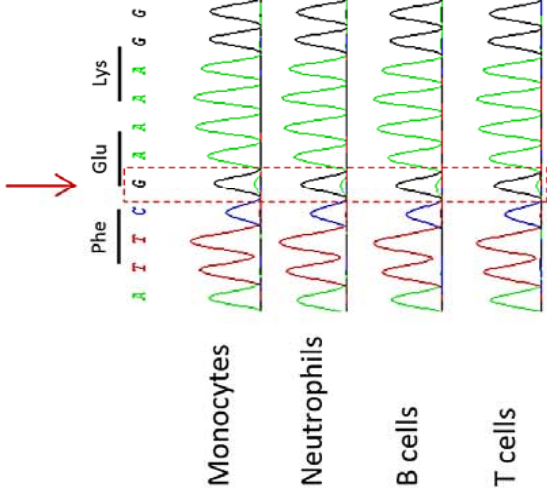
Proband I

c.1705G>A. p.(Glu569Lys)



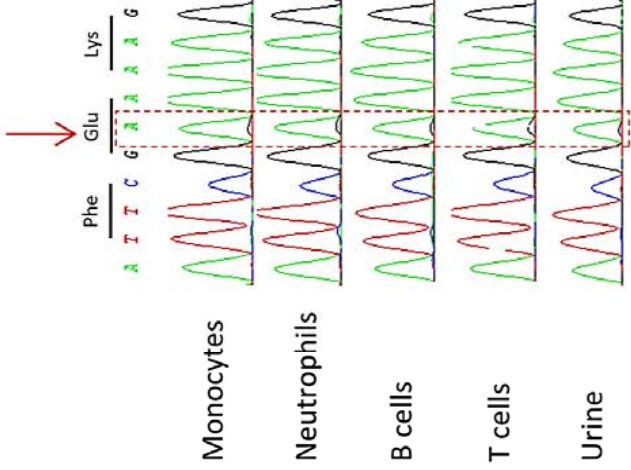
Proband II

c.1705G>A. p.(Glu569Lys)


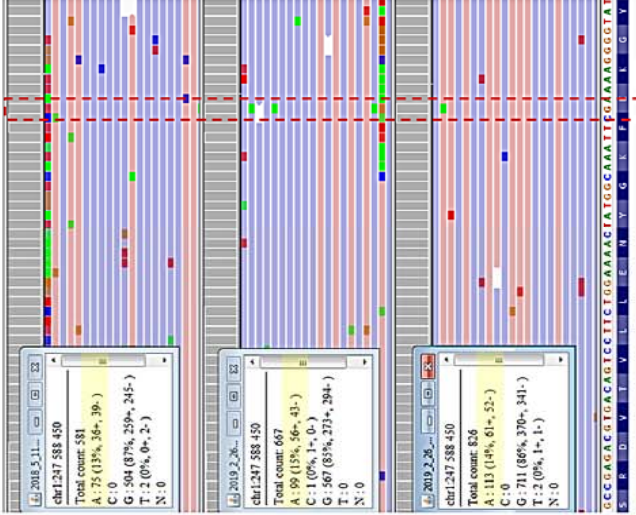
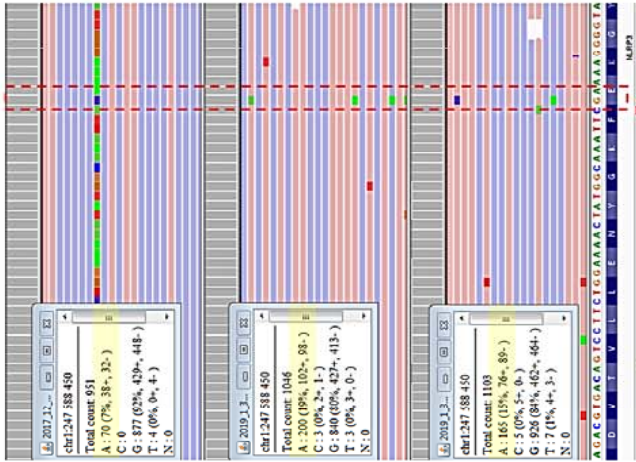


Proband III



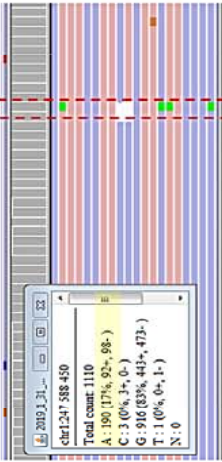
c.1706A>G. p.(Glu569Gly)



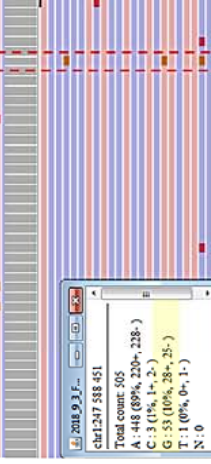
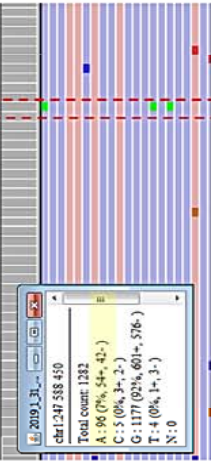
Peripheral blood



cells



cells



ccal cells

