



**HAL**  
open science

## Digestive perforations related to endoscopy procedures: a local management charter based on local evidence and experts' opinion

G. Bertrand, J. Rivory, M. Robert, J. C. Saurin, É Pelascini, O. Monneuse, L.  
Gruner, G. Poncet, P. J. Valette, H. Gimonet, et al.

### ► To cite this version:

G. Bertrand, J. Rivory, M. Robert, J. C. Saurin, É Pelascini, et al.. Digestive perforations related to endoscopy procedures: a local management charter based on local evidence and experts' opinion. *Endoscopy International Open*, 2022, 10 (4), pp.E328-E341. 10.1055/a-1783-8424 . inserm-03755199

**HAL Id: inserm-03755199**

**<https://inserm.hal.science/inserm-03755199>**

Submitted on 22 Aug 2022

**HAL** is a multi-disciplinary open access archive for the deposit and dissemination of scientific research documents, whether they are published or not. The documents may come from teaching and research institutions in France or abroad, or from public or private research centers.

L'archive ouverte pluridisciplinaire **HAL**, est destinée au dépôt et à la diffusion de documents scientifiques de niveau recherche, publiés ou non, émanant des établissements d'enseignement et de recherche français ou étrangers, des laboratoires publics ou privés.

# Digestive perforations related to endoscopy procedures: a local management charter based on local evidence and experts' opinion




## Authors

Gaspard Bertrand<sup>1</sup>, Jérôme Rivory<sup>1</sup>, Maud Robert<sup>2</sup>, Jean-Christophe Saurin<sup>1</sup>, Élise Pelascini<sup>2</sup>, Olivier Monneuse<sup>3</sup>, Laurent Gruner<sup>3</sup>, Gilles Poncet<sup>2</sup>, Pierre-Jean Valette<sup>4</sup>, Hélène Gimonet<sup>4</sup>, Florian Rostain<sup>1</sup>, Charles-Éric Ber<sup>5</sup>, Yves Bouffard<sup>5</sup>, André Boibieux<sup>6</sup>, Marina Ciochina<sup>1</sup>, Verena Landel<sup>7</sup>, Hélène Boyer<sup>7</sup>, Jérémie Jacques<sup>8</sup>, Thierry Ponchon<sup>1,8</sup>, Mathieu Pioche<sup>1</sup>

## Institutions

- Hospices Civils de Lyon, Hôpital Édouard Herriot, Service d'Hépatogastroentérologie, Lyon, France
- Hospices Civils de Lyon, Hôpital Édouard Herriot, Service de Chirurgie Digestive Hépatobiliaire, Lyon, France
- Hospices Civils de Lyon, Hôpital Édouard Herriot, Service de Chirurgie Digestive d'Urgence, Lyon, France
- Hospices Civils de Lyon, Hôpital Édouard Herriot, Service de Radiologie, Lyon France
- Hospices Civils de Lyon, Hôpital Édouard Herriot, Service d'Anesthésie, Section Endoscopie, Lyon, France
- Hospices Civils de Lyon, Hôpital Édouard Herriot, Service de Pathologies Infectieuses, Lyon, France
- Hospices Civils de Lyon, Direction de la Recherche Clinique et de l'Innovation, Lyon, France
- Hôpital Dupuytren, Service de Gastroentérologie, Limoges, France

submitted 18.3.2021

accepted after revision 28.10.2021

## Bibliography

Endosc Int Open 2022; 10: E328–E341

DOI 10.1055/a-1783-8424

ISSN 2364-3722

© 2022. The Author(s).

This is an open access article published by Thieme under the terms of the Creative Commons Attribution-NonDerivative-NonCommercial License, permitting copying and reproduction so long as the original work is given appropriate credit. Contents may not be used for commercial purposes, or adapted, remixed, transformed or built upon. (<https://creativecommons.org/licenses/by-nc-nd/4.0/>)


Georg Thieme Verlag KG, Rüdigerstraße 14,  
70469 Stuttgart, Germany

## Corresponding author

Mathieu Pioche, MD, PhD, Service de gastro-entérologie et d'endoscopie digestive, Pavillon L, Hôpital Edouard Herriot, 5 place d'Arsonval 69437 Lyon, France

Fax: +33472110147

[mathieu.pioche@chu-lyon.fr](mailto:mathieu.pioche@chu-lyon.fr)

 Supplementary material is available under <https://doi.org/10.1055/a-1783-8424>

## ABSTRACT

**Background and study aims** Perforations are a known adverse event of endoscopy procedures; a proposal for appropriate management should be available in each center as recommended by the European Society of Gastrointestinal Endoscopy. The objective of this study was to establish a charter for the management of endoscopic perforations, based on local evidence.

**Patients and methods** Patients were included if they experienced partial or complete perforation during an endoscopic procedure between 2008 and 2018 (retrospectively until 2016, then prospectively). Perforations (size, location, closure) and management (imagery, antibiotics, surgery) were analyzed. Using these results, a panel of experts was asked to propose a consensual management charter.

**Results** A total of 105 patients were included. Perforations occurred mainly during therapeutic procedures (91, 86.7%). Of the perforations, 78 (74.3%) were diagnosed immediately and managed during the procedure; 69 of 78 (88.5%) were successfully closed. Closures were more effective during therapeutic procedures (60 of 66, 90.9%) than during diagnostic procedures (9 of 12, 75.0%,  $P=0.06$ ). Endoscopic closure was effective for 37 of 38 perforations (97.4%)  $<0.5$  cm, and for 26 of 34 perforations (76.5%)  $\geq 0.5$  cm ( $P<0.05$ ). For perforations  $<0.5$  cm, systematic computed tomography (CT) scan, antibiotics, or surgical evaluation did not improve the outcome. Four of 105 deaths (3.8%) occurred after perforation, one of which was attributable to the perforation itself.

**Conclusions** Detection and closure of perforations during endoscopic procedure had a better outcome compared to delayed perforations; perforations  $<0.5$  cm had a very good prognosis and CT scan, surgeon evaluation, or antibiotics are probably not necessary when the endoscopic closure is confidently performed. This work led to proposal of a local management charter.

## Introduction

A perforation is defined as partial or complete damage to the muscular layer of the digestive wall that results immediately or within a specified time, in communication between the digestive lumen and the surrounding tissue. As use of therapeutic endoscopy develops, the number of cases of perforation consequently increases. Indeed, in recent studies, perforations have been reported to occur during about 0.1% of all colonoscopies, but this rate is variable, depending on the type of procedure, and ranges between 0.05% for diagnostic colonoscopies to 2% for therapeutic ones (for endoscopic mucosal resection [EMR]), and can even reach up to 4.5% (for endoscopic mucosal dissection [ESD]); delayed perforation after therapeutic procedures occurs in about 0.5% of cases [1–4]. Perforations are common adverse events (AEs) in endoscopic procedures and have always been a source of significant anxiety for endoscopists. They can lead to serious complications and require prompt management. Morbidity and mortality associated with a perforation depend on its location, size, and management [5–7]. Thus, a clear protocol regarding prevention and management of perforation should be implemented in each center and should be shared with radiologists and surgeons, as recommended by European Society of Gastrointestinal Endoscopy (ESGE) guidelines [8].

In 2014, ESGE guidelines encouraged endoscopy units to create a database to prospectively register AEs. In the hepatogastroenterology unit of Hôpital Edouard Herriot (Lyon, France), such a database was implemented in 2016.

The primary objective of the present study was to establish a charter and an algorithm for management of endoscopic perforations, as recommended by ESGE guidelines in 2014, based on local evidence and expert advice. To this end, we aimed to detail perforations (size, location, closure) that occurred during the study period (2008–2018) and how they were managed (imagery, antibiotics, surgery), and to identify characteristics and situations for which the proportion of salvage surgery would be the highest.

## Patients and methods

### Study design

The present study was a retrospective, single-center, descriptive study about digestive perforation outcomes following endoscopic procedures in the hepatogastroenterology unit of the teaching hospitals in Lyon, France. Between January 2008 and December 2018, patients referred for diagnostic or therapeutic endoscopy who had experienced a partial or complete perforation within 72 hours after the procedure were included in the study. Patients were excluded if the digestive leakage was due to a surgical fistula or if the perforation occurred spontaneously without being related to the endoscopic procedure (occlusion, cancer, or ulcer). Because a local prospective database recording AEs related to endoscopic perforations was implemented in 2016, two periods of inclusion were considered, i.e. before and after 2016. Based on these inclusion and exclusion criteria, patients who underwent endoscopic perforation

were identified and included in the study either using the local prospective database (perforations between 2016 and 2018) or their medical records, when available (perforations between 2008 and 2015).

### Data collection

A retrospective analysis of medical files was performed to retrieve and categorize the data of interest:

type of endoscopic procedure leading to the perforation, classified as either a diagnostic (gastroscopy, endoscopic ultrasound [EUS], colonoscopy) or a therapeutic procedure (EMR), ESD, polypectomy, dilations, stenting, endoscopic retrograde cholangiopancreatography (ERCP); (2) characteristics of the tumor in the case of endoscopic resections; (3) diagnosis of perforation, classified as either immediate or early (diagnosed during the endoscopic procedure) or delayed (diagnosed after the procedure); (4) location of the perforation; (5) size of perforation; (6) type of perforation according to the Sidney classification proposed by Burgess in 2016 [9], which includes six degrees of perforation (0 submucosal, I of II intact muscularis propria with or without fibrosis, III target sign with muscularis propria injured, IV of V obvious transmural perforation without of with contamination); (7) clinical outcome after endoscopy (pain, fever, peritonitis, length of hospitalization, success or failure of the endoscopic closure, rate of consecutive surgical management, mortality); and (8) postoperative management (imaging technique used, indication and type of surgery when performed, follow-up characteristics).

Target sign (type III) was considered as a perforation <0.5 cm.

### Management charter for endoscopic perforations

The 2014 ESGE guidelines recommended establishment of a management charter for endoscopic perforations. To create this charter, several questions were proposed to a panel of physicians in the hospital using a Google form (Google, California, United States). Before responding to the questionnaire, each physician received a version of the present manuscript that included the study results and a discussion about these results in context of the current literature. The panel was composed of 15 physicians from the facility, including five endoscopists (MP, JR, TP, JCS, FR), five digestive surgeons (MR, OM, EP, GP, LG), two gastrointestinal radiologists (PJV, HG), two anesthesiologists (CB, YB), and one infectious disease specialist (AB).

The questions were chosen arbitrarily by the authors based on their experience and preliminary data from the study. Preliminary results and the questions were submitted to a panel of experts, who helped write the charter, and each expert could also write a comment or not answer a question if he or she was not concerned.

### Statistical analysis

Variables were expressed as mean ( $\pm$  standard deviation, SD) or count (percentage). Data were analyzed using the free software BiostatTGV (INSERM U1036, Paris, France) and Excel (Microsoft, Redmond, Washington, United States). The distribution of categorical variables was compared using Fischer's exact test. All

reported *P* values were two-sided and regarded as significant if less than 0.05.

## Results

### Patients

A total of 105 patients with digestive perforation were included in the study; the mean ( $\pm$  SD) age was 65.3 ( $\pm$  13.8) years and 52 were men (49.5%). The mean ( $\pm$  SD) ASA score was 2.3 ( $\pm$  0.6) (► **Table 1**). Between 2008 and 2015, data about 51 perforations were retrieved from medical records, and 54 were prospectively recorded between 2016 and 2018. There were some significant differences between both study periods (Annex 1); however, these differences were not relevant for the purpose of the study and patients from both periods were considered as a single group.

Ninety-one of 105 perforations (86.7%) occurred during therapeutic procedures. Fourteen of 105 perforations (13.3%) occurred during a diagnostic procedure, of which eight (7.6%) were during screening colonoscopies. Colon perforations were the primary location of perforations (53 of 105, 50.5%) (► **Table 1**).

Overall, conservative non-surgical management of perforations was possible in 74 of 105 cases (70.5%). There were 27 delayed perforations detected after endoscopy and clinical management without surgery was possible in five of 27 cases (18.5%). Of these delayed perforations, two of 27 (7.4%) appeared after diagnostic procedures and 25 of 27 (92.6%) after therapeutic procedures ( $P < 0.0001$ ). Among all patients, 31 of 105 (29.5%) underwent salvage surgery, either due to delayed perforation (22 of 105, 20.9%) or a failure of the endoscopic perforation closure (9 of 105, 8.6%). Regarding mortality, four of 105 patients (3.8%) died after an endoscopic perforation: in one patient, death was due to a cerebral hemorrhage on day 3 after surgery for digestive perforation, one patient had an acute chronic cerebral hematoma on day 30 after successful endoscopic closure of the perforation, one had fatal evolution of a metastatic cancer complicated by an aspiration pneumonia on day 23 after endoscopy, and one had delayed digestive bleeding on day 10 after surgery for a duodenal perforation following EMR (► **Table 1**).

### Management of perforations diagnosed early

Overall, 78 of 105 perforations (74.3%) were diagnosed early. Endoscopic closure was always attempted when the perforation was diagnosed immediately (78 of 78, 100%) and was technically feasible in all cases, with successful closure and no need for delayed surgery in 69 of 78 patients (88.5%). Immediate surgery due to failure of the endoscopic closure was performed in nine of 78 patients (11.5%). The endoscopic closures that failed were three of 78 attempts (3.8%) to close large perforations ( $> 1$  cm), one of 78 attempts (1.3%) in an area of previous radiation therapy, two of 78 perforations (2.6%) after resection of colorectal neoplasia invading deeply the appendix, one of 78 perforations (1.3%) after ESD of a cecal adenoma failed to be closed by standard clips, and two of 78 duodenal perforations (2.6%) (1 after papillectomy, one after ERCP).

Endoscopic closure was more frequently successful when perforations occurred during a therapeutic procedure (60 of 66, 90.9%) than during a diagnostic procedure (9 of 12, 75.0%;  $P = 0.06$ ) (► **Table 2**). The proportion of perforations measuring  $< 0.5$  cm was significantly higher for therapeutic procedures (36 of 66, 54.5%) than for diagnostic procedures (1 of 12, 8.3%;  $P = 0.003$ ).

Regarding the size of the perforation, 37 of 38 closures (97.4%) were clinically successful when the perforation was  $< 0.5$  cm (► **Table 2**). Of note, the surgery performed for a colonic perforation  $< 0.5$  cm was due to concomitant presence of a spleen decapsulation seen on CT scan and not because of the perforation itself. When perforation was  $\geq 0.5$  cm, 26 of 34 closures (76.5%) were clinically successful; this proportion was significantly lower than that for successful closures of perforations  $> 0.5$  cm ( $P = 0.01$ ; ► **Table 2**). The proportion of successful endoscopic closures appeared lower in the small bowel (2 of 3, 66.7%), appendix (2 of 4, 50%), and duodenum (10 of 12, 83.3%), compared to the stomach (6 of 6, 100%), esophagus (6 of 6, 100%), rectum (7 of 7, 100%), and colon (36 of 40, 90.0%), although the small number of cases prevented significant differences to be found. The mean ( $\pm$  SD) length of hospital stay was significantly shorter for patients with a successful endoscopic closure ( $8.6 \pm 13.5$  days) than those with closure failure ( $15 \pm 10.8$  days;  $P = 0.02$ , ► **Table 2**).

Early perforations detected and closed with endoscopy had a better clinical outcome (9 of 78 vs 22 of 27 surgeries), corresponded to shorter hospital stays (8.2 vs 16.3 days), and led to less complications. The vast majority of endoscopic closures during therapeutic procedures were performed by advanced senior endoscopists because of the difficulty of the procedure.

## Medical management of perforations

### CT scan

All 27 patients who had delayed perforations were evaluated with CT scan. As for the 78 patients with early perforations, a CT scan was systematically performed after the endoscopic procedure in 45 of 78 patients (57.7%), eight of 78 patients (10.3%) had a CT scan due to delayed symptoms, and 25 of 78 (32.0%) did not undergo any CT scan (► **Table 2**).

Among the 45 asymptomatic patients with perforation diagnosed early who had a systematic CT evaluation, the clinical remission rate was 87% (40 of 45), which was not significantly different from the clinical remission rate in the 25 patients who had no imaging evaluation after endoscopy (100%, 25 of 25;  $P = 0.47$ ). When requested systematically in the absence of symptoms, CT scan results changed the management strategy by indicating the need for delayed surgery in three of 45 (6.7%) patients, two of whom had peritoneal liquid effusion and one of whom had spleen decapsulation; and two other patients required surgery but not because of the CT scan result. Conversely, when a CT scan was requested based on symptoms, four of eight patients (50.0%) ultimately underwent salvage surgery (► **Table 2**). Of the 38 patients with small ( $< 0.5$  cm) perforations, CT scan was performed in 18 (47.4%) and led to a change

► **Table 1** Characteristics of patients and perforations, overall data (2008–2018).

Patients and perforations	Total (n = 105)
Male sex, n (%)	52 (49.5%)
Age, years, mean (± SD)	65.3 (± 13.8)
ASA score, mean (± SD)	2.3 (± 0.6)
▪ 1, n (%)	7 (6.7%)
▪ 2, n (%)	48 (45.7%)
▪ 3, n (%)	34 (32.4%)
▪ 4, n (%)	1 (0.9%)
▪ Not available, n (%)	15 (14.3%)
Diagnosis of perforation, n (%)	
▪ Immediate	78 (74.3%)
▪ Delayed	27 (25.7%)
Type of procedure, n (%)	
▪ Diagnosis	14 (13.3%)
▪ EUS	3 (2.9%)
▪ Colonoscopy	10 (9.5%)
▪ Duodenoscopy	1 (0.9%)
▪ Therapeutic	91 (86.7%)
▪ EMR	33 (31.4%)
▪ ESD	35 (33.3%)
▪ Enteroscopy	4 (3.8%)
▪ ERCP	3 (2.9%)
▪ Dilations	5 (4.7%)
▪ Stenting	1 (0.9%)
▪ Hemostasis	6 (5.7%)
▪ Diverticulotomy	1 (0.9%)
▪ Papillectomy	3 (2.9%)
Endoscopic resections (N = 70), n (%)	70 (66.7%)
▪ Serrated lesions	12 (17.1%)
▪ Adenomatous lesions	58 (82.9%)
Risk factors, n (%)	
▪ Fibrosis	12 (11.4%)
▪ Radiation therapy	2 (1.9%)
▪ Appendix lesion	4 (3.8%)
Location, n (%)	
▪ Esophagus	6 (5.7%)
▪ Stomach	6 (5.7%)
▪ Duodenum	26 (24.8%)
▪ Small bowel	6 (5.7%)
▪ Colon	53 (50.5%)

► **Table 1** (Continuation)

Patients and perforations	Total (n = 105)
▪ Rectum	8 (7.6%)
Size of perforation, n (%) (endoscopy and imaging)	
▪ <0.5 cm	42 (40.1%)
▪ 0.5–1 cm	20 (19.0%)
▪ >1 cm	23 (21.9%)
▪ Not described or not seen	20 (19.0%)
Sidney classification, n (%)	
▪ Type 3 (Target Sign)	13 (12.4%)
▪ Type 4	61 (58.1%)
▪ Type 5	4 (3.8%)
▪ Unseen	27 (25.7%)
Management, n (%) (perforations detected per endoscopy)	
▪ Endoscopic successful closure	69 <sup>1</sup> (65.7%)
▪ Clip	46 <sup>1</sup> (43.8%)
▪ OVESCO clips	19 (18.1%)
▪ Stents	4 (3.8%)
▪ Salvage surgery following failure of endoscopic closure	9 (8.6%)
▪ Delayed perforations	5 (4.8%)
▪ Medical treatment	22 (20.9%)
▪ First-line salvage surgery	
CT scan (<48 h), n (%)	
▪ Yes	74 (70.5%)
▪ No	31 (29.5%)
Death, n (%)	4 (3.8%)
Length of stay, days, mean (± SD)	10.8 (± 12.5)
Time of the procedure when the perforation occurred, n (%)	
▪ 8:00 AM	20 (19.0%)
▪ 9:00 AM	15 (14.3%)
▪ 10:00 AM	17 (16.2%)
▪ 11:00 AM	13 (12.4%)
▪ 12:00 PM	22 (20.9%)
▪ 1:00 PM	7 (6.7%)
▪ 2:00 PM	4 (3.8%)

SD, standard deviation; ASA, American Society of Anesthesiologists; CT, computed tomography; EUS, endoscopic ultrasound; EMR, endoscopic mucosal resection; ESD, endoscopic submucosal dissection; ERCP, endoscopic retrograde cholangiopancreatography.

<sup>1</sup> One patient underwent delayed surgery to resect the lesion despite a successful closure.

► **Table 2** Perforations with an attempt of endoscopic closure: success and failures.

	Total	Success of endoscopic closure	P <sup>1</sup>	Failure of endoscopic closure	P <sup>2</sup>
Number, n (%)	78	69 (88.5%)		9 (11.5%)	
Age, years, mean (± SD)	67.0 (±12.3)	66.8 (± 12.5)		68.2 (± 11.4)	0.37
Size, n (%)			0.01		
▪ <0.5 cm (and Target Sign)	38	37 (97.4%)		1 (2.6%)	
▪ ≥0.5 cm	34	26 (76.5%)		8 (23.5%)	
▪ Not described	6	6 (100%)		0 (0%)	
Location, n (%)			0.69		
▪ Esophagus	6	6 (100%)		0 (0%)	
▪ Stomach	6	6 (100%)		0 (0%)	
▪ Duodenum	12	10 (83.3%)		2 (16.7%)	
▪ Small bowel	3	2 (66.7%)		1 (33.3%)	
▪ Appendix	4	2 (50%)		2 (50%)	
▪ Colon	40	36 (90%)		4 (10%)	
▪ Rectum	7	7 (100%)		0 (0%)	
Procedure, n (%)			0.06		
▪ Diagnostic	12	9 (75%)		3 (25%)	
▪ Therapeutic	66	60 (90.9%)		6 (9.1%)	
▪ ESD	32	30 (93.8%)		2 (6.2%)	
▪ EMR	24	22 (91.7%)		2 (8.3%)	
▪ Enteroscopy	2	2 (100%)		0 (0%)	
▪ ERCP	1	0 (0%)		1 (100%)	
▪ Dilations	5	5 (100%)		0 (0%)	
▪ Stenting	0	0 (0%)		0 (0%)	
▪ Hemostasis	0	0 (0%)		0 (0%)	
▪ Diverticulotomy	1	1 (100%)		0 (0%)	
▪ Papillectomy	1	0 (0%)		1 (100%)	
Antibiotics, n (%)			0.33		
▪ Yes	56	48 (85.7%)		8 (14.3%)	
▪ No	13	13 (100%)		0 (0%)	
▪ Not reported	9	8 (88.9%)		1 (11.1%)	
CTscan, n (%)			0.47		
▪ Systematic	45	40 (88.9%)		5 (11.1%)	
▪ If symptoms	8	4 (50.0%)		4 (50.0%)	
▪ No scan	25	25 (100%)		0 (0%)	
Surgeon evaluation, n (%)			0.003		
▪ Yes	43	34 (79.1%)		9 (20.9%)	
▪ No evaluation	35	35 (100%)		0 (0%)	

► **Table 2** (Continuation)

	Total	Success of endoscopic closure	P <sup>1</sup>	Failure of endoscopic closure	P <sup>2</sup>
Antifungal treatment, n (%)			0.32		
▪ Yes	10	8 (80.0%)		2 (20%)	
▪ No	68	61 (89.7%)		7 (10.3%)	
Nasogastric tube, n (%)			0.21		
▪ Yes	19	15 (78.9%)		4 (21.1%)	
▪ No	59	54 (91.5%)		5 (8.5%)	
Salvage surgery, n (%)	9	0 (0%)		9 (100%)	NA
Death, n (%)	3	2 <sup>3</sup> (66.7%)		1 (33.3%)	0.23
Length of stay, days, mean (± SD)	9.2 (± 13.4)	8.6 (± 13.5)		15 (± 10.8)	0.02

SD, standard deviation; ESD, endoscopic submucosal dissection; EMR, endoscopic mucosal resection; ERCP, endoscopic retrograde cholangiopancreatography; CT, computed tomography; NA, not available.

<sup>1</sup> For each variable, comparison between modalities in case of success.

<sup>2</sup> Comparison between success and failure.

<sup>3</sup> Not related to perforation (1 cerebral hematoma acutization at day 30 and 1 terminal phase cancer at day 23)

in management strategy for one of them (2.6%), which was due to a concomitant spleen decapsulation.

Thirty-six of 78 patients were asymptomatic (46.2%). After endoscopic treatment for perforation, CT images were indicative of an abundant pneumoperitoneum in seven of them (19.5%) who did not have delayed surgery, moderate pneumoperitoneum in 12 (33.3%) who did not have delayed surgery, and small air bubbles in 17 (47.2%), including two that had delayed surgery.

### Surgeon evaluation

A surgical opinion was systematically sought in 43 of 78 patients (55.1%) immediately after diagnosis of perforation, and in 27 of 27 cases (100%) after the appearance of symptoms from delayed perforations. Of the 43 patients with early perforation for which a surgeon was called, nine (20.9%) underwent delayed surgery (1 spleen decapsulation, two liquid effusions seen on CT scan, and six delayed abdominal guarding) (► **Table 2**). For patients with small perforations (<0.5 cm), surgical evaluation was sought in 14 of 38 cases (36.8%) and salvage surgery was needed in one patient, due to spleen decapsulation.

### Antibiotics and antifungal drugs

Most patients (78 of 105, 74.3%) received antibiotics for 3 to 5 days after the diagnosis of perforation; data were missing for 14 of 105 cases (13.3%).

Regarding the immediately diagnosed perforations with attempt of endoscopic closure, 56 of 78 patients (71.8%) received antibiotics and data were missing for nine of 78 patients (11.5%) (► **Table 2**). Of the 13 of 78 patients (16.7%) who did not receive antibiotics, 11 (84.6%) had small perforations (<0.5 cm) that were all successfully closed endoscopically with

hemoclips. The remaining two of 13 cases (15.4%) were one significant perforation (>1 cm) closed with Ovesco clip and one with size not described but that was closed with hemoclips. Among the patients who underwent an attempt at endoscopic closure for immediately diagnosed perforations, clinical success was obtained in 13 of 13 patients (100%) who did not receive antibiotics and in 46 of 56 patients (85.7%) who received antibiotics ( $P=0.33$ ) (► **Table 2**). Antifungal drugs were administered after perforations of the esophagus in four of six patients (66.7%), 14 of 26 with duodenal perforations (53.8%), one of six patients (16.7%) with jejunio-ileal perforations, and never after gastric (0 of 6) or colorectal perforations (0 of 61) (► **Table 3**). Among the 86 of 105 patients (81.9%) who did not receive any antifungal drugs, no infection with fungi was diagnosed during follow-up.

### Nasogastric tube and nil by mouth regimen

A nasogastric tube was used in 34 of 105 patients (29.5%) with perforation, including seven of 61 (11.5%) with colonic perforation, one of six (16.7%) with esophageal perforation, three of six (50%) with gastric perforation, 20 of 26 (76.9%) with duodenal perforation, and three of six (50%) with jejunio-ileal perforation (► **Table 3**). The use of suction was reported in 17 of 34 patients (50%).

Among 59 patients with perforations diagnosed early with attempted endoscopic closure, clinical success was obtained in 54 (91.5%) who did not have a nasogastric tube and 15 (78.9%) who had a nasogastric tube, with no significant difference between these two groups ( $P=0.21$ ) (► **Table 2**).

All patients with perforations diagnosed early were not fed orally during at least the first 24 hours after the perforations occurred. A total of 95 of 105 patients (90.5%) were put on a nil by mouth regimen; another four patients (3.8%) who were



► **Table 3** Medical management of the upper digestive tract perforations.

	Nasogastric tube		Antifungal treatment		Death, n
	Yes	No	Yes	No	
<b>Esophagus</b> (6 cases), n (%)					
▪ Endoscopic closure	1 (16.7%)	5 (83.3%)	4 (66.7%)	2 (33.3%)	1 <sup>1</sup>
▪ Surgery for closure failure	0 (0%)	0 (0%)	0 (0%)	0 (0%)	0
▪ Medical treatment	0 (0%)	0 (0%)	0 (0%)	0 (0%)	0
▪ 1 <sup>st</sup> line delayed surgery	0 (0%)	0 (0%)	0 (0%)	0 (0%)	0
<b>Stomach</b> (6 cases), n (%)					
▪ Endoscopic closure	3 (50%)	3 (50%)	0 (0%)	6 (100%)	0
▪ Surgery for closure failure	0 (0%)	0 (0%)	0 (0%)	0 (0%)	0
▪ Medical treatment	0 (0%)	0 (0%)	0 (0%)	0 (0%)	0
▪ 1 <sup>st</sup> line delayed surgery	0 (0%)	0 (0%)	0 (0%)	0 (0%)	0
<b>Duodenum</b> (26 cases), n (%)					
▪ Endoscopic closure	8 (80%)	2 (20%)	4 (40%)	6 (60%)	0
▪ Surgery for closure failure	2 (100%)	0 (0%)	2 (100%)	0 (0%)	0
▪ Medical treatment	4 (100%)	0 (0%)	2 (50%)	2 (50%)	0
▪ 1 <sup>st</sup> line delayed surgery	6 (60%)	4 (40%)	6 (60%)	4 (40%)	1 <sup>2</sup>
<b>Jejunum and ileum</b> (6 cases), n (%)					
▪ Endoscopic closure	1 (50%)	1 (50%)	0 (0%)	2 (100%)	0
▪ Surgery for closure failure	1 (100%)	0 (0%)	0 (0%)	1 (100%)	1 <sup>3</sup>
▪ Medical treatment	0 (0%)	0 (0%)	0 (0%)	0 (0%)	0
▪ 1 <sup>st</sup> line delayed surgery	1 (33.3%)	2 (66.7%)	1 (33.3%)	2 (66.7%)	0

<sup>1</sup> Death on day 23 not directly related to the perforation that was successfully closed but patient was undernourished and had terminal, metastatic cancer.

<sup>2</sup> Death on day 10 from digestive bleeding and multivisceral failure (cardiac arrest).

<sup>3</sup> Death on day 3 not related to the perforation; caused by cerebral bleeding.

fed immediately after the procedure had delayed perforation. Data regarding the regimen were missing for six of 105 patients (5.7%).

### Establishment of the charter of good practice for perforation management

Using those results and a questionnaire, a panel of 15 local experts (5 endoscopic gastroenterologists, five digestive surgeons, two digestive radiologists, two endoscopic anesthesiologist, and one infectious disease specialist) were asked 23 questions. Their answers (► **Table 4**) were the basis for a charter describing best practices (**Annexes 2–5**, ► **Fig. 1** included, document and algorithms).

## Discussion

Between the two periods studied, before and after the publication and application of ESGE guidelines [8], the proportion of perforations due to diagnostic procedures dramatically decreased from one-quarter to less than 5%. This reduction in

proportion can be partly due to improved knowledge about perforation risks during diagnostic procedures (diverticula) and also to a recent increase in the number of therapeutic techniques, such as ESD procedures, associated with a higher risk of perforation [10–12]. The increasing number of perforations from the first to the second study periods is also probably due to the creation of the database, and the fact that there are no missing data during the second period (prospective collection), while there were probably some during the first period (retrospective collection).

In the present study, perforations during therapeutic procedures were successfully closed in most cases (90%), whereas the post-diagnostic endoscopy perforations required salvage surgeries in one-quarter of patients. There was a difference in clinical outcomes among patients who had early vs delayed perforations. The success rate may also depend on the experience of the endoscopist. Similarly, outcomes after therapeutic perforations have been described as less complicated than after diagnostic ones [13] with fewer salvage surgeries, fewer stomas, and less morbidity.



► **Table 4** Opinion of the panel of local experts using results from the present study (4 pages).

Questions asked	Answers	Total physi- cians 15 (%)	Gastroenter- ologists 5 (%)	Surgeons 5 (%)	Radiolo- gists 2 (%)	Anesthe- siologists 2 ph., n (%)	Infectious disease specialist 1 (%)	Decision
1) Systematic CT scan for perforations <0.5 cm closed endoscopically?	Yes	2 <sup>1</sup> (13.3%)	0 (0%)	2 <sup>1</sup> (40%)	0 (0%)	0 (0%)	0 (0%)	NO
	No	13 (86.7%)	5 (100%)	3 (60%)	2 (100%)	2 (100%)	1 (100%)	
2) Surgeon evaluation for perforations <0.5 cm closed endoscopically?	Yes	1 (6.7%)	0 (0%)	1 (20%)	0 (0%)	0 (0%)	0 (0%)	NO
	No	14 (93.3%)	5 (100%)	4 (80%)	2 (100%)	2 (100%)	1 (100%)	
3) Surveillance in a medical unit for perforations <0.5 cm closed endoscopically?	Yes	13 (92.9%)	5 (100%)	3 (75%)	2 (100%)	2 (100%)	1 (100%)	YES
	No	1 (7.1%)	0 (0%)	1 (25%)	0 (0%)	0 (0%)	0 (0%)	
	NA	1	0	1	0	0	0	
4) Systematic CT scan for unseen perforations if alarming symptoms?	Yes	14 (100%)	5 (100%)	5 (100%)	1 (100%)	2 (100%)	1 (100%)	YES
	No	0 (0%)	0 (0%)	0 (0%)	0 (0%)	0 (0%)	0 (0%)	
	NA	1	0	0	1	0	0	
5) Systematic surveillance in surgical unit for unseen perforation (confirmed by CT scan)?	Yes	12 (85.7%)	5 (100%)	4 (80%)	1 (100%)	1 (50%)	1 (100%)	YES
	No	2 (14.3%)	0 (0%)	1 (20%)	0 (0%)	1 (50%)	0 (0%)	
	NA	1	0	0	1	0	0	
6) If surgery, less invasive surgery as possible, such as suture and drainage?	Yes (based on surgeon evaluation)	12 (92.3%)	5 (100%)	3 (75%)	2 (100%)	2 (100%)	0	YES
	No	1 <sup>2</sup> (7.7%)	0 (0%)	1 <sup>2</sup> (25%)	0 (0%)	0 (0%)	0	
	NA	2	0	1	0	0	1	
7) Systematic surgical evaluation for colic perforation ≥0.5 cm, closed endoscopically?	Systematic	11 (78.6%)	5 (100%)	3 (60%)	1 (100%)	1 (50%)	1 (100%)	YES, systematic
	Only if alarming symptoms	3 (21.4%)	0 (0%)	2 (40%)	0 (0%)	1 (50%)	0 (0%)	
	NA	1	0	0	1	0	0	
8) Systematic CT scan for colic perforation ≥0.5 cm, closed endoscopically?	Systematic	10 <sup>3</sup> (66.7%)	2 (40%)	5 (100%)	1 (50%)	1 <sup>3</sup> (50%)	1 (100%)	YES, systematic
	Only if alarming symptoms	5 (33.3%)	3 (60%)	0 (0%)	1 (50%)	1 (50%)	0 (0%)	
9) Surveillance if no symptoms, for colic perforation ≥0.5 cm, closed endoscopically?	Medical unit	6 (54.5%)	1 (20%)	3 (75%)	1 (100%)	1 (100%)	0	Medical unit, but surgical unit possible
	Surgical unit	5 (45.5%)	4 (80%)	1 (25%)	0 (0%)	0 (0%)	0	
	IC Unit	0 (0%)	0 (0%)	0 (0%)	0 (0%)	0 (0%)	0	
	NA	4	0	1	1	1	1	
10) Systematic intravenous antibiotic prophylaxis targeting digestive germs if perforation, whatever the size?	Yes	11 (100%)	5 (100%)	4 (100%)	0	1 (100%)	1 (100%)	YES
	No	0 (0%)	0 (0%)	0 (0%)	0	0 (0%)	0 (0%)	
	NA	4	0	1	2	1	0	

► Table 4 (Continuation)

Questions asked	Answers	Total physicians 15 (%)	Gastroenterologists 5 (%)	Surgeons 5 (%)	Radiologists 2 (%)	Anesthesiologists 2 ph., n (%)	Infectious disease specialist 1 (%)	Decision
11) Systematic intravenous antibiotics targeting digestive germs during 3 to 5 days if perforation, whatever the size?	Yes, whatever the size	7 (58.3%)	3 (60%)	3 (60%)	0	1 (100%)	0 (0%)	YES, systematic, but only if $\geq 0.5$ cm can be discussed
	Only if $\geq 0.5$ cm or not closed with confidence	5 (41.7%)	2 (40%)	2 (40%)	0	0 (0%)	1 (100%)	
	No, never	0 (0%)	0 (0%)	0 (0%)	0	0 (0%)	0 (0%)	
	NA	3	0	0	2	1	0	
11b Systematic intravenous antifungal treatment during 3 to 5 days if perforation, whatever the size?	Esophagus	10 (83.3%)	3 (75%)	5 (100%)	0	1 (50%)	1 (100%)	YES, in upper digestive tract perforation: esophagus, duodenum, stomach
	Stomach	7 (58.3%)	1 (25%)	5 (100%)	0	1 (50%)	0 (0%)	
	Duodenum	9 (75%)	2 (50%)	5 (100%)	0	1 (50%)	1 (100%)	
	Small bowel	1 (8.3%)	1 (25%)	0 (0%)	0	0 (0%)	0 (0%)	
	Colorectal	0 (0%)	0 (0%)	0 (0%)	0	0 (0%)	0 (0%)	
	No, never	2 <sup>4</sup> (16.7%)	1 (25%)	0 (0%)	0	1 <sup>4</sup> (50%)	0 (0%)	
	NA	3	1	0	2	0	0	
12) Systematic nasogastric tube for upper digestive perforation (regarding endoscopic closure: confidence or not)?	Esophagus:							YES, systematic in duodenum and small bowel, and if not confident in closure in esophagus and stomach (but can be discussed systematic)
	▪ whatever	3 (25%)	0 (0%)	3 (60%)	0 (0%)	0 (0%)	0	
	▪ not confidence	4 (33.3%)	2 (40%)	1 (20%)	1 (100%)	0 (0%)	0	
	Stomach:							
	▪ whatever	5 (41.7%)	0 (0%)	4 (80%)	1 (100%)	0 (0%)	0	
	▪ not confidence	6 (50%)	5 (100%)	1 (20%)	0 (0%)	0 (0%)	0	
	Duodenum:							
	▪ whatever	9 (75%)	3 (60%)	5 (100%)	1 (100%)	0 (0%)	0	
	▪ not confidence	2 (16.7%)	2 (40%)	0 (0%)	0 (0%)	0 (0%)	0	
	Small Bowel:							
	▪ whatever	7 (58.3%)	3 (60%)	3 (60%)	1 (100%)	0 (0%)	0	
	▪ not confidence	2 (16.7%)	1 (20%)	1 (20%)	0 (0%)	0 (0%)	0	
	No, never	1 (8.3%)	0 (0%)	0 (0%)	0 (0%)	0 (0%)	1 (100%)	
NA	3	0	0	1	1	1	1	
13) Systematic nil by mouth regimen for at least 24 hours if perforation, whatever the size?	Yes, always	12 (85.7%)	5 (100%)	5 (100%)	1 (50%)	0 (0%)	1 (100%)	YES, always
	Upper tract	2 (14.3%)	0 (0%)	0 (0%)	1 (50%)	1 (100%)	0 (0%)	
	Lower tract	0 (0%)	0 (0%)	0 (0%)	0 (0%)	0 (0%)	0 (0%)	
	No, never	0 (0%)	0 (0%)	0 (0%)	0 (0%)	0 (0%)	0 (0%)	
	NA	1	0	0	0	1	0	

► **Table 4** (Continuation)

Questions asked	Answers	Total physi- cians 15 (%)	Gastroenter- ologists 5 (%)	Surgeons 5 (%)	Radiolo- gists 2 (%)	Anesthe- siologists 2 ph., n (%)	Infectious disease specialist 1 (%)	Decision
14) Systematic attempt of endoscopic closure when perforation seen whatever the size and the site?	Yes, systematic	13 (100%)	5 (100%)	4 (100%)	1 (100%)	2 (100%)	1 (100%)	YES, systematic
	No	0 (0%)	0 (0%)	0 (0%)	0 (0%)	0 (0%)	0 (0%)	
	NA	2	0	1	1	0	0	
15) Systematic CT scan if endoscopic closure not possible whatever the size and the site?	Yes, systematic	14 (93.3%)	5 (100%)	5 (100%)	1 (50%)	2 (100%)	1 (100%)	YES, systematic after procedure (to have a baseline CT scan)
	Only if symptoms	1 (6.7%)	0 (0%)	0 (0%)	1 (50%)	0 (0%)	0 (0%)	
	No	0 (0%)	0 (0%)	0 (0%)	0 (0%)	0 (0%)	0 (0%)	
16) Systematic surgical evaluation and transfer in surgical unit if endoscopic closure not possible whatever the size and the site?	Evaluation and transfer	6 (50%)	5 (100%)	1 (25%)	0 (0%)	0 (0%)	0	YES, systematic evaluation and transfer (which can be discussed)
	Evaluation, no transfer	3 (25%)	0 (0%)	1 (25%)	1 (100%)	1 (50%)	0	
	No, if symptoms	3 (25%)	0 (0%)	2 (50%)	0 (0%)	1 (50%)	0	
	NA	3	0	1	1	0	1	
17) Systematic opacification if perforation and CT scan performed?	Yes, systematic	3 (23.1%)	1 (33.3%)	1 (20%)	0 (0%)	0 (0%)	1 (100%)	NO, only if doubt on site in CT scan
	Upper tract	1 (7.7%)	1 (33.3%)	0 (0%)	0 (0%)	0 (0%)	0 (0%)	
	Lower tract	0 (0%)	0 (0%)	0 (0%)	0 (0%)	0 (0%)	0 (0%)	
	Only if doubt on site in CT scan	7 <sup>5</sup> (53.8%)	1 (33.3%)	2 <sup>5</sup> (40%)	2 (100%)	2 (100%)	0 (0%)	
	No, never	2 (15.4%)	0 (0%)	2 (40%)	0 (0%)	0 (0%)	0 (0%)	
	NA	2	2	0	0	0	0	
18) Systematic new radiologic exam before reseeding the patient if nil by mouth regimen?	Yes, systematic	1 (8.3%)	0 (0%)	1 (25%)	0 (0%)	0 (0%)	0	NO, only if symptoms (of fistula or incomplete closure for instance)
	If symptoms	11 <sup>6</sup> (91.7%)	5 <sup>6</sup> (100%)	3 (75%)	2 (100%)	1 (100%)	0	
	No, never	0 (0%)	0 (0%)	0 (0%)	0 (0%)	0 (0%)	0	
	NA	3	0	1	0	1	1	
19) Temporary surveillance in surgical unit or intensive care unit if surgery for perforation?	Yes	15 (100%)	5 (100%)	5 (100%)	2 (100%)	2 (100%)	1 (100%)	YES
	No	0 (0%)	0 (0%)	0 (0%)	0 (0%)	0 (0%)	0 (0%)	
20) Isolated pneumoperitoneum should lead to surgery (if CT scan performed)?	No	15 (100%)	5 (100%)	5 (100%)	2 (100%)	2 (100%)	1 (100%)	NO
	Yes	0 (0%)	0 (0%)	0 (0%)	0 (0%)	0 (0%)	0 (0%)	

► **Table 4** (Continuation)

Questions asked	Answers	Total physicians 15 (%)	Gastroenterologists 5 (%)	Surgeons 5 (%)	Radiologists 2 (%)	Anesthesiologists 2 ph., n (%)	Infectious disease specialist 1 (%)	Decision
21) Radiologic features that should lead to surgery if perforation (and CT scan performed)?	Small liquid	0 (0%)	0 (0%)	0 (0%)	0 (0%)	0 (0%)	0 (0%)	Presence of massive liquid, collection > 5 cm and massive tissue infiltration close to perforation should lead to surgery
	Massive liquid	13 (100%)	4 (100%)	5 (100%)	2 (100%)	1 (100%)	1 (100%)	
	Collection > 5 cm	13 (100%)	4 (100%)	5 (100%)	2 (100%)	1 (100%)	1 (100%)	
	Massive tissue infiltration	7 (53.8%)	1 (25%)	4 (80%)	1 (50%)	0 (0%)	1 (100%)	
	NA	2	1	0	0	1	0	
22) Clinical signs of severity for new surgical evaluation if surveillance in medical unit?	Fever > 38.5 °C	14 (93.3%)	4 (80%)	5 (100%)	2 (100%)	2 (100%)	1 (100%)	Fever > 38.5 °C, tachycardia (> 100 of min), polypnea (> 20 of min), massive abdominal pain should lead to a new surgical evaluation <sup>7</sup>
	Tachycardia	14 (93.3%)	5 (100%)	5 (100%)	1 (50%)	2 (100%)	1 (100%)	
	Polypnea	14 (93.3%)	5 (100%)	5 (100%)	1 (50%)	2 (100%)	1 (100%)	
	Massive abdominal pain	15 (100%)	5 (100%)	5 (100%)	2 (100%)	2 (100%)	1 (100%)	
23) Symptoms for surgical evaluation in emergency?	Fever > 38.5 °C	13 (86.7%)	4 (80%)	4 (80%)	2 (100%)	2 (100%)	1 (100%)	Fever > 38.5 °C, tachycardia (> 100 of min), polypnea (> 20 of min), major abdominal pain and moderate pain > 1 hour (to 3 hours) should lead to surgical evaluation in emergency <sup>7</sup>
	Major pain	15 (100%)	5 (100%)	5 (100%)	2 (100%)	2 (100%)	1 (100%)	
	Tachycardia	14 (93.3%)	5 (100%)	5 (100%)	1 (50%)	2 (100%)	1 (100%)	
	Polypnea	14 (93.3%)	5 (100%)	5 (100%)	1 (50%)	2 (100%)	1 (100%)	
	Moderate pain							
	▪ > 1 hour	7 (50%)	3 (60%)	1 (20%)	1 (50%)	1 (50%)	1 (100%)	
	▪ > 3 hours	3 (21.4%)	1 (20%)	1 (20%)	0 (0%)	1 (50%)	0 (0%)	
	▪ > 6 hours	4 (28.6%)	1 (20%)	2 (40%)	1 (50%)	0 (0%)	0 (0%)	
NA	1	0	1	0	0	0		

not answered; CT, computed tomography; SIRS, systemic inflammatory response syndrome; NB, NA answers were disregarded for the calculation of percentages; CRP, C-reactive protein.

<sup>1</sup> Not systematic but depends on the location.

<sup>2</sup> Depends on histology and location of perforation; goal is to avoid digestive stoma.

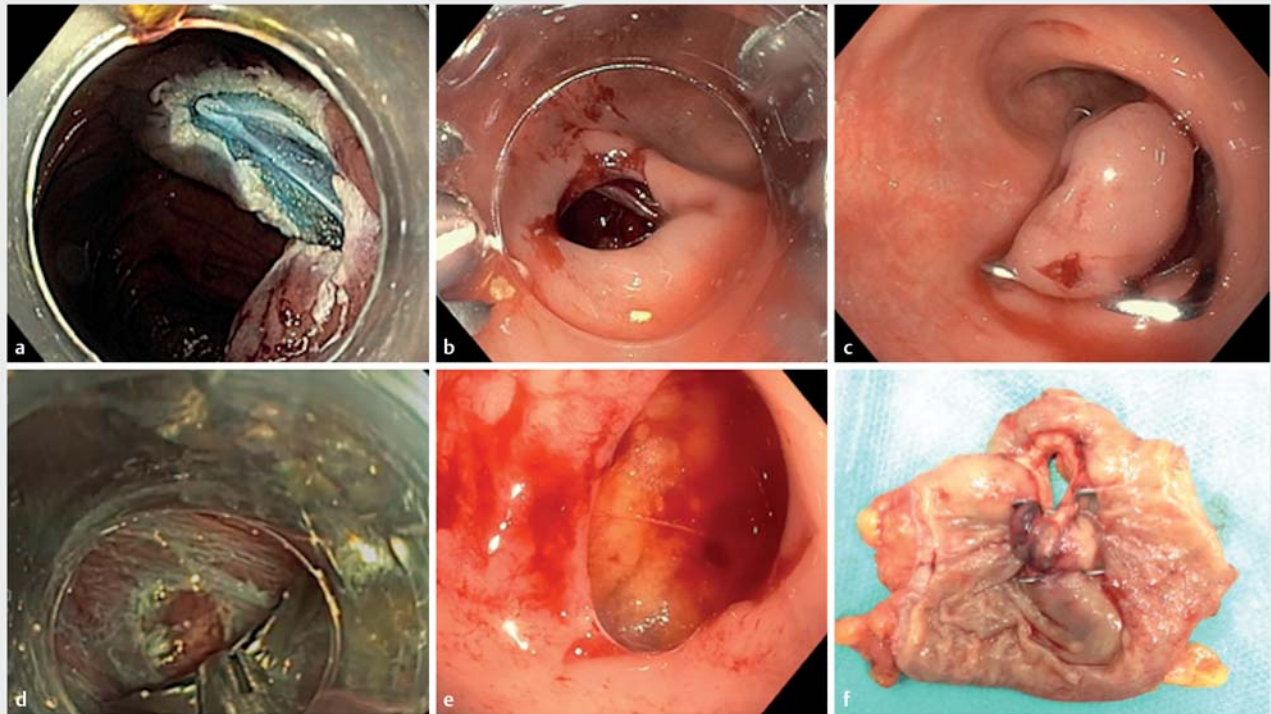
<sup>3</sup> One physician answered: yes, but not immediately (within 24–48 hours or before if symptoms).

<sup>4</sup> One physician answered: not immediately, only if fungi found in liquid on surgery or if no surgery and discuss treatment on day 7.

<sup>5</sup> One physician answered: case by case.

<sup>6</sup> One physician answered: depends on size, type of closure, confidence in the quality of endoscopic closure and baseline CT scan; not systematic.

<sup>7</sup> Others proposals: every organ failure, guarding, contracture, every symptom of SIRS (blood CRP and white cells, platelets, fibrinogen).



► **Fig. 1** Examples of perforation and management **a** target sign, **b** large perforation, **c** ovesco clip, **d** closure with hemoclips, **e** large perforation in the fat tissue, **f** failure of endoscopic closure leading to surgery.

Several explanations could be proposed to explain this difference. First, endoscopists who perform therapeutic procedures may have more experience in therapeutic endoscopy and in perforation management than those who perform only diagnostic procedures [14]; furthermore, diagnostic perforations are usually larger (>1 cm), especially when associated with the passage of the scope through the digestive wall. Thus, reducing the risk of diagnostic procedures (caution in diverticular areas, prudent use of linear EUS scope) appears important to avoid perforations. Conversely, most therapeutic perforations were <0.5 cm, leading to a higher proportion of effective closures, which has also been reported in the literature [15, 16].

There was no significant difference in the number of perforations depending on the time when the procedure was performed; however, one can imagine risky procedures should be performed when endoscopists are less tired and can concentrate more. Therefore, they should not be scheduled at the end of a shift.

Data regarding colonic preparation were lacking in a significant number of cases, mostly because the preparation was done at home in most cases (data not shown). However, a lack of preparation leads to more severe perforations, with a risk of peritonitis.

There was an important difference between perforations diagnosed early and delayed perforations, usually diagnosed within days as a result of a patient's symptoms (pain, fever, abdominal guarding) [17]. When diagnosed during the endos-

copy, perforations were successfully closed in most cases (90%), as previously described [18–20], whereas delayed perforations led to surgery in most cases. In the present study, that included perforations that occurred in a tertiary care center specializing in therapeutic endoscopy, where three-quarters of the perforations were diagnosed during the procedure, whereas only 13% of colonic perforations were detected during the procedure in the British national register for current colonoscopy practice [13]. Thus, particular attention should be paid to the digestive wall to detect muscle injury, especially after endoscopic resection. In parallel, dedicated training sessions could be proposed to teach how to detect perforations and how to close them efficiently, especially for target signs (type III according to Sydney classification) and small perforations (<0.5 cm). We chose this limit in size based on our own experience (data not shown). Indeed, those injuries were almost always closed successfully when detected, as previously described [21, 22].

Endoscopic closure was effective even if concomitant medical management was associated (antibiotics, CT scan, surgeon evaluation). Thus, systematically requesting a CT scan or surgeon evaluation is probably not useful, but on the other hand, detecting early symptoms of leakage (pain, fever, abdominal guarding) could result in fewer surgeries. In fact, in the present study, the proportion of successful endoscopic closures was significantly lower when surgeon evaluation was performed, thus, some of those surgeries might have been avoided by simply proposing medical management [23]. It is also possible that

surgeon evaluation was required when there was a doubt about the quality of the closure. Asking the endoscopist about his or her confidence regarding closure quality would have helped address this hypothesis. Confidence about quality of closure is probably an important point for the management algorithm and should be described in the endoscopy report. In parallel, the presence of a pneumoperitoneum on CT scan was not a risk factor for delayed surgery, underscoring the fact that such radiologic criteria, when isolated, should not be considered to indicate surgery, as previously described in the literature [24–28].

Although retrospective, the results of the present study led a panel of local experts to unanimously adopt a local charter for management that outlined some major points. For example, it was agreed that antibiotics, surgeon evaluation, or CT scan should not be proposed systematically for perforations <0.5 cm when closed endoscopically with confidence by the endoscopist. On the contrary, CT scan or surgeon evaluation should be proposed in case of symptoms or appearance suggestive of delayed leakage, which is usually done [29].

The present study suffered from several limitations, the main one being the amount of missing data related to perforations reported before 2016, because of the retrospective design, particularly concerning medical management following perforation closure. However, because perforations occurred rarely, a prospective study may be difficult to undertake to obtain high-quality data. Nevertheless, the present study included is among those with the largest number of perforations and demonstrated good prognosis for small perforations when endoscopic closure was performed. The study population was inhomogeneous, but perforations constitute an event difficult to describe because of their rareness. It is true that one cannot expect the same outcome while dealing with a perforation in the duodenum and in the colon, which is why we chose a precise algorithm and charter for each of the locations. That helped the study center adopt a local management charter that resulted in conservative management of such perforations, which is in keeping with the recent update to European recommendations [30]. Because the charter proposed herein is not exhaustive, the recently published recommendations should be followed as a complement to the charter. Because readers in other centers may not agree entirely with the generalizability of the charter and algorithm, the authors acknowledge that they are intended for local use only.

## Conclusions

In conclusion, detection and closure of perforations during endoscopy procedures were more successful than those associated with delayed perforations. Small perforations <0.5 cm had a very good prognosis and CT scan, surgeon evaluation, or antibiotics are probably not necessary when an endoscopic closure is confidently performed. The present study led to an example of local management charter as recommended by ESGE guidelines. The proposed charter and algorithm are intended for local use only because as specified in the ESGE guidelines, each center should have its own policy.

## Competing interests

The authors declare that they have no conflict of interest.

## References

- [1] Pedersen L, Sorensen N, Lindorff-Larsen K et al. Colonoscopy adverse events: are we getting the full picture? *Scand J Gastroenterol* 2020; 55: 979–987
- [2] Benazzato L, Zorzi M, Antonelli G et al. Colonoscopy-related adverse events and mortality in an Italian organized colorectal cancer screening program. *Endoscopy* 2021; 53: 501–508
- [3] Yu JX, Lin JL, Oliver M et al. Trends in EMR for nonmalignant colorectal polyps in the United States. *Gastrointest Endosc* 2020; 91: 124–131. e4
- [4] Akintoye E, Kumar N, Aihara H et al. Colorectal endoscopic submucosal dissection: a systematic review and meta-analysis. *Endosc Int Open* 2016; 4: E1030–E1044
- [5] Penz D, Ferlitsch A, Waldmann E et al. Impact of adenoma detection rate on detection of advanced adenomas and endoscopic adverse events in a study of over 200,000 screening colonoscopies. *Gastrointest Endosc* 2020; 91: 135–141
- [6] Rabeneck L, Paszat LF, Hilsden RJ et al. Bleeding and perforation after outpatient colonoscopy and their risk factors in usual clinical practice. *Gastroenterology* 2008; 135: 1899–1906.e1
- [7] Bielawska B, Day AG, Lieberman DA et al. Risk factors for early colonoscopic perforation include non-gastroenterologist endoscopists: a multivariable analysis. *Clin Gastroenterol Hepatol* 2014; 12: 85–92
- [8] Paspatis GA, Dumonceau J-M, Barthet M et al. Diagnosis and management of iatrogenic endoscopic perforations: European Society of Gastrointestinal Endoscopy (ESGE) Position Statement. *Endoscopy* 2014; 46: 693–711
- [9] Burgess NG, Bassan MS, McLeod D et al. Deep mural injury and perforation after colonic endoscopic mucosal resection: a new classification and analysis of risk factors. *Gut* 2017; 66: 1779–1789
- [10] Saito Y, Uraoka T, Yamaguchi Y et al. A prospective, multicenter study of 1111 colorectal endoscopic submucosal dissections (with video). *Gastrointest Endosc* 2010; 72: 1217–1225
- [11] Farhat S, Chaussade S, Ponchon T et al. Endoscopic submucosal dissection in a European setting. A multi-institutional report of a technique in development. *Endoscopy* 2011; 43: 664–670
- [12] Chung I-K, Lee JH, Lee S-H et al. Therapeutic outcomes in 1000 cases of endoscopic submucosal dissection for early gastric neoplasms: Korean ESD Study Group multicenter study. *Gastrointest Endosc* 2009; 69: 1228–1235
- [13] Derbyshire E, Hungin P, Nickerson C et al. Colonoscopic perforations in the English National Health Service Bowel Cancer Screening Programme. *Endoscopy* 2018; 50: 861–870
- [14] Voermans RP, Le Moine O, von Renteln D et al. Efficacy of endoscopic closure of acute perforations of the gastrointestinal tract. *Clin Gastroenterol Hepatol* 2012; 10: 603–608
- [15] Magdeburg R, Sold M, Post S et al. Differences in the endoscopic closure of colonic perforation due to diagnostic or therapeutic colonoscopy. *Scand J Gastroenterol* 2013; 48: 862–867
- [16] Jovanovic I, Zimmermann L, Fry LC et al. Feasibility of endoscopic closure of an iatrogenic colon perforation occurring during colonoscopy. *Gastrointest Endosc* 2011; 73: 550–555
- [17] de'Angelis N, Di Saverio S, Chiara O et al. 2017 WSES guidelines for the management of iatrogenic colonoscopy perforation. *World J Emerg Surg* 2018; 13: 5



- [18] Minami S, Gotoda T, Ono H et al. Complete endoscopic closure of gastric perforation induced by endoscopic resection of early gastric cancer using endoclips can prevent surgery (with video). *Gastrointest Endosc* 2006; 63: 596–601
- [19] Pissas D, Ypsilantis E, Papagrigoiriadis S et al. Endoscopic management of iatrogenic perforations during endoscopic mucosal resection (EMR) and endoscopic submucosal dissection (ESD) for colorectal polyps: a case series. *Therap Adv Gastroenterol* 2015; 8: 176–181
- [20] Takamaru H, Saito Y, Yamada M et al. Clinical impact of endoscopic clip closure of perforations during endoscopic submucosal dissection for colorectal tumors. *Gastrointest Endosc* 2016; 84: 494–502.e1
- [21] Byeon J-S. Colonic perforation: can we manage it endoscopically? *Clin Endosc* 2013; 46: 495–499
- [22] Magdeburg R, Collet P, Post S et al. Endoclipping of iatrogenic colonic perforation to avoid surgery. *Surg Endosc* 2008; 22: 1500–1504
- [23] Pioche M, Bertrand G, Rivory J. Endoscopic perforation during ERM or ESD: who should take care of the patient? *Endosc Int Open* 2018; 06: E313–E314
- [24] Baron TH, Wong Kee Song LM, Zielinski MD et al. A comprehensive approach to the management of acute endoscopic perforations (with videos). *Gastrointest Endosc* 2012; 76: 838–859
- [25] Tamiya Y, Nakahara K, Kominato K et al. Pneumomediastinum is a frequent but minor complication during esophageal endoscopic submucosal dissection. *Endoscopy* 2009; 42: 8–14
- [26] Fujishiro M, Yahagi N, Kakushima N et al. Successful nonsurgical management of perforation complicating endoscopic submucosal dissection of gastrointestinal epithelial neoplasms. *Endoscopy* 2006; 38: 1001–1006
- [27] Maeda Y, Hirasawa D, Fujita N et al. Mediastinal emphysema after esophageal endoscopic submucosal dissection: its prevalence and clinical significance: mediastinal emphysema after esophageal ESD. *Digest Endosc* 2011; 23: 221–226
- [28] Shin YJ, Kim YH, Lee KH et al. CT findings of post-polypectomy coagulation syndrome and colonic perforation in patients who underwent colonoscopic polypectomy. *Clin Radiol* 2016; 71: 1030–1036
- [29] Anderson ML, Pasha TM, Leighton JA. Endoscopic perforation of the colon: lessons from a 10-year study. *Am J Gastroenterol* 2000; 95: 3418–3422
- [30] Paspatis GA, Arvanitakis M, Dumonceau J-M et al. Diagnosis and management of iatrogenic endoscopic perforations: European Society of Gastrointestinal Endoscopy (ESGE) Position Statement – Update 2020. *Endoscopy* 2020; 52: 792–810