



HAL
open science

Taurine Depletion Causes ipRGC Loss and Increases Light-Induced Photoreceptor Degeneration

Diego García-Ayuso, Johnny Di Pierdomenico, Wahiba Hadj-Said, Mélanie Marie, Marta Agudo-Barriuso, Manuel Vidal-Sanz, Serge Picaud, María Villegas-Pérez

► **To cite this version:**

Diego García-Ayuso, Johnny Di Pierdomenico, Wahiba Hadj-Said, Mélanie Marie, Marta Agudo-Barriuso, et al.. Taurine Depletion Causes ipRGC Loss and Increases Light-Induced Photoreceptor Degeneration. *Investigative Ophthalmology & Visual Science*, 2018, 59 (3), pp.1396-1409. 10.1167/iops.17-23258 . inserm-03736231

HAL Id: inserm-03736231

<https://inserm.hal.science/inserm-03736231>

Submitted on 22 Jul 2022

HAL is a multi-disciplinary open access archive for the deposit and dissemination of scientific research documents, whether they are published or not. The documents may come from teaching and research institutions in France or abroad, or from public or private research centers.

L'archive ouverte pluridisciplinaire **HAL**, est destinée au dépôt et à la diffusion de documents scientifiques de niveau recherche, publiés ou non, émanant des établissements d'enseignement et de recherche français ou étrangers, des laboratoires publics ou privés.



Distributed under a Creative Commons Attribution - NonCommercial - NoDerivatives 4.0 International License

Taurine Depletion Causes ipRGC Loss and Increases Light-Induced Photoreceptor Degeneration

Diego García-Ayuso,¹ Johnny Di Pierdomenico,¹ Wahiba Hadj-Said,^{2,3} Mélanie Marie,^{2,3} Marta Agudo-Barriuso,¹ Manuel Vidal-Sanz,¹ Serge Picaud,^{2,3} and María P. Villegas-Pérez¹

¹Departamento de Oftalmología, Facultad de Medicina, Universidad de Murcia, and Instituto Murciano de Investigación Biosanitaria Hospital Virgen de la Arrixaca (IMIB-Virgen de la Arrixaca), Murcia, Spain

²INSERM U968, Institut de la Vision, Paris, France

³Sorbonne Universités, UPMC Université Paris 06, INSERM U968, CNRS UMR 7210, Institut de la Vision, Paris, France

Correspondence: Diego García-Ayuso, Laboratorio de Oftalmología Experimental, Instituto Murciano de Investigación Biosanitaria Virgen de la Arrixaca, Edificio LAIB Planta 5ª, Carretera Buenavista s/n, 30120 El Palmar, Murcia, Spain; diegogarcia@um.es.

María P. Villegas-Pérez, Laboratorio de Oftalmología Experimental, Instituto Murciano de Investigación Biosanitaria Virgen de la Arrixaca, Edificio LAIB Planta 5ª, Carretera Buenavista s/n, 30120 El Palmar, Murcia, Spain; mpville@um.es.

Submitted: October 31, 2017

Accepted: February 15, 2018

Citation: García-Ayuso D, Di Pierdomenico J, Hadj-Said W, et al. Taurine depletion causes ipRGC loss and increases light-induced photoreceptor degeneration. *Invest Ophthalmol Vis Sci.* 2018;59:1396–1409. <https://doi.org/10.1167/iovs.17-23258>

PURPOSE. To examine if light exposure exacerbates retinal neuronal loss induced by taurine depletion.

METHODS. Albino rats received β -alanine in the drinking water to induce taurine depletion. One month later, half of the animals were exposed to white light (3000 lux) continuously for 48 hours and the rest remained in normal environmental conditions. A control group of animals nontreated with β -alanine also was prepared, and half of them were exposed to light using the same protocol. All the animals were processed 2 months after the beginning of the experiment. Retinas were dissected as wholemounts and immunodetected with antibodies against Brn3a, melanopsin, S-opsin, and L-opsin to label different retinal populations: Brn3a⁺ retinal ganglion cells (RGCs) (image-forming RGCs), m⁺RGCs (non-image-forming RGCs), and S- and L/M-cones, respectively.

RESULTS. Light exposure did not affect the numbers of Brn3a⁺RGCs or m⁺RGCs but diminished the numbers of S- and L/M-cones and caused the appearance of rings devoid of cones, mainly in an “arciform” area in the superotemporal retina. Taurine depletion caused a diminution of all the studied populations, with m⁺RGCs the most affected, followed by S-cones. Light exposure under taurine depletion increased photoreceptor degeneration but did not seem to increase Brn3a⁺RGCs or m⁺RGCs loss.

CONCLUSIONS. Our results document that taurine is necessary for cell survival in the rat retina and even more under light-induced photoreceptor degeneration. Thus, taurine supplementation may help to prevent retinal degenerations, especially those that commence with S-cone degeneration or in which light may be an etiologic factor, such as inherited retinal degenerations, AMD, or glaucoma.

Keywords: taurine, retinal ganglion cells, cones, retinal degeneration, intrinsically photosensitive retinal ganglion cell, light, phototoxicity, melanopsin

Taurine is a nonessential amino acid that is synthesized in the liver of most mammals, and it is present in high levels in tissues such as the eyes (mainly in the retina) and muscles.¹ Although taurine is a nonessential amino acid, it is mostly obtained from the diet. The endogenous synthesis of taurine can be insufficient, because in cats² and in monkeys³ nutritional taurine depletion has been shown to cause photoreceptor degeneration. Recently it has been documented that taurine depletion also causes retinal ganglion cell (RGC) loss,^{4–6} and therefore retinal health is dependent on taurine, at least in some species.

In humans, it has been shown that long-term parenteral nutrition lacking taurine results in lower plasma taurine levels and in abnormal electroretinographic responses in children and possibly in adults.^{7,8} Moreover, we have shown that epileptic patients treated with vigabatrin show insufficient taurine plasma levels,⁹ and, recently, it has been proposed that this deficit together with photopic exposure could be the cause of vigabatrin-induced retinal toxicity.^{4,10} In accordance, taurine

supplementation has been recommended to avoid retinal damage in human patients treated long-term with vigabatrin.¹¹

Chronic pharmacological treatment with β -alanine or guanidoethane sulfonate (GES) is necessary to induce taurine depletion in rodents,^{1,6,12–14} because their endogenous taurine synthesis is higher than in other species, such as cats, humans, or monkeys.^{1,12} In mice, we have documented that the topography of photoreceptor loss induced by taurine depletion resembles that observed after light damage, as it is greater in the dorsal retina.⁶ Several authors have suggested a direct relationship between taurine depletion and light sensitivity of retinal neurons.^{6,10,15–17} Thus, the question arises whether retinal degeneration triggered by taurine depletion is greater after light exposure (ALE).

In this work, we have used β -alanine treatment and our model of light-induced retinal damage,^{18–20} to study the effects of an acute light exposure on the retina of taurine-depleted animals. We have investigated the survival of different retinal neurons ALE using techniques recently developed in our laboratory to identify and map in the same retinal flatmounts



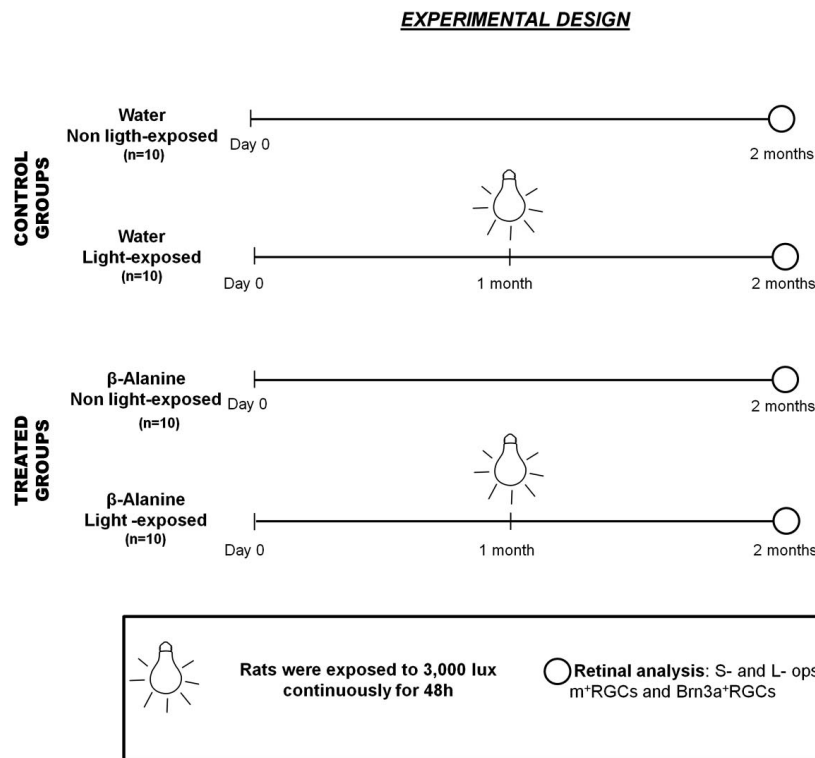


FIGURE 1. Experimental design. Diagram depicting the groups used, the periods of light exposure, and the processing time points.

the entire population of L/M- and S-cones, Brn3a⁺RGCs, and m⁺RGCs ALE.^{21–24}

MATERIALS AND METHODS

Animal Handling

Two-month-old albino Sprague-Dawley (SD) female rats (150–180 g body weight) were obtained from the University of Murcia breeding colony ($n = 40$) and divided into a control group of rats drinking β -alanine-free water (intact group; $n = 20$) and a group of rats treated with β -alanine (Sigma-Aldrich, Madrid, Spain) administered in the drinking water at a concentration of 3% to induce taurine depletion (Fig. 1; $n = 20$). Animals were housed in an environmentally controlled room with a 12-hour:12-hour light-dark cycle (light from 8 AM to 8 PM) and had food and water ad libitum. The light intensity within the cages in our animal care facilities ranged from 5 to 30 lux. One month after the beginning of the treatment, half of the animals from both groups were exposed to light (see below). Light-exposed and nonexposed animals were processed 2 months after the beginning of the experiment, and 1-month ALE (Fig. 1).

All experiments were carried out in accordance with the Spanish and the European Community Council Directives (86/609/EEC), and with the ARVO Statement for the Use of Animals in Ophthalmic and Vision Research, and were previously approved by the Ethics and Animal Studies Committee of the University of Murcia.

Light Exposure

Light exposure was carried out following our model of light-induced retinal degeneration.^{19,20} Briefly, during light exposure, each rat was individually placed in a standard transparent

cage and fed ad libitum having food and water in Petri dishes at the bottom of the cage, to avoid shadows. To prevent the animals from burying their heads in the litter, a metal grid was placed at the bottom of the cage and the litter underneath. The animals were exposed to cold white light (3000 lux; OSRAM GmbH, Munich, Germany) continuously for 48 hours emitted from linear bulbs situated 20 cm above the cages.^{19,20} Light exposure always started between 10:00 AM and 12:00 AM.

Tissue Processing

For euthanasia, rats were first sedated with an intraperitoneal injection of sodium pentobarbital (Dolethal Vetoquinol, S.A., Lure, France) and then euthanized with a lethal dose of sodium pentobarbital. The animals were then perfused transcardially first with saline and later with 4% paraformaldehyde in 0.1 M phosphate buffer (pH 7.4). To avoid melanopsin diurnal fluctuations,^{25,26} animal processing was done between 10:00 and 12:00 AM, at the same time at which light exposure had started. Blood samples were collected just before euthanasia and after centrifugation, plasma was collected and frozen at -20°C until used for amino acid analysis.

HPLC-Tandem Mass Spectrometry (HPLC-MS/MS) Analysis of Taurine Plasma Levels

Taurine plasma levels were analyzed using an HPLC-MS system consisting of an Agilent 1100 Series HPLC (Agilent Technologies, Santa Clara, CA, USA) equipped with a thermostatted μ -wellplate autosampler and a quaternary pump, and connected to an Agilent Ion Trap XCT Plus Mass Spectrometer (Agilent Technologies) using an electrospray (ESI) interface.

Samples and standards (40 μL) were injected into a Zorbax SB-Aq HPLC column (4.6 \times 150 mm, 5 μm ; Agilent Technologies), heated to 40°C , and eluted at a flow rate of 200 $\mu\text{L}/\text{min}$ during the whole separation.

Standards (Taurine; Sigma-Aldrich) were prepared in MilliQ water. Serum samples were filtered through Amicon (Merck Millipore Ltd., Tullagreen, Carrigtwohill, County of Cork, Ireland) 3K centrifugal units to eliminate proteins, and the clean filtrates were used for the analysis. Mobile phase A, consisting of 0.1% formic acid (wt/vol) in MilliQ water, and mobile phase B, consisting of 0.1% formic acid (wt/vol) in acetonitrile, were used for the chromatographic separation. The initial HPLC running conditions were solvent A:B 90:10 (vol/vol). The gradient elution program was 10% solvent B for 10 minutes; a linear gradient from 10% to 100% solvent B in 20 minutes; 10 minutes at constant 100% solvent B. The column was equilibrated with the starting composition of the mobile phase for 15 minutes before each analytical run.

The mass spectrometer was operated in the positive mode with a capillary spray voltage of 3500 V, and a scan speed of 26,000 (m/z)/s from 50 to 200 m/z (Ultrascan mode). The nebulizer gas pressure, drying gas flow rate, and drying gas temperature were set at 30 psi, 8 L/min, and 350°C. Other instrument parameters were optimized for generating the highest signal intensities. Data were obtained in the MS and MS/MS modes using multiple reaction monitoring and processed using the DataAnalysis program for LC/MSD Trap Version 3.2 (Bruker Daltonik GmbH, Bremen, Germany) provided by the manufacturer. Taurine was detected as the $[M+H]^+$ ion at 126 m/z, and confirmed with the transition 126 > 108 m/z.

The ion chromatograms of taurine from both standards and samples were extracted and the peak area was quantified using the DataAnalysis program for LC/MSD Trap Version 3.2 (Bruker Daltonik GmbH). The peak area data of standards were used for the calculation of the calibration curve, from which the concentration of taurine in samples was obtained.

Immunohistofluorescence

The retinas were dissected as whole mounts or prepared for cryostat cross sections.^{22,27} Double immunohistofluorescence staining was performed on the retinas as previously described.^{27,28} Briefly, retinas were permeated, then washed in PBS containing 0.5% Triton X-100 (Tx) and incubated overnight at 4°C with a mixture of the primary antibodies diluted in blocking buffer (2% normal donkey serum and 2% Tx in PBS). Retinas were then washed in PBS and incubated 2 hours at room temperature with a mixture of the secondary antibodies diluted in 2% Tx PBS. Primary detection was performed using antibodies against S-opsin (1:1000; N-20; goat anti-OPN1SW; Santa Cruz Biotechnology, Heidelberg, Germany), against L/M-opsin (1:1200; rabbit antiopsin red/green; Chemicon-Millipore Iberica, Madrid, Spain), against Brn3a (1:750; C-20; goat anti-Brn3a; Santa Cruz Biotechnology) and against melanopsin (1:500; rabbit anti-melanopsin; M1 and M2 subtypes; PAI-780; ThermoFisher Scientific, Madrid, Spain). For secondary detection, various antibodies were used: donkey anti-goat Alexa 594, donkey anti-rabbit Alexa 488, donkey anti-goat Alexa 488, and donkey anti-rabbit Alexa 594. All secondary antibodies were purchased from Molecular Probes (Invitrogen, ThermoFisher, Madrid, Spain) and diluted at 1:500. Finally, the retinas were washed in PBS, mounted on subbed slides, and covered with antifading mounting media (Vectashield mounting medium; Vector Laboratories, Palex Medical, Barcelona, Spain).

Retinal Image Analysis, Quantification, and Distribution of Retinal Populations

Whole-mounted retinas were examined under an epifluorescence microscope (Axioscop 2 Plus; Zeiss Mikroskopie, Jena,

Germany) equipped with a digital high-resolution camera (ProgRes C10; Jenoptik, Jena, Germany), and a computer-driven motorized stage (ProScan H128 Series; Prior Scientific Instruments, Cambridge, UK) controlled by the program Image-Pro Plus (IPP 5.1 for Windows; Media Cybernetics, Silver Spring, MD, USA) as previously described.^{19,27-31} Retinal multiframe acquisitions of the whole retinas were acquired in a raster scan pattern using a $\times 10$ objective (Plan-Neofluar, 10 \times /0.30; Zeiss Mikroskopie). Every single frame was focused manually before acquisition of the image. Depending on the size and position of the retina in the slide, the number of frames necessary to scan the whole retina varies depending on animal age, but for this study we generally needed to acquire 154 individual frames per retina. These frames were then tiled using IPP to create retinal photomontages.

Brn3a⁺RGCs and L/M- and S-opsin⁺ cones were automatically quantified in the photomontages of the entire retina following previously described methods developed in our laboratory.^{27,28,32,33} m⁺RGCs were manually dotted on the retinal images in a masked fashion and the number of dots was quantified using a specific subroutine developed by our group.^{20,24,28}

The topographical distribution of Brn3a⁺RGCs and L- and S-opsins was illustrated using isodensity maps as described. These maps are based on a detailed quantification of cell densities throughout the entire retina, which is represented as filled contour plots using a graphing software.^{27,28,32,33} The topography of m⁺RGCs was visualized using the next neighbor algorithm.^{24,28} All the topographical maps were performed using SigmaPlot (SigmaPlot 9.0 for Windows; Systat Software, Inc., Richmond, CA, USA).

Statistical Analysis

Statistical comparisons were performed using SigmaStat 3.1 for Windows (SigmaStat for Windows TM version 3.11; Systat Software, Inc.). For retinal cell populations, the ANOVA test followed by Tukey's post hoc test was used when comparing more than two groups, and the Mann-Whitney *U* test or the *t*-test when comparing two groups only. Differences were considered significant when $P < 0.05$.

RESULTS

Taurine Plasma Levels

Taurine levels were measured in plasma extracted just before euthanasia to verify the efficacy of β -alanine in depleting taurine plasma levels. Two months of treatment with β -alanine resulted in significantly lower taurine plasma levels compared with those found in control animals ($P < 0.001$; Fig. 2).

Effect of Light-induced Retinal Degeneration and/or Taurine Depletion on the S- and L-Cone Populations

In intact animals, the topography and the mean numbers \pm SD of S- (42,263 \pm 2567; $n = 10$ retinas) and L/M-cones (231,616 \pm 11,735; $n = 10$) were similar to those found in previous studies^{24,27-29,33} (Figs. 3A, 3B, 3F, 4A, 4B, 4F).

In control light-exposed animals, there was a significant decrease of 17% and 14% of the population of S- (35,297 \pm 4315; $n = 10$ retinas) and L/M-cones (200,249 \pm 10,814; $n = 10$), respectively, when compared with intact animals (Figs. 3E, 4E). Isodensity maps revealed a decrease of the warm colors for both types of cones that was more marked in the dorsal retina

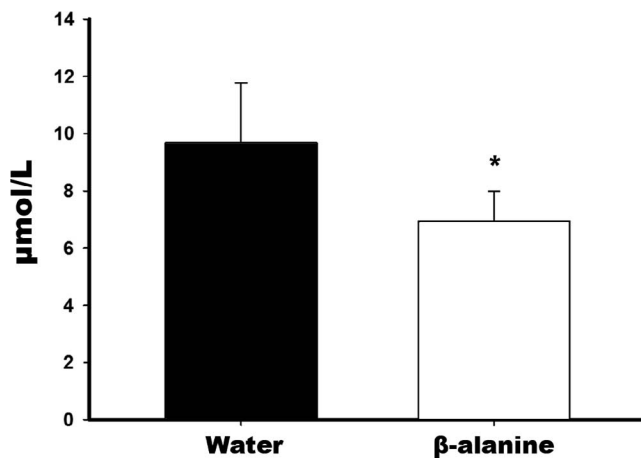


FIGURE 2. Plasma taurine concentration. Plasma taurine concentration in control rats (black bar; $n = 20$ animals) and in experimental rats after 2 months of β -alanine treatment in the drinking water (white bar; $n = 20$ animals).

(Figs. 3C, 4C), especially for L/M-cones, which show normally a higher density in the dorsal retina³³ (Fig. 4A).

In animals treated with β -alanine but not exposed to light, there was a significant reduction of both types of cones. The S- ($33,091 \pm 3565$; $n = 10$ retinas; Fig. 3F) and L/M-cones ($193,455 \pm 6358$; $n = 10$ retinas; Fig. 4F) were reduced by 22% and 17%, respectively, when compared with intact animals.

The animals treated with β -alanine and exposed to light also showed loss of both types of cones. Compared with control retinas, the mean number of S- ($28,302 \pm 4728$; $n = 10$ retinas) and L/M-cones ($178,509 \pm 11,479$; $n = 10$ retinas) decreased significantly, by approximately 34% and 23%, respectively (Figs. 3F, 4F), when compared with intact animals.

The topography of cell loss in these animals (Figs. 3D, 3E, 4D, 4E) revealed that both S- and L/M-cones decreased more in the dorsal retina.

Cone loss was confirmed by cryostat cross sections, because the outer nuclear layer showed a slight reduction in the β -alanine-treated animals compared with control animals (Figs. 5A, 5B). In the light-exposed animals, cross sections revealed a further reduction in the outer nuclear layer thickness, which is higher in the animals treated with β -alanine and exposed to light (Figs. 5C, 5D). This is in accordance with previous publications that document an earlier cone loss, and minimal rod loss, in taurine-depleted animals.⁶

In addition to cone loss, control light-exposed animals also showed a disruption of the normal photoreceptor mosaic: “empty rings” devoid of both types of cones (Fig. 6) appeared mainly in the superotemporal retina, in an area coincident with the “arciform photosensitive area” previously described by our group^{18–20} (Fig. 6A), which is the area most affected by light exposure.

The isodensity maps of the animals treated with β -alanine but not exposed to light showed a decrease of the warm colors for all the studied populations. However, the topography of cone loss was diffuse and did not show the “ring” pattern (Figs. 6H–J) observed ALE.

Light exposure in taurine-depleted animals also caused a disruption in the normal cone mosaic because rings devoid of cones appeared in the retinas. These rings were similar to those observed in control light-exposed animals, but they were

more extensive, and sometimes their borders were not clear and thus were harder to delimit (Figs. 6K–M).

Effect of Light-Induced Retinal Degeneration and/or Taurine Depletion on the Brn3a⁺RGC and m⁺RGC Populations

In intact animals, the topography and the mean numbers \pm SD of Brn3a⁺RGCs ($85,093 \pm 2935$; $n = 10$) and m⁺RGCs (2103 ± 133 ; $n = 10$), were similar to those found in previous studies^{24,27–29,33} (Figs. 7A, 7B, 7E, 8A, 8B, 8F).

In control light-exposed animals, the populations of Brn3a⁺RGCs ($84,293 \pm 2685$; $n = 10$) or m⁺RGCs (2075 ± 101 ; $n = 10$ retinas) were similar to those found in intact animals and thus were not affected by light exposure, in accordance with previously published data^{19,20} (Figs. 7E, 8F).

In animals treated with β -alanine but not exposed to light, there was a significant reduction of 15% of the Brn3a⁺RGCs ($72,978 \pm 5069$; $n = 10$ retinas; Fig. 7F) and of 41% of m⁺RGCs (1246 ± 228 ; $n = 10$ retinas; Fig. 8F).

The animals treated with β -alanine and exposed to light also showed loss of Brn3a⁺RGCs ($67,802 \pm 6095$; $n = 10$ retinas) and m⁺RGCs (1148 ± 324 ; $n = 10$ retinas) that were diminished by 21% and 46%, respectively, when compared with intact animals (Figs. 7F, 8F).

The topography of cell loss in these animals was variable: m⁺RGCs decreased more in the dorsal retina, whereas Brn3a⁺RGC cell loss decreased evenly all throughout the retina (Figs. 7D, 7E, 8D, 8E).

Comparison of the Effect of Light Exposure Between Control and Taurine-Depleted Animals

When we compared cell loss in light-exposed animals between control and taurine-depleted animals, we found that light exposure caused cone loss (Figs. 3E, 4E), but did not damage RGCs (Figs. 7E, 8F), and that light exposure under taurine depletion caused an additional loss of 17% and 9% of S- (Fig. 3F) and L/M-cones (Fig. 4F), respectively.

When we compared cell loss in taurine-depleted animals between not light exposed and light exposed, we found that taurine depletion was more harmful for S- than for L/M-cones: in taurine-depleted retinas, the loss of S- and L/M-cones was 22% and 17%, respectively, and light exposure caused a further reduction of 12% and 6% of these populations (Figs. 3F, 4F), respectively.

Thus, taurine depletion caused loss of S- and L/M-cones and Brn3a⁺RGCs and m⁺RGCs, but the two populations more severely affected were the S-cones and the m⁺RGCs and mainly in the dorsal retina.

DISCUSSION

In this work, we have characterized for the first time the effect of acute light exposure and pharmacological taurine depletion on the general population of RGCs (Brn3a⁺RGCs, related to visual function), the m⁺RGC subtype (intrinsically photosensitive and related to nonvisual function), and on the S- and L/M-cones of the rat retina. β -alanine is a competitive inhibitor of taurine to the taurine transporter activity.¹ Previous studies have shown that β -alanine treatment administered in the drinking water at a concentration of 3% causes a decline in taurine plasma levels^{34–36} and in tissues such as the hippocampus, posterior cortex, and retina, as well as in cellular taurine content^{13,14,37–40} and also that taurine depletion causes loss of retinal neurons^{6,41–45} (see below).

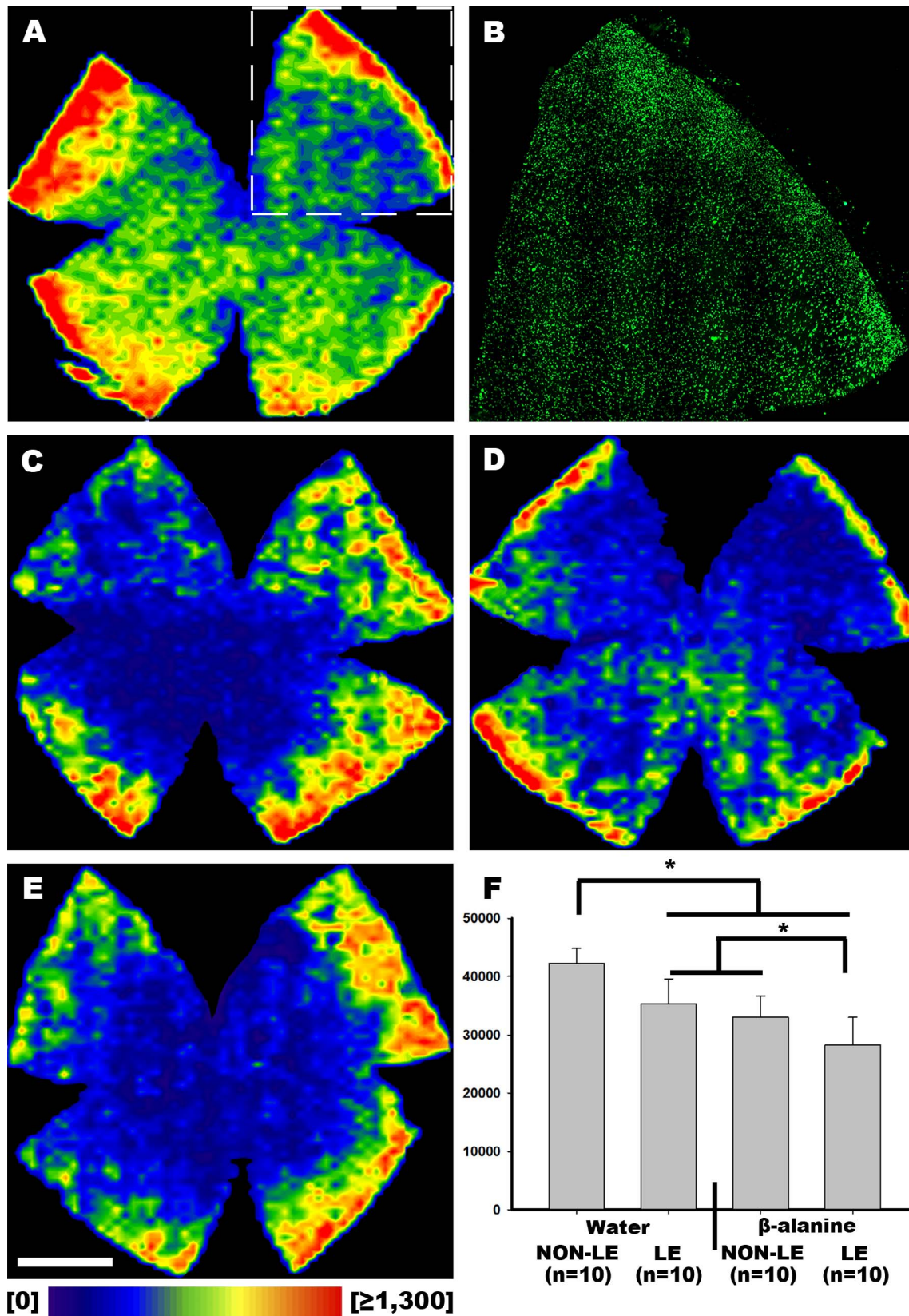


FIGURE 3. Topography of S-opsin⁺ cone loss ALE and/or under taurine depletion. (A) Representative isodensity map showing the topography of S-opsin⁺ cones in albino rats. (B) Magnification from the isodensity map in (A) showing S-cone outer segments. (C) Representative isodensity map showing the topography of S-opsin⁺ cones ALE. (D) Representative isodensity map showing the topography of S-opsin⁺ cones 2 months after β-alanine treatment. (E) Representative isodensity map showing the topography of S-opsin⁺ cones in β-alanine-treated animals ALE. (F) Graph showing the mean numbers ± SD of S-opsin⁺ cones in the control and experimental groups. Isodensity maps show the density of S-opsin⁺ cones with a color scale from 0 S-opsin⁺ cones/mm² (purple) to ≥1300 S-opsin⁺ cones/mm² (red). Scale bar: 1 mm.

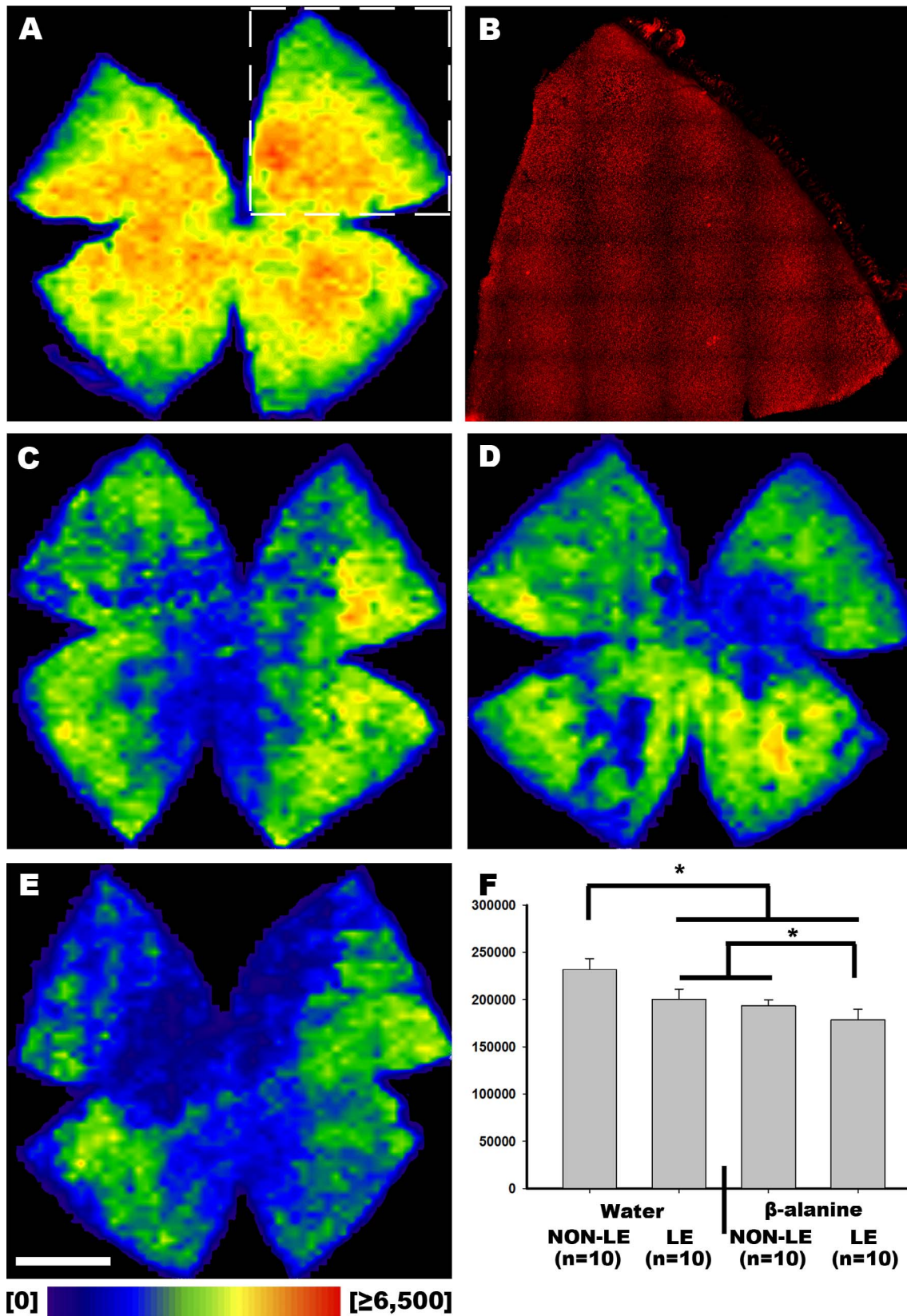


FIGURE 4. Topography of L/M-opsin⁺ cone loss ALE and/or under taurine depletion. (A) Representative isodensity map showing the topography of L/M-opsin⁺ cones in albino rats. (B) Magnification from the isodensity map in (A) showing L/M-cone outer segments. (C) Representative isodensity map showing the topography of L/M-opsin⁺ cones ALE. (D) Representative isodensity map showing the topography of L/M-opsin⁺ cones after 2 months of β-alanine treatment. (E) Representative isodensity map showing the topography of L/M-opsin⁺ cones in β-alanine-treated animals ALE. (F) Graph showing the mean numbers ± SD of L/M-opsin⁺ cones in control and experimental groups. Isodensity maps show the density of L/M-opsin⁺ cones with a color scale from 0 L/M-opsin⁺ cones/mm² (purple) to ≥6500 L/M-opsin⁺ cones/mm² (red). Scale bar: 1 mm.

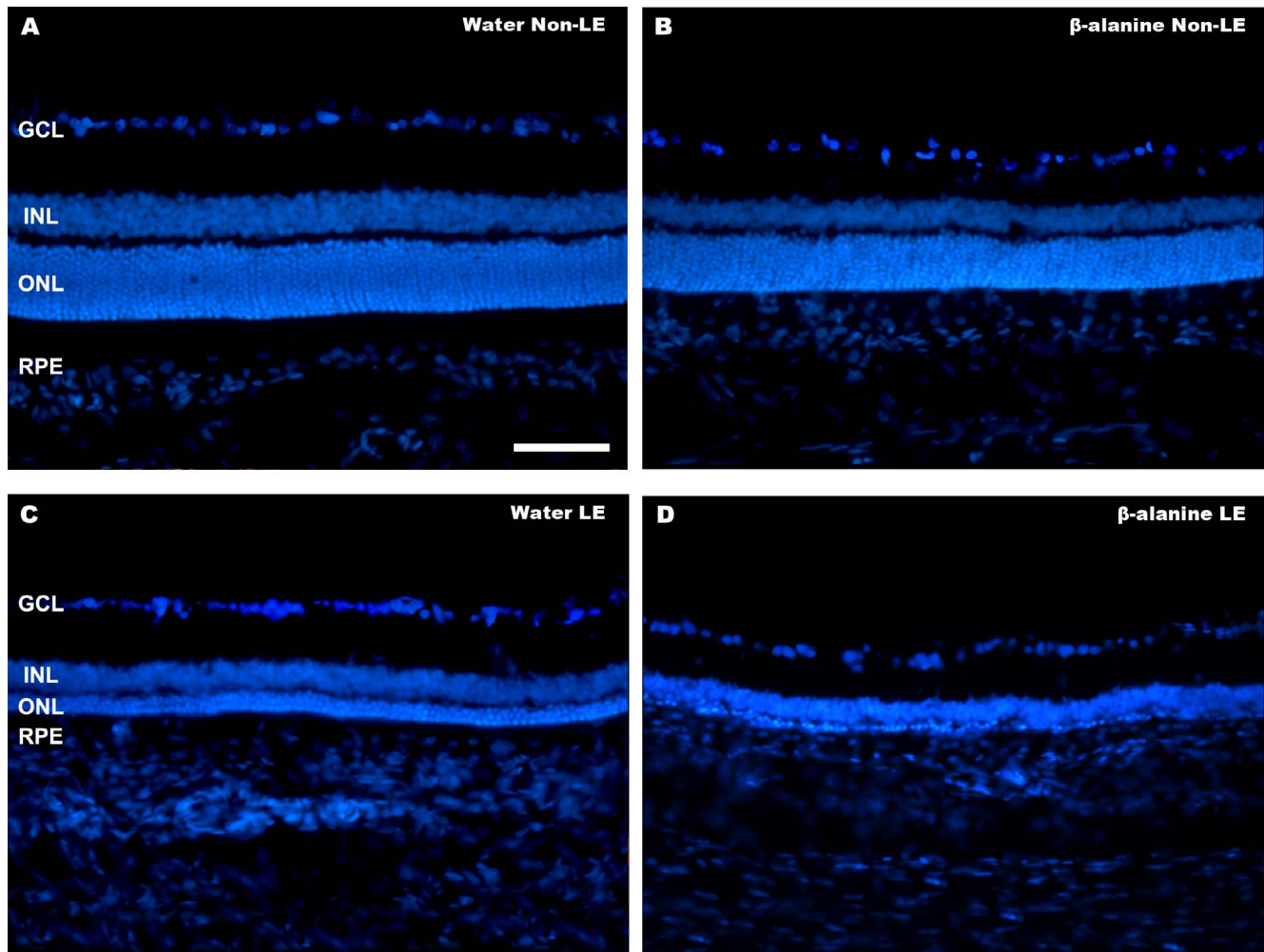


FIGURE 5. Changes in the outer nuclear layer ALE and/or under taurine depletion. Photomicrographs of representative retinal cross sections showing 4',6-diamidino-2-phenylindole (DAPI) counterstaining in the retina of a control animal (A), a β -alanine-treated animal (B), a light-exposed animal (C), and a β -alanine-treated animal ALE (D). Retinal cross sections revealed a slight reduction of the outer nuclear layer in the β -alanine-treated animals, which is increased ALE. GCL, ganglion cell layer; INL, inner nuclear layer; ONL, outer nuclear layer. Scale bar: 100 μ m.

Cone Degeneration: Contribution From Light and/or Taurine Depletion

Various authors have shown that light exposure causes photoreceptor degeneration⁴¹ both in rats^{19,44-49} and in mice.⁵⁰⁻⁵² Light is a risk factor for some retinal degenerations,⁵³⁻⁵⁶ and it accelerates photoreceptor degeneration in some inherited retinal degenerations.^{54,57-59}

In previous work,^{18-20,50} we documented that light exposure causes rapid photoreceptor degeneration and, long-term, alterations in all the retinal layers and RGC loss.¹⁸⁻²⁰ Here, we show, for the first time, that light exposure causes loss of both S- and L/M-cones, but that the loss of S-cones is greater, suggesting that S-cones are more sensitive to light damage than L/M-cones, in accordance with previously published data.^{42,60} We also show that light exposure causes a disruption of the photoreceptor mosaic, characterized by the appearance of rings devoid of cones in the superior retina, similar to those previously observed in some inherited retinal degenerations (see below).

Several studies have shown that taurine depletion, independently of its etiology, causes photoreceptor degeneration,^{6,41-43} in which cone degeneration begins earlier than rod degeneration.^{6,61} In a previous work, we showed that S-

cones were more sensitive to taurine depletion than other neurons,⁶ and we proposed that this could be because S-cones are more sensitive to blue light⁴⁵ or to oxidative stress.⁶ Taurine depletion could act synergistically with light to induce photoreceptor degeneration^{6,15-17}; however, in a previous study maintaining taurine-depleted mice in darkness slowed, but did not avoid, photoreceptor degeneration,¹⁶ suggesting that there were other intrinsic and/or extrinsic factors involved.

The blue component of white light is the most phototoxic,^{62,63} and recent studies have shown that it may cause retinal toxicity even at occupational domestic illuminance.⁴⁹ The effect of this type of light on the retina and the intrinsic and extrinsic factors that may modify this response are at present not known, but it has been postulated that they may worsen retinal degenerations, especially in conditions of low plasma taurine levels, such as in vigabatrin-induced retinal toxicity.^{4,10}

In this study, rings devoid of cones were observed ALE both in control and in taurine-depleted animals mainly in an "arciform" area of degeneration located in the dorsal retina. In previous works, we have described this "arciform area",¹⁸⁻²⁰ as the area with maximal photoreceptor loss and vascular leakage of horseradish peroxidase immediately ALE.¹⁸⁻²⁰ Interestingly, the highest densities of RGCs and L/M-cones

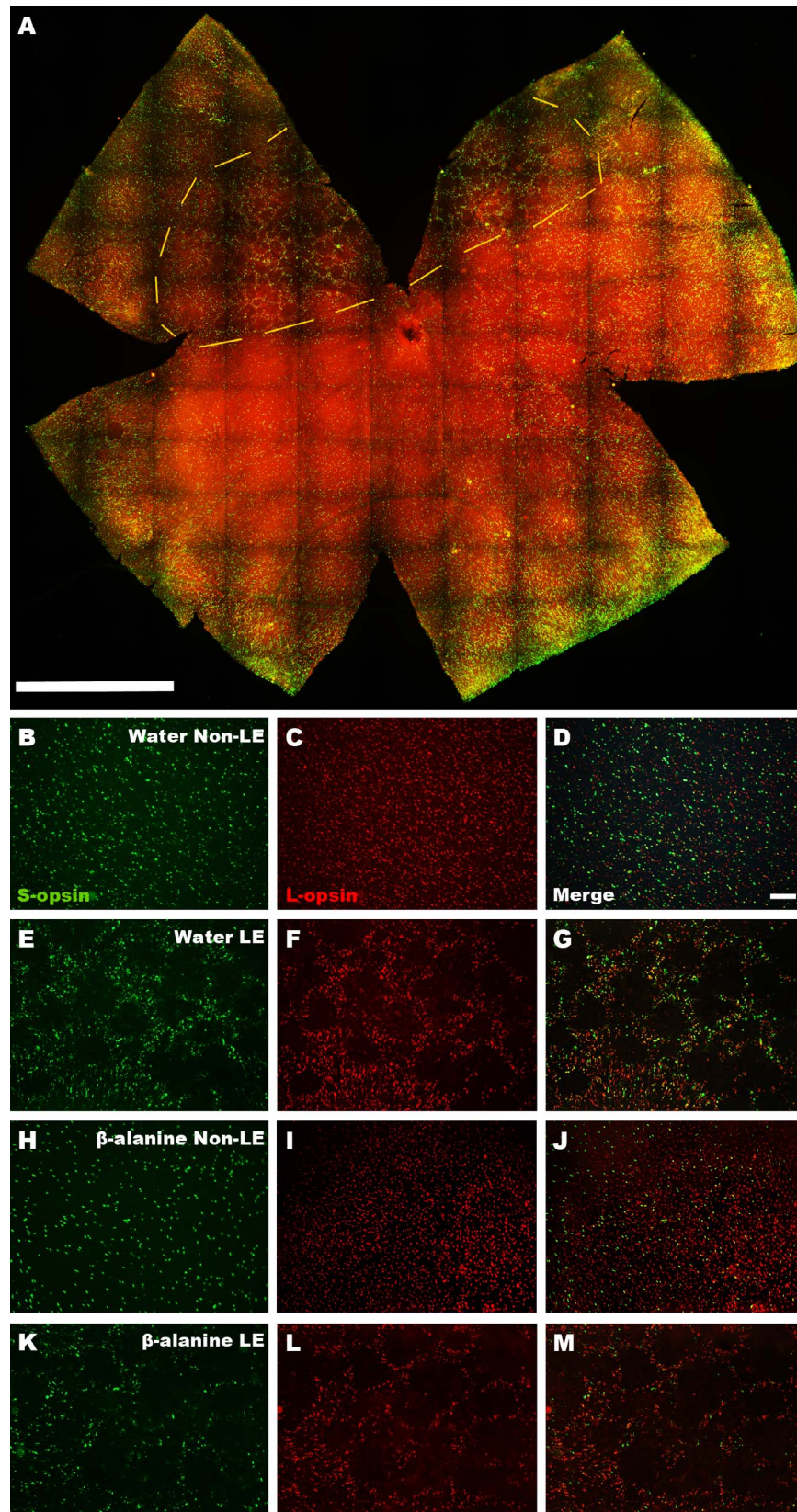


FIGURE 6. Rings of cone degeneration. (A) Photomontage of a whole-mounted retina from a nontreated light-exposed animal showing S-cones (green) and L/M-cones (red). Rings of cone degeneration can be seen in the superotemporal retina. (B–J) Magnifications from the arciform area of whole-mounted retinas showing double immunodetection of S- and L-opsin⁺ cones in control (B–D) nontreated light-exposed (E–G) and treated non-light-exposed (H–J) and light-exposed (K–M) animals. In control retinas, both types of cones are homogeneously distributed, whereas in light-exposed retinas, both types of cones delineate rings devoid of cones. Scale bar: 100 μ m.

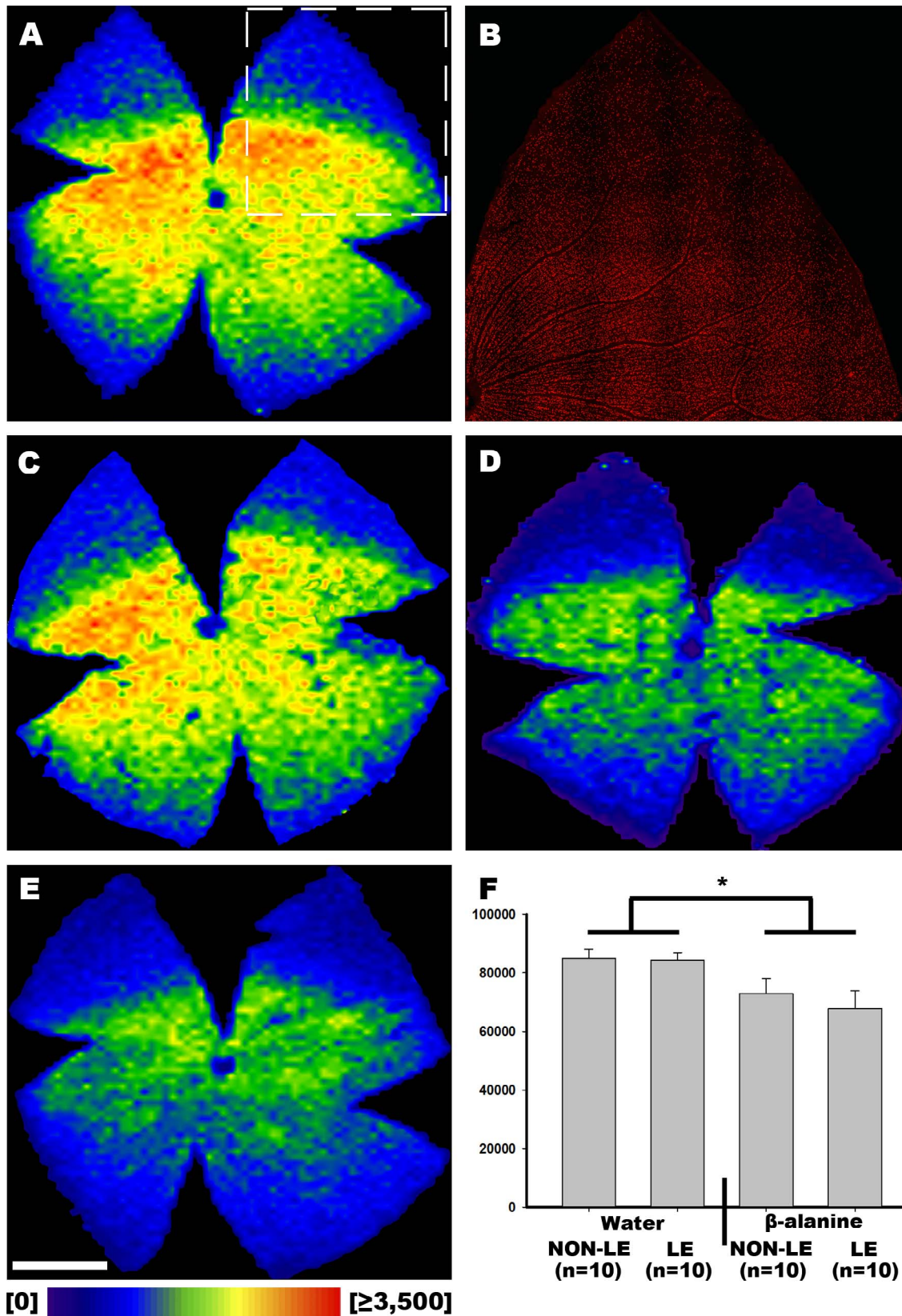


FIGURE 7. Topography of Brn3a⁺RGC loss ALE and/or under taurine depletion. (A) Representative isodensity map showing the topography of Brn3a⁺RGCs in albino rats. (B) Magnification from the isodensity map in (A) showing Brn3a⁺RGCs. (C) Representative isodensity map showing the topography of Brn3a⁺RGCs ALE. (D) Representative isodensity map showing the topography of Brn3a⁺RGCs after 2 months of β-alanine treatment. (E) Representative isodensity map showing the topography of Brn3a⁺RGCs in β-alanine-treated animals ALE. (F) Graph showing the mean numbers ± SD of Brn3a⁺RGCs in the control and experimental groups. Isodensity maps show the density of RGCs with a color scale from 0 RGCs/mm² (purple) to ≥3500 RGCs/mm² (red). Scale bar: 1 mm.

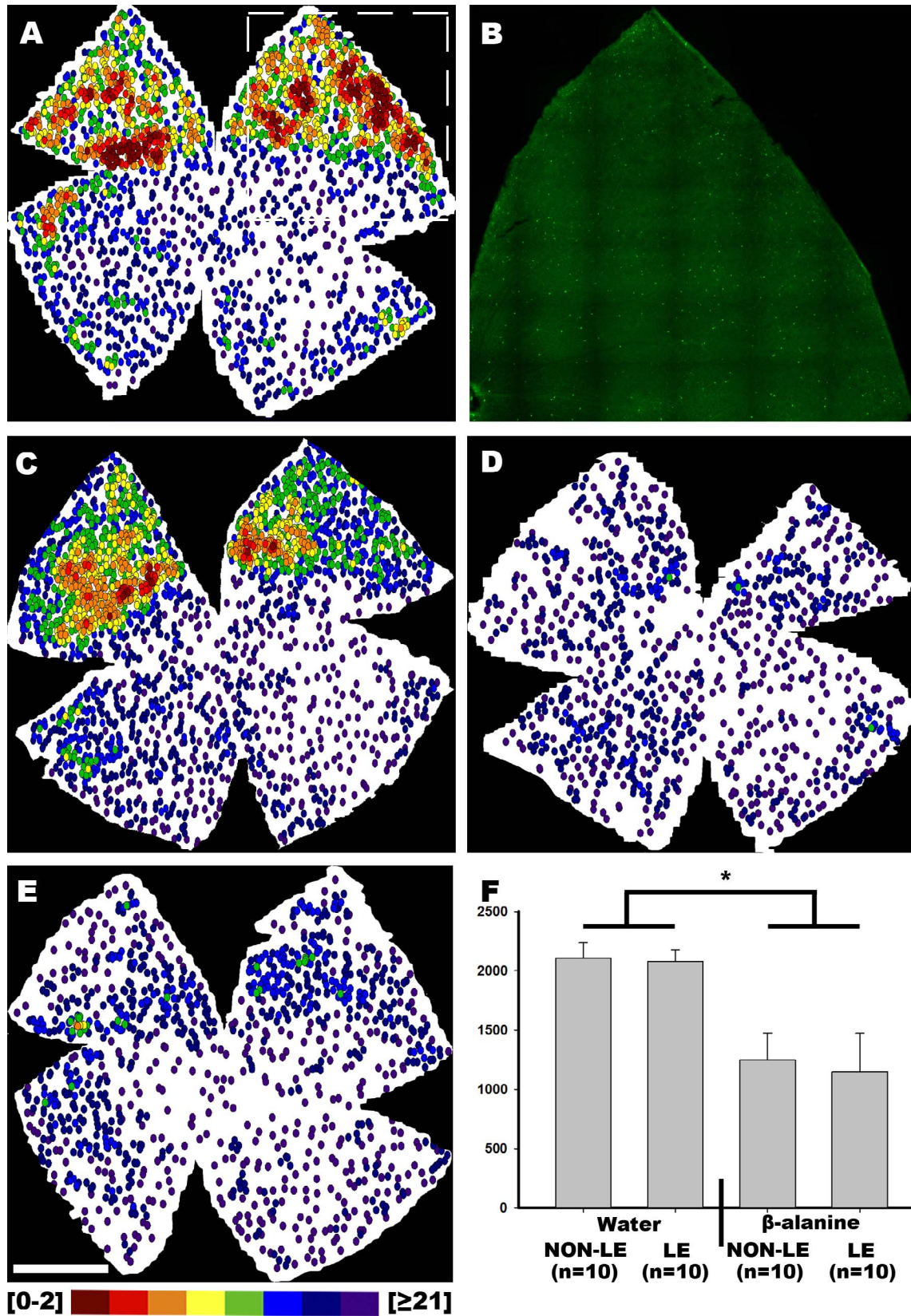


FIGURE 8. Topography of m⁺RGC loss ALE and/or under taurine depletion. (A) Representative isodensity map showing the topography of m⁺RGCs in albino rats. (B) Magnification from the isodensity map in (A) showing m⁺RGCs. (C) Representative isodensity map showing the topography of m⁺RGCs ALE. (D) Representative isodensity map showing the topography of m⁺RGCs after 2 months of β-alanine treatment. (E) Representative isodensity map showing the topography of m⁺RGCs in β-alanine-treated animals ALE. (F) Graph showing the mean number ± SD of m⁺RGCs in the control and experimental groups. In the neighbor maps, each m⁺RGC is represented by a *dot* and the color varies according to the number of its neighbors in a radius of 0.22 mm from *purple* (0-2 neighbors) to *red* (≥21 neighbors). *Scale bar*: 1 mm.

are found normally also in this area,^{33,64,65} and we have suggested that it may correspond to the rat visual streak. Other authors have also found that this is the most “photosensitive area” of the rat retina.^{66,67}

Rings of rod/cone degeneration have been previously described in rat models of inherited retinal degeneration, such as the 334ter-line-3⁶⁸⁻⁷² and the P23H-1 rat.²³ Interestingly, both these rats suffer a rhodopsin mutation that causes rod loss and secondary cone degeneration, and it is possible that these rings lacking photoreceptors may be related to a rod-cone-dependent survival mechanism.^{66,70,73-77} Indeed, healthy rods may be essential for cone survival by secreting factors such as the rod-derived cone viability factor^{73,78-80} and, thus, if rods die, cones may also die. This may also explain why in the non-light-exposed taurine-depleted animals, we were not able to see rings of cone degeneration even when there is cone loss, because taurine deficiency causes cone loss before rod alteration.^{5,9}

However, it is still unclear why the cone mosaic is reorganized into rings after photoreceptor loss. It has been suggested that cone rings could be the result of cone migration through processes of Müller cells⁸¹; whereas other authors have proposed that it is due to cone death,⁶⁸ these studies indicated that rods die in the “center of the rings” and photoreceptor (cones and rods) loss expands outward,^{27,68} suggesting an interdependence between neighboring photoreceptors.^{82,83} Thus, it is likely that rings of cone degeneration could be the result of both cone death and migration.

RGC and ipRGC Degeneration: Contributions From Light and/or Taurine Depletion

In this study, in control animals, the populations of Brn3a⁺RGC and m⁺RGC were not affected by light exposure, according to previously published data in which we show that light exposure does not affect the RGCs¹⁹ in the short-term, but causes a transient melanopsin downregulation, in an attempt to avoid excitotoxicity, that recovers in the first month ALE,²⁰ the time point used in this work.

This study and previous studies have shown RGC loss⁶ and loss of optic nerve axons⁸⁴ in taurine-depleted animals. In diseases proceeding with photoreceptor degeneration, we have shown that RGC loss is a secondary event that occurs long-term after a severe loss of photoreceptors independently of its etiology.^{18,19,22,23,85} However, in taurine-depleted animals, loss of photoreceptors, RGCs, and m⁺RGCs occurs in parallel, reflecting that they may be triggered by the activation of the same pathologic pathway, perhaps mitochondrial malfunction.^{40,86} Interestingly, m⁺RGC is the population most affected by taurine depletion.

Osborne et al.⁸⁷ suggested that light, concretely short-wavelength light, may be a contributing factor for the death of RGCs because of its negative effect on mitochondria, especially when their homeostasis is compromised (i.e., the aging retina or diseases such as diabetes or glaucoma).⁸⁸⁻⁹⁰ Taurine depletion caused by β -alanine treatment has been proposed to cause mitochondrial fragmentation and oxidative stress.⁴⁰ However, in our present study, although RGCs and m⁺RGCs are affected by taurine depletion, they are not further affected by light, whereas cones are. One interesting question is: Why are RGCs and m⁺RGCs not affected by light even under taurine depletion? We think that a possible explanation could be found in the intraretinal unmyelinated axons, because they have been proposed to be responsible for the vulnerability of RGCs to mitochondrial dysfunction.^{87,91-93} In rodents, intraocular axons contain fewer mitochondria than in the human eye, because axons are shorter in the rodent eye, and thus they are less likely to be affected by light,⁸⁷ even under taurine

depletion. In addition, it has been proposed that melanopsin may not only provide m⁺RGCs the capacity to respond to light, but also to protect them from the damaging effects of light.^{87,93} Thus, another intriguing question is whether taurine depletion is causing m⁺RGC death or a transient melanopsin downregulation, because we cannot rule out the possibility that taurine depletion induces melanopsin downregulation as observed ALE²⁰; however, further studies are needed to clarify this fact.

Some studies have shown that taurine supplementation may restore the damaging effects of β -alanine treatment,^{40,86,94} but to date no study has proven this in the retina. Our hypothesis is that taurine supplementation would prevent the retinal degenerative processes, as it was observed in previous works where taurine depletion was induced by vigabatrin treatment,^{4,10} but future studies should test this possibility.

In summary, our results document that taurine is necessary for cell survival in the rat retina in normal conditions and especially ALE. This suggests that taurine supplementation may be beneficial to prevent retinal degenerations that proceed with photoreceptor or RGC loss and in which light may also be a critical etiologic factor, such as inherited retinal degeneration, AMD, or glaucoma.^{10,22,95,96} Finally, our data also suggest that taurine supplementation may be beneficial to prevent retinal degenerations in which S-cone degeneration is the initial event, such as the photoreceptor degenerations that are initiated or worsened by light.

Acknowledgments

The authors thank Ana Martínez Vacas for his help and Alejandro Torrecillas Sánchez for his excellent technical help with the HPLC analysis.

Supported by grants from Fundación Séneca, Agencia de Ciencia y Tecnología Región de Murcia (19881/GERM/15), Spanish Ministry of Economy and Competitiveness, Instituto de Salud Carlos III, Fondo Europeo de Desarrollo Regional “Una Manera de Hacer Europa” (SAF2015-67643-P, PI16/00380, RD16/0008/0026, PI16/00031), and from Light4Deaf. This work performed in the frame of the RHU LIGHT4DEAF (ANR-15-RHU-0001) was supported by French state funds managed by the ANR within the Investissements d’Avenir programme and Optoremod. This work performed in the frame of the OPTOREMODE project (ANR-13-RARE-0004-01) was supported by funds managed by the ANR and Chronomofos: ANR-12-TECS-0013.

Disclosure: **D. García-Ayuso**, None; **J. Di Pierdomenico**, None; **W. Hadj-Said**, None; **M. Marie**, None; **M. Agudo-Barriuso**, None; **M. Vidal-Sanz**, None; **S. Picaud**, None; **M.P. Villegas-Pérez**, None

References

1. Froger N, Moutsimilli L, Cadetti L, et al. Taurine: the comeback of a nutraceutical in the prevention of retinal degenerations. *Prog Retin Eye Res.* 2014;41C:44–63.
2. Hayes KC, Carey RE, Schmidt SY. Retinal degeneration associated with taurine deficiency in the cat. *Science.* 1975; 188:949–951.
3. Neuringer M, Sturman J. Visual acuity loss in rhesus monkey infants fed a taurine-free human infant formula. *J Neurosci Res.* 1987;18:597–601.
4. Jammoul F, Degardin J, Pain D, et al. Taurine deficiency damages photoreceptors and retinal ganglion cells in vigabatrin-treated neonatal rats. *Mol Cell Neurosci.* 2010;43:414–421.
5. Gaucher D, Arnault E, Husson Z, et al. Taurine deficiency damages retinal neurones: cone photoreceptors and retinal ganglion cells. *Amino Acids.* 2012;43:1979–1993.

6. Hadj-Saïd W, Froger N, Ivkovic I, et al. Quantitative and topographical analysis of the losses of cone photoreceptors and retinal ganglion cells under taurine depletion. *Invest Ophthalmol Vis Sci.* 2016;57:4692-4703.
7. Geggel HS, Ament ME, Heckenlively JR, Martin DA, Kopple JD. Nutritional requirement for taurine in patients receiving long-term parenteral nutrition. *N Engl J Med.* 1985;312:142-146.
8. Ament ME, Geggel HS, Heckenlively JR, Martin DA, Kopple J. Taurine supplementation in infants receiving long-term total parenteral nutrition. *J Am Coll Nutr.* 1986;5:127-135.
9. Jammoul F, Wang Q, Nabbout R, et al. Taurine deficiency is a cause of vigabatrin-induced retinal phototoxicity. *Ann Neurol.* 2009;65:98-107.
10. Tao Y, Yang J, Ma Z, et al. The vigabatrin induced retinal toxicity is associated with photopic exposure and taurine deficiency: an in vivo study. *Cell Physiol Biochem.* 2016;40:831-846.
11. Horvath GA, Hukin J, Stockler-Ipsiroglu SG, Aroichane M. Eye findings on vigabatrin and taurine treatment in two patients with succinic semialdehyde dehydrogenase deficiency. *Neuropediatrics.* 2016;47:263-267.
12. Pasantes-Morales H, Quesada O, Carabez A, Huxtable RJ. Effects of the taurine transport antagonist, guanidinoethane sulfonate, and beta-alanine on the morphology of rat retina. *J Neurosci Res.* 1983;9:135-143.
13. González-Quevedo A, Obregón F, Urbina M, Roussó T, Lima L. Effects of taurine deficiency and chronic methanol administration on rat retina, optic nerve and brain amino acids and monoamines. *Nutr Neurosci.* 2003;6:253-261.
14. Horvath DM, Murphy RM, Mollica JP, Hayes A, Goodman CA. The effect of taurine and β -alanine supplementation on taurine transporter protein and fatigue resistance in skeletal muscle from mdx mice. *Amino Acids.* 2016;48:2635-2645.
15. Cocker SE, Lake N. Effects of dark maintenance on retinal biochemistry and function during taurine depletion in the adult rat. *Vis Neurosci.* 1989;3:33-38.
16. Rascher K, Servos G, Berthold G, et al. Light deprivation slows but does not prevent the loss of photoreceptors in taurine transporter knockout mice. *Vision Res.* 2004;44:2091-2100.
17. Rapp LM, Thum LA, Anderson RE. Synergism between environmental lighting and taurine depletion in causing photoreceptor cell degeneration. *Exp Eye Res.* 1988;46:229-238.
18. Marco-Gomariz MA, Hurtado-Montalbán N, Vidal-Sanz M, Lund RD, Villegas-Pérez MP. Phototoxic-induced photoreceptor degeneration causes retinal ganglion cell degeneration in pigmented rats. *J Comp Neurol.* 2006;498:163-179.
19. García-Ayuso D, Salinas-Navarro M, Agudo-Barriuso M, Alarcón-Martínez L, Vidal-Sanz M, Villegas-Pérez MP. Retinal ganglion cell axonal compression by retinal vessels in light-induced retinal degeneration. *Mol Vis.* 2011;17:1716-1733.
20. García-Ayuso D, Galindo-Romero C, Di Pierdomenico J, Vidal-Sanz M, Agudo-Barriuso M, Villegas Pérez MP. Light-induced retinal degeneration causes a transient downregulation of melanopsin in the rat retina. *Exp Eye Res.* 2017;161:10-16.
21. Vidal-Sanz M, Nadal-Nicolás FM, Valiente-Soriano FJ, Agudo-Barriuso M, Villegas-Pérez MP. Identifying specific RGC types may shed light on their idiosyncratic responses to neuroprotection. *Neural Regen Res.* 2015;10:1228-1230.
22. García-Ayuso D, Salinas-Navarro M, Agudo M, et al. Retinal ganglion cell numbers and delayed retinal ganglion cell death in the P23H rat retina. *Exp Eye Res.* 2010;91:800-810.
23. García-Ayuso D, Salinas-Navarro M, Nadal-Nicolás FM, et al. Sectorial loss of retinal ganglion cells in inherited photoreceptor degeneration is due to RGC death. *Br J Ophthalmol.* 2014;98:396-401.
24. Galindo-Romero C, Jiménez-López M, García-Ayuso D, et al. Number and spatial distribution of intrinsically photosensitive retinal ganglion cells in the adult albino rat. *Exp Eye Res.* 2013;108:84-93.
25. González-Menéndez I, Contreras F, Cernuda-Cernuda R, García-Fernández JM. Daily rhythm of melanopsin-expressing cells in the mouse retina. *Front Cell Neurosci.* 2009;3:3.
26. Hannibal J, Georg B, Fahrenkrug J. Differential expression of melanopsin mRNA and protein in Brown Norwegian rats. *Exp Eye Res.* 2013;106:55-63.
27. García-Ayuso D, Ortín-Martínez A, Jiménez-López M, et al. Changes in the photoreceptor mosaic of P23H-1 rats during retinal degeneration: implications for rod-cone dependent survival. *Invest Ophthalmol Vis Sci.* 2013;54:5888-5900.
28. García-Ayuso D, Di Pierdomenico J, Esquivá G, et al. Inherited photoreceptor degeneration causes the death of melanopsin-positive retinal ganglion cells and increases their coexpression of Brn3a. *Invest Ophthalmol Vis Sci.* 2015;56:4592-4604.
29. Nadal-Nicolás FM, Salinas-Navarro M, Jiménez-López M, et al. Displaced retinal ganglion cells in albino and pigmented rats. *Front Neuroanat.* 2014;8:99.
30. Nadal-Nicolás FM, Madeira MH, Salinas-Navarro M, et al. Transient downregulation of melanopsin expression after retrograde tracing or optic nerve injury in adult rats. *Invest Ophthalmol Vis Sci.* 2015;56:4309-4323.
31. Vidal-Sanz M, Galindo-Romero C, Valiente-Soriano FJ, et al. Shared and differential retinal responses against optic nerve injury and ocular hypertension. *Front Neurosci.* 2017;11:235.
32. Nadal-Nicolás FM, Jiménez-López M, Sobrado-Calvo P, et al. Brn3a as a marker of retinal ganglion cells: qualitative and quantitative time course studies in naive and optic nerve-injured retinas. *Invest Ophthalmol Vis Sci.* 2009;50:3860-3868.
33. Ortín-Martínez A, Jiménez-López M, Nadal-Nicolás FM, et al. Automated quantification and topographical distribution of the whole population of S- and L-cones in adult albino and pigmented rats. *Invest Ophthalmol Vis Sci.* 2010;51:3171-3183.
34. Parildar-Karpuzoğlu H, Doğru-Abbasoğlu S, Balkan J, Aykaç-Toker G, Uysal M. Decreases in taurine levels induced by beta-alanine treatment did not affect the susceptibility of tissues to lipid peroxidation. *Amino Acids.* 2007;32:115-119.
35. Khimsuksri S, Wyss JM, Thaeomor A, Paphangkorakit J, Jirakulsomchok D, Roysommuti S. Perinatal taurine exposure programs patterns of autonomic nerve activity responses to tooth pulp stimulation in adult male rats. *Adv Exp Med Biol.* 2013;775:121-134.
36. Roysommuti S, Lerdweeraphon W, Michael Wyss J. Perinatal taurine imbalance followed by high saugar intake alters the effects of estrogen on renal excretory function in adult female rats. *Adv Exp Med Biol.* 2017;975:769-787.
37. Starr MS, Voaden MJ. The uptake, metabolism and release of 14 C-taurine by rat retina in vitro. *Vision Res.* 1972;12:1261-1269.
38. Sturman JA, Messing JM. Depletion of feline taurine levels by b-alanine and dietary taurine restriction. *Nutr Res.* 1996;16:789-795.
39. Jong CJ, Ito T, Mozaffari M, Azuma J, Schaffer S. Effect of beta-alanine treatment on mitochondrial taurine level and 5-taurinomethyluridine content. *J Biomed Sci.* 2010;17:S25.
40. Shetewy A, Shimada-Takaura K, Warner D, et al. Mitochondrial defects associated with β -alanine toxicity: relevance to hyper-beta-alaninemia. *Mol Cell Biochem.* 2016;416:11-22.
41. Lake N, Malik N. Retinal morphology in rats treated with a taurine transport antagonist. *Exp Eye Res.* 1987;44:331-346.

42. Heller-Stilb B, Van Roeyen C, Rascher K, et al. Disruption of the taurine transporter gene (*taut*) leads to retinal degeneration in mice. *FASEB J*. 2002;16:231-233.
43. Leon A, Levick WR, Sarossy MG. Lesion topography and new histological features in feline taurine deficiency retinopathy. *Exp Eye Res*. 1995;61:731-741.
44. Organisciak DT, Vaughan DK. Retinal light damage: mechanisms and protection. *Prog Retin Eye Res*. 2010;29:113-134.
45. Ortín-Martínez A, Valiente-Soriano FJ, García-Ayuso D, et al. A novel in vivo model of focal light emitting diode-induced cone-photoreceptor phototoxicity: neuroprotection afforded by brimonidine, BDNF, PEDF or bFGF. *PLoS One*. 2014;9:e113798.
46. Polosa A, Liu W, Lachapelle P. Retinotopic distribution of structural and functional damages following bright light exposure of juvenile rats. *PLoS One*. 2016;11:e0146979.
47. Polosa A, Bessaklia H, Lachapelle P. Strain differences in light-induced retinopathy. *PLoS One*. 2016;29;11:e0158082.
48. Polosa A, Bessaklia H, Lachapelle P. Light-induced retinopathy: young age protects more than ocular pigmentation. *Curr Eye Res*. 2017;31:1-12.
49. Krigel A, Berdugo M, Picard E, et al. Light-induced retinal damage using different light sources, protocols and rat strains reveals LED phototoxicity. *Neuroscience*. 2016;339:296-307.
50. Montalbán-Soler L, Alarcón-Martínez L, Jiménez-López M, et al. Retinal compensatory changes after light damage in albino mice. *Mol Vis*. 2012;18:675-693.
51. Natoli R, Jiao H, Barnett NL, et al. A model of progressive photo-oxidative degeneration and inflammation in the pigmented C57BL/6J mouse retina. *Exp Eye Res*. 2016;147:114-127.
52. Kamoshita M, Toda E, Osada H, et al. Lutein acts via multiple antioxidant pathways in the photo-stressed retina. *Sci Rep*. 2016;6:30226.
53. Behar-Cohen F, Martinsons C, Vienot F, et al. Light-emitting diodes (LED) for domestic lighting: any risks for the eye? *Prog Retin Eye Res*. 2011;30:239-257.
54. Wright AF, Chakarova CF, Abd El-Aziz MM, Bhattacharya SS. Photoreceptor degeneration: genetic and mechanistic dissection of a complex trait. *Nat Rev Genet*. 2010;11:273-284.
55. Sui GY, Liu GC, Liu GY, et al. Is sunlight exposure a risk factor for age-related macular degeneration? A systematic review and meta-analysis. *Br J Ophthalmol*. 2013;97:389-394.
56. Arnault E, Barrau C, Nanteau C, et al. Phototoxic action spectrum on a retinal pigment epithelium model of age-related macular degeneration exposed to sunlight normalized conditions. *PLoS One*. 2013;8:e71398.
57. Chrysostomou V, Valter K, Stone J. Cone-rod dependence in the rat retina: variation with the rate of rod damage. *Invest Ophthalmol Vis Sci*. 2009;50:3017-3023.
58. Valter K, Kirk DK, Stone J. Optimising the structure and function of the adult P23H-3 retina by light management in the juvenile and adult. *Exp Eye Res*. 2009;89:1003-1011.
59. Organisciak DT, Darrow RM, Barsalou L, Kutty RK, Wiggert B. Susceptibility to retinal light damage in transgenic rats with rhodopsin mutations. *Invest Ophthalmol Vis Sci*. 2003;44:486-492.
60. Zhang T, Zhang N, Baehr W, Fu Y. Cone opsin determines the time course of cone photoreceptor degeneration in Leber congenital amaurosis. *Proc Natl Acad Sci U S A*. 2011;108:8879-8884.
61. Duboc A, Hanoteau N, Simonutti M, et al. Vigabatrin, the GABA-transaminase inhibitor, damages cone photoreceptors in rats. *Ann Neurol*. 2004;55:695-705.
62. Algyere PV, Marshall J, Seregard S. Age-related maculopathy and the impact of blue light hazard. *Acta Ophthalmol Scand* 2006;84:4-15.
63. Busch EM, Gorgels TG, van Norren D. Temporal sequence of changes in rat retina after UV-A and blue light exposure. *Vision Res*. 1999;39:1233-1247.
64. Salinas-Navarro M, Mayor-Torroglosa S, Jiménez-López M, et al. A computerized analysis of the entire retinal ganglion cell population and its spatial distribution in adult rats. *Vision Res*. 2009;49:115-126.
65. Vidal-Sanz M, Salinas-Navarro M, Nadal-Nicolás FM, et al. Understanding glaucomatous damage: anatomical and functional data from ocular hypertensive rodent retinas. *Prog Retin Eye Res*. 2012;31:1-27.
66. Marc RE, Jones BW, Watt CB, Vazquez-Chona F, Vaughan DK, Organisciak DT. Extreme retinal remodeling triggered by light damage: implications for age related macular degeneration. *Mol Vis*. 2008;14:782-806.
67. Tanito M, Kaidzu S, Anderson RE. Delayed loss of cone and remaining rod photoreceptor cells due to impairment of choroidal circulation after acute light exposure in rats. *Invest Ophthalmol Vis Sci*. 2007;48:1864-1872.
68. Li Y, Tao W, Luo L. CNTF induces regeneration of cone outer segments in a rat model of retinal degeneration. *PLoS One*. 2010;5:e9495.
69. Xia X, Li Y, Huang D. Oncostatin M protects rod and cone photoreceptors and promotes regeneration of cone outer segment in a rat model of retinal degeneration. *PLoS One*. 2011;6:e18282.
70. Ji Y, Zhu CL, Grzywacz NM, Lee EJ. Rearrangement of the cone mosaic in the retina of the rat model of retinitis pigmentosa. *J Comp Neurol*. 2012;520:874-888.
71. Hombrebueno JR, Tsai MM, Kim HL, De Juan J, Grzywacz NM, Lee EJ. Morphological changes of short-wavelength cones in the developing S334ter-3 transgenic rat. *Brain Res*. 2010;1321:60-66.
72. Yu WQ, Eom YS, Shin JA, et al. Reshaping the cone-mosaic in a rat model of retinitis pigmentosa: modulatory role of ZO-1 expression in DL-alpha-aminoacidipic acid reshaping. *PLoS One*. 2016;11:e0151668.
73. Léveillard T, Mohand-Saïd S, Lorentz O. Identification and characterization of rod-derived cone viability factor. *Nat Genet*. 2004;36:755-759.
74. Marc RE, Jones BW, Watt CB, Strettoi E. Neural remodeling in retinal degeneration. *Prog Retin Eye Res*. 2003;22:607-655.
75. Stone J, Maslim J, Valter-Kocsi K. Mechanisms of photoreceptor death and survival in mammalian retina. *Prog Retin Eye Res*. 1999;18:689-735.
76. Zhu CL, Ji Y, Lee EJ, Grzywacz NM. Spatiotemporal pattern of rod degeneration in the S334ter-line-3 rat model of retinitis pigmentosa. *Cell Tissue Res*. 2013;351:29-40.
77. Ripps H. Cell death in retinitis pigmentosa: gap junctions and the 'bystander' effect. *Exp Eye Res*. 2002;74:327-336.
78. Mohand-Saïd S, Deudon-Combe A, Hicks D, et al. Normal retina releases a diffusible factor stimulating cone survival in the retinal degeneration mouse. *Proc Natl Acad Sci U S A*. 1998;95:8357-8362.
79. Cronin T, Raffelsberger W, Lee-Rivera I, et al. The disruption of the rod-derived cone viability gene leads to photoreceptor dysfunction and susceptibility to oxidative stress. *Cell Death Differ*. 2010;17:1199-1210.
80. Mei X, Chaffiol A, Kole C, et al. The thioredoxin encoded by the rod-derived cone viability factor gene protects cone photoreceptors against oxidative stress. *Antioxid Redox Signal*. 2016;24:909-923.
81. Lee EJ, Ji Y, Zhu CL, Grzywacz NM. Role of Müller cells in cone mosaic rearrangement in a rat model of retinitis pigmentosa. *Glia*. 2011;59:1107-1117.
82. Huang PC, Gaitan AE, Hao Y, Petters RM, Wong F. Cellular interactions implicated in the mechanism of photoreceptor

- degeneration in transgenic mice expressing a mutant rhodopsin gene. *Proc Natl Acad Sci USA*. 1993;90:8484-8488.
83. Kedzierski W, Bok D, Travis GH. Non-cell-autonomous photoreceptor degeneration in rods mutant mice mosaic for expression of a rescue transgene. *J Neurosci*. 1998;18:4076-4082.
 84. Lake N, Malik N, De Marte L. Taurine depletion leads to loss of rat optic nerve axons. *Vision Res*. 1988;28:1071-1076.
 85. Villegas-Perez MP, Lawrence JM, Vidal-Sanz M, Lavail MM, Lund RD. Ganglion cell loss in RCS rat retina: a result of compression of axons by contracting intraretinal vessels linked to the pigment epithelium. *J Comp Neurol*. 1998;392:58-77.
 86. Jong CJ, Azuma J, Schaffer S. Mechanism underlying the antioxidant activity of taurine: prevention of mitochondrial oxidant production. *Amino Acids*. 2012;42:2223-2232.
 87. Osborne NN, Núñez-Álvarez C, Del Olmo-Aguado S. The effect of visual blue light on mitochondrial function associated with retinal ganglion cells. *Exp Eye Res*. 2014;128:8-14.
 88. Godley BE, Shamsi FA, Liang FQ, Jarrett SG, Davies S, Boulton M. Blue light induces mitochondrial DNA damage and free radical production in epithelial cells. *J Biol Chem*. 2005;280:21061-21066.
 89. Osborne NN, Lascaratos G, Bron AJ, et al. A hypothesis to suggest that light is a risk factor in glaucoma and the mitochondrial optic neuropathies. *Br J Ophthalmol*. 2006;90:237-241.
 90. Osborne NN, Kamalden TA, Majid AS, del Olmo-Aguado S, Manso AG, Ji D. Light effects on mitochondrial photosensitizers in relation to retinal degeneration. *Neurochem Res*. 2010;35:2027-2034.
 91. Yu-Wai-Man P, Griffiths PG, Chinnery PF. Mitochondrial optic neuropathies disease mechanisms and therapeutic strategies. *Prog Retin Eye Res*. 2011;30:81-114.
 92. Sadun AA, La Morgia C, Carelli V. Mitochondrial optic neuropathies: our travels from bench to bedside and back again. *Clin Exp Ophthalmol*. 2013;41:702-712.
 93. Georg B, Ghelli A, Giordano C, et al. Melanopsin-expressing retinal ganglion cells are resistant to cell injury, but not always. *Mitochondrion*. 2017;17:30087-30089.
 94. Kulthinee S, Rakmanee S, Michael Wyss J, Roysommuti S. Taurine supplementation ameliorates the adverse effects of perinatal taurine depletion and high sugar intake on cardiac ischemia/reperfusion injury of adult female rats. *Adv Exp Med Biol*. 2017;975:741-755.
 95. Froger N, Cadetti L, Lorach H, et al. Taurine provides neuroprotection against retinal ganglion cell degeneration. *PLoS One*. 2012;7:e42017.
 96. Froger N, Jammoul F, Gaucher D, et al. Taurine is a crucial factor to preserve retinal ganglion cell survival. *Adv Exp Med Biol*. 2013;775:69-83.