



HAL
open science

Association Between Vision and Brain Cortical Thickness in a Community-Dwelling Elderly Cohort

Chloé Chamard, Jerome J. Maller, Nicolas Menjot, Eloi Debourdeau, Virginie Nael, Karen Ritchie, Isabelle Carrière, Vincent Daien

► **To cite this version:**

Chloé Chamard, Jerome J. Maller, Nicolas Menjot, Eloi Debourdeau, Virginie Nael, et al.. Association Between Vision and Brain Cortical Thickness in a Community-Dwelling Elderly Cohort. *Eye and Brain*, 2022, 14, pp.71-82. 10.2147/EB.S358384 . inserm-03723682

HAL Id: inserm-03723682

<https://inserm.hal.science/inserm-03723682v1>

Submitted on 5 Feb 2024

HAL is a multi-disciplinary open access archive for the deposit and dissemination of scientific research documents, whether they are published or not. The documents may come from teaching and research institutions in France or abroad, or from public or private research centers.

L'archive ouverte pluridisciplinaire **HAL**, est destinée au dépôt et à la diffusion de documents scientifiques de niveau recherche, publiés ou non, émanant des établissements d'enseignement et de recherche français ou étrangers, des laboratoires publics ou privés.



Distributed under a Creative Commons Attribution - NonCommercial 4.0 International License

Association Between Vision and Brain Cortical Thickness in a Community-Dwelling Elderly Cohort

Chloé Chamard^{1,2}, Jerome J Maller^{3,4}, Nicolas Menjot⁵, Eloi Debourdeau¹, Virginie Nael⁶, Karen Ritchie^{2,7}, Isabelle Carriere^{2,*}, Vincent Daien^{1,2,8,*}

¹Department of Ophthalmology, Gui de Chauliac Hospital, Montpellier, F-34000, France; ²Institute for Neurosciences of Montpellier INM, University Montpellier, INSERM, Montpellier, F-34091, France; ³General Electric Healthcare, Melbourne, VIC, Australia; ⁴Monash Alfred Psychiatry Research Centre, Melbourne, VIC, Australia; ⁵Department of Neuroradiology, Gui de Chauliac Hospital, Montpellier, F-34000, France; ⁶Bordeaux Population Health Research Center, UMR 1219, University Bordeaux, INSERM, Bordeaux, F-33000, France; ⁷Department of Clinical Brain Sciences, University of Edinburgh, Edinburgh, UK; ⁸The Save Sight Institute, Sydney Medical School, the University of Sydney, Sydney, NSW, Australia

*These authors contributed equally to this work

Correspondence: Chloé Chamard, Department of Ophthalmology, Gui de Chauliac Hospital, 80 avenue Augustin Fliche, Montpellier, F-34000, France, Tel +33 6 33 55 65 06, Email chloe.chamard@gmail.com

Purpose: Visual impairment is a major cause of disability and impairment of cognitive function in older people. Brain structural changes associated with visual function impairment are not well understood. The objective of this study was to assess the association between visual function and cortical thickness in older adults.

Methods: Participants were selected from the French population-based ESPRIT cohort of 2259 community-dwelling adults ≥ 65 years old enrolled between 1999 and 2001. We considered visual function and brain MRI images at the 12-year follow-up in participants who were right-handed and free of dementia and/or stroke, randomly selected from the whole cohort. High-resolution structural T1-weighted brain scans acquired with a 3-Tesla scanner. Regional reconstruction and segmentation involved using the FreeSurfer image-analysis suite.

Results: A total of 215 participants were included (mean [SD] age 81.8 [3.7] years; 53.0% women): 30 (14.0%) had central vision loss and 185 (86.0%) normal central vision. Vision loss was associated with thinner cortical thickness in the right insula (within the lateral sulcus of the brain) as compared with the control group (mean thickness 2.38 [0.04] vs 2.50 [0.03] mm, 4.8% thinning, $p_{\text{corrected}} = 0.04$) after adjustment for age, sex, lifetime depression and cardiovascular disease.

Conclusion: The present study describes a significant thinning of the right insular cortex in older adults with vision loss. The insula subserves a wide variety of functions in humans ranging from sensory and affective processing to high-level cognitive processing. Reduced insula thickness associated with vision loss may increase cognitive burden in the ageing brain.

Keywords: visual function, vision, cortical thickness, brain, morphometry, MRI

Introduction

Visual impairment is a major cause of disability and institutionalization in older people.¹ It has also been associated with depression and cognitive function, but its effect on brain structure remains relatively unknown.^{2,3}

Recently, voxel-based morphometry (VBM) and surface-based morphometry (SBM) have been used to quantitatively describe structural modifications on MRI brain scans associated with ophthalmic diseases. Several studies have demonstrated lower cortical volume and density in the primary visual cortex and prefrontal cortex in advanced glaucoma.⁴ Amblyopia has also been associated with lower cortical volume in visual areas, which may indicate developmental abnormalities of the visual cortex during the critical growth period.⁵ In 12 patients undergoing cataract surgery, Lou et al demonstrated increased cortical volume in the contralateral primary visual cortex after visual restoration.⁶ Beer et al

further suggested that ophthalmic disease-related cortical thinning reflects diverse micro-structural etiologies.⁷ One study of patients with congenital or acquired blindness reported an association between visual deprivation and restructuring of the functional architecture of the anterior insula in both groups.⁸ The insula is located within the lateral sulcus of the brain and is considered the hub of the “salience network” that identifies sensorial, motor, visceral stimuli and also plays a role in high-level cognitive processing.⁹

To our knowledge, no study has used SBM to assess the association between visual function and brain structure modifications in older adults. Cortical loss may be greater in this population because of multiple factors such as decreased neuronal reserve and plasticity and greater vision loss. The present study aimed to assess the association between visual function and brain cortical thickness in a sample of older community-dwelling participants.

Methods

This study followed the STROBE checklist for reporting observational cross-sectional study findings.¹⁰ The study protocol was approved by the ethics committee of the University Hospital of Bicêtre and Sud Méditerranée III, and written informed consent was obtained from each participant. The guidelines outlined in the Declaration of Helsinki were followed.

Design and Data Source

The study population was derived from the ESPRIT cohort, a French population-based study of 2259 community-dwelling older adults aged ≥ 65 years, who were enrolled between 1999 and 2001 by random selection from the 15 electoral rolls of the Montpellier district. Of the people initially selected at random, more than one quarter (27.3%) did not participate (of these, 3.3% were excluded owing to severe disability). Those who refused to participate were replaced with others from the same district. The methodology of the ESPRIT study was previously described.¹¹ At inclusion and at 2-, 4-, 7-, 10- and 12-year follow-up, participants underwent standardized neurological examinations with blood sampling and completed questionnaires relating to sociodemographic, lifestyle and health characteristics. At 12-year follow-up, participants who were free of dementia and had a Mini Mental State Examination¹² score >24 were also asked to undergo MRI and a vision examination as part of the Cognitive REServe and Clinical ENDOPhenotype (CRESCENDO) study ($n = 380$).¹³ The present study explored the cross-sectional associations between vision loss and cortical thickness at 12-year follow-up.

Participants

Of the 380 participants who underwent MRI after 12 years of follow-up, 340 had a brain scan with complete volumetric data after a quality check and 313 had complete follow-up data from baseline. We excluded participants who were left-handed ($n = 15$), those who had dementia ($n = 4$) or stroke ($n = 18$) and those who had transient visual acuity loss ($n = 61$) and assessed the relation between brain morphology and visual function for the remaining 215 participants (Figure 1).

MRI Protocol and Image Analysis

Neuroimaging data were collected by using a 3-Tesla magnet (Skyra, Siemens, Germany) with a 32-channel head coil. Structural images (3D T1-weighted) were acquired with the following parameters: field of view = 25×25 cm, TE = 2.5 ms, TR = 1690 ms, flip angle = 9° , voxel size = $0.98 \times 0.98 \times 1$ mm³, 176 slices. Regional reconstruction and segmentation involved using FreeSurfer v.6 for image analysis (<http://surfer.nmr.mgh.harvard.edu/>) is described.¹⁴ A quality check was performed, and participants with movement artefacts or poor contrast on scans were excluded. The cortex was segmented into 74 subregions following the Destrieux atlas.¹⁵ We performed exploratory analyses in subregions that might show neuroimaging abnormalities in patients with ophthalmic diseases.^{16–19} The primary and secondary visual cortices, the occipital lobe, corresponded to 14 subregions. The visual associated pathways (ie, ventral pathway [infero-temporal lobe, the “what” pathway] and dorsal pathway [posterior parietal lobe, the “where” pathway]) and prefrontal cortex corresponded to 11 subregions. The 8 subregions of the insula were also analyzed in further detail because of the insular functional rearrangement found in blind people.⁸ Subcortical areas such as the pulvinar nucleus of the thalamus were also found associated with visual function.^{20–23} We analysed 8 subcortical area volumes: thalamus, putamen, pallidum, caudate, amygdala, hippocampus, accumbens and ventral diencephalon.

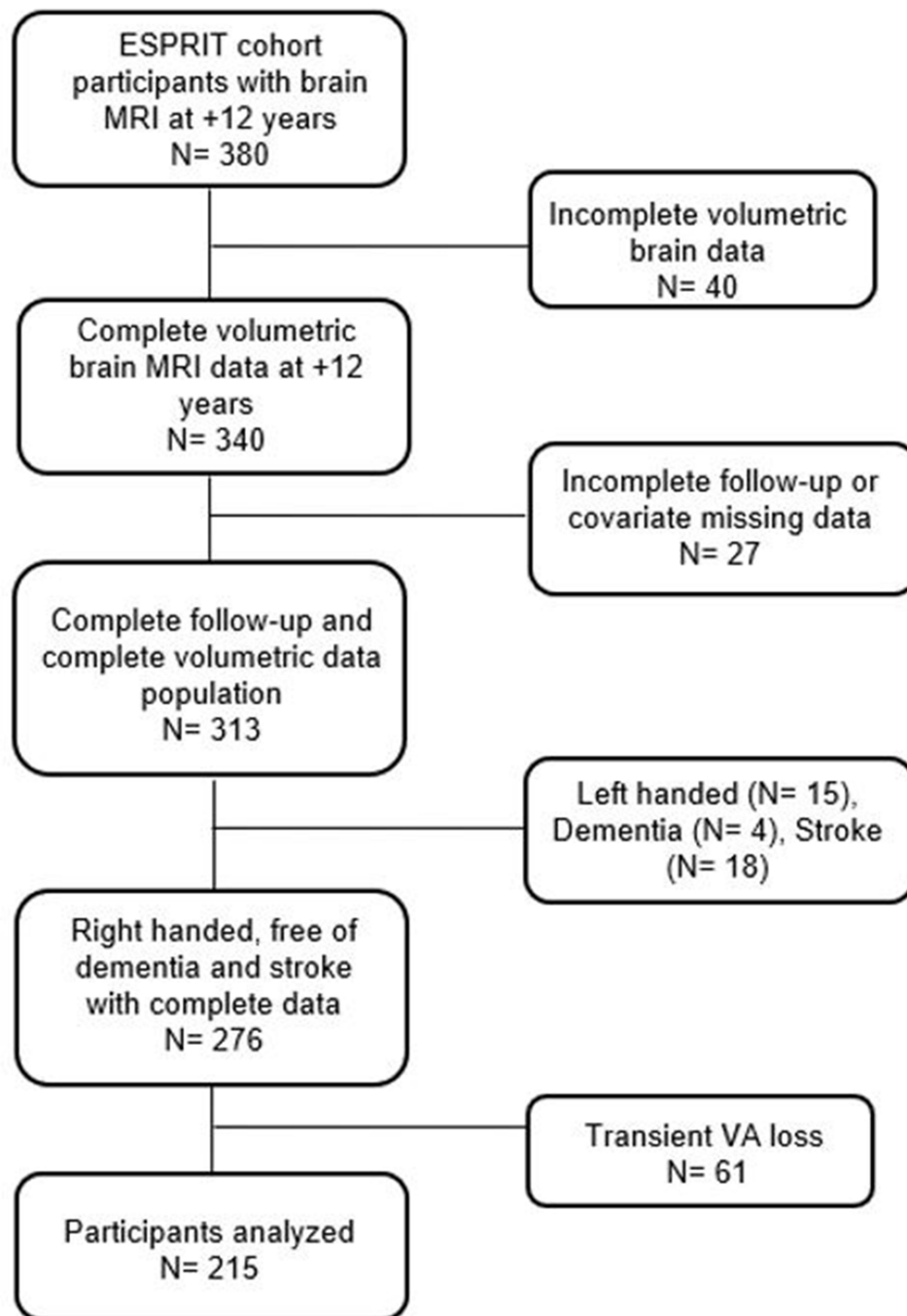


Figure 1 Flow-chart of the participants in the study.

Abbreviations: MRI, magnetic resonance imaging; VA, visual acuity.

Vision Measures

Monocular near-visual acuity was assessed by using the Parinaud scale (a Jaeger-like reading test commonly used by French ophthalmologists) with the current optical correction, at a standardized reading distance of 33 cm. Vision loss was defined as visual acuity of Parinaud 4 or worse (Jaeger 3 or worse) in at least one eye at both the current and previous follow-up.

Covariates

We considered the following sociodemographic factors: age, sex, smoking status and educational level (primary school and higher education). We also considered cardiovascular risk factors such as hypertension, diabetes and history of cardiovascular disease (lifetime history of angina and/or myocardial infarction and/or coronary dilatation and/or aortocoronary bypass and/or cardiac rhythm disease and/or pacemaker and/or cardiac insufficiency), self-reported by participants. Major depression was taken into account because of its association with occipital-cortex grey-matter volume.²⁴ Depression was defined as at least one current or previous major depressive disorder according to the *Diagnostic and Statistical Manual of Mental Disorders*, fourth edition, and using the Mini-International Neuropsychiatric Interview (French version 5.00).

Statistical Analysis

Baseline characteristics of participants are described with number (%) for categorical variables and mean (SD) for continuous variables. Brain cortical thickness measurements were normally distributed. We assessed associations between brain region cortical thickness and vision groups by using analysis of covariance (ANCOVA) adjusted for potential confounders associated with groups ($p \leq 0.20$): age, sex, lifetime depression and cardiovascular disease. We calculated the effect size as the percentage thinning (difference in mean thickness between both groups divided by the control group mean thickness). To manage the multiple brain region examinations, we adjusted significance levels by using the false discovery rate (FDR) method.²⁵ All tests were 2-sided and we used SAS v9.4 (SAS Institute, Inc., Cary, NC) for statistical analyses and the package ggseg of R v4.0.2 for representations of modified brain regions.

Results

Participant Characteristics

The baseline characteristics of the 215 participants are summarized in [Table 1](#). The mean (SD) age was 81.8 (3.7) years and 53.0% of participants were women. A total of 30 (14.0%) participants had persistent central vision loss and 185 (86.0%) were controls with normal central vision. Among the 30 participants with near vision loss, 25 (83.3%) had one-sided vision loss and 5 (16.7%) had bilateral vision loss. Two (6.7%) participants had age-related macular degeneration, 15 (50.0%) cataracts and the 13 (43.3%) remaining neither age-related macular degeneration nor cataracts. The median (interquartile range) corrected near visual acuity was 0.6 (0.5–0.8) logMAR in the vision loss group and 0.1 (0.1–0.1) in the control group ($p < 0.0001$). Overall, 28.4% of participants had lifetime major depression, 10.0% diabetes, 55.5% hypertension and 37.8% cardiovascular diseases, with no significant differences between groups.

We compared the ESPRIT participants who underwent MRI with those who did not at the time of MRI examination. Both populations were comparable for all variables except for the prevalence of cognitive impairment (1.9% vs 10.4%, $p = 0.0004$) and mean age (81.8 vs 83.0, $p = 0.0006$).

Cortical Thickness and Vision Loss ([Table 2](#))

After adjustment for age, sex, lifetime depression and cardiovascular disease, we found an association between vision loss and cortical thickness in the right insula: mean adjusted (SE) cortical thickness was 2.38 (0.04) and 2.50 (0.03) mm in the near vision loss and control groups, respectively ($p_{\text{corrected}} = 0.04$). The groups did not differ in left insula thickness ($p_{\text{corrected}} = 0.2$).

More precisely, the adjusted mean (SE) cortical thickness in the right short gyri, anterior circular sulcus, long insular gyrus and central sulcus, inferior circular sulcus and posterior lateral sulcus was lower in the near vision loss than the control group (short gyri: 8.1% thinning, $p_{\text{uncorrected}} = 0.003$; anterior circular sulcus: 6.7% thinning, $p_{\text{uncorrected}} = 0.0005$; gyrus long-central sulcus: 6.2% thinning, $p_{\text{uncorrected}} = 0.02$; inferior circular sulcus: 4.2% thinning, $p_{\text{uncorrected}} = 0.02$; posterior lateral sulcus: 4.2% thinning, $p_{\text{uncorrected}} = 0.006$), which persisted after FDR correction ($p_{\text{corrected}} = 0.01, 0.004, 0.03, 0.03, 0.02$, respectively).

In the primary and secondary visual cortices, no association persisted after FDR correction.

Table 1 Participant Characteristics by Visual Function Group (n = 215)

	Near Vision Loss N= 30	Control N= 185	P value**
Age, years (mean [SD])	82.4 (3.1)	81.7 (3.8)	0.3
Female, N (%)	19 (63.3)	95 (51.4)	0.3
Near corrected visual acuity, logMAR (median [IQR 25–75])	0.6* (0.5–0.8)	0.1* (0.1–0.1)	<0.0001
Distance corrected visual acuity, logMAR (median [IQR 25–75])	0.5 (0.3–0.7)	0.2 (0.1–0.4)	<0.0001
Total intracranial volume, cm³ (mean [SD])	1475.2 (155.3)	1482.5 (155.4)	0.8
Lifetime depression, N (%)	12 (40.0)	50 (27.0)	0.1
Smoking, N (%)			0.8
Never	20 (66.7)	111 (60.0)	
Former	8 (26.7)	61 (33.0)	
Current	2 (6.7)	13 (7.0)	
Cardiovascular ischemic disease, N (%)	13 (43.3)	68 (36.8)	0.5
Diabetes, N (%)	4 (13.3)	16 (8.6)	0.5
Hypertension, N (%)	18 (60.0)	102 (55.1)	0.6
Education level, N (%)			0.8
Low	5 (16.7)	28 (15.1)	
High	25 (83.3)	157 (84.9)	
Cognitive impairment (MMSE score < 26), N (%)	1 (3.3)	3 (1.6)	0.5

Notes: *0.6 logMAR = Jaeger 5, 0.1 logMAR = Jaeger 1. ** Chi-square test (categorical variables) or Student's t-test (quantitative variables) as appropriate. P-values <0.05 in bold. **Abbreviations:** IQR, interquartile range; MMSE, Mini Mental State Examination; SD, standard deviation.

In the visual associative pathways, we found cortical thinning of the left superior temporal gyrus (5.0% thinning, $P_{corrected}=0.03$), which is part of the ventral pathway (Table 2).

The brain areas where cortical thickness was significantly associated with vision loss are given in Figure 2.

Subcortical Areas

We did not find any association between vision loss and modification of subcortical area volumes ($p > 0.6$).

Discussion

In the present study, near vision loss was associated with a 4.8% thinning of the right insular cortex. The thinning in primary visual cortex subregions was not significant after correction for multiple testing.

Vision Loss and Insula

The insula, located deeply within the lateral sulcus, is the hub of the “salience network” that identifies sensorial, motor and visceral stimuli and forwards them to regions of higher cognitive processing to influence behaviour.⁹ Some studies assessed the functional associations between the insula and visual pathways. Liu et al reported an intrinsic functional reshape in networks of anterior insula subregions after blindness.⁸ Pathways connecting visual areas to anterior insula were strengthened, thus suggesting a transfer of non-visual information between the deprived “visual” cortex and salience network in blind people. Early findings indicated that the “deprived” visual areas participated in the processing of tactile and auditory stimuli in blind people, which may explain these results.²⁶ The work of Niddam et al on migraine with aura further suggests a connection between visual areas and the insula.²⁷ The connectivity between the insula and occipital areas was reduced in migraine with aura but not without aura. Considering these previous functional results, we strongly hypothesize that the insula plays a role in exteroception, particularly in integrating auditive and visual stimuli.

In the present study, the near vision loss group showed a thinner right insular cortex (mean thickness 2.38 [0.04] vs 2.50 [0.03] in vision loss and control groups). These results support previous functional findings.

As previously described in macaques, Dionisio et al confirmed a strong connectivity between the posterior insula and auditory cortex in a cortico-cortical evoked-potentials study.²⁸ The authors also found associations between the right

Table 2 Association of Cortical Thickness and Vision Loss, ESPRIT Study (n = 215)

Brain region	Right Cortical Thickness, mm (Mean [SE])*					Left Cortical Thickness, mm (Mean [SE])*				
	Near vision loss (n=30)	Control (n=185)	Effect size (%)	P value ANCOVA*	P _{FDR} value ANCOVA*	Near vision loss (n=30)	Control (n=185)	Effect size (%)	P value ANCOVA*	P _{FDR} value ANCOVA*
Insular cortex										
Anterior insula										
G short	2.82 (0.07)	3.07 (0.03)	8.1	0.003	0.01	2.96 (0.1)	3.18 (0.08)	6.9	0.02	0.09
S circular anterior	2.43 (0.05)	2.61 (0.02)	6.7	0.0005	0.004	2.49 (0.06)	2.56 (0.05)	2.7	0.2	0.3
S anterior lateral horizontal	2.10 (0.04)	2.11 (0.02)	0.5	0.8	0.8	2.01 (0.06)	2.02 (0.04)	0.5	0.9	0.9
S anterior lateral vertical	2.14 (0.05)	2.21 (0.02)	3.2	0.2	0.3	2.15 (0.06)	2.12 (0.05)	1.4	0.7	0.8
Posterior insula										
G long insular and S central	2.73 (0.07)	2.91 (0.03)	6.2	0.02	0.03	2.70 (0.08)	2.80 (0.06)	3.6	0.2	0.3
S circular inferior	2.26 (0.04)	2.36 (0.02)	4.2	0.02	0.03	2.41 (0.05)	2.47 (0.04)	2.4	0.2	0.3
S circular superior	2.41 (0.03)	2.48 (0.02)	2.8	0.06	0.08	2.34 (0.04)	2.41 (0.03)	2.9	0.05	0.1
S posterior lateral	2.07 (0.03)	2.16 (0.01)	4.2	0.006	0.02	2.04 (0.04)	2.12 (0.03)	3.8	0.02	0.09
Visual cortex										
Primary and secondary visual cortices = Occipital lobe										
G cuneus	1.76 (0.03)	1.76 (0.02)	0.0	1.0	1.0	1.77 (0.03)	1.77 (0.01)	0.0	1.0	1.0
G occipital middle	2.28 (0.05)	2.37 (0.04)	3.8	0.07	0.4	2.32 (0.05)	2.38 (0.04)	2.5	0.2	0.3
G occipital sup	1.97 (0.05)	2.00 (0.04)	1.5	0.5	0.8	1.87 (0.05)	1.91 (0.04)	2.1	0.4	0.5
G fusiform	2.53 (0.07)	2.67 (0.05)	5.2	0.02	0.3	2.57 (0.07)	2.68 (0.05)	4.1	0.06	0.2
G lingual	1.98 (0.03)	2.01 (0.03)	1.5	0.3	0.7	1.91 (0.03)	1.92 (0.03)	0.5	1.0	1.0
Occipital pole	1.85 (0.04)	1.88 (0.03)	1.6	0.4	0.9	1.83 (0.05)	1.85 (0.04)	1.1	0.6	0.6
S calcarine	1.67 (0.03)	1.69 (0.02)	1.2	0.4	0.7	1.58 (0.03)	1.62 (0.02)	2.5	0.2	0.3
S lunatus	1.94 (0.05)	1.98 (0.04)	2.0	0.4	0.7	1.84 (0.04)	1.92 (0.03)	4.2	0.05	0.2
S occipital supero transversal	1.98 (0.03)	2.04 (0.01)	2.9	0.06	0.5	1.98 (0.04)	2.02 (0.03)	2.0	0.2	0.3

S occipital anterior	2.05 (0.05)	2.10 (0.04)	2.4	0.3	0.7	2.07 (0.04)	2.11 (0.03)	1.9	0.3	0.5
S occipital temporolateral	2.25 (0.05)	2.36 (0.04)	4.7	0.02	0.2	2.28 (0.04)	2.37 (0.03)	3.8	0.05	0.2
S lingual	2.14 (0.04)	2.21 (0.03)	3.2	0.04	0.2	2.07 (0.04)	2.16 (0.03)	4.2	0.02	0.2
S parieto occipital	2.00 (0.04)	2.02 (0.03)	1.0	0.5	0.7	1.95 (0.04)	2.00 (0.03)	2.5	0.1	0.3
G and S occipital inferior	2.31 (0.05)	2.41 (0.04)	4.1	0.02	0.2	2.31 (0.05)	2.39 (0.04)	3.3	0.05	0.2
Associative visual area										
• Ventral pathway										
G superior temporal lateral aspect	2.60 (0.06)	2.71 (0.04)	4.1	0.05	0.1	2.66 (0.06)	2.80 (0.05)	5.0	0.02	0.03
G superior temporal planum polare	2.72 (0.07)	2.80 (0.06)	2.9	0.4	0.7	2.99 (0.08)	3.01 (0.06)	0.7	0.9	0.9
G superior temporal planum temporale	2.17 (0.06)	2.28 (0.03)	4.8	0.07	0.3	2.26 (0.05)	2.35 (0.03)	3.8	0.06	0.3
G inferior temporal	2.72 (0.06)	2.82 (0.05)	3.5	0.06	0.3	2.77 (0.05)	2.84 (0.04)	2.5	0.3	0.7
G middle temporal	2.60 (0.06)	2.71 (0.05)	4.1	0.06	0.3	2.67 (0.06)	2.74 (0.04)	2.6	0.3	0.7
• Dorsal pathway										
G and S paracentral	2.09 (0.05)	2.11 (0.04)	0.9	0.9	0.9	2.14 (0.05)	2.14 (0.04)	0.0	0.8	0.9
G angular	2.28 (0.05)	2.38 (0.04)	4.2	0.06	0.3	2.36 (0.05)	2.39 (0.04)	1.3	0.7	0.9
G precuneus	2.18 (0.04)	2.21 (0.03)	1.4	0.7	0.8	2.19 (0.05)	2.24 (0.03)	2.2	0.5	0.8
• Prefrontal cortex										
G middle frontal	2.29 (0.04)	2.36 (0.03)	3.0	0.2	0.4	2.21 (0.04)	2.28 (0.03)	3.1	0.1	0.6
G precentral	2.26 (0.06)	2.36 (0.05)	4.2	0.2	0.4	2.29 (0.06)	2.35 (0.05)	2.6	0.4	0.7
S middle frontal	2.04 (0.03)	2.07 (0.02)	1.4	0.6	0.8	1.99 (0.04)	2.02 (0.03)	1.5	0.5	0.8

Notes: *adjusted for sex, age, lifetime depression, cardiovascular disease. p-values <0.05 in bold.

Abbreviations: G, gyrus; S, sulcus; SE, standard error.

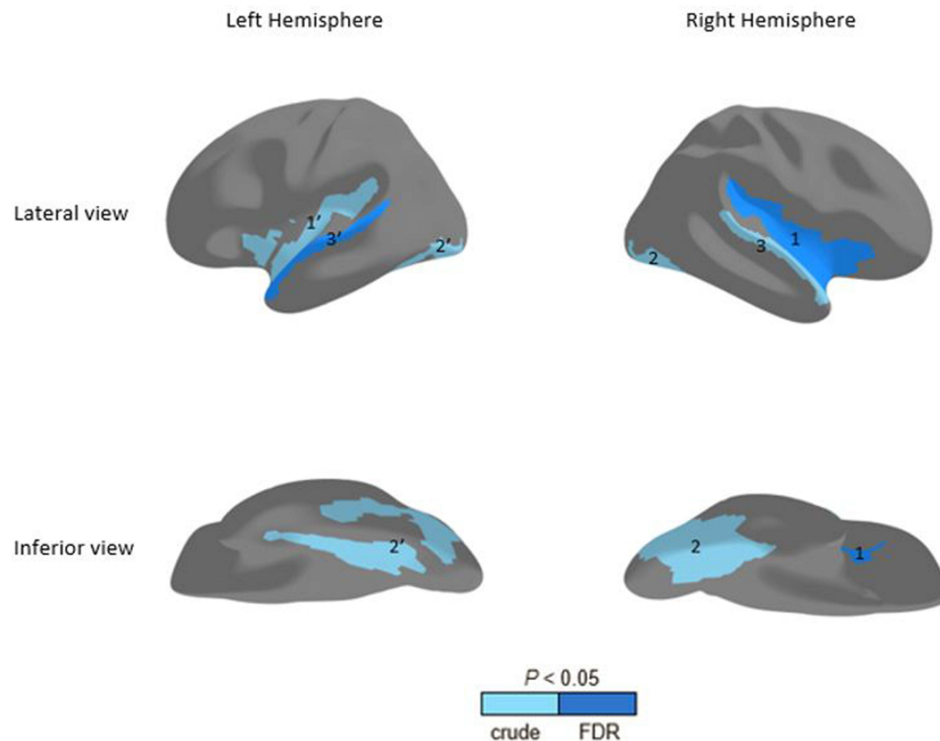


Figure 2 Cortical thinning areas associated with vision loss (ANCOVA test). In the right hemisphere, significant thinning of the insular cortex (1). The thinning of visual cortex (2) and visual associative pathway (3) do not resist to FDR correction. In the left hemisphere, significant thinning of the visual associative pathway (3'). The thinning of insular (1') and visual cortex (2') do not resist to FDR correction.

Abbreviation: FDR, false discovery rate.

posterior insula and left visual ventral associative pathway. Our results agree with these findings in that our vision loss group showed thinner cortical thickness in the right posterior insula and the contralateral superior temporal gyrus (part of the ventral associative pathway).

A recent study of 27 individuals described a structural asymmetry of the insula between right and left hemispheres linked to the lateralization of gesture and language.²⁹ Allen et al compared insular cortical volumes in both hearing and deaf right-handed individuals with or without sign language experience.³⁰ Both deaf and hearing signers showed higher volume in the right insula as compared with non-signers. These results reinforce the hypothesis of a lateralization of insula linked to gesture. The present study, which included only right-handed participants, confirmed previous results showing no difference in left insula cortical thickness between groups. Vision loss may have had no effect on the left insula in our sample because of the non-existence of or little connection between visual areas and left insula in right-handed individuals.

Also, the “salience network”, represented by the insula, is the core of different interoceptive and exteroceptive stimuli guiding behaviour. The insula has been implicated in major depressive disorder.²⁴ In our study, the association remained significant after adjusting for depression, which reinforces the association between vision and insula independent of confounding factors. Lifetime depression was not higher in vision loss than in the control group, but the depression process associated with insula thinning may appear later in this population.

Vision Loss and Visual Cortex

Right hemisphere visual cortex thinning was not statistically significant after FDR correction and need to be confirmed in an independent sample. In the left hemisphere, thinning of the superior temporal gyrus (ventral associative pathway) was significant even after FDR correction.

The visual cortex is divided into primary, secondary and visual associative cortices. The primary visual cortex located around the calcarine sulcus transmits a visual signal to the secondary visual cortex, also in the occipital lobe.

Voxel- and surface-based morphometry of brain imaging data have been used to quantitatively describe structural modifications associated with ophthalmic diseases. Amblyopia was associated with bilateral loss of density in calcarine fissure cortex and visual associative areas, which may indicate developmental abnormalities of the visual cortex during the critical growth period.⁵

The effect of vision recovery on brain structure was demonstrated in older people after cataract surgery, favouring neuronal plasticity persistence in adulthood.⁶ Vision loss in age-related macular degeneration was found associated with reduced grey-matter density in the posterior calcarine fissure, whereas glaucoma was associated with differences in the anterior calcarine fissure (Table 3).³¹ These results corroborate the retinotopy of visual pathways in that loss of function induces cortical thinning.³²

In the present study, near vision loss was associated with thinner cortical thickness in the right and left lingual sulci, but the associations were not significant after adjustment for multiple comparisons. This impairment agrees with previous findings, the lingual sulci being located in the primary visual cortex, near the calcarine sulcus. Also, vision loss was associated with thinner cortical thickness in both occipital inferior gyrus-sulcus as well as both occipito temporolateral sulci, left lunatus sulcus and right fusiform gyrus, although not significantly ($p > 0.2$). These subregions of the occipital lobe are contiguous, which gives further support for their association with vision loss.

Strengths and Limitations

The present study has several strengths. First, the cohort design with a prospective collection of data by protocol allowed for brain scanning with the same device and visual acuity examinations by protocol. It allowed for comparing brain cortical thickness between groups. Visual acuity was assessed with usual optical correction, so we could analyse the effect of everyday visual function on brain structure. Second, the dataset included detailed reporting of the medical history of participants, notably cardiovascular diseases and lifetime major depression. It was crucial to consider lifetime depression status in assessing the association between vision and insular cortical thickness because depression has been associated in some studies with lower insular cortical volume.²⁴ Third, the SBM method for estimating cortical thickness from brain MRI scans is of major interest. Currently, two methods exist: SBM and VBM, both requiring an initial segmentation to separate grey matter, white matter and cerebrospinal fluid. The use of surface models leads to sub-voxel accuracy and high sensitivity, but VBM is considered less accurate than SBM because of the limited resolution of the voxel grid and less robustness to noise and mis-segmentation.³³ Finally, we used the FDR method to control for multiple comparisons. The FDR approach is considered more robust than methods such as Bonferroni correction, which controls false-positive rates and is particularly adapted to analysing a large dataset.¹⁸

The study has some limitations. We included only participants without clinical dementia (Mini Mental State Examination score >24) which probably underestimated the association between vision loss and insular cortical thinning because degenerative ocular diseases such as glaucoma share physiologic aspects with Alzheimer's disease (REF). Further studies in this population will be of interest to better understand the effect of vision loss on brain structures.

The present study did not find any association between vision loss and subcortical volumes while an association was previously described with the pulvinar nucleus of the thalamus.^{20–23} We can assume that the parcellation of subcortical areas of the brain was not at a sufficient level to put in evidence fine changes.

Conclusion

The present study described for the first time a significant thinning of the right insular cortex in older adults with vision loss. The insula subserves a wide variety of functions in humans ranging from sensory and affective processing to high-level cognitive processing. Reduced insula thickness associated with vision loss may increase cognitive burden in the ageing brain. This study highlights the importance of early treatment of ophthalmic disorders in older adults. To conclude a causality between vision loss and insular thinning, further longitudinal analyses are required.

Table 3 Brain Cortical Structures Involved in Degenerative Ophthalmic Diseases in the Literature (PubMed Search Between 2000 and 2020)

Study	Country	N	Age	Design	Diagnosis	MRI analysis Method	Primary Outcome	Thinner Areas	Thicker Areas
Glaucoma									
Boucard et al, 2009 ³¹	The Netherlands	8	72	Crosssectional	POAG	VBM	GM density	Fissure calcarine anteriorly	
Chen et al, 2013 ⁴	China	30	43	Case-control	Advanced POAG	VBM	GM volume	Bilateral: G lingual, G calcarine, G postcentral, G superior frontal, G inferior frontal, rolandic operculum Right: G cuneus, G inferior occipital, G supramarginal Left: G paracentral	
Li et al, 2012 ¹⁷	China	60	50	Case-control	Early / Advanced POAG	VBM	GM density	Bilateral: primary visual cortex, paracentral lobule Right: G precentral, G middle frontal, G inferior temporal, G angular Left: G precuneus, G middle temporal, G superior temporal	
Frezzotti et al, 2016 ³⁴	Italia	25	52	Case-control	Advanced POAG	VBM	GM volume	Bilateral: hippocampus Right: G lingual, G lateral occipital, G superior parietal Left: cerebellum, G postcentral	
Yu et al, 2013 ³⁵	China	76	47	Case-control	POAG	SBM	GM thickness	Bilateral: S calcarine Left: G middle temporal, G fusiform	
Bogorodzki et al, 2014 ¹⁸	Poland	26	72	Case-control	Advanced POAG	SBM (FreeSurfer)	GM thickness	Bilateral: G lingual Right: G precentral, G superior temporal	
Williams et al, 2013 ³⁶	USA	30	66	Case-control	POAG	VBM	GM volume	-	Bilateral: G occipital Right: G middle occipital, G inferior temporal
Age-related macular degeneration									
Boucard, 2009 ³¹	The Netherlands	9	73	Crosssectional	AMD	VBM	GM density	Fissure calcarine posteriorly	
Cataract surgery									
Lou, 2013 ⁶	Denmark	12	71	Cohort	Unilateral cataract surgery	VBM	GM volume		Contralateral V2 (primary visual cortex)
Oculomotor training									
Rosengarth, 2013 ³⁷	Germany	9	72	Cohort	Oculomotor training in AMD	VBM	GM density		Left posterior cerebellum

Abbreviations: N, study sample; MRI, magnetic resonance imaging; POAG, primary open angle glaucoma; VBM, voxel-based morphometry; SBM, surface based morphometry; GM, gray matter; AMD, age-related macular degeneration; G, gyrus; S, sulcus.

Acknowledgments

We thank the Société Française d’Ophtalmologie for sponsoring the study; the society had no role in the design or conduct of this research.

Author Contributions

All authors contributed to data analysis, drafting or revising the article, have agreed on the journal to which the article was submitted, gave final approval of the version to be published, and agree to be accountable for all aspects of the work. Chloé Chamard: methodology, statistical analysis, and writing; Jerome Maller: image analysis and review; Nicolas Menjot, Eloi Debourdeau, Virginie Nael, and Karen Ritchie: review; Isabelle Carrière: investigation, methodology, statistical analysis, and review; and Vincent Daien: investigation, methodology, and review.

Funding

This CRESCENDO study was carried out with the financial support of the ANR – Agence Nationale de la Recherche (MALZ-007-01 — The French National Research Agency — and grants from the “Chercheur d’Avenir” (R12028FF) and Aide à la Recherche en Partenariat avec les Entreprises (ARPE; RPH12007F) allocated by the Languedoc Roussillon administrative regional district (France).

Disclosure

The authors report no conflicts of interest in relation to this work.

References

1. Brézin AP. Blindness, low vision, and other handicaps as risk factors attached to institutional residence. *Br J Ophthalmol*. 2004;88(10):1330–1337. doi:10.1136/bjo.2003.039180
2. Carrière I, Delcourt C, Daien V, et al. A prospective study of the bi-directional association between vision loss and depression in the elderly. *J Affect Disord*. 2013;151(1):164–170.
3. Reyes-Ortiz CA, Kuo YF, DiNuzzo AR, Ray LA, Raji MA, Markides KS. Near vision impairment predicts cognitive decline: data from the Hispanic Established Populations for Epidemiologic Studies of the Elderly. *J Am Geriatr Soc*. 2005;53(4):681–686.
4. Chen WW, Wang N, Cai S, et al. Structural brain abnormalities in patients with primary open-angle glaucoma: a study with 3T MR imaging. *Invest Ophthalmol Vis Sci*. 2013;54(1):545–554.
5. Xiao JX, Xie S, Ye JT, et al. Detection of abnormal visual cortex in children with amblyopia by voxel-based morphometry. *Am J Ophthalmol*. 2007;143(3):489–493.
6. Lou AR, Madsen KH, Julian HO, et al. Postoperative increase in grey matter volume in visual cortex after unilateral cataract surgery. *Acta Ophthalmol*. 2013;91(1):58–65.
7. Beer AL, Plank T, Greenlee MW. Aging and central vision loss: relationship between the cortical macro-structure and micro-structure. *Neuroimage*. 2020;15(212):116670.
8. Liu L, Yuan C, Ding H, et al. Visual deprivation selectively reshapes the intrinsic functional architecture of the anterior insula subregions. *Sci Rep*. 2017;7:458.
9. Downar J, Crawley AP, Mikulis DJ, Davis KD. A multimodal cortical network for the detection of changes in the sensory environment. *Nat Neurosci*. 2000;Mar(3):277–283.
10. von Elm E, Altman DG, Egger M, et al. Strengthening the Reporting of Observational Studies in Epidemiology (STROBE) statement: guidelines for reporting observational studies. *BMJ*. 2007;335(7624):806–808. doi:10.1136/bmj.39335.541782.AD
11. Ritchie K, Artero S, Beluche I, et al. Prevalence of DSM-IV psychiatric disorder in the French elderly population. *Br J Psychiatry*. 2004;184(2):147–152. doi:10.1192/bjp.184.2.147
12. Folstein MF, Folstein SE, McHugh PR. “Mini-mental state”. A practical method for grading the cognitive state of patients for the clinician. *J Psychiatr Res*. 1975;12(3):189–198. doi:10.1016/0022-3956(75)90026-6
13. Charroud C, Le Bars E, Deverduin J, et al. Working memory performance is related to intrinsic resting state functional connectivity changes in community-dwelling elderly cohort. *Neurobiol Learn Mem*. 2016;132:57–66. doi:10.1016/j.nlm.2016.05.008
14. Fischl B. FreeSurfer. *Neuroimage*. 2012;62(2):774–781. doi:10.1016/j.neuroimage.2012.01.021
15. Destrieux C, Fischl B, Dale A, Halgren E. Automatic parcellation of human cortical gyri and sulci using standard anatomical nomenclature. *Neuroimage*. 2010;53(1):1–15.
16. Grill-Spector K, Malach R. The human visual cortex. *Annu Rev Neurosci*. 2004;27:649.
17. Li C, Cai P, Shi L, et al. Voxel-based morphometry of the visual related cortex in primary open angle glaucoma. *Curr Eye Res*. 2012;37(9):794–802.
18. Bogorodzki P, Piątkowska-Janko E, Szaflik J, Szaflik JP, Gacek M, Grieb P. Mapping cortical thickness of the patients with unilateral end-stage open angle glaucoma on planar cerebral cortex maps. *PLoS One*. 2014;9(4):e93682.
19. Guerreiro MJS, Erfort MV, Hensler J, Putzar L, Röder B. Increased visual cortical thickness in sight-recovery individuals. *Hum Brain Mapp*. 2015;36(12):5265–5274.

20. Chou XL, Fang Q, Yan L, et al. Contextual and cross-modality modulation of auditory cortical processing through pulvinar mediated suppression. *Elife*. 2020;6(9):e54157.
21. Fang Q, Chou XL, Peng B, Zhong W, Zhang LI, Tao HW. A Differential Circuit via Retino-Colliculo-Pulvinar Pathway Enhances Feature Selectivity in Visual Cortex through Surround Suppression. *Neuron*. 2020;105(2):355–369.e6.
22. Ibrahim LA, Mesik L, Ji XY, et al. Cross-Modality Sharpening of Visual Cortical Processing through Layer-1-Mediated Inhibition and Disinhibition. *Neuron*. 2016;89(5):1031–1045.
23. Dietrich S, Hertrich I, Kumar V, Ackermann H. Experience-related structural changes of degenerated occipital white matter in late-blind humans - A diffusion tensor imaging study. *PLoS One*. 2015;10(4):e0122863.
24. Ancelin ML, Carrière I, Artero S, et al. Lifetime major depression and grey-matter volume. *J Psychiatry Neurosci*. 2019;44(1):45–53.
25. Glickman ME, Rao SR, Schultz MR. False discovery rate control is a recommended alternative to Bonferroni-type adjustments in health studies. *J Clin Epidemiol*. 2014;67(8):850–857.
26. Ricciardi E, Tozzi L, Leo A, Pietrini P. Modality dependent cross-modal functional reorganization following congenital visual deprivation within occipital areas: a meta analysis of tactile and auditory studies. *Multisens Res*. 2014;27(3–4):247–262.
27. Niddam DM, Lai KL, Fuh JL, Chuang CYN, Chen WT, Wang SJ. Reduced functional connectivity between salience and visual networks in migraine with aura. *Cephalalgia*. 2016;36(1):53–66.
28. Dionisio S, Mayoglou L, Cho SM, et al. Connectivity of the human insula: a cortico-cortical evoked potential (CCEP) study. *Cortex*. 2019;120:419–442.
29. Bidula SP, Króliczak G. Structural asymmetry of the insula is linked to the lateralization of gesture and language. *Eur J Neurosci*. 2015;41(11):1438–1447.
30. Allen JS, Emmorey K, Bruss J, Damasio H. Morphology of the insula in relation to hearing status and sign language experience. *J Neurosci*. 2008;28(46):11900–11905.
31. Boucard CC, Hernowo AT, Maguire RP, et al. Changes in cortical grey matter density associated with long-standing retinal visual field defects. *Brain*. 2009;132(7):1898–1906.
32. Penhune VB, Cismaru R, DorSaint-Pierre R, Petitto LA, Zatorre RJ. The morphometry of auditory cortex in the congenitally deaf measured using MRI. *Neuroimage*. 2003;20(2):1215–1225.
33. Fischl B, Dale AM. Measuring the thickness of the human cerebral cortex from magnetic resonance images. *Proc Natl Acad Sci USA*. 2000;97(20):11050–11055.
34. Frezzotti P, Giorgio A, Toto F, De Leucio A, De Stefano N. Early changes of brain connectivity in primary open angle glaucoma. *Hum Brain Mapp*. 2016;37(12):4581–4596.
35. Yu L, Xie B, Yin X, et al. Reduced cortical thickness in primary open-angle glaucoma and its relationship to the retinal nerve fiber layer thickness. *PLoS One*. 2013;8(9):e73208.
36. Williams AL, Lackey J, Wizov SS, et al. Evidence for widespread structural brain changes in glaucoma: a preliminary voxel-based MRI study. *Invest Ophthalmol Vis Sci*. 2013;54(8):5880–5887.
37. Rosengarth K, Keck I, Brandl-Rühle S, et al. Functional and structural brain modifications induced by oculomotor training in patients with age-related macular degeneration. *Front Psychol*. 2013;4:428.

Eye and Brain

Dovepress

Publish your work in this journal

Eye and Brain is an international, peer-reviewed, open access journal focusing on clinical and experimental research in the field of neuro-ophthalmology. All aspects of patient care are addressed within the journal as well as basic research. Papers covering original research, basic science, clinical and epidemiological studies, reviews and evaluations, guidelines, expert opinion and commentary, case reports and extended reports are welcome. The manuscript management system is completely online and includes a very quick and fair peer-review system, which is all easy to use. Visit <http://www.dovepress.com/testimonials.php> to read real quotes from published authors.

Submit your manuscript here: <https://www.dovepress.com/eye-and-brain-journal>