



HAL
open science

Fatal Neonatal DOLK-CDG as a Rare Form of Syndromic Ichthyosis

K. Komlosi, O. Claris, S. Collardeau-Frachon, J. Kopp, I. Hausser, J. Mazereeuw-Hautier, N. Jonca, A. D. Zimmer, D. Sanlaville, J. Fischer

► **To cite this version:**

K. Komlosi, O. Claris, S. Collardeau-Frachon, J. Kopp, I. Hausser, et al.. Fatal Neonatal DOLK-CDG as a Rare Form of Syndromic Ichthyosis. *Frontiers in Genetics*, 2021, 12, pp.719624. 10.3389/fgene.2021.719624 . inserm-03582080

HAL Id: inserm-03582080

<https://inserm.hal.science/inserm-03582080>

Submitted on 21 Feb 2022

HAL is a multi-disciplinary open access archive for the deposit and dissemination of scientific research documents, whether they are published or not. The documents may come from teaching and research institutions in France or abroad, or from public or private research centers.

L'archive ouverte pluridisciplinaire **HAL**, est destinée au dépôt et à la diffusion de documents scientifiques de niveau recherche, publiés ou non, émanant des établissements d'enseignement et de recherche français ou étrangers, des laboratoires publics ou privés.



Fatal Neonatal DOLK-CDG as a Rare Form of Syndromic Ichthyosis

Katalin Komlosi^{1*}, Olivier Claris^{2,3†}, Sophie Collardeau-Frachon^{4,5†}, Julia Kopp¹, Ingrid Hausser⁶, Juliette Mazereeuw-Hautier⁷, Nathalie Jonca^{8,9}, Andreas D. Zimmer¹, Damien Sanlaville^{10,11} and Judith Fischer¹

¹Institute of Human Genetics, Medical Center, Faculty of Medicine, University of Freiburg, Freiburg, Germany, ²Department of Neonatology, Hospices Civils de Lyon, Hôpital Femme Mère Enfant, Bron, France, ³Claude Bernard University, Lyon, France, ⁴Hospices Civils de Lyon, Hôpital Femme Mère Enfant, Institut de Pathologie, Bron, France, ⁵Faculté de médecine Lyon Est, Claude Bernard University, Lyon, France, ⁶Institute of Pathology, Heidelberg University Hospital, Heidelberg, Germany, ⁷Dermatology Department, Reference Center for Rare Skin Diseases, CHU Larrey, Université Paul Sabatier, Toulouse, France, ⁸Infinity, CNRS, Inserm, UPS, Université Toulouse, Toulouse, France, ⁹CHU Toulouse, Hôpital Purpan, Laboratoire de Biologie Cellulaire et Cytologie, Institut Fédératif de Biologie, Toulouse, France, ¹⁰Hospices Civils de Lyon, Hôpital Femme Mère Enfant, Service de Génétique, Bron, France, ¹¹Institut Neuromyogène, Université de Lyon, Lyon, France

OPEN ACCESS

Edited by:

Anna Tylki-Szymańska,
Children's Memorial Health Institute
(IPCZD), Poland

Reviewed by:

Julien H. Park,
University of Münster, Germany
Hasan Orhan Akman,
Columbia University Irving Medical
Center, United States
Daisy Rymen,
University Hospitals Leuven, Belgium

*Correspondence:

Katalin Komlosi
katalin.komlosi@uniklinik-freiburg.de

[†]These authors have contributed
equally to this work

Specialty section:

This article was submitted to
Genetics of Common and Rare
Diseases,
a section of the journal
Frontiers in Genetics

Received: 02 June 2021

Accepted: 02 November 2021

Published: 08 December 2021

Citation:

Komlosi K, Claris O,
Collardeau-Frachon S, Kopp J,
Hausser I, Mazereeuw-Hautier J,
Jonca N, Zimmer AD, Sanlaville D and
Fischer J (2021) Fatal Neonatal DOLK-
CDG as a Rare Form of
Syndromic Ichthyosis.
Front. Genet. 12:719624.
doi: 10.3389/fgene.2021.719624

Neonatal collodion baby or ichthyosis can pose a diagnostic challenge, and in many cases, only additional organ involvement or the course of the disease will help differentiate between non-syndromic and syndromic forms. Skin abnormalities are described in about 20% of the congenital disorders of glycosylation (CDG). Among those, some rare CDG forms constitute a special group among the syndromic ichthyoses and can initially misdirect the diagnosis towards non-syndromic genodermatosis. DOLK-CDG is such a rare subtype, resulting from a defect in dolichol kinase, in which the congenital skin phenotype (often ichthyosis) is later associated with variable extracutaneous features such as dilatative cardiomyopathy, epilepsy, microcephaly, visual impairment, and hypoglycemia and may lead to a fatal course. We report two neonatal cases of lethal ichthyosis from the same family, with distal digital constrictions and a progressive course leading to multi-organ failure and death. Postmortem trio whole-exome sequencing revealed the compound heterozygous variants NM_014908.3: c.1342G>A, p.(Gly448Arg) and NM_014908.3: c.1558A>G, p.(Thr520Ala) in the *DOLK* gene in the first affected child, which were confirmed in the affected sibling. Reduced staining with anti- α -Dystroglycan antibody was observed in frozen heart tissue of the second child as an expression of reduced O-mannosylation due to the dolichol kinase deficiency. In addition to the detailed dermatopathological changes, both cases presented hepatic and extrahepatic hemosiderosis on histological examination. Our patients represent an early and fatal form of DOLK-CDG with a striking presentation at birth resembling severe collodion baby. Both cases emphasize the phenotypic variability of glycosylation disorders and the importance to broaden the differential diagnosis of ichthyosis and to actively search for organ involvement in neonates with ichthyosis.

Keywords: DOLK, congenital disorders of glycosylation, whole exome sequencing, Mendelian disorders of cornification, syndromic ichthyosis

INTRODUCTION

Pediatric disorders leading to perinatal death still present a challenge for genetic counseling when rapid whole exome/whole genome sequencing (WES/WGS) in the neonatal setting is not available. Affected children often die before a genetic diagnosis can be established and phenotypic descriptions are often insufficient. Complete and rigorous autopsy with multiple tissue sampling of affected fetuses or children is of great importance for detecting all anomalies that can indicate a potential diagnosis, and providing frozen tissue for genetic and functional analysis. A definitive diagnosis always requires a multidisciplinary approach including clinical data, autopsy findings, and genetic results, especially for correct interpretation of the pathogenicity of the identified DNA variants. A confirmed genetic defect is the requirement for targeted carrier testing in parents and prenatal or preimplantation genetic diagnosis in further pregnancies.

Inherited ichthyoses are classified as Mendelian disorders of cornification (MEDOC), which are further defined on the basis of clinical and genetic features and can be divided into non-syndromic and syndromic forms. To date, mutations in more than 50 genes are known to result in various types of ichthyoses (Fischer and Bourrat, 2020). The syndromic ichthyoses are generally very rare and are classified based on the mode of inheritance, and can be further subdivided according to the predominant symptoms (Oji et al., 2010; Fischer and Bourrat, 2020).

Rare forms of congenital disorders of glycosylation (CDG) are among the inborn errors of metabolism presenting at birth with ichthyosis. CDG are due to deficient glycosylation of proteins and lipids and are characterized by multi-organ symptoms with a wide range of clinical severity, from mild symptoms to severe multisystem dysfunction, and even a fatal course (Francisco et al., 2019). The spectrum of clinical manifestations comprises psychomotor delay and intellectual disability, muscle hypotonia, seizures, endocrine and coagulation abnormalities, ophthalmologic anomalies, failure to thrive, and variable dysmorphic features. Skin abnormalities are described in only about 20% of the different CDG forms (Rymen et al., 2012; Haijes et al., 2020; Komlosi et al., 2020). Generally, the skin manifestations represent only a single feature within a much broader phenotype and include orange peel skin, ichthyosis, increased skin laxity, hypo/hyperpigmentation, tumoral calcinosis, aplasia cutis congenita, hypohidrosis, hyperthermia, lipodystrophy, and psoriasis (Rymen et al., 2012; Kouwenberg et al., 2014; Alsubhi et al., 2017; Van Damme et al., 2017; Haijes et al., 2020; Komlosi et al., 2020). CDG linked to ichthyosis or ichthyosiform dry skin with variable neurologic and multi-organ involvement are due to deficiencies within the dolichol (DOLK-, SRD5A3-CDG) and the GPI (glycosylphosphatidylinositol) anchor biosynthesis pathway (PIGL-CDG, MPDU1-CDG) (Schenk et al., 2001; Kranz et al., 2007; Kahrizi et al., 2011; Lefeber et al., 2011; Kapusta et al., 2013; Jaeken et al., 2014; Rymen and Jaeken, 2014; Rush et al., 2017; Thiel et al., 2018; Hall et al., 2020; Ng et al., 2021). Recently, mild manifestations were also observed in a patient with COG5-CDG (Rymen et al., 2012).

We recently described a family with two affected children with COG6-CDG in whom very dry, tight, and rigid skin with hyperkeratosis and scaling was the prominent skin feature at birth (Komlosi et al., 2020).

Construction of the complex N-linked glycan chains on proteins starts with production of the lipid carrier dolichyl phosphate, which serves to anchor the nascent oligosaccharide to the endoplasmic reticulum. It is known that dolichol and dolichyl phosphate metabolites are expressed ubiquitously in humans and are localized to the endoplasmic reticulum but also present in other organelles such as the Golgi apparatus, mitochondria, and lysosomes. In addition to their critical role in glycan synthesis, dolichols have a number of other proposed functions including modulating physiochemical properties of lipid bilayers and shielding of cellular lipids from oxidative damage (Cantagrel et al., 2010; Buczkowska et al., 2015). Dolichol kinase deficiency (DOLK-CDG, OMIM #610768) is an autosomal recessive disorder that results from deficiency of the enzyme responsible for the terminal step in the synthesis of dolichol phosphate. The range of symptoms and age at presentation are highly variable in the patients described so far (Kranz et al., 2007; Lefeber et al., 2011; Kapusta et al., 2013; Rush et al., 2017; Hall et al., 2020). The phenotypic spectrum encompasses three major forms with (1) neurological abnormalities with hypotonia, microcephaly, seizures, and visual impairment with or without ichthyosis; (2) isolated cardiomyopathy; and (3) multiorgan involvement, which can also include ichthyosis (Kranz et al., 2007; Lefeber et al., 2011; Helander et al., 2013; Kapusta et al., 2013; Lieu et al., 2013; Rush et al., 2017; Hall et al., 2020; Paprocka et al., 2021). A few cases with biallelic pathogenic variants in *DOLK* (OMIM *610746) with severe multi-organ involvement encompassing profound muscular hypotonia, ichthyosiform skin, nystagmus, epilepsy, and pulmonary infections leading to death within the first months of life have also been described (Kranz et al., 2007; Lefeber et al., 2011; Lieu et al., 2013; Rush et al., 2017; Hall et al., 2020).

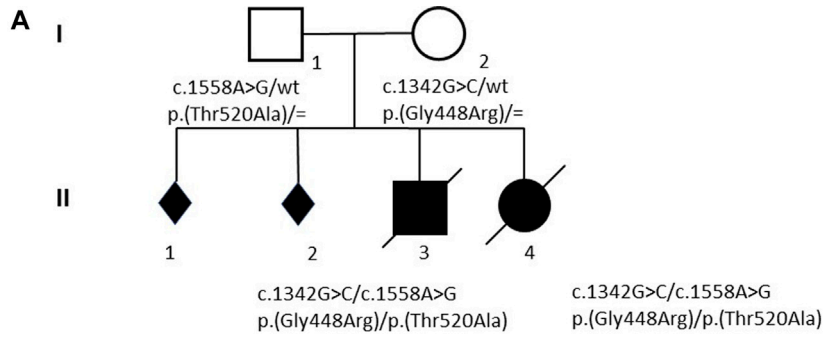
We present two children of a non-consanguineous French couple with compound heterozygous variants in the *DOLK* gene presenting with severe ichthyosis, distal digital constrictions, cardiomegaly, thrombocytopenia, diffuse coagulation defect, and progressive multi-organ failure, which resulted in death in the neonatal period. They represent two additional cases of the early and fatal form of DOLK-CDG with a striking presentation at birth resembling autosomal recessive congenital ichthyosis with progressive multi-organ failure.

MATERIALS AND METHODS

Clinical Report

Patient 1

The study was conducted according to the guidelines of the Declaration of Helsinki, and approved by the Ethics Committee of the University of Freiburg (ethical code number: 436/17). The parents of the patients gave written informed consent to the publication of the clinical information and the pictures.



species	match	gene	aa alignment
Human			448 ALVPPYAGVLA VGVGDTVASIFGST
mutated	not conserved		448 ALVPPYAGVLA VRVGDTVASIFGS
Ptroglydotes	all identical	ENSPTRG00000029053	448 ALVPPYAGVLA VGVGDTVASIFGS
Mmulatta	all identical	ENSMUG00000011755	448 ALVPPYAGVLA VGVGDTVASIFGS
Foetus	no homologue		
Mmusculus	all identical	ENSMUSG00000075419	444 ALVPPYAGVLA VGVGDTVASIFGS
Ggallus	all identical	ENSGALG0000004556	433 ALVPPYAGVLA VGVGDTMASVFGS
Trubripes	no homologue		
Drerio	all identical	ENSDARG00000076991	434 VPPYAGVLA VGVGDTVASVFGS
Dmelanogaster	all identical	FBgn0034141	418 TLALLSGILAV VGD TAASV VGS
Celegans	all identical	Y56A3A.36	219 - - - FAGVAAV VGD SMAAIVGS
Xtropicalis	all identical	ENSXETG00000024754	441 TLLPYAGVLA VGVGDTVASVCGS

species	match	gene	aa alignment
Human			520 S I S T V S L L E A Y T T Q I D N L L L P L Y I
mutated	not conserved		520 S I S T V S L L E A Y A T Q I D N L L L P L Y
Ptroglydotes	all identical	ENSPTRG00000029053	520 S I S T V S L L E A Y T T Q I D N L L L P L Y
Mmulatta	all identical	ENSMUG00000011755	520 S I S T V S L L E A Y T T Q I D N L L L P L Y
Foetus	no homologue		
Mmusculus	all identical	ENSMUSG00000075419	516 S I S T V S L L E A Y T T Q I D N L L L P L Y
Ggallus	all identical	ENSGALG0000004556	505 S V S L V S L L E A Y T T Q I D N L L L P L Y
Trubripes	no homologue		
Drerio	all identical	ENSDARG00000076991	506 S I S M V A M L E A Y T S Q I D N L L L P L Y
Dmelanogaster	all identical	FBgn0034141	484 I F A A L N S A L V E A F T D Q V D
Celegans	not conserved	Y56A3A.36	268 S L - V A T L A E A F I N S M D N F I L P L V
Xtropicalis	all identical	ENSXETG00000024754	513 S I T L V S L L E A F T T Q I D N L V L P L Y

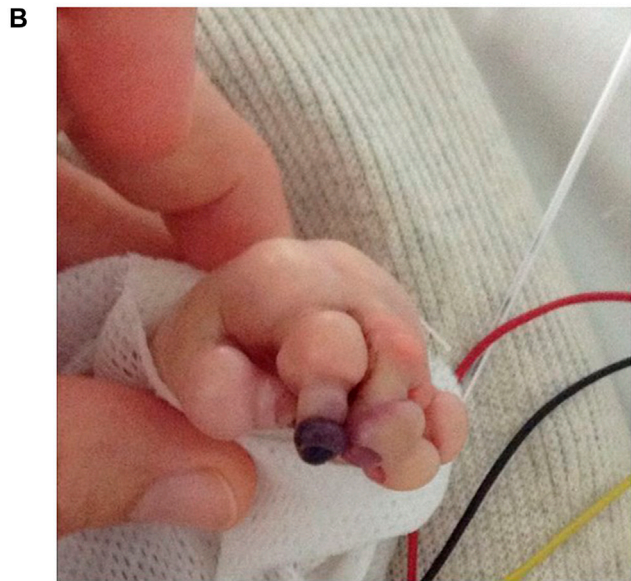


FIGURE 1 | Pedigree of the family, conservation of the AAs among the diverse species (from MutationTaster, www.mutationtaster.org), and skin manifestations of the first child in the neonatal period.

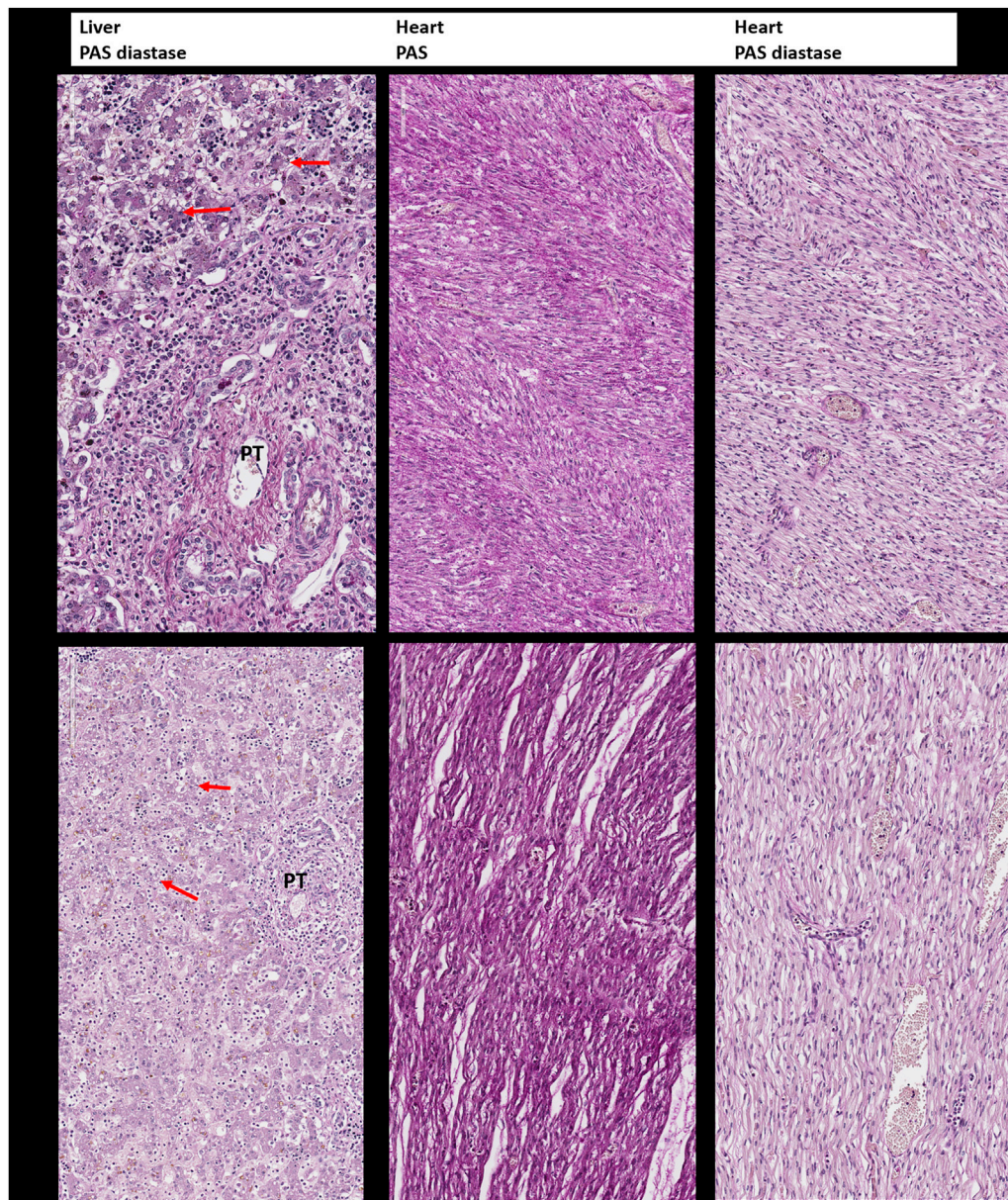
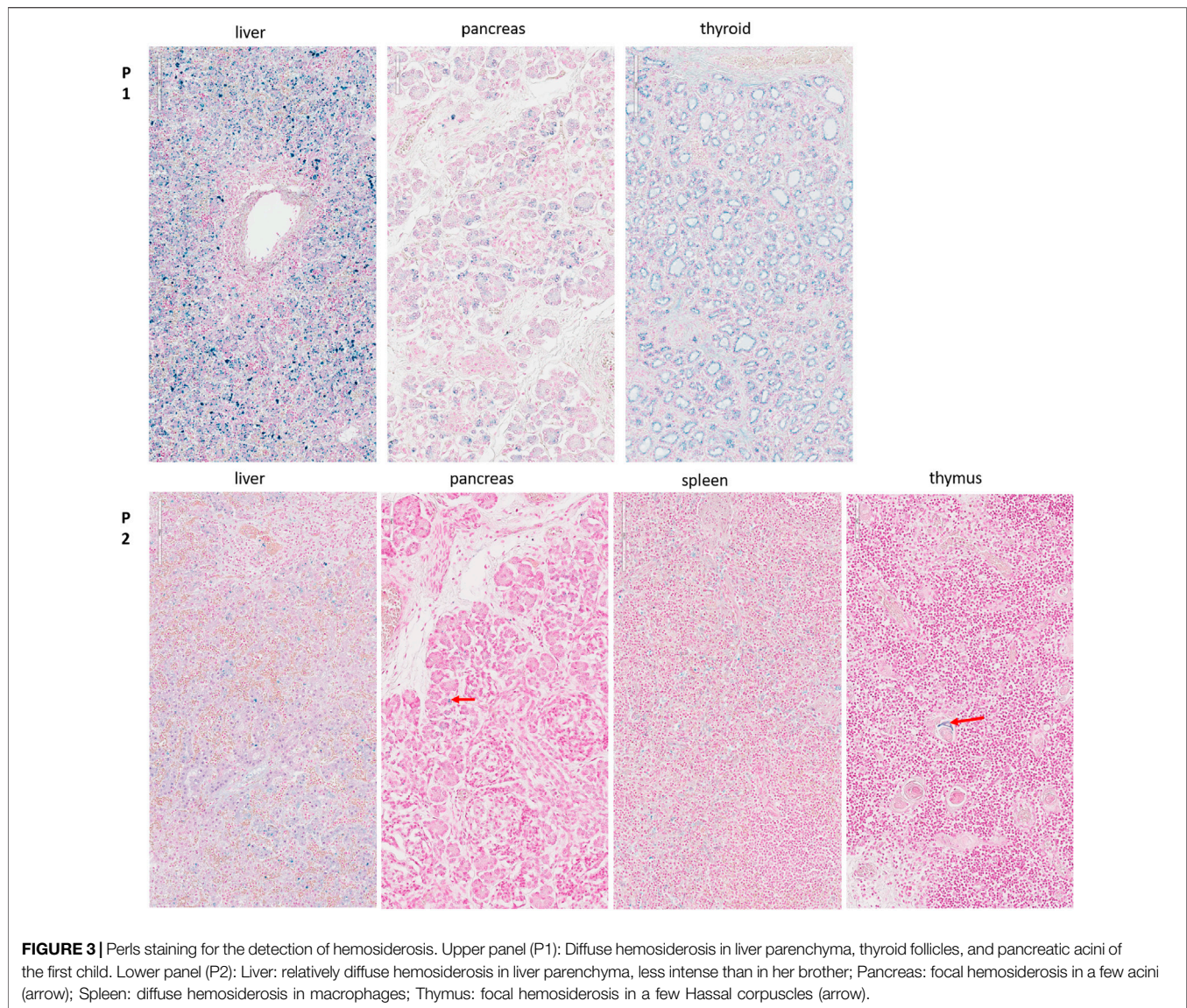


FIGURE 2 | Periodic Acid–Schiff (PAS) and Periodic Acid–Schiff–diastase (PAS-D, PAS diastase) staining for the detection of glycogen. Upper panel: Liver and heart tissue of the first child: no evidence of glycogen storage and diffuse small vacuoles of steatosis in the hepatocytes (arrow). PT: portal tract. Lower panel: Liver and heart tissue of the second child with the same findings as in the brother.

Patient 1 was male and the first child of healthy French European parents (**Figure 1A**). The mother was a 30-year-old with a history of two spontaneous abortions. Pregnancy was complicated by oligohydramnios and intrauterine growth retardation. Prenatal ultrasound examinations did not show any malformation and the couple did not wish further prenatal genetic diagnosis. Pregnancy was marked by rupture of the amniotic membrane at 31 + 2 weeks of gestation and administration of antenatal corticosteroids. The infant was born prematurely at 35 + 1 weeks of gestation by vaginal delivery with a birth weight of 1,840 g (3rd percentile), length of 42.5 cm (3rd

percentile), and occipitofrontal circumference (OFC) of 31.2 cm (10th percentile). Apgar scores were 10/10/10/10 at 1, 3, 5, and 10 min, respectively. Physical examination showed a congenital anomaly of all four extremities resembling amniotic bands with extremity edema and tendinous retractions at the level of the joints (**Figure 1B**), underdeveloped thenar, rigid fingers, signs of oligohydramnios with low-set ears, hypertelorism, broad forehead and flat nose, a narrow chest, and arthrogyrosis (**Supplementary Figure S1A**). The most prominent feature was the very dry, nonelastic, and hard skin. Chest x-ray showed a narrow thorax and lung hypoplasia as a



consequence of the oligohydramnios and cardiomegaly with right deviation of the heart. There was no sign of hepatosplenomegaly on physical examination, with no abdominal ultrasound performed. After an initial stable cardiac and respiratory state, the neonate developed progressive respiratory failure at 12 h of age and was transferred to a level III Neonatal Intensive Care Unit. He was difficult to ventilate adequately, and developed pneumomediastinum and pneumothorax requiring exsufflation. He was subsequently switched from conventional ventilation to high-frequency oscillatory ventilation. Sequential echocardiographs were performed showing severe persistent pulmonary hypertension, a large right-to-left shunting patent ductus arteriosus, and a mild but significant left ventricle hypokinesia with mild mitral and aortic insufficiency. Despite administration of dobutamine and norepinephrine, hypotension persisted and the child developed multi-organ failure after 48 h, with anuria, severe metabolic acidosis (pH 6.97), elevated lactate

(15 mmol/L), thrombocytopenia (64 G/L), elevated transaminases, necrosis of the digits (**Figure 1B**), and a progressive respiratory failure. He died on postnatal day 3. The immediate cause of death was hemodynamic instability, ventricular fibrillation, and severe metabolic acidosis.

Patient 2

Patient 2 was female, born to the same parents 20 months after patient 1 (**Figure 1A**). The pregnancy was complicated by prenatal ultrasound findings of hyperechogenic intestines in gestational week 23. Conventional karyotyping and array CGH analysis from amniotic fluid was normal; *CFTR* screening revealed a heterozygous paternal mutation. After premature rupture of the amniotic membrane and chorioamnionitis, the infant was born prematurely at 32 + 4 weeks of gestation by vaginal delivery with a birth weight of 1,800 g (25th–50th percentile), a length of 44.5 cm (50th–75th percentile), and

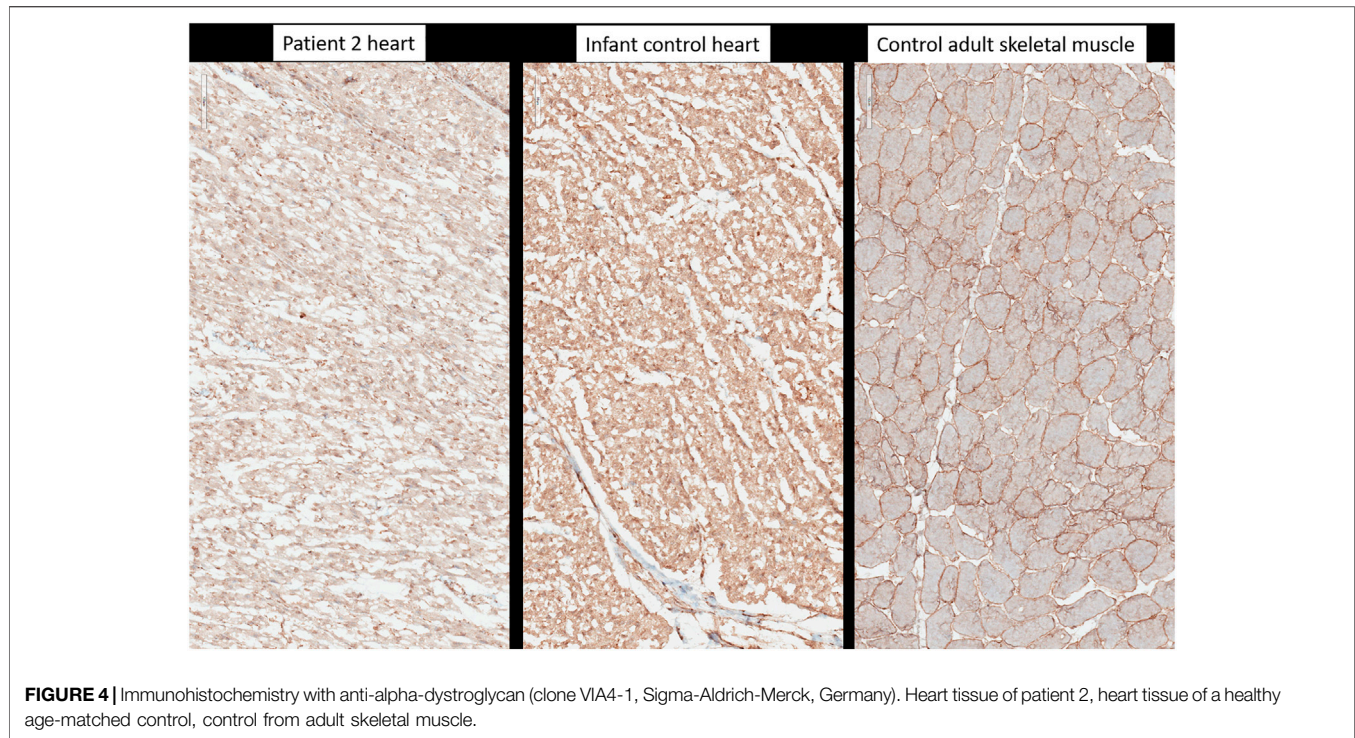


FIGURE 4 | Immunohistochemistry with anti-alpha-dystroglycan (clone VIA4-1, Sigma-Aldrich-Merck, Germany). Heart tissue of patient 2, heart tissue of a healthy age-matched control, control from adult skeletal muscle.

OFC of 29 cm (25th percentile). Apgar scores were 9/8/8/10 at 1, 3, 5, and 10 min, respectively. Physical exam showed collodion membrane with tight and hard skin with fissures, no ectropion or eclabion, and edema of the extremities (**Supplementary Figures S1A,B**). The fingers and toes were fixed in rigid volar/plantar flexion (**Supplementary Figure S1B**) and there was a blackish appearance of some fingers, raising the possibility of necrosis. Relieving incisions of the fingers (fingers II to V of both hands) were performed on day 4. There was no evidence of respiratory distress syndrome and the child was maintained on nasal CPAP (continuous positive airway pressure) until she developed apneic episodes and intubation was indicated. Although initially stable hemodynamically, on postnatal day 5, she developed several bradycardic episodes. There was no sign of hepatosplenomegaly and abdominal ultrasound was normal. Laboratory investigations revealed a diffuse coagulation defect (thrombocyte count: 201 G/L; total coagulation activity: 5.29xT, normal range: 0.8–1.2; Fibrinogen 1.8 g/L; Factor II: 9%, Factor V: 7%, Factor VII: 8%, Factor X: 16%) and plasma transfusion was administered. Ophthalmological examination showed extensive retinal hemorrhage of the right eye. On postnatal day 7, following episodes of crying and recurrent vomiting, the child developed a sudden cardiopulmonary arrest leading to death.

Molecular Genetic Analyses

Since there was no confirmed genetic diagnosis during the neonatal period in either of the siblings, postmortem genetic analyses were performed. With the clinical suspicion of congenital syndromic ichthyosis, a multi-gene panel was initially performed from DNA extracted from a postmortem liver sample of the second child of the family. Mutation

analysis of 66 genes associated with non-syndromic and syndromic ichthyosis (in-house designed HaloPlex Custom Kit, Agilent Technologies, Inc. Santa Clara, CA, United States) detected no pathogenic alterations.

For further analysis, trio whole-exome sequencing of the first child and the parents was performed using DNA extracted from a postmortem thymus sample and from peripheral blood of the healthy parents. Target enrichment of all coding genomic regions (exome) was performed with a Twist Human Core Exome Kit (Twist Bioscience) and sequencing was run on an Illumina platform (NextSeq500 System, San Diego, United States) with 150-bp paired-end reads. Candidate causative variants were validated by Sanger sequencing.

Histopathological Analyses

Histopathological examination of the skin (H&E staining) was performed from the abdominal wall along the incision that was performed for internal examination in the first child (**Figure 5A**) and from the right inner thigh and the scalp of the second affected child (**Figures 5B,C**).

To assess glycogen storage in the liver and heart tissue of the first and second child, Periodic Acid–Schiff (PAS) and Periodic Acid–Schiff–diastase (PAS diastase) stainings were performed on FFPE tissues. For the detection of hemosiderosis, Perls staining was performed on FFPE of liver, spleen, pancreas, renal, thyroid, and thymus samples.

O-mannosylation was assessed by immunohistochemistry on frozen heart tissue sample of the second child with anti- α -Dystroglycan antibody (clone VIA4-1, Sigma-Aldrich Merck, Germany) directed against the O-mannosyl glycans of alpha-dystroglycan. As a control, a normal heart tissue sample from a

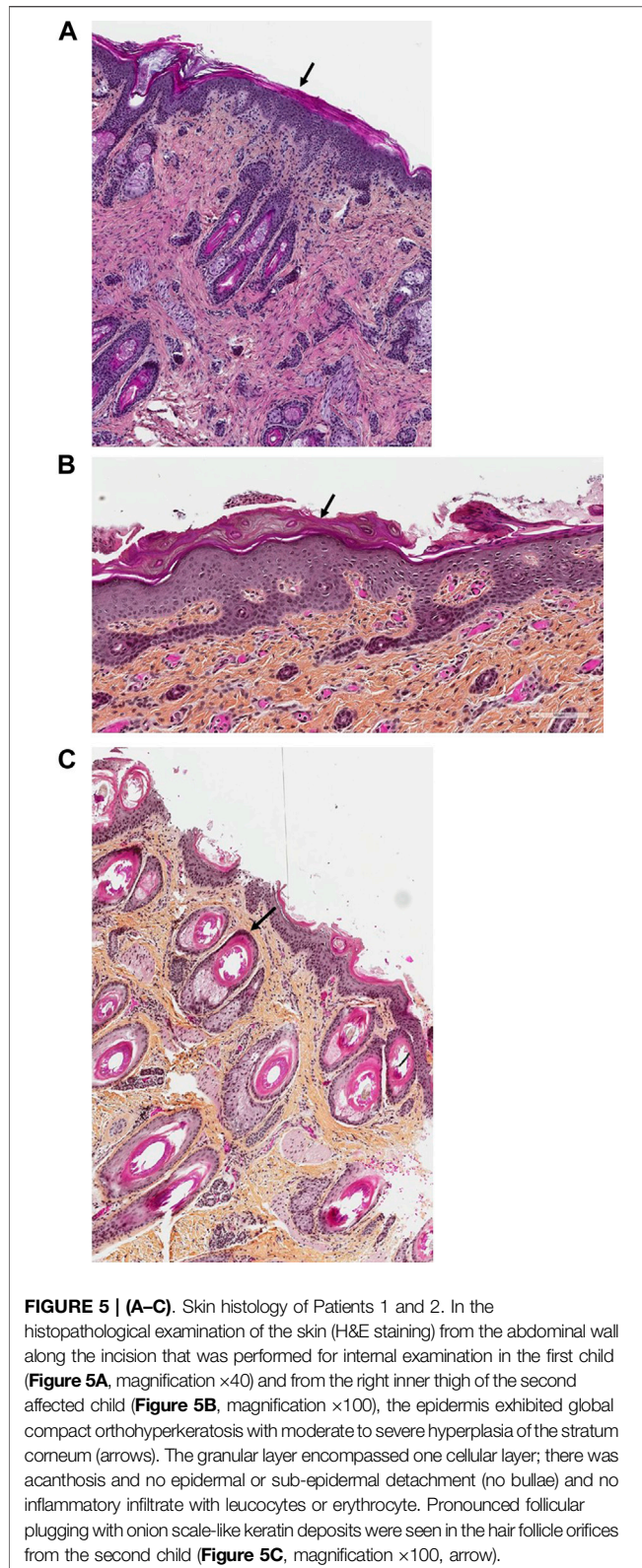


FIGURE 5 | (A–C). Skin histology of Patients 1 and 2. In the histopathological examination of the skin (H&E staining) from the abdominal wall along the incision that was performed for internal examination in the first child (**Figure 5A**, magnification $\times 40$) and from the right inner thigh of the second affected child (**Figure 5B**, magnification $\times 100$), the epidermis exhibited global compact orthohyperkeratosis with moderate to severe hyperplasia of the stratum corneum (arrows). The granular layer encompassed one cellular layer; there was acanthosis and no epidermal or sub-epidermal detachment (no bullae) and no inflammatory infiltrate with leucocytes or erythrocyte. Pronounced follicular plugging with onion scale-like keratin deposits were seen in the hair follicle orifices from the second child (**Figure 5C**, magnification $\times 100$, arrow).

healthy proband of the same age was used. To determine whether the antibody worked, a tissue sample from adult skeletal muscle was used.

RESULTS

Molecular Genetic Results

Trio whole-exome sequencing revealed the compound heterozygous variants NM_014908.3:c.1342G>C, p.(Gly448Arg) and NM_014908.3:c.1558A>G, p.(Thr520Ala) in the *DOLK* gene in the affected first child. Sanger sequencing confirmed both variants in the DNA of the second child (**Figure 1A**). The variant NM_014908.3:c.1342G > C, p. (Gly448Arg), which is maternally derived, has not been described in the literature so far, nor is it listed in clinical databases (ClinVar or HGMD® Professional 2020.3). In the population database gnomAD (the Genome Aggregation Database v2.1.1; <http://gnomad.broadinstitute.org/>), it is listed in heterozygous state in one individual (heterozygous carriers 1/251,402, allele frequency 0.0004%). Several *in silico* algorithms predict a deleterious effect of the variant and even an effect on splicing is predicted. Residue 448 is highly conserved among eukaryotes (**Figure 1A**). According to the ACMG guidelines (Richards et al., 2015) this variant was classified as likely pathogenic (class 4). The second variant NM_014908.3:c.1558A > G, p. (Thr520Ala), which is paternally derived, was already described (Retterer et al., 2016; Rush et al., 2017 and HGMD CM1618868) as pathogenic and results in a non-conservative amino acid substitution of a polar, hydrophilic threonine with a nonpolar, hydrophobic alanine residue. The Threonine-520 residue contributes to a highly conserved cytoplasmic domain (Rush et al., 2017, **Figure 1A**). Data from gnomAD suggest that this variant is rare, with an allele frequency of 0.004% (heterozygous carriers 9/251,490).

No further causative or possibly causative variants were identified in the trio analysis that would explain the striking phenotype in the siblings. Biallelic pathogenic variants in the *DOLK* gene are known to be responsible for DOLK-CDG (OMIM #610768).

Results of the Macroscopic and Histopathological Analyses

In addition to the clinical anomalies previously described in Patient 1 (dry skin, pterygium, arthrogyrosis of joints of all limbs, IUGR, cardiomegaly, and pulmonary hypoplasia, **Supplementary Figure S1A**), autopsy revealed a hypotrophic liver with diffuse steatosis (**Figure 2**, arrow) and hemosiderosis (**Figure 3**). There was no evidence of glycogen storage on PAS diastase staining in the liver (**Figure 2**). The heart weight was increased (18 g, normal value for age = 9.6 ± 2.4 g) without malformation, but ventricle wall measurement did not reveal hypertrophy and no steatosis or glycogen storage was seen on microscopic examination (**Figure 2**). Extrahepatic epithelial hemosiderosis was observed on Perls stainings in pancreatic acini and thyroid follicles (**Figure 3**, lower panel).

On postmortem examination of the second child, there was no IUGR, but pterygium and arthrogyrosis of all limbs and joints, as well as skin anomalies described at birth (**Supplementary Figures S1B,C**). In addition, autopsy highlighted cardiomegaly: the heart weighed 24 g (normal = 12.6 ± 2.9 g) with mildly increased right ventricular thickness (5 mm, normal = $3.2 \pm$

TABLE 1 | Clinical and laboratory comparison of eight DOLK-CDG cases with fatal neonatal or early infantile course.

	Patient 1	Patient 2	Rush et al., 2017 Patient 1	Rush et al., 2017 Patient 2	Hall et al., 2020, P1	Hall et al., 2020, P2	Hall et al., 2020, P3	Hall et al., 2020, P4
Gender	M	F	F	F	M	M	M	F
Age at presentation	Prenatal	Prenatal	At birth	Prenatal	Prenatal/at birth			
Age at death	2 days	7 days	8 days	2 months	9.5 h	24 h	26 h	6 days
Consanguinity	No	No	No	No	No			
DOLK variants	c.1342G > C, <i>p.</i> (Gly448Arg)/c.1558A > G, <i>p.</i> (Thr520Ala)	c.1342G > C, <i>p.</i> (Gly448Arg)/c.1558A > G, <i>p.</i> (Thr520Ala)	c.951C > A, <i>p.</i> (Tyr327*)/c.1558A > G, <i>p.</i> (Thr520Ala)	c.951C > A, <i>p.</i> (Tyr327*)/c.1558A > G, <i>p.</i> (Thr520Ala)	c.1262T > C, <i>p.</i> (Leu421Pro)/c.1373G > T, <i>p.</i> (Gly458Val)			
Pregnancy history of the mother	Two spontaneous abortions	Two spontaneous abortions	Four spontaneous abortions	Four spontaneous abortions	Two early spontaneous abortions			
Pregnancy complications	Oligohydramnios and intrauterine growth retardation	Hyperechogenic intestines	Polyhydramnios	Polyhydramnios and apparent camptodactyly	Polyhydramnios, maternal hypoglycemia (2/4), reduced fetal activity (4/4)			
Gestational weeks at birth	35 + 1	32 + 4	32 + 3	33 + 1	39	40	38	36
Birth measurements	1,840 g (3rd <i>p.</i>) 42.5 cm (3rd <i>p.</i>)	1,800 g (25th–50th <i>p.</i>)	2,060 g (50th <i>p.</i>) 48 cm (>97th <i>p.</i>)	NR	2,580 g (3rd <i>p.</i>) 45 cm (<3rd <i>p.</i>)	2,720 g (5th <i>p.</i>)	2,320 g (3rd <i>p.</i>) 47 cm (10th <i>p.</i>)	2,381 g (25th <i>p.</i>) 48 cm (50th <i>p.</i>)
Weight	31.2 cm (10th <i>p.</i>)	44.5 cm (50th–75th <i>p.</i>)	NR		33 cm (10th <i>p.</i>)		31 cm (3rd <i>p.</i>)	32 cm (25th <i>p.</i>)
Length		29 cm (25th <i>p.</i>)						
OFC								
Facial dysmorphism	Low-set ears, large earlobe, hypertelorism, broad forehead, and flat nose	No, especially no ectropion or eclabion	Taut, shiny skin over the face, slightly downward slanting palpebral fissures	NR	Skin creases on forehead	NR	Relatively normal face	Normal face with forehead creases
Skin (macroscopic)	Collodion membrane with very dry, nonelastic skin	Collodion membrane with tight skin with fissures	Collodion membrane with taut, shiny skin over the entire body	Collodion membrane with taut, shiny skin	Generalized hyperkeratosis, thick skin, linear skin creases	NR	NR	Very thick and cracked soles
Skin histology	Diffuse global hyperkeratosis, compact orthokeratosis, hyperplasia of the stratum corneum, thin granular layer	Diffuse global hyperkeratosis, hyperplasia of the stratum corneum, dilated follicular ostiums, and pronounced follicular plugging	NR	Compact hyperkeratosis with focal parakeratosis, a normal granular layer, minimal dermal inflammation EM: lipid droplets in the stratum corneum	NR	NR	Hyperkeratosis of the skin	NR
Growth retardation	Yes	No	No	NR	3/4 yes			
Microcephaly	No	No	NR	NR	No			
Brain anomalies	NR	Periventricular hemorrhage	No	NR, autopsy declined	NR			

(Continued on following page)

TABLE 1 | (Continued) Clinical and laboratory comparison of eight DOLK-CDG cases with fatal neonatal or early infantile course.

	Patient 1	Patient 2	Rush et al., 2017 Patient 1	Rush et al., 2017 Patient 2	Hall et al., 2020, P1	Hall et al., 2020, P2	Hall et al., 2020, P3	Hall et al., 2020, P4
Cardiac pathology	Cardiomegaly	Cardiomegaly	Right ventricular hypertrophy, biventricular dilation, moderate-severe atrial dilation	Dilatative cardiomyopathy, first-degree heart block	Heart block, cardiomegaly			
Pulmonary manifestations	Pulmonary hypoplasia with focal alveolar bleeding	Thrombosis of the pulmonary arteries with calcification of the vascular walls	Lung development in the late canalicular or early saccular phase, delayed for age	NR	NR			
Gastrointestinal tract manifestations	Hypotrophic liver and steatosis hepatis	Episodic vomiting, hypotrophic liver, and steatosis hepatis	Hepatosplenomegaly with fibrosis, elevated transaminases	Elevated transaminases	NR	Hepatosplenomegaly	Hepatosplenomegaly	Splenomegaly
Digital and joint anomalies	Congenital anomaly of all four extremities resembling amniotic bands with extremity edema and tendinous retractions at the level of the joints, rigid fingers	Edema of the extremities, fingers, and toes fixed in rigid volar/plantar flexion, necrosis of the fingers	Necrosis of the distal phalanges of the hands and feet, sparing the thumbs and halluces fingers and toes fixed in rigid volar/plantar flexion	Milder digital constrictions, less severe digital amputation	Joint flexion, 10-digit circumferential skin constrictions with hypoplastic, absent, and/or clubbed nails	Additionally right knee contracture	Mild contractures of the large joints	Soft tissue lesion protruding from the dorsal surface of the distal phalanx of the second digit of the right hand
Hematologic abnormalities	Coagulation defect, bleeding, and necrosis	Diffuse coagulation defect	NR	Anemia thrombocytopenia	Anemia thrombocytopenia	NR	NR	Thrombocytopenia
Metabolic abnormalities	Severe metabolic acidosis, lactacidemia	Severe metabolic acidosis, lactacidemia	Hypothyroidism	Hypothyroidism	Hypoglycemia hypokalemia	NR	Hyperbilirubinemia	Hypoglycemia

1 mm) without microscopic anomalies. No glycogen storage was seen on PAS and PAS diastase stainings (Figure 2). Immunohistochemistry with α -Dystroglycan antibody on frozen heart tissue showed a reduced expression compared to an age-matched control (Figure 4).

Liver weight in the second child was normal but diffuse steatosis (Figure 2) and hemosiderosis, less intense than in the brother, were present (Figure 3). Extrahepatic hemosiderosis was also seen on Perls staining in macrophages of spleen (diffuse hemosiderosis), while there was focal hemosiderosis in the thymus, in a few Hassall corpuscles (arrow), and in the pancreatic acini (Figure 3).

On histopathological examination of the skin from the abdominal wall (Figure 5A) of Patient 1, the epidermis exhibited global compact orthohyperkeratosis with moderate to severe hyperplasia of the stratum corneum (Figure 5A, arrow). The granular layer encompassed one cellular layer, and there was acanthosis and no epidermal or sub-epidermal detachment (no bullae) and no inflammatory infiltrate with leucocytes or erythrocyte (no signs of erythroderma). Histopathology from the right inner thigh of the second child was similar to those of her brother (Figure 5B); from the scalp, it showed pronounced follicular plugging with onion scale-like keratin deposits in hair follicle orifices (Figure 5C, arrow).

DISCUSSION

Here, we present two new cases of a lethal neonatal phenotype of DOLK-CDG whose severe ichthyosis at birth initially misdirected diagnostic efforts towards an autosomal recessive congenital ichthyosis. However, the combination of severe skin phenotype, distal digital constrictions, cardiomegaly, thrombocytopenia, coagulation defect, and multi-organ failure led to reconsideration and suspicion of an inborn error of metabolism. If CDG is suspected or considered early in the differential diagnosis of severely ill neonates, transferrin isoelectric focusing can be performed to screen for N-linked glycosylation defects as a rapid biochemical first-tier investigation. Due to the rapid fatal course in both of our patients, unfortunately, no isoelectric focusing of serum transferrin was performed. However, we attempted to show the effects of the compound heterozygous mutations of the dolichol kinase gene on reduced O-mannosylation in the second child. Dolichol-phosphate is converted to dolichol-phosphate-mannose, the monosaccharide donor for N-glycosylation inside the ER lumen and for O-mannosylation of alpha-dystroglycan. Immunohistochemistry with anti- α -Dystroglycan antibody directed against the O-mannosyl glycans of α -Dystroglycan on frozen heart tissue sample of the second child showed a reduced expression as an evidence of deficient protein mannosylation.

Dolichol kinase deficiency (DK) can present with a wide range and severity of symptoms (Kranz et al., 2007; Lefeber et al., 2011; Lieu et al., 2013; Rush et al., 2017; Hall et al., 2020). It can often be fatal, particularly when manifesting with cardiomyopathy. At the most severe end of the spectrum, two independent families with two and four affected children each, presenting with a lethal neonatal course including severe ichthyosis, digit skin

constriction rings, dilated cardiomyopathy/cardiomegaly, hepatosplenomegaly, thrombocytopenia, hypoglycemia, and hypothyroidism, have been reported (Rush et al., 2017; Hall et al., 2020). Review of those most severely affected cases shows symptoms partly overlapping with those of our patients (Table 1). Besides presenting with striking congenital ichthyosis, both of our patients had a narrow chest and evidence of pulmonary hypoplasia on autopsy. In both children, evidence of hepatic and extrahepatic (spleen, thymus, thyroid, and pancreas) hemosiderosis was seen, which has only been described in a few cases of CDG so far (Agarwal et al., 2007; Léticée et al., 2010) and can lead to hematological, endocrinological, and immunological abnormalities. Endocrinopathy has already been described in other DOLK-CDG cases. Both of our patients had cardiomegaly; however, due to the rapid fatal course, they did not yet manifest signs of a dilatative cardiomyopathy. Deficient O-mannosylation of α -Dystroglycan in the heart tissue also points to a functional defect of the heart muscle in our second patient. Since altered glycosylation of certain coagulation factors can alter their plasma levels and thus influence the coagulation profile (Hansson and Stenflo, 2005), diffuse coagulopathies are often observed in CDG. The first child of the family showed necrosis of the digits already on the second day of his life probably due to thrombosis possibly caused by deficient glycosylation of clotting factors, e.g., Protein C and Protein S. The second child showed a severe diffuse coagulation defect with strongly decreased coagulation factor activities as an expression of a glycosylation defect and consequent intraretinal hemorrhage and required plasma transfusion.

It is interesting to note that the mothers in all three families reported with severe neonatal DOLK-CDG children had previous early miscarriages (Rush et al., 2017; Hall et al., 2020 and our family). In our family, no additional genetic cause was detected in the trio-exom sequencing, raising the possibility of a contribution of the DOLK mutation. Other prenatal manifestations in the fatal neonatal cases were IUGR (2/8), oligohydramnios (2/8), polyhydramnios (5/8), hyperechogenic intestines (in our case), and unexplained hypoglycemia of the mother during the pregnancy (2/8) (Rush et al., 2017; Hall et al., 2020 and Table 1).

Skin abnormalities have been described in about 20% of the different CDG forms (Rymen et al., 2012; Haijes et al., 2020; Komlosi et al., 2020). Recently, some rare forms have also been classified among the syndromic ichthyosis due to their characteristic skin manifestations (Fischer and Bourrat, 2020). Both siblings described here showed a striking congenital ichthyosis as previously described in this disease by Rush et al. (2017) and mentioned by Kranz et al. (2007) while in the four siblings with fatal neonatal DOLK-CDG recently described by Hall et al. (2020), less severe ichthyosis was seen. The pathomechanisms for the skin involvement in dolichol kinase deficiency are still not fully understood and there is only one previous report describing the detailed dermatopathological changes in this disease (Rush et al., 2017) while Hall et al. shows only the hyperkeratosis in one of the four siblings (Hall et al., 2020). Most theories explaining skin involvement are based on the assumption of the instability of key glycoproteins in skin. Since dolichol biosynthesis follows

the sterol pathway up to the formation of farnesyl-PP, it has also been proposed that accumulation of toxic sterol precursors could contribute to the phenotype in patients with SRD5A3- and DOLK-CDG (Gründahl et al., 2012; Rymen and Jaeken, 2014). Since the diagnosis of a CDG disorder was established in our cases on postmortem samples, 3 years after the death of the second child in the family, no fresh tissue sample was available to assess the accumulation of a possible toxic metabolite precursor. Glycogen storage was not observed in the liver and heart tissue of both children on microscopic examination. One missense mutation found in our patients [*DOLK* NM_014908.3:c.1558A>G, p.(Thr520Ala)] was also found in a patient published by Rush et al. (2017), and the reported dermatopathological changes in this patient concurred with ours as well. Histopathology in our cases was typical for ichthyosis with global compact orthohyperkeratosis, thin granular layer, and follicular plugging (Figures 5A–C). Unfortunately, no skin specimen was available anymore for further ultrastructural analysis in our case. In the previous report by Denecke and Kranz (2009), electron microscopy of a skin biopsy sample revealed hyperkeratosis (Kranz et al., 2007), while Rush et al. showed evidence of abnormal lipid droplet accumulation in the stratum corneum and keratinocytes (Rush et al., 2017). With increasing awareness for rare metabolic disorders including CDG and with the expanding possibilities of rapid genetic diagnoses even in the neonatal setting, it will be very important to further elucidate the pathomechanism of skin and organ involvement in future confirmed DOLK-CDG cases.

CONCLUSION

Our two cases presenting a detailed histopathology besides the clinical data expand the prenatal and postnatal phenotype of DOLK-CDG. They illustrate the broad differential diagnosis of neonatal syndromic ichthyosis and emphasize the importance to actively search for organ involvement in neonates with ichthyosis and to consider the congenital disorders of glycosylation among the possible diagnoses. Congenital ichthyosis with cardiac involvement and distal digital constrictions in combination with multi-organ failure and coagulation defects should prompt strong consideration of DOLK-CDG. In case of suspicion, a rapid first-tier screening using transferrin isoelectric focusing can be performed, followed by genetic analyses. Trio exome sequencing in children with severe disease course and early perinatal death can be valuable in informing the reproductive options of the affected families and allowing them access to prenatal and preimplantation genetic diagnosis.

DATA AVAILABILITY STATEMENT

The original contributions presented in the study are included in the article/**Supplementary Material**. Further inquiries can be directed to the corresponding author.

ETHICS STATEMENT

The studies involving human participants were reviewed and approved by Ethics Committee of the University of Freiburg (ethical code number: 436/17). Written informed consent to participate in this study was provided by the participants' legal guardian/next of kin. Written informed consent was obtained from the minor(s)' legal guardian/next of kin for the publication of any potentially identifiable images or data included in this article.

AUTHOR CONTRIBUTIONS

JF conceived the manuscript. OC performed the clinical diagnosis and treatment of the neonate, and OC, JM-H, and NJ initiated the genetic diagnostics and DS carried out the genetic counseling and further genetic diagnostics of the proband and their parents; SC-F carried out the macroscopic and microscopic pathological examinations; JK and JF carried out the molecular analyses and reviewed the molecular genetic results; AZ performed the bioinformatic analyses; KK and JF planned the manuscript; KK, JF, and IH interpreted the results and researched the literature; KK and JF prepared the manuscript. OC, SC-F, DS, IH, JK, AZ, and JF edited and reviewed the manuscript; JF contributed substantially to the conception, design, and critical revision of the work for important intellectual content. KK drafted the paper and coordinated writing of the manuscript. All authors discussed, read, and approved the manuscript. All authors approve the version to be published and agree to be accountable for all aspects of the work in ensuring that questions related to the accuracy or integrity of any part of the work are appropriately investigated and resolved.

FUNDING

This work was partially supported by the German Research Foundation, Grant/Award Number: FI1767/3-1. The authors confirm independence from the sponsors; the content of the article has not been influenced by the sponsors in any way.

ACKNOWLEDGMENTS

We wish to thank the family for their consent to the publication. We also thank the team of the molecular genetic laboratory of the Institute of Human Genetics Freiburg, Germany, and the team of Institute of Pathology of the Hôpital Femme Mère Enfant, Hospices Civils de Lyon, France for technical assistance in the analyses.

SUPPLEMENTARY MATERIAL

The Supplementary Material for this article can be found online at: <https://www.frontiersin.org/articles/10.3389/fgene.2021.719624/full#supplementary-material>

REFERENCES

- Agarwal, B., Ahmed, A., Rushing, E. J., Bloom, M., Kadom, N., Vezina, G., et al. (2007). Congenital Disorder of Glycosylation-X: Clinicopathologic Study of an Autopsy Case with Distinct Neuropathologic Features. *Hum. Pathol.* 38, 1714–1719. doi:10.1016/j.humpath.2007.05.028
- Alsubhi, S., Alhashem, A., Faqeih, E., Alfadhel, M., Alfaifi, A., Altuwaijri, W., et al. (2017). Congenital Disorders of Glycosylation: The Saudi Experience. *Am. J. Med. Genet.* 173, 2614–2621. doi:10.1002/ajmg.a.38358
- Buczowska, A., Swiezewska, E., and Lefeber, D. J. (2015). Genetic Defects in Dolichol Metabolism. *J. Inher. Metab. Dis.* 38, 157–169. doi:10.1007/s10545-014-9760-1
- Cantagrel, V., Lefeber, D. J., Ng, B. G., Guan, Z., Silhavy, J. L., Bielas, S. L., et al. (2010). SRD5A3 Is Required for Converting Polyprenol to Dolichol and Is Mutated in a Congenital Glycosylation Disorder. *Cell* 142, 203–217. doi:10.1016/j.cell.2010.06.001
- Denecke, J., and Kranz, C. (2009). Hypoglycosylation Due to Dolichol Metabolism Defects. *Biochim. Biophys. Acta (Bba) - Mol. Basis Dis.* 1792, 888–895. doi:10.1016/j.bbadis.2009.01.013
- Fischer, J., and Bourrat, E. (2020). Genetics of Inherited Ichthyoses and Related Diseases. *Acta Derm. Venereol.* 100, adv00096. doi:10.2340/00015555-3432
- Francisco, R., Marques-da-Silva, D., Brasil, S., Pascoal, C., Dos Reis Ferreira, V., Morava, E., et al. (2019). The challenge of CDG Diagnosis. *Mol. Genet. Metab.* 126, 1–5. doi:10.1016/j.ymgme.2018.11.003
- Gründahl, J. E. H., Guan, Z., Rust, S., Reurnert, J., Müller, B., Du Chesne, I., et al. (2012). Life with Too Much Polyprenol: Polyprenol Reductase Deficiency. *Mol. Genet. Metab.* 105, 642–651. doi:10.1016/j.ymgme.2011.12.017
- Haijes, H. A., Jaeken, J., and Hasselt, P. M. (2020). Hypothesis: Determining Phenotypic Specificity Facilitates Understanding of Pathophysiology in Rare Genetic Disorders. *J. Inher. Metab. Dis.* 43, 701–711. doi:10.1002/jimd.12201
- Hall, B. D., Stevenson, R. E., and Jones, J. R. (2020). Fatal Hyperkeratosis Syndrome in Four Siblings Due to Dolichol Kinase Deficiency. *Am. J. Med. Genet.* 182, 1421–1425. doi:10.1002/ajmg.a.61574
- Hansson, K., and Stenflo, J. (2005). Post-translational Modifications in Proteins Involved in Blood Coagulation. *J. Thromb. Haemost.* 3, 2633–2648. doi:10.1111/j.1538-7836.2005.01478.x
- Helander, A., Stödberg, T., Jaeken, J., Matthijs, G., Eriksson, M., and Eggertsen, G. (2013). Dolichol Kinase Deficiency (DOLK-CDG) with a Purely Neurological Presentation Caused by a Novel Mutation. *Mol. Genet. Metab.* 110, 342–344. doi:10.1016/j.ymgme.2013.07.002
- Jaeken, J., Rymen, D., and Matthijs, G. (2014). Congenital Disorders of Glycosylation: Other Causes of Ichthyosis. *Eur. J. Hum. Genet.* 22, 444. doi:10.1038/ejhg.2013.168
- Kahrizi, K., Hu, C. H., Garshasbi, M., Abedini, S. S. S., Ghadami, S., Kariminejad, R., et al. (2011). Next Generation Sequencing in a Family with Autosomal Recessive Kahrizi Syndrome (OMIM 612713) Reveals a Homozygous Frameshift Mutation in SRD5A3. *Eur. J. Hum. Genet.* 19, 115–117. doi:10.1038/ejhg.2010.132
- Kapusta, L., Zucker, N., Frenckel, G., Medalion, B., Gal, T. B., Birk, E., et al. (2013). From Discrete Dilated Cardiomyopathy to Successful Cardiac Transplantation in Congenital Disorders of Glycosylation Due to Dolichol Kinase Deficiency (DK1-CDG). *Heart Fail. Rev.* 18, 187–196. doi:10.1007/s10741-012-9302-6
- Komlosi, K., Gläser, S., Kopp, J., Hotz, A., Alter, S., Zimmer, A. D., et al. (2020). Neonatal Presentation of COG6-CDG with Prominent Skin Phenotype. *JIMD Rep.* 55, 51–58. doi:10.1002/jimd.12154
- Kouwenberg, D., Gardeitchik, T., Mohamed, M., Lefeber, D. J., and Morava, E. (2014). Wrinkled Skin and Fat Pads in Patients with ALG8-CDG: Revisiting Skin Manifestations in Congenital Disorders of Glycosylation. *Pediatr. Dermatol.* 31, e1–e5. doi:10.1111/pde.12233
- Kranz, C., Jungeblut, C., Denecke, J., Erlekotte, A., Sohlbach, C., Debus, V., et al. (2007). A Defect in Dolichol Phosphate Biosynthesis Causes a New Inherited Disorder with Death in Early Infancy. *Am. J. Hum. Genet.* 80, 433–440. doi:10.1086/512130
- Lefeber, D. J., de Brouwer, A. P. M., Morava, E., Riemersma, M., Schuurs-Hoeijmakers, J. H. M., Absmanner, B., et al. (2011). Autosomal Recessive Dilated Cardiomyopathy Due to DOLK Mutations Results from Abnormal Dystroglycan O-Mannosylation. *Plos Genet.* 7, e1002427. doi:10.1371/journal.pgen.1002427
- Léticée, N., Bessières-Grattagliano, B., Dupré, T., Vuillaumier-Barrot, S., de Lonlay, P., Razavi, F., et al. (2010). Should PMM2-Deficiency (CDG Ia) Be Searched in Every Case of Unexplained Hydrops Fetalis? *Mol. Genet. Metab.* 101, 253–257. doi:10.1016/j.ymgme.2010.06.009
- Lieu, M. T., Ng, B. G., Rush, J. S., Wood, T., Basehore, M. J., Hegde, M., et al. (2013). Severe, Fatal Multisystem Manifestations in a Patient with Dolichol Kinase-Congenital Disorder of Glycosylation. *Mol. Genet. Metab.* 110, 484–489. doi:10.1016/j.ymgme.2013.09.016
- Ng, B. G., Hackmann, K., Jones, M. A., Eroshkin, A. M., He, P., Williams, R., et al. (2021). Mutations in the Glycosylphosphatidylinositol Gene PIGL Cause CHIME Syndrome. *Am. J. Hum. Genet.* 90, 685–688. doi:10.1016/j.ajhg.2012.02.010
- Oji, V., Tadimi, G., Akiyama, M., Blanchet Bardon, C., Bodemer, C., Bourrat, E., et al. (2010). Revised Nomenclature and Classification of Inherited Ichthyoses: Results of the First Ichthyosis Consensus Conference in Sorèze 2009. *J. Am. Acad. Dermatol.* 63, 607–641. doi:10.1016/j.jaad.2009.11.020
- Paprocka, J., Jezela-Stanek, A., Tylki-Szymańska, A., and Grunewald, S. (2021). Congenital Disorders of Glycosylation from a Neurological Perspective. *Brain Sci.* 11, 88. doi:10.3390/brainsci11010088
- Retterer, K., Juusola, J., Cho, M. T., Vitazka, P., Millan, F., Gibellini, F., et al. (2016). Clinical Application of Whole-Exome Sequencing across Clinical Indications. *Genet. Med.* 18, 696–704. doi:10.1038/gim.2015.148
- Richards, S., Aziz, N., Aziz, N., Bale, S., Bick, D., Das, S., et al. (2015). Standards and Guidelines for the Interpretation of Sequence Variants: a Joint Consensus Recommendation of the American College of Medical Genetics and Genomics and the Association for Molecular Pathology. *Genet. Med.* 17, 405–423. doi:10.1038/gim.2015.30
- Rush, E. T., Baker, C. V., and Rizzo, W. B. (2017). Dolichol Kinase Deficiency (DOLK-CDG): Two New Cases and Expansion of Phenotype. *Am. J. Med. Genet.* 173, 2428–2434. doi:10.1002/ajmg.a.38287
- Rymen, D., and Jaeken, J. (2014). Skin Manifestations in CDG. *J. Inher. Metab. Dis.* 37, 699–708. doi:10.1007/s10545-014-9678-7
- Rymen, D., Keldermans, L., Race, V., Régál, L., Deconinck, N., Dionisi-Vici, C., et al. (2012). COG5-CDG: Expanding the Clinical Spectrum. *Orphanet. J. Rare Dis.* 7, 94. doi:10.1186/1750-1172-7-94
- Schenk, B., Imbach, T., Frank, C. G., Grubenmann, C. E., Raymond, G. V., Hurvitz, H., et al. (2001). MPDU1 Mutations Underlie a Novel Human Congenital Disorder of Glycosylation, Designated Type if. *J. Clin. Invest.* 108, 1687–1695. doi:10.1172/jci200113419
- Thiel, C., Wortmann, S., Riedhammer, K., Alhaddad, B., Mayatepek, E., Prokisch, H., et al. (2018). Severe Ichthyosis in MPDU1-CDG. *J. Inher. Metab. Dis.* 41, 1293–1294. doi:10.1007/s10545-018-0189-9
- Van Damme, T., Gardeitchik, T., Mohamed, M., Guerrero-Castillo, S., Freisinger, P., Guillemin, B., et al. (2017). Mutations in ATP6V1E1 or ATP6V1A Cause Autosomal-Recessive Cutis Laxa. *Am. J. Hum. Genet.* 100, 216–227. doi:10.1016/j.ajhg.2016.12.010

Conflict of Interest: The authors declare that the research was conducted in the absence of any commercial or financial relationships that could be construed as a potential conflict of interest.

Publisher's Note: All claims expressed in this article are solely those of the authors and do not necessarily represent those of their affiliated organizations, or those of the publisher, the editors, and the reviewers. Any product that may be evaluated in this article, or claim that may be made by its manufacturer, is not guaranteed or endorsed by the publisher.

Copyright © 2021 Komlosi, Claris, Collardeau-Frachon, Kopp, Hausser, Mazereeuw-Hautier, Jonca, Zimmer, Sanlaville and Fischer. This is an open-access article distributed under the terms of the Creative Commons Attribution License (CC BY). The use, distribution or reproduction in other forums is permitted, provided the original author(s) and the copyright owner(s) are credited and that the original publication in this journal is cited, in accordance with accepted academic practice. No use, distribution or reproduction is permitted which does not comply with these terms.