



**HAL**  
open science

# Cytokine release syndrome and tumor lysis syndrome in a multiple myeloma patient treated with palliative radiotherapy: A case report and review of the literature

Axel Cailleateau, Cyrille Touzeau, Bastien Jamet, Valentine Guimas,  
Emmanuel Jouglar, Stéphane Supiot

## ► To cite this version:

Axel Cailleateau, Cyrille Touzeau, Bastien Jamet, Valentine Guimas, Emmanuel Jouglar, et al.. Cytokine release syndrome and tumor lysis syndrome in a multiple myeloma patient treated with palliative radiotherapy: A case report and review of the literature. *Clinical and Translational Radiation Oncology*, 2022, 32, pp.24-28. 10.1016/j.ctro.2021.11.004 . inserm-03561702

**HAL Id: inserm-03561702**

**<https://inserm.hal.science/inserm-03561702>**

Submitted on 8 Feb 2022

**HAL** is a multi-disciplinary open access archive for the deposit and dissemination of scientific research documents, whether they are published or not. The documents may come from teaching and research institutions in France or abroad, or from public or private research centers.

L'archive ouverte pluridisciplinaire **HAL**, est destinée au dépôt et à la diffusion de documents scientifiques de niveau recherche, publiés ou non, émanant des établissements d'enseignement et de recherche français ou étrangers, des laboratoires publics ou privés.



## Case Report

# Cytokine release syndrome and tumor lysis syndrome in a multiple myeloma patient treated with palliative radiotherapy: A case report and review of the literature

Axel Cailleteau<sup>a</sup>, Cyrille Touzeau<sup>b,c,d</sup>, Bastien Jamet<sup>e</sup>, Valentine Guimas<sup>a</sup>, Emmanuel Jouglar<sup>a</sup>, Stéphane Supiot<sup>a,f,\*</sup>

<sup>a</sup> Department of Radiation Oncology, Institut de Cancérologie de l'Ouest, Nantes, St-Herblain, France

<sup>b</sup> Department of Hematology, Centre Hospitalier Universitaire, Nantes, France

<sup>c</sup> CRCINA, INSERM, CNRS, Université d'Angers, Université de Nantes, Nantes, France

<sup>d</sup> Site de Recherche Intégrée sur le Cancer (SIRIC), ILLIAD, Nantes, France

<sup>e</sup> Nuclear Medicine Department, University Hospital of Nantes, Nantes, France

<sup>f</sup> Centre de Recherche en Cancérologie Nantes-Angers (CRCNA), UMR 1232 Inserm – 6299 CNRS, Institut de Recherche en Santé de l'Université de Nantes, Nantes, France



## ARTICLE INFO

## Keywords

Cytokine release syndrome  
Tumor lysis syndrome  
Multiple myeloma  
Radiotherapy  
Leukemia  
Hematology  
Radiation oncology  
Total body irradiation

## ABSTRACT

We present the case of a 53-year-old woman treated with analgesic radiotherapy for a multiple myeloma bone lesion of the forearm. After a first fraction of 5 Gray (Gy), she presented with an acute respiratory syndrome with fever a few hours after the treatment. The same symptoms occurred after the second fraction 3 days later. The patient recovered quickly thanks to intravenous hydration and suspension of the radiotherapy. Biological tests revealed a tumor lysis syndrome. We concluded that the clinical symptoms could be defined as cytokine release syndrome. This is the second time in the literature that cytokine release syndrome has been described following radiotherapy. First, we synthesize TLS and radiotherapy to determine how radiotherapy could be a trigger associated with other well-known factors. Furthermore, we discuss radiotherapy and cytokine release syndrome. **Summary:** We present the case of a woman treated with analgesic radiotherapy for a multiple myeloma bone lesion. Following the first and the second treatment fraction, the patient presented with an acute respiratory syndrome with fever and biological tests revealed a tumor lysis syndrome. We concluded that the clinical symptoms could be defined as cytokine release syndrome. Furthermore, we discuss how radiotherapy could be a trigger of cytokine release syndrome and tumor lysis syndrome in association with chemotherapy drugs.

## Introduction

Using radiotherapy in hematologic malignancies is common, whether to irradiate lymph node sites in lymphoma, or perform total body irradiation in leukemia or symptomatic bone lesions in multiple myeloma (MM). Recently, innovative treatments such as CAR-T cells have changed the prognosis of lymphoma or leukemia and are coming to the forefront in multiple myeloma management [1]. These new treatments are associated with rare toxicities such as cytokine release syndrome (CRS), defined by fever, tachypnea, headache, tachycardia, hypotension, skin rash, and/or hypoxia [2]. The pathophysiology of CRS is caused by the release of effector cytokines (IFN $\gamma$ , TNF $\alpha$ , Interleukin 2) which are responsible for activating monocytes and macrophages,

resulting in the production of pro-inflammatory cytokines (Interleukin 6, IFN $\gamma$ , Interleukin 10, MCP1). CRS as a toxicity of radiotherapy is poorly described in the literature, and to our knowledge only one article describes a case of CRS during RT [3].

Tumor lysis syndrome (TLS) is more common in hematology and is one of the best-known emergencies defined with biological and laboratory settings [4]. It can occur spontaneously or after the use of cytotoxic agents such as chemotherapy. In radiotherapy, this syndrome is more unusual so we wanted to make the synthesis of TLS and radiotherapy to determine how the radiotherapy could be a trigger associated with other well-known factors.

\* Corresponding author at: Department of Radiation Oncology, Institut de Cancérologie de l'Ouest, Nantes, St-Herblain, France.

E-mail addresses: [cyrille.touzeau@chu-nantes.fr](mailto:cyrille.touzeau@chu-nantes.fr) (C. Touzeau), [stephane.supiot@ico-unicancer.fr](mailto:stephane.supiot@ico-unicancer.fr) (S. Supiot).

<https://doi.org/10.1016/j.ctro.2021.11.004>

Received 13 August 2021; Received in revised form 5 November 2021; Accepted 6 November 2021

Available online 12 November 2021

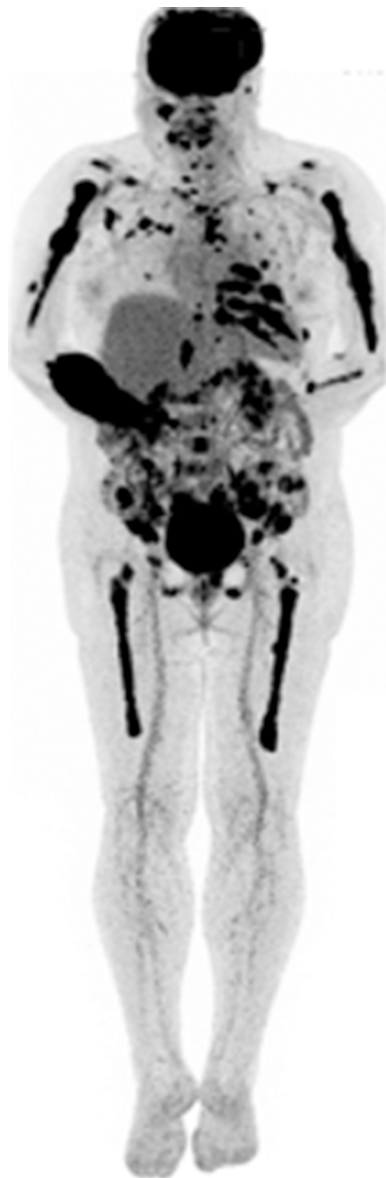2405-6308/© 2021 The Author(s). Published by Elsevier B.V. on behalf of European Society for Radiotherapy and Oncology. This is an open access article under

the CC BY-NC-ND license (<http://creativecommons.org/licenses/by-nc-nd/4.0/>).

## Case history

A 53-year-old woman presented spontaneously at the emergency room with a headache. A brain CT scan showed a frontoparietal extradural hematoma, with no brain herniation, but several cranium osteolysis lesions suggesting MM. Neurosurgeons drained the hematoma and found some bone tissue damage that was sent to a pathologist, who concluded there was plasma cell proliferation. The rest of the balance sheet revealed the following facts: monoclonal gammopathy 31 g/L, IgG kappa with hypogammaglobulinemia A and M. Free light chain kappa 464 mg/L, lambda 10.1 g/L. Anemia 8.1 g/dL, no plasma cell leukemia, myelogram: 4% abnormal plasma cells. Fluorodeoxyglucose-positron emission tomography/computed tomography (FDG-PET/CT) showed diffuse bone marrow uptake, disseminated focal lytic bone lesions, and several extramedullary disease (EMD) lesions, especially an unusual extensive right forearm soft tissue lesion (Fig. 1). The diagnosis of MM with multiple bone lesions was made.

We started a treatment with lenalidomide 25 mg/days 1–14 *per os*; bortezomib 1.3 mg/m<sup>2</sup> subcutaneous injection days 1,4,8,11; dexamethasone 20 mg/days 1–2,4–5,8–9, 11–12.



**Fig. 1.** <sup>18</sup>F-FDG-PET CT Scan: Hypermetabolic lytic bone lesion to the radius, femur, humerus and cranium.

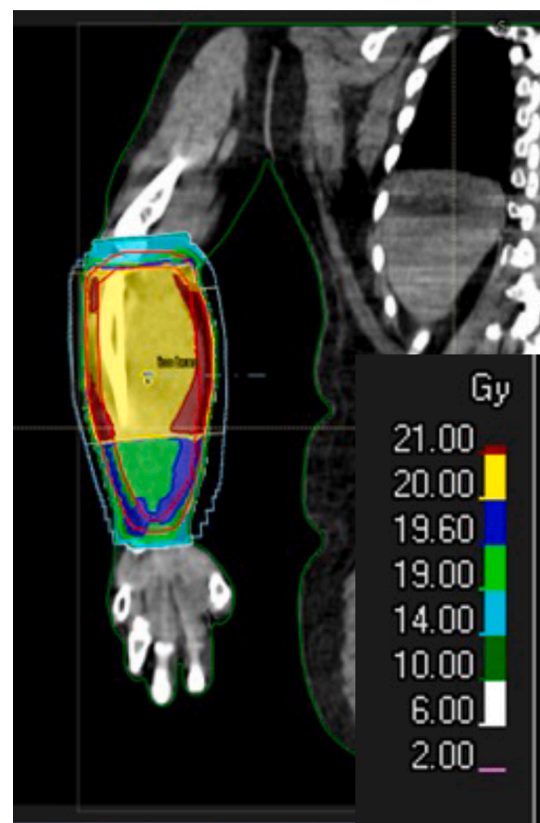
Her principal symptom was pain in the right arm.

She was referred to the radiation oncologist who decided to treat only the forearm with 20 Gray in 4 fractions (5 Gy/fraction)(Fig. 2). At this time, she has received 8 days of dexamethasone, bortezomib twice, and lenalidomide 25 mg per day (Fig. 3).

Two hours after the first session, she experienced acute respiratory distress associated with a temperature of 39.5 °C, cyanosis, oxygen saturation 89%, heart rate 116 bpm, blood pressure 100/66 mmHg. She was treated with oxygen therapy and antibiotics (piperacillin-tazobactam) assuming that she had pneumonia. Intravenous hydration was also increased (1L/24 h) after 500 cc in 30 min in the emergency room according to the heart rate. A complete blood test revealed slight hyperkalemia (5.1 mmol/L), blood cultures were sent to the laboratory. Symptoms decreased quickly the next day and she had 3 days without any radiotherapy. We decided to stop dexamethasone (Fig. 3), assuming she had an infectious process, and to continue with the antibiotics. The blood cultures were still ongoing.

She returned to radiotherapy three days later, and again experienced respiratory distress one hour after the treatment: heart rate 112, temperature 40.1 °C. A complete blood test revealed the following elements: hyperkalemia 5.5 mmol/L, hypocalcemia 2 mmol/L, hyperphosphatemia 2.21 mmol/L, creatinine 128 μmol/L versus 70 μmol/L before radiotherapy, uric acid 305 μmol/L versus 132 μmol/L (Fig. 3). We decided to increase hydration (2L/24 h). She recovered in twelve hours with a standard rate of creatinine and ionics. We decided to continue with lenalidomide and bortezomib and restart dexamethasone as the blood cultures remained sterile. The antibiotics were suspended and the radiotherapy was stopped.

The biological settings were consistent with grade 3 tumor lysis syndrome [2] with laboratory and clinical criteria [4]. We associated



**Fig. 2.** Coronal representation of the dose distribution to the lesion of the forearm. Isodose 100% represented in yellow. (For interpretation of the references to colour in this figure legend, the reader is referred to the web version of this article.)

Timeline	D4	D5	D6	D7	D8	D9	D10	D11	D12	
<b>Radiotherapy</b>	→ 5Gy (D6), 5Gy (D10)									
<b>Systemic treatment</b>										
Bortezomib	x				x			x		
Lenalidomide	x	x	x	x	x	x	x	x	x	
Dexamethasone	x	x						x	x	
<b>Supportive care</b>										
Hydration			500cc in 30 min.	1L/24h	→				2L/24h	STOP
Antibiotics			1L/24h Piperacillin-Tazobactam	→				STOP		
Oxygen therapy			Gentamicin 6L/min	STOP 2L/min	STOP					
Oxygen saturation	97%		<u>After RT: 89%</u>		95%		95%	95%		
Temperature (°C)	37		<u>After RT: 39.5</u>		36.7		<u>Before RT: 36.7</u>	36.5		
Respiratory rate	12		<u>After RT: 28</u>				<u>After RT: 36</u>			
<b>Biological settings</b>			<u>After RT:</u>				<u>After RT:</u>			
Creatinine*	70		63		87		128		63	
Kalemia <sup>∧</sup>	3.4		5.1		4,4		5.5		4.3	
Calcemia <sup>∧</sup>	2.5		2.2		2,3		2		2.22	
Phosphoremia <sup>∧</sup>	0,66		1.83				2.21		0.99	
Uric acid*	132		229				305		143	
LDH (UI/L)			515				542		293	
Blood culture			Sterile		Sterile		Sterile			
CRP (mg/L)	12		61		202		181		28.9	
Monoclonal peak (g/L)	31		31						31	

**Fig. 3.** Timeline of events before, during and after radiotherapy. The timeline starts on Day 4 after initiation of a treatment with lenalidomide 25 mg/day 1–14 *per os*; bortezomib 1.3 mg/m2 subcutaneous injection days 1,4,8,11/dexamethasone 20 mg/day 1–2,4–5,8–9, 11–12 *per os*. Data from day 1 to day 3 are not shown because no side effects occurred. In red: clinical and biological abnormalities after the first and the second fraction of radiation therapy. After the first fraction: tachycardia, acute respiratory distress with fever and hypoxia (CRS). After the second fraction: tachycardia, tachypnea, fever (CRS) and biological TLS with acute renal failure. \*: µmol/L <sup>∧</sup>: mmol/L. (For interpretation of the references to colour in this figure legend, the reader is referred to the web version of this article.)

respiratory distress with a cytokine release syndrome, grade 2 after the first radiotherapy fraction, grade 1 after the second fraction. [2,5]

**Discussion**

The physiopathology of TLS is well known but remains a deadly complication: tumor cell destruction leads to the release of intracellular content which overloads renal excretion. This is why it occurs in hematology malignancies because of chemosensitivity. In the same way, radiotherapy treatment leads to DNA damage which results in cellular lysis. And all of that in a large radiation field can explain the possibility of tumor lysis syndrome after radiotherapy.

Yet, in the literature, radiotherapy is rarely identified as a triggering factor, only in 3% of TLS cases [6], all pathologies combined. It becomes even more unusual when we associate radiotherapy, TLS and myeloma : only two cases in the literature to our knowledge (Table 1).

An expert consensus published guidelines to identify patients and treatments at risk [7,8]. Radiotherapy and multiple myeloma are classified as low risk [7]. This means that no prophylaxis is needed.

However, certain other risk factors, such as hyperuricemia, bulky disease, advanced lactate dehydrogenase (LDH) disease and unfavorable cytogenetics should be added. Our patient presented several of these risks: LDH > 500 UI/L and a bulky disease (Fig. 1), meaning that prevention with hydration and rasburicase should have been discussed.

Here, the patient had already received dexamethasone, lenalidomide and bortezomib injections, all described in the literature as TLS triggers in hematology malignancies [9–12]. However, the timeline underlines an obvious link between the radiotherapy and TLS as the symptoms appeared twice, each time only a few hours after the radiotherapy treatment. In the literature, the number of radiotherapy treatments before the onset of TLS is variable (Table 1): it seems that the syndrome appears either prematurely, in line with the commonly observed post-chemotherapy delay [4], or late, after the last radiotherapy treatment [8,13–16]. More, it seems more frequent with hypofractionated radiotherapy. Another argument supporting our theory is that there was no recurrence of the problem once the radiotherapy had been completed while the patient was still on lenalidomide, bortezomib and dexamethasone. Furthermore, the metabolic volume value (determined with a standardized uptake value threshold of 2.5) of the right forearm soft tissue lesion, corresponding to the PTV was 460 cc, which is very large and unusual in classic MM related bone lesions (Figs. 1 and 2). This is consistent, as TLS is most common in large mass tumors with systemic treatment.

Here, the reaction appeared quickly, with acute respiratory distress, so we were able to react rapidly and avoid renal failure, or even a fatal outcome as commonly seen [14,17]. The symptoms may potentially come from cytokine release syndrome. Some studies suggest that the systemic effects of radiotherapy are associated with the immune system

**Table 1**  
TLS and radiotherapy, a review of the literature.

Tumor type	Age	Radiotherapy site & dose	Delay	TLS Outcome	Year	Systemic treatment	Refs.
Prostate cancer and Chronic Lymphocytic Leukemia	69y	Bone30 Gy/10F	7th fraction	Resolved	2016	BicalutamideGoserelinDexamethasone	[24]
Diffuse large B cell lymphoma	Not reported	Not reported	3rd fraction	Death	2004	Not reported	[25]
Chronic myeloid leukemia	74y	Splenic0.5 Gy/day	3rd fraction	Resolved	2005	HydroxyureaAllopurinol	[26]
Non-Hodgkin's Lymphoma	72y	Splenic0.5 Gy/10F	2 days after the end	Death	1999	No	[14]
Non-Small-Cell Lung cancer	52y	Chest30 Gy/10F	2nd fraction	Death	2008	No	[17]
Breast cancer	73y	Hemi body irradiation8.5 Gy 1 fraction	8.5 Gy	Death	2000	100 mg Hydrocortisone500 mL Hydration	[27]
Chronic myeloid leukemia	38y	Splenic irradiation5 fractions	3 days after the last fraction	Resolved	1990	No	[15]
Metastatic medulloblastoma	34y	Abdominopelvic mass0.1 Gy/day (Cobalt 60)	After 3 days (3 Gy)	Resolved and then restarted RT and chemotherapy	1984	Vincristine 2 mg IV/10 daysDexamethasone 1,5 mg/day	[23]
Neuroblastoma	2 weeks	Hepatic5 Gy/5F	Dose not reported	Resolved(hydration and allopurinol were given in anticipation)	1994	VincristineTenoposide	[28]
Neuroblastoma	3 months	Hepatic5 Gy/5F	Dose not reported	Resolved	1994	No	[28]
Neuroblastoma	2 days	Hepatic5 Gy/5F	Dose not reported	Resolved	1994	VincristineTenoposide	[28]
Prostate cancer	60y	Bone30 Gy/10F	6th day of RT	Death	2012	Docetaxel (75 mg/m2)Estramustine	[29]
Bronchogenic carcinoma	Not reported	Dose not reported	3 days after the last fraction	Resolved	2017	No	[8]
Metastatic Melanoma	65y	Pelvis and left shoulder25 Gy/5F	2 days after the last fraction	Death	2014	No	[16]
Myeloma	79y	5th ribDose not reported	The day after the last fraction	Death	2020	LenalidomideDexamethasone	[13]
Plasmacytoma	77y	CervicalDose not reported	1 week after the last fraction	Death	2020	No	[13]

[18]. Radiation therapy activates the immune system (DAMPs and cytokines production) and affects the immune tumoral microenvironment [19]. Radiotherapy-induced release of pro-inflammatory factors could initiate the immune response, which could be a way to enhance the efficacy of CAR T Cells in treating solid tumors [20,21]. However, since the first case of CRS after radiotherapy was described [3], with no TLS and proved by laboratory studies (cytokine measurements), we can believe that the CRS symptoms described in our case may also be the result of a systemic immune effect of the radiation[22].

There are well-established guidelines for treating and supporting patients with CRS; it depends on the grade of CRS and the use of different agents, such as corticosteroids, anti-interleukins (tocilizumab) and supportive care [5]. We can see in Fig. 3 that no dexamethasone was delivered on the day of the radiotherapy treatment, which could have prevented the CRS.

Finally, better knowledge of TLS and CRS associated with RT would avoid having to interrupt the treatment. Here, discontinuing the radiotherapy led to ineffective analgesia and decreased quality of life for the patient. It is interesting to note that some authors restarted the radiotherapy treatment once the TLS had been resolved, with some precautions, such as continued allopurinol, phosphate binder, and hydration [23]. These authors believe that both preventive measures and a progressive reduction in tumor load prevented the lysis syndrome. In the same way, we should discuss to continue radiotherapy with corticosteroids prophylaxis when CRS occurs.

## Conclusion

The findings in our report show that CRS and TLS are possibilities in a patient with multiple myeloma treated with local radiotherapy. It is important to consider this as an alternative diagnosis for patients with multiple dysfunctions and many symptoms. Our findings also emphasize the systemic effects of radiotherapy, with systemic symptoms such as associated cytokine release syndrome. For the future we need further description of this side effect because prevention is the main treatment, and it is crucial for a successful treatment.

No statistical analysis was performed.

## Declaration of Competing Interest

The authors declare that they have no known competing financial interests or personal relationships that could have appeared to influence the work reported in this paper.

## References

- [1] Zhao W-H, Liu J, Wang B-Y, Chen Y-X, Cao X-M, Yang Y, et al. A phase I, open-label study of LCAr-B38M, a chimeric antigen receptor T cell therapy directed against B cell maturation antigen, in patients with relapsed or refractory multiple myeloma. *J Hematol Oncol* 2018;11(1). <https://doi.org/10.1186/s13045-018-0681-6>.
- [2] National Cancer Institute Common Terminology Criteria for Adverse Events v5.0 NCI, Nov 27, 2017 NIH publication.

- [3] Barker CA, Kim SK, Budhu S, Matsoukas K, Daniyan AF, D'Angelo SP. Cytokine release syndrome after radiation therapy: case report and review of the literature. *J ImmunoTher Cancer* 2018 Dec;6(1):1.
- [4] Cairo MS, Bishop M. Tumour lysis syndrome: new therapeutic strategies and classification: New Therapeutic Strategies and Classification of TLS. *Br J Haematol* 2004 Oct;127(1):3–11.
- [5] Yakoub-Agha I, Moreau A-S, Ahmad I, Borel C, Hadhoum N, Masouridi-Levrat S, et al. Management of cytokine release syndrome in adult and pediatric patients undergoing CAR-T cell therapy for hematological malignancies: Recommendation of the French Society of Bone Marrow and cellular Therapy (SFGM-TC). *Bull Cancer (Paris)* 2019 Jan;106(1):S102–9.
- [6] Firwana BM, Hasan R, Hasan N, Alahdab F, Alnahhas I, Hasan S, et al. Tumor Lysis Syndrome: A Systematic Review of Case Series and Case Reports. *Postgrad Med* 2012;124(2):92–101.
- [7] Cairo MS, Coiffier B, Reiter A, Younes A, on behalf of the TLS Expert Panel. Recommendations for the evaluation of risk and prophylaxis of tumour lysis syndrome (TLS) in adults and children with malignant diseases: an expert TLS panel consensus: TLS Risk Classification in Adults/Children with Malignancies. *Br J Haematol* 2010 Mar 16;149(4):578–86.
- [8] Stuart S, Auten J. A rare seizure: Tumor lysis syndrome after radiation therapy of a solid tumor. *Am J Emerg Med* 2017 Jun;35(6):941.e3-941.e4.
- [9] Moutouh-de Parseval LA, Weiss L, DeLap RJ, Knight RD, Zeldis JB. Tumor Lysis Syndrome/Tumor Flare Reaction in Lenalidomide-Treated Chronic Lymphocytic Leukemia. *J Clin Oncol* 2007;25(31):5047.
- [10] Suzuki K, Terui Y, Nishimura N, Ueda K, Mishima Y, Sakajiri S, et al. Rapid Progression of Anemia Related to Tumor-lysis Syndrome Associated with Bortezomib Treatment in Myeloma Patients. *Jpn J Clin Oncol* 2014 May;44(5):435–41.
- [11] Singh A, Gupta S, Yim B, Thekkekkara R. Tumor Lysis Syndrome in Multiple Myeloma: An Increasingly Recognized Risk—A Report of Seven Cases. *Indian J Hematol Blood Transfus* 2017;33(1):41–4.
- [12] Malik IA, Abubakar S, Alam F, Khan A. Dexamethasone-Induced Tumor Lysis Syndrome in High-Grade Non-Hodgkin's Lymphoma: *South Med J* 1994 Mar;87(3):409–11.
- [13] Yavorkovsky LL, Jing W, Baker R. An upsurge of the serum free light chains as a possible missing link in tumour lysis syndrome in multiple myeloma. *Br J Haematol* 2020;188(5):732–5.
- [14] Schifter T, Cohen A, Lewinski UH. Severe tumor lysis syndrome following splenic irradiation. *Am J Hematol* 1999;60(1):75–6.
- [15] Malik IA, Vellozo P, Khurshid M, Khan A. Radiation induced tumour lysis syndrome in a patient with leukaemia. *JPMA J Pak Med Assoc* 1992 Aug;42(8):191–3.
- [16] Dar L, Gendelman O, Amital H. Tumor lysis syndrome presenting in a patient with metastatic melanoma treated with radiation therapy. *Isr Med Assoc J IMAJ* 2014 Jul;16(7):456–7.
- [17] Noh GY, Choe DH, Kim CH, Lee JC. Fatal Tumor Lysis Syndrome During Radiotherapy for Non-Small-Cell Lung Cancer. *J Clin Oncol* 2008;26(36):6005–6.
- [18] Formenti SC, Demaria S. Systemic effects of local radiotherapy. *Lancet Oncol* 2009;10(7):718–26.
- [19] Zhang C, Liang Z, Ma S, Liu X. Radiotherapy and Cytokine Storm: Risk and Mechanism. *Front Oncol* 2021 May;20(11):670464.
- [20] Hauth F, Ho AY, Ferrone S, Duda DG. Radiotherapy to Enhance Chimeric Antigen Receptor T-Cell Therapeutic Efficacy in Solid Tumors: A Narrative Review. *JAMA Oncol* 2021;7(7):1051. <https://doi.org/10.1001/jamaoncol.2021.0168>.
- [21] Olive PL, Vikse CM, Vanderbyl S. Increase in the fraction of necrotic, not apoptotic, cells in SiHa xenograft tumours shortly after irradiation. *Radiother Oncol* 1999;50(1):113–9.
- [22] Lee DW, Gardner R, Porter DL, Louis CU, Ahmed N, Jensen M, et al. Current concepts in the diagnosis and management of cytokine release syndrome. *Blood*. 2014 Jul 10;124(2):188–95.
- [23] Tomlinson GC, Solberg LA. Acute tumor lysis syndrome with metastatic medulloblastoma. A case report *Cancer* 1984;53(8):1783–5.
- [24] Alkan A, Küttük T, Karcı E, Yaşar A, Hiçsönmez A, Utkan G. Radiation-Induced Tumor Lysis Syndrome in Chronic Lymphocytic Leukemia. *Turk J Hematol* 2016;33(3):248–50.
- [25] Yamazaki H, Hanada M, Horiki M, Kuyama J, Sato T, Nishikubo M, et al. Acute tumor lysis syndrome caused by palliative radiotherapy in patients with diffuse large B-cell lymphoma. *Radiat Med* 2004 Feb;22(1):52–5.
- [26] Chen S-W, Hwang W-S, Tsao C-J, Liu H-S, Huang G-C. Hydroxyurea and splenic irradiation-induced tumour lysis syndrome: a case report and review of the literature. *J Clin Pharm Ther* 2005;30(6):623–5.
- [27] Rostom AY, El-Hussainy G, Kandil A, Allam A. Tumor lysis syndrome following hemi-body irradiation for metastatic breast cancer. *Ann Oncol Off J Eur Soc Med Oncol*. 2000;11(10):1349–52.
- [28] Hain RDW, Rayner L, Weitzman S, Lorenzana A. Acute tumour lysis syndrome complicating treatment of stage IVS neuroblastoma in infants under six months old. *Med Pediatr Oncol* 1994;23(2):136–9.
- [29] Kaplan MA, Kucukoner M, Alpagat G, Isikdogan A. Tumor lysis syndrome during radiotherapy for prostate cancer with bone and bone marrow metastases without visceral metastasis. *Ann Saudi Med* 2012;32(3):306–8.