



HAL
open science

Morphological MRI investigations of the hypothalamus in 232 individuals with Parkinson's disease

Martin Gorges, Barbara Kuntz, Kelly del Tredici, Daniel Schmidt, Hans-Peter Müller, Albert Ludolph, Luc Dupuis, Jan Kassubek

► **To cite this version:**

Martin Gorges, Barbara Kuntz, Kelly del Tredici, Daniel Schmidt, Hans-Peter Müller, et al.. Morphological MRI investigations of the hypothalamus in 232 individuals with Parkinson's disease. *Movement Disorders*, 2019, 34 (10), pp.1566-1570. 10.1002/mds.27814 . inserm-03376294

HAL Id: inserm-03376294

<https://inserm.hal.science/inserm-03376294v1>

Submitted on 13 Oct 2021

HAL is a multi-disciplinary open access archive for the deposit and dissemination of scientific research documents, whether they are published or not. The documents may come from teaching and research institutions in France or abroad, or from public or private research centers.

L'archive ouverte pluridisciplinaire **HAL**, est destinée au dépôt et à la diffusion de documents scientifiques de niveau recherche, publiés ou non, émanant des établissements d'enseignement et de recherche français ou étrangers, des laboratoires publics ou privés.

to have an active role in the termination of synaptic dopamine signals and also in the release of dopamine.¹⁴ Thus, DAT imaging could reflect synaptic dopamine levels or DAT expression, a hypothesis which should be investigated in detail in future imaging studies.

To conclude, there appears to be no correlation between striatal DAT binding and the number of post-mortem striatal axons or nigral neurons. The precise mechanism of changes in DAT binding signal in PD remains to be elucidated, but the amount of synaptic dopamine may have a key role. These results do not support the use of DAT imaging as a surrogate marker for striatal axonal loss. ■

Acknowledgments: The staff of the Department of Pathology and the Department of Nuclear Medicine at Turku University Hospital is gratefully acknowledged. We confirm that we have read the journal's position on issues involved in ethical publication and affirm that this work is consistent with those guidelines.

References

1. Tagliaferro P, Burke RE. Retrograde axonal degeneration in Parkinson disease. *J Parkinsons Dis* 2016;6:1-15.
2. Kordower JH, Olanow CW, Dodiya HB, et al. Disease duration and the integrity of the nigrostriatal system in Parkinson's disease. *Brain* 2013;136(Pt 8):2419-2431.
3. Fazio P, Svenningsson P, Cselényi Z, Halldin C, Farde L, Varrone A. Nigrostriatal dopamine transporter availability in early Parkinson's disease. *Mov Disord* 2018;33:592-599.
4. Saari L, Kivinen K, Gardberg M, Joutsa J, Noponen T, Kaasinen V. Dopamine transporter imaging does not predict the number of nigral neurons in Parkinson disease. *Neurology* 2017;88:1461-1467.
5. Jankovic J. Parkinson's disease tremors and serotonin. *Brain* 2018; 141:624-626.
6. Joutsa J, Gardberg M, Röyttä M, Kaasinen V. Diagnostic accuracy of parkinsonism syndromes by general neurologists. *Parkinsonism Relat Disord* 2014;20:840-844.
7. Dickson DW, Braak H, Duda JE, et al. Neuropathological assessment of Parkinson's disease: refining the diagnostic criteria. *Lancet Neurol* 2009;8:1150-1157.
8. Kraemmer J, Kovacs GG, Perju-Dumbrava L, Pirker S, Traub-Weidinger T, Pirker W. Correlation of striatal dopamine transporter imaging with post mortem substantia nigra cell counts. *Mov Disord* 2014;29:1767-1773.
9. Kaasinen V, Vahlberg T. Striatal dopamine in Parkinson disease: a meta-analysis of imaging studies. *Ann Neurol* 2017;82:873-882.
10. Tian L, Karimi M, Brown CA, Loftin SK, Perlmutter JS. In vivo measures of nigrostriatal neuronal response to unilateral MPTP treatment. *Brain Res* 2014;1571:49-60.
11. Shimony JS, Rutlin J, Karimi M, et al. Validation of diffusion tensor imaging measures of nigrostriatal neurons in macaques. *PLoS One* 2018;13:e0202201.
12. Blesa J, Pifl C, Sánchez-González MA, et al. The nigrostriatal system in the presymptomatic and symptomatic stages in the MPTP monkey model: a PET, histological and biochemical study. *Neurobiol Dis* 2012;48:79-91.
13. Karimi M, Tian L, Brown CA, et al. Validation of nigrostriatal positron emission tomography measures: critical limits. *Ann Neurol* 2013;73:390-396.
14. Levil V. Dopamine release mediated by the dopamine transporter, facts and consequences. *J Neurochem* 2011;118:475-489.

Morphological MRI Investigations of the Hypothalamus in 232 Individuals With Parkinson's Disease

Martin Gorges, PhD,¹ Barbara Kuntz, MS,¹ Kelly Del Tredici, MD, PhD,¹ Daniel G. Schmidt, MSc,¹ Hans-Peter Müller, PhD,¹ Albert C. Ludolph, MD,¹ Luc Dupuis, PhD,² and Jan Kassubek, MD^{1*}

¹Department of Neurology, University of Ulm, Ulm, Germany

²Université de Strasbourg, Inserm, UMR-S1118, Strasbourg, France

ABSTRACT: Background: The pathophysiology of the hypothalamic involvement in Parkinson's disease (PD) is not well understood. The objective of this study was the quantification of hypothalamic volumes in vivo in PD.

Methods: High-resolution T₁-weighted magnetic resonance imaging (MRI) data from 232 individuals with PD and 130 healthy non-PD individuals were used for quantification of the hypothalamic volumes.

Results: The hypothalamus in PD was not atrophied, as indicated by volumetric analyses in the prospectively collected subcohort (30 PD, $V = 921 \pm 78 \text{ mm}^3$ vs 30 non-PD, $V = 917 \pm 67 \text{ mm}^3$; $P = 0.850$) and validated in a large cohort (202 PD, $V = 925 \pm 88 \text{ mm}^3$ vs 100 non-PD, $V = 932 \pm 114 \text{ mm}^3$; $P = 0.602$).

Conclusions: Hypothalamic involvement in PD as shown by a large body of histopathological evidence does not appear to be detectable by MRI-based volumetric quantification. © 2019 The Authors. *Movement Disorders* published by Wiley Periodicals, Inc. on behalf of International Parkinson and Movement Disorder Society.

Key Words: hypothalamus; MR imaging; Parkinson's disease neuropathological stages; volumetry

This is an open access article under the terms of the Creative Commons Attribution-NonCommercial-NoDerivs License, which permits use and distribution in any medium, provided the original work is properly cited, the use is non-commercial and no modifications or adaptations are made.

*Correspondence to: Prof. Jan Kassubek, MD, Department of Neurology, University of Ulm, Oberer Eselsberg 45, 89081 Ulm, Germany; E-mail: jan.kassubek@uni-ulm.de

Relevant conflicts of interest/financial disclosures: None.

Funding agencies: Deutsche Gesellschaft für Parkinson und Bewegungsstörungen e.V. (German Society for Parkinson's Disease and Movement Disorders).

Received: 18 April 2019; **Revised:** 12 July 2019; **Accepted:** 14 July 2019

Published online 21 August 2019 in Wiley Online Library (wileyonlinelibrary.com). DOI: 10.1002/mds.27814

The hypothalamus plays a pivotal integrative role in a broad spectrum of body functions, including energy metabolism^{1,2} and circadian control.³ Pathological changes in the hypothalamus in Parkinson's disease (PD) were noted decades ago, including early observations by Fritz Jakob Lewy⁴ and the work by Braak and colleagues, who reported that the PD-associated pathology targets the hypothalamic tuberomammillary and ventromedial nuclei in an early symptomatic phase.^{5,6} In addition, the importance of a dopaminergic contribution to a broad spectrum of nonmotor symptoms is supported by dopamine dysfunction in the hypothalamus in PD.⁷

Breen and colleagues recently reported hypothalamic volume loss in a small PD cohort.⁸ Other neurodegenerative diseases, such as amyotrophic lateral sclerosis (ALS) or frontotemporal dementia (FTD), are also known to be associated with metabolic changes⁹ in correlation with severe atrophy of the hypothalamus^{10,11} These findings suggest that identification of pathways leading to perturbed energy balance might provide novel therapeutic targets.¹² We tested the hypothesis of whether hypothalamic involvement in PD could be shown by volumetric hypothalamus mapping using a well-established manual segmentation procedure based on high-resolution MRI. A MRI-based quantitative analysis of the hypothalamic volume was performed in >200 individuals with PD compared with matched healthy non-PD individuals.

Materials and Methods

Study Population

The study population was organized into a prospective and a retrospective cohort, including a total of

362 participants including non-PD individuals. All 232 individuals with PD were idiopathic (sporadic) PD cases without any known PD-associated gene mutations. Details on the inclusion and exclusion criteria for both PD cohorts are provided in the Supplementary Material.

Prospective cohort

The study was approved by the Ethical Committee of the University of Ulm, Ulm, Germany (reference 159/17), and all participants provided written informed consent. All individuals with PD underwent standardized clinical-neurological examinations and were diagnosed according to the UK Parkinson's Disease Society Brain Bank clinical diagnostic criteria.¹³ All measurements were performed in the ON state. All non-PD individuals (n = 30) were well-matched healthy elderly volunteers without a history of neurological or psychiatric disease or other medical conditions. Participants' demographics and clinical data are summarized in Table 1. Imaging data were acquired on a 3 Tesla MRI scanner (Prisma Siemens Medical, Erlangen, Germany) using a high-resolution 3-D T₁-weighted magnetization-prepared gradient echo image (MPRAGE) sequence. Whole-brain coverage comprised 192 sagittal slices, no gap, 1.0 × 1.0 × 1.0 mm³ voxels, 240 × 192 × 256 matrix, TE, 2.05 milliseconds; TR, 2300 milliseconds; flip angle, 9°.

Retrospective cohort

All participants provided written informed consent as above (reference 88/11). Hypothalamus volumes from a large representative PD cohort (n = 202, 68 ± 11 years, 6.7 ± 6.3 years of disease duration; UPDRS III score, 24 ± 13) and matched non-PD individuals (n = 100,

TABLE 1. Demographic and clinical data

Variable	Individuals with PD (n = 30)	Healthy non-PD individuals (n = 30)	P
Age (years)	62.7 ± 12.0 (36.2–81.6)	60.2 ± 13.0 (36.1–79.5)	0.43 ^a
Sex (male:female)	22:8	17:13	0.28 ^b
Disease duration (years)	7.9 ± 3.8 (1.4–17.8)	na	na
PD phenotype			
Tremor dominant	10 (33.3%)		
Akinetic-rigid	7 (23.3%)	na	na
Gait disturbance	1 (3.3%)		
Mixed	12 (40.0%)		
UPDRS III	16.7 ± 4.6 (10.0–30.0)	na	na
MoCA ^d	24.9 ± 4.9 (6.0–30.0)	27.2 ± 2.2 (21.0–30.0)	0.030 ^c
ESS ^e	7.8 ± 4.5 (3.0–20.0)	5.7 ± 3.0 (1.0–13.0)	0.122 ^c
BMI ^f (kg/m ²)	28.2 ± 4.0 (21.6–39.0)	26.6 ± 3.7 (21.8–35.5)	0.100 ^a
Eucation (years)	13.0 ± 2.3 (8.0–16.0)	14.6 ± 2.9 (9.0–20.0)	0.052 ^c

Values are given as mean ± standard deviation (min-max).

^at tests (2-sample, unpaired, unequal variances).

^bFisher's exact test.

^cMann-Whitney U test.

^dMontreal Cognitive Assessment.¹⁹

^eEpworth Sleepiness Scale.¹⁶

^fBody mass index.

na, not applicable.

64 ± 9 years) were retrospectively analyzed using the identical segmentation procedure and volumetric analysis pipeline (see Imaging Methods). Imaging data were acquired at a 1.5 Tesla clinical MRI scanner (Symphony, Siemens Medical, Erlangen, Germany) using an MPRAGE sequence (144 sagittal slices, no gap, 1.0 × 1.2 × 1.0 mm³ voxels, 256 × 192 × 256 matrix, TE, 4.2 milliseconds; TR, 1600 milliseconds).

MR-Based Hypothalamus Segmentation

Coronal slices were used for manual delineation of the hypothalamus using a well-established landmark-based procedure¹¹ (Supplementary Fig. 1), which is implemented in the *Tensor* Imaging and Fiber Tracking (TIFT) software package.¹⁴ Prior to hypothalamus delineation, the following steps were performed: (1) rigid brain normalization, (2) spatial up-sampling into a study-specific grid (in-plane resolution of 62.5 × 62.5 μm², slice thickness of 0.5 mm) to improve the accuracy in identifying landmarks and hypothalamic borders, and (3) manual delineation of the left and right hemispheric hypothalamus. In particular, rigid body normalization was performed along the anterior commissure (AC) – posterior commissure (PC) axis

such that the coronal cutting plane was perpendicular to the AC–PC axis.

The hypothalamus was manually delineated, as described previously¹¹ and shown in the Supplementary Figure. The optical tract was excluded from all slices (Supplementary Fig. 1b–i). Prior to the analysis, all data sets were randomized such that the raters were blinded to all demographic and clinical features. This delineation procedure is robust and achieves a high level of reproducibility, as indicated by an intra- and interrater reliability analysis in a subsample of 12 × 3 = 36 randomized data sets. The coefficient of variation (CV) was CV < 4% for 2 raters; the intraclass correlation coefficient between the 2 raters was $r > 0.9$; both can be safely accepted as robust and highly reproducible.

Volumetric Analysis

Intracranial volume as an important covariate for volumetric analyses was determined with the Freesurfer image analysis suite (V.6.0.0; <http://surfer.nmr.mgh.harvard.edu/>). Given the distinct structural connectivity and histopathologically confirmed involvement of the hypothalamus,⁶ we performed anterior-posterior

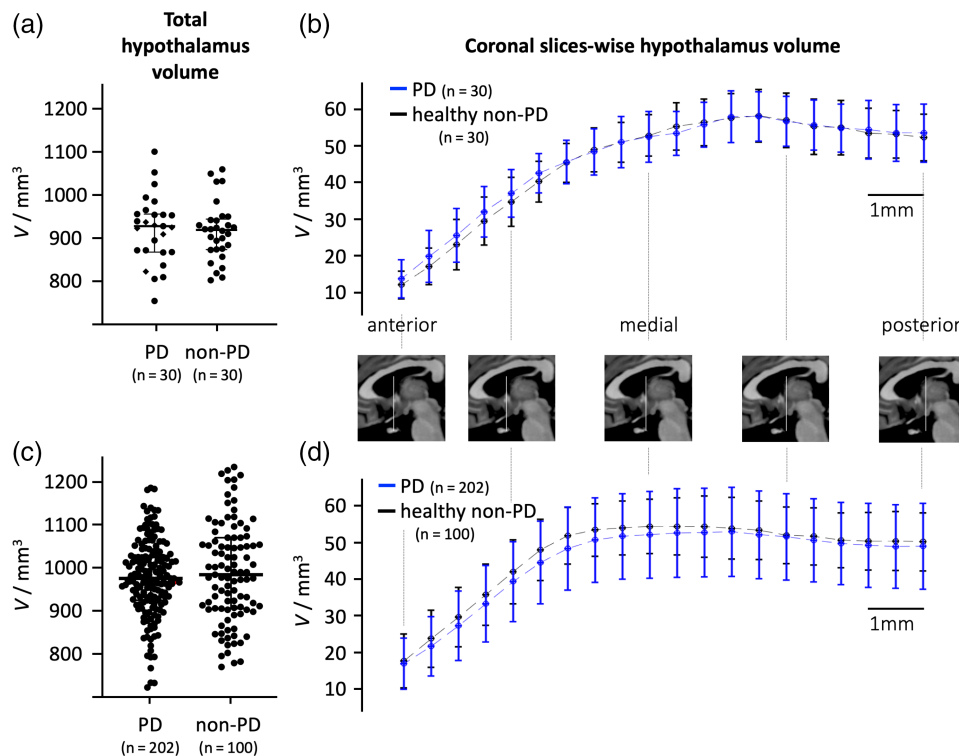


FIG. 1. Volumetric analysis of the hypothalamus in Parkinson's disease (PD). (a) Volumes of the hypothalamus did not differ between PD and non-PD individuals. (b) Slice volumetric analysis provided as mean ± SD of 20 coronal section spanning from the most anterior to the most posterior part of the hypothalamus indicated that the volumes of the coronal slices did not differ between PD (blue error bars) and non-PD individuals (black); t test $P > 0.05$. (c, d) Retrospective volumetric analysis from a large cohort of PD and non-PD individuals revealed similar results indicating no significant differences in hypothalamic volumes for (c) the total hypothalamus and (d) at the single coronal slice level. [Color figure can be viewed at wileyonlinelibrary.com]

segmentation using a technique that was adapted from reference 10 with a refined normalization technique that provides normalization to 20 coronal slices for each data set. All reported volumes were corrected for sex, intracranial volume, and age in a linear regression model¹⁵ as in our previous study.¹¹ The MATLAB-based “Statistical Toolbox” (The Mathworks Inc., Natick, MA) was used for statistical data analysis. Parametric unpaired 2-sample *t* tests for unequal variances were used to test for statistical differences between groups, as indicated by Lilliefors tests for normality. All correlations were studied using Spearman rank order correlation coefficient. All statistical tests were 2-sided, and $P < 0.05$ was considered significant.

Results

Clinical Features

Clinical features are summarized in Table 1. Age, sex, education duration, daytime sleepiness (Epworth Sleepiness Scale¹⁶), and body mass index^{17,18} were not significantly different between PD and non-PD individuals. Individuals with PD displayed worse cognitive performance (Montreal Cognitive Assessment,¹⁹ Mann-Whitney *U* test $z = -2.16$, $P = 0.030$) compared with non-PD individuals.

Morphometric Analyses of the Hypothalamus

The total hypothalamus volumes in the prospective cohort were normally distributed (Lilliefors test $P = 0.10$), and the distribution largely overlapped within the same volume range for both groups (Fig. 1a); the volumes for PD ($n = 30$, $V = 921 \pm 78 \text{ mm}^3$) and healthy non-PD individuals ($n = 30$, $V = 917 \pm 67 \text{ mm}^3$) did not differ ($t = 0.19$, $P = 0.850$). There were also no differences for anterior (t test $t = 1.05$, $P = 0.300$) and posterior ($t = -0.61$, $P = 0.543$) hypothalamic volumes, respectively, between PD and non-PD individuals. The coronal slice-wise hypothalamic volumetric comparison between PD and non-PD individuals indicated no significant effects (Fig. 1b). There were no significant correlations between the hypothalamus volume and either the Montreal Cognitive Assessment score ($r = -0.18$, $P = 0.360$), years of education ($r = 0.14$, $P = 0.500$), disease duration ($r = 0.13$, $P = 0.505$), Epworth Sleepiness Scale ($r = -0.14$, $P = 0.501$), or UPDRS III motor score ($r = 0.03$, $P = 0.903$).

To confirm the volumetric findings, a large cohort of PD and healthy non-PD individuals was retrospectively analyzed for volumetric differences of the hypothalamus. The total hypothalamus volumes were normally well distributed (Lilliefors test $P \geq 0.5$), largely overlapping between groups and did not differ ($t = -0.52$, $P = 0.602$) for PD ($n = 202$, $V = 925 \pm 88 \text{ mm}^3$, volume range, 671–1153 mm^3) and non-PD individuals ($n = 100$, $V = 932 \pm 114 \text{ mm}^3$, 699–1194 mm^3). Coronal slice-wise volumetric comparisons also did not reveal any significant volume difference at the single

hypothalamic slice level, so that these results were in full accordance with the prospective study cohort.

Discussion

Using in vivo MRI, there was no statistical difference in hypothalamus size between PD and non-PD individuals for 2 separate cohorts. The involvement of the hypothalamus was demonstrated in PD several decades ago, including evidence from postmortem studies. First, a subset of hypothalamic neurons become selectively targeted during disease,^{4,20,21} with the tuberomammillary nucleus becoming affected in an early stage of the symptomatic phase,^{5,6} whereas other neuronal populations remain spared.²²⁻²⁴ Second, a number of hypothalamic-dependent functions, such as sleep and circadian rhythmicity, are severely affected by disease progression.^{3,25,26} This hypothalamic involvement could be secondary to dopaminergic^{7,27,28} or serotonergic²⁹ and related to involvement of the autonomic nervous system.³⁰

In the current study, despite these repeatedly observed features of hypothalamic involvement by others, we were unable to observe gross atrophy of the hypothalamus. This contrasts with a previous effort by Breen and colleagues,⁸ who reported volumetric loss in the hypothalamus. However, our study included more than 230 patients, compared with 12 patients in that study,⁸ and we used a different well-established segmentation method for the hypothalamus that overcomes the main challenge of defining its lateral boundaries.

Importantly, when we applied the identical method of hypothalamic volumetry to ALS, we observed a significant hypothalamic atrophy, even in presymptomatic gene carriers, in a large sample of patients¹¹ similar to what has been documented in FTD patients,^{10,12} Thus, our method is sufficiently sensitive to detect differences in volume when present. We think that this differential involvement of the hypothalamus between ALS and FTD, on the one hand, and PD, on the other, could reflect different mechanisms at work between these different neurodegenerative diseases selectively targeting this brain region. Alternatively, the gradually progressive nature of PD might not result in global hypothalamic atrophy while, at the same time, affecting only discrete sets of neurons and their connectivities.³⁰ These results suggest hypothalamus volumetry as a possibly specific biomarker for the ALS-FTD spectrum in contrast to PD.

This study was limited by the lack of postmortem validation of hypothalamic involvement and of the diagnoses. The individuals with PD were all medicated because untreated PD patients might otherwise have experienced difficulties leading to discomfort-induced motion artifacts during MRI scans. In addition, different imaging protocols were used for 2 different cohorts, which might be regarded as a confounding factor when

comparing cross-cohort volumetric data. As a further limitation, it has to be noted that only one specific imaging method was used, and the data analyses did not include other potentially more sensitive approaches such as shape analysis. Future (and ideally, autopsy-controlled) studies should examine the microstructure of the hypothalamus *in vivo*, for example, by diffusion-weighted imaging, and in so doing also address connectome-based analyses of the structural and functional networks of the hypothalamus in PD.

In conclusion, involvement of the hypothalamus in PD as histopathologically evidenced does not appear to be detectable *in vivo* by using MRI-based volumetric quantification. The results further suggested that the macrostructure of the hypothalamus remains stable throughout the course of PD, and this raises the question of whether the involvement of the hypothalamus might be identifiable *in vivo* by investigating its microstructure by diffusion-weighted imaging techniques. Heterogeneity in neurodegenerative diseases with potentially different propagation schemes suggests that the link between involvement at the cellular level and the morphometry of the hypothalamus may depend on the specific underlying neurodegenerative process. ■

Acknowledgments: The authors acknowledge Sonja Fuchs for MRI data acquisition and Ralph Kühne for administrative assistance.

References

- Berthoud H-R, Morrison C. The brain, appetite, and obesity. *Annu Rev Psychol* 2008;59:55–92.
- Dupuis L, Pradat PF, Ludolph AC, Loeffler J-P. Energy metabolism in amyotrophic lateral sclerosis. *Lancet Neurol* 2011;10:75–82.
- Videnovic A, Willis GL. Circadian system — a novel diagnostic and therapeutic target in Parkinson's disease? *Mov Disord* 2016;31:260–269.
- Langston JW, Forno LS. The hypothalamus in Parkinson disease. *Ann Neurol* 1978;3:129–133.
- Braak H, Del Tredici K, Rüb U, de Vos RAI, Jansen Steur ENH, Braak E. Staging of brain pathology related to sporadic Parkinson's disease. *Neurobiol Aging* 2003;24:197–211.
- Braak H, Del Tredici K. Neuroanatomy and pathology of sporadic Parkinson's disease. *Adv Anat Embryol Cell Biol* 2009;201:1–119.
- Chaudhuri KR, Odin P, Antonini A, Martinez-Martin P. Parkinson's disease: the non-motor issues. *Parkinsonism Relat Disord* 2011;17:717–723.
- Breen DP, Nombela C, Vuono R, et al. Hypothalamic volume loss is associated with reduced melatonin output in Parkinson's disease. *Mov Disord* 2016;31:1062–1066.
- Vercruyse P, Vieau D, Blum D, et al. Hypothalamic Alterations in Neurodegenerative Diseases and Their Relation to Abnormal Energy Metabolism. *Front Mol Neurosci* 2018;11:2.
- Piguet O, Petersén A, Yin Ka Lam B, et al. Eating and hypothalamus changes in behavioral-variant frontotemporal dementia. *Ann Neurol* 2011;69:312–319.
- Gorges M, Vercruyse P, Müller H-P, et al. Hypothalamic atrophy is related to body mass index and age at onset in amyotrophic lateral sclerosis. *J Neurol Neurosurg Psychiatry* 2017;88:1033–1041.
- Ahmed RM, Ke YD, Vucic S, et al. Physiological changes in neurodegeneration - mechanistic insights and clinical utility. *Nat Rev Neurol* 2018;14:259–271.
- Hughes AJ, Daniel SE, Kilford L, Lees AJ. Accuracy of clinical diagnosis of idiopathic Parkinson's disease: a clinico-pathological study of 100 cases. *J Neurol Neurosurg Psychiatry* 1992;55:181–184.
- Müller HP, Unrath A, Ludolph AC, Kassubek J. Preservation of diffusion tensor properties during spatial normalization by use of tensor imaging and fibre tracking on a normal brain database. *Phys Med Biol* 2007;52:N99–N109.
- Nordenskjöld R, Malmberg F, Larsson E-M, et al. Intracranial volume normalization methods: considerations when investigating gender differences in regional brain volume. *Psychiatry Res* 2015;231:227–235.
- Nasreddine ZS, Phillips NA, Bédirian V, et al. The Montreal Cognitive Assessment, MoCA: a brief screening tool for mild cognitive impairment. *J Am Geriatr Soc* 2005;53:695–699.
- Politis M, Loane C, Wu K, Brooks DJ, Piccini P. Serotonergic mediated body mass index changes in Parkinson's disease. *Neurobiol Dis*. 2011;43:609–615.
- van der Marck MA, Dicke HC, Uc EY, et al. Body mass index in Parkinson's disease: a meta-analysis. *Parkinsonism Relat Disord*. 2012;18:263–267.
- Johns MW. A new method for measuring daytime sleepiness: the Epworth sleepiness scale. *Sleep* 1991;14:540–545.
- Kremer HP, Bots GT. Lewy bodies in the lateral hypothalamus: do they imply neuronal loss? *Mov Disord* 1993;8:315–320.
- Purba JS, Hofman MA, Portegies P, et al. Decreased number of oxytocin neurons in the paraventricular nucleus of the human hypothalamus in AIDS. *Brain* 1993;116:795–809.
- Javoy-Agid F, Ruberg M, Pique L, et al. Biochemistry of the hypothalamus in Parkinson's disease. *Neurology* 1984;34:672–675.
- Matzuk MM, Saper CB. Preservation of hypothalamic dopaminergic neurons in Parkinson's disease. *Ann Neurol* 1985;18:552–555.
- Pique L, Jegou S, Bertagna X, et al. Pro-opiomelanocortin peptides in the human hypothalamus: comparative study between normal subjects and Parkinson patients. *Neurosci Lett* 1985;54:141–146.
- Chahine LM, Amara AW, Videnovic A. A systematic review of the literature on disorders of sleep and wakefulness in Parkinson's disease from 2005 to 2015. *Sleep Med Rev* 2017;35:33–50.
- St Louis EK, Boeve BF. REM Sleep Behavior Disorder: Diagnosis, Clinical Implications, and Future Directions. *Mayo Clin Proc* 2017;92:1723–1736.
- Politis M, Pavese N, Tai YF, et al. Hypothalamic involvement in Huntington's disease: an *in vivo* PET study. *Brain* 2008;131:2860–2869.
- Pagano G, Molloy S, Bain PG, et al. Sleep problems and hypothalamic dopamine D3 receptor availability in Parkinson disease. *Neurology* 2016;87:2451–2456.
- Joling M, Vriend C, Raijmakers PGHM, et al. Striatal DAT and extrastriatal SERT binding in early-stage Parkinson's disease and dementia with Lewy bodies, compared with healthy controls: An 123I-FP-CIT SPECT study. *Neuroimage Clin* 2019;22:101755.
- Dayan E, Sklerov M, Browner N. Disrupted hypothalamic functional connectivity in patients with PD and autonomic dysfunction. *Neurology* 2018;90:e2051–e2058.

Supporting Data

Additional Supporting Information may be found in the online version of this article at the publisher's web-site.