



HAL
open science

Recrudescence of a high parasitaemia, severe *Plasmodium falciparum* malaria episode, treated by artesunate monotherapy

S. Landre, A. L. Bienvenu, P. Miaillhes, P. Abraham, M. Simon, A. Becker, A. Conrad, G. Bonnot, Y. I. Kouakou, C. Chidiac, et al.

► To cite this version:

S. Landre, A. L. Bienvenu, P. Miaillhes, P. Abraham, M. Simon, et al.. Recrudescence of a high parasitaemia, severe *Plasmodium falciparum* malaria episode, treated by artesunate monotherapy. *International Journal of Infectious Diseases*, 2021, 105, pp.345-348. 10.1016/j.ijid.2021.02.080 . inserm-03337970

HAL Id: inserm-03337970

<https://inserm.hal.science/inserm-03337970>

Submitted on 8 Sep 2021

HAL is a multi-disciplinary open access archive for the deposit and dissemination of scientific research documents, whether they are published or not. The documents may come from teaching and research institutions in France or abroad, or from public or private research centers.

L'archive ouverte pluridisciplinaire **HAL**, est destinée au dépôt et à la diffusion de documents scientifiques de niveau recherche, publiés ou non, émanant des établissements d'enseignement et de recherche français ou étrangers, des laboratoires publics ou privés.



Case Report

Recrudescence of a high parasitaemia, severe *Plasmodium falciparum* malaria episode, treated by artesunate monotherapy

Sophie Landre^a, Anne-Lise Bienvenu^b, Patrick Miaillhes^a, Paul Abraham^c, Marie Simon^d, Agathe Becker^a, Anne Conrad^a, Guillaume Bonnot^e, Yobouet Ines Kouakou^{e,f}, Christian Chidiac^a, Gilles Leboucher^b, Thomas Rimmelé^c, Laurent Argaud^d, Stephane Picot^{e,f,*}

^a Service des Maladies Infectieuses et Tropicales, Hôpital de la Croix-Rousse, Hospices Civils de Lyon, 69004 Lyon, France

^b Service Pharmacie, Groupement Hospitalier Nord, Hospices Civils de Lyon, 69004 Lyon, France

^c Anesthesiology and Critical Care Medicine, Hôpital Edouard Herriot, Hospices Civils de Lyon, Lyon, France

^d Service de Médecine Intensive-Réanimation, Hôpital Edouard Herriot, Hospices Civils de Lyon, 69437 Lyon Cedex 03, France

^e Univ Lyon, Malaria Research Unit, UMR 5246 CNRS-INSA-CPE-University Lyon1, 69100 Villeurbanne, France

^f Institute of Parasitology and Medical Mycology, Hôpital de la Croix-Rousse, Hospices Civils de Lyon, 69004 Lyon, France

ARTICLE INFO

Article history:

Received 3 February 2021

Received in revised form 18 February 2021

Accepted 19 February 2021

Keywords:

Severe malaria

Artesunate

Resistance

K13

Parasite clearance time

ABSTRACT

A patient presenting with severe malaria, with hyperparasitaemia, received 7-day artesunate monotherapy. A severe recrudescence was detected and attributed to hyperparasitaemia, monotherapy and a polyclonal infection without *Kelch 13* gene mutation. A second treatment with artesunate, then quinine, followed by artemether-lumefantrine, was successful.

© 2021 The Authors. Published by Elsevier Ltd on behalf of International Society for Infectious Diseases. This is an open access article under the CC BY-NC-ND license (<http://creativecommons.org/licenses/by-nc-nd/4.0/>).

Introduction

Artesunate is the recommended initial treatment for severe malaria, followed by 3 days of artemisinin-based combination therapy (ACT) (World Health Organization, 2015). Artesunate monotherapy may lead to recrudescence of parasitemia in 40%–50% of cases within 28 days (Wellems et al., 2020). This recrudescence is related to parasite persistence due to induced dormancy and should be distinguished from drug resistance.

Decreased artesunate efficacy was described in South East Asia (Imwong et al., 2017). The combination of polymorphisms on the *Kelch 13* (K13) gene (Ariey et al., 2014) and pharmacology of artesunate (Kouakou et al., 2019) is involved in therapeutic failure. We report a severe malaria case wrongly treated with artesunate

monotherapy, followed by a recrudescence leading to a second severe malaria episode.

Case report

A 65-year-old man returned to France from Chad, where he had stayed for 2 years without malaria prophylaxis. A week later, he was admitted to hospital. He presented with altered febrile consciousness, mottled knees with hemodynamic instability, and acute respiratory distress syndrome (ARDS), requiring invasive mechanical ventilation and admission to an intensive care unit (ICU). He had a medical history of type 2 diabetes, hypertension and obesity (BMI = 36.8 kg/m²). Biological parameters showed a hyperlactatemia (lactate = 4 mmol/L), metabolic compensated acidosis (bicarbonates = 17 mmol/L; pH = 7.47), and acute kidney injury (creatininemia = 180 μmol/L). Platelet count was 20 g/L, hemoglobin 16.1 g/dL, and proteins 5.4 g/dL. Microscopy was positive for *Plasmodium falciparum* (675 000 parasites/μL), confirming a severe malaria episode with respiratory failure

* Corresponding author at: Malaria Research Unit, UMR 5246 CNRS-INSA-CPE-University Lyon1, F-69100 Villeurbanne, France.

E-mail address: stephane.picot@univ-lyon1.fr (S. Picot).

($\text{PaO}_2/\text{FiO}_2 < 150$ mmHg), cardiovascular failure, acute kidney injury and hyper-parasitaemia.

Artesunate intravenous (IV) regimen (2.4 mg/kg) was initiated on day one and continued for 7 days. Continuous venovenous hemodialysis (CVVHD) was performed for the first 72 h, and norepinephrine support was required for 10 days. The patient was discharged from the ICU 4 weeks after admission with a favorable outcome. Shortly afterwards, he presented with hyperthermia, cough, and a pulmonary opacity at the chest X-ray. Because of a swallowing disorder, aspiration pneumonia was suspected, and a cefotaxime metronidazole bi-therapy was initiated. However, he remained febrile and experienced ARDS requiring his readmission to the ICU. He presented hemolysis (hemoglobin = 6.4 g/dL, undetectable haptoglobin, elevated LDH), low platelets (63 G/L), and a lactatemia of 2.5 mmol/L, without kidney dysfunction. Blood smears were positive for *P. falciparum* (240 000 parasites/ μL), leading to a diagnosis of severe malaria recrudescence. Artesunate 2.4 mg/kg was initiated for 3 doses (H0, H12, H24) followed by

5 days of IV quinine (750 mg/8 h) to avoid the hemolytic process caused by artesunate. An oral ACT (artemether-lumefantrine) was then given for 3 days (Figure 1A).

Methods

The malaria diagnosis was confirmed through examination of 100 microscopic fields of 200 red blood cells for thin smears (Giemsa stains) following the requirements of the National Certification Program. The parasite clearance half-life ($\text{PC}_{1/2}$) was determined using $T_{1/2} = \log_e(2)/K$. The Worldwide Antimalarial Resistance Network (WWARN) Parasite Clearance Estimator (PCE) was not used because the 6-hourly blood sampling required was not standard clinical practice. However, the $\text{PC}_{1/2}$ at admission and recrudescence was calculated from 4 and 3 samples, respectively. Molecular tests were performed from fresh blood samples (Ponce et al., 2017). Real-time polymerase chain reaction tests and direct sequencing of the *Pfmsp1*, *Pfmsp2* and *kelch13* genes were conducted from frozen samples.

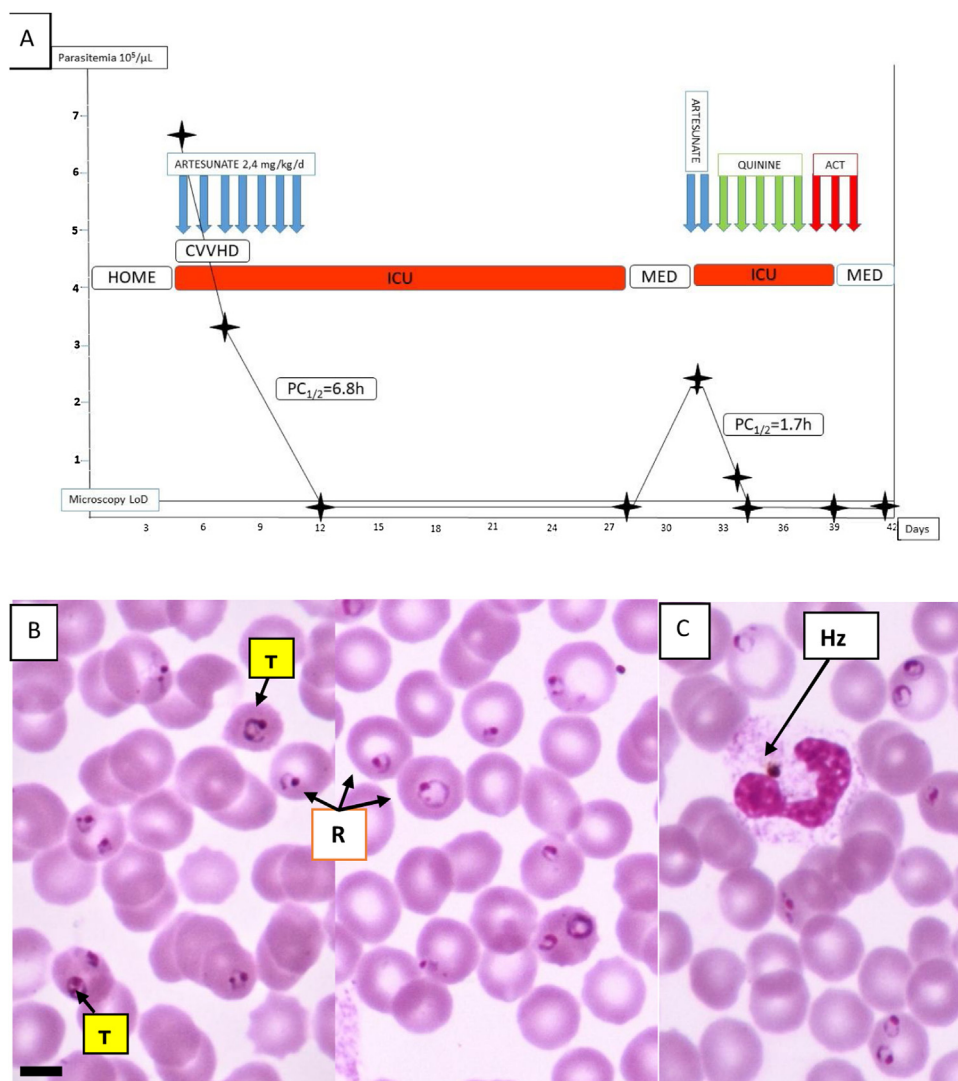


Figure 1. A: Timeline of the 2 malaria episodes with parasitemia (parasites/ μL), antimalarial treatments and hospitalization wards. B: Giemsa stained thin blood film from the blood sample at admission showing *Plasmodium falciparum* (R: Ring stage parasite; T: Trophozoites). Magnification: $\times 1000$. Scale bar = 5 μM . C: One of the 5% neutrophils with engulfed hemozoin pigment.

Results

The patient showed a high parasitemia on initial admission with approximately 90% of ring stages and 10% of developing trophozoites (Figure 1B). Five percent of leucocytes with phagocytosed hemozoin pigment were detected (Figure 1C). After 24 h, and despite artesunate treatment, the parasitic burden remained high (320 000 parasites/ μ L). Parasitemia was 5000 parasites/ μ L 48 h later and negative until Day 28. The estimated $PC_{1/2}$ was 6.8 h, higher than the threshold of 5.5 h for drug sensitivity (Ashley et al., 2014).

The recrudescence was detected on Day 32. Three doses of artesunate led to a decrease in parasitemia at Day 33 and negative from Day 34 to 57 after a switch to IV quinine (to prevent the risk of post-artesunate delayed haemolysis) followed by 3 days of artemether-lumefantrine. The estimated parasite clearance time of the second episode was 1.7 h.

Genotyping of samples collected at admission (Day 5), Day 7 and Day 32 for *Pfmsp1* (Supplementary Figure S1) revealed the presence of 2 clones of *P. falciparum*: one disappeared after the first treatment while the second was responsible for the recrudescence. No polymorphism was detected for the 3 samples in the *K13* gene (Supplementary Figure S2).

Discussion

This patient presented a recrudescence of a severe malaria episode. For the first episode, he received a 7-day therapy of intravenous artesunate with 3 doses (300 mg for 126 kg body weight) given at 12-h intervals, then once a day for 6 days. He did not receive the oral follow-on treatment with an ACT needed to avoid recurrences.

This non-immune patient with high parasitaemia at admission received a prolonged artesunate treatment (7 days) which should have covered 3 parasite life cycles. It is known that patients with hyperparasitaemia have an increased risk of recrudescence (Luxemburger et al., 1995). The need for frequent microscopical measures of blood parasitaemia during the treatment of malaria with high parasite burden should be underscored.

Artemisinin resistance was described (Ashley et al., 2014; Dondorp et al., 2009), manifested in an increase in $PC_{1/2}$ (>5.5 h). There was a delayed estimate of $PC_{1/2}$ during the first episode of severe malaria, but this value should be considered with caution because the WWARN PCE was not used. The *K13* genes of *P. falciparum* identified from the initial and recrudescence episodes were wild-type, eliminating a drug-resistant Plasmodium.

The patient may have been infected by at least 2 clones of *P. falciparum*. It can be suspected that part of the parasite population was cured by artesunate monotherapy, while another part slowly decreased to subpatent levels and survived, despite the 7-day artesunate treatment. There is strong evidence that a 3-day oral ACT, following the initial artesunate regimen, could have prevented the severe recurrence. Practitioners should be aware of the recrudescence risk of severe or non-severe malaria with hyperparasitaemia (Luxemburger et al., 1995).

Why was the recurrence also a severe malaria case? The patient received artesunate treatment according to the summary of product characteristics (SPC). The patient's weight may not have impacted the distribution volume since artesunate is hydrophilic and mainly distributed in lean tissue. According to the artesunate SPC, dose adjustment for renal impairment was unnecessary despite dihydroartemisinin (DHA) metabolites excretion in the urine. The impact of CVVHD on artesunate excretion in the urine was not evaluated, but an increase in artesunate excretion may have occurred. Artesunate is highly bound to proteins, and hypoproteinemia may increase the amount of drug removed by

renal replacement therapy. Unfortunately, the artesunate/DHA dosage used was not available. Age, obesity, hypertension and diabetes probably also contributed to the successive episodes of severe malaria. A retrospective study in adults found that obesity was associated with severe malaria, independently and in association with other metabolic risk factors, such as hypertension, dyslipidemia and diabetes (Wyss et al., 2017). Multiple *P. falciparum* genotype infection has also previously been associated with malaria severity (Nicastrì et al., 2008).

It is of utmost importance to use the recommended 3-day oral ACT after artesunate intravenous treatment (even a 7-day treatment) and perform therapeutic drug monitoring, ensuring optimal drug exposure and avoiding clinical failure. Frequent, repeated microscopic examination of blood smears is needed for early detection of recrudescence, particularly in cases of high parasitaemia. Antimalarial stewardship actions (Bienvenu et al., 2019) could help to promote these good clinical practices.

Authors contribution

All authors contributed equally in Study design, Data collection, Data analysis and Writing.

Ethical approval

Informed consent was obtained from the patient at admission.

Funding source

None.

Conflict of interest

The authors declare no conflict of interest.

Acknowledgments

Not applicable.

Appendix A. Supplementary data

Supplementary material related to this article can be found, in the online version, at doi:<https://doi.org/10.1016/j.ijid.2021.02.080>.

References

- Ariey F, Witkowski B, Amaratunga C, Beghain J, Langlois A-C, Khim N, et al. A molecular marker of artemisinin-resistant *Plasmodium falciparum* malaria. *Nature* 2014;505:50–5, doi:<http://dx.doi.org/10.1038/nature12876>.
- Ashley EA, Dhorda M, Fairhurst RM, Amaratunga C, Lim P, Suon S, et al. Spread of artemisinin resistance in *Plasmodium falciparum* malaria. *N Engl J Med* 2014;371:411–23, doi:<http://dx.doi.org/10.1056/NEJMoa1314981>.
- Bienvenu A-L, Djimdé A, Picot S. Antimalarial stewardship programs are urgently needed for malaria elimination: a perspective. *Parasite* 2019;26:16, doi:<http://dx.doi.org/10.1051/parasite/2019016>.
- Dondorp AM, Nosten F, Yi P, Das D, Phyto AP, Tarning J, et al. Artemisinin resistance in *Plasmodium falciparum* malaria. *N Engl J Med* 2009;361:455–67, doi:<http://dx.doi.org/10.1056/NEJMoa0808859>.
- Imwong M, Suwannasin K, Kunasol C, Sutawong K, Mayxay M, Rekol H, et al. The spread of artemisinin-resistant *Plasmodium falciparum* in the Greater Mekong subregion: a molecular epidemiology observational study. *Lancet Infect Dis* 2017;17:491–7, doi:[http://dx.doi.org/10.1016/S1473-3099\(17\)30048-8](http://dx.doi.org/10.1016/S1473-3099(17)30048-8).
- Kouakou YI, Tod M, Leboucher G, Lavoignat A, Bonnot G, Bienvenu A-L, et al. Systematic review of artesunate pharmacokinetics: implication for treatment of resistant malaria. *Int J Infect Dis* 2019;89:30–44, doi:<http://dx.doi.org/10.1016/j.ijid.2019.08.030>.
- Luxemburger C, Nosten F, Raimond SD, Chongsuphajaisiddhi T, White NJ. Oral artesunate in the treatment of uncomplicated hyperparasitemic falciparum

- malaria. *Am J Trop Med Hyg* 1995;53:522–5, doi:<http://dx.doi.org/10.4269/ajtmh.1995.53.522>.
- Nicastri E, Paglia MG, Severini C, Ghirga P, Bevilacqua N, Narciso P. *Plasmodium falciparum* multiple infections, disease severity and host characteristics in malaria affected travellers returning from Africa. *Travel Med Infect Dis* 2008;6:205–9, doi:<http://dx.doi.org/10.1016/j.tmaid.2008.01.001>.
- Ponce C, Kaczorowski F, Perpoint T, Mialhes P, Sigal A, Javouhey E, et al. Diagnostic accuracy of loop-mediated isothermal amplification (LAMP) for screening patients with imported malaria in a non-endemic setting. *Parasite* 2017;24:53, doi:<http://dx.doi.org/10.1051/parasite/2017054>.
- Wellems TE, Sá JM, Su X-Z, Connolly SV, Ellis AC. “Artemisinin Resistance”: Something new or old? Something of a misnomer?. *Trends Parasitol* 2020;36:735–44, doi:<http://dx.doi.org/10.1016/j.pt.2020.05.013>.
- World Health Organization. Guidelines for the treatment of malaria. 3rd ed. World Health Organization; 2015.
- Wyss K, Wängdahl A, Vesterlund M, Hammar U, Dashti S, Naucler P, et al. Obesity and diabetes as risk factors for severe *Plasmodium falciparum* malaria: results from a Swedish nationwide study. *Clin Infect Dis* 2017;65:949–58, doi:<http://dx.doi.org/10.1093/cid/cix437>.