



# Sevoflurane Sedation with AnaConDa-S Device for a Child Undergoing Extracorporeal Membrane Oxygenation

Yohan Soreze, Jean-Eudes Piloquet, Alain Amblard, Isabelle Constant,  
Jerome Rambaud, Pierre-Louis Léger

## ► To cite this version:

Yohan Soreze, Jean-Eudes Piloquet, Alain Amblard, Isabelle Constant, Jerome Rambaud, et al.. Sevoflurane Sedation with AnaConDa-S Device for a Child Undergoing Extracorporeal Membrane Oxygenation. Indian Journal of Critical Care Medicine, 2020, 24 (7), pp.596 - 598. 10.5005/jp-journals-10071-23487 . inserm-03285234

**HAL Id: inserm-03285234**

**<https://inserm.hal.science/inserm-03285234>**

Submitted on 13 Jul 2021

**HAL** is a multi-disciplinary open access archive for the deposit and dissemination of scientific research documents, whether they are published or not. The documents may come from teaching and research institutions in France or abroad, or from public or private research centers.

L'archive ouverte pluridisciplinaire **HAL**, est destinée au dépôt et à la diffusion de documents scientifiques de niveau recherche, publiés ou non, émanant des établissements d'enseignement et de recherche français ou étrangers, des laboratoires publics ou privés.

See discussions, stats, and author profiles for this publication at: <https://www.researchgate.net/publication/344395354>

# Sevoflurane Sedation with AnaConDa-S Device for a Child Undergoing Extracorporeal Membrane Oxygenation

Article in Indian Journal of Critical Care Medicine · July 2020

DOI: 10.5005/jp-journals-10071-23487

CITATIONS

0

READS

25

6 authors, including:



**Yohan Soreze**

Hôpital Armand-Trousseau (Hôpitaux Universitaires Est Parisien)

11 PUBLICATIONS 53 CITATIONS

[SEE PROFILE](#)



**Alain Amblard**

Hôpital Armand-Trousseau (Hôpitaux Universitaires Est Parisien)

7 PUBLICATIONS 33 CITATIONS

[SEE PROFILE](#)



**Jérôme Rambaud**

Hôpital Armand-Trousseau (Hôpitaux Universitaires Est Parisien)

52 PUBLICATIONS 364 CITATIONS

[SEE PROFILE](#)



**Leger Pierre Louis**

Hôpital Armand-Trousseau (Hôpitaux Universitaires Est Parisien)

20 PUBLICATIONS 127 CITATIONS

[SEE PROFILE](#)

Some of the authors of this publication are also working on these related projects:



UMAC néonatale et pédiatrique Armand-Trousseau [View project](#)



Total liquid ventilation and ultra-fast hypothermia [View project](#)

# Sevoflurane Sedation with AnaConDa-S Device for a Child Undergoing Extracorporeal Membrane Oxygenation

Yohan Soreze<sup>1</sup>, Jean-Eudes Piloquet<sup>2</sup>, Alain Amblard<sup>3</sup>, Isabelle Constant<sup>4</sup>, Jérôme Rambaud<sup>5</sup>, Pierre-Louis Leger<sup>6</sup>

## ABSTRACT

**Background:** Deep sedation in critically ill children undergoing extracorporeal membrane oxygenation (ECMO) can be challenging. Volatile anesthetics like sevoflurane can be a good alternative for patients hospitalized in pediatric intensive care units, in whom adequate sedation is difficult to obtain.

**Case description:** We report here the first pediatric case of a patient under extracorporeal membrane oxygenation receiving sedation by sevoflurane using the AnaConDa-S device. This 2-year-old girl, suffering from congenital diaphragmatic hernia, was put on extracorporeal membrane oxygenation due to a persistent pulmonary hypertension following metapneumovirus infection. Despite high doses of drugs, neither satisfactory sedation nor analgesia could be reached. Sevoflurane allowed her to be released and we were able to wean her from certain drugs. Her physiological parameters and the indicators of pain and sedation improved.

**Conclusion:** Anesthesia using sevoflurane with the AnaConDa-S device is efficient for children under ECMO.

**Clinical significance:** This is the first pediatric report on anesthesia with sevoflurane under ECMO.

**Keywords:** Anesthesia, Extracorporeal membrane oxygenation, Halogenous gas, Sevoflurane.

*Indian Journal of Critical Care Medicine* (2020); 10.5005/jp-journals-10071-23487

Dear Sir,

Critically ill children and neonates undergoing extracorporeal membrane oxygenation (ECMO) often require deep sedation. Intravenous sedative drugs are largely used in this population, but side effects can be an issue. Volatile anesthetics can be used to provide adequate sedation without the main side effects of intravenous drugs. Volatile anesthetics have a low solubility and a reduced accumulation in tissues. They appear to be good candidates for deep sedation in patients undergoing ECMO. Nonetheless, only a few case reports are available in children and neonates.<sup>1</sup>

## CASE DESCRIPTION

We report the case of a 2-year-old patient, with a medical history of congenital diaphragmatic hernia complicated by bronchopulmonary dysplasia and persistent pulmonary hypertension requiring home oxygen therapy and oral sildenafil. When she was 2½ years old, she presented a severe pneumonia secondary to a *Metapneumovirus* infection and developed acute respiratory distress syndrome (ARDS) with worsening of her pulmonary hypertension and respiratory condition. Despite protective mechanical ventilation, pulmonary vasoactive therapy (inhaled and infused), profound analgesia, and neuromuscular blocker treatment, she developed a refractory cardiogenic shock and required to be put on ECMO. During her stay in our unit, we faced issues with her sedation and analgesia management. She was under high doses of opioids (morphine), benzodiazepines (midazolam), ketamine, and α2-agonist (dexmedetomidine). We also tried unusual therapy such as continuous infusion and bolus of propofol and phenobarbital. Despite optimal use of all these drugs, we could not reach a satisfactory relief of pain and discomfort according to the comfort B scale and vital parameters. Therefore, we chose the option to sedate her with anesthetic gas. Both parents were informed of this unusual treatment and they agreed. This oral consent was noticed in the medical record. In order to do this, we

<sup>1-3</sup>Pediatric Intensive Care Unit, Armand-Trousseau Hospital, Assistance Publique-Hôpitaux de Paris, Paris, Ile de France, France

<sup>4</sup>Pediatric Anesthesiology Department, Armand-Trousseau Hospital, Assistance Publique-Hôpitaux de Paris, Paris, Ile de France, France; Sorbonne University, Paris, France

<sup>5,6</sup>Pediatric Intensive Care Unit, Armand-Trousseau Hospital, Assistance Publique-Hôpitaux de Paris, Paris, Ile de France, France; Sorbonne University, Paris, France; INSERM U955-PHYDES-IMRB, Ecole Vétérinaire de Maisons-Alfort (ENVA), France

**Corresponding Author:** Jérôme Rambaud, Pediatric Intensive Care Unit, Armand-Trousseau Hospital, Assistance Publique-Hôpitaux de Paris, Paris, Ile de France, France; Sorbonne University, Paris, France; INSERM U955-PHYDES-IMRB, Ecole Vétérinaire de Maisons-Alfort (ENVA), France, Phone: +33-33-0171738527, e-mail: jerome.rambaud@aphp.fr

**How to cite this article:** Soreze Y, Piloquet J-E, Amblard A, Constan I, Rambaud J, Leger P-L. Sevoflurane Sedation with AnaConDa-S Device for a Child Undergoing Extracorporeal Membrane Oxygenation. *Indian J Crit Care Med* 2020;24(7):596–598.

**Source of support:** Nil

**Conflict of interest:** None

administered inhaled sevoflurane using the AnaConDa-S device (Sedana Medical, Paris, France) (Fig. 1). Sevoflurane infusion was administered between 6 and 20 mL/hour to obtain a sevoflurane concentration ranged from 0.4 to 0.8%. The AnaConDa-S device was inserted on the inspiratory circuit of an Evita XL mechanical ventilator (Dräger, Germany) to avoid the increase of the dead space (50 mL) due to the volume of the device. The expired gas was evacuated in a dedicated absorbent as shown and a continuous monitoring of expired fraction of sevoflurane was performed using the Vamos plus monitor from Dräger, Germany.

After initiating sevoflurane, her vital constants significantly improved. The mean heart rate decreased from 155 bpm to

135 bpm and the mean blood pressure from 80 mm Hg to 65 mm Hg. Bispectral index (BIS) values were significantly lower ( $p < 0.0001$ ) after initiating sevoflurane (Fig. 2). We were able to wean her from ketamine, dexmedetomidine, and pentothal. While on sevoflurane, the amount of sedation she was receiving was reassessed every 6 hours, and we decreased them if she had a satisfactory comfort scale evaluation (11–17 points). This attitude was kept until the end of her stay in our unit (Table 1, Fig. 3).

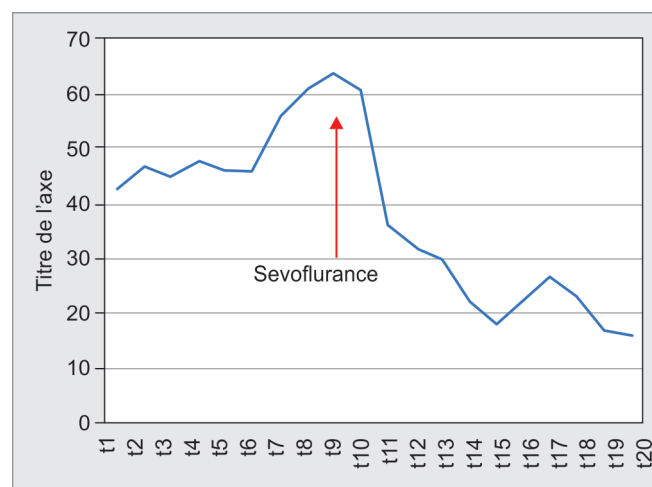
The ECMO blood flow and sweep gas flow were not modified by the adjunction of this treatment. We did not modify her previous apneic ventilation settings (peak pressure of 24 cm H<sub>2</sub>O, positive end expiratory pressure of 10 cm H<sub>2</sub>O, and respiratory rate of 20 cycles per minute). Echocardiography remains unchanged and no new organ dysfunction was identified after sevoflurane initiation. Measurements were obtained directly from the expiratory circuit. There was no air contamination in the patient's room according to the measurements we performed.

Due to the severity of her condition and the absence of improvement, the decision of limitation of her life-sustaining treatments was taken by the medical staff. She died after 2 months in our unit.

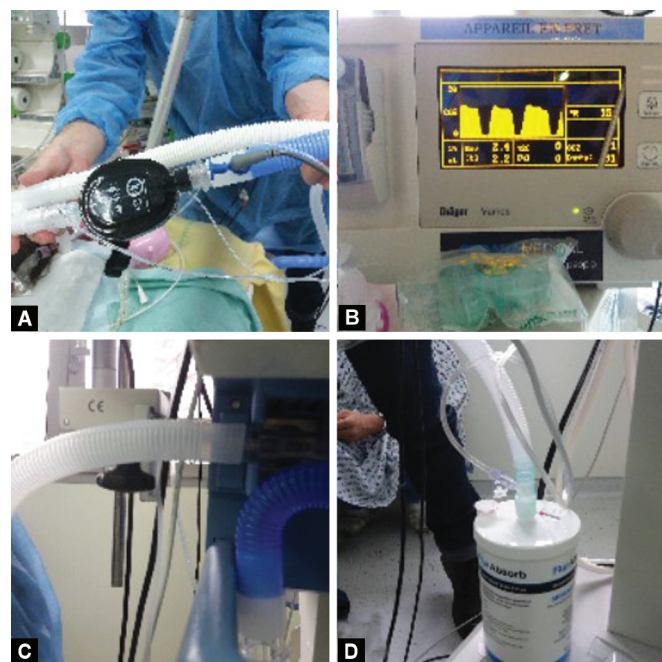
We described here the first pediatric patient under venoarterial ECMO sedated by sevoflurane with the AnaConDa-S device. Meiser

et al.<sup>2</sup> described a case series of six adult patients undergoing ECMO but so far, to our knowledge, no sedation by the sevoflurane AnaConDa-S device was reported in a pediatric patient under ECMO.

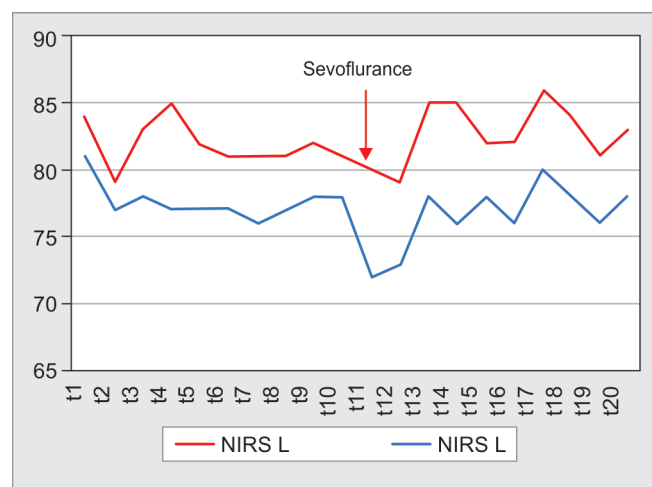
Those last years, concerns about neurotoxicity of volatile anesthetics were reported.<sup>3</sup> However, these concerns from



**Fig. 2:** Evolution of BIS monitoring before and during sevoflurane. Ten values of BIS monitoring were randomly collected before and after sevoflurane initiation. Statistics analysis has been done by *t* test analysis. Sevoflurane was initiated between t10 and t11



**Figs 1A to D:** AnaConDa-S® device set-up. (A) AnaConDa-S device placed on the expiratory circuit; (B) Monitoring of the exhaled gas; (C and D) Evacuation of the exhaled gas



**Fig. 3:** Evolution of NIRS monitoring before and during sevoflurane. NIRS monitoring was performed on the left and the right side of the forehead. Ten values were randomly collected before and after sevoflurane initiation. Statistics analysis has been done by *t* test analysis. Sevoflurane was initiated between t10 and t11

**Table 1:** Doses of sedation before and after introduction of inhaled sevoflurane

	24 hours before Sevo	12 hours after Sevo	24 hours after Sevo	36 hours after Sevo	48 hours after Sevo	60 hours after Sevo	72 hours after Sevo
Midaz µg/kg/hours	400	200	100	100	100	60	60
Morph mg/kg/day	20	10	10	10	10	10	0
Keta mg/kg/hours	3.75	0	0	0	0	0	0
Sufl µg/kg/hours	7	6	4	4	4	3	3
Pentol mg/kg/hours	4	0	0	0	0	0	0
Dexme µg/kg/hours	1.4	0	0	0	0	0	0

experimental studies must be balanced with beneficial interest of these agents.<sup>4</sup> Anyway, special attention must be given to repeated or prolonged administration.<sup>5</sup>

In our opinion, the use of inhaled isoflurane or sevoflurane, with a dedicated mechanical ventilator and a tight monitoring of the expired fraction, should be considered in case of an uncomfortable patient despite high doses of sedative drugs.

## REFERENCES

1. Sackey PV, Martling C-R, Radell PJ. Three cases of PICU sedation with isoflurane delivered by the "AnaConDa". *Paediatr Anaesth* 2005;15(10):879–885.
2. Meiser A, Bomberg H, Lepper PM, Trudzinski FC, Volk T, Groesdonk HV. Inhaled sedation in patients with acute respiratory distress syndrome undergoing extracorporeal membrane oxygenation. *Anesth Analg* 2017;125(4):1235–1239.
3. Jevtovic-Todorovic V. General anesthetics and neurotoxicity: How much do we know? *Anesthesiol Clin* 2016;34(3):439–451.
4. Murphy KL, McGaughy J, Croxson PL, Baxter MG. Exposure to sevoflurane anesthesia during development does not impair aspects of attention during adulthood in rats. *Neurotoxicol Teratol* 2017;60:87–94.
5. Jiang J, Tang C, Ren J, Zhang C, Dong L, Zhu Z. Effect of multiple neonatal sevoflurane exposures on hippocampal apolipoprotein E levels and learning and memory abilities. *Pediatr Neonatol* 2018;59(2):154–160.