



HAL
open science

Left ventricular assist device percutaneous deactivation with a Watchman device

T. Aoun, G. Baudry, G. Rioufol, J. F. Obadia, M. Pozzi

► **To cite this version:**

T. Aoun, G. Baudry, G. Rioufol, J. F. Obadia, M. Pozzi. Left ventricular assist device percutaneous deactivation with a Watchman device. *Annals of Thoracic Surgery*, 2021, pp.S0003-4975(21)00067-9. 10.1016/j.athoracsur.2020.11.051 . inserm-03274413

HAL Id: inserm-03274413

<https://inserm.hal.science/inserm-03274413>

Submitted on 2 Aug 2023

HAL is a multi-disciplinary open access archive for the deposit and dissemination of scientific research documents, whether they are published or not. The documents may come from teaching and research institutions in France or abroad, or from public or private research centers.

L'archive ouverte pluridisciplinaire **HAL**, est destinée au dépôt et à la diffusion de documents scientifiques de niveau recherche, publiés ou non, émanant des établissements d'enseignement et de recherche français ou étrangers, des laboratoires publics ou privés.



Distributed under a Creative Commons Attribution - NonCommercial 4.0 International License

Left ventricular assist device percutaneous deactivation with a Watchman device

Running head: LVAD percutaneous deactivation

Tanous Aoun¹, MD, Guillaume Baudry², MD, Gilles Rioufol², MD, PhD, Jean Francois Obadia¹, MD, PhD, Matteo Pozzi¹, MD, PhD

¹Department of Cardiac Surgery, “Louis Pradel” Cardiologic Hospital, Lyon, France

²Department of Cardiology, “Louis Pradel” Cardiologic Hospital, Lyon, France

Word count: 1464

Corresponding author:

Matteo Pozzi

Department of Cardiac Surgery, “Louis Pradel” Cardiologic Hospital

28, Avenue du Doyen Lépine, 69500 - Lyon, France

Email: mpozzi1979@gmail.com

Abstract

Myocardial recovery in left ventricular assist device patients is a rare event. Surgical explantation remains a risky and challenging procedure. Alternative percutaneous techniques could represent an effective solution. We report the clinical use of a Watchman closure device in a HeartMate 3 left ventricular assist device deactivation.

Abstract word count: 47

Left ventricular assist devices (LVAD) are an established therapeutic option for end-stage heart failure as a bridge-to-transplantation or destination therapy [1]. Ventricular unloading during LVAD support could promote reverse myocardial remodeling leading to device removal in selected patients. However, the bridge-to-recovery (BTR) strategy involves only 1-2% of LVAD patients [2,3]. Although various surgical techniques could represent the definitive therapy for device removal, they are associated with high morbidity and mortality. Minimally invasive or percutaneous deactivation could be suggested as an attractive alternative. We present a case of a successful BTR strategy in a HeartMate 3 (Abbott Cooperation, Abbott Park, Illinois) LVAD with a Watchman (Boston Scientific, Inc, Marlborough, Massachusetts) closure device.

A 43-year-old man received a HeartMate 3 as a BTR on an underlying inotrope-dependent alcoholic cardiomyopathy. His recent medical history was characterized by an episode of refractory cardiogenic shock managed with a peripheral veno-arterial extracorporeal membrane oxygenation for 6 days. The patient was discharged home at postoperative day 55 after LVAD implantation. The patient was up-titrated to the maximum dose of beta-blocker, angiotensin receptor-neprilysin inhibitor and mineralocorticoid receptor antagonist and we got alcohol abstinence for a year. One year after implantation, transthoracic echocardiography performed during a ramp test showed signs of myocardial recovery with improved left ventricular global contractility (left ventricular ejection fraction [LVEF]=53%) as well as reverse remodeling (end-diastolic diameter=44 mm) and a suboptimal right ventricular function (tricuspid annular plane systolic excursion=18 mm, pulsed-wave tissue Doppler-derived systolic myocardial velocity of the tricuspid lateral annulus [S']=8 cm/s) at a reduced speed of 4600 rpm. At right heart catheterization, the hemodynamic conditions remained stable (cardiac output=4.5-4.8 l/min) after a stepwise reduction of the LVAD flow. After multidisciplinary discussion by our Heart Failure Team, we decided on a HeartMate 3 deactivation. We opted for a percutaneous occlusion of the outflow graft and subcutaneous transection of the driveline.

The procedure was performed in our hybrid room under local anesthesia and fluoroscopy guidance. The LVAD outflow graft was accessed through the right femoral artery. A 21 mm Watchman device was deployed in the distal outflow graft proximal to the aortic anastomosis once the HeartMate 3 was turned off (Figure 1A). The aortography performed at the end of the procedure revealed the persistence of a partial backflow through the outflow graft (Figure 1B). The procedure was uneventful. Thereafter, the transection of the driveline was performed in a sterile fashion. A 5-cm skin incision was performed at the exit site following the driveline course. After subcutaneous mobilization, the driveline was transected and the subcutaneous and cutaneous layers were closed in a standard fashion.

The echocardiography performed at hospital discharge on postoperative day 4 showed a non-dilated left ventricle with a normal systolic function (LVEF=50%) and a stable, moderate systolic dysfunction of the right ventricle. Computed tomography confirmed a partial backflow in the outflow graft (Figure 2A). He was left on oral anticoagulation treatment with a goal of international normalized ratio of 2 to 3. One year after the deactivation, the patient was still in New York Heart Association functional class I with no signs of heart failure and satisfactory echocardiographic and hemodynamic findings (LVEF=50%, cardiac output=5.0 l/min, mixed venous oxygen saturation=56%). Computed tomography eventually showed a complete thrombosis of the outflow graft (Figure 2B).

Comment

LVAD explantation or deactivation for ventricular recovery is an attractive solution in order to improve survival and quality of life in long-term mechanical circulatory support patients. Although data from American and European registries showed that approximately 1% of LVAD patients could be weaned from the device [1,4], the incidence of cardiac recovery is higher (11%) in patients implanted with an “a priori” BTR strategy [2]. The lack of 1) well-structured protocols for LVAD weaning, 2) standardized LVAD explantation criteria, 3) adjuvant drug therapy and 4) long-term follow-up data could at least partially explain that the BTR is an under-recognized strategy.

Various explantation techniques have been used and the differences rely on the degree of retained pump material [5]. However, these techniques often imply generous surgical approaches, which display a relevant postoperative morbidity and mortality. More recently, totally percutaneous techniques have been described in LVAD deactivation case reports. Zeigler et al. reported the first catheter-based approach for percutaneous LVAD deactivation by deploying an Amplatzer Vascular Plug II (Abbott) in the distal outflow graft [6]. Grinstein et al. described a LVAD percutaneous withdrawal using an Amplatzer Septal Occluder (Abbott) in the LVAD outflow graft at the level of the anastomosis with the ascending aorta [7]. Finally, Albulushi et al. developed and described a formal program including patient selection and management for percutaneous LVAD deactivation [8]. They performed LVAD deactivation in 7 patients using 3 vascular plugs each in the outflow graft. All procedures have been successful with no subsequent mortality but two patients required heart transplantation 2 months and 3 months, respectively, after the deactivation, underlying the utmost importance of patient selection.

Herein, we present a successful LVAD percutaneous deactivation with a Watchman device allowing for a complete outflow graft thrombosis at 1-year follow-up. We opted for a Watchman device owing to our cardiologists' experience in percutaneous left atrial appendage closure. The 21 mm size (+50% as compared to the 14 mm outflow graft) was chosen to obtain a stronger radial force during the deployment of the device. Moreover, the circular shape and the permeable polyester fabric partially covering the surface of the device seem suitable characteristics for LVAD outflow graft occlusion. Albeit encouraging, we cannot draw exhaustive conclusions from our preliminary experience, as the aforementioned advantages of the Watchman device should be considered speculative. Larger case series should focus the attention on the technical details (appropriate sizing, potential need for multiple closure devices, permeability) of the Watchman device in this specific indication as well as its theoretical advantages over the Amplatzer devices.

Myocardial recovery after LVAD implantation is unusual but should be more actively pursued.

LVAD percutaneous deactivation using a Watchman device can be safely and effectively performed allowing for complete outflow graft thrombosis. Further studies are required to best define the role of this percutaneous closure device in this steadily growing subset of patients eligible to LVAD weaning.

References

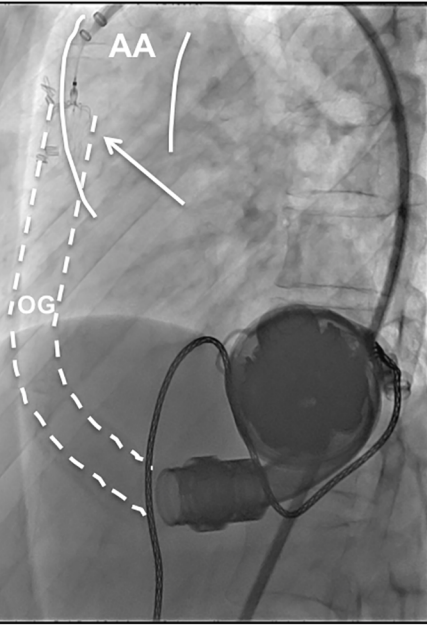
- [1] Teuteberg JJ, Cleveland JC Jr, Cowger J, et al. The Society of Thoracic Surgeons InterMACS 2019 Annual Report: The Changing Landscape of Devices and Indications. *Ann Thorac Surg.* 2020;109:649-660.
- [2] Wever-Pinzon O, Drakos SG, McKellar SH, et al. Cardiac Recovery During Long-Term Left Ventricular Assist Device Support. *J Am Coll Cardiol.* 2016;68:1540-1553.
- [3] Topkara V, Garan R, Fine B, et al. Myocardial Recovery in Patients Receiving Contemporary Left Ventricular Assist Devices. Results From the Interagency Registry for Mechanically Assisted Circulatory Support (INTERMACS). *Circ Heart Fail.* 2016;9:e003157.
- [4] Antonides CFJ, Schoenrath F, de By TMMH, et al. Outcomes of patients after successful left ventricular assist device explantation: a EUROMACS study. *ESC Heart Fail.* 2020;7:1085-1094.
- [5] Baldwin AC, Sandoval E, Letsou GV, Mallidi HR, Cohn WE, Frazier OH. Surgical approach to continuous-flow left ventricular assist device explantation: A comparison of outcomes. *J Thorac Cardiovasc Surg.* 2016;151:192-198.
- [6] Zeigler SM, Sheikh AY, Lee PHU, et al. A Novel, Catheter-Based Approach to Left Ventricular Assist Device Deactivation After Myocardial Recovery. *Ann Thorac Surg.* 2014;98:710-713.
- [7] Grinstein J, Estrada J, Sayer G, et al. Left Ventricular Assist Device Deactivation via Percutaneous Closure of the Outflow Graft. *J Card Fail.* 2016;22:653-655.
- [8] Albulushi A, Goldsweig AM, Stoller D et al. Percutaneous Deactivation of Left Ventricular Assist Devices. *Semin Thorac Cardiovasc Surg.* 2020;32:467-472.

Figure Legends

Figure 1: A) Fluoroscopy showing the implantation of the Watchman device (arrow) in the distal outflow graft proximal to the aortic anastomosis. B) Aortography showing the persistence of a partial retrograde flow through the outflow graft.

AA = ascending aorta. OG = outflow graft.

Figure 2: A) Computed tomography scan image performed before hospital discharge showing the persistence of a partial backflow in the outflow graft through the Watchman device. B) Computed tomography scan image performed at 1-year follow-up showing the complete thrombosis of the outflow graft.

A**B**