HAL
open science

Neochord anterior leaflet treatment to facilitate transcatheter mitral valve replacement with 3D real-time echocardiography

A. Beiras-Fernandez, T. F. Ruf, J. I. Obadia, T. Münzel, F. Kreidel, R. S. Von Bardeleben

To cite this version:

A. Beiras-Fernandez, T. F. Ruf, J. I. Obadia, T. Münzel, F. Kreidel, et al.. Neochord anterior leaflet treatment to facilitate transcatheter mitral valve replacement with 3D real-time echocardiography. European Heart Journal, 2020, 41 (45), pp.4359. 10.1093/eurheartj/ehaa504 . inserm-03269059

HAL Id: inserm-03269059

https://inserm.hal.science/inserm-03269059

Submitted on 23 Jun 2021

HAL is a multi-disciplinary open access archive for the deposit and dissemination of scientific research documents, whether they are published or not. The documents may come from teaching and research institutions in France or abroad, or from public or private research centers.

L'archive ouverte pluridisciplinaire **HAL**, est destinée au dépôt et à la diffusion de documents scientifiques de niveau recherche, publiés ou non, émanant des établissements d'enseignement et de recherche français ou étrangers, des laboratoires publics ou privés.

References

1. Nazir S, Ahuja KR, Alamir MA. Is the National Readmission Database the right database to identify valve-in-valve TAVR patients? *Eur Heart J* 2020;**41**:4357.
2. Hirji SA, Percy ED, Zogg CK, Malarczyk A, Harloff MT, Yazdchi F, Kaneko T. Comparison of in-hospital outcomes and readmissions for valve-in-valve transcatheter aortic valve replacement vs. reoperative surgical aortic valve replacement: a contemporary assessment of real-world outcomes. *Eur Heart J* 2020;**41**:2747–2755.
3. Bavaria J. TAVR update: new insights and perspectives from the US national STS/ACC TVT registry. https://www.sts.org/sites/default/files/102419%201645.%20Bavaria.%20TVT.pdf (6 February 2020).
4. Kaneko T, Vassileva CM, Englum B, Kim S, Yammine M, Brennan M, Suri RM, Thourani VH, Jacobs JP, Aranki S. Contemporary outcomes of repeat aortic valve replacement: a benchmark for transcatheter valve-in-valve procedures. *Ann Thorac Surg* 2015;**100**:1298–1304; discussion 1304.
5. Zogg CK, Pawlik TM, Haider AH. Three common methodological issues in studies of surgical readmission rates: the trouble with readmissions. *JAMA Surg* 2018;**153**:1074–1076.
6. Neupane S, Singh H, Lammer J, Othman H, Yamasaki H, Rosman HS, Bossone E, Mehta RH, Eggebrecht H. Meta-analysis of transcatheter valve-in-valve implantation versus redo aortic valve surgery for bioprosthetic aortic valve dysfunction. *Am J Cardiol* 2018;**121**:1593–1600.

CARDIOVASCULAR FLASHLIGHT

doi:10.1093/eurheartj/ehaa504
Online publish-ahead-of-print 29 July 2020

Neochord anterior leaflet treatment to facilitate transcatheter mitral valve replacement with 3D real-time echocardiography

Andres Beiras-Fernandez[1], Tobias Friedrich Ruf[2], Jean-François I. Obadia[3], Thomas Münzel[2]*, Felix Kreidel[2], and Ralph Stephan von Bardeleben[2]

[1]Department of Heart and Vascular Surgery, Heart Valve Center, University Medical Center Mainz, Mainz, Germany; [2]Center of Cardiology, Heart Valve Center, University Medical Center Mainz, Mainz, Germany; and [3]Hopital Cardiothoracique Louis Pradel, BP Lyon Montchat, Lyon Cedex 03 69394, France
* Corresponding author. Tel: +496131 17 7250, Fax: +496131 17 6615, Email: tmuenzel@uni-mainz.de

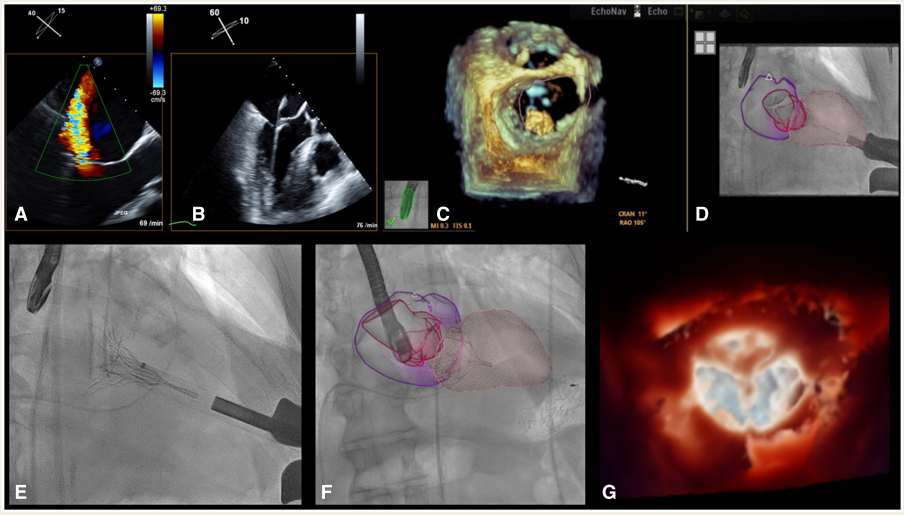

Transapical repair with neochord implantation (Neochord DS1000; Neochord, USA) has emerged as a novel therapy for primary/degenerative mitral valve disease (*Panel A*). Recently, mitral valve replacement with Tendyne (Abbott, USA) was granted CE approval. The Tendyne valve is a trileaflet porcine pericardial valve within a self-expanding covered stent implanted and tethered through the left ventricular apex. Implantation of the Tendyne valve may result in neo left ventricular outflow tract (LVOT) obstruction in the presence of a long anterior mitral leaflet, an elongated anterior chordae, and/or a dynamic septum bulge. We hypothesized that grasping and manually tethering of the anterior mitral valve leaflet (AML) with 1-2 ePTFE neochords would result in a reduced risk of neoLVOT obstruction. The procedure was done in a multi-morbid 69-year-old male with severe mitral regurgitation. Surgery as well as percutaneous edge-to-edge therapy had previously been ruled out due to increased surgical risk and a short posterior mitral leaflet, respectively. Through a reduced anterior lateral thoracotomy, the apex was exposed. Two chords were placed in the central segment of A2 and adjusted to pull the anterior leaflet (*Panels B* and *C*, Supplementary material online, *Videos S1* and *S2*). One of the chords tore the AML in a lampoon split. Through the same transapical access, the introducer sheath of the Tendyne system with a 24-mm Tendyne valve was inserted and the valve deployed in optimal position, with the remaining neochord still tethering AML (*Panels D–G*,elcome Supplementary material online, *Videos S3* and *S4*). After a short period of forward failure resulting from insufficient left ventricular filling, the valve proved competent with normal gradients and no neoLVOT compromise (Supplementary material online, *Videos S5* and *S6*). Follow-up at 6–12–18 months showed excellent valve performance.

Supplementary material is available at *European Heart Journal* online.

© The Author(s) 2020. Published by Oxford University Press on behalf of the European Society of Cardiology.
This is an Open Access article distributed under the terms of the Creative Commons Attribution Non-Commercial License (http://creativecommons.org/licenses/by-nc/4.0/), which permits non-commercial re-use, distribution, and reproduction in any medium, provided the original work is properly cited. For commercial re-use, please contact journals.permissions@oup.com

Downloaded from https://academic.oup.com/eurheartj/article/41/45/4359/5877565 by INSERM user on 24 June 2021