



**HAL**  
open science

# Thiamine Deficiency as a Cause for Acute Circulatory Failure: An Overlooked Association in Western Countries

A. Hayek, M. Djabou, N. Mewton, E. Bonnefoy-Cudraz, T. Bochaton

► **To cite this version:**

A. Hayek, M. Djabou, N. Mewton, E. Bonnefoy-Cudraz, T. Bochaton. Thiamine Deficiency as a Cause for Acute Circulatory Failure: An Overlooked Association in Western Countries. *Canadian Journal of Cardiology (CJC)*: official journal of the Canadian Cardiovascular Society (CCS), 2020, 2 (6), pp.716-718. 10.1016/j.cjco.2020.07.011 . inserm-03268235

**HAL Id: inserm-03268235**

**<https://inserm.hal.science/inserm-03268235v1>**

Submitted on 23 Jun 2021

**HAL** is a multi-disciplinary open access archive for the deposit and dissemination of scientific research documents, whether they are published or not. The documents may come from teaching and research institutions in France or abroad, or from public or private research centers.

L'archive ouverte pluridisciplinaire **HAL**, est destinée au dépôt et à la diffusion de documents scientifiques de niveau recherche, publiés ou non, émanant des établissements d'enseignement et de recherche français ou étrangers, des laboratoires publics ou privés.



## Case Report

# Thiamine Deficiency as a Cause for Acute Circulatory Failure: An Overlooked Association in Western Countries

Ahmad Hayek, MD,<sup>a,b</sup> Mourad Djabou,<sup>a,b</sup> Nathan Mewton, MD, PhD,<sup>b,c</sup>  
Eric Bonnefoy-Cudraz, MD, PhD,<sup>a,b</sup> and Thomas Bochaton, MD, PhD<sup>a,b</sup>

<sup>a</sup> Cardiac Intensive Care Unit, Louis Pradel Hospital, Bron, France

<sup>b</sup> Claude Bernard University Lyon 1, Lyon, France

<sup>c</sup> Investigation Clinical Center, Louis Pradel Hospital, Bron, France

### ABSTRACT

A 42 year-old patient presented with circulatory failure and lactic acidosis. Clinical features, later coupled with biological tests, led to the diagnosis of wet beriberi syndrome and scurvy. Echocardiography showed a pattern of thiamine deficiency with high cardiac output and low vascular resistance. The patient's condition and biological parameters immediately improved after treatment injections of thiamine. Wet BeriBeri is often overlooked in western countries and is a diagnosis that must be considered based on history, and clinical and echocardiographical findings.

### RÉSUMÉ

Un patient âgé de 42 ans a présenté une insuffisance circulatoire et une acidose lactique. Ses caractéristiques cliniques et les résultats de laboratoire obtenus ultérieurement ont mené au diagnostic de béribéri humide et de scorbut. Une échocardiographie a révélé un profil indiquant une carence en thiamine accompagnée d'un débit cardiaque élevé et d'une faible résistance vasculaire. L'état et les paramètres biologiques du patient se sont améliorés immédiatement après l'administration de thiamine par injection. Le diagnostic de béribéri humide est souvent négligé dans les pays occidentaux, mais il faut en tenir compte en présence des signes appropriés : antécédents du patient, observations cliniques et résultats à l'échocardiographie.

Wet BeriBeri is a recognized etiology of high-output heart failure with lactic acidosis. It remains unusual in western countries and is a health hazard. We describe a case of thiamine deficiency associated with scurvy features exhibiting circulatory shock and discuss treatment and outcome.

### Case

A 42-year-old Caucasian man presented to the emergency department with a 1-week history of chest pain and progressive dyspnea. On admission, he had minimal peripheral edema and circulatory failure features with low blood pressure of 90/50 mm Hg, tachypnea at 40 per minute, and tachycardia of 130 beats per minute. Capillary refill time was higher than 3 seconds. A grade 2/6 systolic ejection murmur was found, as well as bilateral pulmonary basal crackles. There was

no fever, no ascites, or any stigmata of cirrhosis. Periodontal disease (with bleeding gums) and features of malnutrition (body mass index 19 kg/m<sup>2</sup>) were also observed. He admitted to chronic alcohol consumption of 20 g/day and a diet restricted to rapidly absorbed refined carbohydrates. Past medical history was otherwise unremarkable. He had no history of toxic ingestions, which was later confirmed with a toxicology screen.

Electrocardiogram showed regular sinus rhythm with a negative T wave in lead augmented vector left. Initial blood tests (Table 1) indicated high levels of N-terminal pro-B-type natriuretic peptide (NT-proBNP) (7527 ng/L), elevated troponin T (high-sensitivity cardiac troponin T [hs-cTnT]; 125 ng/L), and lactic acidosis (6.3 mmol/L). A transthoracic echocardiogram revealed preserved left-ventricular ejection fraction (LVEF 50%) with inferior hypokinesia and non-dilated left cavities (left ventricle diastolic diameter 55 mm; left atrial surface 18 cm<sup>2</sup>). The right-ventricle ejection fraction was also preserved with a tricuspid annular plane systolic excursion of 20 mm. Estimated systolic pulmonary artery pressure was 50 mm Hg. A 2-mm pericardial effusion was found anterior to the right atrium and ventricle. Hemodynamic echographic profile assessment indicated high cardiac output at 9.1 L/min (indexed cardiac output of 4.9 L/min per m<sup>2</sup>), with velocity time integral at 22 cm and heart rate at 110

Received for publication June 22, 2020. Accepted July 16, 2020.

**Ethics Statement:** The research reported has adhered to the relevant ethical guidelines.

Corresponding author: Dr Ahmad Hayek, Hôpital cardiologique Louis Pradel, Unité d'urgence et soins intensifs cardiologiques, 28 avenue Doyen Lépine, 69677 Bron, France. Tel.: 0472357549.

E-mail: [ahmad.hayek0@gmail.com](mailto:ahmad.hayek0@gmail.com)

See page 718 for disclosure information.

### Novel Teaching Points

- Thiamine deficiency is a well known, yet unfrequent cause of circulatory shock and lactic acidosis in western countries and remains a health hazard, especially as a result of malnutrition and alcohol consumption.
- Wet beriberi must be considered based on history, and clinical and echocardiographical findings, without waiting for thiamine testing in patients with dietary decompensation.
- A small drop in thiamine blood levels may be sufficient to explain lactic acidosis and hemodynamic instability.
- Scurvy can occur in conjunction with wet beriberi in patients with altered nutritional status.

beats per minute. Systemic vascular resistance was very low at 465 dynes/sec per cm<sup>5</sup>. A computed tomography scan ruled out aortic dissection, pulmonary embolism, any infectious process, and any cirrhosis feature. Additional laboratory investigations revealed normal thyroid hormone levels, no anemia, and normal serum inflammatory markers (C-reactive protein < 1 mg/L, procalcitonin < 0.5 mg/L), excluding sepsis (Table 1). At this point, wet beriberi was suspected.

Coronary angiography performed on the second day was normal. Acute myocarditis was not suspected since LVEF was preserved with no alteration of cardiac output, and inflammatory markers were negative. Additional metanephrine and normetanephrine levels were in the normal range. Hypoalbuminemia (27 g/L) and iron deficiency were detected. A salivary gland biopsy, performed to rule out amyloidosis, was normal.

Beriberi was confirmed 2 days later with blood tests showing a low serum thiamine (B1) level of 44.7 nmol/L (normal range: 66-200 nmol/L). Scurvy was concomitantly clinically and biologically diagnosed (Vitamin C 6 μmol/L; normal range: 25-85).

Treatment consisted of intravenous injections of 100 mg of thiamine twice a day followed by oral supplementation of 250 mg 3 times a day. β-Blocker therapy was also initially initiated. We observed a rapid improvement in biological and hemodynamic parameters (Fig. 1).

During a 2-month follow-up period without the need for medication (angiotensin-converting enzyme inhibitor or diuretics), he showed no relapse. Thiamine blood level rose to 86.1 nmol/L, and NT-proBNP level normalized. A transthoracic echocardiogram revealed a preserved LVEF (68%) with normal global longitudinal strain—22.3%. Magnetic resonance imaging was performed, revealing no myocardial fibrosis or myocarditis-related scarring.

### Discussion

Thiamine deficiency is an unusual cause of circulatory failure<sup>1</sup> and remains a health hazard, especially due to malnutrition.<sup>2</sup> Treatment with thiamine is safe and effective,

**Table 1.** Biological data at admission for a patient with circulatory shock due to wet beriberi and scurvy

Test	Outcome	Normal range
Natremia, mmol/L	136	136-145
Kalaemia, mmol/L	4.2	3.4-4.5
Chlorine, mmol/L	104	98-107
Bicarbonates, mmol/L	19	22-29
Protein, g/L	62	64-83
Calcium, mmol/L	2.34	2.1-2.55
Urea, mmol/L	3.2	3.2-7.4
Creatinine, μmol/L	67	64-104
Albumin, g/L	27	35-52
Prealbumin, g/L	0.21	0.18-0.45
C-reactive protein, mg/L	< 1.0	< 5.0
Troponin, ng/L	125	< 34
Lactate, mmol/L	6.3	0.5-2.2
Nt-pro-Brain natriuretic peptide, ng/L	7527	<125
AST, U/L	40	5-34
ALT, U/L	21	< 55
Gamma GT, U/L	115	12-64
TSH, mUI/L	3.9	0.4-3.1
T3L, pmol/L	3.0	2.9-4.9
Hemoglobin, g/L	130	130-170

ALT, alanine aminotransferase; AST, aspartate aminotransferase; GT, glutamyl transferase; TSH, thyroid-stimulating hormone; T3L, triiodothyronine.

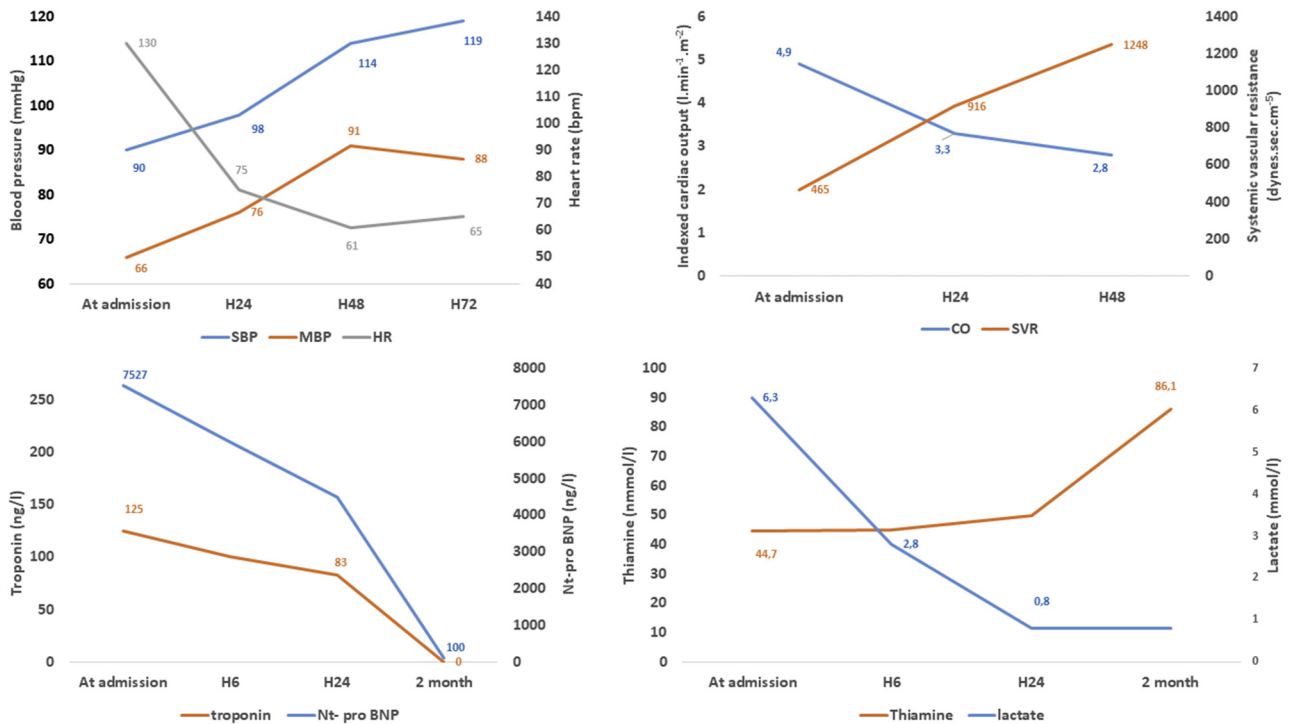
highlighting the importance of suspecting the diagnosis early, particularly in an emergency situation. Its prevalence has never been evaluated in western countries, and the literature is limited to a few case reports. To the best of our knowledge, there are no published data describing thiamine concentration at clinical presentation. In a few case reports, blood levels were found not to be severely depressed.<sup>3,4</sup> To highlight this finding, Martin et al.<sup>5</sup> discussed that not all people are equally sensitive to thiamine deficiency, with consequences depending on genetic predisposition, alcoholic and chronic nutritional state, arguing for the existence of thiamine-using enzyme variants. The capacity for thiamine uptake into the cells may also play a role. However, to clarify these points, genetic studies would be required.

Beriberi is a well known etiology of high-output cardiac failure. Several mechanisms have been proposed to explain the observed hemodynamic abnormalities.<sup>6</sup>

Our case describes a patient with cardiogenic shock due to thiamine deficiency and scurvy. Right heart failure has been previously described in patients with scurvy,<sup>7</sup> mainly as a result of severe pulmonary hypertension. Vitamin C has vasodilatory properties, increasing availability of endothelial nitric oxide.<sup>8</sup> In our case, the data and the complete recovery after thiamine administration suggest the exclusive accountability of thiamine deficiency in the presentation. Diagnosing wet beriberi requires a high clinical level of suspicion based on medical history and physical examination. The only way to establish the diagnosis is to consider it, and monitor improvement after thiamine administration, as blood tests are not rapidly available (they take weeks to be processed).

### Funding Sources

The authors have no funding sources to declare.



**Figure 1.** Acute clinical evolution and biological findings kinetics, for a patient with circulatory shock due to wet beriberi and scurvy. Thiamine injections were started upon admission. bpm, beats per minute; CO, indexed cardiac output; H, hour; HR, heart rate; MBP, mean blood pressure; nt-pro BNP, N-terminal pro-B-type natriuretic peptide; SBP, systolic blood pressure; SVR, systemic vascular resistance.

## Disclosures

The authors have no conflicts of interest to disclose.

## References

- DiNicolantonio JJ, Liu J, O'Keefe JH. Thiamine and cardiovascular disease: a literature review. *Progr Cardiovasc Dis* 2018;61:27-32.
- Whitfield KC, Bourassa MW, Adamolekun B, et al. Thiamine deficiency disorders: diagnosis, prevalence, and a roadmap for global control programs. *Ann N Y Acad Sci* 2018;1430:3-43.
- Lei Y, Zheng M-H, Huang W, Zhang J, Lu Y. Wet beriberi with multiple organ failure remarkably reversed by thiamine administration: a case report and literature review. *Medicine (Baltimore)* 2018;97:e0010.
- Sasaki T, Yukizane T, Atsuta H, et al. [A case of thiamine deficiency with psychotic symptoms—blood concentration of thiamine and response to therapy]. *Seishin Shinkeigaku Zasshi* 2010;112:97-110 [in Japanese].
- Martin PR, Singleton CK, Hiller-Sturmhöfel S. The role of thiamine deficiency in alcoholic brain disease. *Alcohol Res Health* 2003;27:134-42.
- Attas M, Hanley HG, Stultz D, Jones MR, McAllister RG. Fulminant beriberi heart disease with lactic acidosis: presentation of a case with evaluation of left ventricular function and review of pathophysiologic mechanisms. *Circulation* 1978;58:566-72.
- Abbas F, Ha LD, Sterns R, Von Doenhoff L. Reversible right heart failure in scurvy rediscovery of an old observation. *Circ Heart Fail* 2016;9:e003497.
- Taddei S, Virdis A, Ghiadoni L, Magagna A, Salvetti A. Vitamin C improves endothelium-dependent vasodilation by restoring nitric oxide activity in essential hypertension. *Circulation* 1998;97:2222-9.