



HAL
open science

Carotid intraplaque haemorrhage: pathogenesis, histological classification, imaging methods and clinical value

M. Mura, N. Della Schiava, A. Long, E. N. Chirico, V. Pialoux, A. Millon

► **To cite this version:**

M. Mura, N. Della Schiava, A. Long, E. N. Chirico, V. Pialoux, et al.. Carotid intraplaque haemorrhage: pathogenesis, histological classification, imaging methods and clinical value. *Annals of translational medicine*, 2020, 8 (19), pp.1273. 10.21037/atm-20-1974 . inserm-03261174

HAL Id: inserm-03261174

<https://inserm.hal.science/inserm-03261174>

Submitted on 15 Jun 2021

HAL is a multi-disciplinary open access archive for the deposit and dissemination of scientific research documents, whether they are published or not. The documents may come from teaching and research institutions in France or abroad, or from public or private research centers.

L'archive ouverte pluridisciplinaire **HAL**, est destinée au dépôt et à la diffusion de documents scientifiques de niveau recherche, publiés ou non, émanant des établissements d'enseignement et de recherche français ou étrangers, des laboratoires publics ou privés.



Distributed under a Creative Commons Attribution - NonCommercial - NoDerivatives 4.0 International License



Carotid intraplaque haemorrhage: pathogenesis, histological classification, imaging methods and clinical value

Mathilde Mura¹, Nellie Della Schiava^{2,3}, Anne Long^{1,4}, Erica N. Chirico⁵, Vincent Pialoux^{1,6}, Antoine Millon^{2,7}

¹Univ Lyon, University Claude Bernard Lyon 1, Interuniversity Laboratory of Human Movement Biology EA7424, Lyon, France; ²Department of Vascular and Endovascular Surgery, Groupement Hospitalier Est, Louis Pradel Hospital, Hospices Civils de Lyon, Lyon, France; ³Institut National des Sciences Appliquées Lyon, Laboratoire de Génie Electrique et Ferroélectricité EA 682, Villeurbanne, France; ⁴Departement of Internal Medicine and Vascular Medicine, Groupement Hospitalier Edouard Herriot, Hospices Civils de Lyon, Lyon, France; ⁵Department of Biomedical Sciences, Cooper Medical School of Rowan University, Camden, NJ, USA; ⁶Institut Universitaire de France, Paris, France; ⁷Univ Lyon, University Claude Bernard Lyon 1, CarMeN Laboratory, INSERM U1060, Bron, France

Contributions: (I) Conception and design: None; (II) Administrative support: None; (III) Provision of study materials or patients: None; (IV) Collection and assembly of data: None; (V) Data analysis and interpretation: None; (VI) Manuscript writing: All authors; (VII) Final approval of manuscript: All authors.

Correspondence to: Prof. Antoine Millon. 59 Boulevard Pinel, 69500 Bron, France. Email: antoine.millon@chu-lyon.fr.

Abstract: Vulnerable carotid atherosclerotic plaques are characterised by several risk factors, such as inflammation, neovascularization and intraplaque haemorrhage (IPH). Vulnerable plaques can lead to ischemic events such as stroke. Many studies reported a relationship between IPH, plaque rupture, and ischemic stroke. Histology is the gold standard to evaluate IPH, but it required carotid endarterectomy (CEA) surgery to collect the tissue sample. In this context, several imaging methods can be used as a non-invasive way to evaluate plaque vulnerability and detect IPH. Most imaging studies showed that IPH is associated with plaque vulnerability and stroke, with magnetic resonance imaging (MRI) being the most sensitive and specific to detect IPH as a predictor of ischemic events. These conclusions are however still debated because of the limited number of patients included in these studies; further studies are required to better assess risks associated with different IPH stages. Moreover, IPH is implicated in plaque vulnerability with other risk factors which need to be considered to predict ischemic risk. In addition, MRI sequences standardization is required to compare results from different studies and agree on biomarkers that need to be considered to predict plaque rupture. In these circumstances, IPH detection by MRI could be an efficient clinical method to predict stroke. The goal of this review article is to first describe the pathophysiological process responsible for IPH, its histological detection in carotid plaques and its correlation with plaque rupture. The second part will discuss the benefits and limitations of imaging the carotid plaque, and finally the clinical interest of imaging IPH to predict plaque rupture, focusing on MRI-IPH.

Keywords: Carotid atherosclerosis; intraplaque haemorrhage (IPH); magnetic resonance imaging (MRI); stroke prevention

Submitted Feb 27, 2020. Accepted for publication May 10, 2020.

doi: 10.21037/atm-20-1974

View this article at: <http://dx.doi.org/10.21037/atm-20-1974>

Background

Stroke is the second most frequent cause of death in the world and the primary cause of long-term disabilities in western countries (1). At least 80% of all strokes are ischemic and 20% of them are the consequence of the rupture of a vulnerable carotid atherosclerotic plaque

located at the carotid bifurcation (1). As strokes resulting from carotid plaque rupture are known to be linked to embolism (2), plaque vulnerability assessment is likely an essential element in the detection of patients at risk for ischemic stroke and should be a factor when considering carotid endarterectomy (CEA) surgery (3). Currently, the

decision to perform CEA surgery is only based on the degree of carotid stenosis and cerebrovascular medical history (4). The link between stenosis degree and stroke risk has been widely demonstrated (5), and many national guidelines still claim that stenosis should remain the main criteria to classify plaques and thus the decision of CEA (6) even if evidence has been provided otherwise for asymptomatic patients (7,8) thus this sole factor may be insufficient to evaluate the risk-benefit ratio of CEA surgery in these patients (3,9). A meta-analysis showed that for most asymptomatic patients, a very few ischemic events happened after CEA, thus the risk-benefit ratio resulting from the CEA might be unfavourable (3,7,10). Moreover, the 10 years risk of stroke is only 4.6%, suggesting that 95% of the CEA performed on asymptomatic patient are unnecessary (11,12). Thus, it appears that management of CEA in asymptomatic patients need to be rethought and *in vivo* identification of vulnerable plaque has to be improved to be commonly used in a clinical setting for the decision of CEA surgery. In this context, non-invasive imaging methods and more specifically magnetic resonance imaging (MRI) appear to be the most sensitive and specific to identify IPH *in vivo* (13,14), especially in a clinical perspective to predict stroke risk (15-17). In this regards, ESVS guidelines encourage surgeons to use imaging to identify plaque with vulnerable factors in particular intraplaque haemorrhage (IPH) that needs CEA surgery (18). Several vulnerability factors were reported: thin fibrous cap, large lipid-necrotic core volume, monocytes infiltration (19) and IPH (19,20) resulting from immature neovascularization (21). It has been shown that all these factors are unequally involved in plaque destabilisation (19,22,23). Since 1936, IPH has been described as a risk factor of plaque rupture (24). During the 1980s several studies have demonstrated a relationship between carotid IPH and history of ischemic events (25,26). IPH is more prevalent in symptomatic stroke patients, regardless of the time since the event, than in asymptomatic patients (27-30). Carotid IPH has been documented by histological studies over the last 20 years, now it is likely an important factor to consider when classifying vulnerable plaques (26). Currently no drug treatment targeting specifically IPH is available; however statin use is associated with lower prevalence of plaque with neovascularisation (31) and IPH (32). On the contrary, platelet antiaggregant is associated with higher prevalence of IPH (32). In this context, *in vivo* detection of IPH appears to be one of the most reliable factors to predict cerebral ischemic events (15-17).

Carotid IPH

Pathophysiology

IPH is defined by the accumulation of blood components within the atheromatous plaque (26). IPHs are closely linked to the microcirculation within the plaque. McCarthy *et al.* showed that symptomatic plaques showed more, larger and more irregular neo-vessels than asymptomatic plaques (33). Indeed an increased neo-vessels density is associated with IPH and rupture of the plaque (33). In advanced atherosclerotic lesions, hypoxia, along with macrophages triggering inflammation and oxidative stress promoting low density lipoprotein (LDL) oxidation into oxidized LDL (Ox-LDL) processes are merged. All these factors lead to the chronic secretion of vascular endothelial growth factor (VEGF) increasing pathological impaired neoangiogenesis (19). Neo-vessels originating from the vasa vasorum develop through the medium and large arteries from adventitia to the intima (19). These neo-vessels, which lack smooth muscle cells and endothelial gap junctions, are disorganized and incomplete (21,34), and thus are prompt to leak. This results in IPH formation (20) and expansion (35) and the transfer of blood cells that promote plaque rupture (36). IPH carries inflammatory cells (37) that increase the necrotic core volume (38) also indirectly leading to vulnerable plaques rupture and subsequent clinic ischemic events (39).

During IPH, leucocytes, platelets and erythrocytes are released. The leaked erythrocytes break down into iron, cholesterol, glycophorin A and ceroids (24). The erythrocytes and leucocytes (37) extravasated from the lumen of neo-vessels into the atherosclerotic plaque, self-sustain inflammation and pro-oxidant mechanisms (19,40) (*Figure 1*). Indeed, in the hypoxic environment of the plaque, IPH-released neutrophils secrete angiogenic factors such as VEGF and lipid peroxidation by-products, (41,42) known risk-factors for future ischemic events (43). Neutrophils also abundantly express myeloperoxidase, which produce hypochlorous acid and H₂O₂, leading to a decrease in NO bioavailability thus enhancing endothelial dysfunction (44,45). Ultimately, the lysis of neutrophils release highly pro-oxidant materials, such as DNA histones (46). Moreover, the activation of NAD(P)H oxidases and myeloperoxidases in macrophages are known to produce superoxide (O₂^{•-}) enhancing a pro-oxidant environment. To reduce IPH, the leaked erythrocytes are phagocytosed mainly by macrophages. This results in

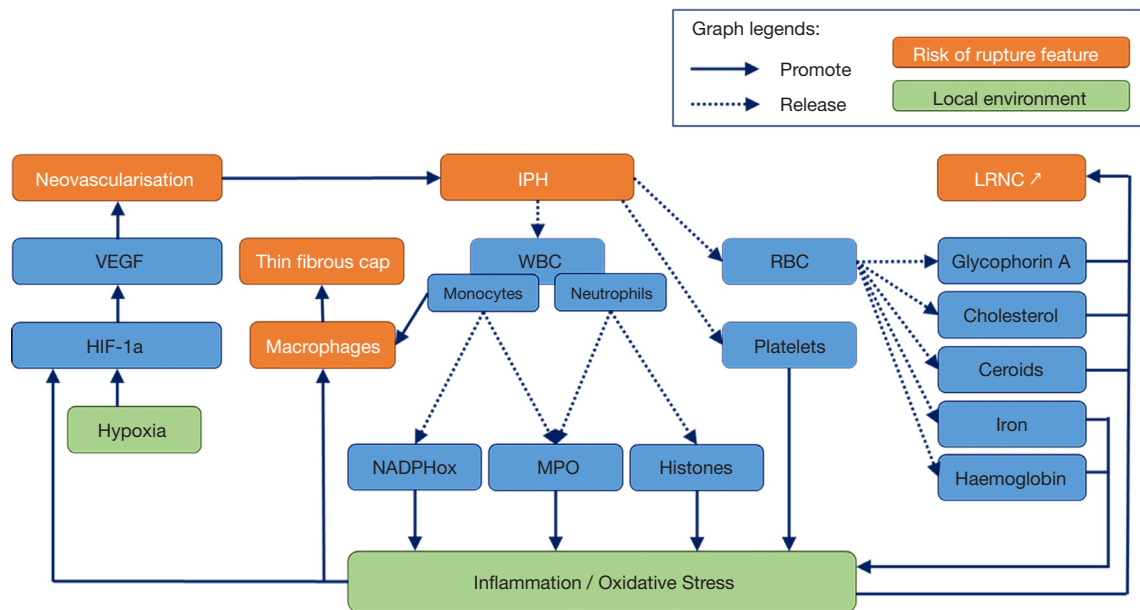


Figure 1 Inflammation and oxidative implications of IPH. IPH, intraplaque haemorrhage; LRNC, lipid rich necrotic core; MPO, myeloperoxidase; NADPHox, nicotinamide adenine dinucleotide phosphate oxidase; RBC, red blood cell; VEGF, vascular endothelial growth factor; WBC, white blood cell.

the release of haemoglobin and iron which are highly pro-oxidant (24) and pro-inflammatory through the conversion of H_2O_2 into the highly toxic hydroxyl (OH^\bullet). In addition, the erythrocytes plasma membrane, which is composed of 40 percent cholesterol, is the primary source of necrotic core expansion during phagocytosis (20,24,47). Therefore regulation mechanisms are implemented to reduce IPH, such as the anti-inflammatory, cytoprotective shift in macrophages phenotype and the recruitment of haptoglobin that metabolise haemoglobin and recycle iron (48). Unfortunately, they are quickly depleted and become inefficient. Consequently, these closely integrated pro-inflammatory and pro-oxidant processes persist which not only enhances IPH but also promotes the growth of the necrotic core (19,49), increasing the risk of ischemic event (36).

Typically the presence of blood in the atherosclerotic plaque is due to leaky neovessels localized to the plaque shoulder (50). However, in different areas, other mechanisms can lead to the presence of blood within the plaque. Cholesterol crystals due to eryptosis can mechanically break neovessels, which bleed into the atheromatous plaque (51,52). Moreover, cholesterol crystal content are independent predictors of thrombus and cardiovascular events (52). Intraplaque blood can also originate from the integration of a luminal erythrocyte-

rich thrombus with the plaque (24,53) or entry of luminal blood (20). Plaque fissures are observed even in plaques with an intact fibrous cap and those that are co-localised with fresh IPH (54). In this case, the thrombus is entrapped into extracellular matrix leading to a narrow lumen, yet it also appears to be a healing process. Histologically, this healing process can be hard to discriminate from IPH (24).

Histology

IPH determination by histology

Histology is the gold standard in studying plaque components like IPH, lipid rich necrotic core (LRNC) and inflammation. Usually, the surgically removed atheromatous plaque also includes the middle part of the media and internal part of the media. In clinical context, surgical pathologists generally evaluate IPH on plaque slices after hematoxylin-eosin (H&E) or Masson trichrome stains, which are non-specific staining for haemorrhage (25,55).

To improve the histological IPHs identifications, several biomarkers are used. The most frequently used is iron, as it links to haemoglobin and is released during erythrocyte phagocytosis; it is highlighted in the adventitia by the Perls technique with Prussian blue stain (Figure 1). Red blood cell (RBC) membrane specific protein cholesterol

Table 1 Histological classifications to determine plaque vulnerability

Classification	Reference	Application	Goal	Features	Stages
American Heart Association classification	Stary 1994; Stary 1995 (62,63)	Histology	Graduate atherosclerosis severity	Isolated macrophages foam cells	Type 1 (initial) lesion
				Mainly intracellular lipid accumulation	Type 2 (fatty streak) lesion
				Type 2 changes & small extracellular lipid pools	Type 3 (intermediate) lesion
				Type 2 changes & core of extracellular lipid	Type 4 (atheroma) lesion
				Lipid core & fibrotic layer, or multiple lipid cores & fibrotic layers or mainly calcific or mainly fibrotic	Type 5 (fibroatheroma) lesion
				Surface defect, hematoma-haemorrhage, thrombus	Type 6 (complicated) lesion
Lovett classification	Lovett 2004 (64)	Histology	Graduate atherosclerosis severity	Definitely stable, e.g., predominantly fibrous, few inflammatory cells, intact cap	Grade 1
				Probably stable, e.g., one feature of instability such as small haemorrhage or inflamed	Grade 2
				Probably unstable, e.g., inflammation, thin cap, and large core but no rupture	Grade 3
				Definitely unstable, e.g., rupture, thrombus, large haemorrhage, thin inflamed cap	Grade 4

crystals are detected by immunohistochemistry with glycophorin A, allowing the discrimination of lipid-rich and erythrocyte-rich parts of the necrotic core (*Figure 1*). Ceroids (56,57) are often co-localised with haem (24) and are markers of senescent RBC but are less specific of IPH than cholesterol crystals (24). They are identified by Raman or fluorescence spectroscopy and are completed by other peroxidation markers. Neutrophils markers such as matrix metalloproteinase-9 (MMP-9), neutrophil gelatinase-associated lipocalin/MMP-9 (NGAL/MMP-9), elastase, CD66b, proteinase 3, myeloperoxidase (MPO) or α -defensins are colocalised with IPH (58). Neutrophils are predictors of recurrent ischemic events.

As these markers are specific to different forms and localisations of RBC, multiple consecutive slice staining could elucidate RBC trafficking and IPH. Moreover, in vulnerable plaques, neo-angiogenesis-derived IPH could be difficult to discriminate from integrate coagulum which is a sign of plaque regression (24). CD34 immunostaining allows for a precise quantification of the micro-vessels density (59). Plaque neo-vascularisation can also be visualised by H&E

staining of endothelial cells (60) or von Willebrand factor (factor VIII) staining (61). To characterise leaky neo-vessels, SMC should also be stained for smooth muscle antibody (SMA), as the presence of factor VIII and absence of SMA indicates that the vessel is leaky.

IPH and vulnerable carotid atherosclerotic plaques in histology

Vulnerable carotid atherosclerotic plaques are composed of various components (*Figure 1*). The lipid-rich necrotic core harbours lipid content such as cholesterol crystals, but also calcifications and haemorrhagic components. As vulnerable plaques continually evolve, different classifications have been established (*Table 1*) (62-64) in order to stratify the associated plaque instability and thus the subsequent ischemic risk.

After surgery, histopathological classifications assess the vulnerability of the carotid atherosclerotic plaque. The American Heart Association classification was the first that aimed to graduate plaque vulnerability (62,63), and more recently, Lovett proposed his own classification, adding

Table 2 IPH stages according to Derksen's classification (70)

IPH stages	Characteristics	IPH age
Recent IPH	Contains unorganised fibrin, intact and some debris of erythrocytes	<2 weeks
Organised IPH	Contains an increased concentration of fibrin, some peripheral capillary and smooth muscle cells as well as a mixture of intact and debris of RBC	Between 2 and 6 weeks
Amorphous IPH	Characterized by disorganized materials and a lack of well delimited cells	>6 weeks
Amorphous IPH with calcifications	Characterized by disorganized materials and a lack of well delimited cells and calcifications	>6 weeks

IPH, intraplaque haemorrhage; RBC, red blood cell.

the inflammation item (64). IPH is an evolving process due to the different pathophysiological processes that are chronologically involved and the subsequent progression of ischemic risk.

In the preclinical setting, mice (ApoE^{-/-} and LDLR^{-/-} under high cholesterol diet) are the most commonly used animals to study atherosclerosis. However, they are poor experimental models of IPH, neovascularisation and plaque rupture. Therefore, IPH data essentially originate from human clinical studies (24) or from other animal species that develop vulnerable carotid atherosclerotic plaques similar to human plaques. For example, annexin V (which is highly released during eryptosis) injection in aortic atheromatous plaque of de-endothelialized rabbits under cholesterol diet leads to the necrotic core growth, free cholesterol crystals formation and higher macrophage recruitment (65) suggesting the role of eryptosis in unstable atherosclerotic plaques. This suggests that in addition to a direct increase in plaque rupture risk (15), IPH might participate in a pathophysiological vicious circle leading to plaque rupture.

Analysing the plaque components, IPH presence is generally associated with a thin fibrous cap and a large necrotic core (19). Pelisek *et al.* found in symptomatic and asymptomatic patients that neo-vessels were present in 93.8% of the plaques with over 70% stenosis and 97.1% of these neo-vessels were immature and leaky leading to IPH (66). A histological study (n=526) led by Redgrave *et al.* on patients with symptomatic carotid plaques who underwent CEA reported that 64.6% of the plaques showed IPH (67). This study also demonstrated that IPH was associated with fibrous cap rupture, independent of other risk factors [OR =3.00 (1.64–5.51)] suggesting that IPH is a contributing factor to plaque vulnerability (67). Vrijenhoek's team reported that IPH was more frequent in men (67%) than in same aged post-menopausal women (54%), while micro-vessels density was not significantly different (68).

Moreover, in the same study IPH leads more often to plaque rupture in men than in women [HR =1.5 (1.1; 2.1)] (68). In most cases, IPH presence was associated with other known risks factors of rupture: necrotic core expansion (19), leaky neo-vessels (20), macrophages accumulation and oxidative stress (19,26).

An Anglo-Dutch group published a histochemistry analysis on symptomatic patients with moderate stenosis. They studied the link between risk factors traditionally associated with plaque rupture and cerebral cardiovascular outcomes (69). Statistical analysis of 1,087 carotid plaques revealed that macrophages infiltration, thrombosis and micro-vessels density [OR (micro-vessels density) 1.49 (1.05; 2.11)] was significantly correlated with plaque vulnerability. On the contrary, no relationship was observed between plaque vulnerability and fibrous cap, lymphocyte infiltration or IPH [OR (IPH) 1.15 (0.84; 1.59)]. The authors suggested that the contradictory findings of neovascularization and IPH could be explained by a blood leakage only present during early IPH in organised stages (Table 2). Nevertheless, this hypothesis was not experimentally tested. Another explanation could be that IPH and thrombosis are hardly discriminable.

IPH histological classifications

None of the previous classification of vulnerable atherosclerotic plaques (62-64) take into account the evolution of IPH, thus several IPH histological classifications were established (70-72). These classifications (71,72) are not commonly used anymore because the classification of Derksen is the most complete and is currently used in anatomopathology. This classification distinguishes four stages of IPH (Table 2) based on histological H&E stain.

According to Derksen's histological classification, organised IPHs are more vulnerable to breakdown than

amorphous and recent IPHs, mainly due to macrophages presence in organised IPHs zones (70). Derksen *et al.* reported that 81% (over 794 studied) of carotid plaques showed an IPH spreading over an average of 5% of the total plaque volume (70). Among these IPHs, 2% were recent, 11% organised, 75% amorphous, and 9% amorphous with calcifications.

However, so far there is no method that can allow *in vivo* diagnosis or follow-up (i.e., imaging) of IPH stages since it is currently only assessable after CEA by histology. Moreover, this criterion is currently not suitable for the clinical decision, because plaque rupture is multifactorial (19,73,74) and other biomarkers need to be taken into account to stratify the ischemic risk (16).

All plaque risk factor of rupture should be evaluated in order to predict future ischemic event, but particular attention should be given in IPH stages assessment especially in the CEA decision for asymptomatic patients.

Imaging

Over the last several years, several imaging techniques have been developed to reliably analyse carotid atherosclerotic plaques composition. In a clinical context, Doppler ultrasonography (75) and computed tomography (CT) (9,10,76) of the supra aortic trunks are commonly used to accurately assess the degree of stenosis. Magnetic resonance angiography (MRA) is being increasingly used (13,77) because it is non-radiant, less nephrotoxic compared to CT, and more accurately examines the cerebral parenchyma.

Ultrasound and contrast enhanced ultrasound

Ultrasounds (US) are the best method to assess the carotid stenosis by imaging (75) but is highly operator dependent. They allow to study the morphologic and hemodynamic features of the plaque by assessing tissues echogenicity. Without contrast medium IPH is hard to discriminate from LRNC only based on carotid plaque echogenicity (78,79). Contrast enhanced US (CEUS) are able to assess neovascularisation *in vivo* in real time (80). IPH can be indirectly visualised in ultrasonography through the vasa vasorum and neovessels analysis by CEUS (80-82); if results of the sole US examination are inconclusive, presence of neovessels observed with CEUS in the carotid plaque might underline IPH presence. Contrast enhanced microbubbles allow for the visualization of vascularized lesions in hyper echogenicity (82). Results on carotid ultrasound with

contrast agent attest that an increased vasa vasorum (83) and microvessels (80) density can enhance the IPH risk. Most of the plaques harbouring an heterogeneous pattern (mixed echoes and anechoic areas) presented IPH at the histological analysis (84).

CT and positron emission tomography (PET) scans

CT is applied in a clinical setting to diagnose morphological abnormalities as stenosis (85), aneurysm or carotid dissection (86) through the tissues density analysis. Computed tomography angiography (CTA) with iodinated contrast medium is required to analyse carotid arteries, but it is also known to underestimate the degree of stenosis (87). However, studies suggest that CTA is able to discriminate IPH parts from lipid-rich and fibrous parts in carotid atherosclerotic plaques (88,89) even if the densities are almost similar (90). Indeed, according to a recent study, IPH can be detected with high sensitivity and specificity by CTA according to attenuation at 25 Hounsfield units (HU) (88). Moreover, calcified rim and soft internal plaques indirectly predict IPH actual presence (91). On symptomatic patients, intraluminal thrombus can be visualized (92). Thus, CT scan is a very specific non-invasive method, but with a limited sensitivity (87). U-King-Im *et al.* compared CT scans and MRI techniques and found the MRI is a better tool to visualise IPH through plaque ulceration (89). Moreover, CT exposes patients to radiation and thus it is not the first-choice technique to assess IPH.

PET scan is an imaging technique with a high sensitivity, but also exposes patients to radiation (93). PET scan is growing imaging technique that is able to measure metabolic activity in different parts of the body. It allows for the visualisation of angiogenesis and macrophage infiltration, and can discriminate lipid-rich plaque from fibrous plaque (94) but failed so far to identify IPH. Several contrast agents have been developed, but fluorodeoxyglucose (FDG) contrast agents targeting macrophages appear to be the most used; they detect inflammation and present good association with histology on carotid and aorta (94) giving details on plaque metabolism. It remains to be demonstrated that the PET signal can reliably predict future long-term cardiovascular events on carotid imaging. With an FDG contrast agent, it is possible to visualise neovessels into the intima (95). Moreover, ¹⁸F-FDG-PET allows the precise visualisation of the plaque anatomy confirmed by guided MRI (96,97). Fluorine F 18-sodium fluoride (¹⁸F-NaF) is a radioactive tracer that can be used in PET-

MRI, it could be a useful imaging technique to characterise vulnerable plaque; tissue sections with high ^{18}F -NaF uptake demonstrated calcification, macrophage infiltration and cell death (98). New contrast agents are needed to precisely characterise IPH.

MRI

The MRI-IPH imaging is a direct method based on iron detection with T1 weighted sequences that produces an intraplaque hyperintense signal (99,100), while other carotid components are visualised as isointense or hypointense signals (101,102). The first sequence validated by histology was a T1-weighted sequence called Magnetic Resonance Direct Thrombus Imaging which is able to detect methemoglobin (103). This sequence detects methaemoglobin-rich haemorrhages, with a strong relationship to histologically confirmed complicated plaques (103). Other sequences were developed, such as 3D Magnetization-Prepared Rapid Acquisition Gradient-Echo (104), three-dimensional T1-weighted Turbo-Spin-Echo sequence (105), Simultaneous Non-contrast Angiography and intraPlaque haemorrhage (106), T1 weigh inversion recovery 3D fast field echo sequence (107) or 3D Spoiled gradient recalled echo pulse sequence for Hemorrhage assessment using INversion recovery and multiple Echoes (3D SHINE) sequences (108). The “black blood” sequence needs no contrast agent to discriminate a LRNC from a lipid core with IPH, as well as other plaque components with a good correlation to histology (109,110). These sequences are specific and sensitive to detect IPH, but they failed in the identification of IPH stages (70). Further sequences such as “black blood” and “gradient echo”, “spin echo” or “fast spin echo” sequences are currently investigated to identify IPH (107).

MRI sensitivity can be enhanced with a dynamic contrast agent, via an intravenous bolus (111). Contrast enhanced MR angiography (CE-MRA) shows a higher sensitivity, specificity, positive predictive value, negative predictive value with a shorter acquisition time and less artefacts for IPH detection (100). Gadolinium enhancement is used to visualise fibrous cap integrity, plaque neovascularization (112), and inflammatory infiltration (113) it also helps to confirm IPH visualised in T1 sequences (112,113). Dynamic contrast intensification techniques can better visualise neovascularisation and inflammation (114). New sequences are currently being investigated in order to better characterize IPH dating and at the same time identify

other vulnerable plaque features, in order to be used in a clinical setting.

Several studies showed a relationship between histological IPH presence and different stages of IPH assessed by MRI (77,115). Depending on classifications, a T1 hyperintense signal is observed if the IPH is fresh, but this hypersignal weakens over time. Limits of this classification may be correlated to the signal intensity variation, because of the interpersonal chemical composition variation in the plaque. Indeed, throughout the brain T1-weighted sequence application, the haemorrhage signal can evolve from hyperintense to hypointense because of the transformation of methemoglobin into hemosiderin (109). Contrary to this, carotid IPH signal can remain hyperintense for more than 18 months (116). The variability of the signal intensity may help in the detection of plaques involved in ischemic events (117) and can also coincide with the different IPH stages, particularly between amorphous and organised stages (70) according to Derksen’s classification (70). Nevertheless, this hypothesis is still not validated by any study. Methemoglobin signal can mix with other tissues signals, such as calcified tissue or hemosiderin, leading to false negatives (100). On the contrary, perivascular-derived signals of adipocytes can lead to IPH false-positives (100). In order to accurately imaging carotid plaque morphology, histopathological variability should be taken into account (118). Indeed, IPH dating by MRI needs to be improved and sequences need to be standardised before clinical use (24,26).

IPH and clinical outcomes

IPH evaluated by histology and clinical outcomes

Although IPH consideration is increasing in the clinical evaluation of the plaque, it should be analysed together with other interrelated clinical and biological factors (i.e., Inflammation, neovascularisation, fibrous cap thickness, necrotic core volume and composition).

Redgrave *et al.* demonstrated on 526 symptomatic patients that IPH was associated with a previous stroke, transient ischemic attack (TIA) or amaurosis fugax (67). Another study showed that IPH is associated with cerebrovascular events risk (68) but only in men, which is a well-known cardiovascular risk factor. Few histological studies demonstrate the importance of identifying carotid IPHs on stroke prognosis. A significant study (n=818) by Hellings *et al.* on symptomatic and asymptomatic stroke

patients who underwent CEA (25) found that IPH was present in 69.9% of asymptomatic plaques and 76.3% of symptomatic plaques. Moreover, IPH increases the risk of cardiovascular events from 17.2% to 30.6% on a 3-year period [HR =1.7 (1.2; 2.5)] independent of perioperative events. IPH were also associated with primary outcomes (vascular death, nonfatal stroke, non-fatal myocardial infarction and vascular intervention), stroke and non-stroke vascular events, underlying an overall risk of cardio-vascular events. Other plaque features were not associated with any cardiovascular event thus IPH presence could improve global health care.

Consequently, imaging methods which are able to visualise neo-vessels and IPH should lead to a better understanding of the vulnerable plaque evolution. The challenge of current research is to be able to diagnose *in vivo* IPH that may cause ischemic events before they happened, in order to improve CEA decision.

Correlation between MRI assessed IPH and clinical events

As previously stated, IPH is an evolving process. The different stages of IPH are unequally involved in plaque vulnerability affecting the subsequent ischemic risk (70). Currently, no imaging technique is precise enough to discriminate Derksen's IPH stages. As blood components break down over time, they have a different chemical composition and magnetic properties (109) thus MRI might be able to identify Derksen's IPH stages (70). However, IPH assessed by MRI (MRI-IPH) appears to be a promising tool to predict cerebral ischemic events as stroke, TIA or amaurosis fugax.

Retrospective studies

Several studies have shown that MRI-IPH is an important tool to assess the plaque risk of rupture in symptomatic patients (119). Retrospective studies have established a positive relationship between unstable plaques detected by MRI and the latest neurological symptoms (120). MRI-IPH was also correlated with prior cardiovascular events (29) independent of stenosis degree, age, sex, hypertension, and smoking habit (107). Singh *et al.* [2013] performed a multivariable analysis and demonstrated that MRI-IPH was associated with the composite cardiovascular event (i.e. angioplasty, stenting or bypass graft) (OR =3.26; 1.14–9.37, P=0.028) (107). A recent study suggests that IPH detected by MPRAGE is a strong indicator of acute focal cerebral infarction (121), moreover IPH increased the risk of acute

cerebral ischemic event from 22% to 47% (122). In another study, recent MRI-IPH was associated with ipsilateral stroke and TIA but only for symptomatic patients. This same study concluded that other risks of plaque rupture might be taken into account to predict ipsilateral stroke (15), while another study showed that IPH was associated with stroke (123). Symptomatic patients had a higher prevalence of cerebrovascular events recurrence (107) and an increased risk of subsequent cardiovascular event (117,119). In two studies, all patients with an MRI T1 hyperintense signal had a greater recurrence risk for ischemic ipsilateral events (117,124), as IPH is a risk factor for further carotid IPH (116).

Prospective studies

As some links between cardiovascular, cerebrovascular and IPH were suggested by retrospective studies (29), prospective studies were conducted. MRI appears to be an interesting tool to assess IPH in asymptomatic patients (16). According to Saam *et al.*, the presence of IPH increases the risk of cerebrovascular events 5.69 times, with an annualised event rate of 17.7 % with IPH and 2.4% without IPH (99). Moreover, carotid plaques containing IPH and a ruptured fibrous cap are highly prone to develop ischemic events (99). Thus, this study showed that IPH diagnosed by MRI is a better predictor of stroke than stenosis (99). Other studies showed that IPH, in association with other rupture risk factors (thin fibrous cap, lipid-rich necrotic core), predicts subsequent cerebrovascular events (16) and ischemic events (stroke or TIA) (101). Symptomatic and asymptomatic patients (101,116,125,126) with carotid MRI-IPH, had an increased risk of subsequent cardiovascular events.

As MRI-IPH appears to predict future cerebrovascular ischemic events (68) and is highly discriminative from other plaque components such as necrotic core, macrophages inflammation and fibrous cap (115,127), it could become a valuable target to identify vulnerable carotid atherosclerotic plaques, but it is necessary to standardise the sequences and validate this technique in both genders in order to establish a strong correlation for all populations (68).

Conclusions

Embolism of vulnerable carotid atherosclerotic plaques is a frequent cause of ischemic stroke. Prevention for carotid plaques to become vulnerable is challenging. *In vivo* tools to assess reliably the factors of carotid plaque evolution are required. It has been demonstrated that IPH is a good predictor of plaque vulnerability and stroke incidence.

Several techniques have been developed to assess IPH such as Doppler ultrasonography and CT. Nevertheless, MRI appears to be the most effective way to assess IPH *in vivo* with reduced risk for the patient. Although MRI may currently be the best way to determine IPH stage, new sequences are required to improve its sensitivity before implementation in clinical practice. Reducing the examination duration, increasing the specificity of the diagnostic alone or in association with other MRI markers of plaque vulnerability could be additional challenges. It also might be relevant to compare *in vivo* imaging analysis to serum biomarkers (128) to better assess vulnerability of the carotid atherosclerotic plaque. A large-scale cohort study is required to validate the MRI sequences used to diagnose *in vivo* IPH as a predictor of cerebral ischemic events.

Acknowledgments

Funding: None.

Footnote

Provenance and Peer Review: This article was commissioned by the Guest Editor (Dr. Kosmas I. Paraskevas) for the series “Carotid Artery Stenosis and Stroke: Prevention and Treatment Part I” published in *Annals of Translational Medicine*. The article was sent for external peer review organized by the Guest Editor and the editorial office.

Conflicts of Interest: All authors have completed the ICMJE uniform disclosure form (available at <http://dx.doi.org/10.21037/atm-20-1974>). The series “Carotid Artery Stenosis and Stroke: Prevention and Treatment Part I” was commissioned by the editorial office without any funding or sponsorship. The authors have no other conflicts of interest to declare.

Ethical Statement: The authors are accountable for all aspects of the work in ensuring that questions related to the accuracy or integrity of any part of the work are appropriately investigated and resolved.

Open Access Statement: This is an Open Access article distributed in accordance with the Creative Commons Attribution-NonCommercial-NoDerivs 4.0 International License (CC BY-NC-ND 4.0), which permits the non-commercial replication and distribution of the article with

the strict proviso that no changes or edits are made and the original work is properly cited (including links to both the formal publication through the relevant DOI and the license). See: <https://creativecommons.org/licenses/by-nc-nd/4.0/>.

References

1. Benjamin EJ, Blaha MJ, Chiuve SE, et al. Heart Disease and Stroke Statistics—2017 Update: A Report From the American Heart Association. *Circulation* 2017;135:e146-603.
2. Wong KS, Caplan LR, Kim JS. Stroke Mechanisms. *Front Neurol Neurosci* 2016;40:58-71.
3. Naylor AR. Time to rethink management strategies in asymptomatic carotid artery disease. *Nat Rev Cardiol* 2011;9:116-24.
4. Eckstein HH. European Society for Vascular Surgery Guidelines on the Management of Atherosclerotic Carotid and Vertebral Artery Disease. *Eur J Vasc Endovasc Surg* 2018;55:1-2.
5. Moore DJ, Miles RD, Gooley NA, et al. Noninvasive assessment of stroke risk in asymptomatic and nonhemispheric patients with suspected carotid disease. Five-year follow-up of 294 unoperated and 81 operated patients. *Ann Surg* 1985;202:491-504.
6. Abbott AL, Paraskevas KI, Kakkos SK, et al. Systematic Review of Guidelines for the Management of Asymptomatic and Symptomatic Carotid Stenosis. *Stroke* 2015;46:3288-301.
7. Endarterectomy for asymptomatic carotid artery stenosis. Executive Committee for the Asymptomatic Carotid Atherosclerosis Study. *JAMA* 1995;273:1421-8.
8. Halliday A, Mansfield A, Marro J, et al. Prevention of disabling and fatal strokes by successful carotid endarterectomy in patients without recent neurological symptoms: randomised controlled trial. *Lancet* 2004;363:1491-502.
9. Rothwell PM, Gibson R, Warlow CP. Interrelation between plaque surface morphology and degree of stenosis on carotid angiograms and the risk of ischemic stroke in patients with symptomatic carotid stenosis. On behalf of the European Carotid Surgery Trialists' Collaborative Group. *Stroke* 2000;31:615-21.
10. Barnett HJM, Meldrum HE, Eliasziw M, North American Symptomatic Carotid Endarterectomy Trial (NASCET) collaborators. The appropriate use of carotid endarterectomy. *CMAJ* 2002;166:1169-79.
11. Halliday A, Harrison M, Hayter E, et al 10-year stroke prevention after successful carotid endarterectomy

- for asymptomatic stenosis (ACST-1): a multicentre randomised trial. *Lancet* 2010;376:1074-84.
12. Naylor AR, Schroeder TV, Sillesen H. Clinical and imaging features associated with an increased risk of late stroke in patients with asymptomatic carotid disease. *Eur J Vasc Endovasc Surg* 2014;48:633-40.
 13. Raghavan P, Mukherjee S, Gaughen J, et al. Magnetic resonance angiography of the extracranial carotid system. *Top Magn Reson Imaging* 2008;19:241-9.
 14. Zhu C, Tian X, Degnan AJ, et al. Clinical Significance of Intraplaque Hemorrhage in Low- and High-Grade Basilar Artery Stenosis on High-Resolution MRI. *AJNR Am J Neuroradiol* 2018;39:1286-92.
 15. Turc G, Oppenheim C, Naggara O, et al. Relationships between recent intraplaque hemorrhage and stroke risk factors in patients with carotid stenosis: the HIRISC study. *Arterioscler Thromb Vasc Biol* 2012;32:492-9.
 16. Takaya N, Yuan C, Chu B, et al. Association between carotid plaque characteristics and subsequent ischemic cerebrovascular events: a prospective assessment with MRI--initial results. *Stroke* 2006;37:818-23.
 17. Yu JH, Kwak HS, Chung GH, et al. Association of Intraplaque Hemorrhage and Acute Infarction in Patients With Basilar Artery Plaque. *Stroke* 2015;46:2768-72.
 18. Aboyans V, Ricco JB, Bartelink MEL, et al. Editor's Choice - 2017 ESC Guidelines on the Diagnosis and Treatment of Peripheral Arterial Diseases, in collaboration with the European Society for Vascular Surgery (ESVS). *Eur J Vasc Endovasc Surg* 2018;55:305-68.
 19. Chistiakov DA, Orekhov AN, Bobryshev YV. Contribution of neovascularization and intraplaque haemorrhage to atherosclerotic plaque progression and instability. *Acta Physiol (Oxf)* 2015;213:539-53.
 20. Virmani R, Kolodgie FD, Burke AP, et al. Atherosclerotic plaque progression and vulnerability to rupture: angiogenesis as a source of intraplaque hemorrhage. *Arterioscler Thromb Vasc Biol* 2005;25:2054-61.
 21. Sluimer JC, Kolodgie FD, Bijnens AP, et al. Thin-walled microvessels in human coronary atherosclerotic plaques show incomplete endothelial junctions relevance of compromised structural integrity for intraplaque microvascular leakage. *J Am Coll Cardiol* 2009;53:1517-27.
 22. Mughal MM, Khan MK, DeMarco JK, et al. Symptomatic and asymptomatic carotid artery plaque. *Expert Rev Cardiovasc Ther* 2011;9:1315-30.
 23. Brennan ML, Hazen SL. Emerging role of myeloperoxidase and oxidant stress markers in cardiovascular risk assessment. *Curr Opin Lipidol* 2003;14:353.
 24. Michel JB, Martin-Ventura JL, Nicoletti A, et al. Pathology of human plaque vulnerability: mechanisms and consequences of intraplaque haemorrhages. *Atherosclerosis* 2014;234:311-9.
 25. Hellings WE, Peeters W, Moll FL, et al. Composition of carotid atherosclerotic plaque is associated with cardiovascular outcome: a prognostic study. *Circulation* 2010;121:1941-50.
 26. Michel JB, Virmani R, Arbustini E, et al. Intraplaque haemorrhages as the trigger of plaque vulnerability. *Eur Heart J* 2011;32:1977-85, 1985a, 1985b, 1985c.
 27. Fryer JA, Myers PC, Appleberg M. Carotid intraplaque hemorrhage: The significance of neovascularity. *J Vasc Surg* 1987;6:341-9.
 28. Imparato AM, Riles TS, Mintzer R, et al. The Importance of Hemorrhage in the Relationship Between Gross Morphologic Characteristics and Cerebral Symptoms in 376 Carotid Artery Plaques. *Ann Surg* 1983;197:195-203.
 29. Millon A, Mathevet JL, Bousset L, et al. High-resolution magnetic resonance imaging of carotid atherosclerosis identifies vulnerable carotid plaques. *J Vasc Surg* 2013;57:1046-1051.e2.
 30. Gao P, Chen Z, Bao Y, et al. Correlation between carotid intraplaque hemorrhage and clinical symptoms: systematic review of observational studies. *Stroke* 2007;38:2382-90.
 31. Koutouzis M, Nomikos A, Nikolidakis S, et al. Statin treated patients have reduced intraplaque angiogenesis in carotid endarterectomy specimens. *Atherosclerosis* 2007;192:457-63.
 32. Derksen WJM, Peeters W, Tersteeg C, et al. Age and coumarin-type anticoagulation are associated with the occurrence of intraplaque hemorrhage, while statins are associated less with intraplaque hemorrhage: a large histopathological study in carotid and femoral plaques. *Atherosclerosis* 2011;214:139-43.
 33. McCarthy MJ, Loftus IM, Thompson MM, et al. Angiogenesis and the atherosclerotic carotid plaque: an association between symptomatology and plaque morphology. *J Vasc Surg* 1999;30:261-8.
 34. Sluimer JC, Gasc JM, van Wanroij JL, et al. Hypoxia, hypoxia-inducible transcription factor, and macrophages in human atherosclerotic plaques are correlated with intraplaque angiogenesis. *J Am Coll Cardiol* 2008;51:1258-65.
 35. Teng Z, He J, Degnan AJ, et al. Critical mechanical conditions around neovessels in carotid atherosclerotic plaque may promote intraplaque hemorrhage.

- Atherosclerosis 2012;223:321-6.
36. Lu J, Duan W, Qiao A. Finite element analysis of mechanics of neovessels with intraplaque hemorrhage in carotid atherosclerosis. *Biomed Eng Online* 2015;14 Suppl 1:S3
 37. Altaf N, Akwei S, Auer DP, et al. Magnetic resonance detected carotid plaque hemorrhage is associated with inflammatory features in symptomatic carotid plaques. *Ann Vasc Surg* 2013;27:655-61.
 38. Björkerud S, Björkerud B. Apoptosis is abundant in human atherosclerotic lesions, especially in inflammatory cells (macrophages and T cells), and may contribute to the accumulation of gruel and plaque instability. *Am J Pathol* 1996;149:367-80.
 39. Altaf N, Daniels L, Morgan PS, et al. Detection of intraplaque hemorrhage by magnetic resonance imaging in symptomatic patients with mild to moderate carotid stenosis predicts recurrent neurological events. *J Vasc Surg* 2008;47:337-42.
 40. Montezano AC, Touyz RM. Oxidative stress, Nox, and hypertension: experimental evidence and clinical controversies. *Ann Med* 2012;44 Suppl 1:S2-16.
 41. Benelli R, Albin A, Noonan D. Neutrophils and Angiogenesis: Potential Initiators of the Angiogenic Cascade. *Chem Immunol Allergy* 2003;83:167-81.
 42. Campbell EL. Hypoxia-recruited angiogenic neutrophils. *Blood* 2015;126:1972-3.
 43. Ogata A, Kawashima M, Wakamiya T, et al. Carotid artery stenosis with a high-intensity signal plaque on time-of-flight magnetic resonance angiography and association with evidence of intraplaque hypoxia. *J Neurosurg* 2017;126:1873-8.
 44. Vita JA, Brennan ML, Gokce N, et al. Serum Myeloperoxidase Levels Independently Predict Endothelial Dysfunction in Humans. *Circulation* 2004;110:1134-9.
 45. Tian R, Ding Y, Peng YY, et al. Myeloperoxidase amplified high glucose-induced endothelial dysfunction in vasculature: Role of NADPH oxidase and hypochlorous acid. *Biochem Biophys Res Commun* 2017;484:572-8.
 46. Saffarzadeh M, Juenemann C, Queisser MA, et al. Neutrophil extracellular traps directly induce epithelial and endothelial cell death: a predominant role of histones. *PLoS One* 2012;7:e32366.
 47. Yeagle PL. Cholesterol and the cell membrane. *Biochim Biophys Acta* 1985;822:267-87.
 48. Haskard DO, Boyle JJ, Evans PC, et al. Cytoprotective signaling and gene expression in endothelial cells and macrophages-lessons for atherosclerosis. *Microcirculation* 2013;20:203-16.
 49. Thrysoe SA, Oikawa M, Yuan C, et al. Longitudinal Distribution of Mechanical Stresses in Carotid Plaques of Symptomatic Patients. *Stroke* 2010;41:1041-3.
 50. Jeziorska M, Woolley DE. Local neovascularization and cellular composition within vulnerable regions of atherosclerotic plaques of human carotid arteries. *J Pathol* 1999;188:189-96.
 51. Abela GS, Aziz K. Cholesterol crystals rupture biological membranes and human plaques during acute cardiovascular events--a novel insight into plaque rupture by scanning electron microscopy. *Scanning* 2006;28:1-10.
 52. Abela GS, Aziz K, Vedre A, et al. Effect of Cholesterol Crystals on Plaques and Intima in Arteries of Patients With Acute Coronary and Cerebrovascular Syndromes. *Am J Cardiol* 2009;103:959-68.
 53. Duguid JB. The Thrombogenic Hypothesis and its Implications. *Postgrad Med J* 1960;36:226-9.
 54. Daemen MJ, Fergusson MS, Gijzen FJ, et al. Carotid plaque fissure: An underestimated source of intraplaque hemorrhage. *Atherosclerosis* 2016;254:102-8.
 55. Chen Y, Yu Q, Xu CB. A convenient method for quantifying collagen fibers in atherosclerotic lesions by ImageJ software. *Int J Clin Exp Med* 2017;10:14904-10.
 56. Burt RC. The incidence of acid-fast pigment (ceroid) in aortic atherosclerosis. *Am J Clin Pathol* 1952;22:135-9.
 57. Mitchinson MJ, Hothersall DC, Brooks PN, et al. The distribution of ceroid in human atherosclerosis. *J Pathol* 1985;145:177-83.
 58. Leclercq A, Houard X, Philippe M, et al. Involvement of intraplaque hemorrhage in atherothrombosis evolution via neutrophil protease enrichment. *J Leukoc Biol* 2007;82:1420-9.
 59. Post S, Peeters W, Busser E, et al. Balance between angiotensin-1 and angiotensin-2 is in favor of angiotensin-2 in atherosclerotic plaques with high microvessel density. *J Vasc Res* 2008;45:244-50.
 60. Moreno PR, Purushothaman KR, Sirol M, et al. Neovascularization in human atherosclerosis. *Circulation* 2006;113:2245-52
 61. Au-Yeung KK, Woo CW, Sung FL, et al. Hyperhomocysteinemia Activates Nuclear Factor-kappaB in Endothelial Cells via Oxidative Stress. *Circ Res* 2004;94:28-36.
 62. Stary HC, Chandler AB, Dinsmore RE, et al. A definition of advanced types of atherosclerotic lesions and a histological classification of atherosclerosis. A report from the Committee on Vascular Lesions of the Council on

- Arteriosclerosis, American Heart Association. *Arterioscler Thromb Vasc Biol* 1995;15:1512-31.
63. Stary HC, Chandler AB, Glagov S, et al. A definition of initial, fatty streak, and intermediate lesions of atherosclerosis. A report from the Committee on Vascular Lesions of the Council on Arteriosclerosis, American Heart Association. *Circulation* 1994;89:2462-78.
 64. Lovett JK, Gallagher PJ, Hands LJ, et al. Histological Correlates of Carotid Plaque Surface Morphology on Lumen Contrast Imaging. *Circulation* 2004;110:2190-7.
 65. Kolodgie FD, Petrov A, Virmani R, et al. Targeting of apoptotic macrophages and experimental atheroma with radiolabeled annexin V: a technique with potential for noninvasive imaging of vulnerable plaque. *Circulation* 2003;108:3134-9.
 66. Pelisek J, Well G, Reeps C, et al. Neovascularization and angiogenic factors in advanced human carotid artery stenosis. *Circ J* 2012;76:1274-82.
 67. Redgrave JNE, Lovett JK, Gallagher PJ, et al. Histological assessment of 526 symptomatic carotid plaques in relation to the nature and timing of ischemic symptoms: the Oxford plaque study. *Circulation* 2006;113:2320-8.
 68. Vrijenhoek JEP, Den Ruijter HM, De Borst GJ, et al. Sex is associated with the presence of atherosclerotic plaque hemorrhage and modifies the relation between plaque hemorrhage and cardiovascular outcome. *Stroke* 2013;44:3318-23.
 69. Howard DPJ, van Lammeren GW, Rothwell PM, et al. Symptomatic carotid atherosclerotic disease: correlations between plaque composition and ipsilateral stroke risk. *Stroke* 2015;46:182-9.
 70. Derksen WJM, Peeters W, van Lammeren GW, et al. Different stages of intraplaque hemorrhage are associated with different plaque phenotypes: a large histopathological study in 794 carotid and 276 femoral endarterectomy specimens. *Atherosclerosis* 2011;218:369-77.
 71. Lennihan L, Kupsky WJ, Mohr JP, et al. Lack of association between carotid plaque hematoma and ischemic cerebral symptoms. *Stroke* 1987;18:879-81.
 72. Lusby RJ, Ferrell LD, Ehrenfeld WK, et al. Carotid plaque hemorrhage. Its role in production of cerebral ischemia. *Arch Surg* 1982;117:1479-88.
 73. Shah PK. Mechanisms of plaque vulnerability and rupture. *J Am Coll Cardiol* 2003;41:15S-22S.
 74. Libby P, Ridker PM, Hansson GK. Progress and challenges in translating the biology of atherosclerosis. *Nature* 2011;473:317-25.
 75. Grant EG, Benson CB, Moneta GL, et al. Carotid artery stenosis: gray-scale and Doppler US diagnosis--Society of Radiologists in Ultrasound Consensus Conference. *Radiology* 2003;229:340-6.
 76. Ricco JB, Gauthier JB, Richer JP, et al. The evolution of carotid and coronary artery disease after operation for carotid stenosis. *Ann Vasc Surg* 1992;6:408-12.
 77. den Hartog AG, Bovens SM, Koning W, et al. Current status of clinical magnetic resonance imaging for plaque characterisation in patients with carotid artery stenosis. *Eur J Vasc Endovasc Surg* 2013;45:7-21.
 78. Saba L, Anzidei M, Marincola BC, et al. Imaging of the carotid artery vulnerable plaque. *Cardiovasc Intervent Radiol* 2014;37:572-85.
 79. Grønholdt ML, Wiebe BM, Laursen H et al. Lipid-rich carotid artery plaques appear echolucent on ultrasound B-mode images and may be associated with intraplaque haemorrhage. *Eur J Vasc Endovasc Surg* 1997;14:439-45.
 80. Coli S, Magnoni M, Sangiorgi G, et al. Contrast-enhanced ultrasound imaging of intraplaque neovascularization in carotid arteries: correlation with histology and plaque echogenicity. *J Am Coll Cardiol* 2008;52:223-30.
 81. Schmidt C, Fischer T, Rückert R-I, et al. Identification of neovascularization by contrast-enhanced ultrasound to detect unstable carotid stenosis. *PLoS One* 2017;12:e0175331.
 82. Feinstein SB. Contrast Ultrasound Imaging of the Carotid Artery Vasa Vasorum and Atherosclerotic Plaque Neovascularization. *J Am Coll Cardiol* 2006;48:236-43.
 83. Moguillansky D, Leng X, Carson A, et al. Quantification of plaque neovascularization using contrast ultrasound: a histologic validation. *Eur Heart J* 2011;32:646-53.
 84. Bluth EI, Kay D, Merritt CR, et al. Sonographic characterization of carotid plaque: detection of hemorrhage. *AJR Am J Roentgenol* 1986;146:1061-5.
 85. Korn A, Bender B, Thomas C, et al. Dual energy CTA of the carotid bifurcation: advantage of plaque subtraction for assessment of grade of the stenosis and morphology. *Eur J Radiol* 2011;80:e120-125.
 86. Postma AA, Das M, Stadler AAR, et al. Dual-Energy CT: What the Neuroradiologist Should Know. *Curr Radiol Rep* 2015;3:16.
 87. Prati F, Pawlowski T, Sommariva L, et al. Intravascular ultrasound and quantitative coronary angiography assessment of late in-stent restenosis: in vivo human correlation and methodological implications. *Catheter Cardiovasc Interv* 2002;57:155-60.
 88. Saba L, Francone M, Bassareo PP, et al. CT Attenuation Analysis of Carotid Intraplaque Hemorrhage. *AJNR Am J*

- Neuroradiol 2018;39:131-7.
89. U-King-Im JM, Fox AJ, Aviv RI, et al. Characterization of carotid plaque hemorrhage: a CT angiography and MR intraplaque hemorrhage study. *Stroke* 2010;41:1623-9.
 90. Wintermark M, Jawadi SS, Rapp JH, et al. High-resolution CT imaging of carotid artery atherosclerotic plaques. *AJNR Am J Neuroradiol* 2008;29:875-82.
 91. Eisenmenger LB, Aldred BW, Kim SE, et al. Prediction of Carotid Intraplaque Hemorrhage Using Adventitial Calcification and Plaque Thickness on CTA. *AJNR Am J Neuroradiol* 2016;37:1496-503.
 92. Eesa M, Hill MD, Al-Khathaami A, et al. Role of CT angiographic plaque morphologic characteristics in addition to stenosis in predicting the symptomatic side in carotid artery disease. *AJNR Am J Neuroradiol* 2010;31:1254-60.
 93. Rudd JHF, Myers KS, Bansilal S, et al. Atherosclerosis inflammation imaging with 18F-FDG PET: carotid, iliac, and femoral uptake reproducibility, quantification methods, and recommendations. *J Nucl Med* 2008;49:871-8.
 94. Menezes LJ, Kotze CW, Agu O, et al. Investigating vulnerable atheroma using combined (18)F-FDG PET/CT angiography of carotid plaque with immunohistochemical validation. *J Nucl Med* 2011;52:1698-703.
 95. Calcagno C, Cornily JC, Hyafil F, et al. Detection of neovessels in atherosclerotic plaques of rabbits using dynamic contrast enhanced MRI and 18F-FDG PET. *Arterioscler Thromb Vasc Biol* 2008;28:1311-7.
 96. Kwee RM, Teule GJ, van Oostenbrugge RJ, et al. Multimodality Imaging of Carotid Artery Plaques: 18F-fluoro-2-deoxyglucose Positron Emission Tomography, Computed Tomography, and Magnetic Resonance Imaging. *Stroke* 2009;40:3718-24.
 97. Izquierdo-Garcia D, Davies JR, Graves MJ, et al. Comparison of Methods for Magnetic Resonance-Guided [18-F]Fluorodeoxyglucose Positron Emission Tomography in Human Carotid Arteries: Reproducibility, Partial Volume Correction, and Correlation Between Methods. *Stroke* 2009;40:86-93.
 98. Mechtouff L, Sigovan M, Costes N, et al. 18 F-NaF PET-MRI: an innovative tool to assess carotid artery plaque vulnerability. *Eur J Neurol* 2018;25:e18-9.
 99. Saam T, Hetterich H, Hoffmann V, et al. Meta-analysis and systematic review of the predictive value of carotid plaque hemorrhage on cerebrovascular events by magnetic resonance imaging. *J Am Coll Cardiol* 2013;62:1081-91.
 100. Qiao Y, Etesami M, Malhotra S, et al. Identification of intraplaque hemorrhage on MR angiography images: a comparison of contrast-enhanced mask and time-of-flight techniques. *AJNR Am J Neuroradiol* 2011;32:454-9.
 101. Gupta A, Baradaran H, Schweitzer AD, et al. Carotid plaque MRI and stroke risk: a systematic review and meta-analysis. *Stroke* 2013;44:3071-7.
 102. Gupta A, Baradaran H, Kamel H, et al. Intraplaque high-intensity signal on 3D time-of-flight MR angiography is strongly associated with symptomatic carotid artery stenosis. *AJNR Am J Neuroradiol* 2014;35:557-61.
 103. Moody AR, Murphy RE, Morgan PS, et al. Characterization of complicated carotid plaque with magnetic resonance direct thrombus imaging in patients with cerebral ischemia. *Circulation* 2003;107:3047-52.
 104. Hishikawa T, Iihara K, Yamada N, et al. Assessment of necrotic core with intraplaque hemorrhage in atherosclerotic carotid artery plaque by MR imaging with 3D gradient-echo sequence in patients with high-grade stenosis. *Clinical article. J Neurosurg* 2010;113:890-6.
 105. Sigovan M, Bidet C, Bros S, et al. 3D black blood MR angiography of the carotid arteries. A simple sequence for plaque hemorrhage and stenosis evaluation. *Magn Reson Imaging* 2017;42:95-100.
 106. Wang J, Börnert P, Zhao H, et al. Simultaneous noncontrast angiography and intraplaque hemorrhage (SNAP) imaging for carotid atherosclerotic disease evaluation. *Magn Reson Med* 2013;69:337-45.
 107. Singh N, Moody AR, Rochon-Terry G, et al. Identifying a high risk cardiovascular phenotype by carotid MRI-depicted intraplaque hemorrhage. *Int J Cardiovasc Imaging* 2013;29:1477-83.
 108. Zhu DC, Vu AT, Ota H, et al. An optimized 3D spoiled gradient recalled echo pulse sequence for hemorrhage assessment using inversion recovery and multiple echoes (3D SHINE) for carotid plaque imaging. *Magn Reson Med* 2010;64:1341-51.
 109. Chu B, Kampschulte A, Ferguson MS, et al. Hemorrhage in the atherosclerotic carotid plaque: a high-resolution MRI study. *Stroke* 2004;35:1079-84.
 110. Ota H, Yarnykh VL, Ferguson MS, et al. Carotid Intraplaque Hemorrhage Imaging at 3.0-T MR Imaging: Comparison of the Diagnostic Performance of Three T1-weighted Sequences. *Radiology* 2010;254:551-63.
 111. Kerwin W, Hooker A, Spilker M, et al. Quantitative magnetic resonance imaging analysis of neovasculature volume in carotid atherosclerotic plaque. *Circulation* 2003;107:851-6.
 112. Cai J, Hatsukami TS, Ferguson MS, et al. In Vivo

- Quantitative Measurement of Intact Fibrous Cap and Lipid-Rich Necrotic Core Size in Atherosclerotic Carotid Plaque: Comparison of High-Resolution, Contrast-Enhanced Magnetic Resonance Imaging and Histology. *Circulation* 2005;112:3437-44.
113. Tang T, Howarth SPS, Miller SR, et al. Assessment of inflammatory burden contralateral to the symptomatic carotid stenosis using high-resolution ultrasmall, superparamagnetic iron oxide-enhanced MRI. *Stroke* 2006;37:2266-70.
 114. Millon A, Boussel L, Brevet M, et al. Clinical and histological significance of gadolinium enhancement in carotid atherosclerotic plaque. *Stroke* 2012;43:3023-8.
 115. Puppini G, Furlan F, Cirotta N, et al. Characterisation of carotid atherosclerotic plaque: comparison between magnetic resonance imaging and histology. *Radiol Med* 2006;111:921-30.
 116. Takaya N, Yuan C, Chu B, et al. Presence of intraplaque hemorrhage stimulates progression of carotid atherosclerotic plaques: a high-resolution magnetic resonance imaging study. *Circulation* 2005;111:2768-75.
 117. Wang X, Sun J, Zhao X, et al. Ipsilateral plaques display higher T1 signals than contralateral plaques in recently symptomatic patients with bilateral carotid intraplaque hemorrhage. *Atherosclerosis* 2017;257:78-85.
 118. Lovett JK, Gallagher PJ, Rothwell PM. Reproducibility of histological assessment of carotid plaque: implications for studies of carotid imaging. *Cerebrovasc Dis* 2004;18:117-23.
 119. Altaf N, MacSweeney ST, Gladman J, et al. Carotid intraplaque hemorrhage predicts recurrent symptoms in patients with high-grade carotid stenosis. *Stroke* 2007;38:1633-5.
 120. Demarco JK, Ota H, Underhill HR, et al. MR Carotid Plaque Imaging and Contrast-Enhanced MR Angiography Identifies Lesions Associated with Recent Ipsilateral Thromboembolic Symptoms: An In Vivo Study at 3T. *AJNR Am J Neuroradiol* 2010;31:1395-402.
 121. Kim S, Kwak HS, Chung GH. Carotid intraplaque hemorrhage in patients with greater than fifty percent carotid stenosis was associated an acute focal cerebral infarction. *Neurol Asia* 2018;23:209-21.
 122. Ryu HJ, Jeon SJ, Choi SS. Carotid Intraplaque Hemorrhage is Associated with Acute Cerebral Ischemic Events and Progression of Stenosis on Magnetic Resonance Imaging. *Investig Magn Reson Imaging* 2017;21:242-51.
 123. Selwaness M, Bos D, van den Bouwhuijsen Q, et al. Carotid Atherosclerotic Plaque Characteristics on Magnetic Resonance Imaging Relate With History of Stroke and Coronary Heart Disease. *Stroke* 2016;47:1542-7.
 124. Yamada K, Yoshimura S, Kawasaki M, et al. Preoperative magnetic resonance plaque imaging and carotid artery stenting: a review. *Interv Neurol* 2012;1:31-8.
 125. Kurosaki Y, Yoshida K, Fukuda H, et al. Asymptomatic Carotid T1-High-Intense Plaque as a Risk Factor for a Subsequent Cerebrovascular Ischemic Event. *Cerebrovasc Dis* 2017;43:250-6.
 126. Hosseini AA, Kandiyil N, Macsweeney STS, et al. Carotid plaque hemorrhage on magnetic resonance imaging strongly predicts recurrent ischemia and stroke. *Ann Neurol* 2013;73:774-84.
 127. Yuan C, Mitsumori LM, Beach KW, et al. Carotid atherosclerotic plaque: noninvasive MR characterization and identification of vulnerable lesions. *Radiology* 2001;221:285-99.
 128. Matic LP, Iglesias MJ, Vesterlund M, et al. Novel Multiomics Profiling of Human Carotid Atherosclerotic Plaques and Plasma Reveals Biliverdin Reductase B as a Marker of Intraplaque Hemorrhage. *JACC Basic Transl Sci* 2018;3:464-80.

Cite this article as: Mura M, Della Schiava N, Long A, Chirico EN, Pialoux V, Millon A. Carotid intraplaque haemorrhage: pathogenesis, histological classification, imaging methods and clinical value. *Ann Transl Med* 2020;8(19):1273. doi: 10.21037/atm-20-1974