



# Images in Vascular Medicine: Vasa vasorum associated with endoleak after endovascular repair of abdominal aortic aneurysm

A. Fikani, P. Lermusiaux, N. Della Schiava, A. Millon

## ► To cite this version:

A. Fikani, P. Lermusiaux, N. Della Schiava, A. Millon. Images in Vascular Medicine: Vasa vasorum associated with endoleak after endovascular repair of abdominal aortic aneurysm. *Vascular Medicine*, 2020, 26 (1), pp.89-90. 10.1177/1358863x20963822 . inserm-03261164

**HAL Id: inserm-03261164**

**<https://inserm.hal.science/inserm-03261164>**

Submitted on 15 Jun 2021

**HAL** is a multi-disciplinary open access archive for the deposit and dissemination of scientific research documents, whether they are published or not. The documents may come from teaching and research institutions in France or abroad, or from public or private research centers.

L'archive ouverte pluridisciplinaire **HAL**, est destinée au dépôt et à la diffusion de documents scientifiques de niveau recherche, publiés ou non, émanant des établissements d'enseignement et de recherche français ou étrangers, des laboratoires publics ou privés.



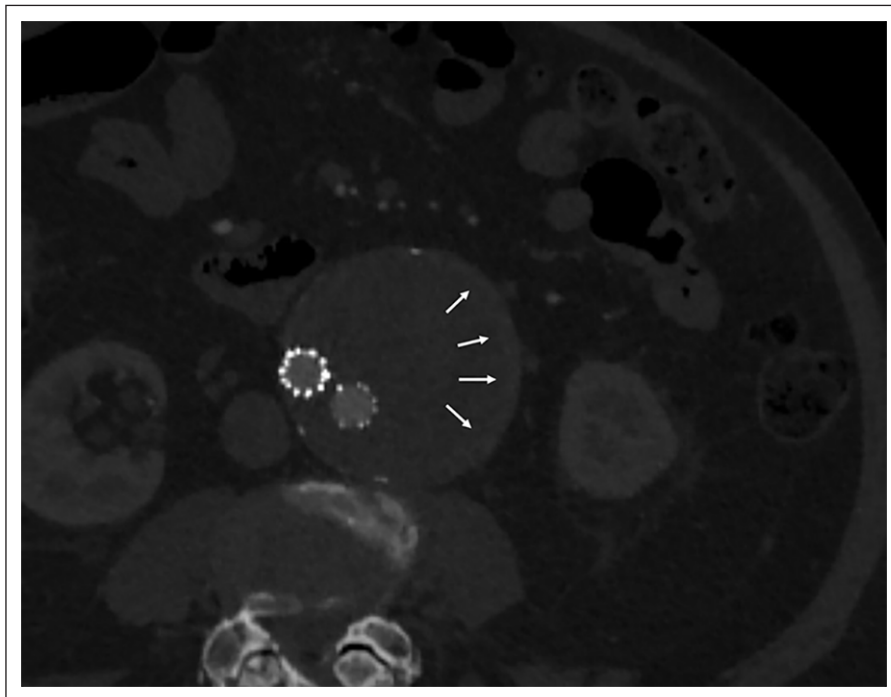
Distributed under a Creative Commons Attribution - NonCommercial 4.0 International License

# Images in Vascular Medicine: Vasa vasorum associated with endoleak after endovascular repair of abdominal aortic aneurysm

Vascular Medicine  
2021, Vol. 26(1) 89–90  
© The Author(s) 2020  
Article reuse guidelines:  
sagepub.com/journals-permissions  
DOI: 10.1177/1358863X20963822  
journals.sagepub.com/home/vmj



Amine Fikani<sup>1,2,3</sup> , Patrick Lermusiaux<sup>1,2</sup>, Nellie Della Schiava<sup>1,2</sup> and Antoine Millon<sup>1,2</sup>



**Panel A**

We present the case of an 84-year-old male patient with a history of endovascular aneurysm repair (EVAR) in 2009. During follow up, a proximal extension cuff and two iliac branch extensions were added for aneurysm progression without evidence of an endoleak.

He presented to our institution for continuous aneurysmal sac progression to reach a diameter of 8 cm. A computed tomography (CT) scan showed no endoleak in the arterial phase. Heterogeneous and patchy enhancement of the intrasaccular thrombus was visualized in the delayed phase (Panel A: arrows). Angiography was performed. A catheter was passed between the right iliac branch and the vessel wall and progressed into the aneurysm sac. Upon contrast injection, a pathway was created inside the thrombus (Panel B: white arrow) to reach a network of vasa vasorum on the aneurysm wall. These arteries (Panel B: black arrows) did not seem connected to any large branch artery.

Continuous enlargement of the aneurysmal sac after EVAR without evidence of an endoleak is poorly understood. It is described as a Type V endoleak.<sup>1,2</sup> Explanations include a low-flow endoleak below the detection threshold of imaging techniques. In our case, investigations led to the discovery of vasa vasorum in direct communication with the intrasaccular thrombus.

In many reports, development of vasa vasorum is thought to be the source of endoleaks.<sup>3</sup> The vasa vasorum forms an arterial plexus within an adventitial layer and

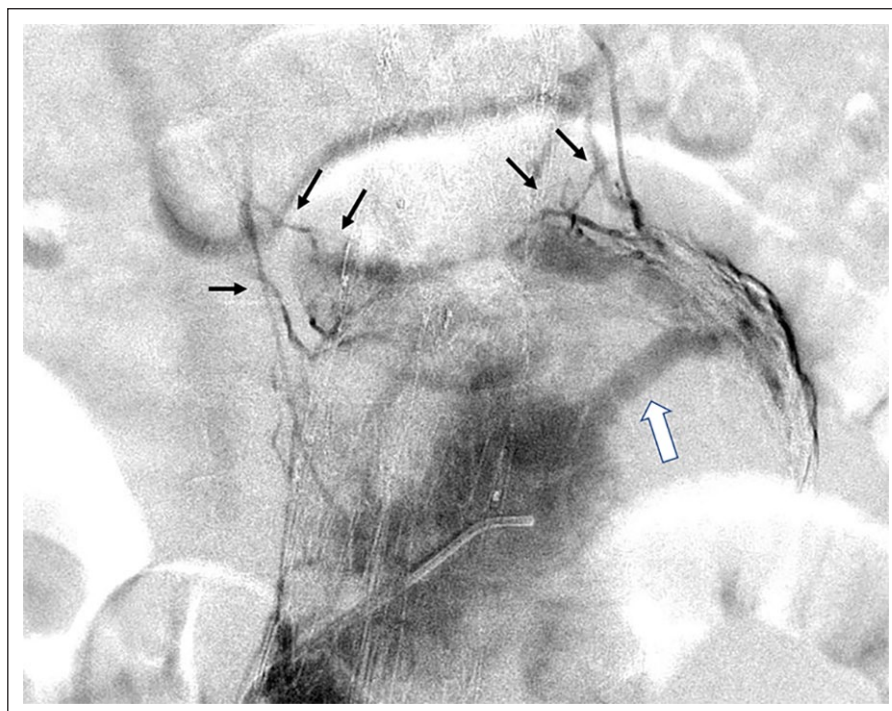
<sup>1</sup>Department of Vascular Surgery, Louis-Pradel Hospital, Lyon, France

<sup>2</sup>Claude Bernard University, Lyon, France

<sup>3</sup>Saint-Joseph University, Beirut, Lebanon

## Corresponding author:

Amine Fikani, Department of Vascular Surgery, Louis-Pradel Hospital, 59 Boulevard Pinel, 69677 Bron, France.  
Email: aminefikani@gmail.com



**Panel B**

originates from a large artery. Marked dilatation of the vasa vasorum within the aortic wall has been reported during exploration of the enlarged abdominal aortic aneurysm sac after EVAR<sup>4</sup> and in histological specimens of the aortic wall after the placement of a stent-graft in experimental studies.<sup>5</sup> Possible causes are the hypoxic environment in the aortic wall after EVAR<sup>5</sup> or an inflammatory process generated by the thrombus derived contents.<sup>4</sup>

Our case shows a direct communication between intrasacular thrombus and hypertrophied vasa vasorum, adding more proof to the possible association between development of vasa vasorum and sac progression in these patients without evidence of an endoleak on CT imaging.

#### Declaration of conflicting interests

The authors declared no potential conflicts of interest with respect to the research, authorship, and/or publication of this article.

#### Funding

The authors received no financial support for the research, authorship, and/or publication of this article.

#### ORCID iD

Amine Fikani  <https://orcid.org/0000-0003-4653-4924>

#### References

1. Moll FL, Powell JT, Fraedrich G, et al. Management of abdominal aortic aneurysms clinical practice guidelines of the European Society for Vascular Surgery. *Eur J Vasc Endovasc Surg* 2011; 41(Suppl 1): S1–S58.
2. Chaikof EL, Dalman RL, Eskandari MK, et al. The Society for Vascular Surgery practice guidelines on the care of patients with an abdominal aortic aneurysm. *J Vasc Surg* 2018; 67: 2–77.e2.
3. Torikai H, Inoue M, Nakatsuka S, et al. Imaging findings of atypical type ii endoleak through vasa vasorum after abdominal endovascular aneurysm repair. *Cardiovasc Intervent Radiol* 2018; 41: 186–190.
4. Mehta M, Darling RC 3rd, Chang BB, et al. Does sac size matter? Findings based on surgical exploration of excluded abdominal aortic aneurysms. *J Endovasc Ther* 2005; 12: 183–188.
5. Sanada JJ, Matsui O, Yoshikawa J, et al. An experimental study of endovascular stenting with special reference to the effects on the aortic vasa vasorum. *Cardiovasc Intervent Radiol* 1998; 21: 45–49.