



**HAL**  
open science

**Position paper on stress cardiac magnetic resonance imaging in chronic coronary syndrome: Endorsed by the Société française de radiologie (SFR), the Société française d'imagerie cardiovasculaire (SFICV) and the Société française de cardiologie (SFC)**

Florent Le Ven, Jean Nicolas Dacher, François Pontana, Gilles Barone-Rochette, Laurent Macron, Jerome Garot, Olivier Genée, Damien Mandry, Luc-Philippe Christiaens, Martine Gilard, et al.

► **To cite this version:**

Florent Le Ven, Jean Nicolas Dacher, François Pontana, Gilles Barone-Rochette, Laurent Macron, et al.. Position paper on stress cardiac magnetic resonance imaging in chronic coronary syndrome: Endorsed by the Société française de radiologie (SFR), the Société française d'imagerie cardiovasculaire (SFICV) and the Société française de cardiologie (SFC). Archives of cardiovascular diseases, 2021, S1875-2136 (21), pp.00062-0. 10.1016/j.acvd.2021.02.004 . inserm-03207180

**HAL Id: inserm-03207180**

**<https://inserm.hal.science/inserm-03207180>**

Submitted on 24 May 2023

**HAL** is a multi-disciplinary open access archive for the deposit and dissemination of scientific research documents, whether they are published or not. The documents may come from teaching and research institutions in France or abroad, or from public or private research centers.

L'archive ouverte pluridisciplinaire **HAL**, est destinée au dépôt et à la diffusion de documents scientifiques de niveau recherche, publiés ou non, émanant des établissements d'enseignement et de recherche français ou étrangers, des laboratoires publics ou privés.



Distributed under a Creative Commons Attribution - NonCommercial 4.0 International License

**Position paper on stress cardiac magnetic resonance imaging in chronic coronary syndrome: Endorsed by the Société Française de Radiologie (SFR), the Société Française d'Imagerie Cardiovasculaire (SFICV) and the Société Française de Cardiologie (SFC)**

**Abbreviated title:** Stress cardiac MRI in chronic coronary syndrome

**Tweet:**

**Florent Le Ven<sup>a,\*</sup>, Jean-Nicolas Dacher<sup>b</sup>, François Pontana<sup>c</sup>, Gilles Barone-Rochette<sup>d</sup>, Laurent Macron<sup>e</sup>, Jerome Garot<sup>f</sup>, Olivier Genée<sup>g</sup>, Damien Mandry<sup>h</sup>, Luc-Philippe Christiaens<sup>i</sup>, Martine Gilard<sup>j</sup>, Louis Boyer<sup>k</sup>, Alain Furber<sup>l</sup>, Alexis Jacquier<sup>m</sup>**

<sup>a</sup> *Department of Cardiology, Brest University Hospital, EA3878GETBO, Université de Bretagne Occidentale, 29609 Brest, France*

<sup>b</sup> *Normandy University, UNIROUEN, INSERM U1096, Department of Medical Imaging (Cardiac Imaging Unit), Rouen University Hospital, 76000 Rouen, France*

<sup>c</sup> *Université de Lille, U1011-EGID, 59045 Lille; INSERM U1011, 59019 Lille; Institut Pasteur de Lille, 59000 Lille; Department of Cardiovascular Radiology, CHU de Lille, 59000 Lille, France*

<sup>d</sup> *Department of Cardiology, CHU Grenoble Alpes, 38700 La Tronche; Radiopharmaceutiques Biocliniques, INSERM U1039, Grenoble Alpes University, 38700 La Tronche; French Alliance Clinical Trial, French Clinical Research Infrastructure Network, 75018 Paris, France*

<sup>e</sup> *Department of Imaging, Centre Cardiologique du Nord de Saint-Denis, 93200 Saint-Denis, France*

<sup>f</sup> *Cardiac MRI-Institut Cardiovasculaire Paris Sud, Jacques Cartier Private Hospital-Ramsay Health, 91300 Massy, France*

<sup>g</sup> *Pôle Santé Oréliance, Centre Cardiologique d'Orléans, 45770 Saran, France*

<sup>h</sup> *Lorraine University, IADI, INSERM U1254, 54000 Nancy; Department of Radiology, Brabois, CHRU Nancy, 54000 Nancy, France*

<sup>i</sup> *Department of Cardiology, CHU de Poitiers, 86021 Poitiers, France*

<sup>j</sup> *Department of Cardiology, Brest University Hospital, EA 4324 ORPHY, Université de Bretagne Occidentale, 29609 Brest, France*

<sup>k</sup> *Pôle Imagerie Diagnostique et Radiologie Interventionnelle, CHU Gabriel Montpied, 63000 Clermont-Ferrand, France*

<sup>l</sup> *Institut MITOVASC, UMR INSERM U1083 and CNRS 6015, Equipe Physiopathologie Cardiovasculaire, Service de Cardiologie, CHU d'Angers, Université d'Angers, 49000 Angers, France*

<sup>m</sup> *Aix-Marseille Université, Department of Radiology and Cardiovascular Imaging, Hôpital Timone, AP-HM,; CNRS, CRMBM (Centre de Résonance Magnétique Biologique et Médicale), 13385 Marseille, France*

\* Corresponding author at: Department of Cardiology, CHU de la Cavale Blanche, Bd Tanguy Prigent, 29609 Brest, France.

*E-mail address:* [florent.leven@chu-brest.fr](mailto:florent.leven@chu-brest.fr) (F. Le Ven).

*Twitter address:* @FlorentVen

## **Summary**

This paper is intended to update the former consensus between the French Societies of Radiology and Cardiology about the use of stress cardiac magnetic resonance imaging in chronic coronary syndrome, published in 2009. The Delphi method was used to build the present consensus. This expert panel consensus includes recommendations for indications, the procedure (with patient preparation), stress-inducing drugs, the acquisition protocol, interpretation and risk stratification by stress magnetic resonance imaging.

## **KEYWORDS**

Angina pectoris;

Myocardial ischaemia;

Stable coronary artery disease;

Cardiac imaging techniques

*Abbreviations:* CAD, coronary artery disease; CTA, computed tomography angiography; ESC, European Society of Cardiology; LGE, late gadolinium chelate enhancement; LV, left ventricle/ventricular; MRI, magnetic resonance imaging; PTP, pretest probability.

## **Background**

Cardiac magnetic resonance imaging (MRI) has become a key examination in routine clinical practice for assessing ventricular function, valvular regurgitation, extracellular volume and myocardial enhancement [1-3]. The goal of this opinion paper issued by a national expert committee from the French Society of Radiology (Société Française de Radiologie [SFR]) and the French Society of Cardiology (Société Française de Cardiologie [SFC]) is to define how stress cardiac MRI should be positioned in the management of patients suspected of having or known to have chronic coronary artery disease (CAD). This consensus includes recommendations for indications, the procedure (with patient preparation), stress-inducing drugs, the acquisition protocol, interpretation and risk stratification by stress MRI.

## **Indications for stress MRI in chronic coronary syndrome**

This section mainly refers to the 2019 European Society of Cardiology (ESC) guidelines for the diagnosis and management of chronic coronary syndromes [4]. Most common indications for stress MRI are summarized in [Table 1](#).

### **In symptomatic patients**

The preliminary stage in approaching the diagnosis of thoracic pain or dyspnoea is to determine the probability of obstructive CAD. Patient assessment should first and foremost be based on clinical questions about the patient's history and risk factors, details of the characteristics of chest pain and the presence of dyspnoea, electrocardiography, chest X-ray and echocardiography. The initial examination should also be used to consider any possible differential diagnoses and to research functional angina (anaemia, hyperthyroidism, severe blood hypertension with left ventricular [LV] hypertrophy, valve disease and, in particular, aortic stenosis and hypertrophic cardiomyopathy or the possibility of rhythm disorders). If the patient's condition is deemed unstable, the clinician must refer to guidelines on acute coronary syndromes, which are not covered in the present document [5, 6].

The pretest probability (PTP) of obstructive CAD is calculated, considering age, sex, presence of dyspnoea and the typical or atypical characteristics of the patient's angina pain. Typical angina pain is defined on the basis of three criteria: (1) the presence of chest pain suggesting angina; (2) triggered by exercise or emotional stress; (3) rapidly alleviated when the patient stops exercising or has taken

nitroderivatives, usually via the sublingual route. Angina pain is described as atypical when only two criteria are present; in most cases when chest pain is not triggered by exercise. If only one of these criteria is present, the pain is not considered to be angina. In agreement with the ESC, we recommend the use of the method of Diamond and Forrester in its 2019 updated version, which gives a more accurate assessment of the probability of obstructive CAD and can also be used for elderly patients (Fig. 1) [4, 7-10].

Patients with a CAD PTP > 15%, especially a mid-to-high PTP, are those who would benefit most from functional non-invasive imaging testing, such as stress MRI, particularly if a revascularization procedure is likely or if the patient has known obstructive CAD [4]. For patients with a PTP between 5% and 15%, testing for diagnosis may be considered after assessing the overall clinical likelihood based on the modifiers of PTP presented in Fig. 2. There is no indication to perform a diagnostic test if the PTP is < 5%.

Functional imaging for myocardial ischaemia, such as stress MRI, is indicated if coronary computed tomography angiography (CTA) has shown CAD of uncertain functional significance or is not diagnostic.

Invasive coronary angiography is recommended as an alternative test to diagnose CAD in patients with a high clinical likelihood, severe symptoms refractory to medical therapy or typical angina at a low level of exercise, LV dysfunction and clinical evaluation that indicates high event risk.

## **In asymptomatic patients**

Data are lacking on indications and how to manage positive test results in asymptomatic subjects. According to ESC guidelines [4], functional imaging or coronary CTA may be considered in “high-risk asymptomatic adults (with diabetes, a strong family history of CAD or when previous risk-assessment tests suggest a high risk of CAD) for cardiovascular risk assessment”.

## **Follow-up of patients with known CAD**

The long-term prognosis for patients with CAD depends on the demographics and clinical features, on LV function and angiographically defined coronary lesions and, finally, on the results of stress imaging. The latter should be considered when an adverse evolution of the patient's obstructive CAD is

suspected: change in (the severity of the) symptoms and the electrocardiogram (onset of Q waves, change in repolarization, onset of left bundle branch block) or worsening of LV function.

There is no randomized study focused on the value of monitoring stable patients by periodical stress imaging. However, a reassessment of their prognosis can be discussed when the time elapsed since the last stress test considered to present a low risk has exceeded its period of validity. A period of 3 to 5 years was proposed in the 2019 ESC guidelines [4].

## **Patient selection for stress MRI in chronic coronary syndrome**

The most exhaustive meta-analyses reveal that MRI stress testing and positron emission tomography-computed tomography are the most sensitive and specific imaging modalities when invasive coronary angiography shows that the patient's stenosis is > 50% or the fractional flow reserve is positive [11]. A strategy guided by MRI has the advantage of decreasing the number of invasive coronary angiographies without compromising patient prognosis [12]. The British healthcare system considers that an MRI-guided strategy for exploring patients referred for angina yields the best cost-effectiveness ratio compared with the other alternatives. A recent study demonstrated that the use of stress MRI compared with invasive fractional flow reserve in patients presenting with stable angina decreased the number of invasive coronary angiographies without compromising patient prognosis [13].

Despite the higher diagnostic performance of stress MRI, the type of imaging to use will essentially depend on availability, local expertise, the presence of contraindications and patient choice. However, MRI should be considered as a more appropriate choice in some clinical situations, summarized in [Table 1](#). MRI does not produce ionizing radiation, and has no sensitivity to breast or diaphragm attenuation or sex-based differences in accuracy [14]. Because of its safety, stress MRI is especially useful in younger and female patients. In obese patients, stress echocardiography may suffer from poor echogenicity, and single-photon emission computed tomography can be limited by attenuation, with a higher incidence of false-positive results. Coronary computed tomographic angiography is hampered by patient morphology and higher radiation. Stress perfusion MRI is feasible and safe, and has accurate discriminative prognostic value, even in morbidly obese patients (body mass index  $\geq 40$  kg/m<sup>2</sup>) [15]. Both single-photon emission computed tomography and stress echocardiography have reduced diagnostic accuracy in patients with left bundle branch block.

Dobutamine stress MRI may have greater diagnostic accuracy than dobutamine echocardiography because of the comprehensive examination with the addition of perfusion and late gadolinium enhancement [16]. Nevertheless, data on accuracy of stress MRI using vasodilators in patients with left bundle branch block is limited, and cannot be recommended over another imaging modality for those patients. Stress MRI is feasible in patients with atrial arrhythmia, and has good discriminative prognostic value [17]. Finally, the main advantage of stress MRI is the ability to accurately evaluate cardiac morphology, function and tissue characteristics during the same test. For instance, this modality should be considered if stress imaging is indicated for a patient with hypertrophic cardiomyopathy, to identify focal or diffuse fibrosis, or for a patient with heart failure, to measure LV ejection fraction (before cardiac resynchronization therapy and/or defibrillator implantation, etc.) and right ventricular function. Stress MRI also offers precise evaluation of myocardial viability as a result of high spatial resolution and excellent correlation with histology, which provides valuable information when considering revascularization.

## **The procedure**

### **Safety of MRI stress tests**

Abundant literature shows that myocardial ischaemia-inducing tests (dobutamine) or coronary reserve tests (adenosine, regadenoson, dipyridamole) can be performed with MRI in perfectly acceptable conditions for the patient [10]. The vasodilators should be preferred to dobutamine, which carries a higher complication rate in clinical practice. Dobutamine can be used at a low dose to research contractile reserve and to explore the viability of the myocardium. Our group regrets that vasodilators have not been granted a visa for MRI stress tests. In France, their use is justified by many articles in the literature, the European recommendations, several randomized studies and meta-analyses and the recommendations from international societies [12, 13, 18-22].

MRI stress tests require strict safety measures: (1) the hospital must be equipped with a cardiology intensive care unit; (2) the patient must be duly informed of how the examination will be carried out, the fact that the drug is being used off-label and the risks entailed, and an informed consent form must be signed; (3) the medical staff should respect the contraindications, dosage and routes of administration of the pharmacological products and contrast agents involved, and be aware



of their side effects and the withdrawal criteria; and (4) contraindications for provoked myocardial ischaemia testing must be respected ([Table 2](#)).

### **Before the stress test**

A physician specialized in cardiovascular imaging should practice stress cardiac MRI in cooperation with a physician trained in cardiorespiratory resuscitation who is able to take care of the patient immediately if necessary [23]. The paramedical team should include two operators, one trained in the use of the emergency trolley and a radiology technician. An area located beside the MRI suite must be available and equipped with all items required for emergency procedures: oxygen and suction drainage, and an emergency trolley equipped with all drugs and antidotes (aminophylline, beta-blockers, salbutamol, adrenalin, nitrates). Nasotracheal intubation equipment and a defibrillator must be available. The different emergency procedures, useful telephone numbers and names of the different operators should be displayed in the room. The patient should be given a 12-channel reference electrocardiogram before being installed in the room. Twelve to 24 hours before a stress MRI, the patient must not take any medication or food that is likely to inhibit drugs or change the interpretation. For dobutamine, beta-blockers and nitroderivatives are prohibited. For dipyridamole, adenosine and regadenoson, caffeine (coffee, tea, chocolate or drinks containing these, food or drugs containing caffeine) aminophylline, dipyridamole and nicotine are contraindicated. Fasting is not mandatory; a light meal is advised before the examination. The vasodilators frequently induce side effects that must be explained to the patient.

### **During the stress test**

Two venous lines (flexible 16 or 20 gauge catheters) are made available, one for injecting the stress-inducing product and the other for the gadolinium-based contrast medium (except for regadenoson, for which a single venous line is sufficient). Patient monitoring (amagnetic device mandatory) should include continuous three-channel electrocardiography, arterial pressure and a digital oximeter. An alarm button is placed in the patient's hand. Oral contact with the technician is allowed via microphones. Headphones are placed on patient's ears to reduce noise. If urgent care or resuscitation is required, the patient must be removed from the examination room immediately.

## **At the end of the stress test**

Care should be taken when the patient stands up because of the risk of orthostatic hypotension. A 12-channel electrocardiogram should be performed to check return to baseline. The patient should remain under surveillance until the electrocardiogram returns to baseline, with no chest pain and recovery from side effects. An aminophylline injection is not given systematically when the stress agent is dipyridamole, the half-life of aminophylline being much longer than that of dipyridamole; it can be helpful if the patient experiences unpleasant side effects. Aminophylline is not indicated after administration of adenosine. Aminophylline is not advised after injection of regadenoson in patients with epilepsy, both drugs having proconvulsive effects. The patients can leave the department after a period of surveillance if no intercurrent clinical event has occurred.

## **Stress-inducing drugs: Precautions and contraindications**

A study suggested that dipyridamole was less sensitive and specific than adenosine or regadenoson for MRI stress testing [24]. Adenosine or regadenoson should therefore be preferred, and dipyridamole should only be used if adenosine or regadenoson are not available in the hospital. In addition, regadenoson is a drug that is easier to use, as there is only one dosage for adults; the likelihood of dosage errors is therefore decreased. Regadenoson specifically targets the cardiac receptors, thus mitigating the benign side effects connected to this vasodilator. This group of experts estimates that regadenoson is currently the most suitable vasodilator to be used in stress cardiac MRI.

## **Dose**

### **Dobutamine**

The expert group does not advise researching myocardial ischaemia with dobutamine, and suggests that vasodilators should be preferred. However, it is possible to use dobutamine to research contractile reserve and assess myocardial viability. The maximum dose is 15 µg/kg/min, which should be reached by steps of 2.5–5 µg/kg/min. The duration of each step should be between 2 and 3 minutes, starting from an initial dose of 5 µg/kg/min.

### **Adenosine**

For adenosine, the dose is 140 µg/kg/min. The dose can be increased to 210 µg/kg/min if, after 2–3 minutes, the patient's heart rate does not increase by 10 beats/min or if systolic blood pressure does not decrease by at least 10 mmHg.

## **Regadenoson**

For regadenoson, a single dose is used in adults, without considering size or weight: 0.4 mg by intravenous injection.

## **Dipyridamole**

For dipyridamole, the dose is 0.56 to 0.82 mg/kg via slow intravenous injection over a period of 3 minutes.

## **Contraindications**

Stress agent contraindications are displayed in [Table 2](#). All three vasodilators (dipyridamole, adenosine, regadenoson) share common contraindications. However, according to available data from observational studies as well as controlled clinical trials, the use of regadenoson in patients with mild-to-moderate asthma and mild-to-moderate chronic obstructive pulmonary disease is safe [25-29].

Regadenoson should be used very cautiously in patients with severe chronic obstructive pulmonary disease, in patients who require 24-hour/day home oxygen administration, have previously been intubated for respiratory failure, have had recent exacerbations or have required up-titration of their medication regimen within a 1-month period, because data in these populations are limited.

Regadenoson should be avoided in patients with severe bronchial asthma.

## **Potential side effects**

At low doses, dobutamine rarely causes complications, but at higher doses (20–40 µg/kg/min) can induce chest pain and palpitations. More serious complications (myocardial infarction, ventricular fibrillation and ventricular tachycardia) are rare.

Adenosine, regadenoson and dipyridamole can induce hot flushes, headaches, precordial pain, palpitations and dyspnoea. These side effects occur frequently (in around 30% of patients), but they

are usually benign and rapidly reversible. More serious side effects (transient conduction disorders, hypotension, sinus tachycardia and bronchospasm) are rarer.

The side effects described for adenosine occur less frequently with regadenoson, but the half-life of regadenoson is longer (so the patient should be monitored for slightly longer with regadenoson than with adenosine).

## **Acquisition protocol**

Cine MRI sequences associated with first-pass perfusion and late enhancement form the basis of any stress cardiac MRI. Examples of acquisition protocols with approximate timelines are proposed in [Fig. 3](#).

### **Cine MRI**

This part is based on fast acquisition cine sequences using steady-state free precession (slice thickness 6–8 mm, with or without 2–4 mm interslice gaps [to make a total of 10 mm]; temporal resolution  $\leq 45$  ms between phases to optimize evaluation of wall motion) [30]. Parallel imaging shortens the acquisition process. These pulse sequences should include at least: slices covering the whole left ventricle (LV) in its short axis from base to apex (the most basal slice must be immediately proximal to the position of the mitral valve); and three long-axis slices of the LV, including two-chamber, four-chamber and LV outflow tract views.

### **Stress test using vasodilators: Myocardial perfusion imaging**

Perfusion MRI is based on a qualitative (visual) analysis of the enhancement of the myocardial signal during the first pass of a bolus injection of gadolinium chelate. The temporal resolution of perfusion sequences should allow the acquisition of three to five slices within an R-R space. Saturation-recovery is used as prepulse.

The following should be performed: at least three slices in the short axis of the LV, and most often a slice in the vertical plane of the long axis and another in the horizontal plane of the long axis, after intravenous injection of a bolus of  $0.05\text{--}0.1$  mmol.kg<sup>-1</sup> of gadolinium chelate (4–5 mL/s using an automatic injector); these slices are acquired on each R-R interval during the minute after injection of the bolus of gadolinium. The acquisitions are performed under pharmacological stimulation during the

last minute of the adenosine injection, 3–5 minutes after the end of the slow intravenous administration of dipyridamole or 1–4 minutes after the intravenous bolus of regadenoson. Pulse sequences must be adapted to the drug-induced tachycardia. A perfusion acquisition at rest after injection of the vasodilators is optional, but may be superfluous if the result of the stress perfusion is unequivocal (normal, ischaemia). Aminophylline could also be injected after the first perfusion acquisition (minimum 1 minute after gadolinium injection) to reverse the vasodilation effect if dipyridamole or regadenoson is used as the stress agent.

### **Late gadolinium chelate enhancement (LGE)**

Two-dimensional or three-dimensional phase-sensitive inversion recovery sequences can be used, 10–15 minutes after the injection of 0.1–0.15 mmol.kg<sup>-1</sup> gadolinium chelate (dose depending on medical staff choice). It might be reasonable to reinject gadolinium chelate to perform good quality LGE after stress perfusion (if rest perfusion was not performed). Inversion time is optimized for each patient, so that the signal for healthy myocardium is zero at the time of acquisition. The slice thickness must be 6–8 mm, and the in-plane spatial resolution must be lower than ~1.4–1.8 mm.

### **Interpretation**

Interpreting stress cardiac MRI is a synthesis that is not restricted to analysing first-pass perfusion under vasodilators. The clinical, electrical and angiographical data (invasive coronary angiography or coronary computed tomography) must be considered, together with all features of the MRI examination (hypokinesia, late enhancement). Therefore, in addition to experience in cardiac MRI, stress MRI should only be performed by teams with clinical competence in CAD.

### **Diagnosis of ischaemia**

The semiology of a first-pass perfusion sequence is fairly unequivocal. After injection, the gadolinium chelate appears successively in the right heart chambers, the pulmonary parenchyma and then the myocardium. Normal myocardium picks up the contrast clearly and evenly. Sometimes a perfusion gradient is observed from the epicardium to the endocardium; this feature must be fleeting to be considered as normal. In the case of coronary reserve deficit, persistent hypoperfusion is found in a segmental area (Fig. 4). This hypoperfused area is researched by browsing (slowly) through the first-

pass sequence image by image. Going through the images using fast cine mode could mislead the observer, and fleeting hypoperfusion could be missed. The perfusion images should be classified using the American Heart Association 17-segment model [31]. The number of diseased segments is used to assess the risk of adverse cardiovascular events. Hypoperfusion in at least two segments is a sign of significant ischaemia, and carries a high risk of cardiovascular events.

The presence of ischaemia is univocal when acquisitions and injections are correctly performed in a patient who has been previously vasodilated. Interpretation is facilitated when using motion compensation algorithms. When rest perfusion images are acquired, it is important to make sure that the vasodilators are no longer effective; this is one of the advantages of adenosine, which has a very short half-life and thus does not require the use of an antagonist. When ischaemia is detected, the first-pass perfusion should be compared with cine sequences (wall motion abnormality and myocardial thinning are searched) and, above all, with the LGE.

If the resting perfusion is normal and no LGE is visible, the hypoperfusion is reversible. Revascularization is a possible solution if at least two adjacent segments appear as hypoperfused during stress imaging. If the hypoperfused segments are perfectly superimposable with LGE, the diagnosis is that of ischaemic heart disease with necrotic sequelae. Occasionally, especially when infarct size is small, hypoperfused segments may not be identified during a first-pass perfusion sequence, although a typical ischaemic LGE pattern is present [19]. If the hypoperfused area is wider than the LGE, perilesional stress hypoperfusion is present; it means that a revascularization procedure could be discussed according to the invasive coronary angiography findings.

## **Viability assessment**

A stress cardiac MRI test must be completed by an analysis of myocardial viability using late enhancement after gadolinium injection. A segmental hypersignal with < 25% of transmural extension indicates a strong probability of functional recovery after revascularization, whereas if > 75% is affected, no improvement can be expected [32]. A meta-analysis of 331 patients showed that < 50% of transmural extension is predictive of functional recovery, with 95% sensitivity and 51% specificity [33]. The contractile reserve test can be useful when the necrotic scar involves 25–50% of the thickness of the wall. The contractile reserve test consists of injecting a low dose of dobutamine (maximum 15 µg/kg/min in consecutive steps of 2.5–5 µg/kg/min every 2 to 3 minutes), analysing the kinetics of

the segment during the injection [34]. The thickness of the myocardium is not sufficient to assess myocardial viability because a thickness of < 5 mm is not specific for non-viability [35].

### **Artefacts and hypoperfusion without epicardial coronary stenosis**

When a linear hyposignal is visible on a single slice, typically on the septum (Fig. 5), this can suggest a truncation artefact (or Gibbs artefact). True myocardial hypoperfusion is characterized by a front wave-shaped hyposignal, persisting for several R-R intervals (at least three). A resting acquisition can be performed, and compared image by image with the stress acquisition. The truncation artefact is generally visible and unchanged in both series (stress and rest); it is restricted to the subendocardium.

Perfusion anomalies can be observed on the first-pass perfusion images, even if the patient does not have significant epicardial coronary artery stenosis, and should not always be considered as “false positives”: if the patient’s heart is hypertrophic, a subendocardial hyposignal can be observed, and could be the substrate of functional angina; also, endothelial dysfunction may lead to subendocardial ischaemia (the hyposignal is often circumferential, and is observed in the context of hypertension and/or diabetes mellitus).

### **Risk stratification by stress MRI**

In line with ESC recommendations, the expert group considers that an ischaemia threshold of at least two segments is the most relevant. A negative (perfusion or dobutamine) MRI stress test is associated with an annualized event rate  $\leq 1\%$  for a follow-up period of > 2 years [36, 37]. This “guarantee” period is assessed on the basis of a heterogeneous population, and should thus be adapted according to the clinical risk factors, such as age, female sex, presence of diabetes or the severity of coronary lesions [38].

In practice, in the case of unknown obstructive CAD, a positive MRI stress test indicates that invasive coronary angiography should be performed to confirm the diagnosis and possibly to treat the involved vessel. A non-conclusive MRI stress test requires an alternative method, such as cardiac CTA or invasive coronary angiography, according to the degree of clinical probability.

In the case of known obstructive CAD, invasive coronary angiography should only be performed if the MRI stress test shows ischaemia in at least two segments, which is a sign of a high likelihood of events, or if there are other criteria of severity, such as the onset of symptoms at a low threshold of

exercise (also a sign of a high risk of events) or if the patient remains symptomatic despite optimal antiangina treatment or if LV function is compromised.

## **Conclusions**

Cardiac stress testing by MRI has become the high-performance technology of choice for the diagnosis and classification of risk in patients with chronic coronary syndrome. Although vasodilators are the preferred products to carry out these procedures, because they are simple and safe to use, their administration in the MRI suite remains off label in France. This group promotes the use of regadenoson for stress cardiac MRI. The latest recommendations issued by the ESC encourage the use of non-invasive imaging when obstructive CAD is suspected, to the detriment of the conventional treadmill test. This change in practice will stimulate the development of MRI stress tests that offer the advantages of relatively low cost and no radiation exposure, while offering a detailed analysis of the heart's morphology and function and the viability of the myocardium during the same examination.

## **Sources of funding**

None.

## **Disclosure of interest**

The authors declare that they have no conflicts of interest concerning this article.



## References

- [1] Alis D, Guler A, Yergin M, Asmakutlu O. Assessment of ventricular tachyarrhythmia in patients with hypertrophic cardiomyopathy with machine learning-based texture analysis of late gadolinium enhancement cardiac MRI. *Diagn Interv Imaging* 2020;101:137-46.
- [2] Capron T, Cautela J, Scemama U, et al. Cardiac magnetic resonance assessment of left ventricular dilatation in chronic severe left-sided regurgitations: comparison with standard echocardiography. *Diagn Interv Imaging* 2020;101:657-65.
- [3] Habert P, Capron T, Hubert S, et al. Quantification of right ventricular extracellular volume in pulmonary hypertension using cardiac magnetic resonance imaging. *Diagn Interv Imaging* 2020;101:311-20.
- [4] Knuuti J, Wijns W, Saraste A, et al. 2019 ESC Guidelines for the diagnosis and management of chronic coronary syndromes. *Eur Heart J* 2020;41:407-77.
- [5] Collet JP, Thiele H, Barbato E, et al. 2020 ESC Guidelines for the management of acute coronary syndromes in patients presenting without persistent ST-segment elevation. *Eur Heart J* 2020.
- [6] Ibanez B, James S, Agewall S, et al. 2017 ESC Guidelines for the management of acute myocardial infarction in patients presenting with ST-segment elevation: The Task Force for the management of acute myocardial infarction in patients presenting with ST-segment elevation of the European Society of Cardiology (ESC). *Eur Heart J* 2018;39:119-77.
- [7] Diamond GA, Forrester JS. Analysis of probability as an aid in the clinical diagnosis of coronary-artery disease. *N Engl J Med* 1979;300:1350-8.
- [8] Genders TS, Steyerberg EW, Alkadhi H, et al. A clinical prediction rule for the diagnosis of coronary artery disease: validation, updating, and extension. *Eur Heart J* 2011;32:1316-30.
- [9] Genders TS, Steyerberg EW, Hunink MG, et al. Prediction model to estimate presence of coronary artery disease: retrospective pooled analysis of existing cohorts. *BMJ* 2012;344:e3485.
- [10] Montalescot G, Sechtem U, Achenbach S, et al. 2013 ESC guidelines on the management of stable coronary artery disease: the Task Force on the management of stable coronary artery disease of the European Society of Cardiology. *Eur Heart J* 2013;34:2949-3003.

- [11] Knuuti J, Ballo H, Juarez-Orozco LE, et al. The performance of non-invasive tests to rule-in and rule-out significant coronary artery stenosis in patients with stable angina: a meta-analysis focused on post-test disease probability. *Eur Heart J* 2018;39:3322-30.
- [12] Greenwood JP, Ripley DP, Berry C, et al. Effect of Care Guided by Cardiovascular Magnetic Resonance, Myocardial Perfusion Scintigraphy, or NICE Guidelines on Subsequent Unnecessary Angiography Rates: The CE-MARC 2 Randomized Clinical Trial. *JAMA* 2016;316:1051-60.
- [13] Nagel E, Greenwood JP, McCann GP, et al. Magnetic Resonance Perfusion or Fractional Flow Reserve in Coronary Disease. *N Engl J Med* 2019;380:2418-28.
- [14] Greenwood JP, Motwani M, Maredia N, et al. Comparison of cardiovascular magnetic resonance and single-photon emission computed tomography in women with suspected coronary artery disease from the Clinical Evaluation of Magnetic Resonance Imaging in Coronary Heart Disease (CE-MARC) Trial. *Circulation* 2014;129:1129-38.
- [15] Kinnel M, Garot J, Pezel T, et al. Prognostic Value of Vasodilator Stress Perfusion CMR in Morbidly Obese Patients (BMI  $\geq$ 40 kg/m<sup>2</sup>) Without Known CAD. *JACC Cardiovasc Imaging* 2020;13:1276-7.
- [16] Mordi I, Stanton T, Carrick D, et al. Comprehensive dobutamine stress CMR versus echocardiography in LBBB and suspected coronary artery disease. *JACC Cardiovasc Imaging* 2014;7:490-8.
- [17] Pezel T, Sanguineti F, Kinnel M, et al. Feasibility and Prognostic Value of Vasodilator Stress Perfusion CMR in Patients With Atrial Fibrillation. *JACC Cardiovasc Imaging* 2021;14:379-89.
- [18] Fratz S, Chung T, Greil GF, et al. Guidelines and protocols for cardiovascular magnetic resonance in children and adults with congenital heart disease: SCMR expert consensus group on congenital heart disease. *J Cardiovasc Magn Reson* 2013;15:51.
- [19] Greenwood JP, Herzog BA, Brown JM, Everett CC, Plein S. Cardiovascular Magnetic Resonance and Single-Photon Emission Computed Tomography in Suspected Coronary Heart Disease. *Ann Intern Med* 2016;165:830-1.
- [20] Jaarsma C, Leiner T, Bekkers SC, et al. Diagnostic performance of noninvasive myocardial perfusion imaging using single-photon emission computed tomography, cardiac magnetic

- resonance, and positron emission tomography imaging for the detection of obstructive coronary artery disease: a meta-analysis. *J Am Coll Cardiol* 2012;59:1719-28.
- [21] Schwitter J, Wacker CM, van Rossum AC, et al. MR-IMPACT: comparison of perfusion-cardiac magnetic resonance with single-photon emission computed tomography for the detection of coronary artery disease in a multicentre, multivendor, randomized trial. *Eur Heart J* 2008;29:480-9.
- [22] Schwitter J, Wacker CM, Wilke N, et al. MR-IMPACT II: Magnetic Resonance Imaging for Myocardial Perfusion Assessment in Coronary artery disease Trial: perfusion-cardiac magnetic resonance vs. single-photon emission computed tomography for the detection of coronary artery disease: a comparative multicentre, multivendor trial. *Eur Heart J* 2013;34:775-81.
- [23] Vignaux O, Deux JF, Chabrilat Y, et al. [Cardiac MRI: technical considerations]. *J Radiol* 2009;90:1133-43.
- [24] Vasu S, Bandettini WP, Hsu LY, et al. Regadenoson and adenosine are equivalent vasodilators and are superior than dipyridamole- a study of first pass quantitative perfusion cardiovascular magnetic resonance. *J Cardiovasc Magn Reson* 2013;15:85.
- [25] Husain Z, Palani G, Cabrera R, et al. Hemodynamic response, arrhythmic risk, and overall safety of regadenoson as a pharmacologic stress agent for myocardial perfusion imaging in chronic obstructive pulmonary disease and bronchial asthma patients. *Int J Cardiovasc Imaging* 2012;28:1841-9.
- [26] Kwon DH, Cerqueira MD, Young R, et al. Lessons from regadenoson and low-level treadmill/regadenoson myocardial perfusion imaging: initial clinical experience in 1263 patients. *J Nucl Cardiol* 2010;17:853-7.
- [27] Prenner BM, Bukofzer S, Behm S, Feaheny K, McNutt BE. A randomized, double-blind, placebo-controlled study assessing the safety and tolerability of regadenoson in subjects with asthma or chronic obstructive pulmonary disease. *J Nucl Cardiol* 2012;19:681-92.
- [28] Salgado Garcia C, Jimenez Heffernan A, Sanchez de Mora E, et al. Comparative study of the safety of regadenoson between patients with mild/moderate chronic obstructive pulmonary disease and asthma. *Eur J Nucl Med Mol Imaging* 2014;41:119-25.

- [29] Thomas GS, Tammelin BR, Schiffman GL, et al. Safety of regadenoson, a selective adenosine A2A agonist, in patients with chronic obstructive pulmonary disease: A randomized, double-blind, placebo-controlled trial (RegCOPD trial). *J Nucl Cardiol* 2008;15:319-28.
- [30] Kramer CM, Barkhausen J, Bucciarelli-Ducci C, Flamm SD, Kim RJ, Nagel E. Standardized cardiovascular magnetic resonance imaging (CMR) protocols: 2020 update. *J Cardiovasc Magn Reson* 2020;22:17.
- [31] Cerqueira MD, Weissman NJ, Dilsizian V, et al. Standardized myocardial segmentation and nomenclature for tomographic imaging of the heart. A statement for healthcare professionals from the Cardiac Imaging Committee of the Council on Clinical Cardiology of the American Heart Association. *Circulation* 2002;105:539-42.
- [32] Kim RJ, Wu E, Rafael A, et al. The use of contrast-enhanced magnetic resonance imaging to identify reversible myocardial dysfunction. *N Engl J Med* 2000;343:1445-53.
- [33] Romero J, Xue X, Gonzalez W, Garcia MJ. CMR imaging assessing viability in patients with chronic ventricular dysfunction due to coronary artery disease: a meta-analysis of prospective trials. *JACC Cardiovasc Imaging* 2012;5:494-508.
- [34] Nagel E, Schuster A. Myocardial viability: dead or alive is not the question! *JACC Cardiovasc Imaging* 2012;5:509-12.
- [35] Shah DJ, Kim HW, James O, et al. Prevalence of regional myocardial thinning and relationship with myocardial scarring in patients with coronary artery disease. *JAMA* 2013;309:909-18.
- [36] Gargiulo P, Dellegrottaglie S, Bruzzese D, et al. The prognostic value of normal stress cardiac magnetic resonance in patients with known or suspected coronary artery disease: a meta-analysis. *Circ Cardiovasc Imaging* 2013;6:574-82.
- [37] Lipinski MJ, McVey CM, Berger JS, Kramer CM, Salerno M. Prognostic value of stress cardiac magnetic resonance imaging in patients with known or suspected coronary artery disease: a systematic review and meta-analysis. *J Am Coll Cardiol* 2013;62:826-38.
- [38] Hachamovitch R, Hayes S, Friedman JD, et al. Determinants of risk and its temporal variation in patients with normal stress myocardial perfusion scans: what is the warranty period of a normal scan? *J Am Coll Cardiol* 2003;41:1329-40.

## Figure legends

**Figure 1.** Pretest probability of obstructive coronary artery disease in 15,815 symptomatic patients according to age, sex and the type of symptoms (adapted from [4]). The patients who presented with isolated dyspnoea or had it as a predominant symptom were included, in addition to the usual categories of Diamond and Forrester's algorithm. The cells in dark green show the groups for whom the non-invasive tests are the most relevant (PTP > 15%). The cells in pale green show the groups with a PTP of 5–15%, for whom diagnostic tests should be considered after overall clinical probability has been assessed, based on the modifiers shown in Fig. 2.

**Figure 2.** Determinants of the clinical likelihood of obstructive coronary artery disease (adapted from [4]). [To be drawn as a flow diagram, in style of image provided.]

<sup>a</sup> If available.

**Figure 3.** Examples of stress magnetic resonance imaging protocols according to vasodilator agent used. A. Adenosine. B. Dipyridamole. C. Regadenoson. Gd: gadolinium; LGE: late gadolinium chelate enhancement.

<sup>a</sup> Optional.

<sup>b</sup> It might be reasonable to reinject gadolinium chelate to perform good quality LGE after stress perfusion (if rest perfusion was not performed).

**Figure 4.** Stress magnetic resonance imaging under regadenoson in a young adult with stenosis of the left anterior descending artery. Three sequential images are shown. A. Gadolinium just reached the left ventricular cavity; no myocardial contrast is visible. B. Whereas normal myocardium is enhanced, the septum and posterior wall perfusion is obviously decreased. C. Hyposignal (ischaemia) persisted during several cardiac cycles.

**Figure 5.** Gibbs artefact in a young patient with hypertension; hyposignal is visible in the phase-encode direction when high contrast gadolinium appears in the left ventricle (thin arrow). The

hyposignal, usually septal, is transient and limited to the endocardium. No ischaemia was present in this patient.

**Table 1** Indications and patient selection for stress cardiac magnetic resonance imaging.

---

Common indications for stress MRI in chronic coronary syndrome

Initial test to diagnose CAD in symptomatic patients with a PTP > 15% (Fig. 1)

Initial test to diagnose CAD in symptomatic patients with a PTP of 5–15% after assessing overall clinical likelihood based on PTP modifiers (Fig. 2)

If coronary CTA has shown CAD of uncertain functional significance or is not diagnostic

In high-risk asymptomatic adults (with diabetes, a strong family history of CAD or when previous risk-assessment tests suggest a high risk of CAD), functional imaging, such as stress MRI, may be considered for cardiovascular risk assessment

Should be considered when an adverse evolution of the patient's obstructive CAD is suspected: change in (the severity of the) symptoms and the electrocardiogram (onset of Q waves, change in repolarization, onset of left bundle branch block, etc.) or deterioration of LV function, if the site and extent of ischaemia would influence clinical decision making

In stable patients with known CAD, reassessment of their prognosis can be discussed when the time elapsed since the last stress test considered to present a low risk has exceeded its period of validity (3–5 years)

Specific situations where stress MRI may be preferable to other imaging modalities

Female patients

Obese patients/poor echogenicity

Younger patients

Atrial fibrillation

Cardiac function and morphology information needed (i.e. hypertrophic cardiomyopathy, precise LV ejection fraction evaluation before CRT, etc.)

Cardiac tissue characterization information needed (i.e. fibrosis in hypertrophic cardiomyopathy, precise evaluation of viability in CAD, etc.)

---

CAD: coronary artery disease; CTA: computed tomography angiogram; CRT: cardiac resynchronization therapy; LV: left ventricular; MRI: magnetic resonance imaging; PTP: pretest probability.



**Table 2** Stress magnetic resonance imaging contraindications.

---

Provoked ischaemia testing contraindications

- Myocardial infarction or recent acute coronary syndrome (< 5 days)
- Uncontrolled rhythm disorder
- Serious conduction disorders (atrioventricular block  $\geq 2$ )
- Known significant untreated stenosis of the left main artery
- Non-controlled heart failure, severe aortic stenosis, obstructive cardiomyopathy
- Patient refusal

Vasodilator (dipyridamole, adenosine, regadenoson) contraindications

- Second- or third-degree atrioventricular block or sinus dysfunction
- Systolic pressure < 90 mmHg
- Severe systemic arterial hypertension ( $\geq 220/120$  mmHg)
- Sinusal bradycardia (heart rate < 40 beats/min)
- Hypersensitivity to the active principle or one of the excipients
- Known hypersensitivity to stress agent
- Active bronchoconstrictive or bronchospastic disease with regular use of inhalers<sup>a</sup>

Dobutamine contraindications

- Severe systemic arterial hypertension ( $\geq 220/120$  mmHg)
- Unstable angina pectoris
- Severe aortic valve stenosis
- Complex cardiac arrhythmias, including uncontrolled atrial fibrillation
- Hypertrophic obstructive cardiomyopathy
- Myocarditis, endocarditis or pericarditis
- Uncontrolled heart failure

Atropine contraindications

- Narrow-angle glaucoma
- Myasthenia gravis
- Obstructive uropathy
- Obstructive gastrointestinal disorders

MRI absolute contraindications

Incompatible cardiac implantable electronic device (PM, ICD and CRT)

Metallic intraocular foreign bodies

Implantable neurostimulation systems

Cochlear implants/ear implant

Drug infusion pumps

Catheters with metallic components

Metallic fragments such as bullets, shotgun pellets and metal shrapnel

Cerebral artery aneurysm clips

Magnetic dental implant, tissue expander, artificial limb, hearing aid, piercing

---

CRT: cardiac resynchronization therapy; ICD: implantable cardioverter defibrillator; MRI: magnetic resonance imaging; PM: pacemaker.

<sup>a</sup> Regadenoson has been demonstrated to be safe to use in patients with mild-to-moderate chronic obstructive pulmonary disease and asthma (see text for details).

	Typical		Atypical		Non-angina		Dyspnoea <sup>a</sup>	
Age (years)	Male	Female	Male	Female	Male	Female	Male	Female
30-39	3%	5%	4%	3%	1%	1%	0%	3%
40-49	22%	10%	10%	6%	3%	2%	12%	3%
50-59	32%	13%	17%	6%	11%	3%	20%	9%
60-69	44%	16%	26%	11%	22%	6%	27%	14%
70+	52%	27%	34%	19%	24%	10%	32%	12%

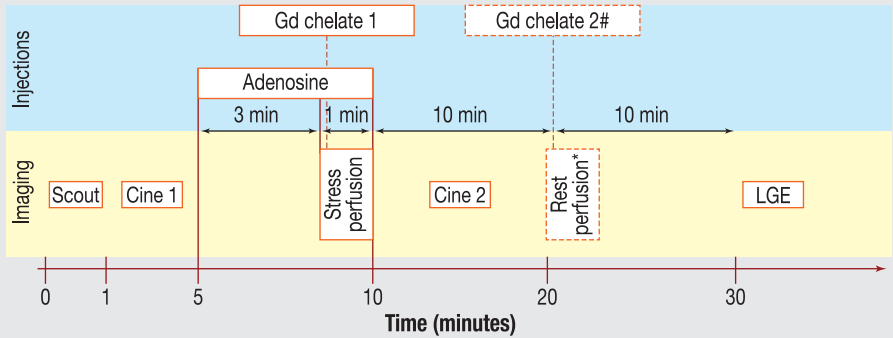
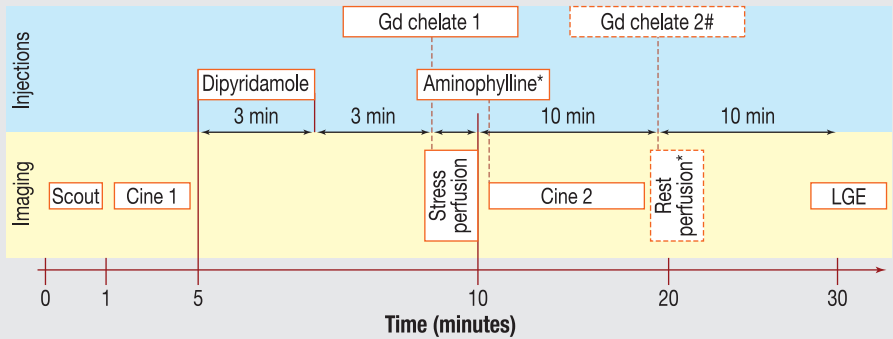
## Pretest probability based on sex, age and type of symptoms

### Decreases the probability

- Normal stress-test<sup>a</sup>
- Absence of coronary calcification (Agatson score = 0<sup>a</sup>)

### Increases the probability

- Risk factors for cardiovascular disease (dyslipidaemia, diabetes, tobacco use, hypertension, family history)
- Abnormalities on the electrocardiogram at rest (Q-waves, changes in ST segment or T-wave)
- Left ventricular dysfunction suggesting obstructive coronary artery disease
- Abnormal stress-test<sup>a</sup>
- Presence of coronary calcifications on the computed tomography scan<sup>a</sup>

**A****B****C**