



Standardized Measurement of Femoral Artery Depth by Computed Tomography to Predict Vascular Complications after Transcatheter Aortic Valve Implantation

Eric Durand, Maryline Penso, Thibault Hemery, Thomas Levesque, Gustavo Moles, Christophe Tron, Najime Bouhzam, Nicolas Bettinger, Stephanie Wong, Jean Nicolas Dacher, et al.

► To cite this version:

Eric Durand, Maryline Penso, Thibault Hemery, Thomas Levesque, Gustavo Moles, et al.. Standardized Measurement of Femoral Artery Depth by Computed Tomography to Predict Vascular Complications after Transcatheter Aortic Valve Implantation. *American Journal of Cardiology*, 2021, pp.S0002-9149(21)00047-3. 10.1016/j.amjcard.2020.12.089 . inserm-03118161

HAL Id: inserm-03118161

<https://inserm.hal.science/inserm-03118161>

Submitted on 24 Apr 2023

HAL is a multi-disciplinary open access archive for the deposit and dissemination of scientific research documents, whether they are published or not. The documents may come from teaching and research institutions in France or abroad, or from public or private research centers.

L'archive ouverte pluridisciplinaire **HAL**, est destinée au dépôt et à la diffusion de documents scientifiques de niveau recherche, publiés ou non, émanant des établissements d'enseignement et de recherche français ou étrangers, des laboratoires publics ou privés.



Distributed under a Creative Commons Attribution - NonCommercial 4.0 International License

Standardized Measurement of Femoral Artery Depth by Computed Tomography to Predict Vascular Complications after Transcatheter Aortic Valve Implantation

Eric Durand, MD, PhD^a; Maryline Penso, MD^a; Thibault Hemery, MD^a

Thomas Levesque, MSc^a; Gustavo Moles, MD^a; Christophe Tron MD^a; Najime

Bouhzam, MD^a; Nicolas Bettinger, MD^a; Stephanie Wong, MD^b; Jean-Nicolas

Dacher, MD, PhD^b; Hélène Eltchaninoff, MD^a

Normandie Univ, UNIROUEN, INSERM U1096, Rouen University Hospital,
Department of Cardiology, FHU REMOD-VHF, F76000, Rouen, France^a

Normandie Univ, UNIROUEN, INSERM U1096, Rouen University Hospital,
Department of Radiology, F76000, Rouen, France^b

Running title: Femoral artery depth and vascular complications after TAVI

Total word count: 5459

Address for correspondence:

Eric Durand, MD, PhD

Department of Cardiology

Rouen University Hospital-Charles Nicolle

1 rue de Germont

76031 Rouen Cedex, France

Tel: +33 232 885 407, Fax: +33 232 888 327

E-mail: eric.durand@chu-rouen.fr

ABSTRACT

Vascular complications (VCs) are difficult to predict and remain an important issue after transfemoral (TF) transcatheter aortic valve implantation (TAVI) although their incidence has decreased with size reduction of introducers. We aimed to evaluate a standardized measurement of femoral artery depth (FAD) using computed tomography (CT) to predict VCs after TAVI. We performed a retrospective study of 679 TF TAVI patients. We evaluated a standardized CT method to measure FAD immediately above the bifurcation. Sheath-to-femoral-artery ratio (SFAR), calcification, and tortuosity were also evaluated. VCs were defined by the Valve Academic Research Consortium (VARC)-2. Receiver operating characteristic (ROC) curves were used to predict major VCs and the need for a stent-graft. The median values of FAD and SFAR were 49.0 (36.2-66.7) mm and 0.95 (0.81-1.18), respectively. Major VCs occurred in 37 (5.4%) patients and a stent-graft was required in 49 (7.1%) patients. FAD predicted the need for a stent-graft [0.61 (0.51-0.70), $p=0.04$] but not major VCs [0.52 (0.40-0.63), $p=0.76$]. In contrast, SFAR did not predict the need for a stent-graft [0.53 (0.43-0.62), $p=0.61$] but predicted major VCs [0.70 (0.58-0.81), $p=0.001$]. Calcification and tortuosity predicted neither major VCs nor the need for a stent-graft. In conclusion, the results of our study suggest that CT measurements of FAD and SFAR provide additional information to predict major VCs and the need for a femoral stent-graft after TF TAVI.

Key Words: Aortic valve stenosis, Transcatheter Aortic Valve Implantation, Vascular injuries, Multidetector computed tomography

INTRODUCTION

Transcatheter aortic valve implantation (TAVI) is currently recommended in patients who are not suitable for surgical aortic valve replacement (SAVR) and in patients who are at increased surgical risk, particularly if patients are suitable for a transfemoral (TF) approach (1-4). Major vascular complications (VCs) are feared after TF TAVI given their prognostic impact although they have considerably decreased in recent years with improved patient selection and size reduction of introducers (3-6). Multidetector computed tomography (MDCT) of the ilio-femoral access is currently the gold standard technique to determine the feasibility of a TF approach (7). MDCT traditionally evaluates the degree of arterial tortuosity, the extent and localization of calcification (particularly at the puncture site), and the minimal diameter to compute the sheath-to-femoral-artery ratio (SFAR) (8). Among these parameters, it SFAR is considered as the strongest predictive factor of major VCs (9-11). On the other hand, it has been frequently observed that puncture of the femoral artery in obese patients, especially when the artery is deep, is more difficult and increases the risk of VCs (12). However, to our knowledge, the impact of femoral artery depth (FAD) to predict VCs after TF TAVI has been poorly evaluated. The aim of our study was therefore to assess the impact of FAD on VCs after TF TAVI using a new standardized protocol to measure FAD using MDCT.

METHODS

Between January 2013 and December 2018, 1,411 consecutive patients were prospectively included in our TAVI database. All patients selected by our multidisciplinary team had severe symptomatic aortic stenosis (AS) and gave written informed consent. Patients who had TAVI via a non-femoral route and who did not

have CT in our center or when CT was not archived were excluded. The study was approved by our local ethics committee with a waiver for retrospective analysis.

Pre-procedural MDCT examinations were performed either with a 64-slice Discovery 350 HD® or with a 256-slice Revolution® CT scanner (both from General Electric Healthcare, Milwaukee, WI, USA). Acquisition protocol was homogeneous and conformed to the recommendations of the Society of Cardiovascular Computed Tomography and the European Society of Cardiovascular Radiology (8).

Tube voltage was set at 100 kVp when patient's body mass index (BMI) was less than 25 kg.m⁻² and 120 kVp when BMI exceeded 25 kg.m⁻². Sixty milliliters of 350 mgI/mL contrast agent (iohexol or iobitridol) were injected at a flow rate of 4 mL/s pulsed by 20 mL of saline at the same flow rate. Bolus tracking was used. CT scanning of the thorax and abdomen was performed on breath-hold in a cranio-caudal direction. Chest scanning was prospectively ECG-gated. ECG was automatically switched off during acquisition for scanning the abdomen and pelvis down to the common femoral artery bifurcation. Cardiac images were not considered in the present study. Sub-millimetric abdominal-pelvic images were reconstructed and transferred to a workstation (ADW Server®, General Electric Healthcare, Milwaukee, WI, USA)

Measurements were performed with the Reformat® tool of the workstation and standardized as follows. To measure FAD, the axial view passing through the center of the femoral heads was first selected (Figure 1). A horizontal line was drawn between the ischial spines. An orthogonal vertical line was drawn from this bi ischiatic line and directed anteriorly. Another orthogonal horizontal line connected the vertical line to the geometric center of the common femoral artery that was used as vascular access for TAVI. Finally, a second vertical line was traced from the center

point of the common femoral artery to the skin surface. An experienced examiner processed all measurements retrospectively on the side of the arterial puncture used for TAVI. The same operator reproduced blindly the same measures a second time in 30 random patients to evaluate intra-observer variability. A second experienced examiner performed independently the measures in the same 30 patients to evaluate inter-observer variability. MDCT reports were also reviewed for calcification and tortuosity, and scored, as previously described (8). Briefly, calcification at the puncture site were quantified as follows: 0) absent; 1) < 30% of the circumference of the vessel; 2) 30-50% of the circumference of the vessel; 3) > 50% of the circumference of the vessel; and 4) 100% of the circumference of the vessel or the totality of the anterior wall. The tortuosity of the ilio-femoral axis was also analyzed using a semi quantitative score as follows: 0) no tortuosity; 1) mild tortuosity (30° to 60°); 2) moderate tortuosity (60° to 90°); and 3) severe tortuosity (> 90°). Finally, Iliac and femoral artery diameters were measured. SFAR was obtained by dividing the sheath size (outer diameter) by the minimum ilio-femoral diameter on the access side.

In our center, TAVI procedures have been performed since 2002 (13). The operating team for TF TAVI consists of 5 experienced operators. Prior to the procedure, the decision to perform TAVI was made by a multidisciplinary team. Only if small ilio-femoral vessel diameters and/or vascular abnormalities preclude a transfemoral approach did patients have TAVI via non-femoral access. Oral anticoagulants were stopped 3 to 4 days before the procedure and we did not use a loading dose of clopidogrel. Balloon and self-expandable prostheses were used during this study: SAPIEN XT prosthesis from January 2013 to September 2014 and SAPIEN 3 prosthesis thereafter. For the SAPIEN XT prosthesis, we used a 16-F

sheath for the 23-mm valve, an 18-F sheath for the 26-mm valve, and a 20-F sheath for the 29-mm valve. For the SAPIEN 3 prosthesis, we used a 14-F sheath for the 23 and 26 mm valves and a 16-F sheath for the 29-mm valve. During the studied period, first generation Corevalve was used in 2013 with an 18-F sheath. From 2014 to 2017, we used the Corevalve Evolut R with a 14-F sheath, and since 2018, the Corevalve Evolut Pro is preferred with a 16-F sheath.

All the procedures were performed using exclusively local anesthesia \pm conscious sedation with access site closure using a single Prostar device (Abbott Vascular, Santa Clara, California, USA) (14). Angiographic guidance was used for puncture of the common femoral artery. Heparin (70 UI/kg) was administered after sheath insertion. Anticoagulation was measured by activated clotting time with, if necessary, repetitive administration of heparin to achieve a clotting time of 250-300 seconds. Protamine was systematically administered at the end of the procedure before vascular closure. Final angiography was obtained to verify the absence of VCs. Dual antiplatelet therapy was prescribed for one month in patients without indication for anticoagulant. In patients at high risk of bleeding, a single antiplatelet therapy was preferred. In patients with an indication for anticoagulant, vitamin K antagonist or direct oral anticoagulant were used without antiplatelet therapy (15, 16).

VCs were defined according to the updated standardized endpoint definitions for TAVI according to the Valve Academic Research Consortium (VARC-2 criteria) and classified as minor or major (17). Thirty-day mortality was also recorded.

Quantitative variables were expressed as mean \pm SD or median (25th to 75th interquartile range) and compared with the Student t test or Wilcoxon rank-sum test, depending on variable distribution. Correlations were assessed using Spearman's rank correlation coefficient. Qualitative variables were presented as number with

percentage and compared with chi-square test or Fisher's exact test. A logistic regression multivariable analysis was used to assess independent correlates of major VCs and the need for a stent-graft. Receiver operator characteristic curves were also used to predict major VCs and the need for a stent-graft. To analyze the SFAR and FAD thresholds that best predicted major VCs and the need for a stent-graft, the intersection of sensitivity and specificity curves was determined with their accompanying positive and negative predictive values. Inter- and intra-observer variabilities were evaluated using Bland-Altman plot and linear logistic regression analysis.

Differences were considered statistically significant at a P value of ≤ 0.05 . All data were analyzed using SPSS software (version 23.0, IBM, Chicago, IL, USA).

RESULTS

The flowchart of the studied population is presented in Figure 2. From January 2013 to December 2018, 1411 patients had TAVI in our center. Among them, 182 (12.9%) patients were excluded because they were implanted via a non-femoral route. An additional 540 (38.3%) TF TAVI patients were excluded because MDCT was performed in another center or was not archived in the picture archiving computerized system (PACS) currently used in our center (Carestream®, Rochester, NY, USA). Thus, 689 (55.7%) TF TAVI patients were included and represented the studied population.

Baseline characteristics of the studied population are shown in Table 1. The mean age was 83.9 ± 6.0 years and 45.8% of patients were male. The mean logistic EuroSCORE was $15.4 \pm 8.9\%$ and all patients had severe symptomatic AS.

MDCT analysis of the ilio-femoral axis is represented in Table 2. The median of FAD was 49.0 (36.2-66.7) mm. Intra- and inter-observer variability of the

measurement of the FAD site was evaluated using Bland-Altman analysis (supplemental figure 1). Using linear regression, we observed a good agreement for both analyses. There was a significant correlation between FAD and weight ($p<0.0001$), BMI ($p<0.0001$), and body area ($p<0.0001$) but not with height ($p=0.4$) (Figure 3). In the studied population, 154 (22.3%) patients had a BMI ≥ 30 Kg/m². FAD was significantly higher in obese patients than in non-obese patients [73.4 (55.9-93.8) vs. 43.8 (33.7-57.2) mm, $p<0.0001$].

Moderate or severe tortuosity of the ilio-femoral axis selected for the implantation was observed in 44.6%. No or less than 30% of anterior calcification was observed at the puncture site in the majority of cases (80.7%). The median of the minimal femoral diameter at the puncture site and SFAR were 6.8 (5.9-7.6) mm and 0.95 (0.81-1.18), respectively. The severity of tortuosity and calcification were not significantly different in obese and non-obese patients. In contrast, SFAR was significantly lower in obese than in non-obese patients [0.91 (0.79-1.08) vs. 0.95 (0.82-1.20) mm, $p=0.02$].

A balloon-expandable valve was used in 88.8%. A 14-F, 16-F, and 20-F sheath was used in 446 (65.1%), 204 (29.8%), and 35 (5.1%) patients, respectively.

During in-hospital follow-up, 105 (15.2%) patients had a VC classified as minor in 68 (9.9%) patients and major in 37 (5.4%) patients. Of note, the incidence of major VC in patients excluded of our study was closely similar (5.5% vs. 5.4%, $p=0.92$).

The distribution types of vascular complications of the studied population are shown in Figure 4. Most of the VCs were access-related. The most frequent complication was hematoma and 4 patients had a non-access related major VC all related to annulus rupture. A stent-graft was used in 49 (7.1%). In 48 cases, the stent-graft was used for failure of vascular closure device (VCD) and in one case due

to iliac rupture. Among patients who need a stent-graft, 25 had a minor VC and 24 had a major VC. Five (0.7%) patients required vascular surgery and all had major VC. Vascular surgery was indicated in 2 cases for persistent bleeding after stent-graft implantation, in 2 cases for evacuation of large hematoma, and in 1 case for acute lower limb ischemia. Obese patients ($\text{BMI} \geq 30 \text{ kg/m}^2$) required more frequently a stent-graft as compared to those with a $\text{BMI} < 30 \text{ kg/m}^2$ (13.6% vs. 5.4%, $p < 0.0001$) and the incidence of major VCs was increased, but not significantly different, in obese patients as compared to non-obese patients (7.8% vs. 4.8%, $p = 0.15$).

FAD was significantly greater in patients requiring a stent-graft for a VC ($P = 0.007$, Figure 5A). In contrast, minimal femoral diameter and SFAR were not significantly different in patients requiring or not a stent-graft (Figure 5B and 5C). The degree of the tortuosity and the extent of calcification at the puncture site were not significantly different in patients requiring or not a stent-graft ($P = 0.82$ and $P = 0.51$, respectively). The incidence of stent-graft increased according to the size of the sheath ($P = 0.04$).

FAD was not significantly different in patients with or without major VCs (Figure 6A). The minimal femoral diameter was not significantly different in patients with or without major VCs (Figure 6B). In contrast, SFAR was significantly higher in patients with than without major VCs ($p < 0.0001$, Figure 6C). The degree of the tortuosity was not significantly different in patients with or without major VCs ($P = 0.81$) but the extent of calcification at the puncture site was significantly greater in patients with than in those without major VCs ($P = 0.02$). The incidence of major VCs increased according to the size of the sheath ($P < 0.0001$).

Predictors of major VCs and the need for a stent-graft were evaluated using multivariate and ROC curve analysis.

After multivariate analysis, FAD was the only predictor of the need for a stent-graft (Table 3) whereas SFAR was the only predictor of major VCs (Table 4)

ROC curve analysis for predictors of the need for a stent-graft is shown in Figure 7. The area under the ROC curve for FAD was 0.61 (0.51-0.70, $p=0.04$) indicating poor accuracy to predict the need for a stent-graft. Other parameters were not significant.

ROC curve analysis for predictors of major VCs is shown in Figure 8. The area under the ROC curve for SFAR was 0.70 (0.58-0.81, $p=0.001$) and for sheath diameter was 0.66 (0.54-0.78, $p=0.006$) indicating fair and poor accuracy to predict major VCs, respectively. Other parameters were not significant.

To analyze the FAD that best predicted the need for a stent-graft, sensitivity and specificity curves were composed. The identified intersection point of the 2 curves provided a threshold of 54 mm. The accompanying sensitivity for the threshold was 63.3% with a specificity of 40.9%, a positive predictive value of 4.9%, and negative predictive value of 89.4%.

To analyze the SFAR that best predicted major VCs, sensitivity and specificity curves were also composed. The identified intersection point of the 2 curves provided a threshold of 1.03. The accompanying sensitivity for the threshold was 67.6% with a specificity of 65.2%, a positive predictive value of 9.5%, and negative predictive value of 97.4%.

Interestingly, major VCs were significantly higher in patients who combined a SFAR >1.03 and a FAD >54 mm than in those with a SFAR < 1.03 and a FAD <54 mm (12% vs. 2.1%, $p<0.0001$). Two examples of low-risk and high-risk patients of VCs according to MDCT analysis of the ilio-femoral access are shown in supplemental figure 2.

The 30-day mortality rate was 8.6% for patients with major VCs and 2.3% for patients without major VCs ($P=0.06$). The 30-day mortality rate for patients requiring a stent-graft was 4.3% and 2.5% for patients not requiring a stent-graft ($P=0.45$).

DISCUSSION

We aimed to evaluate a new MDCT parameter (i.e., measurement of FAD), in addition to usual parameters, to predict major VCs and the need for a stent-graft after TF TAVI. The main results can be summarized as follows: 1) FAD measurement using standardized MDCT is easy and reproducible and was significantly increased in patients requiring a stent-graft; 2) FAD was the only predictor of the need for a stent-graft although ROC curve analysis indicated poor accuracy with a threshold value of 54-mm; 3) Among the other usual parameters, SFAR was the only factor with a fair accuracy to predict major VCs.

For a long time now, it has been known that femoral arterial puncture in obese patients, particularly when the artery is deep, is more difficult and the risk of VCs and bleeding is increased (12, 18). Surprisingly, it has been reported that major VCs are not significantly increased in obese patients after TF TAVI (5, 9, 11, 19). We hypothesized that the measurement of FAD, rather than BMI, would be more appropriate to evaluate the risk of major VCs and in particular the risk of failure of VCD, requiring a stent-graft. In our study, we first showed that FAD can be easily and reproducibly measured using CT. Interestingly, FAD was not significantly different in patients with or without major VCs and FAD was not predictive of major VCs. These results are in accordance with those showing that obesity does not increase the risk of major VCs after TF TAVI (5, 9, 11, 19). However, we observed that FAD was increased in patients requiring a stent-graft and was the only predictive factor of the need for a stent-graft. Of note, most of the stent-grafts were related to the failure of

VCD in our study. We therefore hypothesized that the deeper the femoral artery, the greater the risk of failure of VCD. Predictive factors of failure of VCD for coronary angiography and/or PCI using a femoral approach have been reported. Interestingly, obesity was an independent predictors of failure of VCD (20). Predictive factors of failure of VCD have been evaluated in patients with large arteriotomy for aneurysm repair or TAVI (21). In accordance with our studies, the distance between skin and common femoral artery (i.e., FAD) was a strong predictor of failure of VCD (22). In order to reduce the risk of failure of VCD requiring a stent-graft in patients with a deep femoral artery, several options are possible. First, the shallowest femoral artery should be selected because FAD is commonly asymmetrical. Second, the lower belly should be pushed upwards and the puncture should be performed in a straight direction, otherwise the insertion of the sheath or preclosure device may become difficult. Third, a preventive crossover balloon occlusion technique may be also used to reduce bleeding in case of failure of VCD in patients presenting with very deep femoral artery (23). On the other hand, a surgical cut down can be also discussed in obese patients but it has been reported that the incidence of major VCs is similar between percutaneous and surgical femoral approaches (24). Finally, alternative accesses (e.g. trans-carotid, trans-subclavian, trans-apical) should be privileged in patients with multiple elements unfavorable for femoral approach.

We also assessed the impact of other MDCT parameters to predict VCs after TAVI. In our study, the degree of ilio-femoral tortuosity and the extent of calcification at the puncture site were neither predictive of major VCs nor the need for a stent-graft. In all the studies, the degree of ilio-femoral tortuosity was not an independent predictor of major VCs after TAVI (9, 11). On the other hand, conflicting results were obtained for the extent of calcification at the puncture site (9, 11). We believe that

calcification was not predictive in our study since patients with circumferential or anterior calcification at the puncture site had systematic TAVI via a non-femoral approach.

Our study confirmed that SFAR remains the strongest predictor of major VCs after TF TAVI although the area under the ROC curve is variable among the studies and its positive value is low to predict VCs (9-11). However, to our knowledge, we are the first to evaluate the impact of SFAR on the need for a stent-graft. SFAR was not significantly different in patients with or without a stent-graft and FAD was the only predictive factor. We therefore believe that SFAR and FAD provide additional information and that FAD could be systematically and easily assessed during MDCT in order to evaluate the feasibility of a TF approach before TAVI.

This analysis was retrospectively conducted in a prospectively acquired single-center, nonrandomized cohort with inherent limitations related to its design. Therefore, we were only able to identify correlations and not prove any causality. Additionally, although it represents a real-world situation with inclusion of approximately 700 patients, the number of major VCs was relatively low (7.5%) and the results should be confirmed in a larger population. Furthermore, we excluded about 40% of the patients for whom MDCT was not archived in the PACS currently used in our center. It is therefore possible that this could have resulted in a selection bias. Finally, our results were obtained using preclosing with Prostar device and could not be extrapolated with other VCD.

In conclusion, the results of our study show that FAD measurement is easy and reproducible and can be performed during MDCT assessment of ilio-femoral vessels, before TAVI. Based on our findings, we suggest that FAD is an independent

predictor of the need for a stent-graft for VC after TF TAVI. Further studies are needed to confirm our results prospectively and in a larger population.

ACKNOWLEDGMENTS

The authors are grateful to Nikki Sabourin-Gibbs for her help in editing the manuscript.

SOURCES OF FUNDING

None

DISCLOSURES

Hélène Eltchaninoff has received lecture fees and is proctor for Edwards Lifesciences. Eric Durand has received lecture fees from Edwards Lifesciences. Helène Eltchaninoff and Eric Durand have received a grant by the French Government, managed by the National Research Agency (ANR) under the program “Investissements d’avenir” with the reference ANR-16-RHUS-0003”

1. Baumgartner H, Falk V, Bax JJ, De Bonis M, Hamm C, Holm PJ, Iung B, Lancellotti P, Lansac E, Rodriguez Muñoz D, Rosenhek R, Sjögren J, Tornos Mas P, Vahanian A, Walther T, Wendler O, Windecker S, Zamorano JL; ESC Scientific Document Group. 2017 ESC/EACTS Guidelines for the management of valvular heart disease. *Eur Heart J* 2017;38:2739-2791.
2. Nishimura RA, Otto CM, Bonow RO, Carabello BA, Erwin JP 3rd, Fleisher LA, Jneid H, Mack MJ, McLeod CJ, O'Gara PT, Rigolin VH, Sundt TM 3rd, Thompson A. 2017 AHA/ACC Focused Update of the 2014 AHA/ACC Guideline for the Management of Patients With Valvular Heart Disease: A Report of the American College of Cardiology/American Heart Association Task Force on Clinical Practice Guidelines. *Circulation* 2017;135:e1159-1195.
3. Popma JJ, Deeb GM, Yakubov SJ, Mumtaz M, Gada H, O'Hair D, Bajwa T, Heiser JC, Merhi W, Kleiman NS, Askew J, Sorajja P, Rovin J, Chetcuti SJ, Adams DH, Teirstein PS, Zorn GL 3rd, Forrest JK, Tchétché D, Resar J, Walton A, Piazza N, Ramlawi B, Robinson N, Petrossian G, Gleason TG, Oh JK, Boulware MJ, Qiao H, Mugglin AS, Reardon MJ; Evolut Low Risk Trial Investigators. Transcatheter Aortic-Valve Replacement with a Self-Expanding Valve in Low-Risk Patients. *N Engl J Med* 2019;380:1706-1715.
4. Mack MJ, Leon MB, Thourani VH, Makkar R, Kodali SK, Russo M, Kapadia SR, Malaisrie SC, Cohen DJ, Pibarot P, Leipsic J, Hahn RT, Blanke P, Williams MR, McCabe JM, Brown DL, Babaliaros V, Goldman S, Szeto WY, Genereux P, Pershad A, Pocock SJ, Alu MC, Webb JG, Smith CR; PARTNER 3 Investigators.. Transcatheter Aortic-Valve Replacement with a Balloon-Expandable Valve in Low-Risk Patients. *N Engl J Med* 2019;380:1695-1705.
5. Génèreux P, Webb JG, Svensson LG, Kodali SK, Satler LF, Fearon WF, Davidson

CJ, Eisenhauer AC, Makkar RR, Bergman GW, Babaliaros V, Bavaria JE, Velazquez OC, Williams MR, Hueter I, Xu K, Leon MB; PARTNER Trial Investigators. Vascular complications after transcatheter aortic valve replacement: insights from the PARTNER (Placement of AoRTic TraNscathetER Valve) trial. *J Am Coll Cardiol* 2012;60:1043-1052.

6. Steinvil A, Leshem-Rubinow E, Halkin A, Abramowitz Y, Ben-Assa E, Shacham Y, Bar-Dayan A, Keren G, Banai S, Finkelstein A. Vascular complications after transcatheter aortic valve implantation and their association with mortality reevaluated by the valve academic research consortium definitions. *Am J Cardiol* 2015;115:10010-6.

7. Blanke P, Weir-McCall JR, Achenbach S, Delgado V, Hausleiter J, Jilaihawi H, Marwan M, Nørgaard BL, Piazza N, Schoenhagen P, Leipsic JA. Computed Tomography Imaging in the Context of Transcatheter Aortic Valve Implantation (TAVI)/Transcatheter Aortic Valve Replacement (TAVR): An Expert Consensus Document of the Society of Cardiovascular Computed Tomography. *JACC Cardiovasc Imaging* 2019;12:1-24.

8. Francone M, Budde RPJ, Bremerich J, Dacher JN, Loewe C, Wolf F, Natale L, Pontone G, Redheuil A, Vliegenthart R, Nikolaou K, Gutberlet M, Salgado R.. CT and MR imaging prior to transcatheter aortic valve implantation: standardisation of scanning protocols, measurements and reporting-a consensus document by the European Society of Cardiovascular Radiology (ESCR). *Eur Radiol* 2020;30:2627-2650.

9. Hayashida K, Lefèvre T, Chevalier B, Hovasse T, Romano M, Garot P, Mylotte D,

Uribe J, Farge A, Donzeau-Gouge P, Bouvier E, Cormier B, Morice MC. Transfemoral aortic valve implantation new criteria to predict vascular complications. *JACC Cardiovasc Interv* 2011;4:851-858.

10. Okuyama K, Jilaihawi H, Kashif M, Takahashi N, Chakravarty T, Pokhrel H, Patel J, Forrester JS, Nakamura M, Cheng W, Makkar RR. Transfemoral access assessment for transcatheter aortic valve replacement: evidence-based application of computed tomography over invasive angiography. *Circ Cardiovasc Imaging* 2015;8:e001995.

11. van Kesteren F, van Mourik MS, Vendrik J, Wiegerinck EMA, Henriques JPS, Koch

KT, Wykrzykowska JJ, de Winter RJ, Piek JJ, van Lienden KP, Reekers JA, Vis MM, Planken RN, Baan J Jr. Incidence, Predictors, and Impact of Vascular Complications After Transfemoral Transcatheter Aortic Valve Implantation With the SAPIEN 3 Prosthesis. *Am J Cardiol* 2018;121:1231-1238.

12. Cox N, Resnic FS, Popma JJ, Simon DI, Eisenhauer AC, Rogers C. Comparison of the Risk of Vascular Complications Associated With Femoral and Radial Access Coronary Catheterization Procedures in Obese Versus Nonobese Patients. *Am J Cardiol* 2004;94:1174–1177.

13. Cribier A, Eltchaninoff H, Bash A, Borenstein N, Tron C, Bauer F, Derumeaux G, Anselme F, Laborde F, Leon MB. Percutaneous transcatheter implantation of an aortic valve prosthesis for calcific aortic stenosis: first human case description. *Circulation* 2002;106:3006-3008.

14. Durand E, Borz B, Godin M, Tron C, Litzler PY, Bessou JP, Bejar K, Fraccaro C, Sanchez-Giron C, Dacher JN, Bauer F, Cribier A, Eltchaninoff H. Transfemoral aortic valve replacement with the Edwards SAPIEN and Edwards SAPIEN XT prosthesis

using exclusively local anesthesia and fluoroscopic guidance: feasibility and 30-day outcomes. *JACC Cardiovasc Interv* 2012;5:461-467.

15. Durand E, Blanchard D, Chassaing S, Gilard M, Laskar M, Borz B, Lafont A, Barbey C, Godin M, Tron C, Zegdi R, Chatel D, Le Page O, Litzler PY, Bessou JP, Danchin N, Cribier A, Eltchaninoff H. Comparison of two antiplatelet therapy strategies in patients undergoing transcatheter aortic valve implantation. *Am J Cardiol* 2014;113:355-360.

16. Abdul-Jawad Altisent O, Durand E, Muñoz-García AJ, Nombela-Franco L, Cheema

A, Kefer J, Gutierrez E, Benítez LM, Amat-Santos IJ, Serra V, Eltchaninoff H, Alnasser SM, Elízaga J, Dager A, García Del Blanco B, Ortas-Nadal Mdel R, Marsal JR, Campelo-Parada F, Regueiro A, Del Trigo M, Dumont E, Puri R, Rodés-Cabau J. Warfarin and Antiplatelet Therapy Versus Warfarin Alone for Treating Patients With Atrial Fibrillation Undergoing Transcatheter Aortic Valve Replacement. *JACC Cardiovasc Interv* 2016;9:1706-1717.

17. Kappetein AP, Head SJ, Génèreux P, Piazza N, van Mieghem NM, Blackstone EH,

Brott TG, Cohen DJ, Cutlip DE, van Es GA, Hahn RT, Kirtane AJ, Krucoff MW, Kodali S, Mack MJ, Mehran R, Rodés-Cabau J, Vranckx P, Webb JG, Windecker S, Serruys PW, Leon MB. Updated standardized endpoint definitions for transcatheter aortic valve implantation: the Valve Academic Research Consortium-2 consensus document. *Eur Heart J* 2012;33:2403–2418.

18. Benamer H, Louvard Y, Sanmartin M, Valsecchi O, Hildick-Smith D, Garot P, Narbute I, Hamon M, Ungi I, Monsegu J. A multicentre comparison of transradial and

transfemoral approaches for coronary angiography and PTCA in obese patients: the TROP registry. *EuroIntervention* 2007;3:327-332.

19. Sannino A, Schiattarella GG, Toscano E, Gargiulo G, Giugliano G, Galderisi M, Losi MA, Stabile E, Cirillo P, Imbriaco M, Grayburn PA, Trimarco B, Esposito G. Meta-Analysis of Effect of Body Mass Index on Outcomes After Transcatheter Aortic Valve Implantation. *Am J Cardiol* 2017;119:308-316.

20. Vidi VD, Matheny ME, Govindarajulu US, Normand SL, Robbins SL, Agarwal VV, Bangalore S, Resnic FS. Vascular closure device failure in contemporary practice. *JACC Cardiovasc Interv* 2012; 5: 837–844.

21. Chen IM, Lee TH, Chen PL, Shih CC, Chang HH. Factors in ProGlide Vascular Closure Failure in Sheath Arteriotomies Greater than 16 French. *Eur J Vasc Endovasc Surg* 2019;58:615-622.

22. Urbach J, Houa CR, Lesser JR, Stanberry LI, Garberich RF, Caye D, Sorajja P, Gössl M. Computed tomographic angiography-derived risk factors for vascular complications in percutaneous transfemoral transcatheter aortic valve implantation. *Am J Cardiol* 2019;124:98-104.

23. Genereux P, Kodali S, Leon MB, Smith CR, Ben-Gal Y, Kirtane AJ, Daneault B, Reiss GR, Moses JW, Williams MR. Clinical outcomes using a new crossover balloon occlusion technique for percutaneous closure after transfemoral aortic valve implantation. *JACC Cardiovasc Interv* 2011;4:861-867.

24. Bernardi FLM, Gomes WF, de Brito Jr F, Mangione JA, Sarmiento-Leite R, Siqueira D, Carvalho LA, Tumelero R, Guerios EE, Lemos PA. Surgical cutdown versus percutaneous access in transfemoral transcatheter aortic valve implantation: insights from the Brazilian TAVI registry. *Catheter Cardiovasc Interv* 2015 ;86 :501-505.

FIGURE LEGENDS

Figure 1. Axial CT slice passing through the geometric center of the femoral heads. First, a horizontal line was drawn between the ischial spines (green line). An orthogonal vertical line (green line) was drawn from this bi-ischiatic line and directed anteriorly. Another orthogonal horizontal line (pink) connected the vertical line to the geometric center of the common femoral artery that was used as a vascular access (the right one in the present case). Finally, a second vertical line (blue) was traced from the center point of the common femoral artery to the skin surface.

Figure 2. Study flow chart

Figure 3. Correlation between femoral artery depth and weight (A), body mass index (B), body area (C) and the height (D).

Figure 4. Distribution types of vascular complications. The rates of all vascular complications divided in access (blue) and non-access (orange) related vascular complications and major and minor vascular complications according to the VARC-2 definitions.

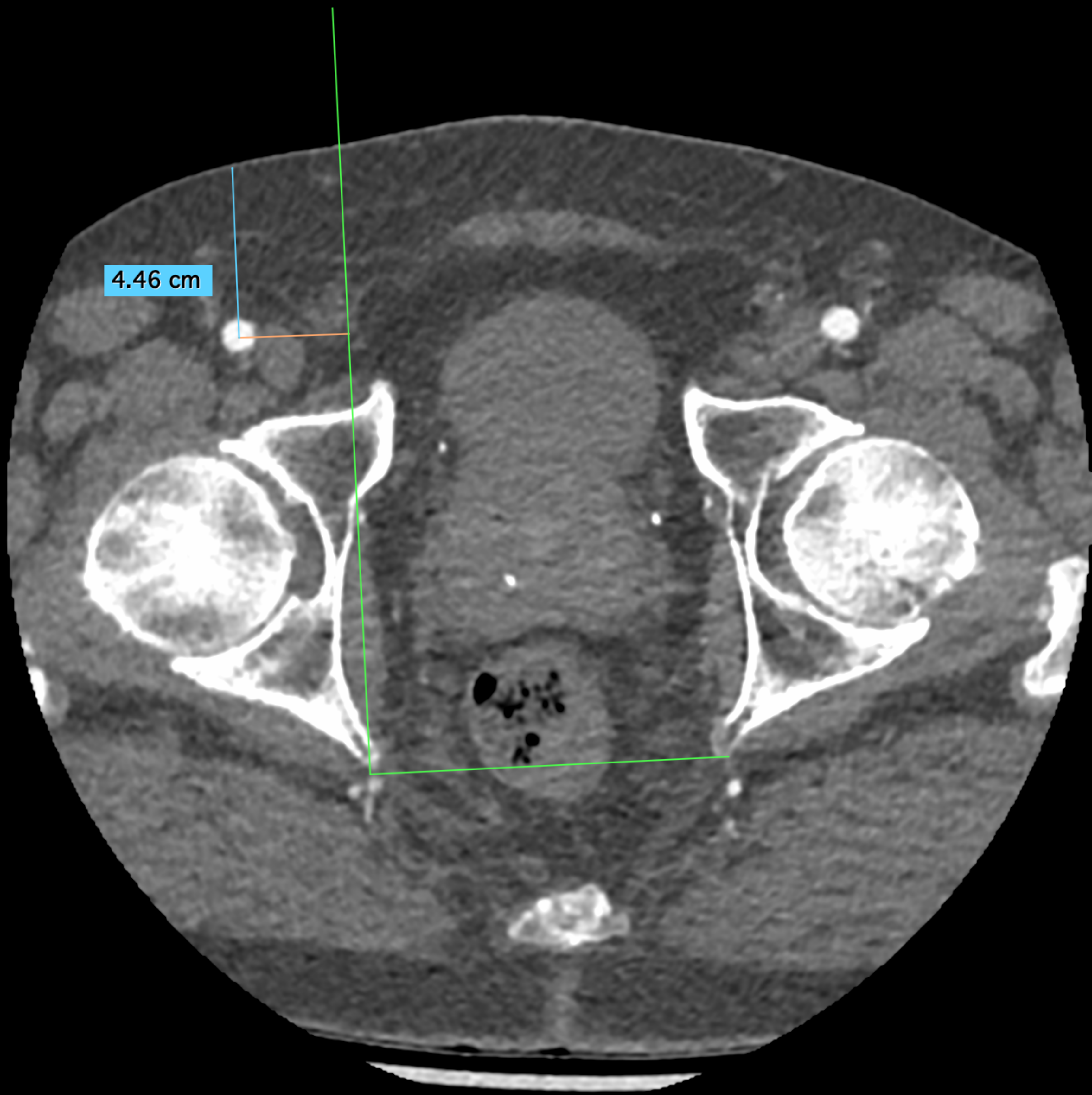
Figure 5. Scatter box plot of femoral artery depth (A), minimal femoral diameter (B), and SFAR (C) in patients whether they required or not a stent-graft for vascular complication.

Figure 6. Scatter box plot of femoral artery depth (A), minimal femoral diameter (B), and SFAR (C) in patients with or without major vascular complication

Figure 7. ROC curve analysis of SFAR (blue), femoral artery depth (green),

tortuosity (yellow), calcification (purple), sheath diameter (black) to predict the need for a stent-graft. The reference line is indicated in red.

Figure 8. ROC curve analysis of SFAR (blue), femoral artery depth (green), tortuosity (yellow), calcification (purple), sheath diameter (black) to predict major vascular complications. The reference line is indicated in red.



4.46 cm

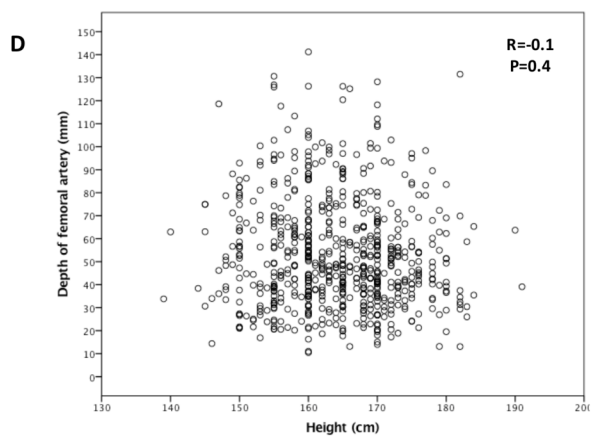
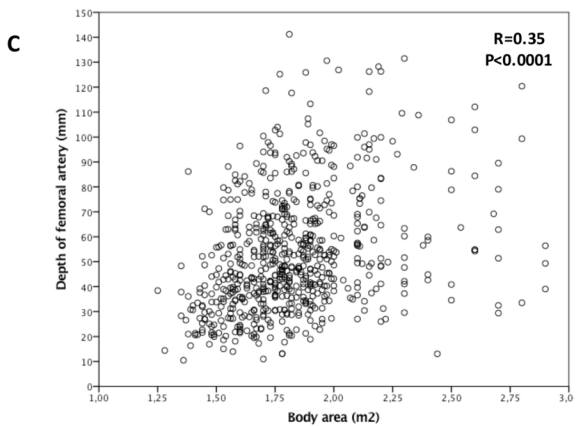
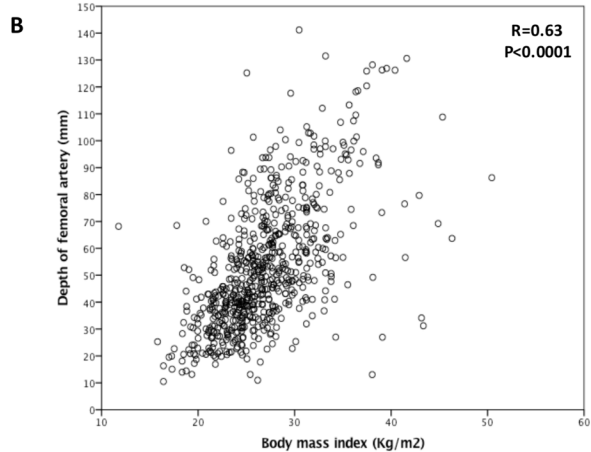
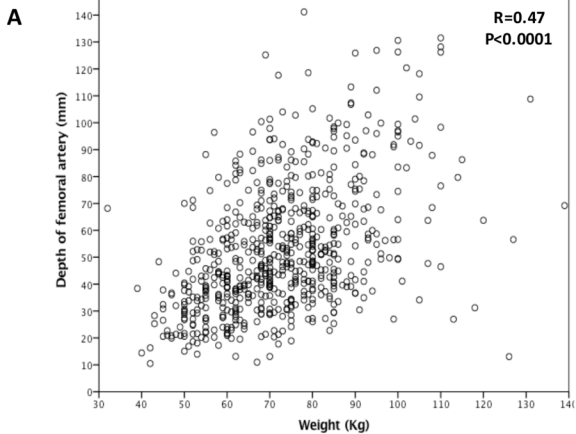
**1411 TAVR
patients**

```
graph TD; A["1411 TAVR patients"] --> B["182 non-femoral TAVR patients"]; A --> C["1229 femoral TAVR patients"]; C --> D["540 TF TAVR patients with an unusable CT"]; C --> E["689 TF TAVR patients with a usable CT"];
```

182 non-femoral
TAVR patients

540 TF TAVR
patients with an
unusable CT

**689 TF TAVR
patients with a
usable CT**

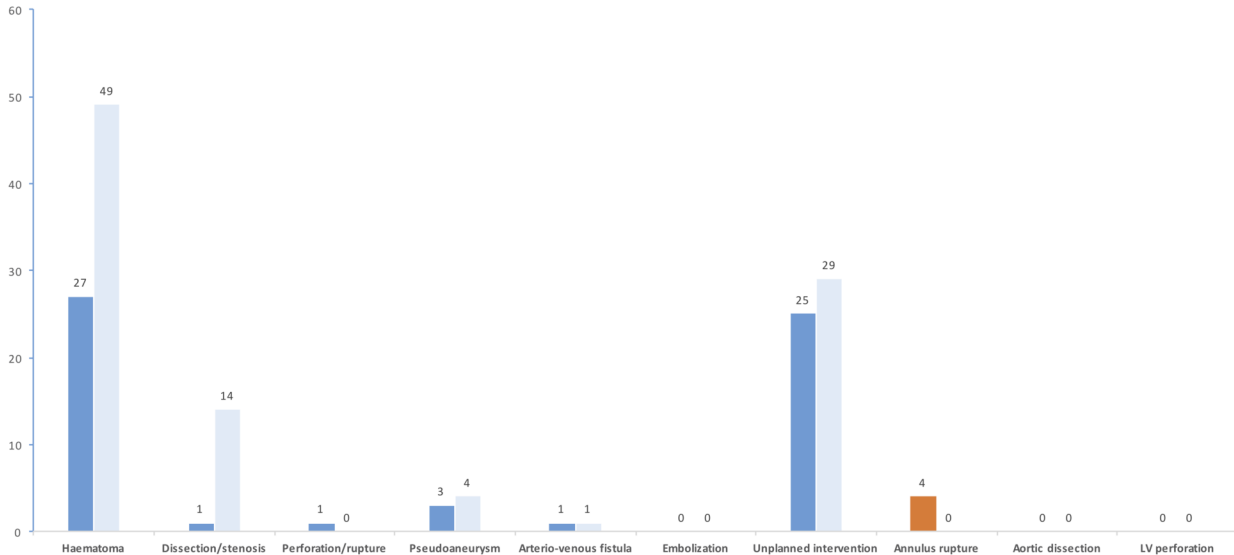


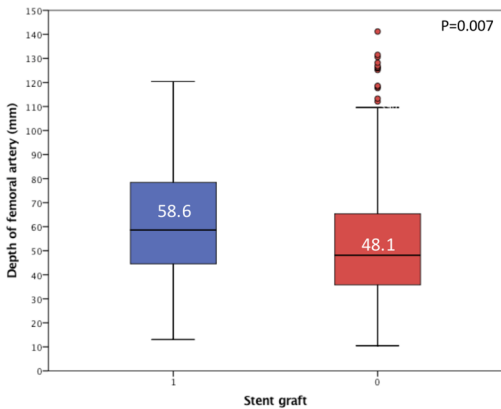
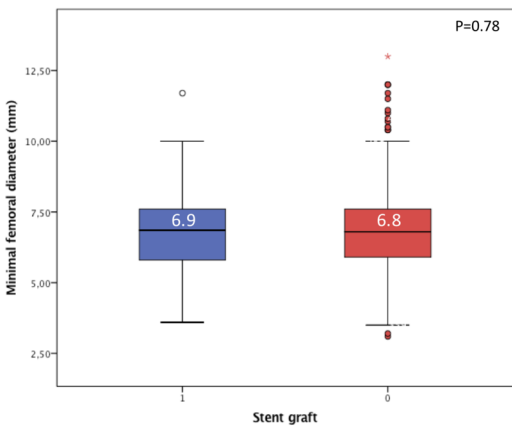
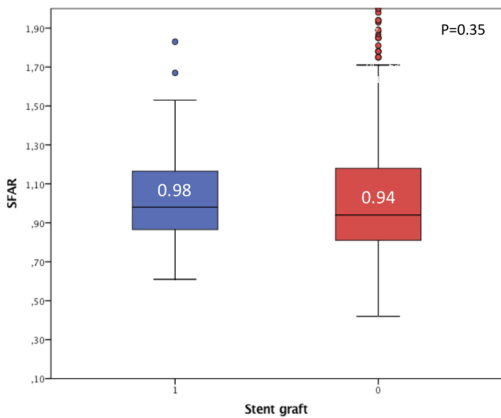
Access site or access-related vascular complication

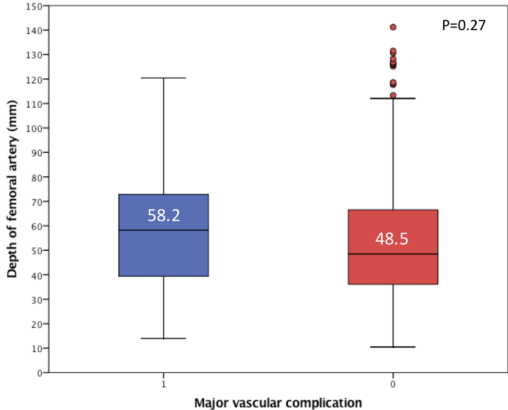
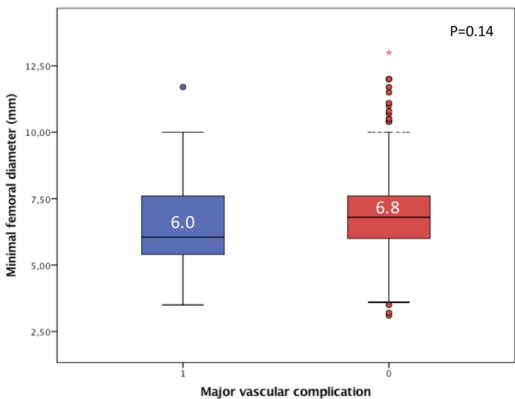
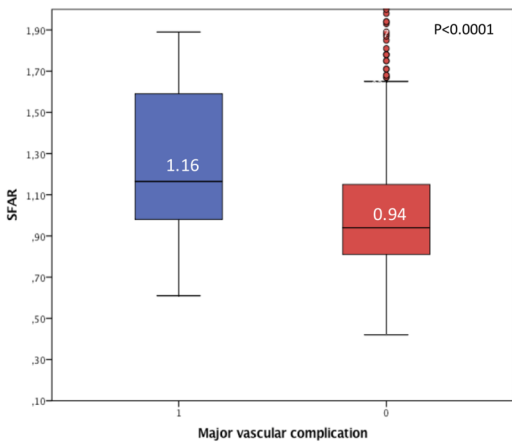
Major Minor

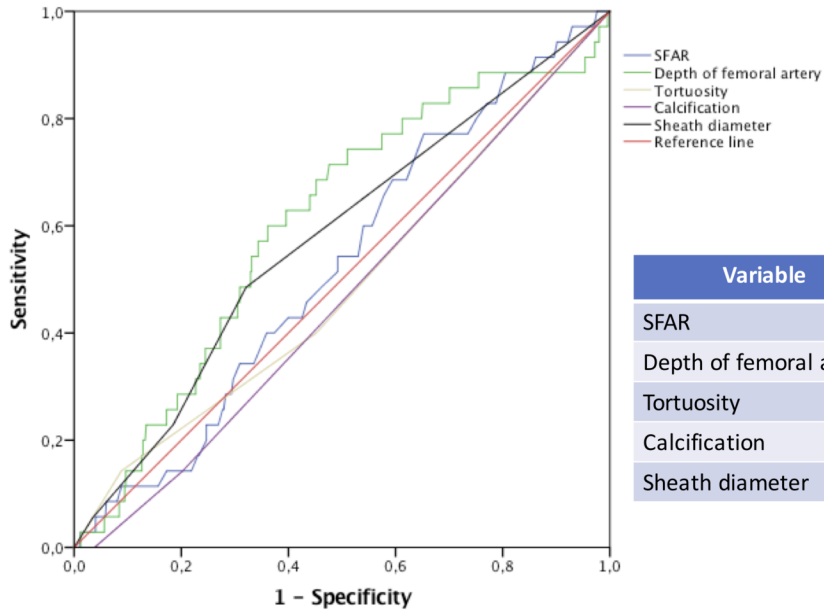
Non access site or access-related vascular complication

Major Minor

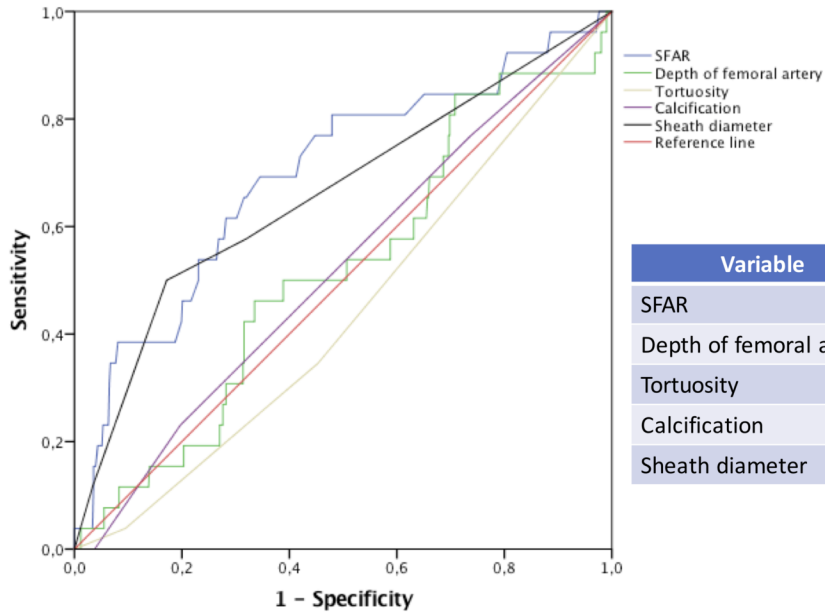


A**B****C**

A**B****C**



Variable	AUC	CI 95%	P
SFAR	0.53	0.43 – 0.62	0.61
Depth of femoral artery	0.61	0.51 – 0.70	0.04
Tortuosity	0.49	0.38 – 0.59	0.82
Calcification	0.46	0.37 – 0.56	0.48
Sheath diameter	0.57	0.48 – 0.67	0.14



Variable	AUC	CI 95%	P
SFAR	0.70	0.58 – 0.81	0.001
Depth of femoral artery	0.52	0.40 – 0.63	0.76
Tortuosity	0.44	0.33 – 0.55	0.29
Calcification	0.52	0.41 – 0.63	0.72
Sheath diameter	0.66	0.54 – 0.78	0.006

Table 1. Baseline characteristics

Characteristics	Overall Population (N=689)
Age (years)	83.9 ± 6.0
Men	311 (45.8%)
Weight (Kg)	71 (62-82)
Height (cm)	165 (158-170)
Body mass index (Kg/m²)	26.5 (23.8-29.7)
Body area (m²)	1.79 (1.65-1.94)
Hypertension	536 (78.9%)
Diabetes mellitus	199 (29.3%)
Dyslipidemia	406 (59.8%)
Prior myocardial infarction	60 (8.8%)
Prior coronary angioplasty	154 (22.7%)
Prior coronary bypass	35 (5.2%)
Atrial fibrillation	236 (34.7%)
Peripheral vascular disease	60 (8.8%)
History of stroke	57 (8.4%)
History of neoplasia	123 (18.1%)
Logistic EuroSCORE (%)	15.4 ± 8.9
Creatinine clearance (ml/ m²)	49.7 ± 20.8
NYHA class	
I	45 (6.6%)
II	253 (36.9%)
III	342 (49.9%)
IV	39 (5.7%)
Aortic valve area (cm²)	0.73 ± 0.21
Median aortic gradient (mmHg)	45.0 ± 14.9
Left ventricular ejection fraction (%)	60.4 ± 13.1
Systolic pulmonary artery pressure (mmHg)	38.5 ± 13.5

Table 2. Computed Tomography analysis of the ilio-femoral axis.

Characteristics	Overall Population (N=689)
Tortuosity	
- Absent or mild	381 (55.3%)
- Moderate	247 (35.8%)
- Severe	61 (8.8%)
Calcium	
- Absent	184 (26.7%)
- < 30%	372 (54.0%)
- 30-50%	110 (16.0%)
- > 50%	23 (3.3%)
Minimal femoral diameter (mm)	6.8 (5.9-7.6)
Femoral artery depth (mm)	49.0 (36.2-66.7)
SFAR	0.95 (0.81-1.18)

Abbreviations. SFAR: sheath-to-femoral-artery ratio

Table 3. Predictors of the need for a stent graft

Variables	HR	CI 95%	P
SFAR	0.77	0.14–4.34	0.77
Tortuosity	1.01	0.60–1.71	0.97
Calcification	0.81	0.50– .32	0.40
Sheath diameter	1.23	0.93– .64	0.15
Minimal femoral diameter	0.96	0.65–1.41	0.83
Femoral artery depth	1.02	1.00–1.04	0.048

Abbreviations. SFAR: sheath femoral artery ratio

Table 4. Predictors of major vascular complications

Variables	HR	CI95%	P
SFAR	8.86	1.42–55.24	0.02
Tortuosity	0.64	0.32–1.28	0.21
Calcification	1.00	0.58–1.73	0.99
Sheath diameter	1.09	0.80–1.49	0.58
Minimal femoral diameter	1.32	0.81–2.14	0.26
Femoral artery depth	1.00	0.98–1.02	0.86

Abbreviations. SFAR: sheath femoral artery ratio