



Dental and maxillofacial features of condylo-mandibular dysplasia: A case series of 21 patients

Hélios Bertin, Fanny-Laure Merlet, Roman-Hossein Khonsari, Jean Delaire, Pierre Corre, Jacques Mercier

► To cite this version:

Hélios Bertin, Fanny-Laure Merlet, Roman-Hossein Khonsari, Jean Delaire, Pierre Corre, et al.. Dental and maxillofacial features of condylo-mandibular dysplasia: A case series of 21 patients. Journal of Cranio-Maxillofacial Surgery, 2020, S1010-5182 (20), pp.30172-4. 10.1016/j.jcms.2020.07.007 . inserm-02915066

HAL Id: inserm-02915066

<https://inserm.hal.science/inserm-02915066>

Submitted on 17 Oct 2022

HAL is a multi-disciplinary open access archive for the deposit and dissemination of scientific research documents, whether they are published or not. The documents may come from teaching and research institutions in France or abroad, or from public or private research centers.

L'archive ouverte pluridisciplinaire **HAL**, est destinée au dépôt et à la diffusion de documents scientifiques de niveau recherche, publiés ou non, émanant des établissements d'enseignement et de recherche français ou étrangers, des laboratoires publics ou privés.



Distributed under a Creative Commons Attribution - NonCommercial 4.0 International License

TITLE

Dental and maxillofacial features of condylo-mandibular dysplasia: a case series of 21 patients

AUTHORS, TITLES, AND AFFILIATIONS

Hélios Bertin^{a,b} (MD, PhD student)

helios.bertin@chu-nantes.fr

Fanny-Laure Merlet^a (MD)

fannylaure.merlet@chu-nantes.fr

Roman-Hossein Khonsari^c (MD, PhD)

roman.khonsari@aphp.fr

Jean Delaire^a (MD)

pr.j.delaire@wanadoo.fr

Pierre Corre^{a,d} (MD, PhD)

pierre.corre@chu-nantes.fr

Jacques Mercier^a (MD)

jacques.mercier@chu-nantes.fr

^a*Service de Chirurgie Maxillo-faciale et Stomatologie, CHU de Nantes, 1 place Alexis Ricordeau, 44093 Nantes Cedex 1, France*

^b*Laboratoire des Sarcomes Osseux et Remodelage des Tissus Calcifiés (Phy.OS), UMR 1238, Faculté de Médecine, 1 rue Gaston Veil, 44035 Nantes Cedex, France*

^c*Chirurgie Maxillo-faciale et Plastique Pédiatrique, Hôpital Necker Enfants Malades, 149 rue de Sèvres, 75015 Paris, France*

^d*Regenerative Medicine and Skeleton (RMeS), Faculté de Chirurgie Dentaire, 1 Place Alexis Ricordeau, 44042 Nantes, France*

CORRESPONDING AUTHOR

Hélios Bertin (MD, PhD student)

Service de Chirurgie Maxillo-faciale et Stomatologie, CHU de Nantes, 1 place Alexis
Ricordeau, 44093 Nantes Cedex 1, France

Tel : +33 240 08 36 79

Fax: +33 240 08 36 68

helios.bertin@chu-nantes.fr

The authors declare to have no financial disclosures or conflicts of interest regarding this manuscript.

Dental and maxillofacial features of condylo-mandibular dysplasia: a case series of 21 patients

ABSTRACT

Introduction: Camel-hump condylo-mandibular dysplasia is a specific form of condyle dysostosis, first described by Delaire. The aim of this study was to describe the clinical and radiographic phenotype of the disease, and to discuss therapeutic options.

Case series: Twenty-one patients were analyzed retrospectively. They exhibited the same unilateral facial asymmetry, which was of mandibular origin, with an elevated commissural line and occlusal cant, and a deviated chin on the side of the deformity. The soft tissues and the ears were always normal in terms of their physical appearance. Radiographic analysis generally revealed a short, curved, and anteriorly displaced condyle, with a high and sharp coronoid process. CT scans revealed that the glenoid fossa was empty. Twelve patients exhibited dental abnormalities, consisting mainly of dental inclusions affecting the lower first and/or second molars (10 patients). A good response to functional orthodontic treatment was achieved in eight patients, while 13 patients required a surgical mandibular lengthening procedure.

Conclusion: Condylo-mandibular dysplasia is a congenital condyle deformity that needs to be recognized and differentiated from craniofacial microsomia in order to be able to provide patient-specific treatments.

KEYWORDS

malocclusion; mandibular condyle; mandibular osteotomy; orthognathic surgery; craniofacial microsomia

INTRODUCTION

Deformities of the mandibular condyle and its related structures are due to a number of factors (Kaneyama *et al.*, 2008). Condyle defects range from hypoplasia or aplasia to hyperplasia and bifidity, and can be divided into either congenital or acquired etiologies (Kaneyama *et al.*, 2008; Singh and Bartlett, 2005). Among the various congenital malformations in humans, craniofacial microsomia is a common cause of condyle hypoplasia. This type of mandibular deformation is associated with ear defects, facial soft-tissue hypoplasia, and facial and systemic malformations (Bertin *et al.*, 2017; Cohen *et al.*, 2017; Bragagnolo *et al.*, 2018).

The posterior vertical growth of the mandible depends on the growth of the condylar unit (Ferri *et al.*, 2006). A mandibular posterior vertical insufficiency syndrome is, therefore, commonly observed in patients with anomalies of the condyle (Mercier *et al.*, 1989). Unilateral posterior vertical insufficiency is characterized by a shortening of the mandibular ramus, which causes asymmetry of the lower third of the face. The commissural line is often elevated, while the chin is deviated on the affected side. An elevation of the maxillary occlusal cant is observed, as well as dental class II malocclusion on the affected side.

Camel-hump condylo-mandibular dysplasia is a rare and specific form of condyle dysostosis, first described by Delaire in 1988 (Delaire, 1988; Delaire, 1991). The deformation takes its name from the typical radiological presentation of the condylar unit (Ferri *et al.*, 2006). There have been very few reports to date of condylo-mandibular dysplasia in the literature. As highlighted by Meazzini *et al.* (Meazzini *et al.*, 2008), a casual example of condylo-mandibular dysplasia was published in the form of 'misdiagnosed' hemifacial microsomia, characterized by successful orthodontic treatment despite substantial condyle deformities (Figueroa *et al.*, 1984; Kaplan *et al.*, 1989; Melsen *et al.*, 1986; Sidiropoulou *et al.*, 2003; Silvestri *et al.*, 1996; Kahl-Nieke and Fischbach, 1998). The main differences between condylo-mandibular dysplasia and craniofacial microsomia are the permanent absence of soft-tissue involvement and a normal appearance of the ears (Meazzini *et al.*, 2011).

The purpose of this case-series study was to refine descriptions of the clinical and radiographic features of condylo-mandibular dysplasia, and to discuss the therapeutic options.

CASE SERIES

Clinical findings

Twenty-one patients were analysed (12 females, nine males). Patient characteristics, clinical and radiological findings, treatments and follow-up are listed in Table 1. The mean age at the time of diagnosis was 7.5 ± 2.18 years (5–11 years). All of the patients exhibited the same clinical phenotype, consisting of facial asymmetry of mandibular origin (left side: 10, right side: 11). Clinical examination revealed mandibular unilateral posterior vertical insufficiency. Intra-oral examination showed elevation of the maxillary occlusal cant, and a class II malocclusion angle toward the condyle deformity (Figures 1a, 1b, 2a, and 2b). The function of the temporomandibular joint (TMJ) was preserved in terms of motion, while the mouth opening deviated towards the affected side. In all patients studied, the mandibular malformation was isolated, with no soft tissue involvement and no ear malformations. Medical histories revealed that the facial asymmetry became noticeable at approximately 3 years of age, with the deformity then becoming more pronounced during childhood. No family histories of congenital condyle disease were found. Three patients exhibited a condyle trauma in childhood, with no evidence of mandibular fracture.

Imaging

Radiographic presentation on the panoramic X-rays was pathognomonic of the disease. The condyle was curved, shortened in its vertical dimension, and anteriorly displaced immediately under the articular tubercle of the temporal bone. The coronoid process was higher and sharp, while the sigmoid notch was replaced by a deep vertical split. The mandibular ramus was short, with a bulging and elevated angle (Figure 3). A craniofacial CT scan or cone-beam CT was available for seven patients. This revealed the presence of a flattened, empty glenoid fossa behind the malformed condyle (Figure 3).

Periodic radiographic follow-up with panoramic X-rays revealed the presence of dental abnormalities in 12 patients on the side of the condyle deformity. These consisted of a tooth inclusion involving the first (three cases) or second (three cases) permanent lower molars, or both lower molars (four cases). One patient exhibited dental agenesis of the second lower molar, while another patient suffered from delayed tooth eruption of the first lower molar (Figure 4).

Treatment

All of the patients underwent early functional orthodontic treatment with various devices consisting of a palate splint that promoted growth of the hypoplastic condyle. By applying propulsion and contralateral diduction movements, the orthodontic treatment was satisfactory in eight patients, with no need for surgical intervention. Clinically, the efficacy of the orthodontic treatment was based on the recovery of normal symmetry of the face, with a horizontalized commissural line and a balanced chin (Figure 1). Radiographically, panoramic X-rays showed that the orthodontic treatment resulted in spontaneous growth of the malformed condyle and a progressive recovery of a normal position in the glenoid fossa until completion of growth (Figure 1). A secondary multiband orthodontic alignment was often necessary to correct the class II malocclusion.

Thirteen patients underwent mandibular surgery after failure of the orthodontic treatment. This consisted of vertical lengthening of the hypoplastic ramus using a costochondral graft (GCG) (six cases) (Figure 2), or a vertical ramus osteotomy (VRO) according to the Caldwell-Letterman technique (five cases). An extraoral approach was performed by means of a low submandibular incision, associated with an intraoral incision for muscular detachment and coronoidectomy. A posterior open bite was created on the affected side and an interocclusal splint was put in place and progressively reduced in height to promote secondary maxillary teeth egression. One patient underwent a bimaxillary approach for overall correction of facial asymmetry. Another patient was treated using a proportional condylectomy to correct a condyle hyperplasia on the malformed condyle secondary to the orthodontic device. The mean age at the time of mandibular lengthening was 12.0 ± 3.7 years. The postoperative follow-up indicated that none of the patients experienced complications. Normal occlusion was restored by spontaneous closure of the open bite with maxillary teeth egression. The surgical results remained stable over time in most of the patients, with a mean follow-up of 9.1 ± 4.7 years. Two patients (No. 3 and No. 7) exhibited partial recurrence of the PVI with no secondary procedure, while for one patient no follow-up data were available.

DISCUSSION

Mandibular condyle and ramus hypoplasia is a well-known craniofacial malformation. It can be classified as a congenital or an acquired deformity according to the developmental circumstances (Kaneyama *et al.*, 2008; Ferri *et al.*, 2006; Mercier *et al.*, 1989; Galea *et al.*, 2018). The most frequently described acquired etiologies are TMJ remodeling after a condyle fracture, TMJ ankylosis, and juvenile idiopathic arthritis (Resnick *et al.*, 2019; Stoor *et al.*, 2018). Congenital causes are dominated by craniofacial deformations of the structures derived from the first and the second branchial arches, such as with craniofacial microsomia (Mercier *et al.*, 1989).

Camel-hump condylo-mandibular dysplasia is a rare congenital condition, first described by Delaire (Delaire, 1988; Delaire, 1991). Various examples of the deformation can be found in the literature. These are described as cases of hemifacial microsomia with a good response to orthodontic treatment (Figuerola *et al.*, 1984; Kaplan, 1989; Melsen *et al.*, 1986; Sidiropoulou *et al.*, 2003; Silvestri *et al.*, 1996; Kahl-Nieke and Fischbach, 1998). Various books have also documented these misdiagnosed cases of hemifacial microsomia with typical radiographic presentations of condylo-mandibular dysplasia (Bell, 1992; Booth *et al.*, 1999; Tessier, 2001). The disease differs from craniofacial microsomia by the permanent absence of soft tissue involvement and the presence of normal-looking ears (Meazzini *et al.*, 2008), while ear deformations (83.2–100%) and soft tissue defects (92–100%) are frequently observed in patients with craniofacial microsomia, and often correlated with the degree of mandibular hypoplasia (Bertin *et al.*, 2017; Cohen *et al.*, 2017; Bragagnolo *et al.*, 2018). Furthermore, radiographic presentation of the condylar unit is pathognomonic of the disease, with deformation of the condyle and the coronoid process presenting as a double hump reminiscent of the back of a camel, hence the name camel-hump condylo-mandibular dysplasia.

Our study described the largest series to date of condylo-mandibular dysplasia, and its complete clinical and radiographic phenotype. Our results were in keeping with those of Meazzini *et al.* who published a case series of nine patients with condylo-mandibular dysplasia and long-term follow-up (Meazzini *et al.*, 2011). Our study highlighted a high rate of dental abnormalities (57.1%), mainly consisting of tooth inclusion of the first and/or second lower molars. Most of these dental anomalies required tooth extraction. In craniofacial microsomia the dental anomalies have been shown to mainly consist of delayed dental development of the lower molars, which correlates with the degree of condyle deformity (Ongkosuwito *et al.*, 2010; Ahiko *et*

al., 2015), with dental agenesis ranging from 6.7% to 32% (Maruko *et al.*, 2001). Dental anomalies thus represent a means for differential diagnosis of condylo-mandibular dysplasia versus craniofacial microsomia.

CT scan analysis carried out in seven patients revealed the presence of an empty glenoid fossa, while the temporal fossa can be absent in craniofacial microsomia. All of the clinical and radiographic features that differentiate the two pathologies are listed in Table 2. Despite these differences between the two pathologies, it is evident that most cases of condylo-mandibular dysplasia are diagnosed and treated as type IIA craniofacial microsomia.

Craniofacial microsomia is a developmental disorder that affects the head and neck structures derived from the first and second branchial arches, as evidenced by various defects of the mandible, the ears, and facial soft tissues (Bertin *et al.*, 2017). Although craniofacial microsomia is a multifactorial disease, it is generally thought that the deformity is due to a multitude of anomalies in the migration of neural crest cells during the fifth and the sixth week of embryonic development. The pathophysiology of condylo-mandibular dysplasia remains unknown. It appears to differ from craniofacial microsomia in that the deformity is limited to the mandibular condyle, without extra-facial abnormalities. The posterior vertical growth of the mandible is determined by the condylar unit (Ferri *et al.*, 2006). The condylar growth plate has a genomic potential to grow, and it is also responsive to hormonal and functional factors (jaw function, lateral pterygoid muscle). As a result, a defect of the condylar unit can induce a disorder of the posterior vertical dimension of the face, with variable dentoalveolar compensation of the maxillary bone (Ferri *et al.*, 2006).

Treatment of condylo-mandibular dysplasia requires a multidisciplinary approach. Affected children should undergo early orthodontic treatment because the malformed condyle retains a functional growth potential, thus making it possible to correct the facial asymmetry. In our experience, more than a third of the patients were treated successfully by use of an early functional device, exhibiting a high degree of growth and spontaneous repositioning of the condyle in the glenoid fossa. Most activators consist of a palatal device that promotes propulsion and diduction contralateral to the hypoplastic condyle. Multiband orthodontics allow for secondary dental alignment. In cases of failure or residual asymmetry after the orthodontic phase, a surgical approach is necessary to restore facial symmetry. Surgical treatment aims not only to achieve facial symmetry and normal occlusion, but also functional and esthetic

outcomes after the completion of growth. Ramus reconstruction can be managed by distraction osteogenesis (DO) or orthognathic ramus elongation procedures. In our experience, the Caldwell-Letterman VRO technique allows for single-stage correction of the ramus height and remains an option in children because it does not interfere with mandibular growth (Anquetil *et al.*, 2020). This procedure provides correction of maxillary occlusal canting by spontaneous dentoalveolar adaptation to the generated open bite. Other orthognathic procedures have been described to lengthen the mandibular ramus without the use of an extraoral approach; these include an inverted-L osteotomy (Medeiros and Ritto, 2009), an Epker-Wolford modified osteotomy with complete sectioning of the pterygomasseteric sling (Ferri *et al.*, 2008), and lowering of the mandibular angle (Grimaud *et al.*, 2017). Six patients in our series underwent a CCG to elongate the ramus in light of the good results that we obtained with this procedure in craniofacial microsomia (Bertin *et al.*, 2017). However, a CCG has to be reserved for replacement of an absent or non-functional TMJ (Bertin *et al.*, 2017; Al-Moraissi *et al.*, 2015), which is not the case in condylo-mandibular dysplasia. Irrespective of the treatment performed, the patients should be managed by a multidisciplinary team, and the clinical follow-up should last until the completion of growth.

CONCLUSION

Condylo-mandibular dysplasia is a particular type of congenital condyle deformity. It needs to be differentiated from craniofacial microsomia in order to be able to provide early, patient-specific orthodontic treatment and a potential secondary orthognathic procedure for ramus lengthening.

REFERENCES

- Ahiko N, Baba Y, Tsuji M, Suzuki S, Kaneko T, Kindaichi J, Moriyama K. Investigation of maxillofacial morphology and dental development in hemifacial microsomia. *The Cleft Palate-Craniofacial Journal* 52 (2): 203–9. <https://doi.org/10.1597/13-179>, 2015.
- Al-Moraissi EA, El-Sharkawy TM, Mounair RM, El-Ghareeb TI. A systematic review and meta-analysis of the clinical outcomes for various surgical modalities in the management of temporomandibular joint ankylosis. *International Journal of Oral and Maxillofacial Surgery* 44 (4): 470–82. <https://doi.org/10.1016/j.ijom.2014.10.017>, 2015.
- Anquetil M, Mercier J, Leveau S, Mrabet S, Durand T, Salagnac JM, Perrin JP, Corre P, Bertin H. Evaluation of vertical ramus osteotomy for the surgical correction of unilateral mandibular posterior vertical insufficiency: long-term follow-up

- results. *Journal of Cranio-Maxillo-Facial Surgery*.
<https://doi.org/10.1016/j.jcms.2020.02.013>, 2020.
- Bell WH. *Modern practice in orthognathic and reconstructive surgery: volume 2*. Edited by William H. Bell. 1992.
- Bertin H, Mercier J, Cohen A, Giordanetto J, Cohen N, Lee SH, Perrin JP, Corre P. Surgical correction of mandibular hypoplasia in hemifacial microsomia: a retrospective study in 39 patients. *Journal of Cranio-Maxillo-Facial Surgery* 45 (6): 1031–38. <https://doi.org/10.1016/j.jcms.2017.03.016>, 2017
- Booth PW, Hausamen JE, Schendel SA. *Maxillofacial Surgery*. Vol. 2. Churchill Livingstone, 1999.
- Bragagnolo S, Colovati MES, Souza MZ, Dantas AG, de Soares MFF, Melaragno MI, Perez AB. Clinical and cytogenomic findings in OAV spectrum. *American Journal of Medical Genetics Part A* 176 (3): 638–48. <https://doi.org/10.1002/ajmg.a.38576>, 2018.
- Cohen N, Cohen E, Gaiero A, Zecca S, Fichera G, Baldi F, Giordanetto JF, Mercier JM, Cohen A. Maxillofacial features and systemic malformations in expanded spectrum hemifacial microsomia. *American Journal of Medical Genetics Part A* 173 (5): 1208–18. <https://doi.org/10.1002/ajmg.a.38151>, 2017.
- Delaire J. The occlusal plane and maxillo-facial surgery. *Orthodontie Française* 59: 811–90, 1988.
- Delaire J. *Pathologie du développement céphalique et syndromes malformatifs craniofaciaux*. Traité de pathologies buccale et maxillo-faciale, Chapitre 2. Piette R (ed.): De Boeck Université, 1991.
- Ferri J, Carneiro JM, Lemiere E, Vereecke F, Baralle MM. Severe congenital hypoplasia of the mandibular condyle-diagnosis and treatment: a report of 2 cases. *Journal of Oral and Maxillofacial Surgery* 64 (6): 972–80. <https://doi.org/10.1016/j.joms.2006.02.019>, 2006.
- Ferri J, Ricard D, Genay A. Posterior vertical deficiencies of the mandible: presentation of a new corrective technique and retrospective study of 21 cases. *Journal of Oral and Maxillofacial Surgery* 66 (1): 35–44. <https://doi.org/10.1016/j.joms.2007.06.657>, 2008.
- Figueroa AA, Gans BJ, Pruzansky S. Long-term follow-up of a mandibular costochondral graft. *Oral Surgery, Oral Medicine, and Oral Pathology* 58 (3): 257–68, 1984.
- Galea CJ, Dashow JE, Woerner JE. Congenital abnormalities of the temporomandibular joint. *Oral and Maxillofacial Surgery Clinics of North America* 30 (1): 71–82. <https://doi.org/10.1016/j.coms.2017.09.003>, 2018.
- Grimaud F, Bertin H, Fauvel F, Corre P, Perrin JP. Vertical ramus elongation and mandibular advancement by endobuccal approach: presentation of a new osteotomy technique. *Journal of Stomatology, Oral and Maxillofacial Surgery* 118 (1): 66–69. <https://doi.org/10.1016/j.jormas.2016.12.003>, 2017.
- Kahl-Nieke B, Fischbach R. Effect of early orthopedic intervention on hemifacial microsomia patients: an approach to a cooperative evaluation of treatment results. *American Journal of Orthodontics and Dentofacial Orthopedics* 114 (5): 538–50. [https://doi.org/10.1016/s0889-5406\(98\)70174-x](https://doi.org/10.1016/s0889-5406(98)70174-x), 1998.
- Kaneyama K, Segami N, Hatta T. Congenital deformities and developmental abnormalities of the mandibular condyle in the temporomandibular joint. *Congenital Anomalies* 48 (3): 118–25. <https://doi.org/10.1111/j.1741-4520.2008.00191.x>, 2008.

- Kaplan RG. Induced condylar growth in a patient with hemifacial microsomia. *The Angle Orthodontist* 59 (2): 85–90. [https://doi.org/10.1043/0003-3219\(1989\)0590085:ICGIAP2.0.CO;2](https://doi.org/10.1043/0003-3219(1989)0590085:ICGIAP2.0.CO;2), 1989.
- Maruko E, Hayes C, Evans CA, Padwa B, Mulliken JB. Hypodontia in hemifacial microsomia. *The Cleft Palate-Craniofacial Journal* 38 (1): 15–19. https://doi.org/10.1597/1545-1569_2001_038_0015_hihm_2.0.co_2, 2001.
- Meazzini MC, Caprioglio A, Garattini G, Lenatti L, Poggio CE. Hemandibular hypoplasia successfully treated with functional appliances: is it truly hemifacial microsomia? *The Cleft Palate-Craniofacial Journal* 45 (1): 50–56. <https://doi.org/10.1597/06-201.1>, 2008.
- Meazzini MC, Brusati R, Caprioglio A, Diner P, Garattini G, Giannì E, Lalatta F. True hemifacial microsomia and hemimandibular hypoplasia with condylar-coronoid collapse: diagnostic and prognostic differences. *American Journal of Orthodontics and Dentofacial Orthopedics* 139 (5): e435–447. <https://doi.org/10.1016/j.ajodo.2010.01.034>, 2011.
- Meazzini MC, Mazzoleni F, Bozzetti A, Brusati R. Does functional appliance treatment truly improve stability of mandibular vertical distraction osteogenesis in hemifacial microsomia? *Journal of Cranio-Maxillo-Facial Surgery* 36 (7): 384–89. <https://doi.org/10.1016/j.jcms.2008.03.002>, 2008.
- Medeiros PJ, Ritto F. Indications for the inverted-L osteotomy: report of 3 cases. *Journal of Oral and Maxillofacial Surgery* 67 (2): 435–44. <https://doi.org/10.1016/j.joms.2008.06.037>, 2009.
- Melsen B, Bjerregaard J, Bundgaard M. The effect of treatment with functional appliance on a pathologic growth pattern of the condyle. *American Journal of Orthodontics and Dentofacial Orthopedics* 90 (6): 503–12, 1986.
- Mercier J, Gordeeff A, Delaire J. Syndrome of unilateral posterior vertical insufficiency of the face. Clinical and therapeutic aspects. *Acta Stomatologica Belgica* 86 (1): 13–32, 1989.
- Ongkosuwito EM, de Gijt P, Wattel E, Carels CEL, Kuijpers-Jagtman AM. Dental development in hemifacial microsomia. *Journal of Dental Research* 89 (12): 1368–72. <https://doi.org/10.1177/0022034510378425>, 2010.
- Resnick CM, Frid P, Norholt SE, Stoustrup P, Peacock ZS, Kaban LB, Klit Pedersen T, Abramowicz S; Temporomandibular Joint Juvenile Arthritis (TMJaw) Working Group. An algorithm for management of dentofacial deformity resulting from juvenile idiopathic arthritis: results of a multinational consensus conference. *Journal of Oral and Maxillofacial Surgery* 77 (6): 1152.e1–1152.e33. <https://doi.org/10.1016/j.joms.2019.02.014>, 2019.
- Sidiropoulou S, Antoniadou K, Kolokithas G. Orthopedically induced condylar growth in a patient with hemifacial microsomia. *The Cleft Palate-Craniofacial Journal* 40 (6): 645–50. https://doi.org/10.1597/1545-1569_2003_040_0645_oicgia_2.0.co_2, 2003.
- Silvestri A, Natali G, Iannetti G. Functional therapy in hemifacial microsomia: therapeutic protocol for growing children. *Journal of Oral and Maxillofacial Surgery* 54 (3): 271–78; discussion 278–80, 1996.
- Singh DJ, Bartlett SP. Congenital mandibular hypoplasia: analysis and classification. *The Journal of Craniofacial Surgery* 16 (2): 291–300, 2005.
- Stoor P, Hodzic Z, Arte S. Surgical treatment of dentofacial deformities caused by juvenile idiopathic arthritis. *The Journal of Craniofacial Surgery* 29 (1): e51–57. <https://doi.org/10.1097/SCS.00000000000004029>, 2018.

CAPTIONS TO ILLUSTRATIONS

Figure 1. Case #4, a 10-year-old boy with a left condylo-mandibular dysplasia (a, b) who was successfully treated, first with a functional device and second by orthodontic treatment. There was a good outcome at the last follow-up, at the age of 20 (c, d). Note the mandibular growth and spontaneous recovery of the left condyle in the glenoid fossa on the successive orthopantomograms at 10 years (e), 12 years (f), 14 years (g), 15 years (h), 16 years (i), and 20 years of age (j).

Figure 2. Case #16, a 6-year-old boy with left condylo-mandibular dysplasia before treatment (a, b), and the corresponding orthopantomogram (c). The same patient at 17 years of age, after mandibular lengthening with a left-side CCG at 7 years of age, revealing good esthetic and architectural results for the procedure (d, e, and f).

Figure 3. Typical presentation of condyle deformities on radiographic images. Schematic representation (a) and orthopantomogram (b) showing a camel-hump condylo-mandibular dysplasia of the left mandible. Three-dimensional reconstructions of a facial CT scan — inferior (c) and lateral (d) views — showing the empty glenoid fossa (*) and the anterior displacement of the malformed condyle.

Figure 4. Panoramic X-rays of eight patients highlighting the dental abnormalities encountered with the disease. (a) Dental agenesis of tooth #37 in an 11-year-old girl. (b–h) Tooth inclusions of the first and the second lower molars in the other seven patients, ranging from 7 to 15 years of age.

DECLARATIONS

Financial disclosure

The authors declare that they have no financial disclosures regarding this manuscript.

Declarations of interest

None

Funding

The authors declare that they received no funding or source of support for this specific study.

Ethics in publishing

Due to the retrospective nature of this study, it was formally granted an exemption from requiring approval from the ethics committee of Nantes University Hospital, in accordance with French legislation Article L. 1121-1 paragraph 1 and R1121-2 of the Public Health Code. All of the subjects and/or their guardians provided their signed consent for use of the photographs.

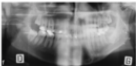
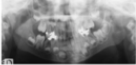Author contributions

All the authors mentioned in this manuscript contributed to the work reported. They have all read and approved the final version of this manuscript and agreed to be accountable for all aspects of work, ensuring integrity and accuracy. The authors contributed as follows: conceptualization – HB, F-LM, JD, PC, and JM; methodology – HB and F-LM; acquisition/investigation – HB, F-LM, and JM; writing – original draft preparation – HB, F-LM, R-HK, PC, and JM; writing – review and editing – HB, R-HK, and JM.

Acknowledgments

The authors thank Mrs Sophie Domingues for her careful reading and correction of the English version of this manuscript.









TABLES

Patient No. Age (years) Gender	Clinical findings and side involved	Dental abnormalities and treatment	Treatment, progression, and follow-up
No. 1 11 ♀	Facial asymmetry (PVI) of the left side	Agenesis of #37	Primary orthodontic treatment Left-side mandibular lengthening with intraoral approach and genioplasty Follow-up 19 months
No. 2 7 ♂	Facial asymmetry (PVI) of the left side	Tooth inclusion of #37, extraction	Primary orthodontic treatment Left-side costochondral graft and right-side lengthening by vertical ramus osteotomy Good outcomes Follow-up 67 months
No. 3 10 ♂	Facial asymmetry (PVI) of the right side	None	Primary orthodontic treatment Right-side costochondral graft Slight facial asymmetry at the last follow-up Follow-up 67 months
No. 4 10 ♂	Facial asymmetry (PVI) of the left side	None	Functional device and orthodontic treatment Good outcomes Follow-up 115 months
No. 5 9 ♂	Facial asymmetry (PVI) of the right side Class II malocclusion	Tooth inclusion of #47, extraction	Primary orthodontic treatment Right-side vertical ramus osteotomy, left-side sagittal split osteotomy, and genioplasty Good outcomes Follow-up 35 months
No. 6 6 ♀	Facial asymmetry (PVI) of the left side	None	Functional device and orthodontic treatment Class III malocclusion after left-side condylar overgrowth No surgery Follow-up 101 months

No. 7 5 ♀	Facial asymmetry (PVI) of the right side	None	Orthodontic treatment Right-side costochondral graft Partial recurrence of asymmetry Follow-up 125 months
No. 8 9 ♂	History of condyle trauma Left-side PVI	None	Orthodontic treatment Left-side extraoral vertical ramus osteotomy Good outcomes Follow-up 72 months
No. 9 5 ♂	Facial asymmetry (PVI) of the left side	Tooth inclusion of #36 and #37, extraction	Primary orthodontic treatment Le Fort I and bilateral sagittal split osteotomy; associated genioplasty Good outcomes Follow-up 234 months
No. 10 11 ♀	Facial asymmetry (PVI) of the left side	Tooth inclusion of #36 and #7, extraction	Primary orthodontic treatment Left-side condyle hyperplasia corrected by condylectomy, right-side sagittal split osteotomy Good outcomes Follow-up 80 months
No. 11 9 ♀	Right-side involvement	Tooth inclusion of #46 and #47, mobilization of #46, extraction of #47	Primary orthodontic treatment Right-side mandibular lengthening by vertical osteotomy, left-side sagittal split osteotomy, and genioplasty Good outcomes Follow-up 194 months
No. 12 5 ♀	Facial asymmetry (PVI) of the left side	Tooth inclusion of #36 and #37, mobilization of #36, extraction of #37	Functional device Orthodontic treatment Good outcomes Follow-up 172 months
No. 13 5 ♀	History of condyle trauma Right side PVI	None	Functional device Orthodontic treatment No data on follow-up
No. 14 5 ♀	Facial asymmetry (PVI) of the right side	Tooth inclusion of #46, extraction	Orthodontic treatment Right-side costochondral graft and left-side sagittal split osteotomy Good outcomes Follow-up 94 months

No. 15 7 ♂	Facial asymmetry (PVI) of the left side	Tooth inclusion of #36	Orthodontic treatment Left-side vertical ramus osteotomy No data on follow-up
No. 16 6 ♂	History of condyle trauma Involvement of the left side	Tooth inclusion of #36	Orthodontic treatment Left-side costochondral graft Good outcomes Follow-up 135 months
No. 17 5 ♀	Facial asymmetry (PVI) of the right side	None	Orthodontic treatment No follow-up
No. 18 10 ♀	Right-side involvement	None	Functional device and orthodontic treatment Good outcomes Follow-up 128 months
No. 19 7 ♀	Facial asymmetry (PVI) of the left side	Delayed eruption of #36	Orthodontic treatment Left-side costochondral graft Good outcomes Follow-up 107 months
No. 20 7 ♂	Facial asymmetry (PVI) of the right side	Inclusion of #47	Orthodontic treatment No follow-up
No. 21 8 ♀	Right-side involvement	None	Functional device and orthodontic treatments Good outcomes Follow-up 90 months

Table 1. Patient characteristics, clinical and radiological findings, treatments and follow-up. PVI = posterior vertical insufficiency

	<i>Craniofacial microsomia</i>	<i>Condylar-mandibular dysplasia</i>
<i>History</i>	Diagnosed at birth	Not diagnosed at birth
<i>Clinical examination</i>	Soft-tissue defects Ear malformations Facial nerve palsy Orbit defects	No soft-tissue defects No ear malformations No nerve deficit No anomaly of the orbits
<i>Affected side</i>	Right-side predominance	No side predominance

<i>Radiographic features</i>	<p>Various degrees of condyle deformity, ranging from hypoplasia to absence of condyle</p> <p>Possible absence of the glenoid fossa</p> <p>Delayed dental development, agenesis (6.7–32%)</p>	<p>Pathognomonic appearance, with short, curved, and anteriorly displaced condyle; high and sharp coronoid process; deep sigmoid notch</p> <p>Empty glenoid fossa</p> <p>Tooth inclusion (1st and/or 2nd lower molars)</p>
<i>Treatment</i>	<p>Minimal or absence of response to orthodontic functional appliance</p>	<p>Good response to orthodontic functional device (good growth potential of the ramus)</p>

Table 2. Differential diagnosis of craniofacial microsomia and condylo-mandibular dysplasia.