HAL
open science

Cobalamin C Deficiency Induces a Typical Histopathological Pattern of Renal Arteriolar and Glomerular Thrombotic Microangiopathy

Mathilde Lemoine, Arnaud François, Steven Grange, Marion Rabant, Valérie Châtelet, David Cassiman, Emilie Cornec-Le Gall, Damien Ambrosetti, Georges Deschênes, Jean-François Benoist, et al.

To cite this version:

Mathilde Lemoine, Arnaud François, Steven Grange, Marion Rabant, Valérie Châtelet, et al.. Cobalamin C Deficiency Induces a Typical Histopathological Pattern of Renal Arteriolar and Glomerular Thrombotic Microangiopathy. Kidney International Reports, 2018, 3 (5), pp.1153-1162. 10.1016/j.ekir.2018.05.015 . inserm-02454020

HAL Id: inserm-02454020

https://inserm.hal.science/inserm-02454020v1

Submitted on 24 Jan 2020

HAL is a multi-disciplinary open access archive for the deposit and dissemination of scientific research documents, whether they are published or not. The documents may come from teaching and research institutions in France or abroad, or from public or private research centers.

L'archive ouverte pluridisciplinaire **HAL**, est destinée au dépôt et à la diffusion de documents scientifiques de niveau recherche, publiés ou non, émanant des établissements d'enseignement et de recherche français ou étrangers, des laboratoires publics ou privés.

KI REPORTS
KIReports.org
CLINICAL RESEARCH

Cobalamin C Deficiency Induces a Typical Histopathological Pattern of Renal Arteriolar and Glomerular Thrombotic Microangiopathy

Mathilde Lemoine[1], Arnaud François[2], Steven Grangé[3], Marion Rabant[4], Valérie Châtelet[5], David Cassiman[6], Emilie Cornec-Le Gall[7], Damien Ambrosetti[8], Georges Deschênes[9], Jean-François Benoist[10] and Dominique Guerrot[1,11]

[1]Nephrology Department, Rouen University Hospital, Rouen, France; [2]Pathology Department, Rouen University Hospital, Rouen, France; [3]Medical Intensive Care Unit, Rouen University Hospital, Rouen, France; [4]Pathology Department, Necker Hospital, Paris, France; [5]Nephrology Department, Caen University Hospital, Caen, France; [6]Metabolic Center and Department of Gatroenterology-Hepatology, University Hospitals Leuven and KU Leuven, Belgium; [7]Nephrology Department, Brest University Hospital, Brest, France; [8]Pathology Department, Nice University Hospital, Nice, France; [9]Biochemistry Department, Robert Debré Hospital, Paris, France; [10]Pediatric Nephrology Department, Robert Debré Hospital, Paris, France; and [11]INSERM U1096, Rouen University Medical School, Rouen, France

Introduction: Cobalamin C (cblC) deficiency is the most common inborn error of vitamin B_{12} metabolism. Renal failure attributed to thrombotic microangiopathy (TMA) has occasionally been described in the late-onset presentation of cblC deficiency, but kidney lesions associated with cblC deficiency remain poorly defined. This study aims to describe the characteristics of kidney disease in cblC deficiency, and to provide a comparative histological analysis with cblC-independent renal TMA.

Methods: We performed a multicenter retrospective study including 7 patients with cblC deficiency and 16 matched controls with cblC-independent TMA. The patients included were aged 6 to 26 years at the time of the first manifestations. All patients presented with acute renal failure, proteinuria, and hemolysis; 5 patients required dialysis.

Results: The histological study revealed arteriolar and glomerular TMA in all patients. After comparison with the cblC-independent TMA control group, a vacuolated aspect of the glomerular basement membrane and the intensity of glomerular capillary wall IgM deposits were more present in cblC deficiency patients than in controls. Six patients were treated with hydroxycobalamin. All of them improved, with disappearance of hemolysis, and 3 of the 4 patients requiring renal replacement therapy were weaned off dialysis.

Conclusion: This study provides a precise description of kidney pathology in cblC deficiency. Due to major therapeutic implications, we suggest that patients with renal TMA be screened for cblC deficiency regardless of age, particularly when the kidney biopsy provides evidence of long-lasting TMA, including a vacuolated aspect of the glomerular basement membrane and glomerular capillary wall IgM deposition.

Kidney Int Rep (2018) **3,** 1153–1162; https://doi.org/10.1016/j.ekir.2018.05.015
KEYWORDS: cobalamin C deficiency; genetic kidney disease; renal pathology; thrombotic microangiopathy
© 2018 International Society of Nephrology. Published by Elsevier Inc. This is an open access article under the CC BY-NC-ND license (http://creativecommons.org/licenses/by-nc-nd/4.0/).

Thrombotic microangiopathy syndromes are characterized by the association of hemolytic anemia, thrombocytopenia, and organ injury due to arteriolar and capillary thrombosis. Typical hemolytic uremic syndrome (HUS) and thrombotic thrombocytopenic purpura (TTP) are the 2 most frequent causes of TMA. Typical HUS is due to a verocytotoxin commonly secreted by *Escherichia coli* O157:H7, whereas TTP is caused by deficiency of von Willebrand factor protease (ADAMTS 13). Other causes of TMA include atypical HUS, resulting from uncontrolled activation of the alternative pathway of complement, malignant hypertension, drugs, or malignancies.[1,2] Familial TMA has been identified in patients with cobalamin C deficiency.

Methylmalonic aciduria (MMA) and homocystinuria cblC type, also named cblC deficiency, is the most common inborn error of intracellular vitamin B_{12}

Correspondence: Mathilde Lemoine, Nephrology Department, CHU Charles Nicolle, 147 avenue du Maréchal Juin, 76230 Bois Guillaume, France. E-mail: ml.mathildelemoine@gmail.com
Received 13 May 2018; accepted 29 May 2018; published online 8 June 2018

metabolism. This autosomal recessive disease, due to mutations in *MMACHC* (methylmalonic aciduria cblC type with homocystinuria) gene,[3] leads to a defect in the synthesis of the 2 active coenzyme derivatives of cobalamin (Cbl), adenosylcobalamin (AdoCbl) and methylcobalamin (MeCbl). The substance AdoCbl acts as a cofactor for the mitochondrial L-methylmalonyl-coenzyme A (CoA) mutase (MMA mutase) during the transformation of methylmalonyl-CoA in succinyl-CoA, whereas MeCbl is required for the intracytoplasmic methylation of homocysteine in methionine by the methionine synthase (Figure 1). Two distinct phenotypes of cblC disease have been described, differing in age at presentation, symptoms, and outcomes.[4] The most frequent is the early-onset disease, characterized by failure to thrive, neurologic deterioration, and hematologic abnormalities during the first year of life.[5] The late-onset forms are rarer, usually less severe, and revealed by neuropsychiatric symptoms, pulmonary arterial hypertension (PAH), HUS, or myelopathy.

Although timely recognition of cblC deficiency is of the utmost importance because it has specific therapeutic implications, the kidney lesions in this setting are poorly described, due to the limited number of cases available and the absence of a specific study.[6] In this context, the identification of characteristic kidney lesions encountered in cblC deficiency would be helpful for pathologists and nephrologists to identify this frequently misdiagnosed entity.

The present study provides a systematic retrospective description of the histopathological findings on kidney biopsy in cblC deficiency, and a comparative analysis of renal lesions in cblC deficiency patients and in matched TMA control patients.

METHODS

Study Population and Data Collection

We performed a multicenter retrospective study in 7 patients with proven cblC deficiency and available kidney biopsy. The cases were selected in 6 different centers in France and Belgium. The diagnosis of cblC deficiency was made by complementation studies or genetic testing. The data collected included clinical (age, hypertension, edema, PAH, neurologic symptoms, and thromboembolic events), biological (hemoglobin, platelets, schizocytes, lactate dehydrogenase [LDH], haptoglobin, plasma creatinine, estimated glomerular filtration rate (eGFR), proteinuria, and complement system), and biochemical (vitamin B_{12}, total homocysteinemia, MMA, and methioninemia) characteristics at initial presentation. The management and the outcome of each patient were also recorded.

The cblC cases were compared with controls with TMA of cblC-independent origin. The controls were selected in 2 different centers (Rouen University Hospital, France, and Necker Hospital, Paris, France). We included all of the patients aged 4 to 28 years who presented between 1999 and 2015 with available kidney biopsy findings revealing renal TMA. Patients with TMA lesions associated with IgA nephropathy or lupus nephritis were excluded. Data on age, proteinuria, eGFR, and cause of TMA were collected for each control.

The eGFR was calculated based on the Modification of Diet in Renal Disease (MDRD) formula for adults and the Schwartz formula for children and adolescents.

All of the research procedures were approved by the local ethics committee of Rouen, France (E2015-36).

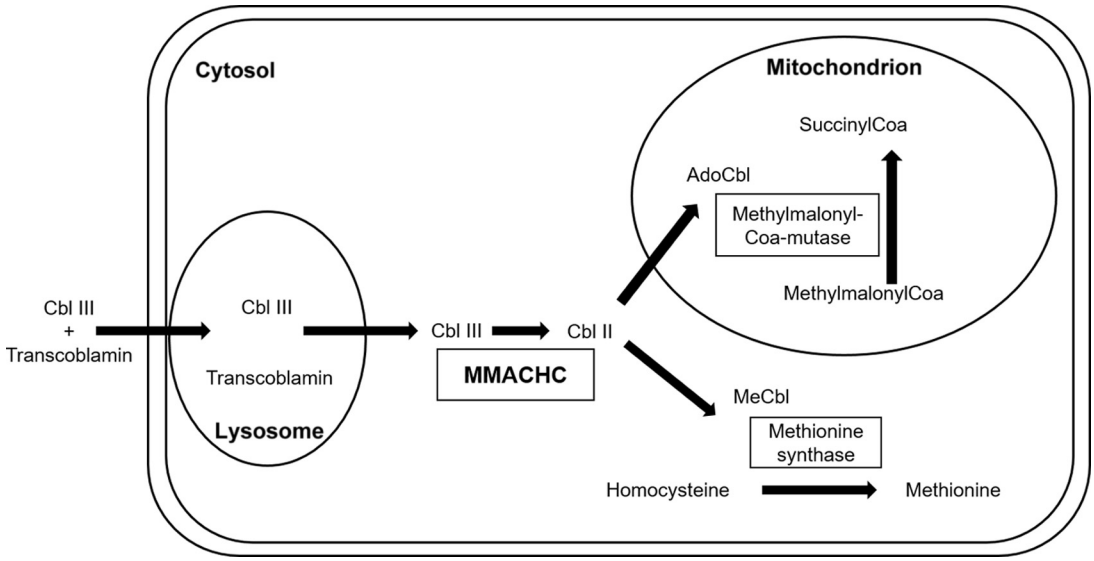

Figure 1. Intracellular cobalamin metabolism. AdoCbl, adenosylcobalamin; Cbl, cobalamin; MeCbl, methylcobalamin; MMACHC, methylmalonic aciduria cblC type with homocystinuria protein.

Kidney Pathology

Kidney biopsy specimens from the cblC patients and control patients were collected. A centralized review of all the biopsy findings was performed in a blinded manner by an experienced pathologist and a nephrologist of Rouen University Hospital. Masson trichrome, hematoxylin/eosin/saffron, and Jones methenamine silver stainings were used to assess glomerular, vascular (interlobular arteries and juxtaglomerular arterioles) and tubulo-interstitial lesions. The severity of each lesion was quantified as following: 0 (no lesion), 1 (light), 2 (moderate), and 3 (severe). The reports of the immunofluorescence study were collected from each center. Intensity of immunofluorescence was quoted from 0 to 3. Ultrastructural electron microscopy was performed in 1 patient.

Statistical Analysis

Quantitative variables are expressed as mean ± SD and were compared with the Mann−Whitney *U* test, whereas qualitative variables are expressed in numbers and percentages and were compared with the Fisher exact test. A *P* value of <0.05 was considered statistically significant.

RESULTS

Baseline Characteristics

Seven patients with cblC deficiency and available kidney biopsy were included. Five of them were previously reported.[7–9] Their baseline characteristics are described in Table 1. All the patients presented with late-onset disease and the age at initial presentation varied from 6 to 26 years. Familial disease was noted in 2 sets of siblings (patients 1 and 2[7] and patients 4 and 5[8]). All but 1 patient had hypertension, and 4 had edema. Only 1 patient had a history of neurological disorder (language delay), 1 had experienced a thromboembolic event, and 1 had PAH.

All of the patients presented with hemolysis, but 4 of them had a normal platelet level. Five patients required renal replacement therapy, and only 1 patient had an eGFR >30 ml/min per 1.73 m^2. Proteinuria was present in all tested patients and ranged from 1.3 to 9.0 g/d. All of the patients had normal C3 and C4 levels, but patient 4 had a heterozygous mutation in complement factor H.

Total homocysteine varied from 44 to 230 μmol/l (normal <13 μmol/l[10]) and urine methylmalonic acid from 19 to 244 μmol/mmol creatinine (normal <4 μmol/mmol[10]).

Table 1. Clinical, biological, and biochemical characteristics of the 7 cases at initial presentation

	Patient 1[7]	Patient 2[7]	Patient 3[9]	Patient 4[8]	Patient 5[8]	Patient 6	Patient 7
Clinical presentation							
Age (yr)	18	18	20	6	8.5	15	26
Hypertension	Yes	Yes	Yes	Yes	No	Yes	Yes
Edema	Yes	No	Yes	Yes	No	No	Yes
PAH	No	Yes	No	No	No	No	No
Neurologic symptoms	Yes	No	No	No	No	No	No
Thromboembolic event	No	No	No	Yes	No	No	No
Biology							
Hemoglobin (g/dl)	7.8	12.5	11.6	7.2	11.5	8.9	7.0
Platelets (g/l)	141	191	101	330	440	128	74
Schizocytes	Yes	Yes	Yes	No	No	No	No
LDH (UI/l)	787	444	1044	NA	NA	1021	3000
Haptoglobin (μmol/l)	< 0.1	NA	< 0.1	0.1	0.2	< 0.2	< 0.1
Creatinine (μmol/l)	Dialysis	Dialysis	Dialysis	Dialysis	55	Dialysis	290
eGFR (ml/min per 1.73 m^2)					110		18
Proteinuria (g/24 h)	6	2	1.3	1.6	4.8	9	7
C3	Normal	NA	Normal	Normal	Normal	Normal	Normal
C4	Normal	NA	Normal	Normal	Normal	Normal	Normal
Complement alternative pathway	Normal	NA	Normal	Factor H mutation	Normal	Normal	Normal
Biochemistry							
Vitamin B_{12} (pg/ml)	558	NA	500	600	550	580	1082
Total plasma homocysteine (μmol/l)	73	NA	185	104	44	97	230
Urine MMA (μmol/mmol)	NA	NA	244	19	22,5	91	83
Plasma methionine (μmol/l)	17	NA	4	30	30	40	NA
Complementation study	No	No	No	Yes	Yes	No	Yes
Genetic study of *MMACHC*							
Mutation 1	c.271dupA	c.271dupA	c.271dupA	c.271dupA	c.271dupA	c.271dupA	c.271dupA
Mutation 2	c.82-9_12delTTTC	c.82-9_12delTTTC	c.389A>G	c.82-9_12delTTTC	c.82-9_12delTTTC	c.82-9_12delTTTC	c.389A>G

EGFR, estited glomerular filtration rate; LDH, lactate dehydrogenase; MMA, methylmalonic acid; NA, not available; PAH, pulmonary hypertension.

Plasma methionine was decreased in 1 tested patient (patient 3) (normal 11−37 μmol/l). Patient 5, who had the lowest homocysteine concentration, was diagnosed early, when she had only proteinuria without kidney failure or extrarenal manifestation.

Genetic analysis of *MMACHC* was available in all patients, revealing compound heterozygosity for the frameshift mutation c.271dupA, together with the splice mutation c.82-9_12delTTTC in patients 1, 2, 4, 5, and 6, and the missense mutation c.389A>G (p.Tyr130Cys) in patients 3 and 7. In 3 patients, the diagnosis was also based on complementation analysis in fibroblasts (patients 4, 5, and 7).

Management and Outcomes

Patient management and outcomes are presented in Table 2. Time between the first presentation and the treatment initiation varied from 10 days to 7 years. One patient was not treated and died of pulmonary veino-occlusive disease at 18 years of age (patient 2). Autopsy showed pulmonary capillary hemangiomatosis and renal TMA. The diagnosis was made 15 years later, when his brother (patient 1) was diagnosed. The 6 other patients were treated with parenteral hydroxycobalamin (OHCbl), betaine, and folinic acid. All of them improved, with disappearance of hemolysis. Three of the 4 patients requiring renal replacement therapy were weaned off dialysis. The fourth received a kidney transplant 1 year after the diagnosis.

Four patients were treated by plasma exchanges before diagnosis, and 3 of them improved temporarily and partially. One patient was treated with eculizumab without any improvement.

Patient 7 had an atypical history. She was diagnosed with a renal TMA during pregnancy and received a kidney transplant 5 years later. The diagnosis of cblC deficiency was made 9 months later, after the recurrence of TMA on the graft. She received a second kidney transplant 6 years after the diagnosis.

One patient relapsed 5 years after treatment initiation because of inobservance. None of the 2 patients who had undergone transplantation relapsed on the kidney graft under treatment.

Histopathological Characteristics of Renal Disease

Nine biopsy specimens were available for the 7 patients (Supplementary Table S1). Light microscopic evaluation revealed glomerular and arteriolar TMA in all patients.

Most of the glomeruli presented typical lesions of TMA (Figure 2), with thickening of the capillary wall (Figure 2a) in all patients and intraglomerular thrombi in 3 patients (Figure 2b). Remodeling of the glomerular basement membrane (GBM), defined as duplication and/or a vacuolar aspect of the GBM, was seen in 6 patients altogether. Typical duplication of the GBM was seen in 2 patients at diagnosis, but was also noted in the 2 biopsies performed during the follow-up (Figure 2c). The GBM vacuoles (Figure 3a) were particularly frequent, as they were present in 6 patients. Microaneurysm, mesangial sclerosis, endocapillary proliferation, and glomerular ischemia were

Table 2. Management and outcomes of the 7 cases

	Patient 1	Patient 2	Patient 3	Patient 4	Patient 5	Patient 6	Patient 7
Management							
Time before treatment (mo)	0.3	N/A	12	18	4	1	84
Hydroxycobalamin	IM	No	IM	SC	SC	IM	IM
Betaine	Yes	No	Yes	Yes	Yes	Yes	Yes
Folinic acid	Yes	No	Yes	Yes	Yes	Yes	Yes
Other treatment	Plasma exchange Solumedrol	No	Eculizumab	Plasma exchange	No	Plasma exchange	Plasma exchange
Outcome after treatment							
Stop hemolysis	Yes	N/A	Yes	Yes	Yes	Yes	Yes
Time (days)	7		0	30	30	NA	NA
Weaning off dialysis	Yes	No	Yes	Yes	N/A	No	N/A
Time (mo)	5		3	0.8			
Relapse	No	N/A	No	Yes	No	No	No
Time (yr)				5			
Dialysis	No	N/A	No	No	No	Yes	Yes
Time (yr)						0	5
Kidney transplantation	No	N/A	No	No	No	Yes	Yes
Time (yr)						1	6
Relapse on graft						No	No
Death	No	Yes	No	No	No	No	No
Time (yr)		1					

IM, intramuscular; N/A, not applicable; NA, not available; SC, subcutaneous.

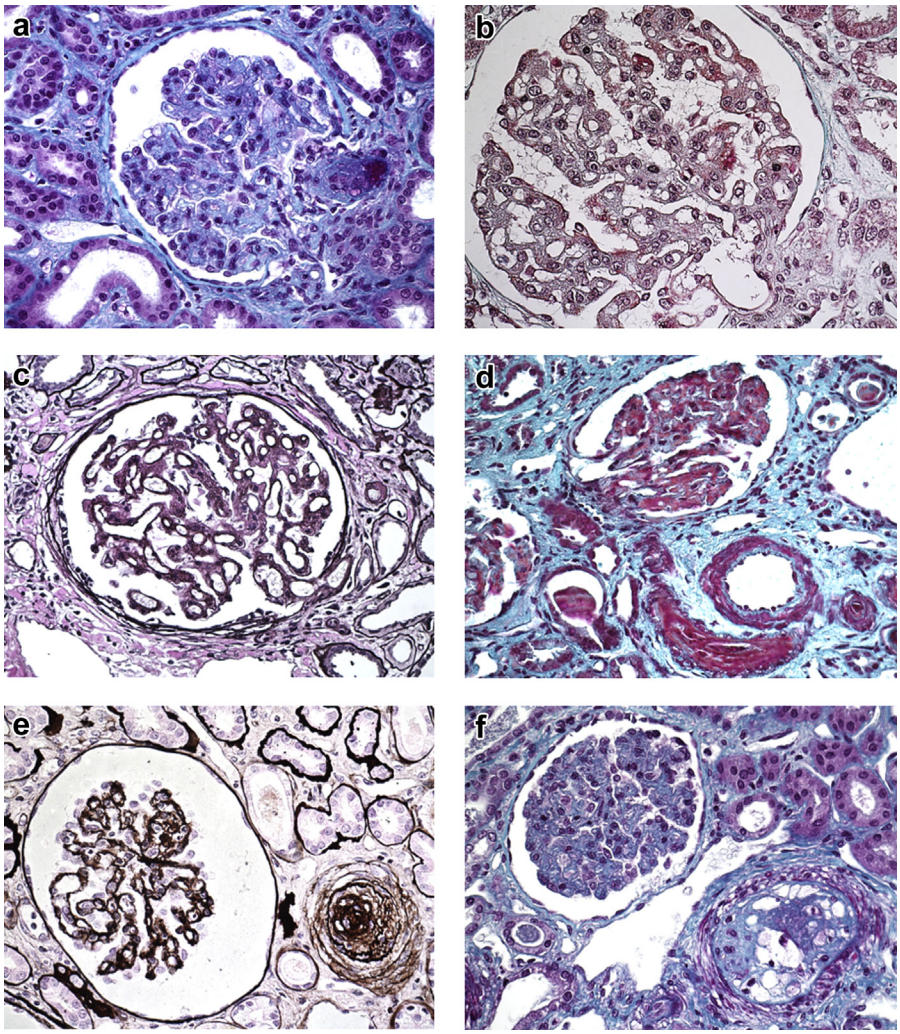

Figure 2. Glomerular and arteriolar lesions of thrombotic microangiopathy in patients with cobalamin C (cblC) deficiency. (a–f) Kidney biopsy. Light microscopy. (a) Arteriolar and glomerular thrombotic microangiopathy with thickening of capillary walls and arteriolar thrombus (patient 1; Masson trichrome staining; original magnification ×400). (b) Global thickening of glomerular capillary walls and endocapillary glomerular thrombi (patient 5; Masson trichrome staining; original magnification ×400). (c) Global thickening of glomerular capillary walls and duplication of the glomerular basement membrane (patient 5 [second biopsy]; Jones staining; original magnification ×400). (d) Massive juxtaglomerular arteriolar and glomerular thrombi (patient 6; Masson trichrome staining; original magnification ×400). (e) Glomerular ischemia and arteriolar fibrous plug (patient 2; Jones staining; original magnification ×400). (f) Glomerular thrombotic microangiopathy and arteriole occluded by fibrosis infiltered by foamy cells (patient 1; Masson trichrome staining; original magnification ×400).

seen in 2, 5, 3, and 4 patients, respectively. Synechiae and extracapillary proliferation were not seen.

All the patients had vascular lesions of TMA. Intravascular thrombi were present in all but one patient (Figure 2d). Fibrous plugs (Figure 2e), fibrous endarteritis (Figure 2f), and hyalinization were seen in 4, 3, and 3 patients, respectively.

Five patients had interstitial fibrosis with tubular atrophy at diagnosis and all of them presented acute tubular necrosis. The most severe lesions of interstitial fibrosis with tubular atrophy were found in the 2 patients who were not weaned off dialysis.

Two patients had a second biopsy during follow up, 1 patient a few months after treatment with eculizumab, revealing an increase in tubulo-interstitial lesions, and 1 patient 5 years after treatment by intramuscular OHCbl, showing disappearance of thrombi but arteriolar hyalinization. The kidney lesions found in the patient presenting with a heterozygous mutation in complement factor H were similar to those of the other patients.

Immunofluorescence reports are detailed in Supplementary Table S2. All but 1 patient had light-to-severe glomerular capillary wall IgM deposits (Figure 3b). One patient had moderate endomembranous C3 deposits, and no patient had IgG deposition.

Electron microscopy was performed in 1 patient (patient 1). It showed thickening of the GBM with vacuolated aspect (Figure 3c) due to intramembranous granular deposits and mesangial extensions (Figure 3d).

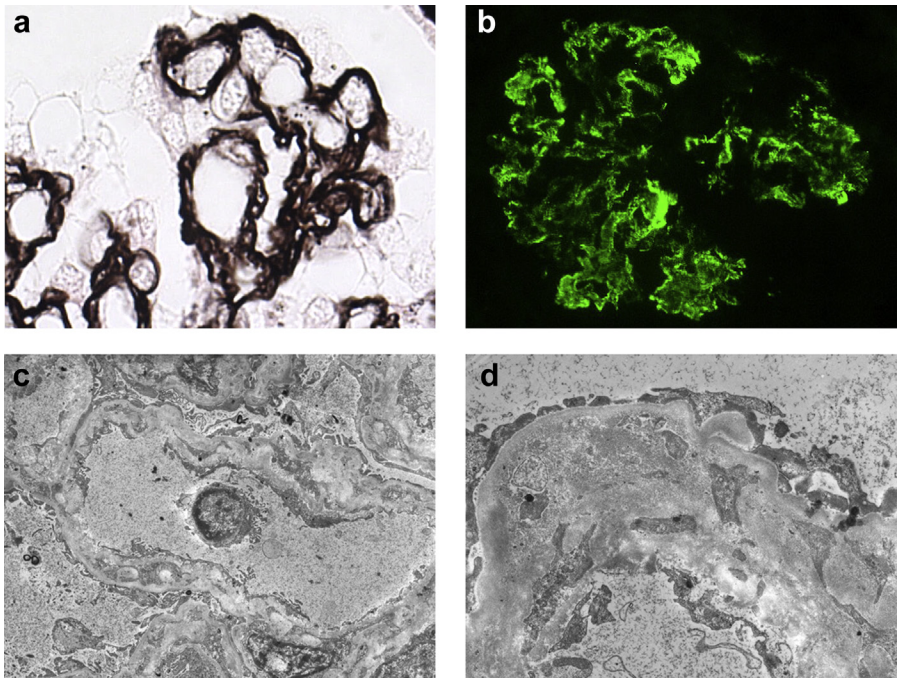

Figure 3. Vacuolated aspect of the glomerular basement membrane (GBM) due to IgM deposits in patients with cobalamin C deficiency. (a) Light microscopy. Glomerular capillary wall thickening with vacuoles and spikes (patient 3; Jones staining; original magnification ×2000). (b) Immunofluorescence microscopy. Glomerular capillary wall granular IgM deposits (patient 1; immunofluorescence staining for IgM; original magnification ×400). (c,d) Electron microscopy. Patient 1. (c) Thickening of the glomerular capillary wall with intramembranous granular deposits and material leading to the vacuolated aspect of the GBM (original magnification ×16,000). (d) Intramembranous granular deposits and mesangial cell expansion in vacuolated GBM (original magnification ×50,000).

Comparison of Renal Histopathological Findings Between cblC Deficiency and Other Causes of TMA

The most frequent causes of cblC-independent TMA were typical HUS, atypical HUS, and malignant hypertension (Supplementary Table S3). There was no difference in age (cblC 15.9 ± 6.8 years vs. control 12.7 ± 7.2 years, $P = 0.3$), dialysis (cblC, n = 5 [71%] vs. control, n = 5 [33%], $P = 0.2$) or proteinuria (cblC 4.5 ± 2.9 g/d vs. control 3.9 ± 8.7 g/d, $P = 0.07$) between the 2 groups.

A comparison of the histopathological characteristics between the 2 groups is reported in Table 3. There was no difference in vascular and tubulo-interstitial lesions between the 2 groups. It is interesting that among the GBM remodeling lesions, we found that the vacuolated appearance of the GBM was significantly more frequent in patients with cblC deficiency than in controls (cblC, n = 6 [86%] vs. controls, n = 1 [7%], $P < 0.001$).

Immunofluorescence study revealed that glomerular IgM deposits were significantly more frequent and abundant among patients with cblC deficiency (cblC 1.8 ± 0.8 vs. controls 0.4 ± 0.5, $P = 0.003$).

DISCUSSION

In this study, we found that cblC patients, as opposed to renal TMA control patients, presented with a peculiar histopathological picture of the GBM associated with a vacuolated aspect and IgM deposits, in addition to arteriolar and glomerular lesions of TMA.

Cobalamin C deficiency is the most common inherited disorder of vitamin B_{12} metabolism. Pediatricians are usually aware of the multisystem disorders associated with early-onset cblC deficiency in infants. On the contrary, the presentation in adults is generally not recognized at an early stage due to limited knowledge of this disorder, and patients with cblC deficiency represent a diagnostic conundrum for the physicians involved. Renal complications in patients with cblC disease are a relatively rare entity, with 40 cases described to date.[7,11] Among them, the majority (24 of 40) presented with late-onset disease, including 12 adolescents or young adults. The most frequently reported renal manifestation was TMA, although a few cases describe an atypical glomerulopathy, considered as glomerular consequences of TMA.[12,13] Biological screening of cblC deficiency is classically recommended in children with TMA, but not in adults.[14] However, recent data highlight the interest for clinicians to consider the diagnosis of cblC deficiency when renal TMA is diagnosed in adolescents or young adults.[1] Recently, Fakhouri *et al.* have proposed a diagnostic algorithm suggesting that cblC deficiency must be ruled out in Shiga toxin-producing *Escherichia coli*–negative

Table 3. Comparison of histopathological findings between TMA during cobalamin C (cblC) deficiency and other causes of TMA

Histological findings	cblC Deficiency (n = 7)	Control TMA (n = 16)	*P* value
Glomerulus			
Glomeruli with TMA (% of glomeruli)	97.6 ± 6.4	95.3 ± 10.1	0.67
Sclerotic glomeruli (% of glomeruli)	1.6 ± 4.2	12.6 ± 21.2	0.12
Thrombi (score)	0.7 ± 1.1	0.6 ± 1.0	0.72
Thickening of capillary wall	2 ± 0.8	1.7 ± 1.1	0.59
Microaneurysm	0.2 ± 0.4	0.3 ± 0.4	0.65
GBM remodeling	n = 6 (86%)	n = 7 (44%)	0,09
Duplication of GBM	n = 4 (57%)	n = 7 (44%)	0.34
GBM vacuoles	n = 6 (86%)	n = 1 (7%)	<0.001
Mesangial sclerosis	1.3 ± 0.9	1.2 ± 1.0	0.72
Endocapillary proliferation	0.6 ± 0.8	0.7 ± 0.7	0.71
Synechiae	0	0.3 ± 0.6	0.27
Ischemia	0.6 ± 0.9	0.6 ± 0.9	0.88
Extracapillary proliferation (n of patients, %)	n = 0 (0%)	n = 1 (6.3%)	0.9
MPGN aspect	n = 2 (29%)	n = 1 (6%)	0.21
Vessels			
Interlobular arteries (score)			
Thrombi	0.3 ± 0.5	0.5 ± 1.1	0.84
Fibrous endarteritis	0.3 ± 0.5	0.7 ± 1.2	0.9
Bulbiform FE	0.8 ± 1.3	0	0.07
Juxtaglomerular arterioles (score)			
Thrombi	1.1 ± 0.7	0.8 ± 0.9	0.29
Bulbiform FE	1 ± 1.4	0.4 ± 0.8	0.38
Fibrous plugs	1.3 ± 1.4	0.5 ± 0.9	0.19
Hyalinization (n of patients, %)	n = 1 (14%)	n = 1 (6%)	0.53
Tubules and interstitium (score)			
Interstitial fibrosis	1.6 ± 0.9	1.3 ± 1.0	0.59
Tubular atrophy	1.3 ± 1.1	0.6 ± 0.9	0.17
Acute tubular necrosis	1.6 ± 0.9	0.8 ± 1.2	0.12
IgM deposits (score)	1.8 ± 0.8	0.4 ± 0.5	0.003

FE, fibrous endarteritis; GBM, glomerular basement membrane; MPGN, membranoproliferative glomerulonephritis; n, number; TMA, thrombotic microangiopathy. Results are expressed as mean ± SD for qualitative variables (comparison with Mann–Whitney *U* test) or as number (percentage) for quantitative variables (comparison with Fisher exact test).

HUS, by the measurement of plasma homocysteine and urine or plasma methylmalonic acid, with or without *MMACHC* direct sequencing.[15] In our study, all but 1 patient were weaned off dialysis after treatment initiation, which supports the benefit of identifying the diagnosis to rapidly start the specific treatment.

Cobalamin C deficiency is due to mutations in *MMACHC* gene, which is located on chromosome 1p34[3] and encodes a protein acting as a cyanocobalamin decyanase.[16] Among the 87 mutations identified in *MMACHC*,[11] c.271dupA, resulting in a frame shift, is the most frequently encountered (40%–55%), and was present in all patients analyzed in our study.[3,17] Several studies suggest a phenotype–genotype correlation, and the homozygous c.271dupA mutation appears to be associated with early-onset disease.[17] In contrast, in heterozygous patients, phenotype appears to be determined by the less deleterious mutation.[18] Indeed, in this study, all patients presented with late-onset disease and they all had at least 1 partially functional allele (splice or missense mutation). The 2 other mutations found in our work were the missense mutation c.389A>G,[17] which has rarely been reported, and the splice mutation c.82-9_12delTTTC, which has been described only in patients with renal TMA.[18]

The pathophysiology of TMA during cblC deficiency is not completely understood. Hyperhomocysteinemia may play a crucial role in renal vascular endothelial toxicity.[19,20] It also alters the antithrombotic properties of the endothelium, possibly through impairing the nitric oxide–mediated inhibition of platelet aggregation,[21,22] and leads to increased coagulation.[23,24] However, the absence of reported cases of TMA during cystathionine synthase deficiency,[25] characterized by hyperhomocysteinemia with hypermethioninemia, highlights the existence of additional factors. Thus, hypomethioninemia may play a role in small vessel injury. In our population, plasma exchange partially improved hemolysis and kidney function in 3 patients, which may suggest a beneficial role of the clearance of a potential circulating factor. Another interesting point is the atypical history of patient 7, in whom the diagnosis was made after a first kidney transplantation. To our knowledge, cblC-related HUS had not yet been reported after kidney transplantation. This case holds important pathophysiological implications, as it strongly supports the role of plasma disturbances in TMA, as opposed to the hypothesis of a primitive involvement of cblC deficiency in vascular endothelial injury at the cellular level. HUS have also been described in cblG[26] and cblE disease,[27] characterized by hyperhomocysteinemia without MMA, whereas only tubulo-interstitial injuries have been reported during MMA without hyperhomocysteinemia.[28] These 2 points remove the potential role of urine or plasma methylmalonic acid. Associated factors of TMA should also be searched, such as complement alternative pathway abnormalities,[8,29] which may participate in endothelial injury in selected cases.

The pathophysiology of TMA during cblC deficiency is supposed to be similar to the pathophysiology of PAH and communicating hydrocephalus.[30] However, in our population, no patient presented with hydrocephaly, and only 1 patient had a history of neurological abnormality, revealed by a language delay. The clinical features are atypical in our study because neurological signs are usually the most frequent symptoms at onset or during course of cblC deficiency.[31] This confirms the wide heterogeneity of cblC disease, and that the diagnosis has to be evoked

even in the absence of neurologic damage.[32] Likewise, only 1 patient presented with PAH in our study, but several cases of PAH during cblC deficiency have been reported, frequently associated with TMA.[33,34]

Our histopathological study revealed arteriolar and glomerular TMA in all cblC patients described, with typical acute and chronic lesions. In their recent review, Beck *et al*. retrospectively reported the results of 16 biopsies of cblC patients.[11] The authors described glomerular TMA lesions with endothelial swelling, glomerular thrombi, and/or duplication of the GBM. In the latter study, there was no immunofluorescence analysis, centralized review or control population. In the present study, we showed that GBM vacuoles and IgM deposition were significantly more frequent in patients with cblC disease, compared to a control population with cblC-independent TMA. Vacuolated GBM has not yet been reported in cblC patients, but IgM deposits have already been described in 3 patients.[12,35] GBM remodelling, including vacuoles, can be seen in chronic TMA. In this study, there was no difference regarding the time from clinical diagnosis of TMA to biopsy between the 2 groups. However, due to the genetically driven pathophysiology of the disease, we can suppose that, as opposed to some cblC-independent TMA patients, the cblC patients presented ongoing lesions years before the diagnosis was made. These findings correlate with the late-onset presentation of the disease in our patients, in which diagnosis is made late because of subacute presentation. This chronic evolution could also explain that cblC patient had relatively normal platelets level, which has already been described in several case reports.[33,35,36] Red blood cell count is also almost normal in our study, and schizocytes, LDH elevation, or low haptoglobin is the only hint to TMA. Cobalamin C deficiency is not an immune-related disease, and no study has yet focused on immune deposits in this disorder. In the few cases reporting the results of autopsy in patients with cblC defect, there are no data on immunofluorescence in other organs.[37,38] Due to the similar histopathological pattern, we can speculate that the vacuolated aspect is secondary to deposits, as occurs in membranous nephropathy. This is supported by the ultrastructural study revealing intramembranous granular deposits, although electron microscopy was available in only 1 patient. In cblC-dependent TMA, endothelial cell injury, especially oxidative stress mediated by hyperhomocysteinemia, may involve complement activation,[39] and leucocyte aggregation,[40] leading to deposits of IgM on the external face of the GBM. We can also speculate that circulating IgM, due to its biochemical characteristics, could be nonspecifically trapped within the glomerular lesions.

This retrospective study is limited mainly by the relatively small number of patients included, due to the rarity of the disease. The strength of this study lies both in the detailed systematic histopathological analysis and in the comparison with cblC-independent TMA, which identifies typical renal lesions occurring in late-onset cblC deficiency. These original results provide novel information for pathologists, who should specifically evoke the diagnosis of cblC deficiency when kidney biopsy reveals TMA lesions associated with a vacuolated aspect of the GBM and/or IgM deposits. Dosage of plasma homocysteine, methylmalonic acid, and methionine are easy and inexpensive procedures that can highlight a misdiagnosed entity in which prognosis is highly linked to the rapidity of treatment initiation. When the diagnosis of cblC deficiency is biochemically suspected, *MMACHC* direct sequencing allows one to affirm the diagnosis, but the specific treatment, including intramuscular injections of OHCbl, betaine, and folinic acid,[5] must be rapidly started, without waiting for confirmatory testing.

In conclusion, we suggest that all the patients with renal TMA be screened for cobalamin metabolism disorder with plasma homocysteine measurement, regardless of age at presentation, particularly when microscopy reveals a vacuolated aspect of the GBM and glomerular capillary wall IgM deposition.

DISCLOSURE

All the authors declared no competing interests.

ACKNOWLEDGMENTS

The authors thank the clinicians (Elisabeth Cassuto, Yannick Le Meur, Laetitia Albano, Hélène Leray Moragues, Vincent Pernin, Françoise Broux, Férielle Louillet) and pathologists (Isabelle Brochériou, Hélène Perrochia, Laurent Doucet, François Comoz, Céline Le Naoures-Mear), who provided access to patients' data and kidney biopsy results. We thank Soumeya Bekri, Metabolic Biochemistry Department, Rouen University Hospital, for her expertise in the biochemical characterization of patient 1. We express our gratitude to Damien Genty for his technical assistance in performing microphotography.

SUPPLEMENTARY MATERIAL

Table S1. Review of the histopathological characteristics of the 9 biopsies.

Table S2. Glomerular immunofluorescence reports for 6 patients.

Table S3. Etiologies of control thrombotic microangiopathies.

Supplementary material is linked to the online version of the paper at www.kireports.org.

REFERENCES

1. George JN, Nester CM. Syndromes of thrombotic microangiopathy. *N Engl J Med*. 2014;371:654–666.
2. Rosove MH. Thrombotic microangiopathies. *Semin Arthritis Rheum*. 2014;43:797–805.
3. Lerner-Ellis JP, Tirone JC, Pawelek PD, et al. Identification of the gene responsible for methylmalonic aciduria and homocystinuria, cblC type. *Nat Genet*. 2006;38:93–100.
4. Rosenblatt DS, Aspler AL, Shevell MI, et al. Clinical heterogeneity and prognosis in combined methylmalonic aciduria and homocystinuria (cblC). *J Inherit Metab Dis*. 1997;20:528–538.
5. Carrillo-Carrasco N, Chandler RJ, Venditti CP. Combined methylmalonic acidemia and homocystinuria, cblC type. I. Clinical presentations, diagnosis and management. *J Inherit Metab Dis*. 2012;35:91–102.
6. Carrillo-Carrasco N, Venditti CP. Combined methylmalonic acidemia and homocystinuria, cblC type. II. Complications, pathophysiology, and outcomes. *J Inherit Metab Dis*. 2012;35:103–114.
7. Grangé S, Bekri S, Artaud-Macari E, et al. Adult-onset renal thrombotic microangiopathy and pulmonary arterial hypertension in cobalamin C deficiency. *Lancet*. 2015;386:1011–1012.
8. Guigonis V, Frémeaux-Bacchi V, Giraudier S, et al. Late-onset thrombocytic microangiopathy caused by cblC disease: association with a factor H mutation. *Am J Kidney Dis*. 2005;45:588–595.
9. Cornec-Le Gall E, Delmas Y, De Parscau L, et al. Adult-onset eculizumab-resistant hemolytic uremic syndrome associated with cobalamin C deficiency. *Am J Kidney Dis*. 2014;63:119–123.
10. Carrillo N, Adams D, Venditti CP. Disorders of intracellular cobalamin metabolism. Available at: http://www.ncbi.nlm.nih.gov/books/NBK1328/. Accessed December 21, 2016.
11. Beck BB, van Spronsen F, Diepstra A, et al. Renal thrombotic microangiopathy in patients with cblC defect: review of an under-recognized entity. *Pediatr Nephrol*. 2017;32:733–741.
12. Brunelli S, Meyers K, Guttenberg M, et al. Cobalamin C deficiency complicated by an atypical glomerulopathy. *Pediatr Nephrol*. 2002;17:800–803.
13. Brandstetter Y, Weinhouse E, Splaingard ML, et al. Cor pulmonale as a complication of methylmalonic acidemia and homocystinuria (Cb1-C type). *Am J Med Genet*. 1990;36:167–171.
14. Loirat C, Saland J, Bitzan M. Management of hemolytic uremic syndrome. *Presse Méd*. 2012;41:e115–e135.
15. Fakhouri F, Zuber J, Frémeaux-Bacchi V, et al. Haemolytic uraemic syndrome. *Lancet*. 2017;12(390):681–696.
16. Kim J, Gherasim C, Banerjee R. Decyanation of vitamin B12 by a trafficking chaperone. *Proc Natl Acad Sci*. 2008;105:14551–14554.
17. Lerner-Ellis JP, Anastasio N, Liu J, et al. Spectrum of mutations in *MMACHC*, allelic expression, and evidence for genotype–phenotype correlations. *Hum Mutat*. 2009;30:1072–1081.
18. Morel CF, Lerner-Ellis JP, Rosenblatt DS. Combined methylmalonic aciduria and homocystinuria (cblC): phenotype–genotype correlations and ethnic-specific observations. *Mol Genet Metab*. 2006;88:315–321.
19. Weiss N. Mechanisms of increased vascular oxidant stress in hyperhomocysteinemia and its impact on endothelial function. *Curr Drug Metab*. 2005;6:27–36.
20. Starkebaum G, Harlan JM. Endothelial cell injury due to copper-catalyzed hydrogen peroxide generation from homocysteine. *J Clin Invest*. 1986;77:1370–1376.
21. Stamler JS, Osborne JA, Jaraki O, et al. Adverse vascular effects of homocysteine are modulated by endothelium-derived relaxing factor and related oxides of nitrogen. *J Clin Invest*. 1993;91:308.
22. Upchurch GR, Welch GN, Fabian AJ, et al. Homocysteine decreases bioavailable nitric oxide by a mechanism involving glutathione peroxidase. *J Biol Chem*. 1997;272:17012–17017.
23. Lentz SR, Sadler JE. Inhibition of thrombomodulin surface expression and protein C activation by the thrombogenic agent homocysteine. *J Clin Invest*. 1991;88:1906.
24. Hajjar KA, Mauri L, Jacovina AT, et al. Tissue plasminogen activator binding to the annexin II tail domain. Direct modulation by homocysteine. *J Biol Chem*. 1998;273:9987–9993.
25. Mudd SH, Skovby F, Levy HL, et al. The natural history of homocystinuria due to cystathionine β-synthase deficiency. *Am J Hum Genet*. 1985;37:1.
26. Vaisbich MH, Braga A, Gabrielle M, et al. Thrombotic microangiopathy caused by methionine synthase deficiency: diagnosis and treatment pitfalls. *Pediatr Nephrol*. 2017;32:1089–1092.
27. Labrune P, Zittoun J, Duvaltier I, et al. Haemolytic uraemic syndrome and pulmonary hypertension in a patient with methionine synthase deficiency. *Eur J Pediatr*. 1999;158:734–739.
28. Morath MA, Hörster F, Sauer SW. Renal dysfunction in methylmalonic acidurias: review for the pediatric nephrologist. *Pediatr Nephrol*. 2013;28:227–235.
29. Bouts AH, Roofthooft MTR, Salomons GS, et al. CD46-associated atypical hemolytic uremic syndrome with uncommon course caused by cblC deficiency. *Pediatr Nephrol*. 2010;25:2547–2548.
30. Greitz D. The hydrodynamic hypothesis versus the bulk flow hypothesis. *Neurosurg Rev*. 2004;27:299–300.
31. Fischer S, Huemer M, Baumgartner M, et al. Clinical presentation and outcome in a series of 88 patients with the cblC defect. *J Inherit Metab Dis*. 2014;37:831–840.
32. Li Q-L, Song W-Q, Peng X-X, et al. Clinical characteristics of hemolytic uremic syndrome secondary to cobalamin C disorder in Chinese children. *World J Pediatr*. 2015;11:276–280.
33. Kömhoff M, Roofthooft MT, Westra D, et al. Combined pulmonary hypertension and renal thrombotic microangiopathy in cobalamin C deficiency. *Pediatrics*. 2013;132:e540–e544.
34. Gündüz M, Ekici F, Özaydın E, et al. Reversible pulmonary arterial hypertension in cobalamin-dependent cobalamin C disease due to a novel mutation in the MMACHC gene. *Eur J Pediatr*. 2014;173:1707–1710.
35. Van Hove JLK, Damme-Lombaerts RV, Grünewald S, et al. Cobalamin disorder Cbl-C presenting with late-onset thrombotic microangiopathy: late-onset cobalamin C disorder. *Am J Med Genet*. 2002;111:195–201.

36. Baumgartner ER, Wick H, Maurer R, et al. Congenital defect in intracellular cobalamin metabolism resulting in homocysteinuria and methylmalonic aciduria. I. Case report and histopathology. *Helv Paediatr Acta*. 1979;34:465–482.

37. Russo P, Doyon J, Sonsino E, et al. A congenital anomaly of vitamin B12 metabolism: a study of three cases. *Hum Pathol*. 1992;23:504–512.

38. Geraghty MT, Perlman EJ, Martin LS, et al. Cobalamin C defect associated with hemolytic-uremic syndrome. *J Pediatr*. 1992;120:934–937.

39. Collard CD, Väkevä A, Morrissey MA, et al. Complement activation after oxidative stress. *Am J Pathol*. 2000;156:1549–1556.

40. Grace PA. Ischaemia-reperfusion injury. *Br J Surg*. 1994;81:637–647.