



Magnetic resonance imaging presentation of deep infiltrating endometriosis nodules before and after pregnancy: A case series

Anne Elodie Millischer, Louis Marcellin, Pietro Santulli, Chloé Maignien, Mathilde Bourdon, Bruno Borghese, François Goffinet, Charles Chapron

► To cite this version:

Anne Elodie Millischer, Louis Marcellin, Pietro Santulli, Chloé Maignien, Mathilde Bourdon, et al.. Magnetic resonance imaging presentation of deep infiltrating endometriosis nodules before and after pregnancy: A case series. PLoS ONE, 2019, 14 (10), pp.e0223330. 10.1371/journal.pone.0223330 . inserm-02315060

HAL Id: inserm-02315060

<https://inserm.hal.science/inserm-02315060>

Submitted on 14 Oct 2019

HAL is a multi-disciplinary open access archive for the deposit and dissemination of scientific research documents, whether they are published or not. The documents may come from teaching and research institutions in France or abroad, or from public or private research centers.

L'archive ouverte pluridisciplinaire **HAL**, est destinée au dépôt et à la diffusion de documents scientifiques de niveau recherche, publiés ou non, émanant des établissements d'enseignement et de recherche français ou étrangers, des laboratoires publics ou privés.

RESEARCH ARTICLE

Magnetic resonance imaging presentation of deep infiltrating endometriosis nodules before and after pregnancy: A case series


Anne Elodie Millischer^{1,2✉‡*}, Louis Marcellin^{2,3✉‡}, Pietro Santulli^{2,3}, Chloe Maignien^{2,3}, Mathilde Bourdon^{2,3}, Bruno Borghese^{2,4}, François Goffinet⁵, Charles Chapron^{2,4}

1 Centre de Radiologie IMPC Bachaumont Pole femme-mere-enfant, Paris, France, **2** Université Paris Descartes, Sorbonne Paris Cité, Faculté de Médecine, Assistance Publique–Hôpitaux de Paris (AP-HP), Service de Chirurgie Gynécologie Obstétrique II et Médecine de la Reproduction, Hôpital Universitaire Paris Centre (HUPC), Centre Hospitalier Universitaire (CHU) Cochin, Paris, France, **3** Equipe Stress Oxydant, Prolifération Cellulaire et Inflammation, Département Développement, Reproduction, Cancer, Inserm U1016, Université Paris Descartes, Sorbonne Paris Cité, Faculté de Médecine, AP-HP, HUPC, CHU Cochin, Paris, France, **4** Equipe Génomique, Epigénétique et Physiopathologie de la Reproduction, Département Développement, Reproduction, Cancer, Inserm U1016, Université Paris Descartes, Sorbonne Paris Cité, Faculté de Médecine, AP-HP, HUPC, CHU Cochin, Paris, France, **5** Port Royal Maternity Unit, Cochin Hospital, Assistance Publique des Hôpitaux de Paris, DHU Risks and Pregnancy, Paris Descartes University, Paris, France

✉ These authors contributed equally to this work.

‡ These authors are joint first authors on this work.

* louis.marcellin@aphp.fr



OPEN ACCESS

Citation: Millischer AE, Marcellin L, Santulli P, Maignien C, Bourdon M, Borghese B, et al. (2019) Magnetic resonance imaging presentation of deep infiltrating endometriosis nodules before and after pregnancy: A case series. PLoS ONE 14(10): e0223330. <https://doi.org/10.1371/journal.pone.0223330>

Editor: Niels Bergsland, University at Buffalo, UNITED STATES

Received: May 9, 2019

Accepted: September 18, 2019

Published: October 4, 2019

Copyright: © 2019 Millischer et al. This is an open access article distributed under the terms of the [Creative Commons Attribution License](https://creativecommons.org/licenses/by/4.0/), which permits unrestricted use, distribution, and reproduction in any medium, provided the original author and source are credited.

Data Availability Statement: All relevant data are within the manuscript and its Supporting Information files.

Funding: The author(s) received no specific funding for this work.

Competing interests: The authors have declared that no competing interests exist.

Abstract

Objective

To compare the magnetic resonance imaging (MRI) features of deep infiltrating endometriosis (DIE) lesions before and after pregnancy.

Design

Retrospective study.

Setting

A single French university tertiary referral hospital.

Patients

Twenty-one women without a prior history of surgery for endometriosis with a radiological diagnosis by MRI with two sets of examinations performed before and after pregnancy.

Interventions

The volumes of the lesions were compared using the same protocol before and after pregnancy based on MRI (1.5 T) examinations by a single experienced radiologist who is a referring practitioner for image-based diagnosis of endometriosis.

Main outcome measure(s)

The DIE lesion volume.

Measurements and main results

Between October 2012 and December 2016, a total of 21 patients (67 lesions) were included and compared before and after pregnancy. The mean time interval between the MRI before pregnancy and delivery was 19.6 ± 8.5 months (median: 17.6, IQR 13.5–25.2 months). The mean time interval between delivery and the MRI after pregnancy was 11.0 ± 6.4 months (median: 8.3, IQR 6–15.2 months). The mean overall DIE lesion volume by MRI was significantly higher before pregnancy compared to after pregnancy ($2,552 \pm 3,315 \text{ mm}^3$ vs. $1,708 \pm 3,266 \text{ mm}^3$, respectively, $p < 0.01$). The mean volume by MRI of the largest lesion of each patient was significantly higher before pregnancy compared to after pregnancy ($4,728 \pm 4,776 \text{ mm}^3$ vs. $3,165 \pm 5,299 \text{ mm}^3$; $p < 0.01$).

Conclusion

Our data indicate a favorable impact of pregnancy on DIE lesion volumes as measured by MRI.

Introduction

Endometriosis is a common chronic benign hormone-dependent gynecological disorder associated with persistent pelvic pain and/or infertility [1, 2] that is characterized by the development of glandular and stromal endometrium-like tissues at ectopic locations.[3] At present, imaging procedures such as ultrasonography (US),[4] and magnetic resonance imaging (MRI) are suitable for diagnosing and for providing follow-up of endometriotic lesions (endometrioma—OMA and deep infiltrating endometriosis—DIE), and allow for a non-surgical diagnosis of endometriosis,[5, 6] without a need for histological confirmation.[5, 7, 8]

The data available regarding the interrelationships between pregnancy and endometriosis are limited or of poor-quality.[9–11] Historically, pregnancy is typically considered to have a positive -albeit temporary- effect on endometriosis, which is most likely due to anovulation, amenorrhea, and pregnancy-related hormonal changes that prevent bleeding in the ectopic endometriotic tissue.[12] Varying degrees of growth changes of ectopic endometriotic lesions have been observed.[11] In addition, severe but rare and unpredictable complications during pregnancy have been reported with puerperal changes in ectopic lesions.[13]

Preliminary data indicate that pregnancies in conjunction with endometriosis are associated with increased adverse pregnancy outcomes such as spontaneous miscarriage,[14] preterm birth, preeclampsia, small-for-gestational-age offspring, and obstetric hemorrhages.[15–22] One of the suspected etiologies stems from the potential increased risk of defective deep placentation.[23, 24] Moreover, endometriosis-like glands have previously been reported to be in close contact with the fetal membranes in pregnant women who have endometriosis.[25]

During pregnancy, the endometrium undergoes decidualization (initiated during the secretory phase of the menstrual cycle and persisting when implantation of the blastocyst occurs) that is mainly induced by progesterone.[26] This decidualization results in conversion of the endometrium into a specialized uterine tissue,[27] thereby controlling trophoblast invasion and guaranteeing optimal accommodation of the gestation.[28] This transformation of the

endometrium involves different metabolic, hormonal, angiogenic, and immune system changes related to steroid exposure.[29] Decidualization also occurs in ectopic endometriotic lesions.[30, 31] It is not clear whether these changes in ectopic lesions persist after delivery. A previous study evaluated the clinical features and the change in size based on US during pregnancy of 25 OMA,[32] and a 3-case series of deep infiltrating endometriosis (DIE) lesions,[30] both of which exhibited a change in size. However, no data are available regarding the progression of DIE lesions before and after pregnancy based on MRI.

Therefore, the aim of this retrospective study was to compare the DIE lesion volume by MRI before and after pregnancy.

Materials and methods

Study design

This study was approved by the National Data Protection Authority (Commission Nationale de l'Informatique et des Libertés, CNIL n° 1755849). French regulations stipulate that this study is exempt from Institutional Review Board (IRB) review because it is an observational study using anonymized data from medical records. The study's exempt status was confirmed by the IRB Ile-de-France. During the study period, women were routinely informed that their records could be used for evaluation of medical practices and that they had the right to opt-out of these studies. This was a retrospective analysis of a series of severe-stage DIE patients without a prior history of surgery for endometriosis and who had a monofetal pregnancy followed in a tertiary care center. Women with a diagnosis of DIE based on MRI criteria [5, 33] obtained before pregnancy were retained for the study. After delivery, an MRI was carried out of women with DIE due to painful symptoms.

Patients

All of the pregnant women received prenatal care at our tertiary university hospital before 22 +0 weeks and they gave birth there after 24+0 weeks in accordance with the protocols of the department.[34]

Imaging protocol

The two sets of pelvic MRI examinations were performed by a single experienced radiologist, who is referring practitioner for image-based diagnosis of endometriosis, using the same protocol before and after pregnancy on a 1.5 T MRI machine (Sonata, Siemens; Erlangen, Germany) based on stringent previously published criteria.[5, 7, 8, 35, 36] The MRI obtained before and after pregnancy were reviewed independently, one month apart, by the same experienced radiologist to avoid memory contamination and inter-operator variability.[37] In keeping with the literature, OMA exhibited pathognomic features of signal loss on T2-weighted imaging, referred to as "T2 shading", and high signal intensity on T1-weighted images with and without fat saturation. These elements reflect the hemorrhagic nature of OMA and they help differentiate them from other T1-hyperintense lesions, such as dermoid and hemorrhagic cysts.[38, 39] DIE nodules are composed of fibromuscular hyperplasia surrounding endometrial glands, displaying T2-hypointense signal, T1 intermediate signal intensity, with masses that had irregular edges and/or thickening of soft tissues leading to distortion of the normal pelvic anatomy and adhesion formation.[38, 40] Deep endometriosis involving the uterosacral ligaments appears as T2-hypointense thickening or nodularity. Rectosigmoid involvement exhibits a specific morphological pattern, in the anterior wall, featuring a semi-lunar hypointense T2 signal nodule, recently described as a "mushroom cap sign".[41] The

DIE lesions were classified based on five locations (i.e., uterosacral ligament(s), the vagina, bladder, intestine, and ureter), [42] and they were diagnosed according to stringent imaging criteria published elsewhere. [36] In cases with multiple DIE lesions, the patients were classified according to the worst location (least to most severe: uterosacral ligament(s), the vagina, bladder, intestine, and ureter). [42] The volumes of the DIE lesions and the sizes of the OMA were assessed by MRI before and after the pregnancy by the same radiologist (AEM). The nodule volume of the uterosacral ligament(s), the bladder, and the intestine were calculated with the volume formula for a general ellipsoid solid ($V = \pi/6 [(a + b)/2]^3$). Posterior vaginal fornix nodules were considered to be spheroids, and the volumes were calculated with the volume formula for a general sphere ($V = 4/3 \pi r^3$). [43]

Data analysis

For each patient, their personal history data and pregnancy-related information were collected including the maternal age, weight, size, assisted reproductive technology (ART), gestity, parity, gestational hypertension, mode of delivery, gestational age at delivery, preterm birth < 37 weeks of gestation, birth weight, small for gestational age offspring, the time interval between the MRI before pregnancy and delivery, and the time interval between delivery and the MRI after pregnancy. For each patient, the distribution of DIE lesions and the presence of OMA were recorded.

Statistical analysis

The continuous data are presented as means with the standard deviation and as medians and the interquartile range (IQR) 25–75%. Paired analyses were used when comparing pre- and post-pregnancy lesion volumes (mm^3) by MRI, and comparisons were performed according to the DIE location. In case of multiple DIE lesions, paired comparisons of lesion volumes before and after pregnancy were also performed according to the largest lesion of each patient. Paired OMA sizes (mm) were compared before and after pregnancy. The quantitative data were compared using the Wilcoxon matched-pairs test. A p-value < 0.05 was considered statistically significant. The data were analyzed using STATA software for Macintosh (Stata/IC 11.0 for Mac, StataCorp College Station, TX, USA).

Results

Between October 2012 and December 2016, 21 DIE patients without a prior history of surgery for endometriosis underwent MRI before and after pregnancy. The characteristics of the women and the pregnancies are presented in Table 1. No endometriosis-related complications were reported during the pregnancies. All of these 21 women were undergoing hormonal treatment at the time of the MRI prior to the pregnancy. The mean time interval between the MRI before pregnancy and delivery was 19.6 ± 8.5 months (median: 17.6, IQR 13.5–25.2 months). The mean time interval between delivery and the MRI after pregnancy was 11.0 ± 6.4 months (median: 8.3, IQR 6–15.2 months). The mean number of DIE lesions was 3.2 ± 1.1 (median: 4, IQR 3–4) (Table 1). The distribution of the DIE location and the OMA based on MRI are presented in Table 2: 19/21 patients exhibited vaginal posterior fornix involvement (90.5%), 20/21 uterosacral involvement (95.2%), 14/21 bowel involvement (66.7%), 3/21 bladder involvement (14.3%), and 15/21 OMAs (71.4%) (Table 2).

Fig 1 depicts the DIE lesions of a woman before (Fig 1A, 1C and 1E) and after (Fig 1B, 1D and 1F) pregnancy based on MRI, with the bowel (Fig 1A and 1B), uterosacral ligaments and the posterior vaginal fornix (Fig 1C and 1D), and OMAs (Fig 1E and 1F) exhibiting a qualitative thinning and reduction in the size of the lesions.

Table 1. Characteristics of the women and the pregnancies.

Items	n = 21
Maternal age, years \pm SD (Min Max)	33.7 \pm 3.2 (26.9; 39.1)
Height, cm \pm SD	166.3 \pm 6.3
Weight, kg \pm SD	58.9 \pm 6.2
ART, n;(%)	9 (42.8)
Gestivity, mean \pm SD	1.1 \pm 0.7
Parity, mean \pm SD	0.2 \pm 0.4
Time interval between the MRI before pregnancy and the delivery, m (Min; Max)	19.6 \pm 8.5 (5.2; 39.5)
Time interval between the delivery and the MRI after pregnancy, m (Min; Max)	11.0 \pm 6.4 (3.1; 22.9)
C-section, n (%)	6 (28.5)
Number of DIE lesions, mean \pm SD	3.2 \pm 1.1
Hypertensive disease, n (%)	1 (4.8)
Gestational age at delivery, WG	38.4 \pm 2.9
Preterm birth < 37 WG, n (%)	3 (14.3)
SGA, n (%)	1 (4.8)

ART: assisted reproductive technology; WG: weeks of gestation, SGA: small for gestational age offspring.

<https://doi.org/10.1371/journal.pone.0223330.t001>

A total of 67 DIE lesions were compared before and after pregnancy. For these DIE lesions, the volume decreased for n = 49/67 lesions (73.1%), was stable for n = 5/67 lesions (7.5%), and increased for n = 13/67 lesions (19.4%). The mean overall DIE lesion volume by MRI was

Table 2. Distribution of the endometriotic lesions.

Patient	Posterior vaginal fornix	Uterosacral Ligaments*	Bowel	Bladder	OMA*
Case 1	1	0	0	0	1
Case 2	1	2	0	0	1
Case 3	1	2	1	0	2
Case 4	1	1	0	0	0
Case 5	1	2	1	0	0
Case 6	1	1	1	1	1
Case 7	1	1	1	0	1
Case 8	1	1	1	0	1
Case 9	1	1	1	1	0
Case 10	1	1	1	0	1
Case 11	0	1	0	0	1
Case 12	1	2	1	0	0
Case 13	1	1	1	1	1
Case 14	0	1	0	0	0
Case 15	1	2	1	0	2
Case 16	1	2	1	0	2
Case 17	1	2	0	0	1
Case 18	1	2	1	0	2
Case 19	1	2	1	0	1
Case 20	1	2	0	0	0
Case 21	1	2	1	0	1

OMA: Ovarian endometrioma

* 1: unilateral lesion 2: bilateral lesion

<https://doi.org/10.1371/journal.pone.0223330.t002>

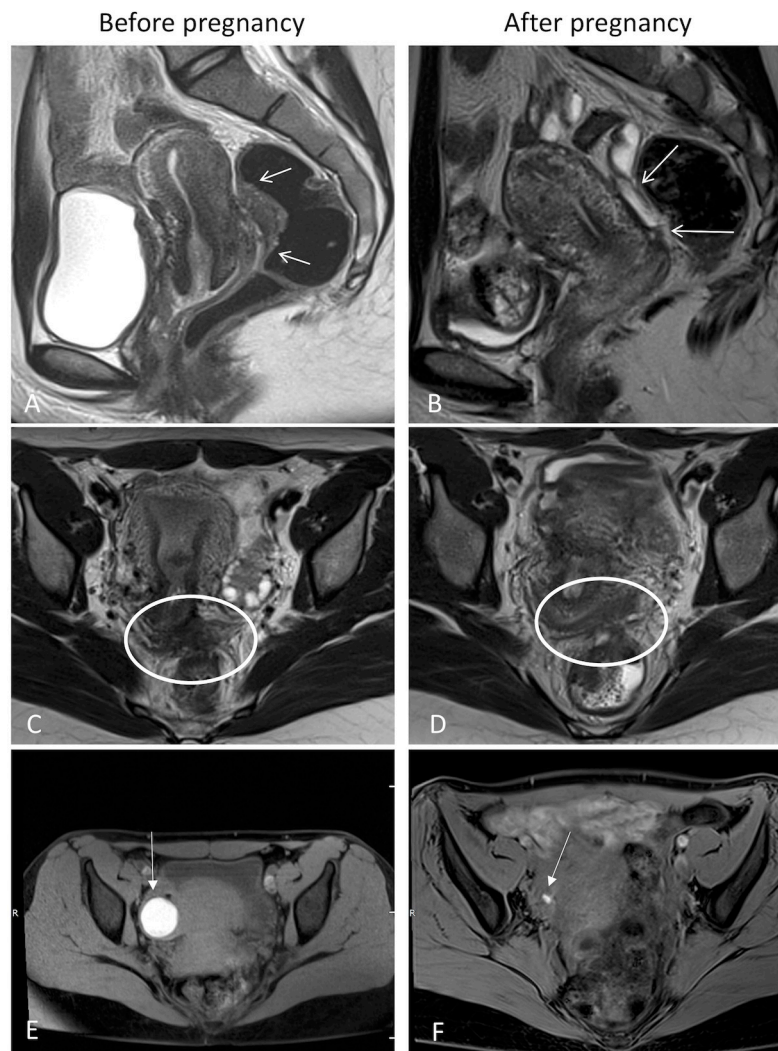


Fig 1. Magnetic resonance imaging of endometriosis, before and after pregnancy. (A,B) sagittal plane, deep infiltrative endometriosis of the bowel (white arrow); (C,D) axial plane, deep infiltrative endometriosis of the uterosacral ligaments and posterior vaginal fornix (white circle); (E,F) axial plane, ovarian endometriosis, axial plane with fat saturation, illustrating a left endometrioma in T1-hypersignal (white arrow).

<https://doi.org/10.1371/journal.pone.0223330.g001>

significantly higher before pregnancy compared to after pregnancy ($2,552 \pm 315 \text{ mm}^3$ vs. $1,708 \pm 3,266 \text{ mm}^3$, respectively, $p < 0.01$) (Table 3). In case of multiple DIE lesions, the mean volume of the largest lesion of each patient was significantly higher before pregnancy compared to after pregnancy ($4,728 \pm 4,776 \text{ mm}^3$ vs. $3,165 \pm 5,299 \text{ mm}^3$; $p < 0.01$) (Table 3). The OMA sizes were significantly higher before pregnancy (Table 3).

Discussion

This study provides the first report of MRI-based DIE lesion size changes before and after pregnancy. We found that there was a significant decrease in the volume of the DIE lesions after pregnancy. The size of the OMA was also significantly reduced.

The strength of this study lies in the following aspects of the methodological design: (i) the MRIs, before and after pregnancy, were performed on the same patient: each patient was

Table 3. Comparison of the volumes of the DIE lesions and the sizes of the OMAs before and after pregnancy by MRI.

Mean DIE lesion volume by MRI	n	Before pregnancy	After Pregnancy	P value
Overall DIE lesions, mm ³	67	2,552 ± 3,315	1,708 ± 3,266	< 0.01
Largest DIE lesion per patient, mm ³		4,728 ± 4,776	3,165 ± 5,299	< 0.01
USL lesions, mm ³	31	1,411 ± 1,485	518 ± 480	< 0.01
Posterior vaginal fornix, mm ³	19	2,741 ± 3,456	2,577 ± 3,318	0.57
Bowel lesions, mm ³	14	4,245 ± 4,579	3,342 ± 5,552	0.06
Bladder lesions, mm ³	3	5,245 ± 5,865	873 ± 553	0.50
Mean OMA size by MRI	19	11.3 ± 10.0	6.4 ± 6.6	0.03
OMA, mm				

DIE: deep infiltrating endometriosis, OMA: endometrioma, MRI: magnetic resonance imaging, USL uterosacral ligament. All of the measurements are presented as means ± the standard derivation.

<https://doi.org/10.1371/journal.pone.0223330.t003>

hence their own control; (ii) the MRIs were performed in a referral center by an experienced radiologist who is a referring practitioner for image-based diagnosis of endometriosis. It is now well accepted that, with experienced radiologists, imaging work-up allows for a non-surgical diagnosis of endometriosis; [5, 6] (iii) there had to be a one-month delay between the two MRI readings (before and after pregnancy) for each woman in order to limit any memory bias; [44] (iv) none of the women had a history of surgery for endometriosis, given the potential impact of pregnancy on DIE lesion progression.

The main shortcoming of our study stems from the lack of information regarding the hormonal cycle and lactation status of the women after delivery when the post-partum MRI was performed. Endometriosis lesions have not been shown to be the result of cellular growth, as is the case for tumors. [45, 46] Instead, endometriotic lesions undergo progressive fibrogenesis, starting with repetitive ectopic endometrial deposits that further evolve into fibrosis and smooth muscle metaplasia. [47, 48] DIE lesions should not be significantly influenced by fluctuations in extrinsic hormonal levels, which are very similar in women without endometriosis. [49] Yet, the local estrogen levels within lesions are significantly elevated [50] and endometriotic stromal and epithelial cells can be affected by menstrual phases, but not the extent of lesional fibrosis. Nevertheless, there have been reports of medical treatment of bladder or bowel DIE using low-dose oral contraceptives, aromatase inhibitors, GnRH agonists or dienogest, [51, 52] with various efficacies. In addition, it is unclear whether lactation has an impact on endometriosis lesions as there have been few studies to date in this regard. [11]

Our study highlights that there appears to be a significant decrease in the volume of DIE lesions after pregnancy. Of note, 13/67 (19.4%) of the DIE lesions increased in volume. A recent report in the literature that investigated a small number of cases of DIE lesions during pregnancy by ultrasound demonstrated a significant reduction in the size of DIE plaques, and that the nodules appeared to be less fibrotic and more homogeneous, with ill-defined contours. [30] Our data also highlight a significant reduction in the size of OMAs. There was no persistent decidualization after pregnancy among the 19 reported cases of OMA, which is similar to what has been reported elsewhere. [27, 53, 54] Although there is limited data regarding the growth dynamics of OMA with pregnancy, most investigators have reported regression or cessation of growth during pregnancy, thus corroborating our data. [53, 55] In a retrospective study, Ueda et al. reported on the natural progression of 25 ovarian endometriotic lesions observed during pregnancy in 24 women, with a decrease in the volume for 13 lesions (52%), and an increase in the volume for 5 lesions (20%). [32]

Our results support the hypothesis that a specific hormonal environment during pregnancy may positively impact the appearance of DIE lesions through several processes: (i) amenorrhea

and the absence of cyclic retrograde fallopian bleeding limiting peritoneal and ectopic implant stimulation;[3] (ii) anovulation secondary to the well-known hormonal ovarian blockade occurring during pregnancy;[56] (iii) high placental production of steroid hormones that may directly modify endometriotic lesions,[57], with a decrease in the intra- and peri-lesional inflammatory status and reduced production of prostaglandins and cytokines;[13] (iv) decidualization of the endometrium during pregnancy, corresponding with the transformation of stromal fibroblasts into epithelioid-like decidual cells and an adjoined massive influx of immune cells,[26] may participate in intrinsic changes that could persist after delivery.

In terms of clinical aspects, previously published studies have reported a beneficial role of pregnancy on endometriosis-related symptomatology,[30, 58–60] without any data regarding the change in the volume and the size of endometriotic lesions based on MRI. Our present study supports the hypothesis of a favorable effect of pregnancy on the volume of DIE lesions. In clinical practice, these results raise the question of the need to systematically perform surgery before pregnancy for DIE patients.[33] However, it is important to stress that, although rare, severe cases of complications during pregnancy, including spontaneous hemoperitoneum,[61] digestive perforation,[62] and ureteral rupture [63] have been linked with the puerperal changes of ectopic lesions. Further studies are necessary to more precisely define the indications for surgery for DIE patients who wish to become pregnant, since there is no clear evidence that surgery can prevent obstetrical risk in case of endometriosis.[64]

Conclusion

This study demonstrates, for the first time, a favorable effect of pregnancy on the volume of DIE lesions, which regressed significantly after pregnancy based on MRI evaluation. Longer follow-up is required to more extensively evaluate the change in DIE lesions during and after pregnancy.

Supporting information

S1 Dataset. Clinical and anatomical data.
(XLSX)

Acknowledgments

The authors wish to thank the staff members of the *Centre de Radiologie IMPC Bachaumont Pole femme-mere-enfant* and the OBGYN department at the Cochin Hospital, for their expert assistance with data collection. We also gratefully acknowledge Sophie Domingues for editing the manuscript.

Author Contributions

Conceptualization: Anne Elodie Millischer, Louis Marcellin.

Data curation: Anne Elodie Millischer, Louis Marcellin, Pietro Santulli, Chloe Maignien, Mathilde Bourdon.

Formal analysis: Anne Elodie Millischer, Louis Marcellin.

Investigation: Anne Elodie Millischer.

Methodology: Louis Marcellin, Pietro Santulli, François Goffinet.

Validation: Louis Marcellin, Pietro Santulli, Chloe Maignien, Mathilde Bourdon.

Visualization: Pietro Santulli, Chloe Maignien, Mathilde Bourdon, Charles Chapron.

Writing – original draft: Anne Elodie Millischer, Louis Marcellin.

Writing – review & editing: Anne Elodie Millischer, Louis Marcellin, Pietro Santulli, Bruno Borghese, François Goffinet, Charles Chapron.

References

1. de Ziegler D, Borghese B, Chapron C. Endometriosis and infertility: pathophysiology and management. *Lancet*. 2010; 376(9742):730–8. Epub 2010/08/31. S0140-6736(10)60490-4 [pii] [https://doi.org/10.1016/S0140-6736\(10\)60490-4](https://doi.org/10.1016/S0140-6736(10)60490-4) PMID: 20801404.
2. Giudice LC. Clinical practice. Endometriosis. *The New England journal of medicine*. 2010; 362(25):2389–98. Epub 2010/06/25. <https://doi.org/10.1056/NEJMcp1000274> PMID: 20573927; PubMed Central PMCID: PMC3108065.
3. Sampson JA. Metastatic or Embolic Endometriosis, due to the Menstrual Dissemination of Endometrial Tissue into the Venous Circulation. *The American journal of pathology*. 1927; 3(2):93–110 43. PMID: 19969738; PubMed Central PMCID: PMC1931779.
4. Tammaa A, Fritzer N, Lozano P, Krell A, Salzer H, Salama M, et al. Interobserver agreement and accuracy of non-invasive diagnosis of endometriosis by transvaginal sonography. *Ultrasound Obstet Gynecol*. 2015; 46(6):737–40. <https://doi.org/10.1002/uog.14843> PMID: 25766661.
5. Nisenblat V, Bossuyt PM, Farquhar C, Johnson N, Hull ML. Imaging modalities for the non-invasive diagnosis of endometriosis. *Cochrane Database Syst Rev*. 2016; 2:CD009591. <https://doi.org/10.1002/14651858.CD009591.pub2> PMID: 26919512.
6. Bazot M, Bharwani N, Huchon C, Kinkel K, Cunha TM, Guerra A, et al. European society of urogenital radiology (ESUR) guidelines: MR imaging of pelvic endometriosis. *Eur Radiol*. 2017; 27(7):2765–75. <https://doi.org/10.1007/s00330-016-4673-z> PMID: 27921160; PubMed Central PMCID: PMC5486785.
7. Medeiros LR, Rosa MI, Silva BR, Reis ME, Simon CS, Dondossola ER, et al. Accuracy of magnetic resonance in deeply infiltrating endometriosis: a systematic review and meta-analysis. *Arch Gynecol Obstet*. 2015; 291(3):611–21. <https://doi.org/10.1007/s00404-014-3470-7> PMID: 25288268.
8. Bazot M, Lafont C, Rouzier R, Roseau G, Thomassin-Naggara I, Darai E. Diagnostic accuracy of physical examination, transvaginal sonography, rectal endoscopic sonography, and magnetic resonance imaging to diagnose deep infiltrating endometriosis. *Fertil Steril*. 2009; 92(6):1825–33. <https://doi.org/10.1016/j.fertnstert.2008.09.005> PMID: 19019357.
9. Lessey BA, Kim JJ. Endometrial receptivity in the eutopic endometrium of women with endometriosis: it is affected, and let me show you why. *Fertil Steril*. 2017; 108(1):19–27. Epub 2017/06/13. <https://doi.org/10.1016/j.fertnstert.2017.05.031> PMID: 28602477; PubMed Central PMCID: PMC5629018.
10. Miravet-Valenciano J, Ruiz-Alonso M, Gomez E, Garcia-Velasco JA. Endometrial receptivity in eutopic endometrium in patients with endometriosis: it is not affected, and let me show you why. *Fertil Steril*. 2017; 108(1):28–31. Epub 2017/07/03. <https://doi.org/10.1016/j.fertnstert.2017.06.002> PMID: 28668152.
11. Leeners B, Damaso F, Ochsenein-Kolble N, Farquhar C. The effect of pregnancy on endometriosis—facts or fiction? *Hum Reprod Update*. 2018; 24(3):290–9. Epub 2018/02/23. <https://doi.org/10.1093/humupd/dmy004> PMID: 29471493.
12. Beecham CT. Surgical treatment of endometriosis with special reference to conservative surgery in young women. *J Am Med Assoc*. 1949; 139(15):971. <https://doi.org/10.1001/jama.1949.02900320001001> PMID: 18113902.
13. Leone Roberti Maggiore U, Ferrero S, Mangili G, Bergamini A, Inversetti A, Giorgione V, et al. A systematic review on endometriosis during pregnancy: diagnosis, misdiagnosis, complications and outcomes. *Hum Reprod Update*. 2016; 22(1):70–103. <https://doi.org/10.1093/humupd/dmv045> PMID: 26450609.
14. Santulli P, Marcellin L, Menard S, Thubert T, Khoshnood B, Gayet V, et al. Increased rate of spontaneous miscarriages in endometriosis-affected women. *Hum Reprod*. 2016; 31(5):1014–23. <https://doi.org/10.1093/humrep/dew035> PMID: 26965434.
15. Kortelahti M, Anttila MA, Hippelainen MI, Heinonen ST. Obstetric outcome in women with endometriosis—a matched case-control study. *Gynecol Obstet Invest*. 2003; 56(4):207–12. <https://doi.org/10.1159/000074815> PMID: 14614250.
16. Fernando S, Breheny S, Jaques AM, Halliday JL, Baker G, Healy D. Preterm birth, ovarian endometriomata, and assisted reproduction technologies. *Fertil Steril*. 2009; 91(2):325–30. <https://doi.org/10.1016/j.fertnstert.2008.01.096> PMID: 18384780.
17. Stephansson O, Kieler H, Granath F, Falconer H. Endometriosis, assisted reproduction technology, and risk of adverse pregnancy outcome. *Hum Reprod*. 2009; 24(9):2341–7. Epub 2009/05/15. <https://doi.org/10.1093/humrep/dep186> PMID: 19439428.

18. Benaglia L, Bermejo A, Somigliana E, Scarduelli C, Ragni G, Fedele L, et al. Pregnancy outcome in women with endometriomas achieving pregnancy through IVF. *Hum Reprod*. 2012; 27(6):1663–7. <https://doi.org/10.1093/humrep/des054> PMID: 22447627.
19. Vercellini P, Parazzini F, Pietropaolo G, Cipriani S, Frattaruolo MP, Fedele L. Pregnancy outcome in women with peritoneal, ovarian and rectovaginal endometriosis: a retrospective cohort study. *BJOG*. 2012; 119(12):1538–43. <https://doi.org/10.1111/j.1471-0528.2012.03466.x> PMID: 22900995.
20. Harada T, Taniguchi F, Onishi K, Kurozawa Y, Hayashi K, Harada T, et al. Obstetrical Complications in Women with Endometriosis: A Cohort Study in Japan. *PLoS One*. 2016; 11(12):e0168476. <https://doi.org/10.1371/journal.pone.0168476> PMID: 28005934; PubMed Central PMCID: PMC5179019.
21. Glavind MT, Forman A, Arendt LH, Nielsen K, Henriksen TB. Endometriosis and pregnancy complications: a Danish cohort study. *Fertil Steril*. 2017; 107(1):160–6. <https://doi.org/10.1016/j.fertnstert.2016.09.020> PMID: 27743699.
22. Saraswat L, Ayansina DT, Cooper KG, Bhattacharya S, Miligkos D, Horne AW, et al. Pregnancy outcomes in women with endometriosis: a national record linkage study. *BJOG*. 2017; 124(3):444–52. Epub 2016/02/19. <https://doi.org/10.1111/1471-0528.13920> PMID: 26887349.
23. Brosens I, Pijnenborg R, Benagiano G. Defective myometrial spiral artery remodelling as a cause of major obstetrical syndromes in endometriosis and adenomyosis. *Placenta*. 2013; 34(2):100–5. <https://doi.org/10.1016/j.placenta.2012.11.017> PMID: 23232321.
24. Brosens I, Pijnenborg R, Vercruysse L, Romero R. The "Great Obstetrical Syndromes" are associated with disorders of deep placentation. *Am J Obstet Gynecol*. 2011; 204(3):193–201. Epub 2010/11/26. <https://doi.org/10.1016/j.ajog.2010.08.009> PMID: 21094932; PubMed Central PMCID: PMC3369813.
25. Marcellin L, Santulli P, Gogusev J, Lesaffre C, Jacques S, Chapron C, et al. Endometriosis also affects the decidua in contact with the fetal membranes during pregnancy. *Hum Reprod*. 2015; 30(2):392–405. <https://doi.org/10.1093/humrep/deu321> PMID: 25432921.
26. Brosens JJ, Parker MG, McIndoe A, Pijnenborg R, Brosens IA. A role for menstruation in preconditioning the uterus for successful pregnancy. *Am J Obstet Gynecol*. 2009; 200(6):615 e1–6. Epub 2009/01/13. <https://doi.org/10.1016/j.ajog.2008.11.037> PMID: 19136085.
27. Sammour RN, Leibovitz Z, Shapiro I, Degani S, Levitan Z, Aharoni A, et al. Decidualization of ovarian endometriosis during pregnancy mimicking malignancy. *J Ultrasound Med*. 2005; 24(9):1289–94. <https://doi.org/10.7863/jum.2005.24.9.1289> PMID: 16123189
28. Schatz F, Guzeloglu-Kayisli O, Arlier S, Kayisli UA, Lockwood CJ. The role of decidual cells in uterine hemostasis, menstruation, inflammation, adverse pregnancy outcomes and abnormal uterine bleeding. *Hum Reprod Update*. 2016; 22(4):497–515. <https://doi.org/10.1093/humupd/dmw004> PMID: 26912000; PubMed Central PMCID: PMC4917742.
29. Gellersen B, Brosens JJ. Cyclic decidualization of the human endometrium in reproductive health and failure. *Endocr Rev*. 2014; 35(6):851–905. Epub 2014/08/21. <https://doi.org/10.1210/er.2014-1045> PMID: 25141152.
30. Coccia ME, Rizzello F, Palagiano A, Scarselli G. The effect of the hormonal milieu of pregnancy on deep infiltrating endometriosis: serial ultrasound assessment of changes in size and pattern of deep endometriotic lesions. *Eur J Obstet Gynecol Reprod Biol*. 2012; 160(1):35–9. <https://doi.org/10.1016/j.ejogrb.2011.10.004> PMID: 22099535.
31. Vannuccini S, Clifton VL, Fraser IS, Taylor HS, Critchley H, Giudice LC, et al. Infertility and reproductive disorders: impact of hormonal and inflammatory mechanisms on pregnancy outcome. *Hum Reprod Update*. 2016; 22(1):104–15. Epub 2015/09/24. <https://doi.org/10.1093/humupd/dmv044> PMID: 26395640.
32. Ueda Y, Enomoto T, Miyatake T, Fujita M, Yamamoto R, Kanagawa T, et al. A retrospective analysis of ovarian endometriosis during pregnancy. *Fertil Steril*. 2010; 94(1):78–84. <https://doi.org/10.1016/j.fertnstert.2009.02.092> PMID: 19356751.
33. Maignien C, Santulli P, Gayet V, Lafay-Pillet MC, Korb D, Bourdon M, et al. Prognostic factors for assisted reproductive technology in women with endometriosis-related infertility. *Am J Obstet Gynecol*. 2017; 216(3):280 e1–e9. <https://doi.org/10.1016/j.ajog.2016.11.1042> PMID: 27899313.
34. Cabrol D, Goffinet F. *Protocoles cliniques en obstétrique*. 4ème édition ed2013.
35. Kinkel K, Frei KA, Balleyguier C, Chapron C. Diagnosis of endometriosis with imaging: a review. *Eur Radiol*. 2006; 16(2):285–98. <https://doi.org/10.1007/s00330-005-2882-y> PMID: 16155722.
36. Millischer AE, Salomon LJ, Santulli P, Borghese B, Dousset B, Chapron C. Fusion imaging for evaluation of deep infiltrating endometriosis: feasibility and preliminary results. *Ultrasound Obstet Gynecol*. 2015; 46(1):109–17. <https://doi.org/10.1002/uog.14712> PMID: 25358293.
37. Millischer AE, Salomon LJ, Porcher R, Brasseur-Daudruy M, Gourdiér AL, Hornoy P, et al. Magnetic resonance imaging for abnormally invasive placenta: the added value of intravenous gadolinium

- injection. *BJOG*. 2017; 124(1):88–95. Epub 2016/06/28. <https://doi.org/10.1111/1471-0528.14164> PMID: 27346286.
38. de Venecia C, Ascher SM. Pelvic Endometriosis: Spectrum of Magnetic Resonance Imaging Findings. *Semin Ultrasound CT MR*. 2015; 36(4):385–93. Epub 2015/08/25. <https://doi.org/10.1053/j.sult.2015.05.001> PMID: 26296488.
39. Togashi K, Nishimura K, Kimura I, Tsuda Y, Yamashita K, Shibata T, et al. Endometrial cysts: diagnosis with MR imaging. *Radiology*. 1991; 180(1):73–8. Epub 1991/07/01. <https://doi.org/10.1148/radiology.180.1.2052726> PMID: 2052726.
40. Siegelman ES, Oliver ER. MR imaging of endometriosis: ten imaging pearls. *Radiographics*. 2012; 32(6):1675–91. Epub 2012/10/16. <https://doi.org/10.1148/rg.326125518> PMID: 23065164.
41. Yoon JH, Choi D, Jang KT, Kim CK, Kim H, Lee SJ, et al. Deep rectosigmoid endometriosis: "mushroom cap" sign on T2-weighted MR imaging. *Abdom Imaging*. 2010; 35(6):726–31. Epub 2010/09/08. <https://doi.org/10.1007/s00261-010-9643-3> PMID: 20820774.
42. Chapron C, Chopin N, Borghese B, Foulot H, Dousset B, Vacher-Lavenu MC, et al. Deeply infiltrating endometriosis: pathogenetic implications of the anatomical distribution. *Hum Reprod*. 2006; 21(7):1839–45. <https://doi.org/10.1093/humrep/del079> PMID: 16543256.
43. Tomayko MM, Reynolds CP. Determination of subcutaneous tumor size in athymic (nude) mice. *Cancer Chemother Pharmacol*. 1989; 24(3):148–54. <https://doi.org/10.1007/bf00300234> PMID: 2544306.
44. Saba L, Guerriero S, Sulcis R, Ajossa S, Melis G, Mallarini G. Agreement and reproducibility in identification of endometriosis using magnetic resonance imaging. *Acta Radiol*. 2010; 51(5):573–80. Epub 2010/04/13. <https://doi.org/10.3109/02841851003657343> PMID: 20380608.
45. Hans Evers JL. Is adolescent endometriosis a progressive disease that needs to be diagnosed and treated? *Hum Reprod*. 2013; 28(8):2023. Epub 2013/07/19. <https://doi.org/10.1093/humrep/det298> PMID: 23861497.
46. Fedele L, Bianchi S, Zanconato G, Raffaelli R, Berlanda N. Is rectovaginal endometriosis a progressive disease? *Am J Obstet Gynecol*. 2004; 191(5):1539–42. Epub 2004/11/18. <https://doi.org/10.1016/j.ajog.2004.06.104> PMID: 15547522.
47. Vigano P, Candiani M, Monno A, Giacomini E, Vercellini P, Somigliana E. Time to redefine endometriosis including its pro-fibrotic nature. *Hum Reprod*. 2018; 33(3):347–52. Epub 2017/12/06. <https://doi.org/10.1093/humrep/dex354> PMID: 29206943.
48. Guo SW. Fibrogenesis resulting from cyclic bleeding: the Holy Grail of the natural history of ectopic endometrium. *Hum Reprod*. 2018; 33(3):353–6. Epub 2018/02/09. <https://doi.org/10.1093/humrep/dey015> PMID: 29420711.
49. Huhtinen K, Desai R, Stahle M, Salminen A, Handelsman DJ, Perheentupa A, et al. Endometrial and endometriotic concentrations of estrone and estradiol are determined by local metabolism rather than circulating levels. *J Clin Endocrinol Metab*. 2012; 97(11):4228–35. Epub 2012/09/13. <https://doi.org/10.1210/jc.2012-1154> PMID: 22969138; PubMed Central PMCID: PMC3485603.
50. Bulun SE, Zeitoun K, Takayama K, Noble L, Michael D, Simpson E, et al. Estrogen production in endometriosis and use of aromatase inhibitors to treat endometriosis. *Endocr Relat Cancer*. 1999; 6(2):293–301. Epub 2000/03/24. PMID: 10731122.
51. Vercellini P, Buggio L, Somigliana E. Role of medical therapy in the management of deep rectovaginal endometriosis. *Fertil Steril*. 2017; 108(6):913–30. Epub 2017/12/06. <https://doi.org/10.1016/j.fertnstert.2017.08.038> PMID: 29202965.
52. Brown J, Crawford TJ, Datta S, Prentice A. Oral contraceptives for pain associated with endometriosis. *Cochrane Database Syst Rev*. 2018; 5:CD001019. Epub 2018/05/23. <https://doi.org/10.1002/14651858.CD001019.pub3> PMID: 29786828; PubMed Central PMCID: PMC6494634.
53. Benaglia L, Somigliana E, Calzolari L, Busnelli A, Cardellicchio L, Ragni G, et al. The vanishing endometrioma: the intriguing impact of pregnancy on small endometriotic ovarian cysts. *Gynecol Endocrinol*. 2013; 29(9):863–6. <https://doi.org/10.3109/09513590.2013.813476> PMID: 23844984.
54. Mascilini F, Moruzzi C, Giansiracusa C, Guastafierro F, Savelli L, De Meis L, et al. Imaging in gynecological disease. 10: Clinical and ultrasound characteristics of decidualized endometriomas surgically removed during pregnancy. *Ultrasound Obstet Gynecol*. 2014; 44(3):354–60. <https://doi.org/10.1002/uog.13323> PMID: 24496773.
55. Bailleux M, Bernard JP, Benachi A, Deffieux X. Ovarian endometriosis during pregnancy: a series of 53 endometriomas. *Eur J Obstet Gynecol Reprod Biol*. 2017; 209:100–4. <https://doi.org/10.1016/j.ejogrb.2015.09.037> PMID: 26482730.
56. Santulli P, Borghese B, Noel JC, Fayt I, Anaf V, de Ziegler D, et al. Hormonal therapy deregulates prostaglandin-endoperoxidase synthase 2 (PTGS2) expression in endometriotic tissues. *J Clin Endocrinol Metab*. 2014; 99(3):881–90. <https://doi.org/10.1210/jc.2013-2950> PMID: 24423291.

57. Vercellini P, Crosignani PG, Somigliana E, Berlanda N, Barbara G, Fedele L. Medical treatment for rectovaginal endometriosis: what is the evidence? *Hum Reprod*. 2009; 24(10):2504–14. <https://doi.org/10.1093/humrep/dep231> PMID: 19574277.
58. Busacca M, Chiaffarino F, Candiani M, Vignali M, Bertulesi C, Oggioni G, et al. Determinants of long-term clinically detected recurrence rates of deep, ovarian, and pelvic endometriosis. *Am J Obstet Gynecol*. 2006; 195(2):426–32. <https://doi.org/10.1016/j.ajog.2006.01.078> PMID: 16890551.
59. Porpora MG, Pallante D, Ferro A, Crisafi B, Bellati F, Benedetti Panici P. Pain and ovarian endometrioma recurrence after laparoscopic treatment of endometriosis: a long-term prospective study. *Fertil Steril*. 2010; 93(3):716–21. <https://doi.org/10.1016/j.fertnstert.2008.10.018> PMID: 19061997.
60. Alberico D, Somigliana E, Bracco B, Dhrouha D, Roberto A, Mosconi P, et al. Potential benefits of pregnancy on endometriosis symptoms. *Eur J Obstet Gynecol Reprod Biol*. 2018; 230:182–7. Epub 2018/10/12. <https://doi.org/10.1016/j.ejogrb.2018.08.576> PMID: 30308401.
61. Lier M, Malik RF, van Waesberghe J, Maas JW, van Rumpt-van de Geest DA, Coppus SF, et al. Spontaneous haemoperitoneum in pregnancy and endometriosis: a case series. *BJOG*. 2017; 124(2):306–12. Epub 2016/10/06. <https://doi.org/10.1111/1471-0528.14371> PMID: 27704657.
62. Setubal A, Sidiropoulou Z, Torgal M, Casal E, Lourenco C, Koninckx P. Bowel complications of deep endometriosis during pregnancy or in vitro fertilization. *Fertil Steril*. 2014; 101(2):442–6. <https://doi.org/10.1016/j.fertnstert.2013.11.001> PMID: 24360567.
63. Chiodo I, Somigliana E, Dousset B, Chapron C. Urohemoperitoneum during pregnancy with consequent fetal death in a patient with deep endometriosis. *J Minim Invasive Gynecol*. 2008; 15(2):202–4. <https://doi.org/10.1016/j.jmig.2007.09.004> PMID: 18312991.
64. Nirgianakis K, Gasparri ML, Radan AP, Villiger A, McKinnon B, Mosimann B, et al. Obstetric complications after laparoscopic excision of posterior deep infiltrating endometriosis: a case-control study. *Fertil Steril*. 2018; 110(3):459–66. Epub 2018/08/14. <https://doi.org/10.1016/j.fertnstert.2018.04.036> PMID: 30098698