



HAL
open science

Periodontal regenerative medicine using mesenchymal stem cells and biomaterials: A systematic review of pre-clinical studies

Sophie Portron, Assem Soueidan, Anne-Claire Marsden, Mia Rakic, Christian Verner, Pierre Weiss, Zahi Badran, Xavier Struillou

► To cite this version:

Sophie Portron, Assem Soueidan, Anne-Claire Marsden, Mia Rakic, Christian Verner, et al.. Periodontal regenerative medicine using mesenchymal stem cells and biomaterials: A systematic review of pre-clinical studies. Dental Materials Journal, 2019, Epub ahead of print. 10.4012/dmj.2018-315 . inserm-02288765

HAL Id: inserm-02288765

<https://inserm.hal.science/inserm-02288765>

Submitted on 16 Sep 2019

HAL is a multi-disciplinary open access archive for the deposit and dissemination of scientific research documents, whether they are published or not. The documents may come from teaching and research institutions in France or abroad, or from public or private research centers.

L'archive ouverte pluridisciplinaire **HAL**, est destinée au dépôt et à la diffusion de documents scientifiques de niveau recherche, publiés ou non, émanant des établissements d'enseignement et de recherche français ou étrangers, des laboratoires publics ou privés.

Periodontal regenerative medicine using mesenchymal stem cells and biomaterials: A systematic review of pre-clinical studies

Sophie PORTRON^{1,2}, Assem SOUEIDAN^{1,2}, Anne-Claire MARSDEN², Mia RAKIC^{1,2}, Christian VERNER², Pierre WEISS¹, Zahi BADRAN^{1,2} and Xavier STRUILLLOU^{1,2}

¹Inserm, UMR 1229, RMeS, Regenerative Medicine and Skeleton, University of Nantes, ONIRIS, Nantes, F-44042, France

²Department of Periodontology, Faculty of Dental Surgery, University of Nantes, Nantes, F-44042, France

Corresponding author, Xavier STRUILLLOU; E-mail: xavier.struilllou@univ-nantes.fr

The aim of the systematic review was to analyze the use of mesenchymal stem cells (MSC) and biomaterial for periodontal regeneration from preclinical animal models and human. Electronic databases were searched and additional hand-search in leading journals was performed. The research strategy was achieved according to the Preferred Reporting Items for Systematic Reviews and Meta-Analyses (PRISMA) guidelines. The including criteria were as follows: MSC, biomaterial, *in vivo* studies, with histologic and radiologic analysis and written in English. The risk of bias was assessed for individual studies. A total of 50 articles were selected and investigated in the systematic review. These results indicate that MSC and scaffold provide beneficial effects on periodontal regeneration, with no adverse effects of such interventions. Future studies need to identify the suitable association of MSC and biomaterial and to characterize the type of new cementum and the organization of the periodontal ligament fiber regeneration.

Keywords: Mesenchymal stem cells, Biomaterial, Periodontal regeneration, Pre-clinical study

INTRODUCTION

The periodontium is a highly specialized and dynamic tissue. It consists in a tooth-anchoring device made of two soft tissues, the gingiva and the periodontal ligament, and of two hard tissues, the cement and the alveolar bone. The gingiva, part of the superficial periodontium, is composed of an epithelium and a connective tissue, forming a periodontal attachment system that allows fluid exchange and assures a complete crimp around the tooth¹. As for the deep periodontium, made of the periodontal ligament, the cement and the alveolar bone, it acts like an alveolar anchorage system, enabling both stability and damping of the tooth. In the oral environment, the periodontium is confronted with more than 1,000 bacteria species². Thus, the space between the tooth and the surrounding gingiva, called sulcus, can become a gateway to potential inflammatory diseases. The most common cause of periodontal destruction is periodontitis^{3,4}. This multifactorial disease is due to an opportunistic bacteria contamination on a specific site, paired with local risk factors (*e.g.*, insufficient oral hygiene, decay) and general risk factors (*e.g.*, HIV, diabetes). In response to this bacterial aggression, an inflammatory process in the gingival sulcus will slowly destroy the periodontal structures and attachment, leading to tooth mobility and premature tooth loss⁵.

Conventional treatment strategies are based on a sustained decrease in the microbial load through a non-surgical or a surgical elimination of the dental plaque associated with assiduous plaque control from the patient. In spite of great progress in the understanding

of the pathogenesis of periodontitis, the tools to treat it seem to only postpone the unavoidable tooth loss linked to periodontal disease, and fail to restore *ad integrum* periodontal tissue, proving it unsatisfactory both for patients and for dental surgeons. Since the 1970s, several procedures have been attempted to restore such lost tissues, including autogenous bone grafting, implantation of biomaterials including bone derivatives and bone substitutes, guided-tissue regeneration (GTR) procedures⁶, and implantation of biologic factors, including enamel matrix proteins^{7,8}. Still, these strategies fail to regenerate the complete periodontium damage since the quality of repaired tissue remain variable and limited^{9,10}. To date, complete periodontal regeneration is not achievable in a highly reproducible and easy way. Therefore, functional and aesthetic sequelae are commonly found in treated patients with a history of periodontitis.

That is why, re-establishing the original structure, properties and functions of the diseased periodontium remains a significant clinical challenge. To address this issue, regenerative medicine using an effective combination of mesenchymal stem cells (MSC) and biomaterial have become subjects of particular interest¹¹. Thus, a wide variety of the studies focus on MSC and try to combine their potential with suitable biomaterials in order to obtain a periodontal regeneration¹². Despite numerous publications in pre-clinical animal models and humans, the efficacy of the association of MSC and biomaterial for periodontal regeneration remain controversial^{13,14}.

To increase the value of individual preclinical studies as proof of concept for randomized clinical trials, systematic reviews have been proposed as the

Color figures can be viewed in the online issue, which is available at J-STAGE.

Received Sep 21, 2018; Accepted Jan 10, 2019

doi:10.4012/dmj.2018-315 JOI JST.JSTAGE/dmj/2018-315

standard method for analyzing experimental work involving animals¹⁵). Systematic review is an essential tool for summarizing evidence reliably and accurately. It provides a starting point for guideline developers for clinical practice. In the case of regenerative medicine for the enhancement of periodontal regeneration, a systematic review may provide valuable information for a suitable clinical practice.

In this context, the purpose of the present systematic review was to assess the scientific literature to obtain more clarity on the efficacy of periodontal regeneration strategies using the association of MSC and biomaterials in pre-clinical animal and human studies.

MATERIALS AND METHODS

The different studies concerning periodontal regeneration with the help of MSC and biomaterials on human or animal models have been collected and analyzed.

Information sources and search strategy

The research strategy was achieved according to the Preferred Reporting Items for Systematic Reviews and Meta-Analyses (PRISMA) guidelines¹⁵) as much as possible. Original articles were searched using electronic and manual databases until March 2018. Furthermore, relevant articles were screened by hand to potentially add relevant new articles.

This search was applied to Medline, Cochrane Library, Lilacs and Report Evidence-based Practice Centers (EPC). Electronic searches were completed by additional hand-search performed for the International Journal of Periodontics and Restorative Dentistry, the Journal of Clinical Periodontology, the Journal of Dental Research, the Journal of Periodontal Research and the Journal of Periodontology.

The following Medical Subject Heading (MeSH) terms and keywords were used: “stem cell”, “periodontal”, “regeneration”, “biomaterial”, and “*in vivo*”. Only English articles were included, and no publication dates or publication status restrictions were imposed.

Study selection and inclusion/exclusion criteria

For the selection of studies, two investigators (SP, XS) screened the titles and the abstracts of the publications in an unblinded, standardized manner. Selection was

based on the inclusion and exclusion criteria defined so as to include only the most valuable articles (Table 1). Studies deemed to meet the inclusion criteria and those with insufficient information to make a clear decision were selected. The second phase consisted of assessing the whole articles by the same investigators to determine the eligibility of the study. The selection process was recorded in detail to a PRISMA flow diagram (Fig. 1). Any disagreements between the two investigators regarding inclusion of a study were resolved by discussion.

Data collection process and data items

The characteristics of the study were extracted independently by the same investigators and recorded. The data were compared for accuracy and any discrepancies were discussed and resolved by consensus.

Both reviewers extracted from the included studies the following data: (1) Cell type, passage number, differentiation, number per defect; (2) Biomaterial (+/-membrane); (3) Animal models: species, strain, sex, age, weight; (4) Number of defects per group; (5) Defect type, size, induced inflammation; (6) Treatment groups; (7) Observation period; (8) Qualification of newly formed tissues; (9) Results (Table 2). If one of these data is not reported in the Table, it means that the information is not mentioned by the authors.

Risk of bias in individual studies

To ascertain the risk of bias in eligible articles, the same investigators in a blind manner evaluated their methodology either by SYRCLE's Risk of Bias tool for animal intervention studies¹⁶), or by Risk Of Bias in Nonrandomized Studies of Interventions (ROBINS-I) tool¹⁷) modified for human non-randomized trials; or by the Cochrane Collaboration's tool for human randomized trials¹⁸). The case reports were excluded from the risk of bias analysis because of the absence of adapted methodology.

Regarding SYRCLE's Risk of Bias tool, the unit of analysis errors is assessed as a “high risk of bias” if the interventions to parts of the body within one participant (*i.e.*, splits mouth: control and experimental side) was reported. In addition, many items remain as “unclear” due to the poor description of methodology. In order to complete the investigation, two items were added

Table 1 Inclusion and exclusion criteria

Inclusion criteria:	Exclusion criteria:
<ul style="list-style-type: none"> ✓ Studies using MSC ✓ Studies using biomaterial ✓ Studies with the precise number of specimens ✓ <i>in vivo</i> studies ✓ Studies with histologic and radiologic analysis ✓ Studies written in English 	<ul style="list-style-type: none"> - Studies using only MSC - Studies using growth factors only - <i>in vitro</i> studies - <i>in vivo</i> studies on rodents and lagomorphs - Studies on implant or bone regeneration only - Studies with $p > 0.05$ - Review - Studies without control groups

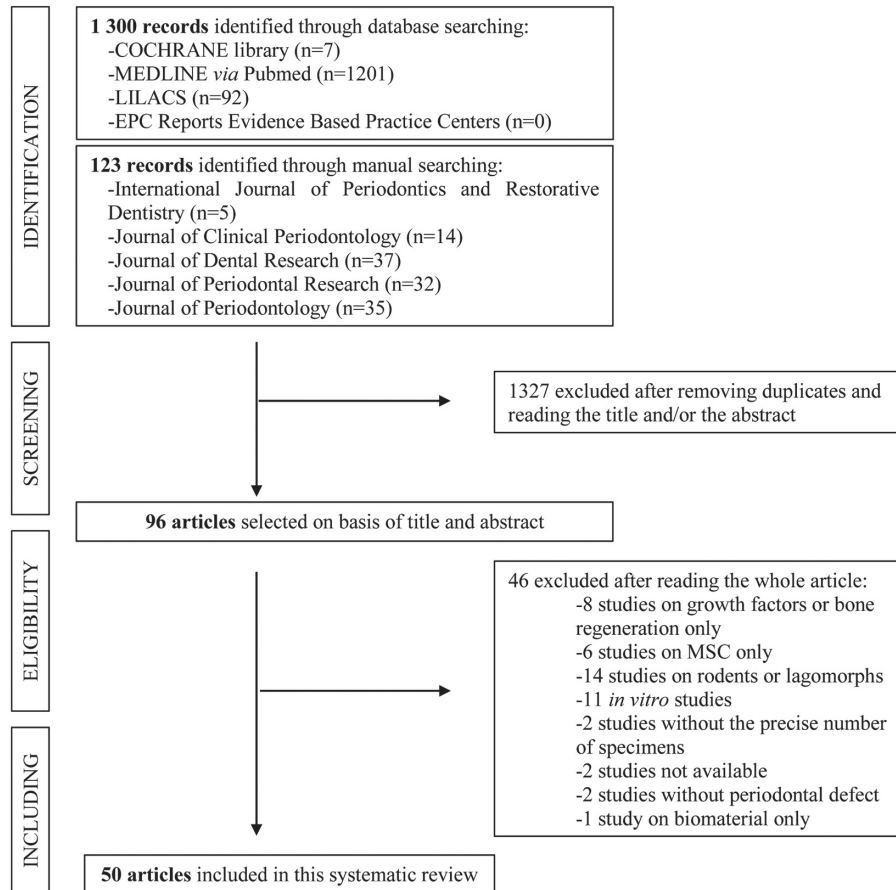


Fig. 1 PRISMA flowchart for identifying eligible studies.

mentioned as follows: “mention of randomization” and “mention of binding”.

Concerning the Cochrane Collaboration’s and SYRCLE’s Risk of Bias tool, we considered that there was no exclusion of animals when the number of animals reported in the method section equaled to the number mentioned in the results section. Disagreements between the investigators were resolved by consensus.

Data synthesis

A meta-analysis could not be performed because of the studies’ heterogeneity. Consequently, we conducted a descriptive and systematic analysis of the studies.

RESULTS

Study selection

Taking into account the previously defined criteria, 1,423 studies were initially identified (Fig. 1). The electronic search of Medline, Cochrane library, Lilacs, EPC databases provided 1,300 articles. Additionally, 123 studies were selected by hand-searching the International Journal of Periodontics and Restorative Dentistry, the Journal of Clinical Periodontology, the Journal of Dental Research, the Journal of Periodontal

Research and the Journal of Periodontology. After adjusting for duplicates and reading the title and/or the abstract, 96 studies remained. Out of these, 96 were discarded because after reviewing the whole article, it appeared that these papers clearly did not meet the inclusion criteria. A total of 50 articles were included in the systematic review.

Study characteristics

The studies were then ranked in a comparative Table (Tables 2 and 3) according to the alphabetical order. These tables show a wide variety of combinations of MSC and biomaterials. The review began with an analysis of the type of population, mainly of preclinical animal species. Indeed, experimental models in majority are found in dogs, employed in 25 studies. Twelve studies were performed with miniature pigs and two with sheep. Only 11 studies have been performed with humans. A variety of periodontal defects were used in the selected studies, including class III furcation defects (7 studies), fenestration defects (3 studies), intrabony with class II furcation defects (1 study), class II furcation defects (6 studies), dehiscence defects (2 studies), a root-shaped implant sockets (2 studies), alveolar sockets (2 studies), combined periodontal-endodontic lesions (1 study) but

Table 2 Comparative table of pre-clinical animal studies in periodontal regeneration combining MSC and biomaterials

Reference	Cell type/ passage number/ differentiation/ number per defect	Biomaterial+/- membrane	Animal model/ species/sex/age/ weight	Number of defects per group	Defect type/size/ induced inflammation	Treatment groups	Observation period	Qualification of newly formed tissues	Results
Akizaki T <i>et al.</i> 2005 ⁽⁴⁾	-PDLSC -P4-6 -vit C stimulation -1×10 ⁵ /sheet	Hyaluronic acid sheet	DOG Beagle, female, 3 years-old, 9.8 and 11.2 kg	5 (a, b)	-dehiscence defects -5×5mm ² -no inflammation	(a) PDLSC+hyaluronic acid sheet (b) hyaluronic acid sheet	2 months	- <u>Histological</u> : HES, Masson trichrome staining - <u>Histomorphometric</u>	No sign of inflammation or recession in the 2 groups. Formation of cement, bone, and ligament more significant in the group (a) than in the group (b)
Chen G <i>et al.</i> 2015 ⁽⁵⁾	-DFSC -undifferentiated	Gelatin electrospun sheet (APES)+treated dentin matrix (TDM)+native dental pulp extracellular matrix (DPEM)	MINIATURE PIG 1 year old	3 (a, b)	-root-shaped implant socket -no inflammation	(a) DFSC+DPEM+APES+TDM (b) TDM	3 months	- <u>Histological</u> - <u>Radiological</u> : micro-CT - <u>Immunohistochemical</u> : Col-1, Col-3, periostin, DMP-1 sialoprophosphoprotein, GFP	The sandwich composites APES/TDM/ DPEM and DFSC generated periodontal ligament -like tissues
Ding G <i>et al.</i> 2010 ⁽³⁾	-PDLSC -P0 -undifferentiated -2 cell sheets	HA/β-TCP +gelatin membrane	MINIATURE PIG female Wuzhishan, male Guizhou, 6-8 months old, 30-40 kg	6 (a, b, c, d, e)	-intrabony defects -3×7×5mm ³ -inflammation	(a) PDLSC autologous+HA-β-TCP (b) PDLSC allogenic+HA-β-TCP (c) PDLSC autologous and allogenic+HA-β-TCP (d) HA+β-TCP (e) empty defect	3 months	- <u>Clinical</u> : CAL, PD, GR, blood and biochemical tests - <u>Histological</u> : HES - <u>Histomorphometric</u> - <u>Radiological</u> : CT	Allogenic and autogenous PDLSC have improved periodontal regeneration in the same way compared to other groups; with a nearly complete recovery of bone cement and ligament
Dogan A <i>et al.</i> 2002 ⁽⁶⁾	-regenerated periodontal ligament derived cells -P4 -undifferentiated -2×10 ⁵	Autologous blood coagulum	Dog	2 (a, b)	-class II furcation defects -5×2 mm ² -no inflammation	(a) regenerated periodontal ligament derived cells+autologous blood coagulum (b) empty	1, 5 months	- <u>Histological</u> : HES - <u>Histomorphometric</u>	Seeding of cells into periodontal defects promote the bone regeneration and adaptation of connective tissue fibers on exposed dentin surface with limited cementum formation
Dogan A <i>et al.</i> 2003 ⁽⁷⁾	-regenerated periodontal ligament derived cells -P4 -undifferentiated -2×10 ⁵	Autologous blood coagulum	Dog	2 (a, b)	-fenestration defects -5×5 mm ² -no inflammation	(a) regenerated periodontal ligament derived cells+autologous blood coagulum (b) empty	1, 5 months	- <u>Histological</u> : HES - <u>Histomorphometric</u>	In the cell-seeding group, the main periodontal healing pattern was connective tissue adaptation, characterized by parallel bundles of collagen fibrils resting on root dentin

Table 2 continued

Fawzy El-Sayed KM <i>et al.</i> 2012 ⁽⁴¹⁾	-GMSC -P3 undifferentiated 2×10^7	Bio oss® +Bio-Gide®	MINIATURE PIG 1 female and 7 males, 18±1 months old, 46.9±4.6 kg	8 (a, b, c, d, e, f)	-intrabony defects -3×7×5 mm ³ -inflammation	(a) GMSC+Bio oss® (b) GMSC+collagen scaffold (c) bio oss® (d) collagen scaffold (e) mucoperiosteal flap and root planning only (f) without intervention	-Clinical: CAL, PD, GR, BOP, PI -Histological: HES -Histomorphometric -Radiological: CT	The treatments with GMSC compared with scaffolds alone or control groups have entailed better results
Fawzy El-Sayed KM <i>et al.</i> 2015 ⁽⁴³⁾	-GMSC -P3 undifferentiated 2×10^7	IL-1ra-releasing HA-ECM +Bio-Gide®	MINIATURE PIG 2 females and 6 males, 5-6 years old, 50.8±7.2 kg	8 (a, b, c, d)	-intrabony defects -3×7×5 mm ³ -inflammation	(a) GMSC+IL-1ra-HA-ECM (b) GMSC+HA-ECM (c) mucoperiosteal flap and root planning only (d) without intervention	-Clinical: CAL, PD, GR, BOP, PI -Histological: HES -Histomorphometric -Radiological: CT	Outcomes were significantly better in experimental groups (a, b) as compared to control groups (c, d). The results support the concept of cell-based therapy in conjunction with suitable scaffolds for future periodontal regeneration
Fu X <i>et al.</i> 2014 ⁽⁴⁸⁾	-PDLSC or SHED -P3 vit C stimulation 2 cell sheets	HA/β-TCP	MINIATURE PIG female, 9-12 months old, 40-45 kg	6 (a, b, c)	-intrabony defects -5×7×7 mm ³ -inflammation	(a) PDLSC+HA-β-TCP (b) SHED+HA-β-TCP (c) HA-β-TCP	-Clinical: CAL, PD, GR -Histological: HES -Radiological: CT	No significant difference between the 2 groups PDLSC and SHED, both have significantly improved periodontal regeneration with a very small inflammatory area
Gao ZH <i>et al.</i> 2016 ⁽⁴⁹⁾	PDLSC: -P3 vit C stimulation 2 cell sheets DFSC: -P2-P3 undifferentiated 2×10^6	HA/TCP	MINIATURE PIG 18 months old, 50-60 kg	46 (a) 9 (b)	-root-shaped implant socket -4.1×10 mm ² -no inflammation	(a) HA+TCP+DPSC+PDLSC (b) dental implants	-Clinical: PD, GR, gingivitis, peri-implantitis -Histological: HES, toluidine blue staining -Radiological: CT, micro-CT -Biochemical: compressive strength, modulus of elasticity, torsional force -SEM	These data showed that the group (a) could function as well as the group (b). Histological staining showed that PDL like and bone tissue had been generated, similar to the natural sample in both groups. Neither the group (a) nor the group (b) showed gingivitis or peri-implantitis. However, the restoration success rate was significantly lower in with the group (a) than with the group (b)
Hasegawa N <i>et al.</i> 2006 ⁽⁵²⁾	-BMSC undifferentiated 2×10^7	Atelocollagen	DOG Beagle, female, 12-20 months old, 10-14 kg	6 (unclear)	-class III furcation defects -4mm in depth -no inflammation	(a) BMSC+atelocollagen (b) no treatment	-Histological: HES -Immunohistochemical: GFP, Proliferating Cell Nuclear Antigen (PCNA)	Outcome showed that the defects were almost regenerated with cementum, periodontal ligament, and alveolar bone after MSC transplantation
Inukai T <i>et al.</i> 2013 ⁽⁵³⁾	-PDLSC undifferentiated	Atelocollagen	DOG 18-36 months old, 15-25 kg	5 (unclear)	-intrabony defects -4×5 mm ² -no inflammation	(a) PDLSC+atelocollagen (b) atelocollagen+PBS (c) no treatment	-Histological: HES -Histomorphometric -Radiological: dental X-ray	Both cement and bone heights as well as bone surface were more significant in the group with PDLSC
Iwata T <i>et al.</i> 2009 ⁽⁵⁶⁾	-PDLSC -P3 osteoinductive medium 9×10^4	PGA/β-TCP	DOG Beagle male, 10 kg	4 (a, b)	-intrabony defects -5×5×4 mm ³ -no inflammation	(a) PDLSC+PGA+β-TCP (b) PGA+β-TCP	-Histological: HES, Azan staining -Histomorphometric -Radiological: micro-CT	PDLSC permitted bone and cement regeneration with correctly orientated collagen while a limited formation bone was noted in the control group

Table 2 continued

Jiang J <i>et al.</i> 2010 ⁽⁶⁰⁾	-Periodontal cells -P3 -undifferentiated -5×10 ⁶	β-TCP +ePTFE membranes	DOG Beagle, 9.5 and 10.5 kg (a, b, c)	4 (a, b, c)	-class III furcation defects -3×4 mm ² -inflammation	(a) PDLSC+atocollagen (b) atocollagen (c) empty	3 months 1 month	-Histological: HES, Mallory's trichrome stain -Histomorphometric -Radiological	PDLSC associated with atocollagen significantly improve periodontal and bone formations compared to control groups (b, c)
Kawaguchi H <i>et al.</i> 2004 ⁽²³⁾	-BMSC -P3 -undifferentiated -2×10 ⁶ , 5×10 ⁶ , 1×10 ⁷ , 2×10 ⁷	Atelocollagen	DOG Beagle female, 10–14 kg, 12–20 months old	Unclear	-class III furcation defects -4 mm in depth -no inflammation	(a) BMSC+atocollagen (b) atelocollagen	1 month	-Histological: HES, Azan staining -Histomorphometric	In the BMSC group, necement covered nearly all denuded dentin surface, added to bone and ligament formation (Sharpey's fibers like). But no <i>ad-integrum</i> bone recovery. No root system ankylosis or root resorption
Khorsand A <i>et al.</i> 2013 ⁽⁶¹⁾	-DPSC -P3 -undifferentiated -2×10 ⁷ /default	3-4 Bio-Oss® granules	DOG Mongrel male 1–2 years old, 14–22 kg	10 (a, b)	-intraony defects -3×5×8 mm ³ -inflammation	(a) DPSC+Bio-Oss® (b) Bio-Oss®	2 months	-Histologic: HES -Histomorphometric	The cement generated in the presence of DPSC was thicker and covered a bigger surface compared with the control group. Likewise the formation of ligament was more significant in the test group. However, no noticeable difference in bone formation between the 2 groups
Lang H <i>et al.</i> 1998 ⁽⁸²⁾	-Primary cell cultures from alveolar bone and periodontal ligament -vit C stimulation -2×10 ⁷ /mL	Gelita® +ePTFE membranes	MINIATURE PIG Trol types, 4–8 years old	8 (a, b, c, d, e)	-intraony and class II furcation defects -inflammation	(a) cells+Gelita® (b) Gelita® (c) empty with membrane (d) empty without membrane (e) no treatment	10, 30, 90 days	-Clinical: PI, PD, GR, Sulcus Bing Index -Histological: polyfluorochrome labeling, toluidine blue staining	The study shows that the primary cell cultures from alveolar bone and periodontal ligament leads to formation of new cementum and bone
Li H <i>et al.</i> 2009 ⁽⁸³⁾	-Cryopreserved or No-cryopreserved BMSC -P4 -undifferentiated -5×10 ⁶ /mL	Collagen membrane +ePTFE membranes	DOG Beagle, female, 12–18 kg	9 (a, b) 8 (c)	-fenestration defects -5×5 mm ² -no inflammation	(a) BMSC cryopreserved+ collagen (b) BMSC no cryopreserved+ collagen (c) collagen	2 months	-Histological: HES, Masson's staining -Histomorphometric	BMSC whether cryopreserved or not showed a better periodontal regeneration with bone, cement and ligament neofornation compared with the group with collagen only
Liu Y <i>et al.</i> 2008 ⁽⁸²⁾	-PDLSC -P3 -undifferentiated -2×10 ⁷	HA/β-TCP +gelatin membranes	MINIATURE PIG 12 months old, 30–40 kg	24 (a) 12 (b, c)	-intraony defects -7×3×5 mm ³ -inflammation	(a) PDLSC+HA-β-TCP (b) HA-β-TCP (c) no treatment	3 months	-Clinical: CAL, PI, PD, GR, BOP -Histological: HES, GFP -Radiological: CT	The treatment with PDLSC entailed bone, ligament and cement regeneration with a good anchoring of Sharpey's fibers compared with the other groups
Liu Z <i>et al.</i> 2016 ⁽⁶⁴⁾	-BMSC -undifferentiated	collagen- hydroxyapatite scaffold	DOG Beagles, male, 12 months old 10.5–1.2 kg	6 (a, b, c, d)	-intraony defects -3×5mm ² -no inflammation	(a) BMSC+HA+collagen (b) BMSC+HA+collagen-cross linked (c) empty (d) no treatment	3 dogs: 3 months 3 dogs: 6 months	-Histological: HES, Masson's staining -Radiological: Micro-CT	In group (a, b), newly formed alveolar bone, periodontal ligament and cementum were regenerated without aberrant events. BMSC provided no added value to healing

Table 2 continued

Memicanin D <i>et al.</i> 2014 ⁽³¹⁾	-PDLSC -P3 -undifferentiated -2x10 ⁶	Gelfoam® +Gore-Tex®	SHEEP female	7 (a, b)	-intrabony defects -5 mm in depth -no inflammation	(a) PDLSC+Gelfoam® (b) Gelfoam®	2 months	-Histological: HES, modified tetrachrome -Histomorphometric -Immunohistochemical: OPN, BSP, COL-I, αSMA, BrdU	PDLSC group shows a superior regeneration in bone and collagen fibers (similar to Sharpey's fibers) inserted in neocement
Mrozik KM <i>et al.</i> 2013 ⁽³⁷⁾	-PDLSC -P3 -undifferentiated -1x10 ⁷	Gelfoam® +resorbable barrier membrane	SHEEP Merino ewes, 3-5 years old, 63.5-72.0 kg	7 (a, b) 6 (c)	-dehiscence -10 mm in depth -no inflammation	(a) PDLSC+Gelfoam® (b) Gelfoam® (c) empty	1 month	-Histological: HES, tetrachrome staining -Histomorphometric	Enhanced cementum regeneration following allogeneic PDLSC implantation
Nagahara T <i>et al.</i> 2015 ⁽³⁸⁾	-BMSC -P3 -undifferentiated -2x10 ⁷	β-TCP/ atelocollagen	DOG Beagle, female, 10-14 kg	20 (a, b) 16 (c) 10 (d)	-class III furcation defects -4 mm in depth -inflammation	(a) BMSC+β-TCP+atelocollagen (b) BMSC+atelocollagen (c) β-TCP+atelocollagen (d) atelocollagen	1 and 2 months	-Histological: HES, Azan and TRAP Staining -Immunohistochemical: OPN	The new cementum length in the groups (a, b) was higher at 4 and 8 weeks compared to control groups. And new connective tissue fibers were inserted into the cementum in both groups (a, b). The new bone volume was improved in group (a) but no in group (b)
Nakahara T <i>et al.</i> 2004 ⁽³⁹⁾	-PDLSC -undifferentiated -3x10 ⁵	type I (70-80%) and type III (20-30%) atelocollagen +ePTFE membranes	DOG Beagle, female, 10-12 kg	6 (a, b)	-fenestration defects -6x4 mm ² -no inflammation	(a) PDLSC+atelocollagen (b) empty	1 month	-Histological: HES, Masson's trichrome staining -Histomorphometric	Cement formation was a lot more significant with PDLSC But no difference in bone formation between the groups
Nakajima R <i>et al.</i> 2014 ⁽⁴²⁾	-dental socket-derived stem cells -osteoinductive medium	PGA+β-TCP collagen	DOG Beagle male, 1 year old, 10 kg	6 (a, b) 8 (a, b, c)	-intrabony defects -5x5 mm ² -no inflammation	(a) DSC/PGA+β-TCP (b) PGA+β-TCP	2 months	-Histological: HES, Azan staining	A histologic analysis showed newly formed bone in both groups, whereas newly formed cementum-like tissue and Sharpey's fiber-like tissue were observed in the group (a) only.
Núñez J <i>et al.</i> 2012 ⁽⁴⁰⁾	-CDC or PDLSC -P5-6 -undifferentiated -CDC>75x10 ⁴ ; PDLDC>75x10 ⁴	collagen	DOG Beagle, male, 1 year old, 10 kg	8 (a, b, c)	-intrabony defects -3x4 mm ² -inflammation	(a) CDC+collagen (b) PDLSC+collagen (c) collagen	3 months	-Histological: Toluidine blue staining -Histomorphometric	Higher rates of cement found in test groups as well as a more significant gain in attachment and in conjunctive tissue. PDLSC or CDC failed to stimulate further the bone regeneration
Ozasa M <i>et al.</i> 2014 ⁽⁴⁸⁾	-ASC -P4	fibrin gel	DOG Beagle, female, 50-56 months old 9-11 kg	unknown	-class II furcation defects -4 mm in depth -inflammation	(a) ASC+fibrin gel® (b) fibrin gel	1, 5 months	-Histological: AZAN -Histomorphometric -Radiological: micro-CT	ASC transplanted sites have shown periodontal regeneration, including new alveolar bone, periodontal ligament and cementum formation with vertically inserted fibers

Table 2 continued

Paknejad M <i>et al.</i> 2015 ⁽⁷⁾	-BMSC -P3 -undifferentiated -2x10 ⁷ /default	Bio oss [®]	DOG Mongrel, male, 1-2 years old, 14-22 kg	9 (a, b)	-intrabony defects -4x4 mm ² -inflammation	(a) BMSC+Bio oss [®] (b) Bio oss [®]	2 months	-Histological: HES -Histomorphometric	Formation of new cementum and periodontal ligament were significantly higher in the test group. Whereas bone formation in the test and control groups were no statistically different
Simsek SB <i>et al.</i> 2012 ⁽⁴⁾	-BMSC or Autologous cortical bone undifferentiated -1x10 ⁷ /mL	PRP autologues	DOG Mongrel, 15 kg	6 (a, b, c, d, e)	-class II furcation defects -5x2 mm ² -no inflammation	(a) BMSC+PRP (b) autogenous cortical bone+PRP (c) PRP (d) autogenous cortical bone (e) no treatment	2 months	-Histological: HES -Histomorphometric	The regeneration of cement and alveolar bone was more significant in the groups (a, b, d), even if, in these 3 groups, BMSC showed the highest potential for periodontal regeneration.
Sonoyama W <i>et al.</i> 2006 ⁽⁸⁾	-PDL/C+SCAP -P1-3 -4x10 ⁶	Gelfoam [®] +HA+ β-TCP	MINIATURE PIG male, 4-8 months old, 20-40 kg	6 (a, b)	-alveolar socket -no inflammation	(a) [PDL/C+SCAP/Gelfoam [®]]+HA +β-TCP (b) HA+β-TCP	1 month	-Histological: HES -Immunohistochemical: human mitochondria antibody -Radiological: CT	Periodontal regeneration observed in test groups: formation of a bio-root with a good compressive force
Suard FF <i>et al.</i> 2011 ⁽⁸⁾	-PDLSC -P2-3 -undifferentiated -3x10 ⁶	collagen sponge +absorbable membrane Goretex	DOG Beagle, 10-20 kg, 1.46±0.18 years old	7 (a, b)	-intrabony with class II furcation defects -5x2 mm ² -no inflammation	(a) PDLSC+collagen (b) collagen	3 months	-Histological: HES -Histomorphometric	The results presented a better periodontal regeneration in the group with LAD cells
Suard FF <i>et al.</i> 2012 ⁽⁹⁾	-PDLSC -P2-3 -undifferentiated -3x10 ⁶	Collagen +2 absorbable membranes (GTR)	DOG Beagle, 10-20 kg, 1.46±0.18 years old	7 (a, b, c, d)	-intrabony with class II furcation defects -5x2 mm ² -no inflammation	(a) PDLSC+collagen (b) collagen+GTR (c) GTR (d) empty	3 months	-Histological: HES -Histomorphometric	The group with LAD cells showed a better periodontal regeneration with a more significant bone and cement width
Tobita M <i>et al.</i> 2013 ⁽⁸⁾	-ASC -P2 -undifferentiated -1.5x10 ⁷ /mL	PRP gel	DOG Beagle, 9 or 10 months old, 8-10 kg	8 (a, b, c)	-intrabony with with class III furcation defects -5 mm in depth -no inflammation	(a) ASC+PRP gel (b) PRP gel (c) empty	2 months	-Histological: HES, Azan or elastic van Gieson staining -Histomorphometric -Immunohistochemical: Osteocalcin -Radiological: X-ray	Better bone, cement and ligament-like regeneration in test group, the group without treatment showed gingival invasion
Tsumanuma Y <i>et al.</i> 2011 ⁽³⁾	-PDL/C or BMSC or Periosteal cells -P3 -osteonductive medium -cell sheet	PGAβ-TCP/type I collagen	DOG Beagle, male, 10 kg	4 (a, b, c, d)	-intrabony defects -5x5 mm ² -no inflammation	(a) PDL/C+PGA+ β-TCP/type I collagen (b) BMSC+PGA+β-TCP/type I collagen (c) Periosteal cells+PGA+β-TCP/ type I collagen (d) PGA+β-TCP/type I collagen	1 month	-Histological: HES, Azan staining -Histomorphometric -Immunohistochemical: neurofilament protein	PDL cells group shows a more significant cement thickness. Moreover, presence of correctly orientated collagen fibers, while they are slanted in the group (b) and parallel in the group (c). However, no difference in bone formation or in long junctional epithelium

Table 2 continued

Tsumanuma Y <i>et al.</i> 2016 ⁽⁸⁾	-PDLSC -P5 -osteoinductive medium -cell sheet	PGA/ β -TCP/collagen + absorbable membrane (GTR)	DOG Beagle	8 (a, b, c)	-intrabony defects -5 \times 5 mm ² -no inflammation	(a) PDLSC autologous/PGA+ β -TCP+collagen (b) PDLSC allogenic/PGA+ β -TCP+collagen (c) β -TCP+collagen	-Histological: Azan staining -Enzyme-linked immunosorbent assay: CRP, IL-10, IFN- γ , CD30 -Histomorphometric -Radiological: micro-CT	In the group (b), dense collagen fibers were observed, which attached perpendicularly to the cementum-like tissue. In the groups (a, c), collagen fibers were oriented obliquely or parallel to the root surface. There were no differences between the autologous or allogenic groups in the histomorphometric analyses
Wei N <i>et al.</i> 2010 ⁽⁹⁾	-BMSC -P3 -2 \times 10 ⁷ /defect	Alginate hydrogel	DOG Beagle male, 6–10 months old, 5–10 kg	4 (a, b)	-class III furcation defects -5 mm in depth -no inflammation	(a) BMSC+hydrogel (b) empty	-Histomorphometric: HES or Masson trichrome -Immunohistochemical: BrdU, α -SMA, osteocalcin	The transplanted BMSC migrated into the periodontal ligament, alveolar bone, cementum and blood vessels. BMSC transplantation has the potential to regenerate periodontal tissue.
Yang JR <i>et al.</i> 2013 ⁽⁷⁾	-Embryonic stem cells -P43-45 -GFP-label -1 \times 10 ⁹ /defects	Collagen	MINIATURE PIG female 5 months old 25–30 kg	6 (a, b)	-class II furcation defects -4 \times 5 \times 3 mm ³ -inflammation	(a) embryonic stem cells MSC+collagen (b) collagen	-Clinical: PD, CAL -Histological: HES -Immunohistochemical: GFP, periostin; aspirin, cementum attachment protein, osteopontin; osteocalcin, RUNX2	Embryonic cells to improve the regeneration of periodontal furcation defects is feasible
Yang KC <i>et al.</i> 2016 ⁽²⁾	-DPSC: P3-P5 -epithelial cells: P2-P3/1.76-3.1 \times 10 ⁶ -odontoblastic-induced DPSC: 20.3-33.2 \times 10 ⁶ -osteoblastic-induced DPSC: 19.2-27.8 \times 10 ⁶	gelatin chondroitin-hyaluronan	MINIATURE PIG 7 males, 10 females, 5–7 weeks old	8 (a) 3 (b, c, d)	-alveolar sockets -no inflammation	(a) cells layers+scaffold (b) scaffold (c) empty (d) without intervention	-Histological: HES -Immunohistochemical: DMP-1, OPN, COL-1, CK14, VEGF -Radiological: X-ray	This study demonstrated that a bioengineered cell/scaffold could achieve tooth regeneration. The regenerated tooth had crown, root, and pulp structures with enamel-like tissues, dentin, cementum, odontoblast-like cells, and periodontal tissues.
Zang S <i>et al.</i> 2016 ⁽³⁾	-BMSC -P3-5 -undifferentiated	-chitosan -anorganic bovine bone	DOG Beagles, 15 months old, 10–15 kg	6 (a, b, c, d, e, f)	-intrabony defects -4 \times 7 mm ² -no inflammation	(a) BMSC+chitosan (b) BMSC+chitosan+anorganic bovine bone (c) chitosan+anorganic bovine bone (d) chitosan (e) anorganic bovine bone (f) empty	-Histological: HES, Masson's trichrome staining -Histomorphometric -Immunohistochemical: osteocalcin -Radiological: micro-CT	BMSC associated with chitosan/anorganic bovine bone scaffolds could promote periodontal repair. The quantity of the newly formed bone and cementum in the groups (b, e) was significantly higher compared with the other groups.

Table 2 continued

Zhu B <i>et al.</i> 2017 ⁽²⁾	-PDLSC or BMSC (iliac- or jaw-derived) -P2-4 -osteoinductive medium	treated dentine matrix (TDM)+ceramic bone (CA)	MINIATURE PIG 2 years old	10 (a) 8 (b)	-intrabony defects -5.2x5 mm ² -no inflammation	(a) jBMSC+PDLSC+TDM+CA (b) iBMSC+PDLSC+TDM+CA	3 months	-Histological: HES, Masson's trichrome -Immunohistochemical: Col 1	Both construct implantation, jBMSC or iBMSC showed PDL-like tissue regeneration. However, the implantation of jBMSC seems to be more appropriate to form parallel collagen fibers and bone tissue
---	---	--	---------------------------	--------------	--	---	----------	--	---

HA, hydroxyapatite; TCP, tricalcium phosphate; PGA, polyglycolic acid; ePTFE, e-polytetrafluoroethylene; PRP, platelet-rich plasma; DPSC, dental pulp stem cells; PDLSC, periodontal ligament stem cells; PDLC, periodontal ligament cells; DFSC, dental follicle stem cells; CDC, cementum derived cells; GMSC, gingival margin stem cells; SHED, stem cells from human exfoliated deciduous teeth; BMSC, bone marrow stem cells; ASC, adipose stem cells; MSC, mesenchymal stem cells; SCAP, stem cells from apical papilla; CAL, clinical attachment level; PI, plaque index; PD, probing depth; GR, gingival recession; BOP, bleeding on probing; HES, hematoxylin eosin stain; ECM, extracellular matrix; OPN, osteopontin; BSP, bone sialoprotein; Col, collagen; α SMA, alpha smooth muscle actin; GFP, green fluorescent protein; TRAP, tartrate-resistant acid phosphatase; CRP, serum c-reactive protein; IL-10, interleukin-10; INF-c, interferon-c; CD, cluster of differentiation; VEGF, vascular endothelial growth factor; DMP-1, dentin matrix protein-1; CT, computed tomography; SEM, scanning electron microscopy.

Table 3 Comparative table of human studies in periodontal regeneration combining MSC and biomaterials

Reference	Cell type/ passage number/ differentiation/ number per defect	Biomaterial +/- membrane	Animal model/ species/sex/age/ weight	Number of defects per group	Defect type/size/ induced inflammation	Treatment groups	Observation period	Qualification of newly formed tissues	Results
Aimetti M <i>et al.</i> 2014 ⁽¹⁾	-DPSC -P0 -undifferentiated	Collagen sponge (type III)	HUMAN male 56 years old	1	-intrabony defects -inflammation	DPSC+collagen sponge scaffold	6 and 12 months	-Clinical: CAL, PI, PD, GR -Radiological: dental X-ray	At the 12 months examination, the CAL gain amounted to 6 mm with a residual probing pocket depth of 3 mm. No apical displacement of the gingival margin was observed
Chen FM <i>et al.</i> 2016 ⁽⁶⁾	-PDLSC -undifferentiated -cells sheets	Bio oss [®] +Bio-Gide [®]	HUMAN Male, female 26.05±4.44 -30.04±7.90 years old	20 (a) 21 (b)	-intrabony defects ≥3mm in depth -inflammation	(a) PDLSC+Bio-oss [®] (b) Bio-oss [®]	3, 6 and 12 months	-Clinical: CAL, PD, GR -Radiological: dental X-ray	Significant difference between the experimental and the control groups was not observed
Dhote R <i>et al.</i> 2015 ⁽¹⁾	-allogenic human umbilical cord -P0 -rh-PDGF-BB stimulation -1x10 ⁹ /default	β -TCP	HUMAN 8 males and 6 females, 20-43 years old	12	-intrabony defects ≥5 mm in depth -inflammation	(a) allogenic human umbilical cord+ β -TCP (b) open flap debridement	6 months	-Clinical: CAL, PI, PD, GR, BOP -Radiological: dental X-ray	Stimulated cells implantation resulted in a significant added benefit in terms of CAL gains, PD reductions greater radiographic defect fill and improvement in linear bone growth
Feng F <i>et al.</i> 2010 ⁽⁸⁾	-PDLC -P1 -undifferentiated	calcium carbonate	HUMAN male 25 and 42 years old	Patient n ^o 1 12 teeth Patient n ^o 2 3 teeth Patient n ^o 3 1 tooth	-intrabony defects >6 mm in depth -inflammation	PDLC+calcium carbonate	3-72 months	-Clinical: CAL, PD, GR, BOP, PI -Radiological: dental X-ray	PDLP implantation improve periodontal tissue regain, specifically marked by a significant decreased in gingival recession and increased attachment gain

Table 3 continued

Hernandez-Monjaraz B <i>et al.</i> 2018 ⁽²⁾	-allogenic DPSC -P3 -undifferentiated -5x10 ⁶ /default	Collagen sponge +effon-coated titanium membrane	HUMAN male 61 years old	1	-intrabony defects -inflammation	Allogenic DPSC+collagen sponge	3, 6 months	-Clinical: PD, mobility -Radiological: Cone beam volumetric tomography; bone mineral density	The gingiva showed no signs of inflammation, and depth of the periodontal pocket and dental mobility both decreased. Densitometry assays revealed an increase in bone mineral density in the walls of the defect
Ki V <i>et al.</i> 2017 ⁽³⁾	-PDLSC -P0 -undifferentiated	Abgel [®] CTM; gelatin sponge	HUMAN male 27 years old	1	-intrabony defects -9 mm in depth -inflammation	PDLSC+Abgel [®] CTM	24 months	-Clinical: CAL, PD, GR, relative attachment -Radiological: dental X-ray	PDLSC implantation has resulted in successful clinical and radiographic parameters: CAL decreased PD and satisfactory defect fill of intrabony defects
Li Y <i>et al.</i> 2016 ⁽³⁾	-DPSC -P3 -undifferentiated	β-TCP	HUMAN female 30 and 38 years old	Patient n°1 1 tooth Patient n°2 1 tooth	-combined periodontal- endodontic lesions -5-6 mm in depth -inflammation	DPSC+β-TCP	1, 3, and 9 months	-Clinical: CAL, PI, PD, GR, BOP, furcation lesion, mobility -Radiological: dental X-ray	DPSC graft dramatically improved the clinical symptoms of periodontitis.
Okuda K <i>et al.</i> 2009 ⁽⁷⁾	-Periosteal cells -P0 -undifferentiated	HA+PRP	HUMAN female 53, 63 and 71 years old	3	-Intrabony defects -inflammation	Periosteal cells+HA+PRP	6 months	-Clinical: PD, CAL -Radiological: dental X-ray	On average, results show a reduction of pockets of 6mm, a gain in attachment of 4.3mm at 6 months
Rosen PS <i>et al.</i> 2015 ⁽⁸⁾	-MSCs allografts (Osteocel, NuVasive) -undifferentiated	demineralized freeze-dried and freeze-dried bone allografts +BioXclude [®]	HUMAN Male and female 39-70 years old	6	-class III and IV furcation defects -inflammation	MSC+BioXclude [®]	6, 9, 24 or 30 months	-Clinical: furcation lesion -Radiological: dental X-ray	4 furcations treated were completely closed 1 furcation was reduced to Class I on their facial aspect while the lingual aspect was completely closed 1 remained as a Class III furcation
Yamada Y <i>et al.</i> 2005 ⁽²¹⁾	-BMSC -osteoinductive medium -1x10 ⁷ /mL	PRP gel	HUMAN female, 54 years old	1	-intrabony defects -inflammation	BMSC+PRP gel	12 months	-Clinical: CAL, PD -Radiological: dental X-ray	A reduction of 4mm when probing, a clinical attachment gain of 4mm with no more bleeding or tooth mobility
Yamamiya K <i>et al.</i> 2008 ⁽⁶⁾	-periosteal cells -P0 -undifferentiated	HA+PRP	HUMAN 14 females and 1 male, 55.8-9.1 years old	15 (a, b)	-intrabony defects -6 mm in depth -inflammation	(a) periosteal cells+PRP+HA (b) HA+PRP	12 months	-Clinical: CAL, PD, GR, BOP, gingival inflammation -Radiological: dental X-ray	the test group presented better results with enhancement in CAL gain and bone density even if the control group obtained satisfying results

TCP, tricalcium phosphate; PRP, platelet-rich plasma; DPSC, dental pulp stem cells; PDLSC, periodontal ligament stem cells; BMSC, bone marrow stem cells; MSC, mesenchymal stem cells; CAL, clinical attachment level; PI, plaque index; PD, probing depth; GR, gingival recession; BOP, bleeding on probing.

most of the articles used intrabony defects (26 studies). It seemed relevant to underline that although periodontitis is an inflammatory disease, the defects models employed in preclinical studies were largely not inflammatory (in 26/39 studies, defects were surgically created). Then, the studies were categorized according to the type of MSC or biomaterial used. The periodontal ligament stem cells (PDLSC) were by far the most studied with 16 publications, whereas bone marrow stem cells (BMSC) were used in only 12 studies. As for scaffolds, collagen is used in most of the studies (10 studies). The general analysis of clinical studies has shown that studies mostly based on animals mainly used a combination of PDLSC and collagen.

Risk of bias within studies

Figure 2 shows the overall results of the risk of bias assessment. Subgroup analyses was performed to assess the quality of preclinical studies (Fig. 2a), non-randomized human trials (Fig. 2b) and randomized human trials (Fig. 2c), using an adapted methodology. Firstly, the risk of bias assessment for preclinical animal studies was investigated. Establishing that only 44 and 72% of the studies do not mention randomization or blinding respectively, our data show a high score of unclear risk of bias for the selection, performance and detection items (47, 95 and 95%, respectively). Interestingly, the data outcomes were adequately addressed for 87% of the studies. Furthermore, the majority of the studies were free from selective outcome reporting (67%). Thereafter, non-randomized human trials were investigated for

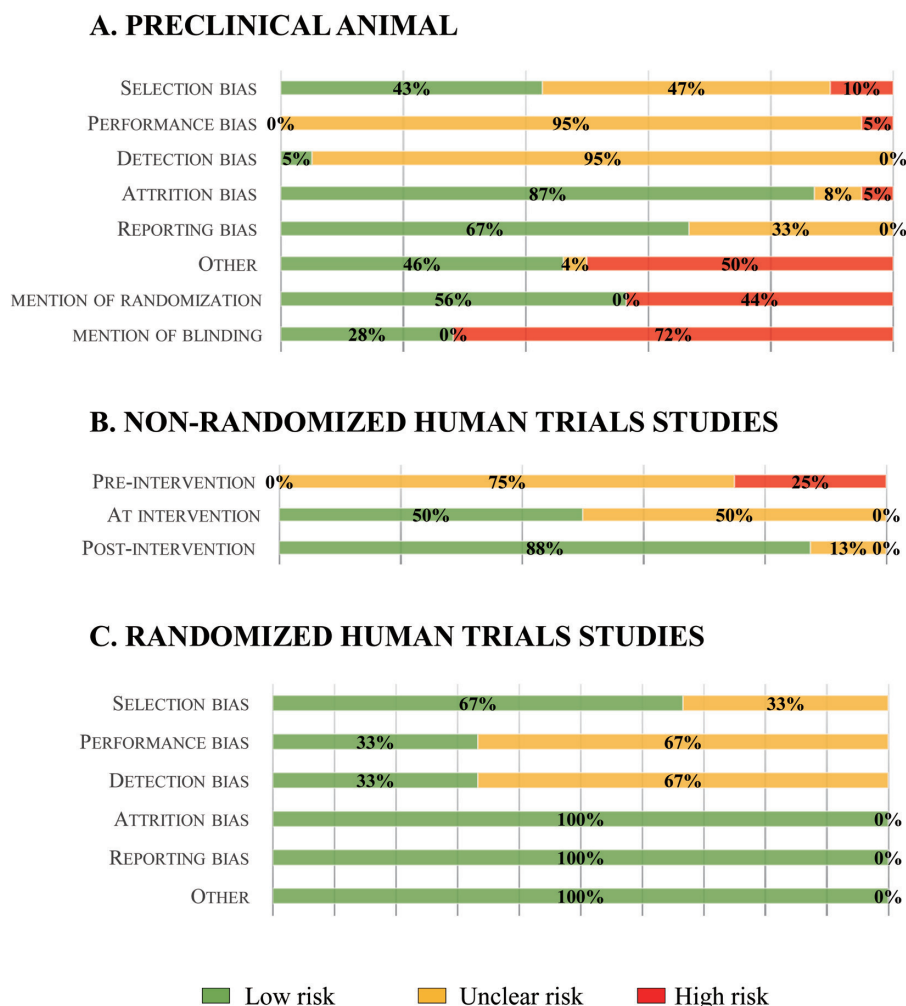


Fig. 2 Risk of bias assessment of included studies.

A, Risk of bias graph for animal studies, using the SYRCLE's tool, averaged per item.; B, Risk of bias graph for non-randomized human trials, using the ROBINS-I tool, averaged per item.; C, Risk of bias graph for randomized human trials, using the Cochrane Collaboration's tool, averaged per item. The green, yellow and red colors depict the percentages of studies with low, unclear or high risk of bias of the total number of assessed studies.

the quality of the methodology. Results revealed that 75 and 50% of the studies were marked for unclear risk of bias for pre-intervention and at-intervention items respectively. On the opposite, post-intervention items display a low risk of bias (88%). As expected for randomized human trials, our results did not show a high risk of bias. However, regarding selection bias, 33% of the included studies were marked for an unclear risk of bias. In addition, only 33% of the articles were considered to have a low risk of bias for its performance and detection. Finally, all studies were considered to have a low risk of bias for their attrition and reporting.

Synthesis of results

For each study, the relevant results are summarized for studies of preclinical animal models (Table 2) and for Human studies (Table 3). Overall analysis showed the association of MSC and biomaterial enhancement of periodontal regeneration for the majority of the studies.

DISCUSSION

The significant impact of periodontal disease on general health and the quality of life necessitates the need to regenerate the damaged tissue more effectively¹⁹. Consequently, the regeneration of bone, cementum and an effective periodontal ligament remains a major challenge. Periodontal regenerative medicine is considered as a promising treatment modality for future therapy. Along this line, the present systematic review intended to investigate the controversial results raised from the scientific literature on the efficacy of the periodontal regeneration strategies, using the association of MSC and biomaterials in pre-clinical animal models and humans.

Literature searches retrieved 50 studies. After a careful analysis, our results revealed that it was not possible to perform direct head-to-head comparisons of these studies as a result of variations between studies, in terms of the healing time after cell transplantation, the biomaterials applied, the defect type and size, the used cell types and passage number, and the number of cells per defect. Not surprisingly, no meta-analysis of the data could be carried out.

Indeed, the study of the risk of bias has revealed that poor reporting of animal studies in scientific publications is of serious concern. Preclinical animal studies and case reports are, in general, analyzed with less methodological rigour than trials. Key measures to avoid bias such as, randomization and blinding, were infrequently reported. This may lead to an overestimation of the effects of cells on periodontal regeneration compared to the group control system. This seriously hampers drawing reliable conclusions from animal studies. Despite these limitations, the combined analysis of the included studies still generated extra and valuable information that could not be derived from the individual analysis of studies.

Periodontal regenerative medicine is a multidisciplinary field combining biology and

engineering. In this context, the present discussion focuses first on MSC and second on biomaterials used for periodontal regeneration.

Stem cell biology has become an important field in regenerative medicine and tissue engineering therapy since the discovery and characterization of MSC. In particular, stem cells have great versatility at the level of tissue regeneration for many different characteristics and can modulate chronic inflammation, a central feature in periodontitis. Given the characteristics of these cells, they are considered a potentially useful tool for the efficient regeneration of periodontal tissues²⁰. Thus, one of the most important issues for clinical application of regenerative medicine approaches is the type of cell used.

Bone marrow has been the main source of MSC used for regenerative medicine. For several years now, BMSC has been the object of a lot of periodontal regeneration research, more often on animal models. To date, there exists only one case reported on a human suffering from chronic periodontitis. The authors concluded that the combination of BMSC and Platelet-rich Plasm (PRP) should entail a radiological and clinical improvement in terms of pocket depth, attachment gain, loss of bleeding on probing, and tooth mobility²¹. In addition, a randomized trial, focusing on the safety and the efficacy of regenerative treatment of infrabony defects using autologous BMSC, combined with collagen scaffolds enriched with fibrin glue is ongoing (NIH clinical trial registration number: NCT02449005). The combination of BMSC and PRP has also been a success on animal models in 3 different studies, each independently conducted by Simsek *et al.*, Hasegawa *et al.*, and Kawaguchi *et al.*²²⁻²⁴. Even though the periodontal regeneration was nearly complete in the study by Simsek *et al.*, both Hasegawa and Kawaguchi unfortunately concluded with incomplete tissue regeneration and particularly, that of the alveolar bone. With average positive results, the BMSC seems to enable an improvement in bone, periodontal ligament and cement regeneration^{25,26}. However, bone marrow suffers certain limitations that are related to its painful harvest and to the limited number of collectable cells. In light of these limitations, authors investigate other sources of adult tissues in order to collect stem cells. Within the orofacial area, several sources of MSC have attracted scientific interest, given their similarity to BMSC, their immunoregulatory capacity, and their minimally invasive harvest procedure²⁷.

Periodontal (PDL) derived cells

Thirty years ago, the concept that stem cells may reside in the periodontal tissues was put forward by Melcher²⁸. Not until 2004, PDLSC were first isolated and characterized as stem cells²⁹. Over the past several years, the number of animal studies on PDL-derived cells have been increasing. Not surprisingly, in the present systematic review, the majority, *i.e.* 40% of the 50 studies were dedicated to periodontal ligament-derived cells. Feng *et al.* were the first to transplant progenitor cells of the periodontal ligament combined

with calcium carbonate, into periodontal defects of 3 patients suffering from chronic periodontitis. The results concluded in a gain of clinical attachment with a decrease in pocket depth, a bone tissue regeneration and finally, a recession improvement over 72 months³⁰. Menicanin *et al.* have combined autologous PDLSC to a gelatin scaffold on sheep models. The results in the test groups were very encouraging due to a superior regeneration with the development of cement, bone and ligament structures³¹. In addition, Liu *et al.* and Ding *et al.* independently obtained the same types of results, with a near complete regeneration of the periodontal tissues after implanting a combination of autologous PDLSC to HA/ β TCP in intrabony defects on porcine models over a period of 12 weeks^{32,33}. Moreover, in order to simplify the clinical protocol set for the dental surgeon in his everyday practice, some studies use periodontal ligament cells without isolating the stem cells beforehand. Combined with either a collagen scaffold, calcium carbonate, PGA, HA, β -TCP or hyaluronic acid, different authors agree that their cells shown a significant improvement in terms of the height and thickness of the bone, of cement and the periodontal ligament regeneration^{30,34-39}. A systematic review by Bright *et al.* on PDL-derived cells for periodontal regeneration reported that 12 out of the 17 included studies relate a statistically significant positive effect in periodontal regeneration¹⁴. A recent randomized clinical trial on 20 patients suffering from chronic periodontitis revealed that the implantation of PDLSC associated with Bio-Oss[®] over a period of 1 year significantly improved the alveolar bone height and the clinical parameters over time, but no significant differences between the implantation of PDLSC/Bio-Oss[®] and the implantation of only Bio-Oss[®] were found⁴⁰. In conclusion, even if the results are contradictory, the majority of the studies reveal a positive and promising effect on the regenerative potential of PDL-derived cells.

The use of dental pulp stem cells (DPSC) has shown some potential towards regenerating the periodontium. Interestingly, 3 independent case reports described an improvement of the clinical parameters of periodontitis by the implantation of DPSC with collagen scaffold^{41,42} or β -TCP⁴³. Although the results of several pre-clinical animal studies and case reports were promising, human randomized trials are required to evaluate the efficacy of those procedures in regenerating true periodontal defects.

The others stem cells used

The efficiency of cellular therapy using autologous gingival fibroblasts has been evaluated by Fawzy *et al.* when they were combined with gingival margin stem cells (GMSC) to Bio-Oss[®] or IL-1ra-releasing HA-ECM scaffold on a miniature pig subject. Whatever the biomaterial used, the team of researchers concluded with a reduction of pocket depth, a gain of clinical attachment and of bone density^{44,45}. In 2008, Yamamiya *et al.* conducted a study on 30 patients suffering from chronic periodontitis, where they combined periosteal cells with

PRP and HA over a period of 1 year⁴⁶. The results were positive from a clinical and a radiological point of view. Okuda *et al.* also studied the same combination in a dog model and reached the same conclusion⁴⁷. Adipose stem cells (ASC) has always seemed very appealing to researchers in periodontal regeneration. Tobita *et al.* and Ozasa *et al.* implanted ACS into periodontal defects on canine models with PRP⁴⁸ or fibrin gel⁴⁹, respectively. The morphometric, histologic, immuno-histologic and radiological analysis confirmed a superior bone, cement and ligament formation in the cell group.

Interestingly, a previous systematic review and meta-analysis, which included a large number of studies using only animal models (sheep, dog, minipigs, rats, mice), provided evidence for the enhancement of periodontal regeneration by the implantation of either PDL-derived cells or BMSC^{50,51}.

To have a chance of achieving periodontal regeneration, the cells need to be delivered and stabilized on the defect by a biomaterial. The concept of a scaffold is based on a biomimetic strategy, capable of incorporating and releasing molecules, and permitting cell to cell and cell to matrix interactions. The choice of the releasing method will depend on the type of cell population released and on the type of defect; specifically, the number of alveolar bone walls involved. When defects are larger, outcomes may improve when cells are associated with bone substitute or cell sheets attached with PGA are transplanted onto the tooth root surface, after which the bone defects are filled with bone substitute^{36,38,39,52,53}. On the opposite, gel scaffold might be used when lesions are retentive. As shown in this systematic review, clinical studies mainly use a scaffold made of collagen. Collagen materials may be particularly useful due to their biocompatibility, resorbability, cell occlusiveness and their capability of promoting wound healing. Collagen offer a safe scaffold material because of occurring naturally and being involved in numerous physiological processes. Although collagen can be constituted into various forms such as fibers, sheets, hydrogels, and sponges¹¹. Most biomaterials have some drawbacks such as follows: unpredictable cell-biomaterial interactions, non-homogeneous biodegradation, immune reaction, and low efficiency cell seeding. Injectable scaffolds, easily applied without invasive surgery, can improve cell retention, distribution and more importantly activate *in situ* cell proliferation and differentiation. Hydrogels are not only biocompatible with a high resorption level but they show a better cell retention than other injectable biomaterials, as confirmed by a number of studies⁵⁴. They can be prepared from alginate, chitosan, collagen or cellulose, seeded with cells and then gelation can be initiated by changing the temperature, pH, cross-linking or radical polymerization. The goal is to obtain a high cell retention followed by a good integration capacity and a high level of surviving cells with reduced side effects and minimal stress for the patient¹².

The present systematic review achieves, for the first time, a comprehensive analysis of the scientific literature concerning the periodontal regenerative

medicine. To date, current data indicate that MSC associated with suitable scaffolds may provide beneficial effects on periodontal regeneration in preclinical animal models and humans. In particular interest, the human studies suggest that there are no adverse effects of such interventions^{40,42}.

Although clinical trials are promising, future animal studies are still needed to determine the suitable association of MSC and biomaterial for periodontal regeneration and to characterize the type of cementum, and the organization of the periodontal ligament fiber that is regenerated. Furthermore, these studies should also compare periodontal regenerative medicine with the gold standard therapies used to repair periodontium.

CONCLUSION

Several approaches using MSC for regenerating damaged periodontium are under study with varying degrees of clinical applications. Given the heterogeneity of the studies concerning the periodontal regenerative medicine, narrative reviews are insufficient. A systematic approach appears essential to provide guidance to support future studies and should provide information that can be generalized. Our results indicate that MSC may provide beneficial effects on periodontal regeneration. The present systematic review supports crucial information for the implementation of regenerative medicine strategies in clinical practice in the future.

ACKNOWLEDGMENTS

The authors also gratefully acknowledge Paronantes association.

CONFLICTS OF INTEREST

This research did not receive any specific grant from funding agencies in the public, commercial, or not-for-profit sectors.

REFERENCES

- Schroeder HE, Listgarten MA. The gingival tissues: the architecture of periodontal protection. *Periodontol* 2000 1997; 13: 91-120.
- Socransky SS, Haffajee AD, Dzink JL. Relationship of subgingival microbial complexes to clinical features at the sampled sites. *J Clin Periodontol* 1988; 15: 440-444.
- Albandar JM. Epidemiology and risk factors of periodontal diseases. *Dent Clin North Am* 2005; 49: 517-532.
- Eke PI, Dye BA, Wei L, Thornton-Evans GO, Genco RJ. Prevalence of periodontitis in adults in the united states: 2009 and 2010. *J Dent Res* 2012; 91: 914-920.
- Pihlstrom BL, Michalowicz BS, Johnson NW. Periodontal diseases. *Lancet* 2005; 366: 1809-1820.
- Needleman I, Giedrys-Leeper E, Tucker R, Worthington H. Guided tissue regeneration for periodontal infra-bony defects. In: *The Cochrane Database of Systematic Reviews*. 2001.
- Polimeni G, Xiropaidis AV, Wikesjö UME. Biology and principles of periodontal wound healing/regeneration. *Periodontol* 2000. 2006; 41: 30-47.
- Bartold PM, Gronthos S, Ivanovski S, Fisher A, Huttmacher DW. Tissue engineered periodontal products. *J Periodontol Res* 2016; 51: 1-15.
- Needleman I, Hv W, Tucker R. Guided tissue regeneration for periodontal infra-bony defects (Review). *Cochrane Database Syst Rev* 2006; 19: 1-35.
- Hynes K, Menicanin D, Gronthos S, Bartold PM. Clinical utility of stem cells for periodontal regeneration. *Periodontol* 2000 2012; 59: 203-227.
- Chen FM, Jin Y. Periodontal tissue engineering and regeneration: current approaches and expanding opportunities. *Tissue Eng Part B Rev* 2010; 16: 219-255.
- Bartold PM, G Mcculloch CA, Sampath Narayanan A, Pitaru S. Tissue engineering: a new paradigm for periodontal regeneration based on molecular and cell biology. *Periodontol* 2000; 24: 253-269.
- Monsarrat P, Vergnes JN, Nabet C, Sixou M, Snead ML, Planat-Bénard V, *et al*. Concise review: mesenchymal stromal cells used for periodontal regeneration: A systematic review. *Stem Cells Transl Med* 2014; 3: 768-774.
- Bright R, Hynes K, Gronthos S, Bartold PM. Periodontal ligament-derived cells for periodontal regeneration in animal models: A systematic review. *J Periodontol Res* 2015; 50: 160-172.
- Liberati A, Altman DG, Tetzlaff J, Mulrow C, Gøtzsche PC, Ioannidis JPA, *et al*. The PRISMA statement for reporting systematic reviews and meta-analyses of studies that evaluate health care interventions: Explanation and elaboration. *PLoS Med* 2009; 6: e1000100.
- Hooijmans CR, Rovers MM, Vries RBM De, Leenaars M, Ritskes-hoitinga M, Langendam MW. SYRCLE's risk of bias tool for animal studies. *BMC Med Res Methodol* 2014; 14: 1-9.
- Sterne J, Hernán M, Reeves B, Savović J, Berkman N, Viswanathan M, *et al*. Risk of bias in non-randomized studies of interventions (ROBINS-I): detailed guidance. *Br Med J* 2016; 355: i4919.
- Higgins JPT, Altman DG, Gøtzsche PC, Jüni P, Moher D, Oxman AD, *et al*. The cochrane collaboration's tool for assessing risk of bias in randomised trials. *Br Med J* 2011; 343: 1-9.
- Williams RC, Barnett AH, Claffey N, Davis M, Gadsby R, Kellett M, *et al*. The potential impact of periodontal disease on general health: a consensus view. *Curr Med Res Opin* 2008; 24: 1635-1643.
- Hernández-Monjaraz B, Santiago-Osorio E, Monroy-García A, Ledesma-Martínez E, Mendoza-Núñez VM. Mesenchymal stem cells of dental origin for inducing tissue regeneration in periodontitis: A mini-review. *Int J Mol Sci* 2018; 19: pii: E944.
- Yamada Y, Ueda M, Hibi H, Baba S. A novel approach to periodontal tissue regeneration with mesenchymal stem cells and platelet-rich plasma using tissue engineering technology: a clinical case report. *Int J Periodontics Restorative Dent* 2005; 26: 363-369.
- Hasegawa N, Kawaguchi H, Hirachi A, Takeda K, Mizuno N, Nishimura M, *et al*. Behavior of transplanted bone marrow-derived mesenchymal stem cells in periodontal defects. *J Periodontol* 2006; 77: 1003-1007.
- Kawaguchi H, Hirachi A, Hasegawa N, Iwata T, Hamaguchi H, Shiba H, *et al*. Enhancement of periodontal tissue regeneration by transplantation of bone marrow mesenchymal stem cells. *J Periodontol* 2004; 75: 1281-1287.
- Simsek SB, Keles GC, Baris S, Cetinkaya BO. Comparison of mesenchymal stem cells and autogenous cortical bone graft in the treatment of class II furcation defects in dogs. *Clin Oral Investig* 2012; 16: 251-258.
- Zhu B, Liu W, Zhang H, Zhao X, Duan Y, Li D, *et al*. Tissue-specific composite cell aggregates drive periodontium

- tissue regeneration by reconstructing a regenerative microenvironment. *J Tissue Eng Regen Med* 2017; 11: 1792-1805.
- 26) Nagahara T, Yoshimatsu S, Shiba H, Kawaguchi H, Takeda K, Iwata T, *et al.* Introduction of a mixture of β -tricalcium phosphate into a complex of bone marrow mesenchymal stem cells and type I collagen can augment the volume of alveolar bone without impairing cementum regeneration. *J Periodontol* 2015; 86: 456-464.
 - 27) Chalisserry EP, Nam SY, Park SH, Anil S. Therapeutic potential of dental stem cells. *J Tissue Eng* 2017; 8: 1-17.
 - 28) Melcher AH. Cells of periodontium: Their role in the healing of wounds. *Ann R Coll Surg Engl* 1985; 67: 130-131.
 - 29) Seo BM, Miura M, Gronthos S, Mark Bartold P, Batouli S, Brahimi J, *et al.* Investigation of multipotent postnatal stem cells from human periodontal ligament. *Lancet* 2004; 364: 149-155.
 - 30) Feng F, Akiyama K, Liu Y, Yamaza T, Wang TM, Chen JH, *et al.* Utility of PDL progenitors for in vivo tissue regeneration: A report of 3 cases. *Oral Dis* 2010; 16: 20-28.
 - 31) Menicanin D, Mrozik KM, Wada N, Marino V, Shi S, Bartold PM, *et al.* Periodontal-ligament-derived stem cells exhibit the capacity for long-term survival, self-renewal, and regeneration of multiple tissue types in vivo. *Stem Cells Dev* 2014; 23: 1001-1011.
 - 32) Liu Y, Zheng Y, Ding G, Fang D, Zhang C, Bartold PM, *et al.* Periodontal ligament stem cell-mediated treatment for periodontitis in miniature swine. *Stem Cells* 2008; 26: 1065-1073.
 - 33) Ding G, Liu Y, Wang W, Wei F, Liu D, Fan Z, *et al.* Allogeneic periodontal ligament stem cell therapy for periodontitis in swine. *Stem Cells* 2010; 28: 1829-1838.
 - 34) Akizuki T, Oda S, Komaki M, Tsuchioka H, Kawakatsu N, Kikuchi A, *et al.* Application of periodontal ligament cell sheet for periodontal regeneration: A pilot study in beagle dogs. *J Periodontol Res* 2005; 40: 245-251.
 - 35) Inukai T, Katagiri W, Yoshimi R, Osugi M, Kawai T, Hibi H, *et al.* Novel application of stem cell-derived factors for periodontal regeneration. *Biochem Biophys Res Commun* 2013; 430: 763-768.
 - 36) Iwata T, Yamato M, Tsuchioka H, Takagi R, Mukobata S, Washio K, *et al.* Periodontal regeneration with multi-layered periodontal ligament-derived cell sheets in a canine model. *Biomaterials* 2009; 30: 2716-2723.
 - 37) Mrozik KM, Wada N, Marino V, Richter W, Shi S, Wheeler DL, *et al.* Regeneration of periodontal tissues using allogeneic periodontal ligament stem cells in an ovine model. *Regen Med* 2013; 8: 711-723.
 - 38) Sonoyama W, Liu Y, Fang D, Yamaza T, Seo BM, Zhang C, *et al.* Mesenchymal stem cell-mediated functional tooth regeneration in Swine. *PLoS One* 2006; 1: 1-8.
 - 39) Tsumanuma Y, Iwata T, Kinoshita A, Washio K, Yoshida T, Yamada A, *et al.* Allogeneic transplantation of periodontal ligament-derived multipotent mesenchymal stromal cell sheets in canine critical-size supra-alveolar periodontal defect model. *Biores Open Access* 2016; 5: 22-36.
 - 40) Chen FM, Gao LN, Tian BM, Zhang XY, Zhang YJ, Dong GY, *et al.* Treatment of periodontal intrabony defects using autologous periodontal ligament stem cells: a randomized clinical trial. *Stem Cell Res Ther* 2016; 7: 33.
 - 41) Aimetti M, Ferrarotti F, Cricenti L, Mariani GM, Romano F. Autologous dental pulp stem cells in periodontal regeneration: a case report. *Int J Periodontics Restorative Dent* 2014; 34 (Suppl): 27-33.
 - 42) Hernández-Monjaraz B, Santiago-Osorio E, Ledesma-Martínez E, Alcauter-Zavala A, Mendoza-Núñez VM. Retrieval of a periodontally compromised tooth by allogeneic grafting of mesenchymal stem cells from dental pulp: A case report. *J Int Med Res* 2018; 1: 1-11.
 - 43) Li Y, Zhao S, Nan X, Wei H, Shi J, Li A, *et al.* Repair of human periodontal bone defects by autologous grafting stem cells derived from inflammatory dental pulp tissues. *Stem Cell Res Ther* 2016; 7: 1-9.
 - 44) Fawzy El-Sayed KM, Paris S, Becker ST, Neuschl M, De Buhr W, Sälzer S, *et al.* Periodontal regeneration employing gingival margin-derived stem/progenitor cells: An animal study. *J Clin Periodontol* 2012; 39: 861-870.
 - 45) Fawzy El-Sayed KM, Mekhemar MK, Beck-Broichsitter BE, Bähr T, Hegab M, Receveur J, *et al.* Periodontal regeneration employing gingival margin-derived stem/progenitor cells in conjunction with IL-1ra-hydrogel synthetic extracellular matrix. *J Clin Periodontol* 2015; 42: 448-457.
 - 46) Yamamiya K, Okuda K, Kawase T, Hata K, Wolff LF, Yoshie H. Tissue-engineered cultured periosteum used with platelet-rich plasma and hydroxyapatite in treating human osseous defects. *J Periodontol* 2008; 79: 811-818.
 - 47) Okuda K, Yamamiya K, Kawase T, Mizuno H, Ueda M, Yoshie H. Treatment of human infrabony periodontal defects by grafting human cultured periosteum sheets combined with platelet-rich plasma and porous hydroxyapatite granules: case series. *J Int Acad Periodontol* 2009; 11: 206-213.
 - 48) Tobita M, Uysal CA, Guo X, Hyakusoku H, Mizuno H. Periodontal tissue regeneration by combined implantation of adipose tissue-derived stem cells and platelet-rich plasma in a canine model. *Cytotherapy* 2013; 15: 1517-1526.
 - 49) Ozasa M, Sawada K, Iwayama T, Yamamoto S, Morimoto C, Okura H, *et al.* Periodontal tissue regeneration by transplantation of adipose tissue-derived multi-lineage progenitor cells. *Inflamm Regen* 2014; 34: 109-116.
 - 50) Yan XZ, Yang F, Jansen JA, de Vries RBM, van den Beucken JJJP. Cell-based approaches in periodontal regeneration: a systematic review and meta-analysis of periodontal defect models in animal experimental work. *Tissue Eng Part B Rev* 2015; 21: 411-426.
 - 51) Tassi SA, Sergio NZ, Misawa MYO, Villar CC. Efficacy of stem cells on periodontal regeneration: Systematic review of pre-clinical studies. *J Periodontol Res* 2017; 52: 793-812.
 - 52) Nakajima R, Ono M, Hara ES, Oida Y, Shinkawa S, Pham HT, *et al.* Mesenchymal stem/progenitor cell isolation from tooth extraction sockets. *J Dent Res* 2014; 93: 1133-1140.
 - 53) Tsumanuma Y, Iwata T, Washio K, Yoshida T, Yamada A, Takagi R, *et al.* Comparison of different tissue-derived stem cell sheets for periodontal regeneration in a canine 1-wall defect model. *Biomaterials* 2011; 32: 5819-5825.
 - 54) Chen FM, Zhang J, Zhang M, An Y, Chen F, Wu ZF. A review on endogenous regenerative technology in periodontal regenerative medicine. *Biomaterials* 2010; 31: 7892-7927.
 - 55) Chen G, Chen J, Yang B, Li L, Luo X, Zhang X, *et al.* Combination of aligned PLGA/Gelatin electrospun sheets, native dental pulp extracellular matrix and treated dentin matrix as substrates for tooth root regeneration. *Biomaterials* 2015; 52: 56-70.
 - 56) Dogan A, Ozdemir A, Kubar A, Oygür T. Assessment of periodontal healing by seeding of fibroblast-like cells derived from regenerated periodontal ligament in artificial furcation defects in a dog: a pilot study. *Tissue Eng* 2002; 8: 273-282.
 - 57) Doğan A, Özdemir A, Kubar A, Oygür T. Healing of artificial fenestration defects by seeding of fibroblast-like cells derived from regenerated periodontal ligament in a dog: A preliminary study. *Tissue Eng* 2003; 9: 1189-1196.
 - 58) Fu X, Jin L, Ma P, Fan Z, Wang S. Allogeneic stem cells from deciduous teeth in treatment for periodontitis in miniature swine. *J Periodontol* 2014; 85: 845-851.
 - 59) Gao ZH, Hu L, Liu GL, Wei FL, Liu Y, Liu ZH, *et al.* Bio-root and implant-based restoration as a tooth replacement alternative. *J Dent Res* 2016; 95: 642-649.
 - 60) Jiang J, Wu X, Lin M, Doan N, Xiao Y, Yan F. Application of autologous periosteal cells for the regeneration of class III

- furcation defects in Beagle dogs. *Cytotechnology* 2010; 62: 235-243.
- 61) Khorsand A, Eslaminejad MB, Arabsolghar M, Paknejad M, Ghaedi B, Rokn AR, *et al.* Autologous dental pulp stem cells in regeneration of defect created in canine periodontal tissue. *J Oral Implantol* 2013; 39: 433-443.
- 62) Lang H, SchÜler N, Nolden R. Attachment formation following replantation of cultured cells into periodontal defects —A study in minipigs. *J Dent Res* 1998; 77: 393-405.
- 63) Li H, Yan F, Lei L, Li Y, Xiao Y. Application of autologous cryopreserved bone marrow mesenchymal stem cells for periodontal regeneration in dogs. *Cells Tissues Organs* 2009; 190: 94-101.
- 64) Liu Z, Yin X, Ye Q, He W, Ge M, Zhou X, *et al.* Periodontal regeneration with stem cells-seeded collagen-hydroxyapatite scaffold. *J Biomater Appl* 2016; 31: 121-131.
- 65) Nakahara T, Nakamura T, Kobayashi E, Kuremoto K, Matsuno T, Tabata Y, *et al.* In situ tissue engineering of periodontal tissues by seeding with periodontal ligament-derived cells. *Tissue Eng* 2004; 10: 537-544.
- 66) Nuñez J, Sanz-Blasco S, Vignoletti F, Muñoz F, Arzate H, Villalobos C, *et al.* Periodontal regeneration following implantation of cementum and periodontal ligament-derived cells. *J Periodont Res* 2012; 47: 33-44.
- 67) Paknejad M, Eslaminejad MB, Ghaedi B, Rokn AR, Khorsand A, Etemad-Moghadam S, *et al.* Isolation and assessment of mesenchymal stem cells derived from bone marrow: histologic and histomorphometric study in a canine periodontal defect. *J Oral Implantol* 2015; 41: 284-291.
- 68) Suaid FF, Ribeiro FV, Rodrigues TL, Silvério KG, Carvalho MD, Nociti FH, *et al.* Autologous periodontal ligament cells in the treatment of class II furcation defects: A study in dogs. *J Clin Periodontol* 2011; 38: 491-498.
- 69) Suaid FF, Ribeiro FV, Gomes TRLES, Silvério KG, Carvalho MD, Nociti FH, *et al.* Autologous periodontal ligament cells in the treatment of class III furcation defects: a study in dogs. *J Clin Periodontol* 2012; 39: 377-384.
- 70) Wei N, Gong P, Liao D, Yang X, Li X, Liu Y, *et al.* Auto-transplanted mesenchymal stromal cell fate in periodontal tissue of beagle dogs. *Cytotherapy* 2010; 12: 514-5121.
- 71) Yang JR, Hsu CW, Liao SC, Lin YT, Chen LR, Yuan K. Transplantation of embryonic stem cells improves the regeneration of periodontal furcation defects in a porcine model. *J Clin Periodontol* 2013; 40: 364-371.
- 72) Yang KC, Kitamura Y, Wu CC, Chang HH, Ling TY, Kuo TF. Tooth germ-like construct transplantation for whole-tooth regeneration: an in vivo study in the miniature pig. *Artif Organs* 2016; 40: E39-50.
- 73) Zang S, Jin L, Kang S, Hu X, Wang M, Wang J, *et al.* Periodontal wound healing by transplantation of jaw bone marrow-derived mesenchymal stem cells in chitosan/anorganic bovine bone carrier into one-wall infrabony defects in beagles. *J Periodontol* 2016; 87: 971-981.
- 74) Dhote R, Charde P, Bhongade M, Rao J. Stem cells cultured on beta tricalcium phosphate (beta-TCP) in combination with recombinant human platelet-derived growth Factor-BB (rh-PDGF-BB) for the treatment of human infrabony defects. *J Stem Cells* 2015; 10: 243-254.
- 75) Ki V, Ryana H, Dalvi PJ. Autologous periodontal stem cell assistance in periodontal regeneration technique (SAI-PRT) in the treatment of periodontal intrabony defects: A case report with one-year follow-up. *J Dent Res Dent Clin Dent Prospects* 2017; 11: 123-126.
- 76) Rosen PS, Froum SJ, Cohen DW. Consecutive case series using a composite allograft containing mesenchymal cells with an amnion-chorion barrier to treat mandibular class III/IV furcations. *Int J Periodont Restora Dent* 2015; 35: 453-460.