



**HAL**  
open science

## Pyoderma Gangrenosum Under Dabrafenib and Trametinib for Metastatic Melanoma

Mélanie Saint-Jean, Marie Le Moigne, Justine Daguze, Céline Bossard, Lucie  
Peuvrel, Gaëlle Quereux, Brigitte Dréno

► **To cite this version:**

Mélanie Saint-Jean, Marie Le Moigne, Justine Daguze, Céline Bossard, Lucie Peuvrel, et al.. Pyoderma Gangrenosum Under Dabrafenib and Trametinib for Metastatic Melanoma. *Acta Dermatovenereologica*, 2018, 98 (5), pp.530-531. 10.2340/00015555-2890 . inserm-02099570

**HAL Id: inserm-02099570**

**<https://inserm.hal.science/inserm-02099570>**

Submitted on 15 Apr 2019

**HAL** is a multi-disciplinary open access archive for the deposit and dissemination of scientific research documents, whether they are published or not. The documents may come from teaching and research institutions in France or abroad, or from public or private research centers.

L'archive ouverte pluridisciplinaire **HAL**, est destinée au dépôt et à la diffusion de documents scientifiques de niveau recherche, publiés ou non, émanant des établissements d'enseignement et de recherche français ou étrangers, des laboratoires publics ou privés.

## Pyoderma Gangrenosum Under Dabrafenib and Trametinib for Metastatic Melanoma

Mélanie SAINT-JEAN<sup>1,2</sup>, Marie LE MOIGNE<sup>1</sup>, Justine DAGUZE<sup>1</sup>, Céline BOSSARD<sup>3</sup>, Lucie PEUVREL<sup>1,2</sup>, Gaëlle QUEREUX<sup>1,2</sup> and Brigitte DRENO<sup>1,2\*</sup>; on behalf of GESTIM Nantes group of cutaneous adverse events induced by anticancer drugs  
<sup>1</sup>Dermatology Department, <sup>2</sup>CIC1413, CRCINA Inserm 1232, and <sup>3</sup>Pathology Department, CHU Nantes, Nantes, France. \*E-mail: brigitte.dreno@wanadoo.fr

Accepted Jan 23, 2018; Epub ahead of print Jan 24, 2018

In recent years a combination of *BRAF* and *MEK* inhibitors has become the first-line treatment for *BRAF* V600 mutated unresectable or metastatic melanoma, with a response rate of 70% (1). Cutaneous adverse events are frequent and mostly related to *BRAF* inhibitor treatment. Reported toxicities can be severe, and include skin rash, photosensitivity, dry skin, and squamous cell carcinoma (2).

In addition to the numerous cases of neutrophilic *BRAF* inhibitor-induced panniculitis reported previously, rare cases of other neutrophilic dermatoses have been described in the literature, including 2 cases of Sweet's syndrome (3, 4) and 2 cases of neutrophilic eccrine hidradenitis (5).

To the best of our knowledge, this is the first report of pyoderma gangrenosum (PG) in a patient treated with combined *BRAF* and *MEK* inhibitor for metastatic melanoma.

### CASE REPORT

A 74-year-old man presented with a medical history of hypertension, which was being treated with lercanidipine, candesartan and hydrochlorothiazide, and atrial fibrillation being treated with oral anticoagulant. He had had a primary melanoma on his back in 1995, which was treated with local excision (Breslow index 1.6 mm) with no adjuvant treatment. Eight years later he had a relapse of melanoma, with metastasis to axillary lymph nodes and a cutaneous nodule on the back histologically

proven to be melanoma metastasis. As the disease was unresectable, he was given several treatments: NY-ESO1 vaccine (NCT01213472), vemurafenib alone in 2014, dabrafenib alone in 2015, anti-PD1 nivolumab, talimogene laherparepvec (T-VEC) injections (NCT02366195), dabrafenib combined with trametinib in Mekinist access protocol (protocol NCT02416232) (Fig. 1). More recently, after European Medicines Agency approval, the same combination of *BRAF* and *MEK* inhibitor was continued off protocol.

Ten weeks after introduction of dabrafenib and trametinib, the patient presented with an acute and painful ulceration overlying a subcutaneous melanoma metastasis on his back with no accompanying fever. The ulcer was necrotic with pustules on the edge (Fig. 2). Laboratory evaluation revealed an inflammatory syndrome with an increase in C-reactive protein (146 mg/l) and neutrophils leukocytosis (12,360/mm<sup>3</sup>). The first hypothesis was a tumour necrosis with superinfection. Skin cultures were performed and a methicillin-sensible *Staphylococcus aureus* was isolated. Based on this result, the patient received amoxicillin and clavulanic acid for 7 days with no clinical improvement. Pathological examination of a skin specimen revealed a dense infiltrate of neutrophils in the dermis with no identifiable tumour cells (negative Melan-A staining) or pathogenic agents (Fig. S1<sup>1</sup>), using Periodic acid-Schiff (PAS) and Grocott staining. This confirmed the other hypothesis; clinical suspicion of PG. Considering the benefit/risk ratio, targeted therapy was continued and the patient received minocycline, 100 mg per day, in parallel, for the PG. Tolerance was excellent. Healing of PG was obtained after 3 months of minocy-

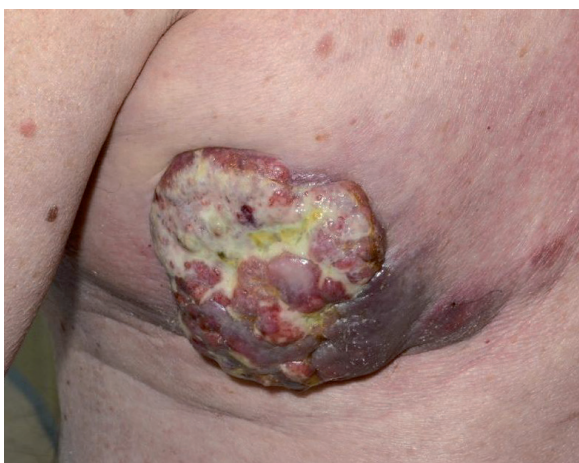


Fig. 1. Clinical aspect of the metastasis on the patient's back at the start of dabrafenib and trametinib treatment.

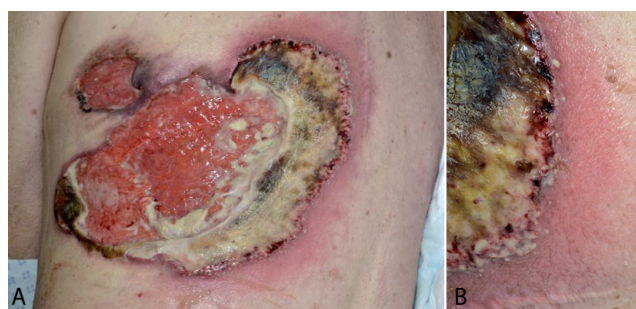

Fig. 2. (A) Pyoderma gangrenosum of the back 10 weeks after the start of treatment. (B) Pustules on the edge of the ulcer.

<sup>1</sup><https://www.medicaljournals.se/acta/content/abstract/10.2340/00015555-2890>

cline treatment, and this was later stopped (Fig. S2<sup>1</sup>). No recurrence of PG was noted within 5 months. Moreover, complete remission of melanoma was confirmed, with a negative positron emission tomography scanner. Finally, in the context of cancer-induced protein malnutrition and to avoid a very long time for re-epithelialization, the patient underwent a skin graft of the back in order to cover the large residual defect. Targeted therapy is ongoing.

## DISCUSSION

Several types of neutrophilic dermatoses have been reported previously with *BRAF*-targeted therapy, including neutrophilic panniculitis (more than 50 cases) and, more rarely, Sweet's syndrome (3, 4) (2 cases) and neutrophilic eccrine hidradenitis (5) (2 cases). Most of the cases were reported with vemurafenib therapy. Four cases of panniculitis and one case of eccrine hidradenitis were reported under dabrafenib alone (6–9). Two cases of panniculitis were observed under dabrafenib and trametinib (10). Our case of PG under dabrafenib and trametinib is the first case of PG described under *BRAF* and/or *MEK* inhibitors. Notably, the PG occurred on the location of a melanoma metastasis and could have been either directly induced by the targeted therapy or favoured in the context of local tumour necrosis due to this latter treatment.

Concerning panniculitis, in more than half of the cases with available data, targeted therapy was continued without dose reduction with favourable evolution, despite occasional recurrence of lesions. Concerning the other rare neutrophilic dermatoses, the treatment was stopped in the 4 cases. In view of the benefit our patient was experiencing under targeted therapy, we chose not to stop it. Regarding PG, several treatments have been proposed including topical and oral corticosteroids, as well as non-steroidal anti-inflammatory drugs, particularly in cases with associated arthralgia. To our knowledge, there is no previous reported use of minocycline in this context. It was the drug of choice for 2 main reasons: first, minocycline has previously been described to have efficacy in neutrophilic dermatoses including PG. Moreover, it induces an anti-inflammatory effect, but with mild immunosuppression, which is valuable in the context of metastatic melanoma.

Interestingly, our patient had previously been treated separately with the 2 *BRAF* inhibitors vemurafenib and dabrafenib alone, as *MEK* inhibitors were not approved in Europe at that time. Vemurafenib was used in our patient for 5 months and dabrafenib for 4 months with no skin toxicity. In this case, PG appeared with a delayed onset of 10 weeks, after re-challenging with dabrafenib.

Nonetheless, our patient had been heavily pretreated, including with NY-ESO1 vaccine and T-VEC injections. One could hypothesize that these prior treatments could have induced local immune modifications, possibly favouring the occurrence of PG.

Finally, according to most reported cases, and as also found in our case, a link between targeted therapy-induced neutrophilic skin toxicity and the therapeutic response of metastatic melanoma to targeted therapy is suggested. Indeed, in 66% of the evaluable cases (18 out of 27), a partial or complete response was described under treatment.

This is the first reported case of PG in a patient re-challenged with dabrafenib and trametinib for metastatic melanoma. The PG healed completely with minocycline treatment.

*The authors have no conflicts of interest to declare.*

## REFERENCES

1. Ascierto PA, McArthur GA, Dreno B, Atkinson V, Liszkay G, Di Giacomo AM, et al. Cobimetinib combined with vemurafenib in advanced BRAF(V600)-mutant melanoma (coBRIM): updated efficacy results from a randomised, double-blind, phase 3 trial. *Lancet Oncol* 2016; 17: 1248–1260.
2. Peuvrel L, Quereux G, Saint-Jean M, Brocard A, Nguyen JM, Khammari A, et al. Profile of vemurafenib-induced severe skin toxicities. *J Eur Acad Dermatol Venereol* 2016; 30: 250–257.
3. Yorio JT, Mays SR, Ciurea AM, Cohen PR, Wang WL, Hwu WJ, et al. Case of vemurafenib-induced Sweet's syndrome. *J Dermatol* 2014; 41: 817–820.
4. Pattanaprichakul P, Tetzlaff MT, Lapolla WJ, Torres-Cabala CA, Duvic M, Prieto VG, et al. Sweet syndrome following vemurafenib therapy for recurrent cholangiocarcinoma. *J Cutan Pathol* 2014; 41: 326–328.
5. Herms F, Franck N, Kramkimel N, Fichel F, Delaval L, Laurent-Roussel S, et al. Neutrophilic eccrine hidradenitis in two patients treated with BRAF inhibitors: a new cutaneous adverse event. *Br J Dermatol* 2017; 176: 1645–1648.
6. Zimmer L, Livingstone E, Hillen U, Domkes S, Becker A, Schadendorf D. Panniculitis with arthralgia in patients with melanoma treated with selective BRAF inhibitors and its management. *Arch Dermatol* 2012; 148: 357–361.
7. Ramani NS, Curry JL, Kapil J, Rapini RP, Tetzlaff MT, Prieto VG, et al. Panniculitis with necrotizing granulomata in a patient on BRAF inhibitor (dabrafenib) therapy for metastatic melanoma. *Am J Dermatopathol* 2015; 37: e96–99.
8. Leal L, Agut-Busquet E, Romani J, Sabat M, Yebenes M, Saez A, et al. Cutaneous granulomatous panniculitis and sarcoidal granulomatous papular eruption in a patient with metastatic melanoma treated with a BRAF inhibitor. *J Dermatol* 2016; 43: 715–716.
9. Anforth RM, Blumetti TC, Kefford RF, Sharma R, Scolyer RA, Kossard S, et al. Cutaneous manifestations of dabrafenib (GSK2118436): a selective inhibitor of mutant BRAF in patients with metastatic melanoma. *Br J Dermatol* 2012; 167: 1153–1160.
10. Mossner R, Zimmer L, Berking C, Hoeller C, Loquai C, Richtig E, et al. Erythema nodosum-like lesions during BRAF inhibitor therapy: report on 16 new cases and review of the literature. *J Eur Acad Dermatol Venereol* 2015; 29: 1797–1806.