

White matter abnormalities in depression: a categorical and phenotypic diffusion MRI study.

Julie Coloigner^{1*}, Jean-Marie Batail^{1,2,3*}, Olivier Commowick¹, Isabelle Corouge¹, Christian Barillot^{1*} and Dominique Drapier^{2,3*}

¹Univ Rennes, Inria, CNRS, Inserm, IRISA UMR 6074, VISAGES ERL U-1228, F-35000 Rennes, France.

²Centre Hospitalier Guillaume R gnier, Academic Psychiatry Department, 35703 Rennes, France

³Univ of Rennes, "Behavior and Basal Ganglia" research unit (EA 4712), Rennes, France

* These authors contributed equally to this work.

Corresponding author:

Julie Coloigner, Ph.D.

Unit  VisAGeS U1228, INSERM, INRIA, Universit  Rennes I

IRISA, UMR CNRS 6074

Campus de Beaulieu

35042 Rennes Cedex

France

E-mail: julie.coloigner@inria.fr

Abstract 350 words

Mood depressive disorder is one of the most disabling chronic disease with a high rate of everyday life disability that affects 350 million people around the world. Recent advances in neuroimaging have reported widespread structural abnormalities, suggesting a dysfunctional frontal-limbic circuit involved in the pathophysiological mechanisms of depression. However, a variety of different white matter regions has been implicated. These inconsistent results might be attributed to various factors: symptoms and duration of the disease as well as clinical phenotype. In this study, we examined WM integrity in a large cohort (114 patients) compared to a healthy control group. Consistent with previous studies, reduced white matter integrity was observed in the genu of the corpus callosum extending to the inferior fasciculus and posterior thalamic radiation, confirming a frontal-limbic circuit abnormality. Our analysis also reported other patterns of increased fractional anisotropy and axial diffusivity as well as decreased apparent diffusion coefficient and radial diffusivity in the splenium of the corpus callosum and posterior limb of the internal capsule. Moreover, we sought to identify specific WM alterations in relation to specific depressive phenotypes such as anhedonia (i.e. lack of pleasure), anxiety and psychomotor retardation –three core symptoms involved in depression. A positive correlation between FA and anhedonia was found in superior longitudinal fasciculus as well as a negative correlation in the cingulum. Then, the analysis of the anxiety and diffusion metric revealed that increased anxiety was associated with greater FA values in genu and splenium of corpus callosum, anterior corona radiata and posterior thalamic radiation. Finally, the motor retardation analysis showed a correlation between increased Widlöcher depressive retardation scale scores and reduced FA in the body and genu of the corpus callosum, fornix, and superior striatum. Through this twofold approach (categorical and phenotypic), this study has underlined the need to move forward to a research area of biomarkers, which help to understand the pathophysiology of mood depressive disorder and to stratify precise phenotypes of depression with targeted therapeutic strategies.

Keywords: diffusion-weighted imaging, voxel-based analysis, fractional anisotropy value, depression, categorical and phenotypic approach.

1 Introduction

Mood Depressive Disorder (MDD) is one of the most disabling chronic diseases with a high rate of everyday life incapacity that affects 350 million people around the world (Smith, 2014). This pathology is considered underdiagnosed, without adequate therapeutic resources, which emphasizes the need to be a public health priority (Ferrari et al., 2013). One of the most important causes of misdiagnosis is the poor interrater reliability of actual classifications (Freedman et al., 2013). Mood Depressive Episode criterion of the Diagnostic and Statistical Manual of Mental Disorders (DSM-5) (Edition, 2013) indeed encompass a wide range of clinical phenotypes of depression “from gravely disabled melancholic patients to many individuals in the general population who do not seek treatment” (Freedman et al., 2013). This suggests that DSM-5 does not provide a valid tool for helpful and reliable diagnosis and therapeutic strategies. In this context, despite the extensive therapy options available for depression, up to 80% of patients will suffer from a relapse (Gotlib et al., 2008). On the neurobiological side, this disease is characterized by a profound and persistent dysregulation of affect and mood (Fitzgerald, 2013), which coexist with additional disturbance including cognitive dysfunction, insomnia, fatigue and appetite disturbance (Drevets, 2001). Consequently, understanding the neural correlates underlying depression, and its phenotype variability, will optimize the diagnosis and treatment of individual depressed patients.

Over the last decades, recent advances in neuroimaging have greatly increased our knowledge of MDD, particularly its neural bases. Widespread structural abnormalities have been reported including regional tissue loss in the hippocampus, amygdala, basal ganglia, prefrontal cortex and anterior cingulate cortex (Arnone et al., 2013; Zou et al., 2010). These results suggested that a dysfunctional cortical-subcortical neural circuit is involved in the pathophysiology and psychopathology of the depression (Chen et al., 2016; Korgaonkar et al., 2011; Sacchet et al., 2014). More particularly, a frontal-limbic circuit abnormality is considered as the locus of the dysfunction underlying mood-regulation in MDD (Chen et al., 2016; Korgaonkar et al., 2011; Sacchet et al., 2014). Structural connectivity analysis provides important information allowing for the characterization of cortical and subcortical abnormalities. White matter (WM) investigations have become a rapidly growing area of research in psychotic disorders including schizophrenia (Buchsbaum et al., 1998), bipolar disorder (Benedetti et al., 2015; Magioncalda et al., 2016) and depression (Chen et al., 2017). In this context, in the brain, diffusion-weighted imaging (DWI), a noninvasive magnetic resonance imaging (MRI) technique based on the extent of water diffusion, enables the quantification of the fiber orientation and integrity of WM pathways within neural networks (Assaf et al., 2008; Taylor et al., 2004). The most common DWI measure is the fractional anisotropy (FA), an invariant property of DWI that reflects a nonspherical diffusion tensor with a preferential orientation.

Several MDD studies (Chen et al., 2017; Korgaonkar et al., 2011) have revealed significant FA reductions in the body of the corpus callosum (CC) (Han et al., 2014; Korgaonkar et al., 2011), bilateral anterior limb of the internal capsule (ALIC) (Chen et al., 2016; Jia et al., 2010; Zou et al., 2008) and superior longitudinal fasciculus (SLF) (Ota et al., 2015) in MDD patients relative to healthy controls. However, existing knowledge about WM integrity is limited due to the small number of participants in most studies and the variety of different WM regions implicated (Liao et al., 2013; Murphy et al., 2011; Sexton et al., 2009). These inconsistent results might be attributed to various factors. The high

heterogeneity of MDD individuals in terms of disease characteristics (i.e. symptoms and duration of the disease), could be considered a main cause of these inconsistencies (Chen et al., 2016). Previous studies have indeed demonstrated the influence of episodes or illness duration (de Diego-Adelino et al., 2014), illness severity (Henderson et al., 2013) and antidepressant drugs (Dusi et al., 2015; Taylor et al., 2014) on WM. The FA reduction was associated with depression severity and illness duration in MDD patients in the genu of corpus callosum, anterior thalamic radiation, anterior cingulum, and sagittal striatum, which indicates that DWI may be of clinical value in measuring and tracking disability in MDD (Chen et al., 2016; Henderson et al., 2013). One additional source of heterogeneity could be the clinical phenotype (Fried, 2015), such as anhedonia (i.e. lack of pleasure), anxiety and psychomotor retardation –three core symptoms involved in depression. As mentioned above, DSM-5 diagnosis criteria include a wide panel of emotional, motivational and cognitive symptoms (Edition, 2013). Some of these dimensions can be negatively correlated such as motivation and anhedonia severity (Batail et al., 2017). Then, the high variability of diagnosis criteria could lead to poor diagnosis interrater reliability (Freedman et al., 2013). For the last two decades, neuroimaging studies in MDD have identified many putative biomarkers, based on actual disease classification, which remain inconsistent tools. Therefore, there is a need to find new imaging biomarkers which could potentially improve our understanding the pathophysiology of MDD (Young et al., 2016). Then, the investigation of core dimensions of depression such as anxiety, anhedonia and psychomotor retardation, is of great importance for identifying the fundamental and specific changes in the microarchitecture of WM, elucidating the essential pathophysiology of MDD, and help to stratify precise phenotypes of depression with targeted therapeutic strategies.

Therefore, the first aim of this study was to examine WM integrity in a larger cohort of MDD patients to address more consistent and replicable WM microarchitecture abnormalities than previously found in previous studies. The second aim of our study was to identify specific WM alterations in relation to specific dimensions of depression such as anhedonia, anxiety and psychomotor retardation.

2 Materials and Methods

2.1 Participants

One hundred and fourteen depressed patients were recruited from routine care units in the psychiatric university hospital of Rennes between November 2014 and January 2017 and were enrolled in a naturalistic prospective cohort study. The study was approved by an ethic committee and is registered in www.clinicaltrials.gov (NCT02286024), written informed consents were obtained from all subjects.

The study was proposed to patients suffering from a Mood Depressive Episode (MDE) under DSM-5 criteria with or without personal history of Mood Depressive Disorder (unipolar or bipolar subtype). Exclusion criteria included other Axis-I disorders (except for Obsessive-Compulsive Disorder and four anxious comorbidities such as posttraumatic stress disorder, social phobia, generalized anxiety disorder or panic disorder), which were explored using the Mini-International Neuropsychiatric Interview (Lecrubier et al., 1997). Patients with severe chronic physical illness were not included. Other exclusion criteria were potential safety contraindications for MRI (pacemakers, metal implants, pregnancy, and lactation), diagnosed neurodegenerative disorders (e.g. Parkinson's

disease, Alzheimer's disease, Huntington's disease), a history of significant head injury, or diagnosed dementia (according to DSM-5 criteria).

Depressed patients underwent clinical interview and examination, including routine neuropsychological testing and MRI. For each subject, demographic data, comorbidities and medication, as well as clinical variables were collected (see Table 1). A composite measure of medication load for each patient was assessed using a previously established method (Sackeim, 2001).

The control group was composed of 65 healthy volunteers, who previously participated in neuroimaging studies. The two groups were matched in terms of age (CTL: 48.6 ± 11.8 , MDD: 48.3 ± 15.4 ; Student *t*-test *p*-value=0.5) and gender (CTL: 17M/48F, MDD: 43M/71F; Chi-square *p*=0.5).

2.2 Clinical assessment

Patients were assessed by a single structured clinical interview by a trained psychiatrist. Depression severity was assessed using Montgomery and Åsberg Depression Rating Scale (MADRS) (Montgomery et al., 1979). Additionally, the Widlöcher Depressive Retardation Scale (WDRS) (Widlöcher, 1983) was used to estimate psychomotor retardation. State anxiety was measured using State Trait Anxiety Inventory A (STAI-YA) (Spielberger et al., 1970). Then, the anhedonia scores were assessed by Snaith Hamilton Pleasure Scale (SHAPS) (Snaith et al., 1995).

2.3 MRI acquisition

Patients and healthy subjects were scanned on a 3T whole body Siemens MR scanner (Magnetom Verio, Siemens Healthcare, Erlangen, Germany) with a 32-channel head coil. The 3D T1-weighted image was acquired covering the whole brain (176 sagittal slices) with TR = 1.9 s, TE = 2.26 ms, flip angle = 9°, in-plane resolution = 2 mm × 2 mm, FOV = 256 mm × 256 mm and thickness/gap = 1.0/0 mm).

DWI data were gathered on 60 slices using an interleaved slice acquisition, slice thickness of 2 mm, no gap, in-plane resolution = 1 mm × 1 mm and in a 256 mm × 256 mm field of view. The acquisition matrix was 128 × 128, the reconstruction matrix was 128 × 128, using 30 directions and a b-value of 1000 s/mm². TR/TE = 11 000/99 ms, flip angle was 90°, pixel bandwidth was 1698 Hz, and the imaging frequency was 123.2 MHz.

2.4 Image processing

Preprocessing of diffusion images was mainly performed using the open source medical image processing toolbox Anima (<https://github.com/Inria-Visages/Anima-Public/wiki>). Diffusion images were corrected for eddy current-induced image distortion using Block-Matching Distortion Correction method ensuring an opposite symmetric transformation (Hedouin et al., 2017). Then, rigid realignment was then performed to compensate for subject motion and ensure voxel-to-voxel correspondence across gradients. Then, denoising step using blockwise non-local means filtering was applied (Coupé et al., 2008). Skull stripping was performed using an atlas-registration-based method. The structural image of each patient was transformed to the atlas image, using the linear and non-linear block-matching algorithms (Commowick et al., 2012a, b; Ourselin et al., 2000). Then, the atlas intracranial brain

mask was inversely transformed by applying the inverse of two calculated transformation matrix and multiplied with the original structural image of the patient.

Diffusion tensor images were then estimated using a log-Euclidean estimation method proposed by Fillard et al. (Fillard et al., 2007), from which diffusion scalar maps were calculated.

Then, a two-step co-registration method was used to transform the diffusion data into the Montreal Neurological Institute (MNI) template space. First, the FA image was co-registered with the structural image; then the structural image was non-linearly transformed to the MNI template space, using the block-matching algorithms (Commowick et al., 2012a, b; Ourselin et al., 2000). Then, we applied these parameters to the other diffusion metrics to normalize them to the MNI space. Next, an average FA image was generated and thresholded to $FA > 0.3$ to confine the statistical analysis within the WM regions (Du et al., 2017). Then, this map was used to mask the FA, apparent diffusion coefficient (ADC), axial diffusivity (AD) and radial diffusivity (RD) maps, to include the major WM tracts and avoid small peripheral tracts that would cause excessive inter-participant variability.

2.5 Statistical analysis

Statistical tests of the diffusion metrics (FA, ADC, AD and RD) in the MNI space between MDD and CTL were performed using voxel-based two-sample t-test with age, gender, duration of disease and medication load as nuisance covariates. The result was corrected for multiple comparison using False Discovery Rate (FDR) correction with ($p < 0.05$) (Benjamini et al., 1995).

To investigate the relationship between diffusion metrics and clinical variables (WDRS, STAI-YA and SHAPS) in the MDD group, Pearson correlation was performed in a voxelwise manner. This analysis was restricted to FA values, because the metric is more likely to capture microstructure-induced diffusion abnormalities than ADC, AD and RD (Westin et al., 2002). Thresholds were set at a corrected $p < 0.05$, with multiple comparison correction using FDR correction ($p < 0.05$) (Benjamini et al., 1995).

3 Results

3.1 Demographics and clinical measures

Women, middle-aged predominantly represented the patient population. They have severe characteristics of disease with a long mean duration of illness (range: 25% < 3 years and 17% > 21 years) and episode (range: 50% \geq 14 episodes). A large majority of patients suffered from recurrent depressive episodes (50% of the patients had more than 3 episodes). Actual depressive episode was moderately intense (MADRS total score = 27.4 ± 5.9). Indeed, 78% of this cohort suffered from high anxiety ($36 \leq AES \leq 65$) and 27% from very high anxiety higher than 65. All patients were under treatment (Table 1).

3.2 Whole brain structural alteration Data: Differences between Groups

Compared with CTL, the MDD group had lower FA in the cingulum, the inferior longitudinal fasciculus (ILF), posterior thalamic radiation (PTR), cingulum and the genu of CC (see Figure 1). However, the MDD group had

greater FA in the posterior limb of the internal capsule (PLIC) and splenium of CC. The maximum FA differences in genu of CC and splenium of CC were -33% and +11%, respectively. The identified WM regions and maximum FA values for these clusters (corrected for age, gender, disease duration and medication load) are summarized in Table 2.

Table 1: Demographic and clinical characteristics of the MDD group.

	MDD group (n=114)		
	Mean	SD	Range
<i>Sociodemographic variables</i>			
Age (years)	48.2	15.3	18 - 77
Gender (M/F)	43M/71F	-	-
Education (years)	12.2	3.6	4-20
Duration of illness (years)	15.1	13.9	0 - 60
Number of episodes	4.4	4.5	0-30
Duration of episode (weeks)	30.0	37.8	0-170
Number of suicidal attempts	1.1	2.0	0-10
<i>Medication</i>			
Medication load	3.1	1.2	0-7
Antidepressant	74.6%	-	-
Mood stabilizer	35.1%	-	-
Antipsychotic	14.0%	-	-
Benzodiazepine	49.1%	-	-
<i>Clinical variables</i>			
WDRS	21.4	9.0	2 - 43
MADRS	27.1	5.9	15 - 43
STAI-YA			
SHAPS	5.5	4.0	0 - 14
AES	40.3	8.9	24 - 69

All results except gender and medications are given as mean, standard deviation (sd) and the range. The percentage of patients having used the prescribed medicines: antidepressant, mood stabilizer, antipsychotic and benzodiazepine have been reported. WDRS: Widlöcher Depressive Retardation Scale; MADRS: Montgomery-Åsberg Depression Rating Scale; STAI: State-Trait Anxiety Inventory A; SHAPS: Snaith Hamilton Pleasure Scale.

For these significant regions, the results of two-sample t-test were also reported in the Table for the other diffusion metrics (ADC, AD and RD). Of the 6 clusters examined, all of them showed significant RD differences after FDR correction, whereas only 3 and 5 regions showed significant differences for ADC and AD, respectively.

Table 2: Brain areas with significant FA differences between the MDD and CTL groups.

Inter-group comparison		MDD vs.CTL			
Cerebral regions	Tracts	Right or Left	MNI coordinates	t-value	cluster size
Anterior cingulate	gCC	R/L	[±11,35,5]	-7.41	6959
Cingulum gyrus	Cingulum	R/L	[±11,-25,33]	-9.36	36859
Insula	ILF	R/L	[±6,-16,31]	-3.39	4338
Thalamus	PTR	R/L	[±27, -28,7]	-10.15	4109
Parahippocampal gyrus	PLIC	R/L	[±15,18,-16]	7.01	451
Posterior cingulate	sCC	R/L	[-8,38,7]	3.91	398

The t-value corresponds to the maximum value of the cluster. The cluster size is given in mm³. gCC and sCC: genu and splenium of the corpus callosum, ILF: Inferior Longitudinal Fasciculus, PTR: Posterior Thalamic Radiation (ATR), PLIC: Posterior Limb of the Internal Capsule.

Table 3: Statistic results of diffusion metric (FA, ADC, AD and RD) between the MDD and control groups.

Inter-group comparison		MDD vs.CTL			
Cerebral regions	Tracts	FA	ADC	AD	RD
Anterior cingulate	gCC	↘	↗	↘	↗
Cingulum gyrus	Cingulum	↘	↗	NS	↗
Insula	ILF	↘	↗	↘	↗
Thalamus	PTR	↘	↗	↘	↗
Parahippocampal gyrus	PLIC	↗	↘	↘	↘
Posterior cingulate	sCC	↗	↘	↘	↘

Up and down arrows indicate increased and decreased of the diffusion metric (FA, ADC, AD and RD) in MDD group compared to healthy control group. The arrows in bold front correspond to changes, which survived after FDR correction ($p \leq 0.05$). NS means no significant difference was found. gCC and sCC: genu and splenium of the Corpus Callosum, ILF: Inferior Longitudinal Fasciculus, PTR: Posterior Thalamic Radiation, PLIC: Posterior Limb of the Internal Capsule.

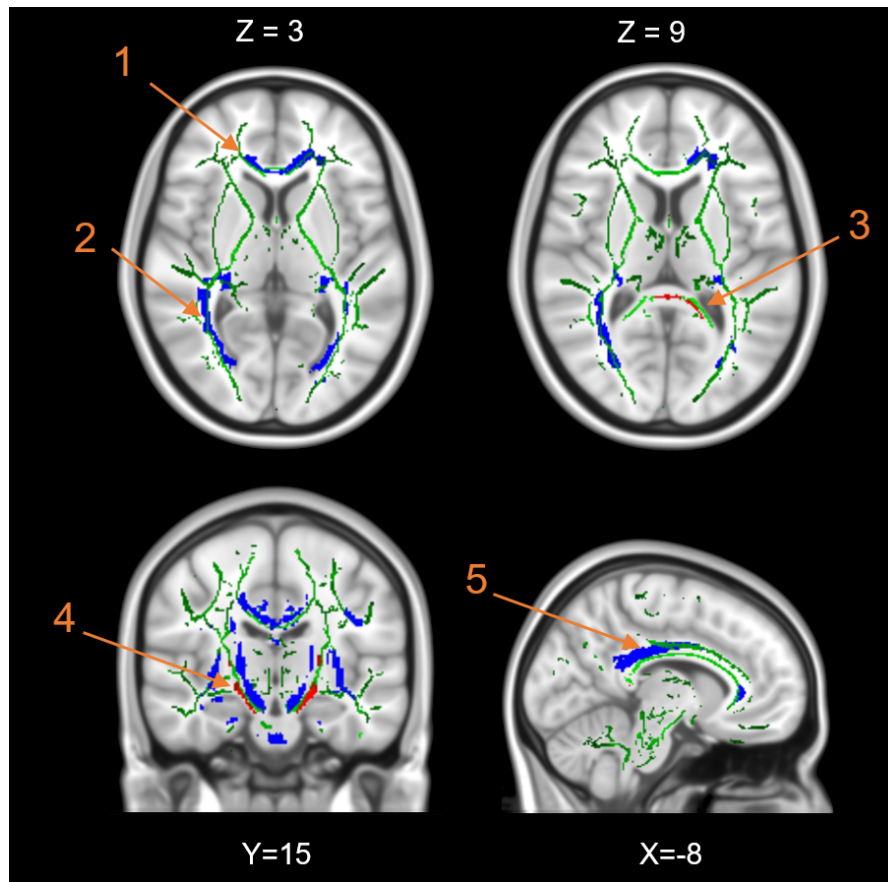


Figure 1: Axial, coronal and sagittal brain slices showing significant differences of the FA values between MDD and control groups, overlaid on the FA skeleton of Johns Hopkins University diffusion white matter atlas (green). Voxels with negative t-values (MDD<Control) are shown in blue and positive values (MDD>Control) with red. Arrows indicate the five clusters: genu (1) and splenium (3) of corpus callosum, posterior thalamic radiation/Inferior longitudinal fasciculus (2), bilateral posterior limb of internal capsule (4) and cingulum (5).

3.3 Correlation of structural connectivity and clinical scores

Analyses revealed eight clusters, as displayed in Figure 2. As the psychomotor retardation increased (i.e. WRDS values increased), the FA value decreased in the body and the genu of the CC, the superior corona radiata, the superior striatum (see Figure 2.A.). Additionally, as displayed in Figure 2.B., a positive correlation was found between the FA values and anxiety, measured by STAI-YA, in the genu and splenium of the CC, anterior corona radiata and posterior thalamic radiation. However, anxiety was negatively correlated with FA values in the body of CC. Similarly, a negatively correlation was found between the FA values and anhedonia with cingulum, genu of CC and posterior thalamic radiation (see Figure 2.C.). Furthermore, increased anhedonia (i.e. SHAPS values increased) was associated with greater FA values in superior longitudinal fasciculus.

Table 4: Voxel-wise correlations between FA and clinical variables.

Cerebral regions	Tracts	Right or Left	MNI coordinates	t-value	cluster size
Correlation with WDRS					
Anterior cingulate	bCC	R	[0,-13,20]	-3,84	3638
		L	[-14,-3,27]	-4,67	1877
Cingulate gyrus	SCR	L	[-19,-22,35]	-3,39	576
Parahippocampal gyrus	SS/PLIC	R/L	[±33, -45,-6]	-3,81	384
Superior frontal gyrus	gCC	R	[21,45,5]	-3,24	394
Correlation with STAI-YA					
Anterior cingulate	gCC	R/L	[0, 26, 8]	4,08	995
Insula	ACR	L	[-24, 29, 10]	3,53	1786
Precuneus	PTR	R/L	[±26,-69, 19]	4,01	938
Posterior cingulate	sCC	R	[-4,38,20]	3,88	306
Cingulate gyrus	bCC	R	[-23,25,38]	-3,02	562
Correlation with SHAPS					
Cingulate gyrus	Cingulum	L	[5,12,29]	-3,36	855
Anterior cingulate	gCC	R	[9,33,14]	-3,53	450
Cuneus	PTR	L	[-22,-72,11]	-3,49	342
Superior temporal gyrus	SLF	L	[-57,-29,4]	3,44	322

The *t*-value corresponds to the maximum correlation of the cluster. The cluster size is given in mm³. WDRS: Widlöcher Depressive Retardation Scale; MADRS: Montgomery-Åsberg Depression Rating Scale; STAI-YA: State-Trait Anxiety Inventory; SHAPS: Snaith Hamilton Pleasure Scale, gCC, bCC and sCC: genu, body and splenium of the Corpus Callosum, ACR and SCR: anterior and superior corona radiata, SS: sagittal stratum, PLIC: posterior limb of the internal capsule, PTR: posterior thalamic radiation, SLF: superior longitudinal fasciculus, PTR: posterior thalamic radiation..

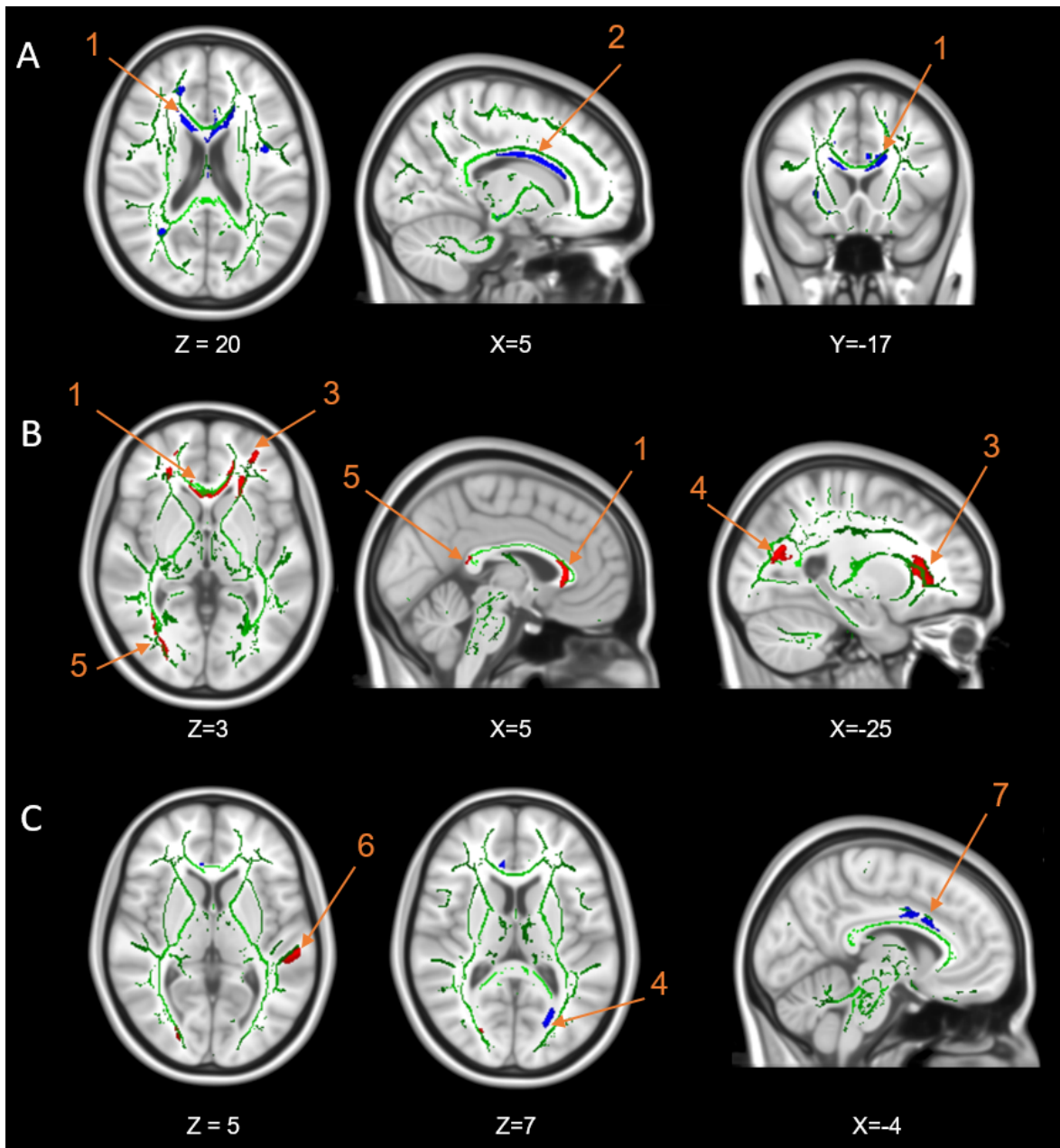


Figure 2: Axial, coronal and sagittal brain slices showing significant correlation between FA values and clinical variables: (A) WDRS, (B) STAI-YA and (C) SHAPS within the MDD group, overlaid on the FA skeleton of Johns Hopkins University diffusion white matter atlas (green). Voxels with negative correlation are shown in blue and positive correlation with red. Eight clusters are indicated by arrows: genu (1), body (2) and splenium (5) of corpus callosum, anterior corona radiata (ACR) (3), posterior thalamic radiation/Inferior longitudinal fasciculus (4), superior longitudinal fasciculus (SLF) (6) and cingulum (7).

4 Discussion

4.1 Anatomic connectivity abnormalities in depression

This is the first study analyzing diffusion metrics in such a large depression cohort. Analyses revealed widespread white matter abnormalities in the MDD group compared to CTL. As previously reported in many studies (Chen et al., 2017; Duffy et al., 2014; Henderson et al., 2013; Korgaonkar et al., 2011; Olvet et al., 2016), reduced WM integrity (i.e. decreased of FA and AD as well as increased ADC and RD) was observed in the genu of the CC extending to the ILF and PTR in MDD patients relative to healthy controls. Decreased FA and AD were observed in the cingulum combined with a normal or slightly increased RD and ADC. This pattern may represent decreased myelination (Korgaonkar et al., 2011) ; however, it could also result from a decrease in the number of normally myelinated fibers or an altered WM microstructure in the affected WM tracts (e.g., axonal degeneration (Bennett et al., 2010)).

The CC is the largest WM pathway providing a physical pathway for information transfer between the two hemispheres. The genu is the most rostral region of the corpus callosum connecting between prefrontal brain regions. The most caudal region, the splenium, connects association areas of the parietal and temporal lobes (anterior splenium) and occipital lobes (posterior splenium). In addition, the body is the midsection between the genu and the splenium associating the motor areas. In general, the corpus callosum changes structurally throughout life, but most dramatically during childhood and adolescence. Moreover, patients with disruption in axonal myelination exhibit executive deficits as well as cognitive dysfunction. Therefore, this tract constitutes key components of the frontotemporal and frontolimbic connections whose dysfunction is thought to underlie many of the emotional, cognitive and behavioral deficits associated with depression. However, the splenium is less vulnerable to damage than the genu and body of the CC, which are both late-myelinating. Moreover, reduced callosal thickness was found in this area only in late-onset depression compared to control, reflecting a more widespread compromise in corticocortical connectivity (Ballmaier et al., 2008).

The cingulum bundle lies within the cingulate gyrus and is an important association pathway linking prefrontal and parahippocampal regions. To date there is no conclusive evidence for cingulum bundle microstructural alterations in MDD groups. No changes in FA were demonstrated in adults (Carballedo et al., 2012; Zhang et al., 2012). However, reductions of FA in this region were reported in treatment-resistant MDD (de Diego-Adelino et al., 2014). The structural brain tissue markers FA and MD of the middle-anterior and middle-posterior cingulum bundle was associated with executive functioning and divided attention (Schermuly et al., 2010). The PTR joins the occipital and posterior parietal cortex with the posterior thalamus, including the pulvinar, and includes the optic radiation from the lateral geniculate body. A previous meta-analytic study that compared 231 MDD patients with 261 healthy participants found reduced FA in posterior thalamic radiation (Liao et al., 2013). This reduction of WM integrity in thalamus may be related to the role of the thalamus in motivation circuit, contributing to the motivational deficits associated with depression (Henderson et al., 2013) or to dysfunctional facial recognition in patients with MDD, as shown by other functional MRI studies (Liao et al., 2013).

The ILF connects the anterior part of temporal and occipital lobes, and could be related to emotion and visual processing information deficits of depression (de Diego-Adelino et al., 2014).

From a clinical perspective, our findings provide robust evidence that the reduction of white-matter integrity in the interhemispheric connections and fronto-limbic neuronal circuits may lead to a better understanding of the pathophysiology of MDD. These results are consistent with an overall hypothesis that depression involves a disconnection of prefrontal, striatal, and limbic emotional areas.

However, this analysis also reported other patterns with an increase of FA and AD as well as decreased ADC and RD in the PLIC and sCC in patients with depression. These findings in this large MDD cohort contrast with the previous results obtained with small and heterogeneous samples of patients suffering from depression. Previous studies reported inconsistent results concerning the sCC, varying from reduced WM integrity (Ota et al., 2015; Reppermund et al., 2014) to no effect. The white matter abnormality in the sCC and PLIC could potentially be associated with anxiety (Kim et al., 2017). As described in the section 4.2, patients of this cohort indeed suffered from high anxiety.

4.2 Phenotypic approach

This study builds on the research domain criteria (RDoC) approach. This initiative was proposed by the American National Institute of Mental Health to develop “new ways of classifying mental disorder based on behavioral dimensions and neurobiological measures” (NIMH, 2008). This approach promises to increase our understanding of basic network-level abnormalities and their relation to psychopathology (Insel et al., 2010). Depression, as currently defined, spans two of the RDoC domains: the Loss construct within the Negative Valence Systems domain and various Reward constructs within the Positive Valence Systems domain. This study focuses specifically on these two dimensions by analyzing the relation between diffusion metrics and two clinical measures, called SHAPS and STAI-YA measures (Cuthbert et al., 2013; Insel et al., 2010). Then, although RDoC program does not propose a behavioral domain, the relationship with psychomotor retardation using WRDS was investigated because of its central role in depression and discriminative potential for different phenotypes (melancholic subtype, bipolar/unipolar and consequences on treatment) (Bennabi et al., 2013). Through these three core dimensions of depression, this study highlights that depressive phenotypes can be underlined by wide differences according to the level of anxiety, anhedonia or psychomotor retardation. As developed below, phenotypic approach leads to a more specific, consistent and closer to physiopathology biomarkers.

The relationship between WM integrity and anhedonia

Consistent with previous studies, we found decreased FA as anhedonia increased in the cingulum. Indeed, Bracht et al. suggested that this tract could be a biomarker of vulnerability to depression (Bracht et al., 2015). Thus, the FA value in the cingulum bundle was also described negatively correlated with trait anhedonia (Keedwell et al., 2012). In addition, the same abnormality was described in women with a family history of depression (Keedwell et al., 2012), or in first depressed un-medicated patients (Yang et al., 2017). Altogether, these results suggested that cingulum WM alteration is involved in the pathophysiological mechanism of depression and is probably linked with reward sensitivity dimension.

Increased FA related to increased anhedonia was also found in SLF. Some studies reported the role of this tract in linking aspects of default mode network and cognitive control and its consequence on executive functioning (Jenkins et al., 2016). Moreover, patients suffering from depression could exhibit a deficit in executive functioning and related with a deficit in programming actions relative to hedonic valence. However, based on these arguments, the opposite correlation between FA and SHAPS was found in SLF. This result may represent a compensatory neuroplasticity or selective neurodegeneration mechanism (Jenkins et al., 2016; Mole et al., 2016).

Other significant decreased FA were found associated with decreased anhedonia in PTR. This result echoes the literature that pointed out the involvement of thalamic cortical projections in MDD (Hermesdorf et al., 2017; Korgaonkar et al., 2011). Previous studies have found that such WM alterations were particularly significant in melancholic MDD (Korgaonkar et al., 2011). Our study is the first that links anhedonia and PTR. Moreover, decreased FA was related with increased anhedonia in gCC. WM abnormalities of gCC were linked with the severity of depression (Chen et al., Sci reports, 2016). This tract is involved in decision making, reward processing (i.e. anhedonia) and emotional regulation (Chen et al., 2016). WM alteration in this area leads to disturbances in cognitive functioning such as memory, executive functions and emotions (Chen et al., 2016). Taken together, our result can lead to the hypothesis that WM alteration in gCC and PTR participates to the severity of depression through one specific phenotype involved in emotion regulation, executive functioning, reward, and decision-making such as anhedonia.

Anxiety and WM integrity

To our knowledge, no study has correlated patient anxiety with white matter integrity in depressed patients. Most of the studies have chosen a categorical approach in comparing MDD with or without anxious comorbidity (Canu et al., 2015; Delaparte et al., 2017). Despite a large sample, no significant connectivity abnormality has been linked with anxiety (Delaparte et al., 2017).

In this study, the phenotypic analysis of anxiety revealed a relationship between anxiety and FA values in genu and splenium of CC, ACR and PTR. Kim et.al. also reported a positive correlation between anxiety and FA values in these three tracts (Kim et al., 2017). Moreover, a meta-analysis has identified that patients suffering from emotional disorders, such as post-traumatic stress disorders had decreased FA in superior corona radiata and anterior thalamic radiation compared with healthy controls (Jenkins et al., 2016).

Psychomotor retardation and WM integrity

Our phenotypic analysis with motor retardation revealed a correlation between increased WRDS scores and reduced FA in body and genu of CC, superior corona radiata and superior striatum. To date, only two studies had explored the relationship between white matter integrity and motor retardation in depression, using a behavioral metric called actimetry. First, a positive association was found between activity level and structural alterations of cortico-cortical white matter in motor pathways, such the connection between the rostral anterior cingulate cortex and pre-Supplementary Motor Area (SMA) and between the dorsolateral prefrontal cortex and pre-SMA in MDD

(Bracht et al., 2012). The authors attributed this result to a relation between these circuits and movement initiation. Then, the second study has pointed out a negative link between FA and left parahippocampal gyrus (Walther et al., 2012), suggesting a plausible link between cerebral alteration in this region and impaired motor planning. Consistent with these results, we exhibited the implication of parahippocampal gyrus and the cingulate. Furthermore, we found that striatal pathway could also play a role in psychomotor retardation. This circuit was also reported in (Bennabi et al., 2013), showing a link between this behavior impairment and dopamine as well as noradrenergic transmission in basal ganglia such as striatum and caudate nucleus.

To sum up, this phenotypic approach pointed out abnormal structural connectivity that have never been demonstrated in depression. One critical findings concern anxiety which have been linked with higher connectivity in areas such as corpus callosum, anterior corona radiata and posterior thalamic radiation whereas categorical approach for depression have shown strictly the opposite findings for posterior thalamic radiation and genu of corpus callosum. These results support the stratification of patients suffering from depression according to these core dimensions. This study allowed a better understanding of critical mechanism involved in pathophysiology of depression and to more reliable imaging biomarkers.

4.3 Limitations

The depression cohort is heterogeneous with regard to demographic and clinical parameters such as age and gender of subjects, age of onset of depression, potentially increasing variability. However, the patient heterogeneity is also a strength of this study because it disrupts coincidental associations.

Another investigation will be needed to determine whether diffusion changes are associated with poorer neurocognitive performance. Further studies should include neurocognitive tests in order to refine clinical phenotype such as executive functioning, memory, attention, information treatment speed, and emotional patterns, and therefore permit a better accuracy of biomarkers.

Another limitation is the use of self-completed questionnaire to assess anhedonia (SHAPS) and psychomotor retardation (WRDS). Furthermore, these latter scales despite their good psychometric properties are not considered as valid scales for dimensional approach such as RDoC.

All patients were under psychotropic medication. There is some evidence that psychotropic treatment could lead to decreased FA in schizophrenic patients after medication (Wang et al., 2013). Another study have pointed out that such confounding factor could open to type II errors (Hafeman et al., 2012). We assumed that this is a limitation but have chosen to control this issue using a medication load score as described above.

Finally, it is important to note that this study cannot be included in a RDoC program. In fact, it does not strictly emphasize the recommendations such as translational perspective (normal to pathologic, from basic science to behavioral science), or the use of reliable and valid measures of fundamental components (Cuthbert et al., 2013). Nevertheless, this study addresses the utility of a deconstruction of actual phenotype of depression from a simple disease-based biomarker to a more specific, symptom-based, severity-related, biomarker.

5 Conclusions

Our study aimed to conduct both categorical and dimensional approach in the study of anatomical connectivity biomarkers in MDD.

First, our results highlight the well-known WM abnormalities in a large cohort of currently depressed patients and compared to controls. The frontolimbic disconnection hypothesis has been replicated as well as large decreased connectivity in widespread brain areas (corpus callosum extending to the inferior fasciculus and posterior thalamic radiation). In addition to previous studies with smaller samples, our results reveal other patterns of increased FA in posterior limb of internal capsule and splenium of corpus callosum.

On the other side, the phenotypic approach has identified some specific patterns related to anxiety, anhedonia and psychomotor retardation – three core symptoms of depression. This latter approach highlighted that within a depressive population, there is a wide variability of anatomic connectivity depending on the severity of each core dimension. This study pointed out that such an approach probably allows more specific and accurate biomarkers than categorical ones, which emphasized widespread abnormalities.

In the future, a dimensional approach could help stratifying different depressive phenotypes, better understanding the pathophysiology characterizing core dimensions, and consequently propose a robust framework for developing targeted therapeutic strategies.

6 Acknowledgments

MRI data acquisition was supported by the Neurinfo MRI research facility from the University of Rennes I. Neurinfo is granted by the European Union (FEDER), the French State, the Brittany Council, Rennes Metropole, Inria, Inserm and the University Hospital of Rennes. This work has been funded by Institut des Neurosciences Cliniques de Rennes (INCR). The authors thank Mr Stéphane Brousse and Mr Jacques Soulabaille for their involvement in the conduct of the study.

References

- Arnone, D., et al., 2013. State-dependent changes in hippocampal grey matter in depression. *Molecular Psychiatry* 18, 1265-1272.
- Assaf, Y., Pasternak, O., 2008. Diffusion tensor imaging (DTI)-based white matter mapping in brain research: a review. *Journal of molecular neuroscience* 34, 51-61.
- Ballmaier, M., et al., 2008. Mapping callosal morphology in early-and late-onset elderly depression: an index of distinct changes in cortical connectivity. *Neuropsychopharmacology* 33, 1528.
- Batail, J., et al., 2017. Apathy and depression: Which clinical specificities? *Personalized Medicine in Psychiatry*.
- Benedetti, F., et al., 2015. White matter microstructure in bipolar disorder is influenced by the serotonin transporter gene polymorphism 5-HTTLPR. *Genes, Brain and Behavior* 14, 238-250.

- Benjamini, Y., Hochberg, Y., 1995. Controlling the false discovery rate: a practical and powerful approach to multiple testing. *Journal of the royal statistical society. Series B (Methodological)*, 289-300.
- Bennabi, D., et al., 2013. Psychomotor retardation in depression: a systematic review of diagnostic, pathophysiologic, and therapeutic implications. *BioMed research international* 2013.
- Bennett, I.J., et al., 2010. Age- related differences in multiple measures of white matter integrity: A diffusion tensor imaging study of healthy aging. *Human brain mapping* 31, 378-390.
- Bracht, T., et al., 2012. Cortico-cortical white matter motor pathway microstructure is related to psychomotor retardation in major depressive disorder. *PloS one* 7, e52238.
- Bracht, T., et al., 2015. A review of white matter microstructure alterations of pathways of the reward circuit in depression. *Journal of affective disorders* 187, 45-53.
- Buchsbaum, M.S., et al., 1998. MRI white matter diffusion anisotropy and PET metabolic rate in schizophrenia. *Neuroreport* 9, 425-430.
- Canu, E., et al., 2015. Brain structural abnormalities in patients with major depression with or without generalized anxiety disorder comorbidity. *Journal of neurology* 262, 1255-1265.
- Carballedo, A., et al., 2012. Reduced fractional anisotropy in the uncinate fasciculus in patients with major depression carrying the met- allele of the Val66Met brain- derived neurotrophic factor genotype. *American Journal of Medical Genetics Part B: Neuropsychiatric Genetics* 159, 537-548.
- Chen, G., et al., 2017. Intrinsic disruption of white matter microarchitecture in first-episode, drug-naïve major depressive disorder: A voxel-based meta-analysis of diffusion tensor imaging. *Progress in Neuro-Psychopharmacology and Biological Psychiatry*.
- Chen, G., et al., 2016. Disorganization of white matter architecture in major depressive disorder: a meta-analysis of diffusion tensor imaging with tract-based spatial statistics. *Scientific reports* 6.
- Commowick, O., et al., 2012a. Automated diffeomorphic registration of anatomical structures with rigid parts: Application to dynamic cervical MRI. *Medical Image Computing and Computer-Assisted Intervention–MICCAI 2012*, 163-170.
- Commowick, O., et al., 2012b. Block-matching strategies for rigid registration of multimodal medical images. *Biomedical Imaging (ISBI), 2012 9th IEEE International Symposium on. IEEE*, pp. 700-703.
- Coupé, P., et al., 2008. An optimized blockwise nonlocal means denoising filter for 3-D magnetic resonance images. *IEEE transactions on medical imaging* 27, 425-441.
- Cuthbert, B.N., Insel, T.R., 2013. Toward the future of psychiatric diagnosis: the seven pillars of RDoC. *BMC medicine* 11, 126.
- de Diego-Adelino, J., et al., 2014. Microstructural white-matter abnormalities associated with treatment resistance, severity and duration of illness in major depression. *Psychological medicine* 44, 1171-1182.
- Delaparte, L., et al., 2017. A comparison of structural connectivity in anxious depression versus non-anxious depression. *Journal of psychiatric research* 89, 38-47.
- Drevets, W.C., 2001. Neuroimaging and neuropathological studies of depression: implications for the cognitive-emotional features of mood disorders. *Current opinion in neurobiology* 11, 240-249.

- Du, X., et al., 2017. Diffusion tensor imaging of the structural integrity of white matter correlates with impulsivity in adolescents with internet gaming disorder. *Brain and behavior* 7, e00753.
- Duffy, S.L., et al., 2014. Cognitive impairment with and without depression history: an analysis of white matter microstructure. *Journal of psychiatry & neuroscience: JPN* 39, 135.
- Dusi, N., et al., 2015. Brain structural effects of antidepressant treatment in major depression. *Current neuropharmacology* 13, 458-465.
- Edition, F., 2013. Diagnostic and statistical manual of mental disorders. Am Psychiatric Assoc.
- Ferrari, A.J., et al., 2013. Burden of depressive disorders by country, sex, age, and year: findings from the global burden of disease study 2010. *PLoS medicine* 10, e1001547.
- Fillard, P., et al., 2007. Clinical DT-MRI estimation, smoothing, and fiber tracking with log-Euclidean metrics. *IEEE transactions on medical imaging* 26, 1472-1482.
- Fitzgerald, P.J., 2013. Gray colored glasses: is major depression partially a sensory perceptual disorder? *Journal of affective disorders* 151, 418-422.
- Freedman, R., et al., 2013. The initial field trials of DSM-5: new blooms and old thorns. Am Psychiatric Assoc.
- Fried, E.I., 2015. Problematic assumptions have slowed down depression research: why symptoms, not syndromes are the way forward. *Frontiers in psychology* 6, 309.
- Gotlib, I.H., Hamilton, J.P., 2008. Neuroimaging and depression: current status and unresolved issues. *Current Directions in Psychological Science* 17, 159-163.
- Hafeman, D.M., et al., 2012. Effects of medication on neuroimaging findings in bipolar disorder: an updated review. *Bipolar disorders* 14, 375-410.
- Han, K.-M., et al., 2014. Cortical thickness, cortical and subcortical volume, and white matter integrity in patients with their first episode of major depression. *Journal of affective disorders* 155, 42-48.
- Hedouin, R., et al., 2017. Block-Matching Distortion Correction of Echo-Planar Images With Opposite Phase Encoding Directions. *IEEE Trans. Med. Imaging* 36, 1106-1115.
- Henderson, S.E., et al., 2013. A preliminary study of white matter in adolescent depression: relationships with illness severity, anhedonia, and irritability. *Frontiers in psychiatry* 4.
- Hermesdorf, M., et al., 2017. Reduced fractional anisotropy in patients with major depressive disorder and associations with vascular stiffness. *NeuroImage: Clinical* 14, 151-155.
- Insel, T., et al., 2010. Research domain criteria (RDoC): toward a new classification framework for research on mental disorders. Am Psychiatric Assoc.
- Jenkins, L.M., et al., 2016. Shared white matter alterations across emotional disorders: A voxel-based meta-analysis of fractional anisotropy. *NeuroImage: Clinical* 12, 1022-1034.
- Jia, Z., et al., 2010. High-field magnetic resonance imaging of suicidality in patients with major depressive disorder. *American Journal of Psychiatry* 167, 1381-1390.
- Keedwell, P.A., et al., 2012. Cingulum white matter in young women at risk of depression: the effect of family history and anhedonia. *Biological psychiatry* 72, 296-302.
- Kim, M.-K., et al., 2017. White matter correlates of anxiety sensitivity in panic disorder. *Journal of affective disorders* 207, 148-156.

- Korgaonkar, M.S., et al., 2011. Loss of white matter integrity in major depressive disorder: Evidence using tract- based spatial statistical analysis of diffusion tensor imaging. *Human brain mapping* 32, 2161-2171.
- Lecrubier, Y., et al., 1997. The Mini International Neuropsychiatric Interview (MINI). A short diagnostic structured interview: reliability and validity according to the CIDI. *European psychiatry* 12, 224-231.
- Liao, Y., et al., 2013. Is depression a disconnection syndrome? Meta-analysis of diffusion tensor imaging studies in patients with MDD. *Journal of psychiatry & neuroscience: JPN* 38, 49.
- Magioncalda, P., et al., 2016. Patterns of microstructural white matter abnormalities and their impact on cognitive dysfunction in the various phases of type I bipolar disorder. *Journal of affective disorders* 193, 39-50.
- Mole, J.P., et al., 2016. Increased fractional anisotropy in the motor tracts of Parkinson's disease suggests compensatory neuroplasticity or selective neurodegeneration. *European radiology* 26, 3327-3335.
- Montgomery, S.A., Asberg, M., 1979. A new depression scale designed to be sensitive to change. *The British journal of psychiatry* 134, 382-389.
- Murphy, M.L., Frodl, T., 2011. Meta-analysis of diffusion tensor imaging studies shows altered fractional anisotropy occurring in distinct brain areas in association with depression. *Biology of mood & anxiety disorders* 1, 3.
- NIMH, 2008. National Institute of Mental Health. The National Institute of Mental Health strategic plan., pp. (NIH Publication No. 08-6368).
- Olvet, D.M., et al., 2016. A comprehensive examination of white matter tracts and connectometry in major depressive disorder. *Depression and anxiety* 33, 56-65.
- Ota, M., et al., 2015. White matter abnormalities in major depressive disorder with melancholic and atypical features: A diffusion tensor imaging study. *Psychiatry and clinical neurosciences* 69, 360-368.
- Ourselin, S., et al., 2000. Block matching: A general framework to improve robustness of rigid registration of medical images. *MICCAI*. Springer, pp. 557-566.
- Reppermund, S., et al., 2014. White matter integrity and late-life depression in community-dwelling individuals: diffusion tensor imaging study using tract-based spatial statistics. *The British journal of psychiatry* 205, 315-320.
- Sacchet, M.D., et al., 2014. Structural abnormality of the corticospinal tract in major depressive disorder. *Biology of mood & anxiety disorders* 4, 8.
- Sackeim, H.A., 2001. The definition and meaning of treatment-resistant depression. *The Journal of clinical psychiatry*.
- Schermuly, I., et al., 2010. Association between cingulum bundle structure and cognitive performance: an observational study in major depression. *European psychiatry* 25, 355-360.
- Sexton, C.E., et al., 2009. A systematic review of diffusion tensor imaging studies in affective disorders. *Biological psychiatry* 66, 814-823.
- Smith, K., 2014. Mental health: a world of depression. *Nature News* 515, 180.

- Snaith, R., et al., 1995. A scale for the assessment of hedonic tone the Snaith-Hamilton Pleasure Scale. *The British journal of psychiatry* 167, 99-103.
- Spielberger, C.D., et al., 1970. Manual for the state-trait anxiety inventory.
- Taylor, W.D., et al., 2004. Diffusion tensor imaging: background, potential, and utility in psychiatric research. *Biological psychiatry* 55, 201-207.
- Taylor, W.D., et al., 2014. Cingulum bundle white matter lesions influence antidepressant response in late-life depression: a pilot study. *Journal of affective disorders* 162, 8-11.
- Walther, S., et al., 2012. Frontal white matter integrity is related to psychomotor retardation in major depression. *Neurobiology of disease* 47, 13-19.
- Wang, Q., et al., 2013. White-matter microstructure in previously drug-naïve patients with schizophrenia after 6 weeks of treatment. *Psychological medicine* 43, 2301-2309.
- Westin, C.-F., et al., 2002. Processing and visualization for diffusion tensor MRI. *Medical image analysis* 6, 93-108.
- Widlöcher, D.J., 1983. Psychomotor retardation: clinical, theoretical, and psychometric aspects. *Psychiatric Clinics of North America*.
- Yang, X.-h., et al., 2017. White matter microstructural abnormalities and their association with anticipatory anhedonia in depression. *Psychiatry Research: Neuroimaging* 264, 29-34.
- Young, J.J., et al., 2016. Is there progress? An overview of selecting biomarker candidates for major depressive disorder. *Frontiers in psychiatry* 7, 72.
- Zhang, A., et al., 2012. Quantitative tract-specific measures of uncinate and cingulum in major depression using diffusion tensor imaging. *Neuropsychopharmacology* 37, 959.
- Zou, K., et al., 2010. Changes of brain morphometry in first-episode, drug-naïve, non-late-life adult patients with major depression: an optimized voxel-based morphometry study. *Biological psychiatry* 67, 186-188.
- Zou, K., et al., 2008. Alterations of white matter integrity in adults with major depressive disorder: a magnetic resonance imaging study. *Journal of psychiatry & neuroscience: JPN* 33, 525.