



# Biocompatibility, resorption and biofunctionality of a new synthetic biodegradable membrane for guided bone regeneration

Alain Hoornaert, Cyril D'arros, Marie-Françoise Heymann, Pierre Layrolle

## ► To cite this version:

Alain Hoornaert, Cyril D'arros, Marie-Françoise Heymann, Pierre Layrolle. Biocompatibility, resorption and biofunctionality of a new synthetic biodegradable membrane for guided bone regeneration. Biomedical Materials, 2016, 11 (4), pp.045012. 10.1088/1748-6041/11/4/045012 . inserm-01702004

**HAL Id: inserm-01702004**

**<https://inserm.hal.science/inserm-01702004>**

Submitted on 6 Feb 2018

**HAL** is a multi-disciplinary open access archive for the deposit and dissemination of scientific research documents, whether they are published or not. The documents may come from teaching and research institutions in France or abroad, or from public or private research centers.

L'archive ouverte pluridisciplinaire **HAL**, est destinée au dépôt et à la diffusion de documents scientifiques de niveau recherche, publiés ou non, émanant des établissements d'enseignement et de recherche français ou étrangers, des laboratoires publics ou privés.

PAPER • OPEN ACCESS

# Biocompatibility, resorption and biofunctionality of a new synthetic biodegradable membrane for guided bone regeneration

To cite this article: Alain Hoornaert *et al* 2016 *Biomed. Mater.* **11** 045012

View the [article online](#) for updates and enhancements.

## Related content

- [Evaluation of 3D printed PCL/PLGA/-TCP versus collagen membranes for guided bone regeneration in a beagle implant model](#)  
J-Y Won, C-Y Park, J-H Bae *et al.*
- [In vitro and in vivo evaluations of a novel post-electrospinning treatment to improve the fibrous structure of chitosan membranes for guided bone regeneration](#)  
Hengjie Su, Kwei-Yu Liu, Anastasios Karydis *et al.*
- [Tissue reaction to bilayered collagen](#)  
Shahram Ghanaati, Markus Schlee, Matthew J Webber *et al.*

## Recent citations

- [Development of layered PLGA membranes for periodontal tissue regeneration](#)  
Itsumi Yoshimoto *et al*
- [Sequential controlled-released dual-drug loaded scaffold for guided bone regeneration in a rat fenestration defect model](#)  
Zhenzhao Guo *et al*

## Biomedical Materials

## OPEN ACCESS



CrossMark

## RECEIVED

17 January 2016

## REVISED

29 May 2016

## ACCEPTED FOR PUBLICATION

27 June 2016

## PUBLISHED

10 August 2016

Original content from this work may be used under the terms of the Creative Commons Attribution 3.0 licence.

Any further distribution of this work must maintain attribution to the author(s) and the title of the work, journal citation and DOI.



## PAPER

## Biocompatibility, resorption and biofunctionality of a new synthetic biodegradable membrane for guided bone regeneration

Alain Hoornaert<sup>1</sup>, Cyril d'Arros<sup>2</sup>, Marie-Francoise Heymann<sup>3</sup> and Pierre Layrolle<sup>3,4</sup><sup>1</sup> CHU Nantes, Faculty of Dental Surgery, Nantes, France<sup>2</sup> Biomedical Tissues SAS, Nantes, France<sup>3</sup> Inserm, U957, Laboratory of Pathophysiology of Bone Resorption and Primary bone Tumor Therapy, Faculty of Medicine, University of Nantes, Nantes, France<sup>4</sup> Director of Research, Inserm U957, Faculty of Medicine, 1 rue Gaston Veil, 44035 Nantes, FranceE-mail: [pierre.layrolle@inserm.fr](mailto:pierre.layrolle@inserm.fr)**Keywords:** guided bone regeneration, membranes, poly-lactic-glycolic acid, collagen, biocompatibility, biodegradation

## Abstract

Membranes for guided bone regeneration (GBR) were prepared from the synthetic biodegradable polymer poly-D,L-lactic/glycolic acid (PLGA). This GBR membrane has a bi-layered structure with a dense film to prevent gingival fibroblast ingrowth and ensure mechanical function, and a micro-fibrous layer to support colonization by osteogenic cells and promote bone regeneration. Hydrolysis and biodegradation were both studied *in vitro* through soaking in phosphate buffered saline (PBS) and *in vivo* by implantation in the subcutis of rats for 4, 8, 16, 26, 48 and 52 weeks. Histology revealed an excellent colonization of the micro-fibrous layer by cells with a minimal inflammatory reaction during resorption. GBR using the synthetic PLGA membrane was evaluated on critical-size calvaria defects in rats for 4 and 8 weeks. Radiographs, micro-computed tomography and histology showed bone regeneration with the PLGA membrane, while the defects covered with a collagen membrane showed a limited amount of mineralized bone, similar to that of the defect left empty. The biofunctionality of the PLGA membranes was also compared to collagen membranes in mandible defects in rabbits, associated or not with beta-tricalcium phosphate granules. This study revealed that the bi-layered synthetic membrane made of PLGA was safer, more biocompatible, and had a greater controlled resorption rate and bone regeneration capacity than collagen membranes. This new PLGA membrane could be used in pre-implantology and peri-odontology surgery.

## Introduction

Membranes for guided bone regeneration (GBR) are part of the bone augmentation process prior to dental implants. The GBR membranes are used as a physical barrier to prevent gingival tissue ingrowth, as well as for maintaining a bone regeneration space [1]. For instance, alveolar sockets are filled with calcium phosphate biomaterials and covered by a GBR membrane until dental implants are inserted 16–24 weeks after tooth extraction [2]. The GBR membrane should maintain its physical integrity for a similar delay. The concept of guided tissue regeneration (GTR) is used frequently to regenerate periodontal defects. Membranes are used to stop the fast growing connective tissues and to allow time for periodontal ligament cementum and bone regeneration. In periodontology, the membrane needs to guide tissue regeneration for a minimum of 4–6 weeks [3–6].

Most GBR membranes are made of animal-derived collagen (i.e. porcine, bovine), which poses problems with regards to safety and uncontrolled resorption rates. These collagen membranes are also difficult to handle when wet during surgery because they lack rigidity and adaptability to anatomy. Certain studies have reported that these collagen membranes have unfavourable mechanical properties [7] and inadequate barrier stability over time [8–10]. The biodegradation of collagen membranes in the human body is variable, depending on the tissue of origin and chemical cross-linking. As a result, these membranes do not maintain their mechanical integrity over long periods and often collapse over bone defects. In addition, their permeability to cells and tissues cannot be controlled as collagen membranes are prepared from different animal tissues, with different structures and porosities (i.e. porcine skin, bovine pericardium).

There are a few dental membranes made of synthetic non-degradable and biodegradable materials. Non-resorbable membranes made of poly-tetrafluoroethylene (PTFE) or titanium mesh are efficient for maintaining space for bone augmentation [11, 12]. However, they are often exposed and become infected requiring a second surgery to remove them before inserting the dental implants. Synthetic resorbable membranes overcome these disadvantages but do not give results of the same quality, especially with regards to marginal bone gain [13, 14]. The cause of this discrepancy comes from the membrane's capacity to maintain space in the defect. The current generation of GBR membranes is still associated with major disadvantages related to poor clinical manageability [15], poor control of the rate of degradation [16], a lack of space-maintaining properties [15, 17], and poor understanding of the biological mechanisms governing bone regeneration [18]. The ideal bone regeneration membrane should therefore be synthetic, biocompatible, easy to handle during surgery and resorbable, but it should also maintain its physical barrier function for 16–24 weeks. Finally, the ideal membrane should mimic the structure of collagen to allow cell colonization and thus guide bone tissue healing.

In dental and maxillofacial surgery, membranes are often used to cover defects filled with synthetic calcium phosphate bone substitutes such as beta-tricalcium phosphate ( $\beta$ -TCP), hydroxyapatite (HA) or biphasic calcium phosphate in the form of granules [19–21]. These synthetic bone fillers are osteoconductive and favour bone regeneration in the defect. The membrane covers the biomaterial granules and ensures a physical barrier towards the gingival tissue for optimal bone regeneration of the defect [22].

In this context, the aim of this study was to produce a new synthetic biodegradable membrane and to evaluate its biocompatibility, resorption and biofunctionality in different animal models. The membrane is made of poly-D,L-lactic/glycolic acid (PLGA), a well-known biodegradable polymer widely used in other medical applications (e.g. resorbable sutures, surgical meshes) [23, 24]. This membrane has a bi-layer structure composed of a dense layer bound to a micro-fibrous layer. It is expected that the dense film will prevent fibroblastic cell migration from conjunctive tissues and provide enough rigidity to maintain space in the defect. The micro-fibrous layer mimics the structure of collagen, favouring cell migration and tissue regeneration. Since a porcine derived collagen membrane (COLL) completely degraded within 8 weeks in a pilot experiment, the biocompatibility and resorption of the synthetic biodegradable PLGA membrane were compared to commercially available resorbable dental membranes made of poly-D,L-lactic acid (PLA) in the subcutis of rats. The biofunctionality in GBR of the synthetic biodegradable PLGA membrane was compared with the porcine derived collagen membrane (COLL) on the calvaria of rats and mandibular defects in rabbits, filled or not filled with  $\beta$ -TCP granules.

## Materials and methods

### Preparation of the PLGA membrane

Medical grade PLGA copolymer (85/15 molar ratio, inherent viscosity midpoint of  $3.1 \text{ dl g}^{-1}$ ) was purchased from Corbion Purac (ref. Purasorb PLG 8531, Corbion Purac BV, Gorinchem, The Netherlands). The PLGA dental membrane (Tisseos<sup>®</sup>, Biomedical Tissues SAS, Nantes, France) was manufactured using a proprietary process in an ISO 6 clean room in respect of the ISO 13485 certification for medical devices. Briefly, the polymer was dissolved in chloroform and a dense layer was prepared by film casting. A micro-fibrous layer was then prepared by jet-spraying with compressed air. After drying overnight, the bi-layered membrane was cut into  $15 \times 25 \text{ mm}$  or  $20 \times 30 \text{ mm}$  pieces, packaged in double sealed pouches and sterilized with gamma irradiation at 25 kGy (Ionisos SA, Dagneux, France).

### Other biomaterials

A commercially available PLA dental membrane (PLA; Epiguide<sup>®</sup>, Kensey Nash Corp., Exton, USA) was purchased for comparison of the biocompatibility and resorption rates in the subcutis of rats. A cross-linked porcine collagen membrane (COLL; CovaMax<sup>®</sup>, Biotech Dental, Salon-de-Provence, France) and  $\beta$ -TCP granules (TCP; 0.5–1 mm, Crossbone<sup>®</sup>, Biotech Dental) were used in bio-functionality models of bone regeneration of calvaria defects in rats and mandible defects in rabbits.

### Characterization of the PLGA membranes

The microstructure of the membrane was investigated by using a scanning electron microscope (SEM; Hitachi TM3000 Tabletop Microscope, Tokyo, Japan). Thickness was measured with a non-contact laser device (Keyence LK-G87; Keyence, Itasca, IL, USA) at several locations ( $n = 10$ ). The mechanical properties of the PLGA membrane were measured using a mechanical test bench (FAVIMAT Fiber Test) equipped with holders of 7.5 mm in width at a distance of 10 mm and a load cell of 3200 cN. A pre-load of 0.5 cN and a crosshead speed of  $50 \text{ mm min}^{-1}$  were applied. The tensile strength, elasticity and maximum tear resistance values were determined ( $n = 5$ ). The resistance to suturing was measured according to the NF 94-801 2007 standard. A 4/0 suture (Prolene, Ethicon) was passed through the membrane, 5 mm away from the side. The membrane was fixed with a 15 mm wide holder while the suture was fixed on the load cell at a distance of 20 mm. A crosshead speed of  $100 \text{ mm min}^{-1}$  was applied. The maximum load at rupture was recorded ( $n = 5$ ).

### Hydrolysis of the PLGA membrane

The degradation of the PLGA membrane was first studied *in vitro*. After weighing, membranes measuring  $20 \times 30 \text{ mm}$  and  $400 \mu\text{m}$  thick were immersed in closed glass vials containing 17 ml of phosphate buffer saline (PBS; Lonza) in a thermoregulated oven at  $37^\circ\text{C}$ . After 2,

4, 12, 26, 38 and 48 weeks, the pH was measured and the solution was passed through cellulose filters. After drying, a digital calliper and laser device were used to measure the dimensions and thickness of the membranes. The remaining membranes were weighed to determine the weight lost during hydrolysis and dissolved in pure chloroform at a concentration of  $0.1 \text{ g dl}^{-1}$ . The intrinsic viscosity was measured using an Ubbelohde tube in a thermoregulated water bath at  $25 \pm 1^\circ\text{C}$ . For each time point  $n = 4$  membranes were used.

### Animal experimentation

The surgery protocols were conducted in accordance with European regulations on animal welfare and complied with the guidelines of the Animal Care and Use Committee of the University of Nantes, France. The animals were housed in cages with pelleted food and water in a temperature-controlled room with a 12 h artificial day/night cycle at the experimental therapeutic unit of the Faculty of Medicine. They were acclimatised for at least 2 weeks prior to surgery.

### Subcutis implantation in rats

The biocompatibility and resorption of the membranes were assessed in the subcutis of rats in accordance with the ISO 10993-6 standard [25]. A pilot experiment of subcutis implantation of the porcine derived collagen (COLL) membrane indicated its complete resorption within 8 weeks. For these reasons, the study was conducted with another commercially available dental membrane, PLA, which has a comparable degradation rate than the experimental PLGA membrane. Forty albino rats of the Wistar strain (male, 7 weeks old, body weight 125–150 g) were purchased from a certified stockbreeder (Janvier Labs, Le Genest Saint Isle, France). The rats were placed under general anaesthesia by inhalation of 1.5% isoflurane (Forane®, Baxter Healthcare Corp. USA). Pre- and post-operative analgesia was provided by intramuscular injection of buprenorphine ( $30 \mu\text{l kg}^{-1}$ , 2 times  $\text{d}^{-1}$  for 3 d; Buprécare, Axience, Pantin, France). The animals were identified with numbered ear tags. An area approximately 8 cm in length and 4 cm in width was depilated on the back of each rat using an electric shaver. After disinfection with povidone iodine 10% solution (Betadine®), a sterile field was placed on the back of the animal. A skin incision was made para median, along the vertebral column, followed by separation of two unconnected subcutaneous pouches by means of blunt dissection. Each animal received a 10 mm diameter PLGA (Tisseos) and PLA (Epi-Guide) disc in two separate subcutis pouches. The PLGA disc was implanted on the right side with the micro-fibrous layer facing the muscle, and the PLA disc was placed on the left. The skin was sutured using non-absorbable 4/0 sutures (Peters Surgicals, Bobigny, France). After 4, 8, 16, 26 and 52 weeks of implantation, the animals were euthanized by prolonged inhalation of carbon dioxide gas. Immediately after euthanasia, the

back of the animal was shaved and a wide skin incision was made to expose the subcutis-implanted membranes. The sites were examined and photographed with a graduated ruler in order to determine the diameter of the membrane remaining. After dissection, samples isolating each membrane were fixed in 10 volumes of neutral 4% formaldehyde (MicromMicrotech, France) and stored at  $4^\circ\text{C}$  for 2 d.

### Bone regeneration in critical-sized calvaria defects in rats

The capacity of the membranes to guide the regeneration of a critical-sized bone defect was assessed on the calvaria of rats. Three experimental groups (defect left EMPTY, PLGA, and COLL membranes) and two time points (4 and 8 weeks) were designed. For each experimental group,  $n = 6$  samples were used giving a total of 36 animals. The rats (Wistar, male, 7 weeks old, body weight 125–150 g, Janvier Labs) were operated under anaesthesia by inhalation of 1.5% isoflurane. Analgesic (Buprenorphine,  $30 \mu\text{l kg}^{-1}$ , 2 times  $\text{d}^{-1}$  for 3 d) was injected before and after surgery, as described in the previous section. The head was shaved, disinfected with iodine solution and covered with a sterile fenestrated sheet. Local anaesthesia was performed by injection of adrenaline articaine hydrochloride (0.5 ml, Alphacaine SP, Dentsply). A 1.5 cm skin incision was made and the skull was exposed by blunt dissection. The periosteum was detached from the calvaria bone. A critical-sized defect of 5 mm in diameter was carefully created on the calvaria bone using a trephine mounted on a dental micro-motor (Nouvag NM3000, Switzerland). Constant saline irrigation was maintained during drilling. The disc of calvaria bone was carefully removed. The PLGA membrane was cut into an 8 mm diameter disc and placed on the calvaria defect with the micro-fibrous layer facing the bone, while the dense layer was against the subcutis tissue. The skin incision was closed with non-resorbable 4/0 sutures. The surgical procedure was repeated with a commercially available collagen membrane (COLL) used as the control. Calvaria defects that were left empty served as negative controls. Following surgery, the animals were observed daily, and body weight was determined every week. After 4 and 8 weeks, the rats were euthanized by inhalation of an overdose of carbon dioxide gas. The calvarias were dissected and cut using a circular diamond saw mounted on a dental hand piece (Nouvag NM3000). The explants were observed for signs of tissue necrosis, inflammation or infection. The samples were fixed in buffered 4% formaldehyde solution for 2 d at  $4^\circ\text{C}$  prior to histology. Radiographs were taken using a digital x-ray microradiography apparatus (Faxitron MX-20). Semi quantitative scoring [26] was used to assess bone regeneration in accordance with a previously published method. Briefly, a score of 0 corresponded to no bone formation within the defect, while a score of 4 was for bone that bridged the entire span of the defect.



### Bone regeneration in critical-sized mandibular defects in rabbits

This study was conducted to evaluate the GBR of a PLGA membrane covering a mandibular bone defect [27]. The defect was left empty or filled with TCP granules. The bone regeneration was compared with a dental membrane made of porcine collagen (COLL). A total of four groups were tested with two possible sites of implantation in the rabbit mandible with a healing time of 8 weeks. Given a sample size of  $n = 6/\text{group}$  and bilateral implantation, 12 New Zealand White rabbits were used in this study (adult females, average body weight of 3.2–3.5 kg). The animals were purchased from a certified breeder (Hypharm, Roussay, France) and acclimatized in individual cages at the Experimental Unit. For analgesia, 1 h before and for 2 d after the surgery, the rabbits received buprenorphine ( $0.05 \text{ mg kg}^{-1}$ , s.c. 12 hourly). General anaesthesia was obtained by injection of a mixture of xylazine/ketamine (intramuscular, Imalgene  $0.35 \text{ ml kg}^{-1}$ ; Rompun  $2\% 0.25 \text{ ml kg}^{-1}$ ). Prophylactic antibiotherapy was administered by injection of Marbofloxacin (i.m.  $2 \text{ mg kg}^{-1}$  for 3 d, Marbocyl 10% Vétoquinol). The mandible was shaved and disinfected with povidone iodine solution. The sites were covered with a sterile adhesive fenestrated sheet. Local anaesthesia was administered by injection of adrenaline hypochloride ( $0.5 \text{ ml}$ , Alphacaine SP, Dentsply). A 2 cm cutaneous incision was made on the ramus, and the mandibular bone was exposed by smooth dissection. A bone defect with the dimensions  $10 \times 5 \times 5 \text{ mm}$  was created under saline irrigation using an oscillating saw mounted on a dental micro-motor (Nouvag NM3000) on both side of the mandible. The defects were filled with TCP granules or not, and covered with the bi-layered PLGA membrane, with the micro-fibrous layer facing the bone defect and the dense film facing out. The PLGA membrane was placed on the right side of the mandible. The skin tissue was closed with absorbable 4/0 braided sutures (4/0 Vicryl<sup>®</sup>, Ethicon, USA). The collagen membrane was implanted on the left side with or without TCP granules. The animals were euthanized 8 weeks after the surgery under general anaesthesia by intra-cardiac injection of an overdose of sodium pentobarbital ( $1 \text{ ml}$  Dolethal<sup>®</sup>, Vetoquinol France). A broad dissection of the mandible was carried out and both upper rami were cut with a diamond saw. The specimens were immediately fixed in 10 volumes of buffered 4% formaldehyde solution and stored at  $4^\circ\text{C}$ .

### Micro-computed tomography


The mandibles were scanned by micro-computed tomography (microCT; Skyscan 1076, Belgium). The x-ray source was operated at a voltage of 50 kV and a current of  $200 \mu\text{A}$ . The detector was rotated to  $180^\circ$  in  $0.6^\circ$  steps with an exposure time of 1.7 s, giving a spatial resolution of  $18 \mu\text{m}$  per voxel. The 3D reconstructions were made using CTVOX software.

### Histology and histomorphometry

Once fixed, the rats' subcutis and calvaria samples were processed for decalcified paraffin histology. The samples were placed in cassettes and decalcified in 4.13% EDTA/0.2% PFA in PBS pH 7.4 for 96 h at  $50^\circ\text{C}$  using an automated microwave decalcifying apparatus (KOS Histostation, Milestone Med. Corp. Kalamazoo, MI, USA). The samples were then rinsed with water and dehydrated in ascending series of 80, 95 and 100% ethanol baths, and finally in butanol for 30 min (Automated dehydration station, Microm Microtech, France). The samples were then immersed in liquid paraffin at  $56^\circ\text{C}$  (Histowax) and embedded at  $-16^\circ\text{C}$ . Blocks were cut by using a standard microtome (Leica RM2250). Thin histology sections ( $3\text{--}5 \mu\text{m}$  thick) were made perpendicular to the plane of the skin for the subcutis implants, and in the middle of the calvaria defects. The sections were mounted on microscopy glass slides and stained with hematoxylin/eosin or Masson's trichrome using an automated coloration station (Microm Microtech).

Non-decalcified histology with poly-methylmethacrylate (PMMA) resin embedding was used for the mandible defects in rabbits. The samples were dehydrated in ascending concentrations of ethanol and in acetone for 24 h each. They were then impregnated with methyl methacrylate for 48 h at  $-20^\circ\text{C}$ . Finally, they were embedded in PMMA resin in the presence of an initiator and propagator for radical polymerization at  $4^\circ\text{C}$  for 4 d. The samples were cut transversally into two parts using a circular diamond saw (Leica SP1600, Solms, Germany). One part was used to produce  $30 \mu\text{m}$  stained sections and descriptive analyses of the bone defect. The section was mounted on a plexiglass microscope slide with UV light epoxy curing resin, and polished with SiC papers using grinding/polishing equipment (Meatserv 250, Buehler, Dusseldorf, Germany). After 1 min etching with hydrochloric acid ethanol (2 ml HCl 37 wt.%/98 ml absolute ethanol), the sections were stained by soaking in 1% toluidine blue for 90 s, rinsing with demi- $\text{H}_2\text{O}$  and in 0.3% basic fushin for 60 s. Contiguous SEM images (Hitachi TM3000) of the block were taken at  $50\times$  magnifications and assembled. The resulting image allowed the quantitative measurement of the newly formed mineralized bone and the quantity of biomaterial based on the grey intensity in the defect that defined the region of interest (ROI). Image analysis was carried out using the freeware ImageJ (National Institutes of Health, Bethesda, MD, USA). The newly formed bone surface was expressed as a percentage of the ROI.

The stained slices were scanned (NanoZoomer 2.0RS, Hamamatsu Corp. Japan) and observed with the virtual microscope (NDP view software, Hamamatsu Corp). Tissues and cells in the different membranes were identified and scored by M F Heymann, a medical doctor specializing in anatomic pathology. Tissue necrosis, neovascularization, fibrosis and fat tissue infiltration were scored according to the 10993-6 standard



**Figure 1.** Photographs of the synthetic bi-layered PLGA dental membrane. (A) Macro-photography showing the micro-fibres and dense layers, (B) SEM of the cross-section showing the thin dense layer (arrows) and thick layer of micro-fibres, (C) SEM of the surface of the dense layer and (D) SEM of the micro-fibre layer.

[26]. The number of granulocytes, lymphocytes, plasmocytes, macrophages and giant cells were numbered in the membranes at a magnification of  $\times 400$ . A score of 0 was given in the absence of cells and score 4 corresponded to a high number of cells gathered in wide-ranging areas

#### Statistical analysis

Quantitative data were presented as the mean  $\pm$  standard deviation. Analyses of variances followed by least significant difference post hoc assessments were applied to compare the groups using GraphPad Prism 5.0 software (GraphPad Software Inc., La Jolla, USA). Differences were considered significant if their  $p$ -values were less than 5% ( $*p < 0.05$ ).

## Results

### Structure and characteristics of the PLGA membrane

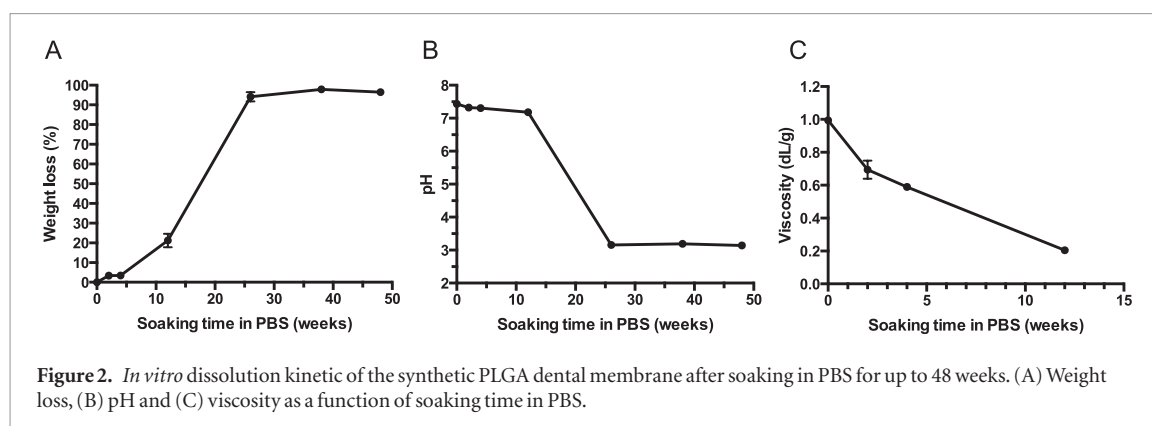
The synthetic PLGA membrane is shown in figure 1. The membrane exhibited two layers, a micro-fibrous mat side and a dense glossy side (figure 1(A)). The membrane was designed with a dense layer to prevent epithelial tissue ingrowth, and a micro-fibrous layer to guide bone regeneration. These two layers are clearly visible on the cross-section observed by SEM (figure 1(B)). The thin and dense film appeared in contact with a thick and porous layer made of micro-fibres. The overall thickness of the membrane was around  $400\ \mu\text{m}$  while the thickness of the dense layer was approximately  $25\ \mu\text{m}$ . A flat, smooth, non-porous surface with no evidence of surface irregularity was observed on the dense side (figure 1(C)). In contrast,

the micro-fibrous layer exhibited a highly porous structure with interlaced non-woven fibres. The diameters of the fibres ranged from  $0.2$  to  $2\ \mu\text{m}$  (figure 1(D)). The membranes had a weight of  $50 \pm 5\ \text{mg}$  on average for a  $20 \times 30\ \text{mm}$  size, corresponding to a basis weight of approximately  $80\ \text{g m}^{-2}$ . This basis weight was comparable to standard cellulose paper.

The mechanical properties of the PLGA membrane were measured to ensure both their resistance to surgical handling, and their compatibility with suturing. The ultimate stress and strain were determined as  $6.7 \pm 2.6\ \text{N}$  and  $7.6 \pm 4.0\%$ , respectively. The maximum resistance to initial tear was  $47 \pm 5\ \text{cN}$ . The maximum resistance to suture traction was  $2.83 \pm 1.09\ \text{N}$ .

### *In vitro* hydrolysis of the PLGA membrane

The hydrolysis of the PLGA membrane was studied in an aqueous physiological environment (figure 2). After 2 weeks in PBS, the PLGA membrane had a similar shape with a bi-layered structure. After 4 weeks, the PLGA membranes had bent and swelled, but maintained their physical integrity with a bi-layered structure. After 12 weeks of hydrolysis, the membrane remained in one piece, but exhibited significant bending and swelling. No membrane could be found after 26 weeks of hydrolysis in PBS. As shown in figure 2, there was a good correlation between the weight loss of the PLGA membranes and the pH variations in the PBS solution. The weight loss was not significant in the first 4 weeks but began to increase at 12 weeks, reaching a plateau of around 100% at 26 weeks. Similarly, the pH remained stable, at around 7.4, for the first 12 weeks of hydrolysis in PBS. The pH then dropped to 3.2 at 26 weeks and remained stable at this value until 48 weeks. Intrinsic



viscosity was also measured, as it is a good indication of hydrolysis of the polymer chains. The viscosity of the PLGA polymer decreased rapidly as a function of soaking time in PBS. After only 4 and 8 weeks, the viscosity had reduced two- and five-fold respectively, indicating a significant breakdown in the polymer chains. Overall, these results indicated that the PLGA membrane had completely degraded in approximately 26 weeks *in vitro*.

### Subcutis implantation in rats

All rats recovered with no complications and macroscopic examination showed a good wound closure without signs of inflammation or infection. After 4 and 8 weeks of subcutis implantation, both the PLA and PLGA membranes were clearly visible and encapsulated within a vascularized fibrous tissue. Both types of disc had already reduced in diameter. After 16 weeks, both the PLA and PLGA membranes appeared to be fragmented. After 52 weeks, the PLGA membrane could not be found while the PLA membrane discs had greatly reduced in diameter.

Histology images of the PLA and PLGA membranes are shown in figure 3. After 4 weeks, fibrosis was observed around both types of implant. The fibrous capsule was narrow, with a maximum of 1–4 cell layers around both types of membrane. No fat tissue infiltration was observed in either case. Neovascularization was focalized with a maximum of 4–7 capillaries. In the PLA membrane, there was little cell colonization, particularly after a short implantation time. In contrast, many cells had infiltrated the polymer micro-fibres of the PLGA membrane at as early as 4 weeks. The dense film (white) was visible up to 8 weeks but appeared highly distorted and fragmented. The polymer micro-fibres of the PLGA membranes appeared in white bundles and loose strands. At 8 weeks, many macrophage-like cells and multi-nucleated giant cells have infiltrated both types of polymer membrane (figure 4). Collagen (green) was also present between the PLGA micro-fibres. After 16 weeks, the diameters of the PLGA polymer micro-fibres increased sharply because of hydrolysis and swelling. The PLA membrane appeared fragmented at 16 weeks with the presence of collagen between the fragments. At 26 weeks, the PLGA membrane was almost completely degraded with only

a few polymer micro-fibres visible. As shown in figure 4, these remaining PLGA fibres were surrounded by macrophages and multi-nucleated giant cells, embedded in collagen fibrous tissue. At 26 weeks, the PLA membrane appeared highly fragmented and similarly invaded by macrophages and multi-nucleated cells, as well as by collagenous fibrous tissue.

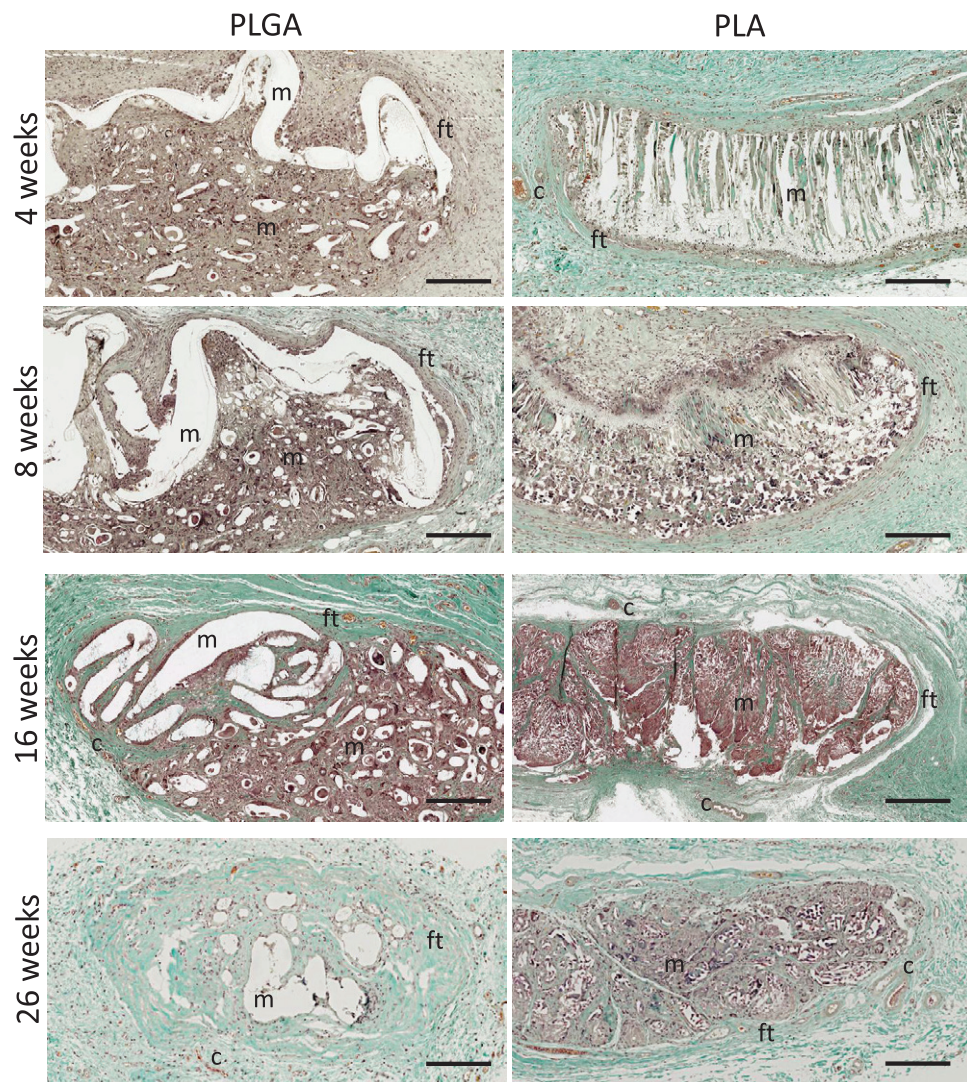
The reduction in the diameter of both membranes was plotted as a function of the implantation time (figure 5(A)). Both types of membrane considerably reduced in diameter after 4 weeks. For the PLA membrane, the diameter decreased gradually over 52 weeks. For the PLGA membrane, the reduction in diameter was more rapid, and only four out of six implanted PLGA membranes could be retrieved at 26 weeks. A good correlation was therefore found between *in vitro* hydrolysis and *in vivo* degradation of the PLGA membranes.

Counting of the macrophages and multi-nucleated giant cells indicated less of these cells in contact with the PLGA membranes than with the PLA membranes (figures 5(B) and (C)). These cellular elements were characteristic of local inflammation due to the presence of a foreign body reaction. Counts of the other cells, such as granulocytes, plasmocytes and lymphocytes, as well as tissue necrosis, neovascularization and fibrosis always scored less than 2 for both membranes (data not shown). Both types of membrane can therefore be considered to be biocompatible.

### GBR of the PLGA membrane on calvaria defects in rats

All the animals recovered from surgery without complications and gained weight normally. As shown in the radiographs in figure 6, the 5 mm diameter calvaria defect had a critical size, as only marginal bone healing was observed at 4 and 8 weeks. When a collagen membrane (COLL) was applied to the defect, bone healing was observed on the edge of the circular defect. Centripetal bone growth and, in some cases, partial bone bridging of defects were observed in the case of the synthetic PLGA membrane. Semi-quantitative scoring corroborated these observations with an increase of GBR using the synthetic PLGA membrane in comparison to the defects left empty (table 1). However, the difference was not statistically significant.



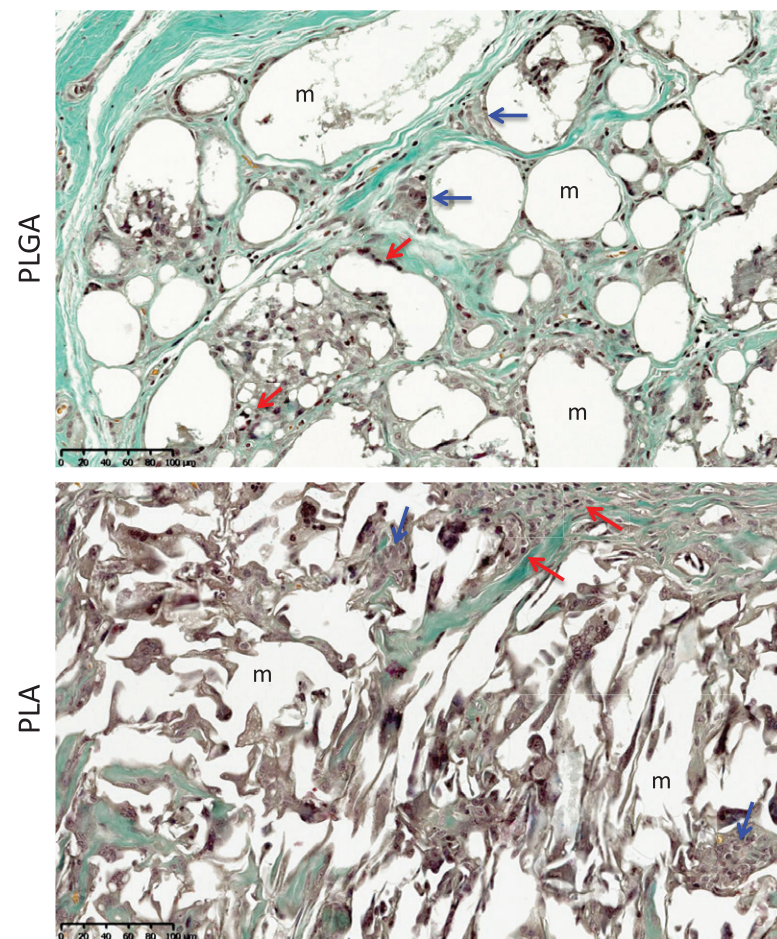


**Figure 3.** Histology of subcutis implants in rats of the synthetic PLGA bi-layered membrane and a porous PLA dental membrane after 4, 8, 16 and 26 weeks. Both membranes (*m*) are surrounded by fibrous tissue (*ft*) with capillary blood vessels (*c*) (Masson Trichrome staining; original magnification  $\times 100$ ; bar = 250  $\mu\text{m}$ ).

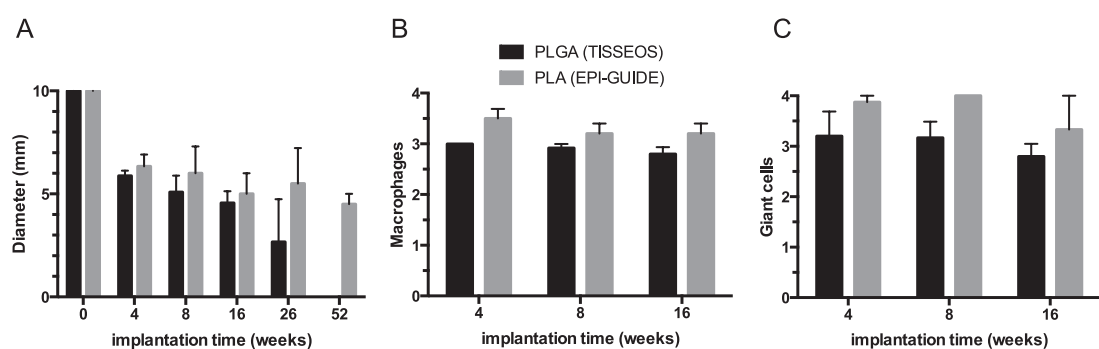
Histology sections of the calvaria defects for the three groups at 4 and 8 weeks are shown in figure 7. After 4 weeks, the defects left empty appeared weakly healed. The collagen membrane was visible but did not completely cover the bone defect. In contrast, the PLGA membrane was clearly recognizable with its bi-layer structure, consisting of a dense film and a layer of micro-fibres. The PLGA membrane filled the defect area and guided the centripetal bone healing. After 8 weeks, the same histology results were observed. Partial bone healing and a few bone spicules were observed in the critical-sized defects left empty. As previously observed, the porcine collagen membrane only partially covered the defect, but still allowed GBR. The PLGA membrane was clearly visible across the bone defect. The dense film had functioned as a barrier, while the micro-fibrous layer guided the bone healing. As expected, the new PLGA membrane had the properties necessary to guide bone regeneration.

#### Comparative GBR of the PLGA membrane in rabbit mandibles

All the animals recovered from surgery without complications and gained weight normally. After 8 weeks, micro-tomographies of the rabbit mandibles were taken (figure 8(A)). The sub-mandibular bone defects covered by the collagen or the PLGA dental membrane were still visible. No signs of osteolysis were observed around the defects covered with either the COLL membrane or the synthetic PLGA membrane. As shown in figure 8(B), bone growth was comparable in the defects covered with either type of membrane. When the defects were filled with TCP granules and covered with the membranes, more bone growth was observed than without the synthetic bone filler (figure 8(C)). In both cases, newly formed bone was observed in direct contact with the TCP granules. These qualitative observations were corroborated by histomorphometry analysis of the bone growth. The amount of bone in the mandibular defects was  $24.6 \pm 3.6\%$  and  $30.0 \pm 8.7\%$



**Figure 4.** Histology of subcutis implants in rats of the synthetic PLGA bi-layered membrane and a porous PLA dental membrane after 26 weeks showing macrophages (red arrows) and multinucleated giant cells (blue arrows) around polymer material (Masson Trichrome staining; original magnification  $\times 200$ ; bar =  $100\ \mu\text{m}$ ).



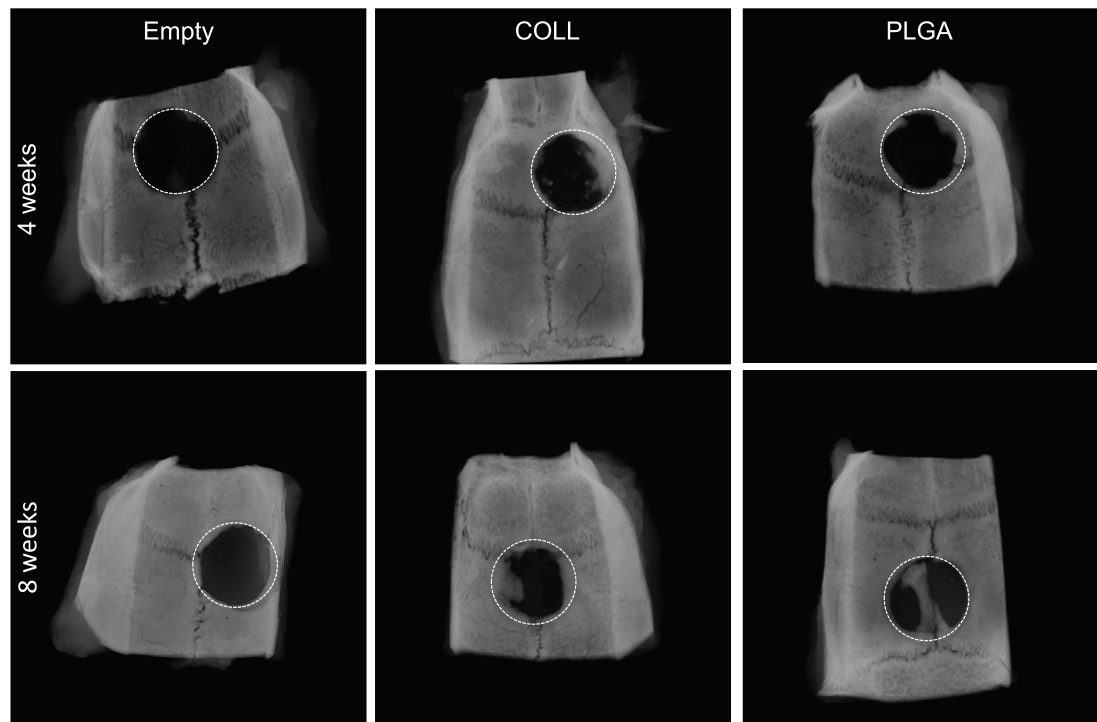
**Figure 5.** Comparison of the resorption rate and biocompatibility of two synthetic dental membranes made of PLGA and PLA polymers after subcutis implantation in rats for up to 52 weeks. (A) *In vivo* degradation given by the apparent diameter of the discs, (B) number of macrophage cells and (C) number of multi-nucleated giant cells as a function of implantation time ( $n = 8/\text{group}$ ). Scoring system: 0, no; 1, minimal; 2, mild; 3, moderate; 4, extensive.

for the collagen and PLGA membranes, respectively. When TCP granules were used in combination with membranes, newly formed bone was  $39.1 \pm 3.4\%$  and  $39.4 \pm 2.7\%$  for the COLL and PLGA membranes, respectively. These histomorphometry results were, however, not statistically significant. In this model, both types of membranes formed a physical barrier to maintain the TCP granules, favoured bone regeneration and prevented epithelial tissue ingrowth in the bone defects.

## Discussion

The present study describes a new synthetic, resorbable PLGA membrane with a bi-layered structure. The membrane was made of synthetic PLGA, a biodegradable polymer that is well-documented and widely used in medical devices [28, 29]. The synthetic PLGA membrane has two layers: (i) a thin dense film that was designed to prevent the invasion of soft connective tissue cells into the membrane-protected





**Figure 6.** Radiographs after 4 and 8 weeks of calvaria defects (dashed circles) left empty, or covered either by a porcine collagen membrane (COLL) or by the synthetic PLGA dental membranes.

**Table 1.** Semi-quantitative analysis of the GBR in critical-sized calvaria defects in rats covered with either a porcine collagen (COLL) or a synthetic PLGA membrane in comparison to the defects left empty after 4 and 8 weeks of healing ( $n = 6/\text{group}$ ).

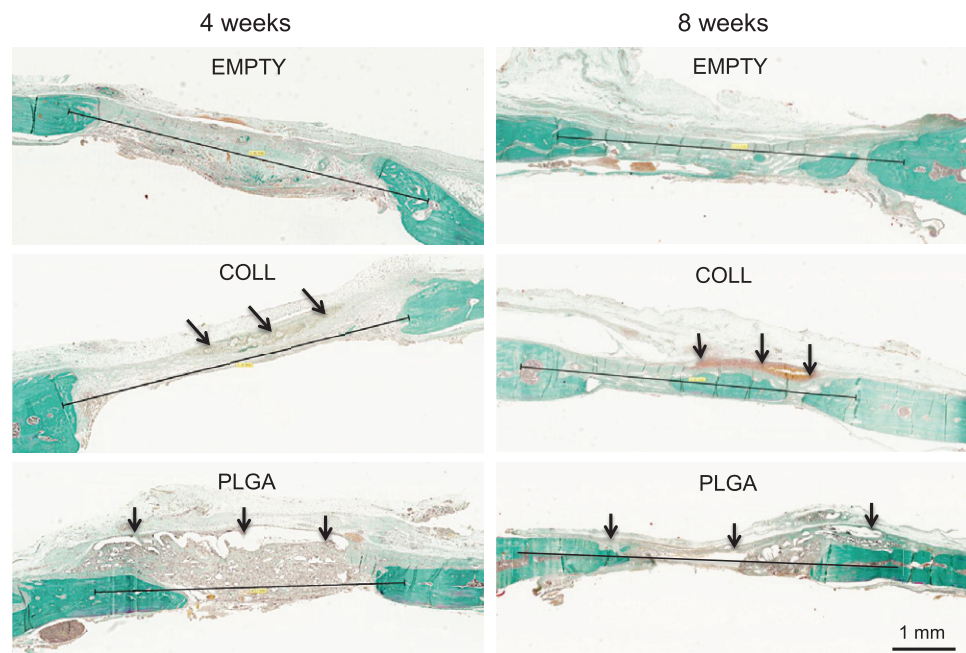
Healing time (weeks)	EMPTY	COLL	PLGA
4	$1.50 \pm 0.29$	$1.33 \pm 0.21$	$2.00 \pm 0.45$
8	$1.75 \pm 0.25$	$1.67 \pm 0.21$	$2.00 \pm 0.26$

space and (ii) a thick micro-fibrous layer that stabilizes the blood clot and allows cells from bone to colonize the membrane. The mechanical flexibility of dental membranes under wet conditions is one of the most important properties of GBR membranes because it ensures easy handling in surgical use. The PLGA membrane has this property and it was easy to adjust on bone defects, while dental surgeons generally find collagen membranes difficult to manipulate. The dense layer provided a certain amount of rigidity, while the micro-fibrous layer ensured good adherence to the bone surface. Furthermore, the mechanical strength of the new PLGA membrane was enough to bear handling with surgical instruments, as well as suturing to soft tissues and comparable to reported values for other dental membranes [30].

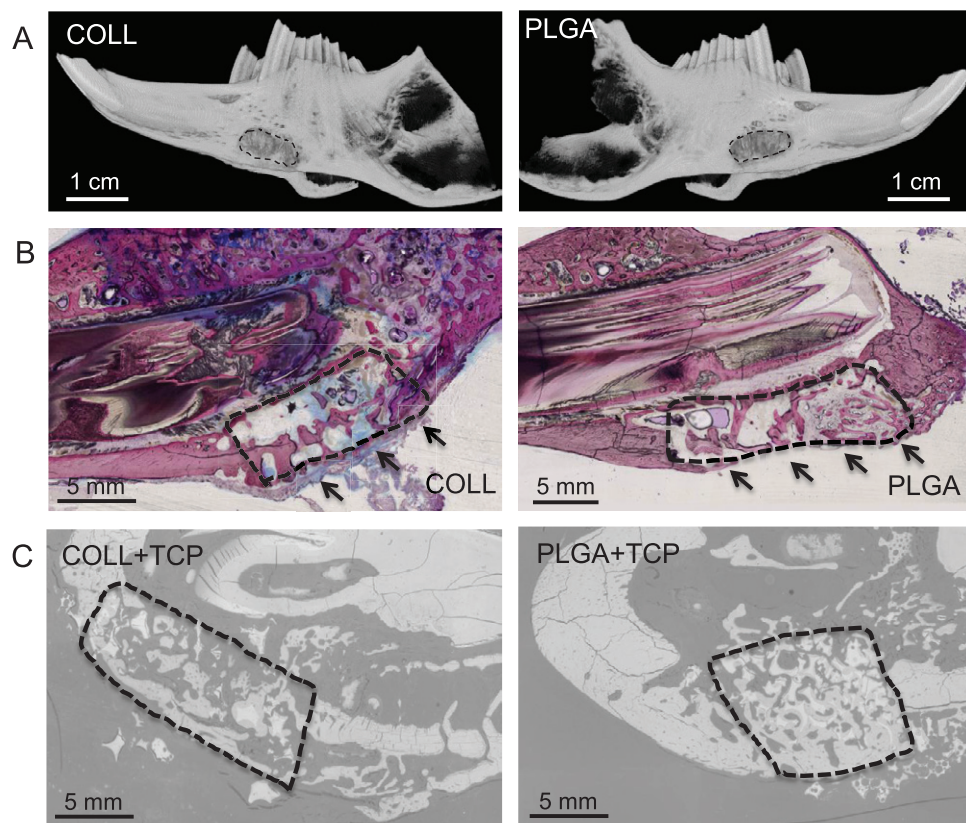
Adequate physical integrity over time is also known to be an important requirement for membranes in GTR. The choice of the material is particularly important with regard to its resorption *in vivo*. The degradation of collagen dental membranes varies in relation to the tissue of origin, chemical cross-linking, porosity and the implantation site. Numerous enzymes are able

to degrade collagen membranes in the body, while the PLGA copolymers degrade by hydrolysis in a more predictable manner. The degradation of PLGA is driven by bulk hydrolysis of polymer chains that break down into lactic and glycolic acids. *In vivo*, these compounds are metabolized into carbon dioxide gas and water. It is well-known that PLGA copolymers have different degradation times depending on their molecular weight, glycolic acid content, D,L isoforms, crystallinity and porosity [31]. For instance, the pure PLA polymer degrades in approximately 7 months while PLGA 50/50 and PLGA 70/30 co-polymers degrade in approximately 2–4 weeks and 6–8 weeks, respectively [32]. This difference in degradation time is related to the higher content of hydrophilic glycolic acid units in PLGA 50/50 which facilitate the absorption and diffusion of water and thus the hydrolysis of the ester bonds. The PLGA 85/15 copolymer formulation was selected to manufacture the present dental membrane, based on its degradation time, which should match the kinetics of gingival and bone tissue healing. In general, gingival tissue healing is completed in less than 2 weeks, and membrane degradation should not disturb the wound closure. Alveolar bone usually heals in about 4 months and dental implants are generally inserted 4–6 months after tooth extraction. An ideal dental membrane should therefore maintain its physical integrity and barrier function for 16 weeks. Lu *et al* [31] have shown that PLGA 85/15 foams degraded in approximately 12–14 weeks indicating that this composition would be suitable for the dental application.

In the present study, the degradation of the PLGA membrane was studied both *in vitro* and *in vivo*.



**Figure 7.** Histology after 4 and 8 weeks of calvaria defects in rats either left empty, or covered by a porcine collagen (COLL) or a synthetic PLGA dental membrane (Masson Trichrome staining). The black line corresponds to the original 5 mm defect. The membranes are shown by arrows.



**Figure 8.** Comparative GBR of mandible defects in rabbits filled or not filled with TCP granules and covered with porcine collagen or synthetic PLGA dental membrane after 8 weeks. (A) microCT reconstructions showing the bone defects (dashed line); (B) representative histology images (Toluidine blue/basic fushin staining) and (C) SEM images.

Viscosity measurements corroborated the breakdown of the polymer chains by hydrolysis. Weight loss and a drop in pH were also observed in PBS around 16 weeks (figure 2), while the acidic environment was not harm-

ful for either biocompatibility or bone regeneration *in vivo* (figures 3–8). In the subcutis implantation study, the PLGA membrane lost its structural integrity in 16 weeks and was completely degraded in 26 weeks,



in line with the *in vitro* results and studies reported in the literature [33, 34]. It is particularly important to maintain physical integrity in order to prevent gingival tissue growth in the bone defect. Here, wound healing was not disturbed by the degradation of the membrane, indicating an optimal degradation time for the PLGA membrane. Furthermore, the degradation products did not disturb bone healing, as has previously been reported for osteosynthesis plates made of PLA polymers [35]. The present PLGA dental membrane was made with a small quantity of polymer (30–50 mg). As a result, the biodegradable PLGA barrier membrane did not induce osteolysis, which would be visible on the radiographs of both the rat calvaria and rabbit mandibles, but instead GBR (figures 6–8). Larger amounts of bone were found in rat calvaria defects covered with the PLGA membrane compared to the defects left empty (table 1). Although not significant, bone regeneration was greater with the PLGA membrane than with the collagen membrane.

In the rabbit study, the feasibility of a combination of a synthetic bone filler (TCP granules) with the synthetic PLGA membrane was demonstrated. Synthetic bone fillers in the form of granules are often used for filling alveolar bone sockets, sinus or periodontal defects because these biomaterials are osteoconductive. Beta-TCP granules are also more resorbable than HA [36, 37]. The synthetic PLGA membrane maintained the TCP granules in the mandible defect while preventing epithelial tissue ingrowth. It also ensured similar bone quantities in defects to those obtained with the porcine-derived collagen dental membrane (figure 8).

Some studies have indicated that PLGA materials could lead to inflammation [38–40]. In these studies, bone plates and screws made of high molecular weight and crystalline poly-L-lactic acid were used for fracture fixation of zygomatic and ankle bones. Patients returned with a swelling at the site of implantation with remnants of degraded PLLA material surrounded by a dense fibrous capsule and signs of chronic inflammation. Nevertheless, the size and degradation rate of these PLLA devices were completely different than those reported here for the PLGA dental membrane. First, the quantity of material was several grams of polymer for the orthopaedic devices in comparison to 30–50 mg for the present dental membrane. Furthermore, the complete hydrolysis of the PLLA devices required 2–3 years while the PLGA 85/15 membrane resorbed in 12–26 weeks due to its high glycolic content. Consequently, the cell and tissue response towards the present PLGA membrane is not comparable to those reported for previous PLLA devices. The present animal studies have demonstrated that the tissue fibrosis was thin, indicating that the material is biocompatible until complete resorption. These observations are in good agreement with previous clinical studies using a dental membrane made of PLGA [41, 42].

## Conclusion

In this study, a resorbable, synthetic PLGA bi-layered dental membrane for GBR was designed, characterized and evaluated in animal models. This membrane has a bi-layered structure with a dense film to prevent epithelial tissue ingrowth and a micro-fibrous layer to support cell colonization and bone regeneration. The membrane maintained its structural integrity and barrier function for 16 weeks, and degraded by hydrolysis of the polymer chains. The PLGA membrane was easy to apply over the defects together with synthetic bone filler granules. GBR was successfully demonstrated with the PLGA membrane on both calvaria defects in rats and mandibular defects in rabbits. Overall, this biodegradable synthetic barrier PLGA membrane may be a safer and more predictable alternative for GBR than animal derived collagen products.

## Disclosures

Alain Hoornaert and Pierre Layrolle are co-founders of the spin-off company Biomedical Tissues from the University of Nantes that produces the synthetic dental membrane Tisseos®. Nevertheless, they have not received any financial incentive for performing this study. Cyril D'Arros was an employee of Biomedical Tissues.

## Acknowledgments

The authors would like to thank Jérôme Amiaud and Séverine Battaglia for their technical expertise and support in histological procedures and microCT, respectively. This study was partially supported by the public investment bank, bpi France. The authors are grateful to Kirsty Snaith of Medicis Traduction for grammar and spelling corrections to the manuscript.

## References

- [1] Nyman S, Gottlow J, Karring T and Lindhe J 1982 The regenerative potential of the periodontal ligament. An experimental study in the monkey *J. Clin. Periodontol.* **9** 257–65
- [2] Weber H-P, Morton D, Gallucci G O, Rocuzzo M, Cordaro L and Grutter L 2008 Consensus statements and recommended clinical procedures regarding loading protocols *Int. J. Oral Maxillofac. Implants* **24** 180–3
- [3] Sculean A, Nikolidakis D, Nikou G, Ivanovic A, Chapple IL C and Stavropoulos A 2015 Biomaterials for promoting periodontal regeneration in human intrabony defects: a systematic review *Periodontol.* **2000** **68** 182–216
- [4] Lutz R, Neukam F W, Simion M and Schmitt C M 2015 Long-term outcomes of bone augmentation on soft and hard-tissue stability: a systematic review *Clin. Oral Implants Res.* **26** 103–22
- [5] Kao R T, Nares S and Reynolds M A 2015 Periodontal regeneration—intrabony defects: a systematic review from the AAP regeneration workshop *J. Periodontol.* **86** S77–104
- [6] Retzepi M and Donos N 2010 Guided bone regeneration: biological principle and therapeutic applications *Clin. Oral Implants. Res.* **21** 567–76

- [7] Hürzeler M B, Quiñones C R and Schüpbach P 1997 Guided bone regeneration around dental implants in the atrophic alveolar ridge using a bioresorbable barrier. An experimental study in the monkey. *Clin. Oral Implants Res.* **8** 323–31
- [8] Miller N, Penaud J, Foliguet B, Membre H, Ambrosini P and Plombas M 1996 Resorption rates of 2 commercially available bioresorbable membranes. A histomorphometric study in a rabbit model *J. Clin. Periodontol.* **23** 1051–9
- [9] Zhao S, Pinholt E M, Madsen J E and Donath K 2000 Histological evaluation of different biodegradable and non-biodegradable membranes implanted subcutaneously in rats *J. Craniomaxillofac. Surg.* **28** 116–22
- [10] Owens K W and Yukna R A 2001 Collagen membrane resorption in dogs: a comparative study *Implant Dent.* **10** 49–58
- [11] Ronda M, Rebaudi A, Torelli L and Stacchi C 2014 Expanded vs. dense polytetrafluoroethylene membranes in vertical ridge augmentation around dental implants: a prospective randomized controlled clinical trial *Clin. Oral Implants Res.* **25** 859–66
- [12] Watzinger F, Luksch J, Milleli W, Schopper C, Neugebauer J, Moser D and Ewers R 2000 Guided bone regeneration with titanium membranes: a clinical study *Br. J. Oral Maxillofac. Surg.* **38** 312–5
- [13] Rosen P S and Reynolds M A 2001 Guided bone regeneration for dehiscence and fenestration defects on implants using an absorbable polymer barrier *J. Periodontol.* **72** 250–6
- [14] Kohal R-J, Trejo P M, Wirsching C, Hürzeler M B and Caffesse R G 1999 Comparison of bioabsorbable and bioinert membranes for guided bone regeneration around non-submerged implants. An experimental study in the mongrel dog *Clin. Oral Implants Res.* **10** 226–37
- [15] Rakhmatia Y D, Ayukawa Y, Furuhashi A and Koyano K 2012 Current barrier membranes: titanium mesh and other membranes for guided bone regeneration in dental applications *J. Prosthodont. Res.* **57** 3–14
- [16] Klinger A, Asad R, Shapira L and Zubery Y 2010 *In vivo* degradation of collagen barrier membranes exposed to the oral cavity *Clin. Oral Implants Res.* **21** 873–6
- [17] Lee S W and Kim S G 2014 Membranes for the guided bone regeneration *J. Korean Assoc. Maxillofac. Plast. Reconstr. Surg.* **36** 239–46
- [18] Araújo M G, Silva C O, Misawa M and Sukekava F 2015 Alveolar socket healing: what can we learn? *Periodontol.* **2000** 68 122–34
- [19] Chappard D, Guillaume B, Mallet R, Pascaretti-Grizon F, Baslé M F and Libouban H 2010 Sinus lift augmentation and beta-TCP: a microCT and histologic analysis on human bone biopsies *Micron* **41** 321–6
- [20] Buser D, Hoffmann B, Bernard J-P, Lussi A, Mettler D and Schenk R K 1998 Evaluation of filling materials in membrane-protected bone defects. A comparative histomorphometric study in the mandible of miniature pigs *Clin. Oral Implants Res.* **9** 137–50
- [21] Lee J H, Jung U-W, Kim C-S, Choi S-H and Cho K S 2008 Histologic and clinical evaluation for maxillary sinus augmentation using macroporous biphasic calcium phosphate in human *Clin. Oral Implants Res.* **19** 767–71
- [22] Sheikh Z, Sima C and Glogauer M 2015 Bone replacement materials and techniques used for achieving vertical alveolar bone augmentation *Materials* **8** 2953–93
- [23] McCaul L K, Bagg J and Jenkins W M M 1999 Rate of loss of irradiated polyglactin 910 (Vicryl Rapide) from the mouth: a prospective study *Br. J. Oral Maxillofac. Surg.* **38** 328–30
- [24] Deeken C R, Abdo M S, Frisella M M and Matthews B D 2011 Physicomechanical evaluation of absorbable and nonabsorbable barrier composite meshes for laparoscopic ventral hernia repair *Surg. Endosc.* **25** 1541–52
- [25] ISO 10993-6-2006 *Biological Evaluation of Medical Devices Part 6: Test for Local Effects After Implantation* (Geneva, Switzerland: International Organization for Standardization)
- [26] Spicer P P, Kretlow J D, Young S, Jansen J A, Kasper F K and Mikos A G 2012 Evaluation of bone regeneration using the rat critical size calvarial defect *Nat. Protocols* **7** 1918–29
- [27] Miloro M, Haralson D J and Desa V 2010 Bone healing in a rabbit mandibular defect using platelet-rich plasma *J. Oral Maxillofac. Surg.* **68** 1225–30
- [28] Razak S, Sharif N and Rahman W 2012 Biodegradable polymers and their bone applications: a review *Int. J. Basic Appl. Sci.* **12** 31–49
- [29] Gunatillake P A and Adhikari R 2003 Biodegradable synthetic polymers for tissue engineering *Eur. Cell Mater.* **5** 1–16 (discussion 16)
- [30] Leal A I, Caridade S G, Ma J, Yu N, Gomes M E, Reis R L, Jansen J A, Walboomers X F and Mano J F 2013 Asymmetric PDLLA membranes containing Bioglass® for guided tissue regeneration: characterization and *in vitro* biological behavior *Dent. Mater.* **29** 427–36
- [31] Lu L, Peter S J, Lyman M D, Lai H L and Leite S M 2000 *In vitro* and *in vivo* degradation of porous poly(DL-lactic-co-glycolic acid) foams *Biomaterials* **21** 1837–45
- [32] Cai Q, Shi G, Bei J and Wang S 2003 Enzymatic degradation behavior and mechanism of poly(lactide-co-glycolide) foams by trypsin *Biomaterials* **24** 629–38
- [33] Vert M, Mauduit J and Li S 1994 Biodegradation of PLA/GA polymers: increasing complexity *Biomaterials* **15** 1209–13
- [34] Wu L and Ding J 2004 *In vitro* degradation of three-dimensional porous poly(D,L-lactide-co-glycolide) scaffolds for tissue engineering *Biomaterials* **25** 5821–30
- [35] Böstman O M and Pihlajamäki H K 2000 Adverse tissue reactions to bioabsorbable fixation devices *Clin. Orthop. Relat. Res.* **216**–27
- [36] Jensen S S and Terheyden H 2008 Bone augmentation procedures in localized defects in the alveolar ridge: clinical results with different bone grafts and bone-substitute materials *Int. J. Oral. Maxillofac. Implants* **24** 218–36
- [37] Sanz M and Vignoletti F 2015 Key aspects on the use of bone substitutes for bone regeneration of edentulous ridges *Dent. Mater.* **31** 640–7
- [38] Schliephake H and Kracht D 1997 Vertical ridge augmentation using polylactic membranes in conjunction with immediate implants in periodontally compromised extraction sites: an experimental study in dogs *Int. J. Oral Maxillofac. Implants* **12** 325–34
- [39] Schliephake H, Dard M, Planck H, Hierlemann H and Stern U 2000 Alveolar ridge repair using resorbable membranes and autogenous bone particles with simultaneous placement of implants: an experimental pilot study in dogs *Int. J. Oral Maxillofac. Implants* **15** 364–73
- [40] Bergsma J E, De Bruijn W C, Rozema F R and Bos R 1995 Late degradation tissue response to poly(L-lactide) bone plates and screws *Biomaterials* **16** 25–31
- [41] Schneider D, Weber F E, Grunder U, Andreoni C, Burkhardt R and Jung R E 2014 A randomized controlled clinical multicenter trial comparing the clinical and histological performance of a new, modified polylactide-co-glycolide acid membrane to an expanded polytetrafluoroethylene membrane in guided bone regeneration procedures *Clin. Oral Implants Res.* **25** 150–8
- [42] Benic G I and Hammerle C H F 2014 Horizontal bone augmentation by means of guided bone regeneration *Periodontol.* **2000** **66** 13–40