



HAL
open science

Severe compromise of preosteoblasts in a surgical mouse model of bisphosphonate-associated osteonecrosis of the jaw

Luis Córdova, Florian Guilbaud, Jérôme Amiaud, Séverine Battaglia, Céline Charrier, Frédéric Lézot, Benoît Piot, Françoise Rédini, Dominique Heymann

► To cite this version:

Luis Córdova, Florian Guilbaud, Jérôme Amiaud, Séverine Battaglia, Céline Charrier, et al.. Severe compromise of preosteoblasts in a surgical mouse model of bisphosphonate-associated osteonecrosis of the jaw. *Journal of Cranio-Maxillofacial Surgery*, 2016, 44 (9), pp.1387 - 1394. 10.1016/j.jcms.2016.07.015 . inserm-01644757

HAL Id: inserm-01644757

<https://inserm.hal.science/inserm-01644757>

Submitted on 22 Nov 2017

HAL is a multi-disciplinary open access archive for the deposit and dissemination of scientific research documents, whether they are published or not. The documents may come from teaching and research institutions in France or abroad, or from public or private research centers.

L'archive ouverte pluridisciplinaire **HAL**, est destinée au dépôt et à la diffusion de documents scientifiques de niveau recherche, publiés ou non, émanant des établissements d'enseignement et de recherche français ou étrangers, des laboratoires publics ou privés.

Severe Compromise of Preosteoblasts in a Surgical Mouse Model of Bisphosphonate-Associated Osteonecrosis of the Jaw

Luis A. Córdova, DDS PhD.^{a, b, c*}, Florian Guilbaud BSc^{a, b}, Jérôme Amiaud BSc^{a, b},
Séverine Battaglia BSc^{a, b}, Céline Charrier BSc^{a, b}, Frédéric Lezot, PhD^{a, b}, Benoît Piot, MD,
PhD^{d, e}, Françoise Redini, PhD^{a, b}, Dominique Heymann, PhD^{a, b, e, f}

^aINSERM, UMR 957, Equipe Ligue Contre le Cancer 2012, 1 rue Gaston Veil, Nantes cedex 1, 44035, Nantes, France.

^bUniversity of Nantes, Nantes Atlantique Universities, Pathophysiology of Bone Resorption and Therapy of Primary Bone Tumours Laboratory, 1 rue Gaston Veil, Nantes cedex 1, 44035, Nantes, France

^cDepartment of Oral and Maxillofacial Surgery, San Borja Arriarán University Hospital - Faculty of Dentistry, University of Chile, Sergio Livingstone Polhammer 943, Independencia, Santiago, Chile

^dDepartment of Stomatology and Maxillofacial Surgery, Nantes University Hospital, Nantes, France, 1 place Alexis-Ricordeau 44093 Nantes Cedex 1, France

^eNantes University Hospital, Nantes, France, 1 place Alexis-Ricordeau 44093 Nantes Cedex 1, France

^fDepartment of Oncology and Metabolism, Medical School, Beech Hill Road, S10 2RX Sheffield, UK

Luis A. Córdova, lcordova@stanford.edu

Florian Guilbaud, florian.guilbaud@univ-nantes.fr

Jérôme Amiaud, jerome.amiaud@univ-nantes.fr

Séverine Battaglia, severine.battaglia@univ-nantes.fr

Céline Charrier, celine.charrier@univ-nantes.fr

Frédéric Lezot, frederic-lezot@univ-nantes.fr

Benoit Piot, benoit.piot@chu-nantes.fr

Françoise Redini, francoise.redini@univ-nantes.fr

Dominique Heymann, dominique.heyman@sheffield.ac.uk

¹ Corresponding author: Luis A. Córdova

Current address: Division of Plastic & Reconstructive Surgery, Stanford School of Medicine, 257 Campus Dr, GK211, Stanford, CA 94035, United States

Phone: +1(650)-736 1722

Cell: +1 (650)-736-4374

E-mail: lcordova@stanford.edu

Financial support for this research was provided by:

- The Gueules Cassées Foundation, project N°FGC 14-2012,
- The Agence Nationale de la Recherche, Grant 2007 “Pathophysiology of Human Diseases “2007 Project N°RO 7196N
- The Ligue National Contre le Cancer “Equipe Ligue 2012”
- University of Chile and CONICYT- Becas Chile (CONICYT PAI/INDUSTRIA 79090016).

ABSTRACT

Objectives: Since the effect of amino-bisphosphonates on osteoblastic lineage in bisphosphonate-associated osteonecrosis of the jaw (BONJ) is a controversial issue, we assessed the effects of intermediate and long-term high doses of zoledronic acid (ZOL) in bone and vascular cell components of the alveolar basic multicellular units (BMUs), using a surgical mouse model of BONJ.

Material and Methods: Thirty-two mice were treated twice a week (i.p.) with either 100 µg/kg of ZOL (n=16) or saline (n=16) for 12 weeks. The first left maxillary molar was extracted at the end of the third week. Semi-quantitative histomorphometry was carried-out assessing empty lacunae, osteoclasts (TRAP), preosteoblasts (Osterix) and perivascular cells (CD146) at weeks 6 (intermediate) and 12 (long-term). The alveolar bone mass was assessed by micro-CT at the same time points.

Results: The formation of osteonecrotic-like lesions was observed in 21% of mice. Moreover, a decreased number of preosteoblasts, contrasted with the increased number of osteoclasts at both time points. In addition, osteoclasts display multinucleation and detachment from the endosteal surface. Moreover, the number of perivascular cells increased at the intermediate timepoint. The alveolar bone mass increased exclusively with long-term ZOL treatment.

Conclusions: A reduction in the number of osteoblastic lineage and an increase in the number of osteoclasts were induced by intermediate and long-term high doses of ZOL associated to surgical stimulus in mice.

Clinical relevance: The compromise of osteoblastic lineage by amino-bisphosphonates is a potential mechanism contributing to BONJ development and could support the use of bone anabolic therapies in clinics.

KEYWORDS: Zoledronic acid, osteoclast, osteoblast, alveolar bone, basic multicellular unit.

INTRODUCTION

Osteonecrosis of the jaw associated with the long-term use of bisphosphonates (BONJ) is characterized by persistent jaw bone exposure after a surgical procedure in patients with a history of use of bisphosphonates and without previous exposure to head and neck radiotherapy [1]. The long-term use of intravenous third generation amino-bisphosphonates (risedronate and zoledronic acid), the most powerful antiresorptive agents, was considered as a critical risk factor related with the development of BONJ [2, 3]. The pathogenesis of BONJ remains unknown. Various potential explanations have been proposed, nevertheless, the most logic hypothesis is the suppression of bone remodelling induced by bisphosphonates, based on the intrinsic mode of action of bisphosphonates [4–6].

Bone remodelling is the coupled process initiated by osteoclastic bone resorption followed by osteoblastic new bone formation [7]. This process occurs in the entire skeleton throughout life and it takes place in the basic multicellular units (BMUs) of cortical and trabecular bone [7]. A tight control of bone remodelling in each BMU is essential for maintaining normal bone mass. This control is regulated by dynamic interactions between the cell components and coupling factors released during bone remodelling in each BMU [8]. The formers include: osteoclasts, osteoblasts, vascular (e.g.: pericytes and endothelial cells), immune cells (e.g.: macrophages and dendritic cells) and their corresponding precursors [7]. Coupling factors include those released by osteoclasts during their differentiation: cardiotrophine 1, sphingosine-1-phosphate, BMP6 and Wnt10b, collagen triple helix repeat containing 1 (CTHRC1) and Sema4D; and those released from the resorbed bone matrix: IGF-1 and TGF- β [8]. Under this complex scenario, the fully comprehension of the effect of amino-bisphosphonates on each component of BMU might be the key to understand the cellular basis of BONJ.

Focusing on the bone cell interactions, the beneficial effects of amino-bisphosphonates on osteoclast differentiation/activity and subsequent increase of bone density have been extensively studied at preclinical and clinical level. However, there is not a clear understanding about their effects on osteoblastic lineage [9]. Human bone sequestrum show an evident compromise of osteoblastic components in terminal stages of osteonecrotic lesions [10]. This stage is characterized by the absence of endosteal osteoblasts in bone marrow

spaces, empty osteocyte lacunae and damage in the canalicular system [10]. These morphological changes suggest the compromise of both, osteoblastic precursors and mature osteocytes [11, 12]. In addition, *in vitro* studies report cytotoxic effects of bisphosphonates on osteoblastic cells, decreasing, their viability and osteogenic ability in a dose-dependent manner [3, 13]. However, the vast majority of these reports were carried out in single cell culture systems and did not reproduce, due to technical limitations, all the environmental factors of the BMUs. Therefore, the understanding of effects of amino- isphosphonates on osteoblastic lineage in alveolar BMUs is a crucial and missing issue in the pathogenesis of BONJ. We postulated that osteoblastic cells are sensitive to effect of amino-bisphosphonates and their compromise could contribute to the development of BONJ. The aim of our study was thus to assess – at the cellular level - the intermediate and long-term effects of high doses of zoledronic acid on the bone and vascular cell components of BMU, osteoblasts, osteoclast and pericytes, using a surgical mouse model for BONJ.

MATERIAL AND METHODS

Animals, drug administration and surgical procedure

Thirty-two C57BL/6 male mice (Janvier, Le Genest-Saint Isle, France) aged 10 weeks were randomly divided into two groups and treated intra-peritoneally (i.p.) with either 200 µg/kg of zoledronic acid (kindly provided by Amgen, Switzerland) weekly (experimental group; n=16) or saline solution (control group; n=16) for 12 weeks (Table 1 and Supplementary appendix 1). The drug tolerance of the mice was assessed daily by clinical examination. The total dose of zoledronic acid administered to the mice was the equivalent of a lifetime dose of the drug over 4 years of therapy in a 70 kg adult multiple myeloma patient [13]. At the end of the third week, the first left maxillary molar was surgically extracted from all the animals (Supplementary appendix 1). After 6 weeks of treatment with zoledronic acid (or saline solution), and 3 weeks after the molar extraction, 50 % of the animals were sacrificed to assess the situation at an intermediate time point (equivalent of 2 years according to Pozzi *et al.*, 2009). The other 50 % of the animals was sacrificed at the end of the protocol, after 12 weeks of treatment with zoledronic acid (or saline solution) (equivalent of 4 years according to Pozzi *et al.*, 2009) and 9 weeks after the molar extraction, for the long-term assessment (Table 1).

Histology analysis

Harvested maxillae were fixed in 4% buffered formaldehyde for 48 hours and then decalcified with 4.13% ethylenediaminetetraacetic acid (EDTA) and 0.2% paraformaldehyde in phosphate buffered saline (PBS) for 96 hours using the KOS microwave histostation (Milestone, Kalamazoo, MI, USA) before embedding in paraffin. Two 4 µm-thick sagittal sections were obtained from 2 levels of the alveolar socket site (each one separated by 50 µm). All slides were stained with Masson trichrome to assess the bone matrix and empty lacunae in both, bone sequestrum and submucosal bone. Furthermore, all slides were stained with tartrate-resistant acid phosphatase (TRAP) to identify osteoclasts (Table 1 and Supplementary appendix 1). The immunostaining for osteoblastic cells was performed using rabbit monoclonal anti-osterix antibody (1/800; Abcam). The immunostaining of the pericytes was carried out using rabbit monoclonal anti-CD146 antibody (1/200; Abcam).

Histological images were acquired using a NanoZoomer 2.0-RS slide scanner (Hamamatsu, Japan). The region of interest (ROI) corresponded to a rectangular area of

alveolar bone comprising the full length of the alveolar socket. Static histomorphometric analysis of the number of empty lacunae, percentage of osteoclasts [14–16], number of osterix and CD146⁺ cells in their defined ROIs, were performed using ImageJ software (NIH, Bethesda, MD, USA).

Micro-computed tomography assessment

The analysis of alveolar bone microarchitecture was performed at the time of necropsy (6 and 12 weeks) using the high-resolution X-ray micro-computed tomography (micro-CT) system for small-animal imaging SkyScan-1076 (SkyScan, Kontich, Belgium) (Table 1 and Supplementary appendix 1). The assessment of alveolar bone density was performed by measuring the mineralized bone detected within the VOI (Bone Volume; BV) and expressed in cubic millimetres (mm³).

Statistical analysis

All analyses were performed using GraphPad InStat Version 3.02 software (GraphPad Software, La Jolla, CA, USA). The histological and micro-CT results were analyzed with ANOVA and an unpaired parametric two-tailed t test. Results were considered significant at p value ≤ 0.05 .

RESULTS

Zoledronic acid and molar extraction induce clinical osteonecrotic changes in mouse alveolar bone

A 12-week administration of high doses of zoledronic acid was well tolerated by all mice assessed by their body weight follow (data not shown). In addition, we observed the presence of exposed bone (sequestrum) in the operative site in 21 % of the samples at the intermediate time point. The aspect of the sequestrum was opaque and yellowish bone, slightly attached to the local mucosa (Figure 1A). No sequestrum and normal healing of oral mucosa were observed in mice assessed at the long time point.

We next analyzed the histological features of the bone sequestrum and submucosal bone at the operative site. The exposed bone had many empty lacunae, devoid of their osteocytes and distributed throughout the sequestrum (Figure 1B). In addition, empty lacunae were observed in the superficial layer of the submucosal bone (Figure 1B). Their quantification in the ROI at both, intermediate (6 weeks) and long (12 weeks) time points showed that zoledronic acid induced a significant increase in the number of empty lacunae only after 12 weeks of therapy (Figure 1C, $p=0.001$).

Zoledronic acid and molar extraction decrease the number of osteoblastic cells in alveolar BMUs

To reveal the effect of zoledronic acid on osteoblastic cells in alveolar BMUs, we performed a qualitative analysis of the alveolar socket on histologic slices, followed by a semi-quantitative assessment of osterix positive cells using immunohistochemistry (Figure 2). New trabecular bone could be observed in both the zoledronic acid and saline treated groups at the intermediate time point. Otherwise, after long-term treatment with zoledronic acid (12 weeks), the BMUs exhibited a large surface of calcified bone matrix with narrow marrow spaces within it compared with those treated with saline. Osterix immunopositive cells were detected in the superficial layer of the trabecular bone. In addition, the number of osterix positive cells decreased significantly in the BMUs of mice that received intermediate ($p=0.04$) or long-term ($p=0.01$) treatment with zoledronic acid compared to the mice treated with saline solution (Figure 2).

Zoledronic acid and molar extraction increase the number of aberrant giant multinucleated osteoclasts in alveolar BMUs

As it has been admitted that bisphosphonates, and particularly zoledronic acid, increase the apoptosis of osteoclasts, thus decreasing bone remodelling, we next assessed the effect of our protocol on the osteoclasts in the alveolar BMUs. At the intermediate time point and in the long-term, we observed considerable morphological changes in the TRAP⁺ cells between zoledronic acid-treated mice and those treated with saline solution (Figure 3). In the former group, the shape of the osteoclasts was dramatically modified and the treatment resulted in the formation of large, multinucleated osteoclasts compared to those observed in the control mice (Figure 3). In addition, some of these cells were detached from the bone surface and located within the bone marrow spaces. Interestingly, semi-quantification showed significant increases in the TRAP⁺ cell in the mice that received the intermediate ($p=0.001$) or long-term bisphosphonate treatments ($p=0.03$) (Figure 3).

Zoledronic acid and molar extraction increase the bone volume of the extraction socket

Considering the high impact of zoledronic acid on bone remodelling through its inhibition of osteoclastic bone resorption, we next assessed the microarchitecture of trabecular bone in alveolar BMUs using a volumetric assessment by micro-tomography (micro-CT). We observed a significant increase in the percentage of bone volume (BV) in the VOI in mice treated with long-term zoledronic acid compared to controls (Figure 4) ($p=0.01$). In contrast, no difference was observed with the intermediate term treatment (Figure 4).

Intermediate treatment with zoledronic acid and molar extraction increases the number of pericyte-like cells (CD146⁺) in alveolar BMUs

Given the potentially anti-angiogenic effects of zoledronic acid, we assessed the presence of CD146⁺ peri-vascular cells (pericytes-like) within the BMUs using immunohistochemistry. Positive cells located in the bone marrow spaces of alveolar BMUs were clearly identified. Interestingly, a significant increase in CD146⁺ pericyte-like cell numbers was detected in mice that received an intermediate treatment with zoledronic acid compared to those that received the saline solution (Supplementary appendix 2) ($p=0.01$). On the contrary, no difference was detected in the long-term treated mice (data not shown).

DISCUSSION

Maxillomandibular alveolar bone is a particular unit of the skeleton that undergoes periodic stimulus (e.g. facial and dental development, chewing, etc.), exhibiting a higher bone turnover than non-alveolar bone [17]. Bone turnover depends of the coupling activities of osteoblasts and osteoclasts in BMUs [7, 8]. Otherwise, zoledronic acid markedly decreases bone turnover by apoptosis of the osteoclasts, blocking the bone resorption and subsequently, increasing the bone mass [18]. This antiresorptive effect is the main advantage for the treatment of human osteolytic diseases [18–20]. The effects of BPs on other cell components of BMUs such as osteoblastic, vascular and immune cells remain misunderstood [8, 21]. On other hand, while bisphosphonate effects on bone tissue have been described in BMUs of axial and appendicular skeleton, the specific effects of bisphosphonates on maxillomandibular alveolar bone, the precise site affected by osteonecrosis, is still less understood, too. We therefore assessed the effects of a human equivalent protocol of intermediate and long-term intravenous high doses of zoledronic acid on bone and vascular cells involved in the bone remodelling cycle in alveolar BMUs using an adapted surgical mouse model of osteonecrosis of the jaw [22].

We first confirmed that our protocol induced the major features of BONJ reported in human series [23, 24]. We showed jaw-like osteonecrotic lesions characterized by the formation of sequestrum and empty lacunae in alveolar bone at the operative site. Bone sequestrum was observed in a small number of samples at the intermediate time point of the treatment. Consequently, most samples showed normal healing at the operative site. The variable reproduction of bone exposition and secuestrum has been also reported in different murine models of ONJ, and seems to be associated with the degree of surgical trauma [25]. Otherwise, empty lacunae, the other key feature in human and experimental osteonecrotic diseases [26, 27], were recognized widely in the bone sequestrum and selectively in the superficial layer of submucosal bone in the alveolar socket. Interestingly, the number of empty lacunae in the submucosal bone significantly increased after long-term treatment, suggesting that this finding may be associated with the cumulative doses fixed in the alveolar bone. This fact is in agreement with previous clinical and experimental reports [1, 28–30], supporting the hypothesis that long-term exposure to high doses of amino-bisphosphonates determines their accumulation in alveolar BMUs, inducing local changes and constituting a potential first step in the development of osteonecrosis of the jaw [13, 29, 31, 32].

Interestingly, our study demonstrated that zoledronic acid significantly decreased the number of osteoblastic cells in the alveolar BMUs. This observation was in agreement with the down-regulation of gene expression implicated in osteoblast signalization, osteoprogenitor cell differentiation and activation that has been observed in patients treated with high doses of zoledronic acid with and without BONJ by multiple myeloma [23]. The same study showed that the suppression of bone formation markers was most pronounced in BONJ patients [23]. In addition, a decrease in osteoblasts number was observed in the long bones after 3 weeks of systemic treatment with increasing doses of zoledronic acid [13]. Moreover, the absence of woven bone in the alveolar socket after tooth extraction in mice treated with bisphosphonate and denosumab, two agents associated with osteonecrotic-lesions, has recently been demonstrated [33]. In this study, seric levels of bone-specific alkaline phosphatase, a biomarker of osteoblastic cell activity, was also decreased [33]. Similarly, a cytotoxic effect characterized by the inhibition of viability, bone matrix secretion and mineralization was observed in osteoblasts after prolonged exposure to zoledronic acid under *in vitro* conditions [13]. While the main action of bisphosphonates occurs by the direct effect on osteoclasts in the bone matrix resorption phase of the remodelling cycle, the reduction in the number of osteoblastic cells in alveolar BMUs strongly suggests that zoledronic acid has a potentially additional effect in the apposition phase of this cycle. Further studies are needed to determine the mechanisms underlying this hypothesis. Accordingly, these clinical and experimental data might be related with the successful use of human recombinant parathyroid-hormone (rhPTH), a bone anabolic strategy, as a therapeutic approach for BONJ in clinic. [34, 35].

Otherwise, zoledronic acid induced an increase in the number of osteoclasts and a severe disruption in osteoclast morphology after both intermediate and long-term treatment. Indeed, we reported a significant increase in the percentage of TRAP⁺ cell observed in zoledronic acid-treated mice at both time points and the detachment of them from the bone trabeculae surface. Taken together, these findings suggest a paradoxal effect of zoledronic acid on osteoclasts, primarily supposed to decrease the number and activity of them. Osteoclasts with altered morphology were also reported in biopsies of patients under long-term of amino-bisphosphonate therapy, highlighting their dose-dependence [36, 37]. The cytoskeletal reorganization of osteoclasts through inhibition of the protein prenylation induced by amino-bisphosphonates was proposed as an explanation for these facts [38, 39].

Similar data were observed in biopsies of patients after treatment with teriparatide and who had previously been treated with bisphosphonates [37]. These aberrant osteoclasts may be subject to prolonged apoptosis or be functionally inhibited by zoledronic acid [36]. Our study shows consistent findings to support the lack of osteoclast bone-resorptive function in these aberrant osteoclasts.

We also observed that zoledronic acid increased the number of vascular cells exclusively after intermediate-term treatment. Our results are controversial considering the generic compromise of the vasculature in osteonecrotic diseases (e.g. femoral osteonecrosis and osteoradionecrosis) [40, 41]. Specifically, BONJ patients have shown vascular compromise through decreases in serum levels of vascular-endothelial-growth-factor (VEGF) [42]. In addition, case report studies show an increase in the incidence and severity of osteonecrosis of the jaw after single administration of bisphosphonates or associated with bevacizumab, a recombinant human monoclonal antibody that targets VEGF [43, 44]. There are also numerous *in vitro* studies demonstrating the considerable impact of nitrogen-containing bisphosphonates over non nitrogen-containing bisphosphonates, decreasing the viability and migration of endothelial cells, as well as increasing their apoptosis [45, 46]. Despite this, only a restricted number of *in vivo* studies have shown the anti-angiogenic effects of nitrogen-containing bisphosphonates [47–50]. We hypothesize that our results are strongly influenced by the inflammatory and reparative response triggered following the molar extraction.

The regulation of the bone mass is the product of the coupled phases of the bone remodelling cycle in each BMU: resorption driven by mature osteoclasts, and formation driven by pre- and mature osteoblasts. The increased alveolar bone mass at the long-term time point showed in our study, confirms the inactivation of osteoclasts and subsequent osteolysis. Interestingly, it occurs despite the decreased number of osteoblastic cells. We propose that the long-term treatment with zoledronic acid affect both, the osteoclastic bone resorption for a long period and, transiently, the osteoblastic bone formation. Thus, a decreased number of osteoblastic cells were thus capable of synthesizing the bone matrix and increasing the alveolar bone mass. This hypothesis might be related with the reported increased bone turnover rate of alveolar bone rather than that of non-alveolar bone sites [17]. Also, this finding could be explained by the bone anabolic effect of the early inflammatory stage in the alveolar socket after the molar extraction. The link between inflammation and bone repair was

recently proposed and it may be regulated by oncostatin M-signalling produced by monocyte/macrophage cells [51]. A STAT3 activation in mesenchymal stem cells has also been reported [52].

CONCLUSION

Following administration of long-term high doses of zoledronic acid and molar extraction in a mouse model of bisphosphonates related to osteonecrosis of the jaw, we confirm that the cell components of alveolar BMUs were significantly disrupted (Supplementary appendix 3). The number of osteoblastic cells was dramatically reduced. In addition, the osteoclasts were inactivated, increased in number and exhibiting an aberrant morphology. The vascular precursors increased significantly after the intermediate-term treatment. Despite this evident cell imbalance, the alveolar bone mass increased, confirming that the effect of zoledronic acid is mostly antiresorptive rather than anti-anabolic in the alveolar operative site. In short, consistent histological and micro-architectural findings support the disruption of the normal homeostasis of alveolar BMUs induced by the administration of zoledronic acid, with an additional surgical dental stimulus. Further *in vivo* studies will be necessary for more in-depth study of the specific mechanisms involved in this disruption.

CONFLICT OF INTEREST

The authors declare that they have no conflict of interest.

ETHICAL APPROVAL:

All applicable international, national, and/or institutional guidelines for the care and use of animals were followed. All procedures performed in studies involving animals were in accordance with the ethical standards of the institution or practice at which the studies were conducted.”

REFERENCES

1. Ruggiero SL, Dodson TB, Assael LA, et al. (2009) American Association of Oral and Maxillofacial Surgeons position paper on bisphosphonate-related osteonecrosis of the jaws--2009 update. *J Oral Maxillofac Surg Off J Am Assoc Oral Maxillofac Surg* 67:2–12. doi: 10.1016/j.joms.2009.01.009
2. Wessel JH, Dodson TB, Zavras AI (2008) Zoledronate, Smoking, and Obesity Are Strong Risk Factors for Osteonecrosis of the Jaw: A Case-Control Study. *J Oral Maxillofac Surg* 66:625–631. doi: 10.1016/j.joms.2007.11.032
3. Basso FG, Silveira Turrioni AP, Hebling J, de Souza Costa CA (2013) Zoledronic acid inhibits human osteoblast activities. *Gerontology* 59:534–541. doi: 10.1159/000351194
4. Mawardi H, Giro G, Kajiya M, et al. (2011) A role of oral bacteria in bisphosphonate-induced osteonecrosis of the jaw. *J Dent Res* 90:1339–1345. doi: 10.1177/0022034511420430
5. Kim RH, Lee RS, Williams D, et al. (2011) Bisphosphonates Induce Senescence in Normal Human Oral Keratinocytes. *J Dent Res* 90:810–816. doi: 10.1177/0022034511402995
6. Allen MR, Burr DB (2009) The pathogenesis of bisphosphonate-related osteonecrosis of the jaw: so many hypotheses, so few data. *J Oral Maxillofac Surg Off J Am Assoc Oral Maxillofac Surg* 67:61–70. doi: 10.1016/j.joms.2009.01.007
7. Sims NA, Martin TJ (2014) Coupling the activities of bone formation and resorption: a multitude of signals within the basic multicellular unit. *BoneKEY Rep.* doi: 10.1038/bonekey.2013.215
8. Sims NA, Ng KW (2014) Implications of osteoblast-osteoclast interactions in the management of osteoporosis by antiresorptive agents denosumab and odanacatib. *Curr Osteoporos Rep* 12:98–106. doi: 10.1007/s11914-014-0196-1
9. Sakagami N, Amizuka N, Li M, et al. (2005) Reduced osteoblastic population and defective mineralization in osteopetrotic (op/op) mice. *Micron Oxf Engl* 1993 36:688–695. doi: 10.1016/j.micron.2005.06.008
10. Lesclous P, Abi Najm S, Carrel J-P, et al. (2009) Bisphosphonate-associated osteonecrosis of the jaw: a key role of inflammation? *Bone* 45:843–852. doi: 10.1016/j.bone.2009.07.011
11. Koch FP, Merkel C, Al-Nawas B, et al. (2011) Zoledronate, ibandronate and clodronate enhance osteoblast differentiation in a dose dependent manner--a quantitative in vitro gene expression analysis of *Dlx5*, *Runx2*, *OCN*, *MSX1* and *MSX2*. *J Cranio-Maxillo-fac Surg Off Publ Eur Assoc Cranio-Maxillo-fac Surg* 39:562–569. doi: 10.1016/j.jcms.2010.10.007
12. Manzano-Moreno FJ, Ramos-Torrecillas J, De Luna-Bertos E, et al. (2015) High doses of bisphosphonates reduce osteoblast-like cell proliferation by arresting the cell cycle and inducing apoptosis. *J Cranio-Maxillo-fac Surg Off Publ Eur Assoc Cranio-Maxillo-fac Surg* 43:396–401. doi: 10.1016/j.jcms.2014.12.008
13. Pozzi S, Vallet S, Mukherjee S, et al. (2009) High-Dose Zoledronic Acid Impacts Bone Remodeling with Effects on Osteoblastic Lineage and Bone Mechanical Properties. *Clin Cancer Res* 15:5829–5839. doi: 10.1158/1078-0432.CCR-09-0426
14. Gobin B, Battaglia S, Lanel R, et al. (2014) NVP-BEZ235, a dual PI3K/mTOR inhibitor, inhibits osteosarcoma cell proliferation and tumor development in vivo with

- an improved survival rate. *Cancer Lett* 344:291–298. doi: 10.1016/j.canlet.2013.11.017
15. Gobin B, Huin MB, Lamoureux F, et al. (2014) BYL719, a new α -specific PI3K inhibitor: Single administration and in combination with conventional chemotherapy for the treatment of osteosarcoma. *Int J Cancer* n/a–n/a. doi: 10.1002/ijc.29040
 16. Lamoureux F, Baud'huin M, Rodriguez Calleja L, et al. (2014) Selective inhibition of BET bromodomain epigenetic signalling interferes with the bone-associated tumour vicious cycle. *Nat Commun*. doi: 10.1038/ncomms4511
 17. Allen MR, Burr DB (2008) Mandible matrix necrosis in beagle dogs after 3 years of daily oral bisphosphonate treatment. *J Oral Maxillofac Surg Off J Am Assoc Oral Maxillofac Surg* 66:987–994. doi: 10.1016/j.joms.2008.01.038
 18. Heymann D (2010) Bisphosphonates and bone diseases: past, present and future. *Curr Pharm Des* 16:2948–2949.
 19. Heymann D, Ory B, Gouin F, et al. (2004) Bisphosphonates: new therapeutic agents for the treatment of bone tumors. *Trends Mol Med* 10:337–343. doi: 10.1016/j.molmed.2004.05.007
 20. Le Goff B, Guillot P, Glémarec J, et al. (2010) A comparison between bisphosphonates and other treatments for osteoporosis. *Curr Pharm Des* 16:3037–3044.
 21. Pazianas M (2011) Osteonecrosis of the jaw and the role of macrophages. *J Natl Cancer Inst* 103:232–40. doi: 10.1093/jnci/djq516
 22. Bi Y, Gao Y, Ehrchiou D, et al. (2010) Bisphosphonates cause osteonecrosis of the jaw-like disease in mice. *Am J Pathol* 177:280–290. doi: 10.2353/ajpath.2010.090592
 23. Raje N, Woo S-B, Hande K, et al. (2008) Clinical, Radiographic, and Biochemical Characterization of Multiple Myeloma Patients with Osteonecrosis of the Jaw. *Clin Cancer Res* 14:2387–2395. doi: 10.1158/1078-0432.CCR-07-1430
 24. Marx RE (2003) Pamidronate (Aredia) and zoledronate (Zometa) induced avascular necrosis of the jaws: a growing epidemic. *J Oral Maxillofac Surg Off J Am Assoc Oral Maxillofac Surg* 61:1115–1117.
 25. Marino KL, Zakhary I, Abdelsayed RA, et al. (2011) Development of a Rat Model of Bisphosphonate-Related Osteonecrosis of the Jaw (BRONJ). *J Oral Implantol* 110909140919004. doi: 10.1563/AAID-JOI-D-11-00057
 26. Okazaki S, Nishitani Y, Nagoya S, et al. (2009) Femoral head osteonecrosis can be caused by disruption of the systemic immune response via the toll-like receptor 4 signalling pathway. *Rheumatology* 48:227–232. doi: 10.1093/rheumatology/ken462
 27. Aghaloo TL, Kang B, Sung EC, et al. (2011) Periodontal disease and bisphosphonates induce osteonecrosis of the jaws in the rat. *J Bone Miner Res* 26:1871–1882. doi: 10.1002/jbmr.379
 28. Marx RE, Sawatari Y, Fortin M, Broumand V (2005) Bisphosphonate-Induced Exposed Bone (Osteonecrosis/Osteopetrosis) of the Jaws: Risk Factors, Recognition, Prevention, and Treatment. *J Oral Maxillofac Surg* 63:1567–1575. doi: 10.1016/j.joms.2005.07.010
 29. Allen MR (2008) Skeletal accumulation of bisphosphonates: implications for osteoporosis treatment. *Expert Opin Drug Metab Toxicol* 4:1371–1378. doi: 10.1517/17425255.4.11.1371
 30. Aguirre JI, Akhter MP, Kimmel DB, et al. (2012) Oncologic doses of zoledronic acid induce osteonecrosis of the jaw-like lesions in rice rats (*Oryzomys palustris*) with periodontitis. *J Bone Miner Res Off J Am Soc Bone Miner Res* 27:2130–2143. doi: 10.1002/jbmr.1669
 31. Hoff AO, Toth BB, Altundag K, et al. (2008) Frequency and risk factors associated with osteonecrosis of the jaw in cancer patients treated with intravenous

- bisphosphonates. *J Bone Miner Res Off J Am Soc Bone Miner Res* 23:826–836. doi: 10.1359/jbmr.080205
32. Daubiné F, Le Gall C, Gasser J, et al. (2007) Antitumor effects of clinical dosing regimens of bisphosphonates in experimental breast cancer bone metastasis. *J Natl Cancer Inst* 99:322–330. doi: 10.1093/jnci/djk054
33. Williams DW, Lee C, Kim T, et al. Impaired Bone Resorption and Woven Bone Formation Are Associated with Development of Osteonecrosis of the Jaw-Like Lesions by Bisphosphonate and Anti- Receptor Activator of NF- κ B Ligand Antibody in Mice. *Am J Pathol*. doi: 10.1016/j.ajpath.2014.07.010
34. Doh R-M, Park H-J, Rhee Y, et al. (2015) Teriparatide therapy for bisphosphonate-related osteonecrosis of the jaw associated with dental implants. *Implant Dent* 24:222–226. doi: 10.1097/ID.0000000000000232
35. Khan A, Morrison A, Ruggiero S, et al. (2015) Response to Comments on “Diagnosis and Management of Osteoporosis of the Jaw: A Systematic Review and International Consensus.” *J Bone Min Res*. doi: 10.1002/jbmr.2524
36. Weinstein RS, Roberson PK, Manolagas SC (2009) Giant Osteoclast Formation and Long-Term Oral Bisphosphonate Therapy. *N Engl J Med* 360:53–62. doi: 10.1056/NEJMoa0802633
37. Jobke B, Pfeifer M, Minne HW (2009) Teriparatide Following Bisphosphonates: Initial and Long-Term Effects on Microarchitecture and Bone Remodeling at the Human Iliac Crest. *Connect Tissue Res* 50:46–54. doi: 10.1080/03008200802412462
38. Jobke B (2009) Giant osteoclast formation and long-term oral bisphosphonate therapy. *N Engl J Med* 360:1676; author reply 1677–1678. doi: 10.1056/NEJMc090167
39. Roelofs AJ, Thompson K, Gordon S, Rogers MJ (2006) Molecular Mechanisms of Action of Bisphosphonates: Current Status. *Clin Cancer Res* 12:6222s–6230s. doi: 10.1158/1078-0432.CCR-06-0843
40. Kim HKW (2007) Osteonecrosis and osteonecrosis of the jaw (ONJ). *J Musculoskelet Neuronal Interact* 7:348–349.
41. Hansen T, Kunkel M, Weber A, James Kirkpatrick C (2006) Osteonecrosis of the jaws in patients treated with bisphosphonates - histomorphologic analysis in comparison with infected osteoradionecrosis. *J Oral Pathol Med Off Publ Int Assoc Oral Pathol Am Acad Oral Pathol* 35:155–160. doi: 10.1111/j.1600-0714.2006.00391.x
42. Santini D, Vincenzi B, Dicuonzo G, et al. (2003) Zoledronic Acid Induces Significant and Long-Lasting Modifications of Circulating Angiogenic Factors in Cancer Patients. *Clin Cancer Res* 9:2893–2897.
43. Estilo CL, Fornier M, Farooki A, et al. (2008) Osteonecrosis of the jaw related to bevacizumab. *J Clin Oncol Off J Am Soc Clin Oncol* 26:4037–4038. doi: 10.1200/JCO.2007.15.5424
44. Lescaille G, Coudert AE, Baaroun V, et al. (2014) Clinical study evaluating the effect of bevacizumab on the severity of zoledronic acid-related osteonecrosis of the jaw in cancer patients. *Bone* 58:103–107. doi: 10.1016/j.bone.2013.10.002
45. Ziebart T, Pabst A, Klein MO, et al. (2011) Bisphosphonates: restrictions for vasculogenesis and angiogenesis: inhibition of cell function of endothelial progenitor cells and mature endothelial cells in vitro. *Clin Oral Investig* 15:105–111. doi: 10.1007/s00784-009-0365-2
46. Walter C, Pabst A, Ziebart T, et al. (2011) Bisphosphonates affect migration ability and cell viability of HUVEC, fibroblasts and osteoblasts in vitro. *Oral Dis* 17:194–199. doi: 10.1111/j.1601-0825.2010.01720.x
47. Wood J, Bonjean K, Ruetz S, et al. (2002) Novel antiangiogenic effects of the

bisphosphonate compound zoledronic acid. *J Pharmacol Exp Ther* 302:1055–1061. doi: 10.1124/jpet.102.035295

48. Fournier P, Boissier S, Filleur S, et al. (2002) Bisphosphonates inhibit angiogenesis in vitro and testosterone-stimulated vascular regrowth in the ventral prostate in castrated rats. *Cancer Res* 62:6538–6544.

49. Stresing V, Fournier PG, Bellahcène A, et al. (2011) Nitrogen-containing bisphosphonates can inhibit angiogenesis in vivo without the involvement of farnesyl pyrophosphate synthase. *Bone* 48:259–266. doi: 10.1016/j.bone.2010.09.035

50. Pabst AM, Ziebart T, Ackermann M, et al. (2014) Bisphosphonates' antiangiogenic potency in the development of bisphosphonate-associated osteonecrosis of the jaws: influence on microvessel sprouting in an in vivo 3D Matrigel assay. *Clin Oral Investig* 18:1015–1022. doi: 10.1007/s00784-013-1060-x

51. Guihard P, Danger Y, Brounais B, et al. (2012) Induction of Osteogenesis in Mesenchymal Stem Cells by Activated Monocytes/Macrophages Depends on Oncostatin M Signaling. *STEM CELLS* 30:762–772. doi: 10.1002/stem.1040

52. Nicolaidou V, Wong MM, Redpath AN, et al. (2012) Monocytes Induce STAT3 Activation in Human Mesenchymal Stem Cells to Promote Osteoblast Formation. *PLoS ONE* 7:e39871. doi: 10.1371/journal.pone.0039871

FIGURE AND TABLE LEGENDS

Table 1: Experimental design. Number of mouse or samples included per group or per assay.

Figure 1: Zoledronic acid and a surgically-induced mouse model of osteonecrosis of the jaw (BONJ) assessed at intermediate and long-term treatment time points. (A) Clinical view of the sequestrum after the intermediate term treatment (black arrows); (B) Masson's trichrome stained slides showing empty lacunae (black arrows) in the sequestrum and submucosal bone of alveolar BMUs and (C) number of empty lacunae within the assessed area. (BMUs, basic multicellular units; w6, intermediate assessment; w12, long delay assessment; ZOL, zoledronic acid; NaCl, sodium chloride; ROI, region of interest; $**p<0.01$).

Figure 2: Osteoblast number decreases in alveolar BMUs after zoledronic acid treatment and molar extraction. Immunodetection of osteoblasts (osterix⁺ cells) confirms that ZOL-treated mice show a significant decrease in the number of osteoblastic cells in alveolar BMUs at both time points assessed. (BMUs, basic multicellular units; week 6 (w6), intermediate assessment; w12, long-term assessment; ZOL, zoledronic acid; NaCl, sodium chloride; ROI, region of interest; $*p<0.05$).

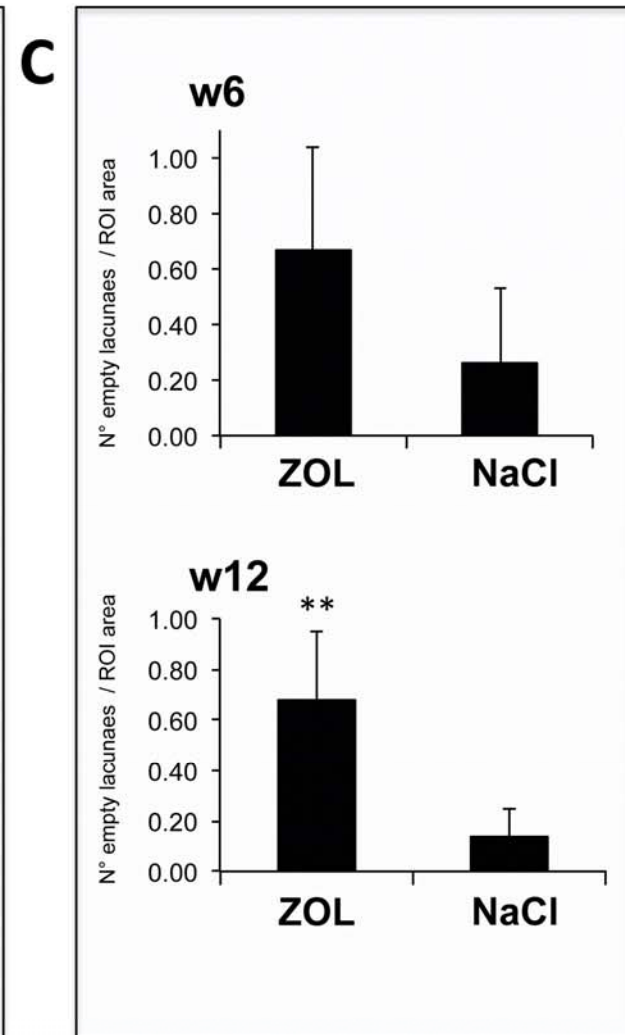

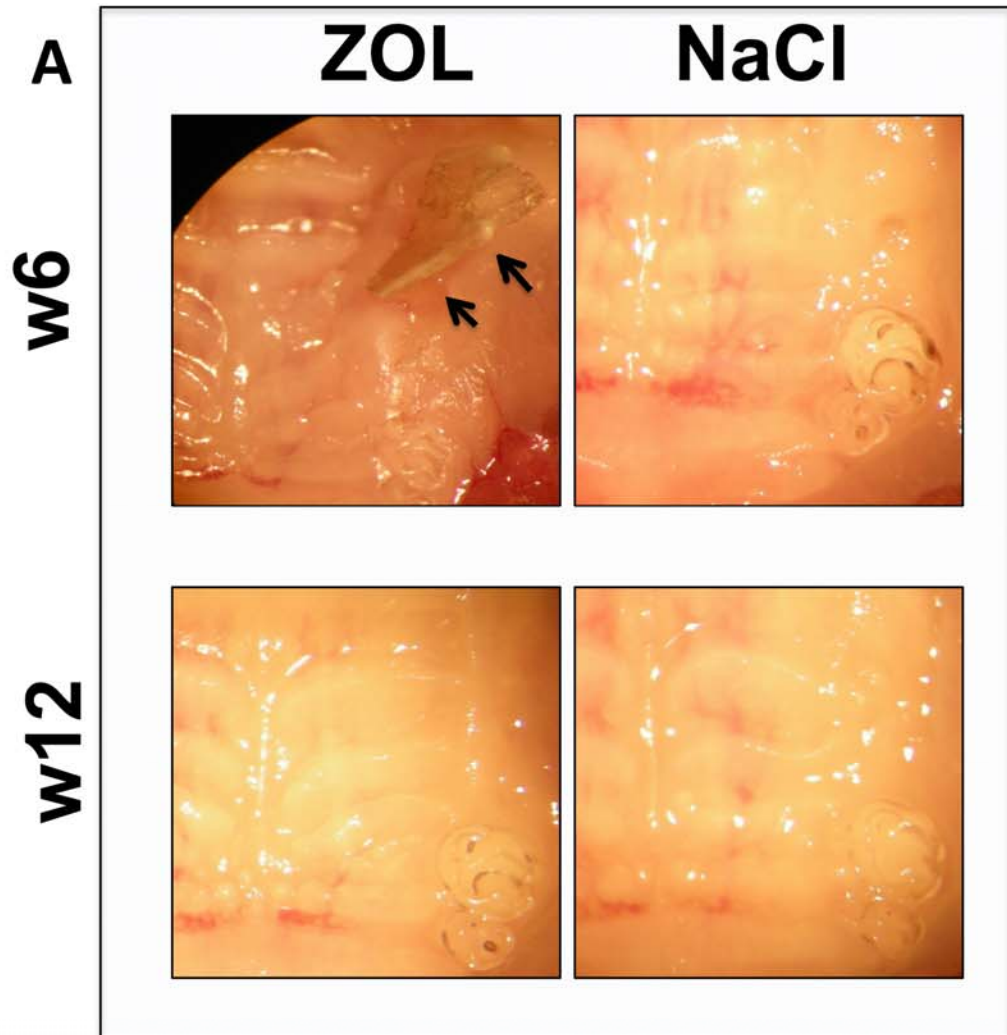
Figure 3: An increased number of dysmorphic osteoclasts were observed in alveolar BMUs after zoledronic acid treatment and molar extraction. TRAP-stained slices showing the aberrant morphology of the osteoclasts and a significant increase in the percentage of TRAP⁺ cells observed in alveolar BMUs after intermediate and long-term administration of zoledronic acid. (BMUs, basic multicellular units; week 6 (w6), intermediate assessment; w12, long-term assessment; ZOL, zoledronic acid; NaCl, sodium chloride; $*p<0.05$ and $**p<0.01$).

Figure 4: Bone volume of the extraction socket is upmodulated by bisphosphonate treatment and molar extraction. Microarchitectural assessment shows an increase in the bone volume in alveolar BMUs at the long-term time point. (2D, two dimensional view; 3D, tridimensional view; 2M, second maxillary left molar; 3M, third maxillary left molar; BMUs, basic multicellular units; week 6, (w6) intermediate assessment; w12, long delay assessment; ZOL, zoledronic acid; NaCl, sodium chloride; VOI, volume of interest; $*p<0.05$).

FIGURE LEGEND OF SUPPLEMENTARY APPENDIX

Supplementary appendix 2: CD146⁺ perivascular cells are affected in alveolar BMUs by the intermediate zoledronic acid treatment associated with molar extraction. Immunodetection of CD146⁺ cells confirms that ZOL-treated mice show a significant increase in the number of perivascular cells (black arrows) in alveolar BMUs at the intermediate delay. (BMUs, basic multicellular units; week 6 (w6), intermediate assessment; w12, long delay assessment; ZOL, zoledronic acid; NaCl, sodium chloride; ROI, region of interest; $*p<0.05$).

Supplementary appendix 3: Disruption of cell components of alveolar BMUs by zoledronic acid.



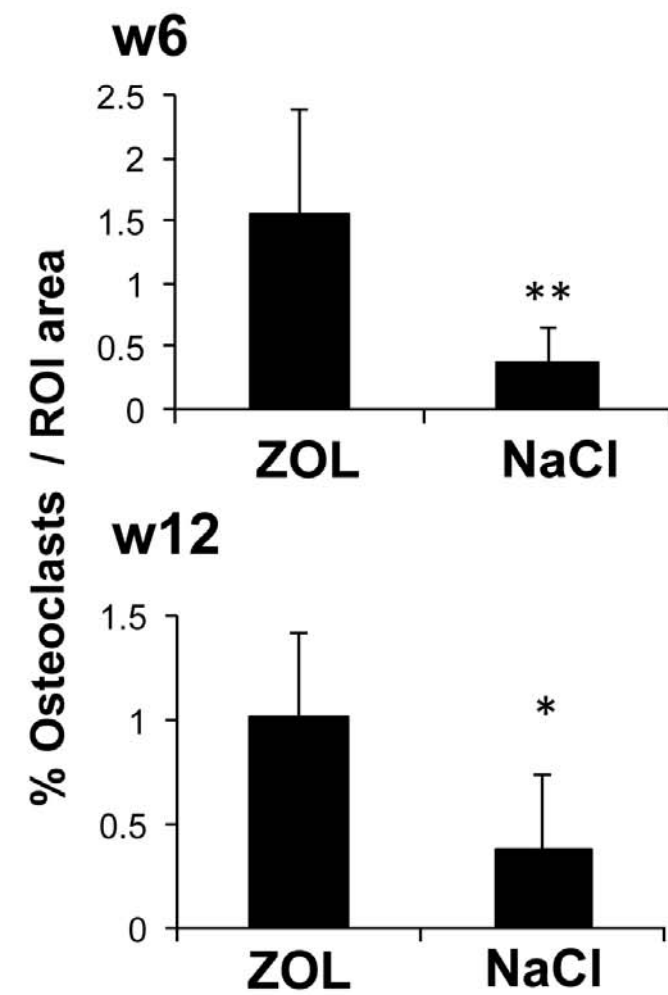
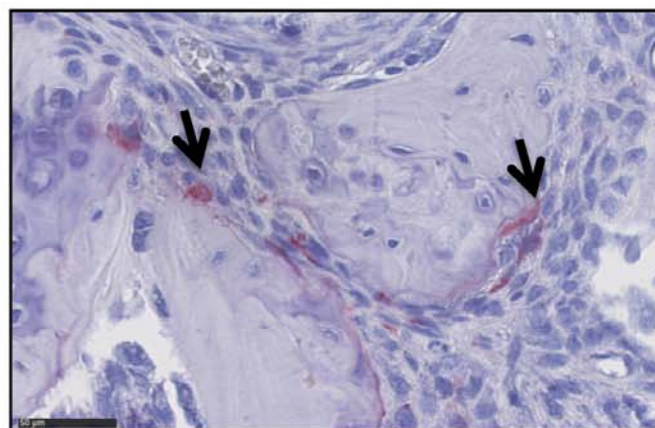
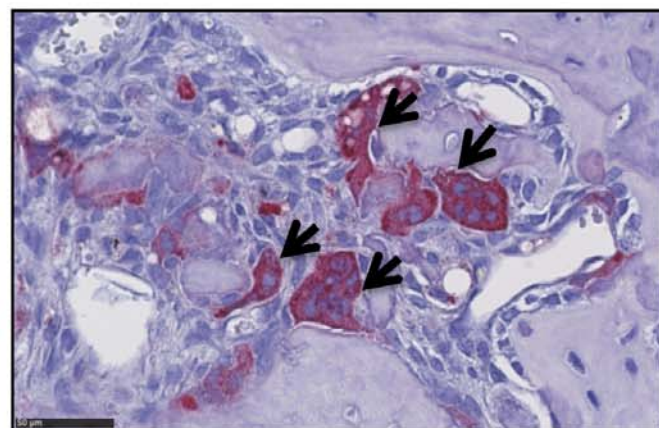
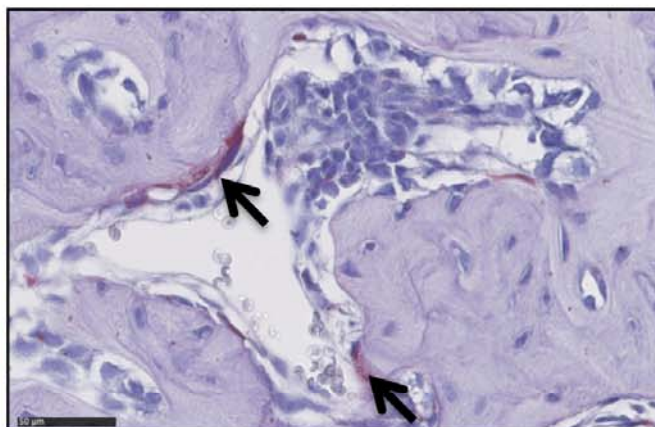
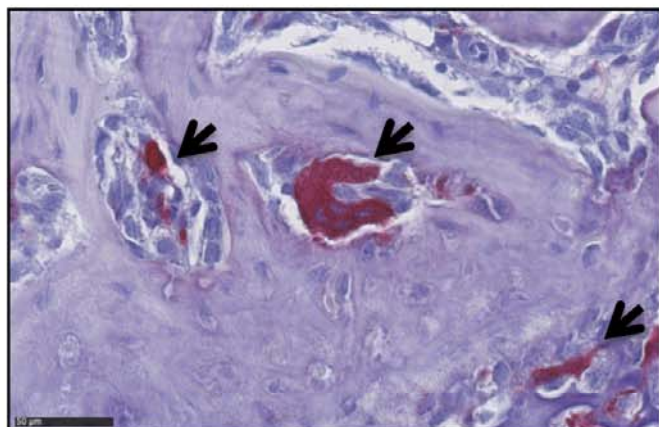
TRAP

w6

w12

ZOL

NaCl



OSTERIX

