



HAL
open science

Comparison of inhomogeneity distortion correction methods in diffusion MRI of the spinal cord

Haykel Snoussi, Emmanuel Caruyer, Olivier Commowick, Elise Bannier, Anne Kerbrat, Christian Barillot

► **To cite this version:**

Haykel Snoussi, Emmanuel Caruyer, Olivier Commowick, Elise Bannier, Anne Kerbrat, et al.. Comparison of inhomogeneity distortion correction methods in diffusion MRI of the spinal cord. ESMRMB - 34th Annual Scientific Meeting European Society for Magnetic Resonance in Medicine and Biology, Oct 2017, Barcelone, Spain. inserm-01579134v2

HAL Id: inserm-01579134

<https://inserm.hal.science/inserm-01579134v2>

Submitted on 26 Feb 2019

HAL is a multi-disciplinary open access archive for the deposit and dissemination of scientific research documents, whether they are published or not. The documents may come from teaching and research institutions in France or abroad, or from public or private research centers.

L'archive ouverte pluridisciplinaire **HAL**, est destinée au dépôt et à la diffusion de documents scientifiques de niveau recherche, publiés ou non, émanant des établissements d'enseignement et de recherche français ou étrangers, des laboratoires publics ou privés.

Comparison of inhomogeneity distortion correction methods in diffusion MRI of the spinal cord

Haykel Snoussi¹, Emmanuel Caruyer^{1,2}, Olivier Commowick¹, Elise Bannier^{1,3}, Anne Kerbrat³, Christian Barillot^{1,2}

¹ VisAGeS Reseach Unit, Inria Rennes - Bretagne Atlantique, France

² CNRS, IRISA UMR 6074, Rennes, France

³ Centre Hospitalier Universitaire de Rennes, Neurinfo platform, France

1 Introduction

Diffusion MRI (dMRI) is a modality that describes the geometry of neural architecture. Diffusion images suffer from various artifacts originating from subject and physiological motion, eddy currents and B0-field inhomogeneity. These can severely affect image quality particularly in the spine region. However, strategies exist to correct these distortions, including co-registration, point spread function, phase field map and reversed gradient polarity method (RGPM). In this work, we focus on the comparative evaluation of correction methods using RGPM which provides best results [1]. More precisely, we compared Voss [1, 2] plus two other recent methods: Topup (FSL) [3] and HySCO (ACID/SPM) [4].

2 Subjects and Methods

Data acquisition: 116 dMRI datasets were acquired on 61 multiple sclerosis subjects and 9 healthy volunteers (between 1 and 3 yearly visits/subject) from Rennes and Montpellier hospitals (3T Siemens Verio and Skyra, respectively) using the following parameters: sagittal orientation, TR/TE=3600/90ms, $2 \times 2 \times 2 \text{mm}^3$ resolution, 6 $b=0$ and 30 non-collinear DWI (900 s.mm^{-2}) plus one $b=0$ image with reverse phase-encoding direction. After a conservative quality control (see below), we kept 69 acquisitions.

Quality control: In order not to bias the distortion correction comparison, we eliminated images with too many artifacts not related to B0-field inhomogeneity (motion, ghosting) and acquisitions for which rigid registration between anatomical and diffusion failed.

Comparing distortion correction methods: The whole spinal cord was segmented using the Spinal Cord Toolbox [5] on a T2-weighted scan to obtain a binary mask which is registered to the first $b=0$ volume. Cross-correlation was computed (Fig. 1) between each corrected dMRI and the rigidly registered T2 image (Fig. 2), only within the spinal cord region.

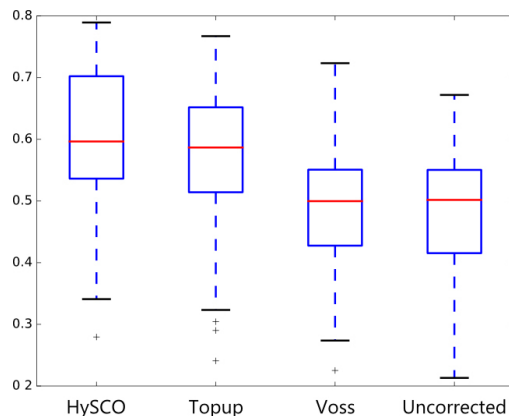


Fig. 1. Cross-correlation between T2 and corrected $b=0$ diffusion images

3 Results

ANOVA was performed on the cross-correlation scores, and confirmed that there is a significant improvement using correction distortion ($F=19.8$, $p=1.2710^{-11}$). Further, a Tukeys test showed that both HySCO and Topup perform better than Voss and uncorrected ($p<210^{-4}$). However there is no significant difference between Voss and no correction. This last result is in contradiction with [1] which included 3 datasets, while we report results on 69 acquisitions.

Another finding (data not reported) is that changing the order in which RGPM images are given as input (first $F>H$ then $H>F$, or reverse) yields different results, albeit no significant difference was noted.

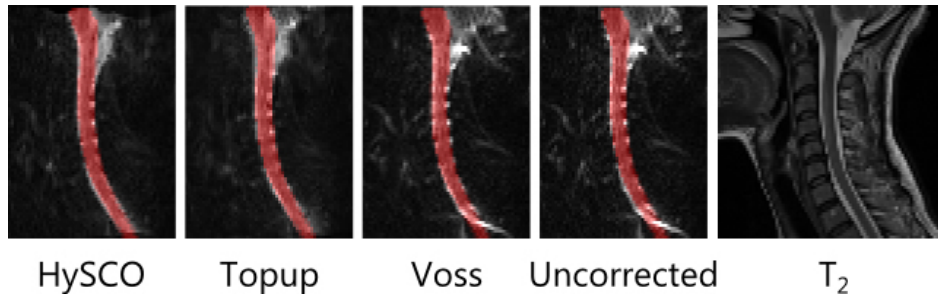


Fig. 2. Example of a corrected $b=0$ volume; the mask of the spine computed using T_2 and registered to the diffusion image is overlaid

4 Discussion and Conclusion

This comparative study conducted on 69 images confirms that performing a distortion correction step gives better alignment with anatomical image which is important for the accuracy of the subsequent analysis; out of the 3 methods tested, HySCO and Topup provide best results.

Acknowledgments

MRI data acquisition was supported by the Neurinfo MRI research facility from the University of Rennes I. Neurinfo is granted by the the European Union (FEDER), the French State, the Brittany Council, Rennes Metropole, Inria, Inserm and the University Hospital of Rennes.

References

1. J. Cohen-Adad, H. Lundell, and S. Rossignol, "Distortion correction in spinal cord dti: what's the best approach," in *Proceedings of the 17th Annual Meeting of ISMRM, Honolulu, USA*, vol. 3178, 2009.
2. H. U. Voss, R. Watts, A. M. Uluğ, and D. Ballon, "Fiber tracking in the cervical spine and inferior brain regions with reversed gradient diffusion tensor imaging," *Magnetic resonance imaging*, vol. 24, no. 3, pp. 231–239, 2006.
3. J. L. Andersson, S. Skare, and J. Ashburner, "How to correct susceptibility distortions in spin-echo echo-planar images: application to diffusion tensor imaging," *Neuroimage*, vol. 20, no. 2, pp. 870–888, 2003.
4. L. Ruthotto, H. Kugel, J. Olesch, B. Fischer, J. Modersitzki, M. Burger, and C. Wolters, "Diffeomorphic susceptibility artifact correction of diffusion-weighted magnetic resonance images," *Physics in Medicine & Biology*, vol. 57, no. 18, p. 5715, 2012.
5. B. De Leener, S. Lévy, S. M. Dupont, V. S. Fonov, N. Stikov, D. L. Collins, V. Callot, and J. Cohen-Adad, "Sct: Spinal cord toolbox, an open-source software for processing spinal cord mri data," *Neuroimage*, vol. 145, pp. 24–43, 2017.