



**HAL**  
open science

## **Donor-Derived Keratinocytes in Actinic Keratosis and Squamous Cell Carcinoma in Patients with Kidney Transplant**

Laurence Verneuil, Mariana Varna, Christophe Leboeuf, Louis François Plassa, Morad Elbouchtaoui, Irmine Loisel-Ferreira, Fatiha Bouhidel, Marie-Noelle Peraldi, Celeste Lebbé, Philippe Ratajczak, et al.

### ► To cite this version:

Laurence Verneuil, Mariana Varna, Christophe Leboeuf, Louis François Plassa, Morad Elbouchtaoui, et al.. Donor-Derived Keratinocytes in Actinic Keratosis and Squamous Cell Carcinoma in Patients with Kidney Transplant. *Journal of Investigative Dermatology*, 2012, 133 ((4)), pp.1108-1111. <10.1038/jid.2012.422>. <inserm-01397779>

**HAL Id: inserm-01397779**

**<https://inserm.hal.science/inserm-01397779v1>**

Submitted on 16 Nov 2016

HAL is a multi-disciplinary open access archive for the deposit and dissemination of scientific research documents, whether they are published or not. The documents may come from teaching and research institutions in France or abroad, or from public or private research centers.

L'archive ouverte pluridisciplinaire HAL, est destinée au dépôt et à la diffusion de documents scientifiques de niveau recherche, publiés ou non, émanant des établissements d'enseignement et de recherche français ou étrangers, des laboratoires publics ou privés.



HAL Authorization

# Donor-Derived Keratinocytes in Actinic Keratosis and Squamous Cell Carcinoma in Patients with Kidney Transplant

*Journal of Investigative Dermatology* (2013) 133, 1108–1111; doi:10.1038/jid.2012.422; published online 29 November 2012

## TO THE EDITOR

The homing ability of hematopoietic stem cells has enabled their therapeutic use. We have previously shown in allogeneic hematopoietic stem-cell recipients that donor-derived cells can be detected in skin in acute graft-versus-host disease (Murata *et al.*, 2007) and in squamous cell carcinoma (SCC) of the oral mucosa (Janin *et al.*, 2009). In kidney transplant recipients, population-based studies show an increased risk of skin SCC (Moloney *et al.*, 2006; Wisgerhof *et al.*, 2010), which are remarkable for: (i) their incidence, 250 times higher than in the normal population (Mackenzie *et al.*, 2010), (ii) their prevalence over basal cell carcinoma, (iii) the fact that they are multiple, and (iv) their association with multiple actinic keratosis (AK). Donor-derived cells have been identified in one case of basal cell carcinoma (Aractingi *et al.*, 2005). Here we address the question of the presence of donor-derived cells in skin SCC and in associated AK in kidney transplant recipients.

In three patients with AK and SCC who had received sex-mismatched kidney transplants, and for whom remaining tissue samples and DNA from donor and recipient were available, we conducted a chimerism study using four independent methods, FISH for X and Y chromosome detection, ZFYqPCR, polymorphic microsatellite analyses, and HRM on mitochondrial DNA (Supplementary Data online). The study was approved by the Institutional Review Board of Hôpital Saint-Louis (Paris, France) and written informed consent was obtained according to the Helsinki Declaration.

AK and SCC lesions included in this study were not contiguous, but 5 to 10 cm apart.

XY-FISH combined with cytokeratin on the same tissue section showed cytokeratin-positive cells with the donor genotype in two female recipients of male kidney transplants. The percentage of chimeric cells was 4% in the SCC and 2% in the two AKs studied for Patient 1 (Figure 1a), and 5% in the SCC and 3 and 0% in the two AKs studied for Patient 2 (Table 1). Chimeric XY cells were distributed in the basal layer in AK and in the basal layer and the invasive areas in SCC. No chimeric cell was found in normal surrounding skin. The third patient with sex-mismatched kidney transplant (Patient 3) was male, and no chimeric XX cytokeratin-positive cell was found in his SCC or AK.

As donor-derived cells were only found in female recipients of male kidney transplants, we performed a qPCR for ZFY gene on AK and SCC tissue sections, which confirmed the presence of the Y chromosome in Patient 1 SCC and two AKs (Figure 1b) and Patient 2 SCC and one of the two AKs studied.

To check these chromosomal results using completely different methods, which also associated molecular markers and morphological selection of cell populations, we performed microsatellite PCR and HRM analyses on laser-microdissected cells. Laser microdissection, performed on tissue sections after immunostaining of inflammatory cells, enabled us to collect only keratinocytes from the basal layer in AK and keratinocytes from the basal layer and from invasive areas in the dermis in SCC (Figure 1c). The polymorphic microsatellite marker analyses performed on laser-microdissected cells confirmed the presence of cells of donor origin in the SCC and two AKs of Patient 1, using four different

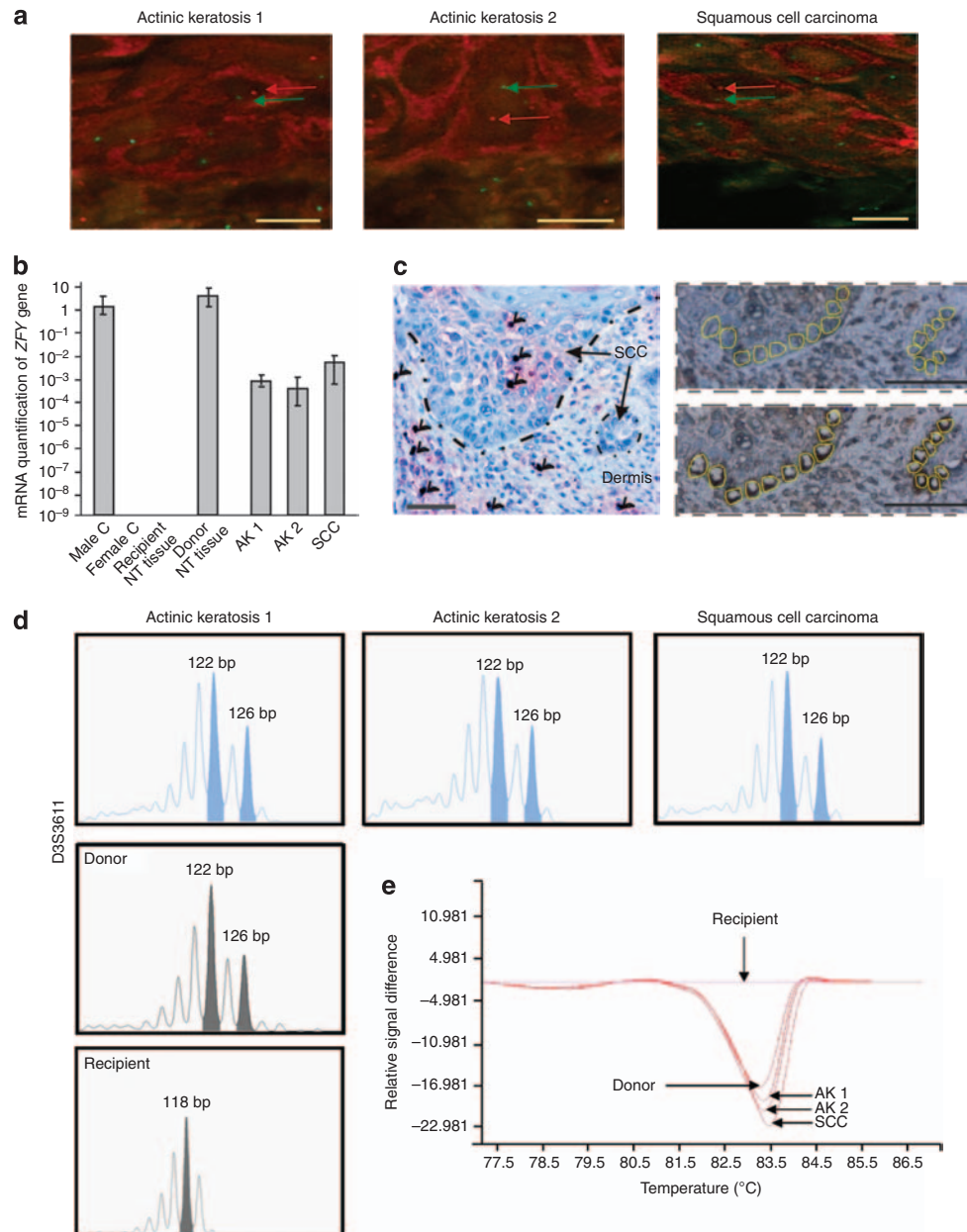
dinucleotide repeats: D3S3611, D5S2095, D8S1820, and D9S162 (as shown for D3S3611 in Figure 1d). It also confirmed the presence of cells of donor origin in the SCC and one AK of Patient 2, using three different dinucleotide repeats: D3S1597, D5S2095, and D8S1820. Polymorphic microsatellite analyses D3S3611, D8S1820, and D17S1879 showed recipient origin for Patient 3 SCC and AK.

We performed mitochondrial DNA HRM in the same samples of laser-microdissected keratinocytes from AK and SCC. This second independent method also showed the presence of cells of donor origin in the SCC and two AKs of Patient 1 (Figure 1e), and in the SCC and one AK of Patient 2. The cells of the SCC and AK of Patient 3 were all of recipient origin.

Altogether, we provide conclusive evidence for the presence of donor-derived basal keratinocytes in AK, and of donor-derived basal and invasive keratinocytes in skin SCC in two kidney transplant recipients.

These data imply the homing of stem/progenitor cells from the kidney transplants to the recipients' skin. For the homing of stem/progenitor cells from adult kidney to the skin, no experimental data are available. Multipotent progenitor cells from Bowman's capsule in adult human kidney have been isolated and characterized (Sagrinati *et al.*, 2006), but a transfer of mesenchymal stem cells with the transplant cannot be excluded.

Using combined XY-FISH and immunostaining on whole tissue sections enabled us to observe that chimeric cells were only present in SCC and AK, and not in normal peripheral skin. In addition, the donor-derived cells we identified in SCC were located in the basal layer and in invasive areas, which correspond to the "outer proliferating layer" where tumor-initiating cells have recently



**Figure 1. Cells of same donor origin in AK and SCC in Patient 1.** (a) Using FISH-XY, cytokeratin-positive basal cells with an X (green) Y (red) genotype are detected in AK and SCC. Scale bars = 10  $\mu$ m. (b) PCR detects Y chromosome in the two AKs and SCCs of the female recipient. (c) Laser microdissection of CD45-negative basal and invasive cells in SCC. Arrows: CD45-positive cells. Scale bars = 100  $\mu$ m. (d) Comparison of DNA profiles from laser-microdissected keratinocytes from AK and SCC with donor and recipient normal cells. Microsatellite analysis at D3S3611 locus shows donor origin (base-pair 122 and base-pair 126) of the microdissected keratinocytes from the two AKs and the SCCs. (e) Mitochondrial DNA-HRM PCR shows similar profiles for laser-microdissected keratinocytes of the two AKs and SCCs, and for donor cells.

been characterized in skin SCC (Patel *et al.*, 2012). We also identified donor-derived cells in the basal layer of AK, which is usually considered as a benign disease, although molecular studies have shown frequent loss of heterozygosity (Rehman *et al.*, 1994) and gene expression patterns are in favor of a spectrum of disease progression from

normal human skin to AK and SCC (Padilla *et al.*, 2010). In our cases, the concentration of chimeric cells in AK and SCC could be linked to the tissue remodeling accompanying disease progression, as stem/progenitor cells are recruited to the sites of skin injuries in experimental conditions (Zong *et al.*, 2008), and tissue repair shares common

mechanisms with stem-cell renewal in carcinogenesis (Beachy *et al.*, 2004). In the kidney transplant recipients we studied, the precise role of chimeric stem cells in skin SCC oncogenesis remains to be established, but the detection of chimeric cells at the stage of AK is in favor of a multistep process in the disease progression.

**Table 1. XY-FISH data in AK and SCC of three sex-mismatched kidney transplant recipients**

Sex	Kidney transplantation		Skin tumor		XY FISH						
	Recipient/donor	Age at transplant (years)	Timelapse transplant-tumor (years)	Site	Type	XX	XY	Total	XX cells, %	XY cells, %	% Chimeric cells, corrected <sup>1</sup>
<i>Patients with skin tumor after sex-mismatched kidney transplant</i>											
XY cells											
1	F/M	43	14	Forehead	SCC	66	4	107	61.7	3.7	5.9
			12	Forehead	AK	82	2	121	67.8	1.7	2.3
			12	Cheek	AK	68	2	117	58.1	1.7	2.4
2	F/M	46	3	Neck	SCC	60	5	98	61.2	5.1	8.1
			3	Neck	AK	88	3	132	66.7	2.3	3.3
			1	Neck	AK	95	0	141	67.4	0.0	0
XX cells											
3	MF	59	5	Nose	SCC	0	71	119	0.0	59.7	0
			4	Nose	AK	0	61	94	0.0	64.9	0
<i>Patient with skin tumor after sex-matched kidney transplantation</i>											
	M/M	43	7	Forehead	SCC	0	52	91	0.0	57.1	
			7	Forehead	AK	0	66	109	0.0	60.6	
<i>Patients with skin tumor without kidney transplantation (control)</i>											
	M			Nose	SCC	0	79	127	0.0	62.2	
				Cheek	AK	0	102	147	0.0	69.4	
	M			Leg	SCC	0	72	112	0.0	64.3	
				Leg	AK	0	101	141	0.0	71.6	

<sup>1</sup>Tumor samples from two patients with SCC and AK without kidney transplantation setting (control) were examined. To determine the efficiency of sex chromosome detection in basal and suprabasal layers of SCC and AK, a FISH-XY protocol was applied. Tumor sections from the two patients with SCC and AK were analyzed and the percent detection averaged for either SCC  $\{((79:127) + (72:112) \times 100) : 2 = 63.25\%$  or AK  $\{((102:147) + (101:141) \times 100) : 2 = 70.5\%$ . The normalization factor was derived by dividing 100% by the average percent for either SCC (100:63.25 = 1.58) or AK (100:70.5 = 1.42). Here the normalization factor was 1.42 and 1.58 for XX and XY cells detections of AK and SCC, respectively.

**CONFLICT OF INTEREST**

The authors state no conflict of interest.

**ACKNOWLEDGMENTS**

Grants were received from Région-Ile-de-France, Cancéropôle Ile-de-France, INCa, and ANR. LV is a Société-Française-Dermatologie grant recipient. A. Swaine assisted with language editing.

**Laurence Verneuil<sup>1,2,3,4</sup>, Mariana Varna<sup>1,2,5</sup>, Christophe Leboeuf<sup>4,2</sup>, Louis François Plassa<sup>6</sup>, Morad Elbouchtaoui<sup>1,2,5</sup>, Irmine Loisel-Ferreira<sup>1,2,5</sup>, Fatiha Bouhidel<sup>1,2,5</sup>, Marie-Noelle Peraldi<sup>2,7</sup>, Celeste Lebbe<sup>2,8</sup>, Philippe Ratajczak<sup>1,2</sup> and Anne Janin<sup>1,2,5</sup>**

<sup>1</sup>Inserm U728, Paris, France; <sup>2</sup>Laboratoire de Pathologie, UMR-S 728, Université Paris Diderot, Sorbonne Paris Cité, Paris, France; <sup>3</sup>Department of Dermatology, CHU Caen, Caen, France; <sup>4</sup>Université de Caen Basse-Normandie Medical School, Caen, France; <sup>5</sup>Department of Pathology, Hôpital Saint-Louis,

AP-HP, Paris, France; <sup>6</sup>Department of Biochemistry, Hôpital Saint-Louis, AP-HP, Paris, France; <sup>7</sup>Department of Nephrology, Hôpital Saint-Louis, AP-HP, Paris, France and <sup>8</sup>Department of Dermatology, Hôpital Saint-Louis, AP-HP, Paris, France  
E-mail: verneuil-l@chu-caen.fr or anne.janin728@gmail.com

**SUPPLEMENTARY MATERIAL**

Supplementary material is linked to the online version of the paper at <http://www.nature.com/jid>

**REFERENCES**

Aractingi S, Kanitakis J, Euvrard S et al. (2005) Skin carcinoma arising from donor cells in a kidney transplant recipient. *Cancer Res* 65:1755–60  
Beachy PA, Karhadkar SS, Berman DM (2004) Tissue repair and stem cell renewal in carcinogenesis. *Nature* 432:324–31  
Janin A, Murata H, Leboeuf C et al. (2009) Donor-derived oral squamous cell carcinoma after allogeneic bone marrow transplantation. *Blood* 113:1834–40

Mackenzie KA, Wells JE, Lynn KL et al. (2010) First and subsequent nonmelanoma skin cancers: incidence and predictors in a population of New Zealand renal transplant recipients. *Nephrol Dial Transplant* 25:300–6  
Moloney FJ, Comber H, O’Lorcain P et al. (2006) A population-based study of skin cancer incidence and prevalence in renal transplant recipients. *Br J Dermatol* 154:498–504  
Murata H, Janin A, Leboeuf C et al. (2007) Donor-derived cells and human graft-versus-host disease of the skin. *Blood* 109:2663–5  
Padilla RS, Sebastian S, Jiang Z et al. (2010) Gene expression patterns of normal human skin, actinic keratosis, and squamous cell carcinoma: a spectrum of disease progression. *Arch Dermatol* 146:288–93  
Patel GK, Yee CL, Terunuma A et al. (2012) Identification and characterization of tumor-initiating cells in human primary cutaneous squamous cell carcinoma. *J Invest Dermatol* 132:401–9  
Rehman I, Quinn AG, Healy E et al. (1994) High frequency of loss of heterozygosity in actinic keratoses, a usually benign disease. *Lancet* 344:788–9

Sagrinati C, Netti GS, Mazzinghi B *et al.* (2006) Isolation and characterization of multipotent progenitor cells from the Bowman's capsule of adult human kidneys. *J Am Soc Nephrol* 17:2443–56

Wisgerhof HC, Edelbroek JR, de Fijter JW *et al.* (2010) Subsequent squamous- and basal-cell carcinomas in kidney-transplant recipients after the first skin cancer: cumulative incidence and risk factors. *Transplantation* 89:1231–8

Zong ZW, Cheng TM, Su YP *et al.* (2008) Recruitment of transplanted dermal multipotent stem cells to sites of injury in rats with combined radiation and wound injury by interaction of SDF-1 and CXCR4. *Radiat Res* 170:444–50

## Evidence of Differentiation in Myeloid Malignancies Associated Neutrophilic Dermatitis: A Fluorescent *In Situ* Hybridization Study of 14 Patients

*Journal of Investigative Dermatology* (2013) 133, 1111–1114; doi:10.1038/jid.2012.408; published online 29 November 2012

### TO THE EDITOR

Neutrophilic dermatoses (NDs) are characterized by dense infiltrates of mature neutrophils typically located in the upper dermis. Despite having dissimilar clinical presentations, Sweet's syndrome, pyoderma gangrenosum, neutrophilic eccrine hidradenitis, and other related disorders are recognized as part of the spectrum of NDs because of their overlapping clinical and histopathological findings (Vignon-Pennamen and Wallach, 1991). Although most instances of ND have a benign course, some extracutaneous localizations of the neutrophilic infiltrates can be potentially life-threatening (Vignon-Pennamen, 2000).

Little is known about the pathophysiology of ND. The findings of high CD3, IL-1, IL-8, and tumor necrosis factor- $\alpha$  expressions by immunohistochemical staining in the dermis of ND patients (Marzano *et al.*, 2010) and the impressive effects of corticosteroids in alleviating these diseases have underlined a role for activated T lymphocytes in the recruitment of mature neutrophils to the dermis. Moreover, targeted immunosuppressive agents such as tumor necrosis factor- $\alpha$  inhibitors and the IL-1R inhibitor anakinra have been successfully used in the treatment of Sweet's syndrome, which has further emphasized the importance of these cytokines in the pathophysiology of

ND (Yamauchi *et al.*, 2006; Delluc *et al.*, 2008; Lipsker *et al.*, 2010).

Around 20% of patients with Sweet's syndrome have an underlying hematological malignancy, which is predominantly a myeloid neoplasm (Cohen *et al.*, 1988). In these cases, one could hypothesize that neutrophils have differentiated from the malignant clone, showing an aberrant phenotype, which promotes dermal invasion. In this model, neutrophils in the dermal infiltrate should be clonally related to the underlying myeloid malignancy, which has never been formally demonstrated to date.

We thus conducted a multicentric retrospective study, which included 14 ND patients (8 men and 6 women) with (1) a histopathological diagnosis of Sweet's syndrome ( $n=12$ ), pyoderma gangrenosum ( $n=1$ ), or neutrophilic eccrine hidradenitis ( $n=1$ ), and (2) a diagnosis of myelodysplastic syndrome (MDS,  $n=2$ ) or acute myeloid leukemia (AML,  $n=12$ ), and with a medullar cytogenetic abnormality that would be informative in a fluorescent *in situ* hybridization (FISH) study.

In two patients, the ND was present at the initial presentation of AML. This condition was chemotherapy-induced in seven patients and occurred without any identifiable trigger in four patients. All patients but one were febrile when the ND diagnosis was established, and

four patients had an extracutaneous involvement (lung ( $n=1$ ), muscle ( $n=1$ ), mouth ( $n=2$ )), which is a much higher frequency than what is reported in idiopathic ND (Vignon-Pennamen, 2000). No patient had concomitant neutrophil leukocytosis. Three patients were profoundly neutropenic at the time of ND occurrence. This observation confirms that hyperleukocytosis is irrelevant as a diagnostic criterion for ND associated with myeloid malignancies.

To test the hypothesis of a clonal relationship between the skin-infiltrating neutrophils and the bone marrow blasts, the FISH study was conducted on 3  $\mu$ m skin tissue sections processed using the Histology FISH Accessory Kit (Dako, Glostrup, Denmark). After hybridization with specific probes (Table 1), scoring of the hybridization signals was performed on 200 consecutive morphologically intact nuclei, with a normal cutoff value evaluated at 10% (Haralambieva *et al.*, 2002). This approach was noninformative in three patients because of an insufficient number of analyzable nuclei. Among the other 11 patients analyzed, 8 showed the same cytogenetic anomaly in the neutrophils infiltrating the skin and in the bone marrow (Figure 1), whereas there were no evidence of any clonal cytogenetic abnormality in the neutrophils of the remaining three patients.

A previous study using a HUMARA assay has found evidence of clonality in the skin neutrophils of 80% of women (median age 60 years) with ND, regardless of whether they had an underlying