



Clinical Features of Spontaneous Partial Healing During *Mycobacterium ulcerans* Infection

Estelle Marion, Annick Chauty, Marie Kempf, Yannick Le Corre, Yves Delneste, Anne Croue, Laurent Marsollier

► To cite this version:

Estelle Marion, Annick Chauty, Marie Kempf, Yannick Le Corre, Yves Delneste, et al.. Clinical Features of Spontaneous Partial Healing During *Mycobacterium ulcerans* Infection. Open Forum Infectious Diseases, 2016, 10.1093/ofid/ofw013 . inserm-01281366

HAL Id: inserm-01281366

<https://inserm.hal.science/inserm-01281366>

Submitted on 2 Mar 2016

HAL is a multi-disciplinary open access archive for the deposit and dissemination of scientific research documents, whether they are published or not. The documents may come from teaching and research institutions in France or abroad, or from public or private research centers.

L'archive ouverte pluridisciplinaire **HAL**, est destinée au dépôt et à la diffusion de documents scientifiques de niveau recherche, publiés ou non, émanant des établissements d'enseignement et de recherche français ou étrangers, des laboratoires publics ou privés.

Clinical Features of Spontaneous Partial Healing During *Mycobacterium ulcerans* Infection

Estelle Marion,^{1,2} Annick Chauty,¹ Marie Kempf,³ Yannick Le Corre,⁴ Yves Delneste,⁶ Anne Croue,⁵ and Laurent Marsollier²; for the Franco-Beninese Buruli Research Group

¹Centre de Dépistage et de Traitement de l'Ulçère de Buruli de Pobè, Fondation Raoul Follereau, Bénin; ²Atip/Avenir Team, Centre de Recherche en Cancérologie Nantes-Angers (CRCNA), Université et Centre Hospitalier Universitaire (CHU) d'Angers; ³Laboratoire de Bactériologie et d'Hygiène Hospitalière, ⁴Service de Dermatologie, ⁵Laboratoire d'Anatomie Pathologique, CHU d'Angers, ⁶Team "Innate Immunity", Université d'Angers, Labex IGO, France

Background. Buruli ulcer, caused by *Mycobacterium ulcerans*, is a necrotizing skin disease leading to extensive cutaneous and subcutaneous destruction and functional limitations. Spontaneous healing in the absence of medical treatment occurs in rare cases, but this has not been well described in the literature.

Methods. In a retrospective case study in an area of Benin where this disease is highly endemic, we selected 26 Buruli ulcer patients presenting features of spontaneous healing from a cohort of 545 Buruli ulcer patients treated between 2010 and 2013.

Results. The 26 patients studied had a median age of 13.5 years and were predominantly male (1.4:1). Three groups of patients were defined on the basis of their spontaneous healing characteristics. The first group (12 patients) consisted of patients with an ulcer of more than 1 year's duration showing signs of healing. The second (13 patients) group contained patients with an active Buruli ulcer lesion some distance away from a first lesion that had healed spontaneously. Finally, the third group contained a single patient displaying complete healing of lesions from a nodule, without treatment and with no relapse.

Conclusions. We defined several features of spontaneous healing in Buruli ulcer patients and highlighted the difficulties associated with diagnosis and medical management. Delays in consultation contributed to the high proportion of patients with permanent sequelae and a risk of squamous cell carcinoma. Early detection and antibiotic treatment are the best ways to reduce impairments.

Keywords. Buruli ulcer; *M ulcerans*; spontaneous healing.

Buruli ulcer is a neglected tropical disease caused by *Mycobacterium ulcerans*, an environmental mycobacterium. This skin infection, which mostly affects children, has emerged or re-emerged in the last 2 decades, particularly around the Gulf of Guinea in West Africa [1]. The route of transmission has yet to be clearly determined, but inoculation of the derma with the bacterium appears to be necessary [2]. After an estimated incubation period of a few weeks to several months, *M ulcerans* causes necrotizing hypodermatitis, in the form of a nodule, an edema, or a plaque [3]. After destruction of the subcutaneous tissue (caused by a cytotoxic, immunosuppressive and analgesic toxin called mycolactone [4–6]), the skin may break down, leading to the development of largely painless necrotic ulcers with characteristic undermined edges [7].

No specific vaccine against Buruli ulcer is currently available. Bacillus Calmette-Guérin (BCG) vaccination was initially thought to have incomplete but significant short-term protective effects [8, 9] or to confer partial protection against *M ulcerans* osteomyelitis [10]. However, other studies provided no evidence of a protective effect [11, 12] or even reported a higher risk of Buruli ulcer in adults and children over the age of 5 years that had been vaccinated with BCG [13].

The severity of Buruli ulcer lesions depends on their form, extent, and localization [14]. Indeed, early lesions (nonulcerative) may differ in clinical appearance (taking the form of a nodule, plaque, or edema), and these different forms progress differently. For example, a nodule may spontaneously progress to a small circumscribed ulcer, whereas an edema of the entire limb generally progresses to extensive ulceration with severe functional impairment [14, 15]. Other factors may also determine the severity of Buruli ulcer. These factors include human immunodeficiency virus coinfection [16–18] and time from onset to first consultation (which depends partly on local healthcare management) [19, 20].

Small Buruli ulcer lesion can be treated with a combination of rifampin and an aminoglycoside for 8 weeks, but larger lesions require additional extensive surgery in dedicated hospitals [21–23]. Even in cases of effective medical treatment, more than 20% of patients present permanent functional sequelae 1 year later [14].

Received 18 January 2016; accepted 22 January 2016.

Correspondence: E. Marion, CRCNA U892, Angers 49100, France (estelle.marion@inserm.fr).

Open Forum Infectious Diseases®

© The Author 2016. Published by Oxford University Press on behalf of the Infectious Diseases Society of America. This is an Open Access article distributed under the terms of the Creative Commons Attribution-NonCommercial-NoDerivs licence (<http://creativecommons.org/licenses/by-nc-nd/4.0/>), which permits non-commercial reproduction and distribution of the work, in any medium, provided the original work is not altered or transformed in any way, and that the work is properly cited. For commercial re-use, please contact journals.permissions@oup.com. DOI: 10.1093/ofid/ofw013

If left untreated, Buruli ulcers progress to chronic ulcerations with a risk of dissemination and bone destruction [14, 19, 24]. Although many publications mention the occurrence of spontaneous healing in some patients, the process remains poorly described or studied [7, 25–32]. Questions thus remain unresolved: Are healing cases rare in the Buruli ulcer context? What are the principal clinical features of this healing process?

In this context, we performed a retrospective study in a highly specialized Buruli ulcer diagnosis and treatment center in Benin. Moreover, we provide a comprehensive description of the various clinical presentations of the spontaneous partial healing of Buruli ulcer.

METHODS AND RESULTS

Study Design, Data Collection, and Definitions

A retrospective study was conducted at the Centre de Diagnostic et de Traitement de la Lèpre et de l'Ulcère de Buruli (CDTLUB) in Pobè, Benin, which has one of the largest databases for cases of Buruli ulcer confirmed by polymerase chain reaction (PCR) [14].

We first conducted a preliminary analysis of 545 Buruli ulcer patients treated at the CDTLUB in Pobè from 2010 to 2013. For the selection of medical records, we used several key words defined on the basis of publications in this field: spontaneous healing, spontaneous clearance, scar, old ulcer, scarring lesion. During this review step, medical records containing at least 1 of the chosen key words were selected. If the clinical records were incomplete (eg, lack of photographic monitoring, patients lost to follow-up), the patient was excluded.

The preselected clinical records were then fully examined and patient information was collected (including age, sex, date of onset, date of diagnosis, clinical features, past medical history, medical and laboratory analysis, lesion examination, imaging data, and clinical monitoring). None of the patients received pharmacological treatment for mycobacterial infection before consulting at the Centre de Dépistage et de Traitement de l'Ulcère de Buruli (CDTUB) Pobè.

Cohort Presentation

We selected 26 patients (sex ratio M/F=1.4), on the basis of our criteria, from the database of the CDTLUB. Median patient age at diagnosis was 13.5 years (5–70 years), with female patients tending to be older than male patients (Figure 1). The age distribution of male and female patients was similar to that for the entire population of 545 Buruli ulcer patients from 2010 to 2013 (Figure 1).

Almost all the patients (25 of 26) had category 3 lesions (World Health Organization nomenclature) presenting as single lesions of more than 15 cm in diameter or osteomyelitis, or multiple lesions, and/or lesions at critical sites. In 85% of patients (22 of 26), lesions were present on the lower limbs (59% for the total cohort, $P < .05$, Fisher test). Three patients presented multiple active Buruli ulcer lesions (2 patients with 2 lesions, 1 patient with 3 lesions).

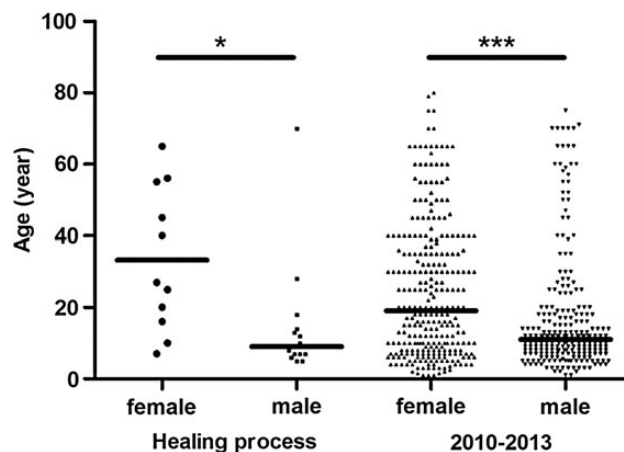


Figure 1. Age distribution, by sex, of Buruli ulcer patients in the spontaneous healing cohort and in the general cohort of patients seen between 2010 and 2013. The age distribution is similar for the 2 cohorts, with female patients older than male patients in both cohorts. Mann–Whitney U test; * $P < .05$, *** $P < .0001$.

We found that 77% (20 of 26) of patients had waited at least 1 year after the first signs of an active lesion before consulting at the CDTUB Pobè (13% for the total cohort, $P < .001$, Fisher test). Complete physical examination of body showed that 13 of the 26 patients had a healed scar with a stellate appearance consistent with an old Buruli ulcer lesion at some distance from the active lesion. An exhaustive study of the clinical records of each patient, including the clinical features of the lesion and the medical history of the patient, led us to define 3 groups on the basis of the healing process observed, as described below.

Group 1: Spontaneous Healing Process in Progress

Patients of this group ($n = 12$) typically had an ulcer that had been present on a limb for more than 1 year and was healing (Table 1). Seven of the 12 patients in this group were male (median age = 9 years) and 5 were female (median age = 25 years). The edges of the lesion were defined by skin repair and re-epithelialization processes (Figure 2). The lesions typically displayed no edema, plaque, necrosis, or acute inflammation (Figure 2). Despite the lack of specific clinical signs of Buruli ulcer, microbiological analysis based on PCR (73%), acid-fast bacilli (45%), and culture (9%) demonstrated the presence of *M ulcerans* infection (9%) (Table 1). Swabbing was difficult because the edges of the lesions had healed. Biological confirmation was obtained principally by biopsy during surgical repair (eg, debridement, skin graft). Most patients (75%) presented physical impairment on arrival at the center and, even with combined drug treatment and surgery, this impairment was irreversible in 42% of patients (Table 1). The need for surgery and rehabilitation resulted in hospitalization for 2 to 7 months. In 1 patient, the lesion progressed to squamous cell carcinoma 6 months after release from hospital and 3 years after the first signs of this lesion. The affected limb had to be amputated.

Table 1. Characteristics of Patients Presenting a Buruli Ulcer Lesion Undergoing Spontaneous Healing

Patient	Age, Years/ Sex	Clinical Form	Site	Patient Delay, Weeks	Hospital Stay, Days	Antibiotics	Surgery	PCR	Culture	DSE	Physical Impairment, Arrival	Physical Impairment, Final	Squamous Cell Carcinoma
1	7/F	U	LL	>52	73	C/R	No	NA	NA	NA	1	1	0
2	9/M	U	UL	30	78	S/R	Yes	+	–	+	0	0	0
3	7/M	U	UL	>52	105	S/R	Yes	+	–	+	1	1	0
4	14/M	U	UL	>52	219	S/R	Yes	+	–	–	1	1	0
5	18/M	U	LL	>52	56	S/R	No	–	–	–	1	1	0
6	20/F	U	UL	>52	155	S/R	Yes	–	–	–	1	1	1
7	10/M	U	UL	>52	99	S/R	Yes	+	–	+	1	1	0
8	65/F	U	UL	52	56	C/R	No	+	–	–	0	0	0
9	25/F	U	UL	18	75	S/R	Yes	+	–	+	1	0	0
10	55/F	U	UL	>52	122	C/R	Yes	+	–	–	0	0	0
11	5/M	U	UL	>52	127	C/R	Yes	–	–	–	1	1	0
12	6/M	U	UL	52	152	S/R	Yes	+	+	+	1	0	0
Mean	Age 20	U	83% LL	>52	110	100%	75%	73%	9%	36%	75%	58%	8%

Abbreviations: C/R, clarithromycin and rifampicin; DSE, direct smear examination; LL, lower limb; NA, not available; PCR, polymerase chain reaction; S/R, streptomycin and rifampicin; U, ulcer; UL, upper limb.

Group 2: Active Buruli Ulcer Lesion After Initial Spontaneous Healing

There were 13 patients in this group (n = 13): 8 were male (median age = 10 years) and 5 were female (median age = 40 years) (Table 2). Patients presented 1 (77%) or multiple (23%) active Buruli ulcer lesions, with bone involvement in 40% of the patients, mostly on the lower limbs. All of the active lesions

were biologically confirmed, at least by PCR. There was frequently a long interval between the onset of symptoms and consultation, with 77% of patients waiting more than 1 year after the onset of the active lesion before seeking medical attention (Table 2).

During medical examination, 1 or several stellate scars were observed, some distance away from the active lesion (Figure 3). The scars were located on the same lower limb as the active lesion, on the contralateral lower limb, upper limbs, abdomen, or head (Table 2). The history of the previous lesions and the appearance of the scars were consistent with the spontaneous healing of an old Buruli ulcer lesion. The interval between total healing of the previous lesion and the occurrence of the active lesion was highly variable: from 4 weeks to more than 1 year. Biological confirmation of *M ulcerans* infection was not performed on healed tissues at the consultation. However, in 2 cases, the need for surgery to minimize functional impairment made it possible to confirm the presence of *M ulcerans* DNA in the healed tissues.

On arrival, most patients (70%) presented physical impairments due to the spontaneously healed old lesion or the active lesion. After drug treatment (100% of patients) and surgery (92% patients), the patients continued to display functional damage. Limb amputation was required in 1 patient, due to the development of a squamous cell carcinoma at the site of the treated lesion after the completion of drug treatment. Hospital stay exceeded 120 days for 46% of the patients, due to the presence of extensive or multifocal lesions, osteomyelitis, or physical impairment.

Group 3: Complete Spontaneous Healing

One patient (n = 1) presented *M ulcerans* infection progressing spontaneously towards complete healing without treatment.

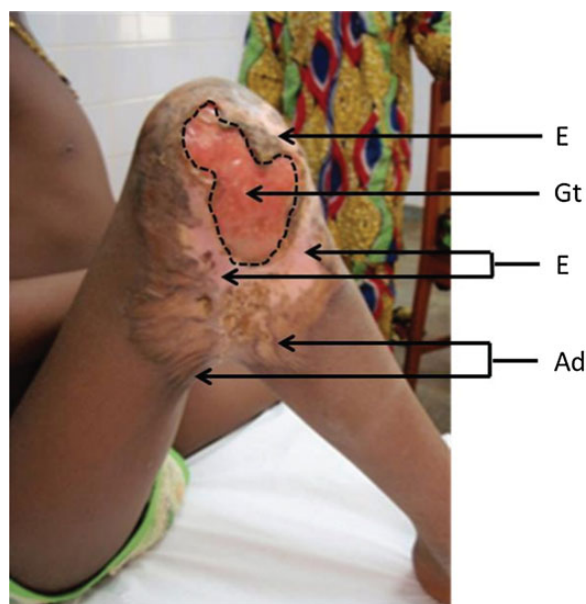


Figure 2. Typical case of group 1 spontaneous healing in progress (*Mycobacterium ulcerans* lesions with evidence of healing tissues). Clinical examination showed a large ulcer on the outside of the right knee, measuring approximately 10 × 6.5 cm, with a well demarcated border. The base of the ulcer was clean and there was granulation tissue. Partial healing was observed, and peripheral epithelialization was associated with adhesions restricting the motion of the joint. The black dotted line circumscribes the ulcerative area. Abbreviations: Ad, adhesion; E, peripheral epithelialization; Gt, granuloma tissue.

Table 2. Characteristics of Patients With an Active Buruli Ulcer Lesion Some Distance From a Spontaneously Healed Lesion

Patient	Age, Years/ Sex	Clinical Form	Site	Number of Active lesions	Distant Scar	Patient Delay, Weeks	Hospital Stay Days	Antibiotics	Surgery	PCR	Culture	DSE	Physical Impairment, Arrival	Physical Impairment, Final	Time to Second Lesion, Weeks ^a	Squamous Cell Carcinoma
1	10/F	EUoSC	2 LL	2	LL	>52	240	S/R	Yes	+ 2 UL	–	–	1	1	>52	0
2	12/M	UoSC	LL, UL	2	Back	>52	405	S/R	Yes	+ UL, LL	+ UL	+ UL, LL	1	1	>52	0
3	56/F	UC	2 UL	>2	2 UL	>52	120	S/R	Yes	+ UL	–	+ UL	1	1	>52	0
4	70/M	EUC	UL	1	UL	>52	55	S/R	Yes	+	–	+	1	1	NA	0
5	45/F	QUC	UL	1	UL	24	55	S/R	No	+	+	+	0	0	8	0
6	8/M	OC	UL	1	UL	12	40	S/R	Yes	+	–	+	0	0	4	0
7	28/M	UC	UL	1	UL	>52	120	S/R	Yes	+	–	–	1	1	>52	1
8	7/M	OsC	UL	1	Abdomen	>52	57	S/R	Yes	+	–	+	1	1	>52	0
9	16/F	UC	UL	1	UL	52	68	S/R	Yes	+	–	+	0	0	4	0
10	7/M	OsC	2 LL, 2 UL	1	2 UL, 1 LL	>52	70	S/R	Yes	+ UL	–	–	1	1	8	0
11	5/M	UC	Buttock	1	Head	36	65	C/R	Yes	+ Buttock	+	–	0	0	36	0
12	40/F	UC	UL	1	UL	>52	125	S/R	Yes	+	–	+	1	1	>52	0
13	13/M	OsC	2 UL, 1 LL	>2	UL, LL	>52	155	S/R	Yes	+ UL, LL	–	+ LL	1	1	>52	0
Mean	Age 24	38% Os	92% LL	30% multi		>52	121	100%	92%	100%	23%	69%	69%	69%	>52	8%

Abbreviations: C/R, clarithromycin and rifampicin; DSE, direct smear examination; E, edema; LL, lower limb; Os, osteomyelitis; Q, plaque; S/R, streptomycin and rifampicin; U, ulcer; UL, upper limb.
^aTime to second lesion provided by patient history.

The patient, a 27-year-old woman, presented a typical painless nodule (3 cm diameter) on the right arm. Fine-needle aspiration was performed on the nodule to confirm *M ulcerans* infection [33, 34]. *Mycobacterium ulcerans* was detected by PCR and Ziehl-Neelsen staining. Nodule excision or antibiotic treatment was refused by the patient. Two months after the first consultation, medical staff visited the patient and found that the nodule had disappeared, with a small induration in its place. During interviews, the patient and her family indicated that the patient had received no drug treatment or traditional treatment. Three months later, the patient was seen again. No active lesion was detectable and a small scar was visible (Figure 4). She was seen again 3 years later and had suffered no relapse during this period. This clinical case highlights the ability of some *M ulcerans* lesions to resolve spontaneously.

DISCUSSION

Spontaneous healing is known to occur in most infectious diseases [35–38]. However, there have been few descriptions of spontaneous healing in cases of *M ulcerans* infection. There is no medical consensus concerning the relevance of this process in this disease, mostly due to the lack of epidemiological studies. In this context, we conducted the first retrospective study of spontaneous healing, in which we reviewed 545 cases of Buruli ulcer.

We included 26 (4.7%) Buruli ulcer patients described as “presenting a spontaneous healing process”, according to our criteria. In most cases, the spontaneous healing was a lengthy process observed in old extensive Buruli ulcer lesions. The delay in seeking medical attention resulted in irreversible physical impairment in most patients. Furthermore, 2 patients subsequently displayed squamous cell carcinoma, which is not surprising because the depigmented scar of a healed lesion on black skin is a risk factor of this cancer.

Spontaneous healing may manifest in different ways, as highlighted by the 3 different clinical groups defined in this study. In group 1, the patients had old ulcerative lesions that were healing. This form is not typical of active Buruli ulcer lesions and its diagnosis is difficult, particularly given the difficulty obtaining samples for biological confirmation (absence of an undermined edge). Moreover, there are several differential diagnoses (varicose ulcers, for example), and the history of the disease recorded during the patient interview is critical to facilitate diagnosis. The patients in group 2 had an active lesion occurring at some distance from a typical Buruli ulcer scar [26, 27, 30]. Again, the history of this lesion is the key to associating the scar with a typical Buruli ulcer that healed spontaneously.

These observations of a spontaneous healing process demonstrate that patients can develop an immune response able to counteract the effects of *M ulcerans* and mycolactone and to promote tissue remodeling. The occurrence of a second active Buruli ulcer lesion at some distance from a healed lesion

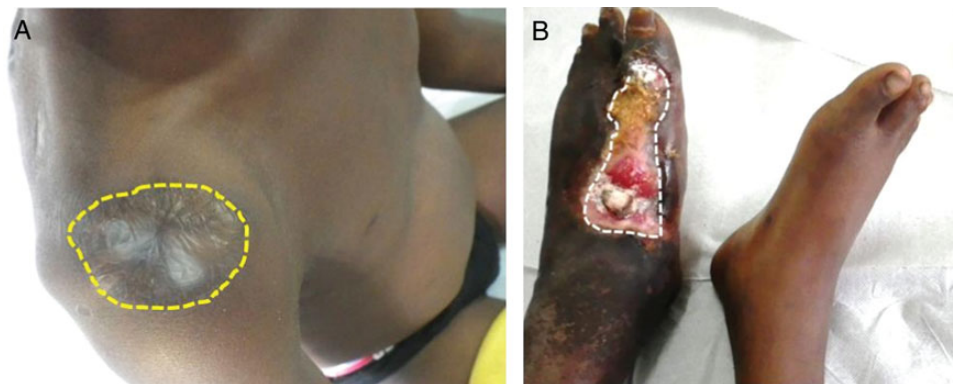

Figure 3. Typical group 2 clinical form (old spontaneously healed Buruli ulcer and an active lesion [n = 13]). The patient presented (A) a stellate scar on the upper part of the right arm, 8 cm in diameter (B) a typical active *Mycobacterium ulcerans* ulcerative lesion on the left foot, measuring approximately 10 × 5 cm. The lesion had undermined edges and was painless. *Mycobacterium ulcerans* infection was confirmed by polymerase chain reaction and acid-fast bacilli on tissue extracted from this lesion. The yellow dotted line circumscribes the scar area with a stellate appearance (edema). The white dotted line circumscribes the active lesion (ulceration).

suggests that the immune response involved in healing cannot sterilize the tissue, or even confer protection against *M. ulcerans*. Therefore, the development of a vaccine against *M. ulcerans* may be compromised. It seems unlikely that the occurrence of a second lesion is due to a second contamination event involving the inoculation of the skin with the bacillus. Given the high rate of osteomyelitis observed in second lesions, it seems more likely that *M. ulcerans* disseminates systemically, as suggested by other studies [14, 16, 19, 24].

The single patient in group 3 provides a formal demonstration of the possibility of spontaneous healing of Buruli ulcer without the intervention of Western or traditional medicine.

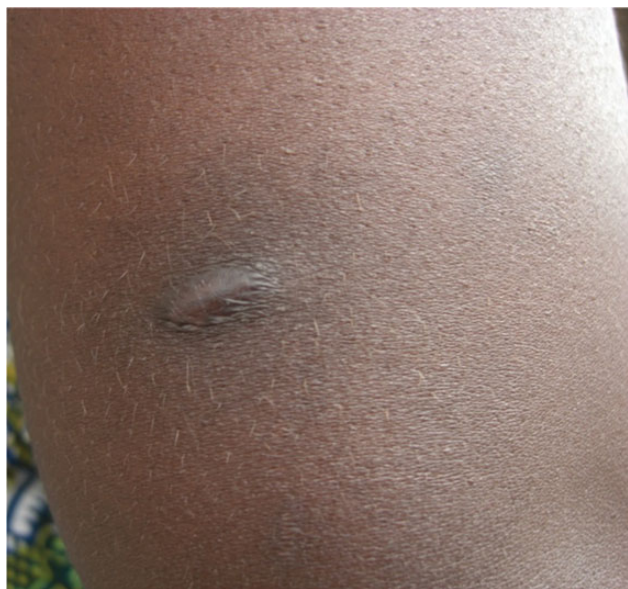

Figure 4. Complete spontaneous healing of a *Mycobacterium ulcerans* lesion. Scar resulting from the spontaneous complete healing of a nodule in a woman who received no treatment.

It is reasonable to assume that the number of cases of spontaneous healing is underestimated, because patients do not seek medical assistance for small, painless cutaneous lesions. Even though we cannot exclude that patients used traditional therapies before visiting the doctor, the potential impact of such therapies on the course of the disease remains highly speculative.

Finally, this study raises key questions about the contribution of bacterial and host factors to the documented heterogeneity of the clinical presentation of Buruli ulcer. We cannot rule out the possibility that bacterial strain affects virulence, adaptation, and ability to modulate the immune response. However, this effect is not likely to be the key determinant, because molecular [39] epidemiological studies have shown that *M. ulcerans* diversity is poor (within the same endemic area). In this context, our results suggest that host genetic factors are the key determinants of pathogen control governing the initiation of spontaneous healing.

CONCLUSIONS

It is not currently possible to characterize the pathophysiological aspects of spontaneous healing in patients with Buruli ulcer, given the small number of patients identified to date, the difficulty obtaining access to patients in areas where Buruli ulcer is endemic, and for ethical reasons. Furthermore, there is currently no satisfactory experimental model for dissecting the molecular pathway underlying the process of spontaneous healing in Buruli ulcer, and such a model would facilitate the development of treatments to induce healing in patients.

Acknowledgments

Members of the Franco-Beninese Buruli Research Group are as follows: Quentin B. Vincent (Laboratory of Human Genetics of Infectious Diseases, Necker Branch, Institut National de la Recherche Médicale [INSERM] U1163 and Université Paris Descartes, Sorbonne Paris Cité, Institut Imagine, Paris, France); Laurent Abel (Laboratory of Human Genetics of Infectious Diseases, Necker Branch, INSERM U1163 and Université Paris Descartes, Sorbonne Paris Cité, Institut Imagine, Paris, France and

St. Giles Laboratory of Human Genetics of Infectious Diseases, Rockefeller Branch, Rockefeller University, New York, NY); Christian Johnson (Fondation Raoul Follereau, Paris, France); Alexandre Alcaïs (Laboratory of Human Genetics of Infectious Diseases, Necker Branch, INSERM U1163, Université Paris Descartes, Sorbonne Paris Cité, Institut Imagine, and Unité de Recherche Clinique, Paris Centre Descartes Necker Cochin, Assistance Publique-Hôpitaux de Paris, Paris, France, and St. Giles Laboratory of Human Genetics of Infectious Diseases, Rockefeller Branch, Rockefeller University, New York, NY); Estelle Marion and Laurent Marsollier (Atip/Avenir Team, CRCNA, INSERM U892 et CNRS U6299, Université et CHU d'Angers, Angers, France); Marie Kempf (Laboratoire de Bactériologie, CHU d'Angers, Angers, France); Jean-Paul Saint-André (Laboratoire d'Anatomie Pathologique, CHU d'Angers, Angers, France); Ambroise Adeye (Centre de Dépistage et de Traitement de l'Ulcère de Buruli, Pobè, Benin); Annick Chauty (Fondation Raoul Follereau, Paris, France and Centre de Dépistage et de Traitement de l'Ulcère de Buruli, Pobè, Benin); Didier Agossadou (Programme de Lutte Contre la Lèpre et l'Ulcère de Buruli, Ministère de la Santé, Cotonou, Bénin).

Financial support. This work was funded by Institut Nationale de la Santé et de la Recherche Médicale, Atip Avenir Program, Agence Nationale de Recherche (ANR) sur le Sida et les Hépatites, BU_SPONT_HEAL Project (Infect-ERA, ANR), Région Pays de la Loire, and Fondation Raoul Follereau-France.

Potential conflicts of interest. All authors: No reported conflicts. All authors have submitted the ICMJE Form for Disclosure of Potential Conflicts of Interest.

References

- Huang GK, Johnson PD. Epidemiology and management of Buruli ulcer. *Expert Rev Anti Infect Ther* **2014**; 12:855–65.
- Williamson HR, Mosi L, Donnell R, et al. *Mycobacterium ulcerans* fails to infect through skin abrasions in a guinea pig infection model: implications for transmission. *PLoS Negl Trop Dis* **2014**; 8:e2770.
- Trubiano JA, Lavender CJ, Fyfe JA, et al. The incubation period of Buruli ulcer (*Mycobacterium ulcerans* infection). *PLoS Negl Trop Dis* **2013**; 7:e2463.
- George KM, Chatterjee D, Gunawardana G, et al. Mycolactone: a polyketide toxin from *Mycobacterium ulcerans* required for virulence. *Science* **1999**; 283:854–7.
- Marion E, Song OR, Christophe T, et al. Mycobacterial toxin induces analgesia in Buruli ulcer by targeting the angiotensin pathways. *Cell* **2014**; 157:1565–76.
- Torrado E, Adusumilli S, Fraga AG, et al. Mycolactone-mediated inhibition of tumor necrosis factor production by macrophages infected with *Mycobacterium ulcerans* has implications for the control of infection. *Infect Immun* **2007**; 75:3979–88.
- Asiedu K, Sherpbier R, Raviglione MC. Buruli ulcer *Mycobacterium ulcerans* infection. W.H.O. Global Buruli Ulcer Initiative. Report 2000. Geneva: World Health Organization; **2000**.
- Uganda Buruli Group. BCG vaccination against *Mycobacterium ulcerans* infection (Buruli ulcer). First results of a trial in Uganda. *Lancet* **1969**; 1:111–5.
- Smith PG, Revell WD, Lukwago E, Rykushin YP. The protective effect of BCG against *Mycobacterium ulcerans* disease: a controlled trial in an endemic area of Uganda. *Trans R Soc Trop Med Hyg* **1976**; 70:449–57.
- Portaels F, Aguiar J, Debacker M, et al. *Mycobacterium bovis* BCG vaccination as prophylaxis against *Mycobacterium ulcerans* osteomyelitis in Buruli ulcer disease. *Infect Immun* **2004**; 72:62–5.
- Pouillot R, Matias G, Wondje CM, et al. Risk factors for Buruli ulcer: a case control study in Cameroon. *PLoS Negl Trop Dis* **2007**; 1:e101.
- Nackers F, Dramaix M, Johnson RC, et al. BCG vaccine effectiveness against Buruli ulcer: a case-control study in Benin. *Am J Trop Med Hyg* **2006**; 75:768–74.
- Debacker M, Portaels F, Aguiar J, et al. Risk factors for Buruli ulcer, Benin. *Emerg Infect Dis* **2006**; 12:1325–31.
- Vincent QB, Ardant MF, Adeye A, et al. Clinical epidemiology of laboratory-confirmed Buruli ulcer in Benin: a cohort study. *Lancet Glob Health* **2014**; 2:e422–30.
- O'Brien DP, Friedman ND, McDonald A, et al. Clinical features and risk factors of oedematous *Mycobacterium ulcerans* lesions in an Australian population: beware cellulitis in an endemic area. *PLoS Negl Trop Dis* **2014**; 8:e2612.
- Johnson RC, Ifebe D, Hans-Moevi A, et al. Disseminated *Mycobacterium ulcerans* disease in an HIV-positive patient: a case study. *AIDS* **2002**; 16:1704–5.
- Kibadi K, Colebunders R, Muyembe-Tamfum JJ, et al. Buruli ulcer lesions in HIV-positive patient. *Emerg Infect Dis* **2010**; 16:738–9.
- Vincent QB, Ardant MF, Marsollier L, et al. HIV infection and Buruli ulcer in Africa. *Lancet Infect Dis* **2014**; 14:796–7.
- Pommelet V, Vincent Q, Ardant MF, et al. Analysis of 81 osteomyelitis cases from a cohort of 1,257 PCR-confirmed *Mycobacterium ulcerans* infections in Benin. *Clin Infect Dis* **2014**; 59:1256–64.
- Marion E, Carolan K, Adeye A, et al. Buruli ulcer in South Western Nigeria: a retrospective cohort study of patients treated in Benin. *PLoS Negl Trop Dis* **2015**; 9:e3443.
- Converse PJ, Nuermberger EL, Almeida DV, Grosset JH. Treating *Mycobacterium ulcerans* disease (Buruli ulcer): from surgery to antibiotics, is the pill mightier than the knife? *Future Microbiol* **2011**; 6:1185–98.
- World Health Organization. Treatment of *Mycobacterium ulcerans* (Buruli Ulcer): Guidance for Health Workers. Geneva: World Health Organization; **2012**.
- Chauty A, Ardant MF, Marsollier L, et al. Oral treatment for *Mycobacterium ulcerans* infection: results from a pilot study in Benin. *Clin Infect Dis* **2011**; 52:94–6.
- Lagarigue V, Portaels F, Meyers WM, Aguiar J. Buruli ulcer: risk of bone involvement! Apropos of 33 cases observed in Benin. *Med Trop (Mars)* **2000**; 60:262–6.
- Portaels F, Silva MT, Meyers WM. Buruli ulcer. *Clin Dermatol* **2009**; 27:291–305.
- van der Werf TS, van der Graaf WT, Tappero JW, Asiedu K. *Mycobacterium ulcerans* infection. *Lancet* **1999**; 354:1013–8.
- Gordon CL, Buntine JA, Hayman JA, et al. Spontaneous clearance of *Mycobacterium ulcerans* in a case of Buruli ulcer. *PLoS Negl Trop Dis* **2011**; 5:e1290.
- Dega H, Chosidow O, Barete S, et al. *Mycobacterium ulcerans* infection. *Ann Med Interne (Paris)* **2000**; 151:339–44.
- Herbinger KH, Beissner M, Huber K, et al. Efficiency of fine-needle aspiration compared with other sampling techniques for laboratory diagnosis of Buruli ulcer disease. *J Clin Microbiol* **2010**; 48:3732–4.
- Muelder K, Nourou A. Buruli ulcer in Benin. *Lancet* **1990**; 336:1109–11.
- Walsh DS, Portaels F, Meyers WM. Buruli ulcer (*Mycobacterium ulcerans* infection). *Trans R Soc Trop Med Hyg* **2008**; 102:969–78.
- Meyers WM. Mycobacterial infections of the skin. In: Doerr W, Seifert G, eds. *Tropical Pathology*. Berlin: Springer-Verlag; **1995**; 9:291–377.
- Eddyani M, Fraga AG, Schmitt F, et al. Fine-needle aspiration, an efficient sampling technique for bacteriological diagnosis of nonulcerative Buruli ulcer. *J Clin Microbiol* **2009**; 47:1700–4.
- Phillips RO, Sarfo FS, Osei-Sarpong F, et al. Sensitivity of PCR targeting *Mycobacterium ulcerans* by use of fine-needle aspirates for diagnosis of Buruli ulcer. *J Clin Microbiol* **2009**; 47:924–6.
- Morizot G, Delgiudice P, Caumes E, et al. Healing of Old World cutaneous leishmaniasis in travelers treated with fluconazole: drug effect or spontaneous evolution? *Am J Trop Med Hyg* **2007**; 76:48–52.
- Costa JM, Saldanha AC, Silva CM, et al. Spontaneous regional healing of extensive skin lesions in diffuse cutaneous Leishmaniasis (DCL). *Rev Soc Bras Med Trop* **1995**; 28:45–7.
- Jesudasan K, Christian M. Spontaneous healing in paucibacillary leprosy. *Indian J Med Res* **1985**; 81:119–22.
- Browne SG. Self-healing leprosy: report on 2749 patients. *Lepr Rev* **1974**; 45:104–11.
- Ablordey AS, Vandellannoote K, Frimpong IA, et al. Whole genome comparisons suggest random distribution of *Mycobacterium ulcerans* genotypes in a Buruli ulcer endemic region of Ghana. *PLoS Negl Trop Dis* **2015**; 9:e0003681.