



HAL
open science

An overview of cardiac morphogenesis.

Jean-Marc Schleich, Tariq Abdulla, Ron Summers, Lucile Houyel

► **To cite this version:**

Jean-Marc Schleich, Tariq Abdulla, Ron Summers, Lucile Houyel. An overview of cardiac morphogenesis.. Archives of cardiovascular diseases, 2013, 106 (11), pp.612-23. 10.1016/j.acvd.2013.07.001 . inserm-00941964

HAL Id: inserm-00941964

<https://inserm.hal.science/inserm-00941964>

Submitted on 4 Feb 2014

HAL is a multi-disciplinary open access archive for the deposit and dissemination of scientific research documents, whether they are published or not. The documents may come from teaching and research institutions in France or abroad, or from public or private research centers.

L'archive ouverte pluridisciplinaire **HAL**, est destinée au dépôt et à la diffusion de documents scientifiques de niveau recherche, publiés ou non, émanant des établissements d'enseignement et de recherche français ou étrangers, des laboratoires publics ou privés.

An overview of cardiac morphogenesis

Une anthologie du développement cardiaque normal

Jean-Marc Schleich^{a,*}, Tariq Abdulla^b, Ron Summers^b, Lucile Houyel^c

^a *Service de Cardiologie et de Maladies Vasculaires, Hôpital de Pontchaillou; INSERM U 1099; Université de Rennes, LTSI, Rennes, France*

^b *Department of Electronic, Electrical and Systems Engineering, Loughborough University, Loughborough, UK*

^c *Service de Chirurgie des Cardiopathies Congénitales, Hôpital Marie-Lannelongue, Le Plessis-Robinson, France*

* Corresponding author. Service de Cardiologie et de Maladies Vasculaires, Hôpital de Pontchaillou, 35033 Rennes Cedex 09, France.

Tel: +33 2 99 28 25 17. Fax: +33 2 99 28 25 18.

E-mail address: jean-marc.schleich@chu-rennes.fr (J.-M. Schleich).

Word count: 8755

Summary

Accurate knowledge of normal cardiac development is essential for properly understanding the morphogenesis of congenital cardiac malformations that represent the most common congenital anomaly in newborns. The heart is the first organ to function during embryonic development and is fully formed at 8 weeks of gestation. Recent studies stemming from molecular genetics have allowed specification of the role of cellular precursors in the field of heart development. In this article we review the different steps of heart development, focusing on the processes of alignment and septation. We also show, as often as possible, the links between abnormalities of cardiac development and the main congenital heart defects. The development of animal models has permitted the unravelling of many mechanisms that potentially lead to cardiac malformations. A next step towards a better knowledge of cardiac development could be multiscale cardiac modelling.

Résumé

La connaissance du développement normal du cœur est essentielle pour la compréhension de la genèse des malformations cardiaques congénitales, lesquelles représentent l'anomalie congénitale la plus fréquente chez le nouveau-né. Le cœur est le premier organe à se former durant le développement de l'embryon et sa formation se termine vers la huitième semaine de grossesse. Les études récentes provenant de la génétique moléculaire ont permis de spécifier le rôle des précurseurs cellulaires dans le champ du développement cardiaque. Dans cet article, nous décrivons les différentes étapes du développement cardiaque en insistant sur les processus d'alignement et de septation. Nous montrons aussi souvent que possible les liens entre les anomalies du développement cardiaque et les principales malformations cardiaques congénitales. Le développement des modèles animaux a permis de révéler de nombreux mécanismes à l'origine des malformations cardiaques. La prochaine étape pour une meilleure compréhension du développement cardiaque pourrait être la modélisation cardiaque multi niveaux.

KEYWORDS

Normal heart development;

Embryology;

Cardiac morphogenesis;

Congenital heart defects

MOTS CLÉS

Développement cardiaque normal ;

Embryologie ;

Morphogénèse cardiaque

Cardiopathies congénitales

Abbreviations: AV, atrioventricular; FHF, first heart field; OT, outflow tract; SHF, second heart field; VSD, ventricular septal defect; WG, week(s) of gestation.

Background

The first functioning organ in the embryo is the heart. It begins to beat from 2 weeks of gestation (WG) onwards (4 weeks of amenorrhea) and is fully formed at 8 WG. The development of the heart is highly conserved through evolution and follows the same general pattern in all vertebrates. Fusion of the primary heart tubes is followed by a rightward looping of the newly formed linear heart tube, differentiation of the chambers and valves, and development of the conduction system and coronary circulation.

Congenital heart defects represent the most common congenital anomaly in newborns, with a prevalence of 8–10 per 1000 births [1]. Delineating the normal sequence of heart development is essential for understanding the morphogenesis of congenital cardiac malformations. However, studying cardiac embryology is no easy task because it involves intricate structures and functions that evolve in space and time, and are closely interrelated. Moreover, understanding the developing heart requires a three-dimensional conceptualization that remains very complex for a human mind. In this article, the major processes involved in all stages of normal heart development are reviewed. Particular focus is given to those processes essential to the correct alignment and septation of cardiac structures. This provides a narrative through which congenital heart defects may be investigated, as sequential disruption of normal development.

The beginnings: formation of the primitive heart tube (days 15–21)

The heart starts to form at the beginning of the third WG. By the end of the second WG (day 15), the embryo is a flat disc made of two cell layers: the epiblast and the hypoblast. The primitive streak, which establishes the longitudinal axis of the embryo, appears at the median and caudal parts of the embryonic disc. At day 16, the epiblastic cells migrate towards the primitive streak and invaginate (gastrulation), leading to the differentiation of the embryo into three layers: ectoderm, mesoderm and endoderm.

The heart derives from the anterior mesoderm. At this stage, the mesodermal cells are still precardiac cells. However, the different axes of the embryo are already predetermined, particularly the left-right axis. Mesodermal cells differentiate into cardiac cells in response to

induction signals from the endoderm, such as bone morphogenetic protein [2]. In the mesoderm, there are five transcription factors that are considered to be the primordial genes involved in cardiac development and these are highly conserved through the evolution of animal species: NKX2.5, Mef2, GATA, Tbx and Hand [3]. This ancestral genetic network controls the fate of the cardiac cells, the expression of protein-coding genes and cardiac morphogenesis. These genes regulate themselves and control their expression [3]. Precardiac cells are multipotent and differentiate into myocardial, endothelial and smooth muscle cells by a phenomenon called progressive lineage restriction [4]. Myocardial cells thus differentiate into chamber-specific myocytes (atrial and ventricular) and conduction cells [5].

Mesodermal precardiac cells migrate towards the cephalic pole of the embryo to form the cardiogenic crescent or first heart field (FHF). With cephalic then lateral inflexion of the embryo, the crescent migrates anteriorly and its two parts fuse on the midline to form the primitive linear heart tube (Fig. 1). This tube consists of an inner endothelial layer and an external myocardial layer, separated by cardiac jelly.

Tissue origins: the cardiac fields

The heart does not develop solely from cells of the primary linear heart tube. Very early in cardiac development, a second population of cardiac cells is present at the medial and ventral parts of the FHF [6]. This group of cells, called the second heart field (SHF), migrates medially and into the pharyngeal regions when the primary heart tube forms. SHF cells express the transcription factor *islet-1* and differentiate into cardiac myocytes, smooth muscle cells and endothelial cells [7].

After the loop, the SHF is located within the pharyngeal mesoderm, at the inner curvature, between the outflow and inflow tracts. The role of the SHF is of major importance for the development of the four-chamber heart: cells from the anterior part of the SHF (anterior heart field) contribute myocardial cells to the right ventricle and to the outflow tract (OT), and smooth muscle cells to the base of the aorta and the pulmonary artery [8]; cells from the posterior part of the SHF (dorsal mesocardium) contribute myocardial cells to the walls of the atria and to the atrial septum, and smooth muscle cells to the walls of the systemic and pulmonary veins [9].

The FHF then serves as a scaffold for building most of the heart from the cells of the SHF [10] and gives rise only to the left ventricle and to the most primitive part of the atria, including the two appendages.

Two extracardiac cellular populations also contribute cells to the heart and vessels: the cardiac neural crest provides cells for the OT and the great arteries through migration to these areas; and the epicardium arises from the proepicardial organ, which is located at the posterior part of the heart, near the venous pole – proepicardial cells give rise to the epicardium, which covers the surface of the heart, and invade the myocardium to form fibroblasts and smooth muscle cells for the coronary arteries.

Looping, convergence and wedging

There are three steps that are fundamental to a proper alignment of cardiac structures, which is itself mandatory for normal cardiac septation. These three steps are looping, convergence and wedging [11]. The intricate link between these processes and the development of the internal structures of the heart is illustrated in Fig. 2.

Cardiac looping

Cardiac looping is the first manifestation of right-left lateralization in the embryo [12]. The primitive straight heart tube loops to the right at 23–24 days of intrauterine life (D-loop), folding to the right into a S-shape, after an initial displacement to the left of the caudal part of the heart, termed 'jogging' (Fig. 3). This step is crucial for the further morphology of the heart because it brings the future cardiac chambers into their relative spatial positions. The current theory about how the cardiac looping occurs is that the cilia within the primary node (or Hensen's node) rotate, creating an extracellular flow current that determines the rightward bend of the tube [13]. The anomalies of cardiac looping affect the laterality of the heart. If there is complete reversal of the loop, the heart is in situs inversus totalis or a complete mirror-image. The reversal can be incomplete and random, leading to all types of unusual segmental arrangements, often associated with heterotaxy syndromes.

Convergence

The loop creates two limbs in parallel, an inflow (proximal) limb and an outflow (distal) limb, separated by the inner curvature [14]. The process of convergence brings the two limbs together craniocaudally, permitting alignment of the OT with the ventricular, atrioventricular (AV) and atrial septa [14]. Immediately after cardiac looping (early looping stage), the inlet segment (atria and AV canal) is located entirely above the future left ventricle and the outlet segment (the conotruncus or OT) is located entirely above the future right ventricle, leading to both double-inlet left ventricle and double-outlet right ventricle types of AV and ventriculoarterial connection. From this stage on, the heart continues to grow by addition of myocardial cells from the SHF, both at its arterial pole (anterior heart field) and at its venous pole (posterior heart field or dorsal mesocardium).

The atria and the ventricles develop and differentiate along the anteroposterior and right-left axis.

Four transitional zones can be described in the developing heart [15]. The endocardial cushions of the AV canal and the OT constitute two transitional zones, delimiting, respectively, the inlet segment and the outlet segment of the heart. The zone of junction between these two segments is the inner curvature, which is the pivot around which the remodelling of the AV and ventriculoarterial junctions will take place, including convergence and wedging (Fig. 4). The cushions contribute to septation and to the formation of the cardiac valves.

The sinus venosus contributes to atrial septation and to the atrial conduction pathways.

The primary fold joins together the inner and the outer curvature (Fig. 4), at the site of the future primitive ventricular septum; it contributes to ventricular septation and to the formation of the AV node and ventricular conduction pathways. The primary fold is also the starting point of the establishment of the right AV connection, which is initially absent.

The right ventricle and the ventricular OT grow rapidly by addition of myocardial cells from the SHF. At the same time, the right AV connection develops, along with the muscular bands of the right ventricle. This series of 'morphogenetic shifts' leads to alignment in the same sagittal plane of the AV canal, the future atrial and ventricular septa, and the developing OT [11]. This alignment, or convergence, is absolutely necessary to further normal septation. During this

process, the inner curvature (further ventriculoinfundibular fold) deepens and the endocardial cushions in the AV region grow and fuse to form the AV septum.

Cardiac malformations resulting from a defect occurring at the convergence stage are often severe, as they concern both the ventricles and the AV valves. They can be caused either by a lack of ventricular growth or by an absent or anomalous development of the right AV junction. These anomalies result in a malalignment between the atrial and ventricular septa, resulting itself in various congenital heart defects, including double inlet ventricle, tricuspid atresia and ventricular hypoplasia.

Wedging

The anterior heart field, part of the SHF, facilitates the elongation of the OT by addition of myocardial cells, in response to the migration of cardiac neural crest cells towards the OT [16]. Elongation of the OT is necessary for proper alignment (convergence) and wedging.

During wedging, the myocardial wall of the OT undergoes a counterclockwise rotation, viewed from the ventricular side, so that the aortic valve rotates behind the pulmonary trunk, going down and to the left to settle between the two AV valves, establishing mitral-aortic continuity [8, 14, 17] (Fig. 2). At the same time, the conal septum develops by fusion and muscularization of the endocardial cushions of the OT [18] and is taken along leftwards by the rotation of the developing aortic valve, to join the upper primitive ventricular septum at the level of the upper division (the 'Y') of the septal band or septomarginal trabeculation, itself derived from the primary fold [15]. The left part of the ventriculoinfundibular fold ('subaortic conus') then disappears, corresponding to the so called 'absorption of the subaortic conus', establishing the mitroaortic fibrous continuity.

A malalignment between the OT and the ventricles inevitably results in a failure of fusion of the outlet septum with the primitive ventricular septum and in a ventricular septal defect (VSD) located between the two limbs of the Y of the septal band. This type of VSD is common to all so-called 'conotruncal' (or neural crest) defects. Tetralogy of Fallot can then be considered as a failure within the last step of cardiac looping – wedging – leading to a malalignment between the

OT and the ventricles [19, 20]. In other words, tetralogy of Fallot may result from an arrest of rotation of the OT at the base of the great arteries [21].

Failure of myocardialization, leading to incomplete or abnormal convergence and wedging, is a major cause of many congenital heart defects, especially double outlet right ventricle [22]. Anomalies of both convergence and wedging produce malalignment of both inlet and outlet segments, while anomalies of wedging produce malalignment of the OT only.

The venous pole: atrial septation and development of the pulmonary veins

The venous pole consists of two parts: the sinus venosus and the primitive atrium, separated by the sinoatrial fold. The sinus venosus connects to the right atrium because of the asymmetric growth of the right part of the primitive atrium [9]. Ultimately, the right atrium has two parts: the trabeculated part (right atrial appendage); and the sinus venosus, with its two valves (right [Eustachian and Thebesian valves] and left [atrial septum]). The sinus venosus receives the caval veins and the coronary sinus.

Development of the pulmonary veins

The common pulmonary vein takes its origin within the dorsal mesocardium (itself part of the posterior SHF), in the form of a mediopharyngeal cellular strand. In the beginning, the common pulmonary vein is connected to the sinus venosus, itself separated from the primitive atrium (the atrial appendages) by the sinoatrial fold [9]. At this stage, connections between the pulmonary venous plexus and the vitelline and cardinal veins persist. Progressively, the common pulmonary vein incorporates within the left part of the primitive atrium, being pushed to the left by the growth of the vestibular spine, a structure also derived from the posterior part of the SHF. The incorporation of the pulmonary vein into the left atrium contributes to its identity: the left atrial wall consists of an inner vascular part, derived from pulmonary venous tissue, and an outer myocardial part [9]. If there is a defect of incorporation of the common pulmonary vein into the left atrium, the primitive connections persist, leading to the various types of abnormal pulmonary venous return: either with the derivatives of the cardinal veins (right [innominate vein,

superior vena cava, azygos vein]; left [coronary sinus]); or with the derivatives of the umbilicovitelline veins (portal vein, ductus venosus; inferior vena cava).

Direct drainage of all or part of the pulmonary veins within the morphologically right atrium is observed in heterotaxy syndromes; its mechanism is still unclear – possibly malposition of the septum primum or defect of the vestibular spine?

Atrial septation

At the beginning of the fifth week of intrauterine life, the septum primum (or primitive atrial septum) develops from the roof of the common atrium. Its inferior part is crescent-shaped with two extremities, anterior and posterior. At the posterior part of the common atrium, immediately underneath the septum primum and above the AV endocardial cushions, appears the vestibular spine (dorsal mesenchymatous protrusion, dorsal mesocardium), which derives from the posterior SHF and expresses *Isl1* (Fig. 5a) [23]. The inferior free edge of the septum primum is covered by a mesenchymal cap, which is considered as the anteroposterior extension of the vestibular spine [24]. At its anterior extremity, the mesenchymal cap is continuous with the anterosuperior AV endocardial cushion. The space between these three mesenchymatous structures constitutes the primitive interatrial foramen or ostium primum.

Progressively, these structures converge and fuse together to close the ostium primum, at 7 WG . The mesenchyme is then invaded by surrounding myocardial cells (muscularization) to form the anteroinferior rim of the oval fossa [25].

Before the closure of the ostium primum, fenestrations appear at the superior part of the septum primum and grow to form the 'ostium secundum' or oval foramen, or secondary interatrial foramen (Fig. 5b). This ostium preserves an opening, allowing blood to flow from the right to the left atrium during foetal life.

The last component of the atrial septum to appear is the septum secundum, which invaginates from the superior part of the common atrium to the right of the septum primum (Fig. 5c). Subsequent to birth, this fold provides the buttress against which the flap valve, representing the primitive atrial septum, abuts to close the oval foramen.

Atrioventricular septation

The AV junction consists of the AV valves, the lowest part of the interatrial septum (vestibular septum) and the inferior part of the ventricular septum (inlet septum). The remodelling of this junction takes place around the mesenchyme of the endocardial cushions of the AV canal.

At the early looping stage, the endocardial cushions of the AV canal connect the common atrium to the developing left ventricle. At this stage, there is still no connection between the right component of the common atrium and the developing right ventricle. While the right ventricle grows by addition of myocardial cells of the anterior SHF, the right AV junction develops from the dorsal part of the primary fold, between the inner curvature and the right part of the AV canal.

The inlet septum is formed by the fusion and expansion of the endocardial cushions of the AV canal and later muscularizes (Fig. 5c).

Ventricular growth and septation

With cardiac looping, the ventral surface of the straight heart tube swivels around to become the outer curvature of the heart and the dorsal surface becomes the inner curvature of the heart.

The outer curvature takes part in the active growth of the ventricles, while the remodelling of the inner curvature controls the alignment between the inlet and outlet segments of the heart [10].

The right ventricle develops later than the left ventricle [26], by addition of cardiomyocytes from the anterior SHF [6]. This differential growth contributes to convergence.

Because the two ventricles develop from two different cell lineages, the genetic sequence necessary to their morphogenesis is also different, which explains, in part, the morphogenesis of the univentricular types of congenital heart defects [6]. Among the various genes involved, Hand2 (d-Hand) is necessary for growth of the right ventricle by addition of cardiomyocytes by the SHF and Hand1 (e-Hand) is specific to the left ventricle [10]. These genes are expressed in the ventricular trabeculations but not within the interventricular septum [27].

From day 35 to day 39, the ventricles grow considerably, with expansion of the myocardial wall on the outer curvature, by a phenomenon called ballooning [28]. The myocardium proliferates and forms increasingly numerous trabeculations, which are the first manifestation of

the differentiation of the future left and right ventricles [29]. These trabeculations give the ventricular wall a spongy appearance and allow oxygenation of the myocardium before formation of the coronary arteries; then, the migration of cells from the epicardium allows maturation of the myocardium [15].

The interventricular septum has three anatomical parts: the trabecular or apical component, of muscular origin; the inlet component, of mesenchymal origin, formed by fusion then myocardialization of the endocardial cushions of the AV canal; and the outlet component, also of mesenchymal origin, formed by fusion then myocardialization of the endocardial cushions of the OT.

A recent study in mice using two complementary transgenes expressed in the embryonic right (Mlc1v) and left (Mlc3f) ventricles provides new insights into the formation of the interventricular septum [27]. During the early stages of development, the contributions of left and right ventricular lineages are symmetrical in the developing interventricular septum. Then the left ventricular cardiomyocytes dominate the septum, particularly in its dorsal part. A third population of cardiomyocytes could be added by the inner curvature of the heart. The formation of the interventricular septum would thus be first passive then active, reconciling the two previous hypotheses of Van Mierop and Kutsche (active growth from the apex to the base of the heart) and Patten (passive growth due to ballooning of the ventricular cavities) [27, 29, 30].

The arterial pole: development of the outflow tract

Until the wedging stage, characterized by rotation of the right part of the OT enabling the future aortic valve to reach the mitral valve [16], the OT remains entirely above the developing right ventricle.

Rotation of the OT has several consequences: establishment of the aortic-mitral fibrous continuity, with the disappearance (or absorption) of the subaortic conus, which represents the left portion of the ventriculoinfundibular fold; development of the ventriculoinfundibular fold itself from the inner curvature of the heart; and formation of the outlet septum from the endocardial cushions of the conus and its leftwards displacement until it reaches the upper part of the primitive ventricular septum and fuses with it, between the two limbs of the septal band. The

outlet septum in the normal heart is then a very small structure inserted between the two limbs of the septal band, in continuity with the ventriculoinfundibular fold.

Origins of the outflow tract

Two structures contribute cells to the developing OT: the cardiac neural crest; and the anterior part of the SHF (anterior heart field).

Cardiac neural crest cells migrate through the developing aortic arches to the aortic sac and the developing OT [31]. The role of the cardiac neural crest in the development of the arterial pole of the heart was demonstrated in the early 1970s by ablation experiments in chick embryos: total ablation resulted in common arterial trunk, partial ablation resulted in various heart defects, such as tetralogy of Fallot with or without pulmonary atresia, double-outlet right ventricle and malalignment VSDs, always associated with anomalies of the aortic arches [32]. These cardiac anomalies taken as a whole have since been named 'conotruncal defects'. A link was later established between this phenotype and the human DiGeorge syndrome, caused by 22q1.1 microdeletion. The major candidate gene for this chromosomal anomaly is *Tbx1* [31].

Cardiac neural crest cells contribute smooth muscle cells to the walls of the two great vessels. However, the major role of the cardiac neural crest is to give the signal to the SHF to add cardiac myocytes, and later smooth muscle cells, to the developing OT [17]. These cells permit the growth and elongation of the OT, which is necessary for wedging to occur properly. Experimental ablation of the anterior heart field in mice embryos leads to defects of alignment of the OT, elongation and thus wedging, leading to so-called conotruncal defects [8]. If ablation is performed later in development, the anterior heart field also fails to add smooth muscle cells to the proximal portion of the great vessels, which could be responsible for anomalies of the position of the coronary orifices [8].

The OT develops then from two cellular origins: the cardiac neural crest cells for the distal portion of the great vessels; and the anterior heart field for the proximal portion of the great vessels (smooth muscle cells) and the conus (cardiomyocytes).

These two structures exhibit close interdependency: if the cardiac neural crest cells fail to migrate, there is a lack of addition of cells from the anterior heart field to the developing OT, which leads to a lack of wedging and thus a conotruncal defect [33].

Septation of the outflow tract

The aorta and the pulmonary artery both arise from the aortic sac [34]. In the dorsal part of the aortic sac, a mesenchymatous protrusion called 'arterial spine' goes towards the distal part of the endocardial cushions of the conus, giving the primitive aortopulmonary septum. Fusion between the distal parts of the endocardial cushions gives rise to the aorta on the right and the pulmonary artery on the left, which connect with the fourth and sixth aortic arches, respectively.

The embryonic aortopulmonary foramen closes by fusion of the distal endocardial cushions with the arterial spine. Failure of this foramen to close leads to an aortopulmonary window [34].

Cardiac defects resulting from abnormal development of the OT include: the so-called conotruncal defects, resulting from abnormal wedging (tetralogy of Fallot and variants, including tetralogy of Fallot with pulmonary atresia; common arterial trunk; some types of double-outlet right ventricle; some types of interrupted aortic arch; and malalignment VSD); and transposition of the great arteries, which, although involving the OT, is now considered primarily as a laterality defect, as it affects the laterality of wedging – it shares the same genes with double discordance (or physiologically corrected transposition of the great arteries) and heterotaxy syndromes [35].

The endocardial cushions: formation of the cardiac valves

The four cardiac valves all share a common origin: the mesenchyme of the endocardial cushions. Their formation involves four steps: epithelial-to-mesenchymal transformation; growth; remodelling; and apoptosis [36]. Their development is intimately related with cardiac septation and with the development of inflow and outflow segments.

The main steps of valve development

Epithelial-to-mesenchymal transformation

In the primitive linear heart tube, the two cellular layers (myocardium and endocardium) are separated by the extracellular matrix or cardiac jelly. During the loop, the cardiac jelly disappears from the cardiac chambers, persisting only at the segments of junction: the AV canal and the OT. The position of the future valves relative to the cardiac chambers is determined by bone morphogenetic protein 2 and TBx2 expression in the myocardium, and Notch1 expression in the endocardium. The loss of endocardial adhesion and adoption of an invasive phenotype induced by Notch and transforming growth factor-beta signalling constitute an epithelial-to-mesenchymal transformation. Invasion of the extracellular matrix by the newly formed mesenchymal cells leads to the formation of the endocardial cushions, as shown in Fig. 4 [37].

Growth

The endocardial cushions grow by cell proliferation and extracellular matrix synthesis, mediated by bone morphogenetic protein and vascular endothelial growth factor.

Remodelling

The remodelling stage includes delamination of the valvar leaflets from the myocardium and transformation of the mesenchymal tissue into fibrous tissue and collagen, mediated by FGF, PTPN11, Wnt and periostin. The transition between growth and remodelling is mediated by NAFTC1. Periostin null mice exhibit hypertrophic and shortened valvular leaflets, leading to prolapsed mitral valve and bicuspid aortic valves [36].

Apoptosis

The phenomenon of apoptosis sculpts and thins the valvar leaflets during foetal life.

Formation of the tricuspid valve

The tricuspid valve develops from the thirty-fifth day of intrauterine life, from an excavation within the posteroinferior part of the primary fold, to the right of the inferior AV cushion, called the 'tricuspid gully' [38] (Fig. 6). This funnel expands to form the inlet part of the developing right ventricle, including the moderator band and the tricuspid valve. The myocardial funnel drives

blood from the right atrium, under the myocardium of the inner curvature (parietal band or supraventricular crest), to the middle part of the developing right ventricle, through a primary orifice pointed towards the OT [39]. At the convergence stage, fenestrations appear at the distal part of the funnel, creating the inferior orifice of the tricuspid valve. The primitive anterosuperior orifice becomes the anteroseptal commissure. The tricuspid valve is then initially an entirely muscular structure, with three walls: a septal wall, made up of the ventricular septum itself; an inferior wall, made up of the inferior wall of the developing right ventricle; and an anterior wall, made up of the anterior wall of the tricuspid gully.

These three myocardial walls are covered internally by the mesenchymal tissue of the endocardial AV cushions. The three leaflets of the tricuspid valve delaminate from these three muscular walls. The anterior leaflet delaminates – or rather ‘demyocardializes’ – first, during the eighth WG, by apoptosis, leading to gradual disappearance of its myocardial external part. Then the inferior leaflet and, lastly, the septal leaflet delaminate from the respectively inferior and septal myocardial walls of the right ventricle, from the inferior part of the tricuspid gully towards the annulus (right AV junction).

The tricuspid valve and its tendinous chordae are derived almost entirely from the mesenchyme of the AV cushions and, to a lesser extent, from the adjacent AV myocardium, via the delamination process. The tendinous cords are formed by fragmentation of the distal part of the ventricular side of the leaflets. They are, like the valvular leaflets, of mesenchymal origin and later undergo a fibrous transformation. The papillary muscles are of myocardial origin, formed by compaction within the trabecular layer of the myocardium [40].

Ebstein’s malformation can be considered as a failure of delamination of the inferior and septal leaflets from the walls of the muscular inlet component. In contrast to the inferior and septal leaflets, the anterior leaflet always retains its normal junctional hinge from the AV junction along the parietal band and often undergoes complete ‘demyocardialization’. In the most severe cases of Ebstein’s malformation, the leading edge of the anterior leaflet is attached in a linear fashion onto the distal margin of the right ventricle inlet funnel, forming a partition between the inlet and the muscular component, due to failure of formation of the definitive inferior orifice of the tricuspid valve [41]. Ebstein’s anomaly can then be considered as an arrest in normal

cardiac development and its anatomical severity depends on the developmental stage at which the arrest occurs.

Formation of the mitral valve

The two leaflets of the mitral valve share a common origin – the endocardial cushions of the AV canal – but their development is totally different. The formation of the mitral valve is intimately related with the septation process. During wedging, the aortic valve rotates to nestle between the developing tricuspid and mitral valve, as shown in Fig. 2. The aortic valve thus separates the future anterior leaflet of the mitral valve, which develops from the fusion of the superior and inferior cushions, from the ventricular septal surface [39]. Because of this, the anterior leaflet of the mitral valve does not have an initial muscular component and is entirely of mesenchymal origin. This process also explains why the normal mitral valve has no septal attachments, the papillary muscles developing only from the free lateral wall of the left ventricle [38]. The mural leaflet delaminates from the inferior wall of the left ventricle, according to the same mechanism as that for the inferior and septal tricuspid leaflets.

The chords derive from the leaflets themselves, while the papillary muscles develop by compaction within the trabecular layer of the myocardium of the left ventricular free wall [40].

Formation of the aortic and pulmonary valves

The arterial valves develop from the mesenchyme of the OT endocardial cushions, concomitant with the formation of the conal septum and the process of wedging. The fusion of the right and left lateral cushions on the midline determines two symmetrical valve primordia, separated by a protrusion of the posterior wall of the aortic sac ('arterial spine'), which represents a transient aortopulmonary septum [42]. The two intercalated cushions form the anterior leaflet of the pulmonary valve and the posterior non-coronary leaflet of the aortic valve. The sinuses of Valsalva then form as an excavation between the cushions and the arterial wall, by an apoptosis phenomenon [43]. The two semilunar valves, aortic and pulmonary, are thus morphologically identical, but separate, structures [44].

Abnormal fusion, or an excess of normal fusion, of the endocardial cushions can lead to bicuspid arterial valves. Excessive fusion of the right and left aortic leaflets is most common, and could be associated with aortic coarctation, VSD and dilatation of the ascending aorta. Abnormal fusion of the right and non-coronary leaflets of the aortic valve would evolve towards aortic stenosis and regurgitation [45].

After the end of the twelfth WG until birth, the valvar leaflets continue to develop and become thinner, by apoptosis.

The coronary arteries

The connection of the coronary arteries to the aorta is the last step in the formation of the heart and occurs within the seventh WG, after completion of septation. Epicardium, originating from the proepicardial organ, is necessary for the formation of the first coronary vessels [46], but a recent study has suggested that another source of the coronary plexus may be the venous endothelial cells of the sinus venosus [47]. The epithelial cells of the proepicardial organ undergo epithelial-to-mesenchyme transformation and migrate within the subepicardial space, then into newly formed spaces within the developing myocardium [48]. The subepicardial and myocardial spaces are continuous, but there is no communication with the ventricular lumen, unlike what happens in birds: in mammals, no myocardial sinusoids are found at any stage of normal development. However, sinusoids can develop in pathological situations: high ventricular pressure (pulmonary atresia with intact ventricular septum); defect of maturation of the ventricular myocardium (non-compaction); and abnormal development (coronary-ventricular fistulae).

A primitive endothelial network forms within the myocardium by vasculogenesis. Then, by angiogenesis and remodelling, the first arterial coronary vessels appear in the posterior AV sulcus, on the inferior surface of the heart, and spread towards the apex (interventricular sulcus) and the origin of the great vessels, forming the periarterial circle [49].

Bogers et al. demonstrated in 1989 that the coronary arteries enter the aorta rather than emerge from it [50]. In the normal heart, the coronary arteries always connect to the base of the aorta within the left and right anterior sinuses of Valsalva, while the posterior part of the aortic

valve is devoid of coronary arteries. What determines these 'coronary' and 'non-coronary' zones is still a subject of controversy. Several hypotheses have been advanced concerning the pattern of penetration of the coronary arteries within the aorta. A recent study has revealed a major role for Tbx1 in coronary artery patterning in mice, suggesting a subaortic 'coronary-permissive' and a subpulmonary 'coronary-refractory' domain [51]. Deletion of Tbx1 induces a shortened OT with a pulmonary component defect, as shown by diminished expression of the 96-16 transgene. Théveniau-Ruissy et al. hypothesized that the abnormal coronary artery pattern observed in the Tbx1^{-/-} mouse mutant was the consequence of a severely reduced 'subpulmonary' coronary-refractory myocardial domain malpositioned in the dorsal/left side of the OT [51].

The aortic arches

The aortic arches originate from the mesoderm of the pharyngeal arches; they connect the aortic sac ventrally (itself created by fusion of the initially paired ventral aortas) to the initially bilateral dorsal aortas [52]. Initially paired and symmetrical, some of them (the third, fourth and sixth) undergo remodelling into the asymmetric great arteries, under the guidance of cardiac neural crest cells. The six aortic arches appear sequentially, not simultaneously, in a craniocaudal order. The first and second aortic arches are populated by non-cardiac neural crest cells and develop mainly into skeletal elements. The third aortic arch becomes the common carotid arteries and the proximal portion of the internal carotid arteries. The fourth aortic arch forms the horizontal aorta. The fifth aortic arch is inconstant and its persistence is exceptional. The sixth arch forms the arterial duct and the initial part of the central pulmonary arteries.

Several parts of the aortic arches system undergo regression, the first one being the right sixth aortic arch. Pitx2c mutant mice have aortic arch anomalies due to impaired remodelling, with abnormal laterality of the patent sixth aortic arch. These experiments suggest that the situs of the descending aorta (and thus of the aortic arch) is determined by the laterality of the sixth aortic arch [53].

Cardiac neural crest cells migrate through the developing aortic arches to reach the OT of the heart. Thus, they play a major role in the remodelling of the initially bilateral aortic arches into the definitive great vessels and also in the separation of the initially common arterial trunk into the ascending aorta and the pulmonary trunk [42]. Indeed, a 22q1.1 microdeletion was found in 24% of isolated anomalies of the aortic arches and in 67% when associated with stenosis or atresia of proximal pulmonary arteries [54]. Migrating cardiac neural crest cells send positional information to the aortic arches via the Hox genes, which have a different expression in the sixth arch versus the third and fourth arches: HoxB5 expression is specific for the distal sixth aortic arch, which becomes the arterial duct [53]. Tbx1, the major candidate gene for microdeletion 22q1.1, is involved in the formation, growth and remodelling of the aortic arches. Laterality genes like Pitx2c are also involved, but seem to act through the anterior SHF, which determines the rotation of the OT necessary for the final position of the two great vessels. This rotation would determine a differential distribution of blood flow in the sixth aortic arch, a decreased blood flow within the sixth aortic arch resulting in its regression and the establishment of the normal left aortic arch [55]. These findings would explain, in part, the haemodynamic theory of Rudolph et al. that a diminutive blood flow through the pulmonary valve favours abnormal development of the right sixth aortic arch [56].

The conduction system

The heart is among the very few organs that are functional as soon as they begin to form. The straight heart tube has peristaltic contractions, well before the sinoatrial node (the pacemaker of the heart) appears. The substrate for this peristalsis is the alternation in the straight heart tube of segments with slow and fast conduction. In mammalian and avian embryonic ventricles, the contraction wave starts in the inflow part of the heart tube and propagates to the ventricles and then to the OT (base-to-apex), as in lower vertebrates [57]. Lower vertebrates have a spongy myocardium, without coronary vasculature, and have no insulating fibrous plane between the atrial and ventricular myocardium. Higher vertebrates develop a compact myocardium, which is necessary to answer the increase in heart beat and pressure. This compact myocardium allows maturation of the conduction system, with a base-to-apex activation in the trabecular part of the

ventricles and an apex-to-base activation in the subepicardial compact myocardium, related to the development of the His-Purkinje system [57]. This developmental change in the activation pattern of the heart is thus intimately related with the development of compact myocardium.

The primary heart tube contains only slow-conducting and poorly differentiated cardiomyocytes [58]. With the growth of the heart by addition of cardiomyocytes to the two extremities of the tube, the developing ventricular and atrial chambers acquire a working myocardial phenotype, made of fast-conducting and contractile myocardial cells [59]. Connexin 43 can be detected in the working myocardium, reflecting the formation of an increasing number of gap junctions between the cells, at the origin of the fast-conducting properties. Could be changed by : The atrial and ventricular myocardial become separated by insulating fibrous tissue which is derived from the epicardium and is termed the AV ring [58,60]. Within the AV ring, the AV node is developed at the posterior part of the AV canal by specification of myocardial cells that retain their initial phenotype and thus do not differentiate into functional myocardium [59]. The atrial and ventricular myocardial become separated by insulating fibrous tissue which is derived from the epicardium and is termed the AV ring [58,60]. Within the AV ring, the AV node is developed at the posterior part of the AV canal by specification of myocardial cells that retain their initial phenotype and thus do not differentiate into functional myocardium [59].

The transcription factors responsible for the development of conduction tissues are now well known and appear to be similar in humans and mice [60]. HCN4 is first expressed through the entire primitive heart tube, with a gradual decrease of expression from the venous to the arterial pole. Later, HCN4 expression is confined to the sinus node primordium (at the junction of the superior vena cava and the right atrium), in the myocardium surrounding the AV junction and the coronary sinus. Abnormal persistence of HCN4 activity in various myocardial structures, such as the pulmonary venous sleeves, the coronary sinus, the lower atrial rims, the right OT and the atrial appendages, could explain the occurrence of certain arrhythmias [60].

Nkx2.5 is present in both the sinoatrial and AV nodes. The transcription factor Tbx3 is involved in early specification of the myocytes of the systemic venous sinus, the AV canal, the AV node and the AV bundle, and is responsible for repression of the working myocardial gene programme [61]. In a recent study, Tbx3 was proven to be able to reprogramme differentiated working cardiomyocytes into pacemaker cells in mice, raising hopes for future therapy for conduction disorders [61].

The laterality gene Pitx2 plays a crucial role in the establishment of the pacemaker of the heart, preventing the formation of a left-sided sinoatrial node by restricting the slow-conducting

myocardium to the right sinus venosus region [62]. Mice knocked out for Pitx2 exhibit right atrial isomerism with bilateral sinoatrial nodes [63].

The AV node develops from the AV canal myocardium and is made of slow-conducting tissue. The main function of the AV node is to slow down the impulses coming from the atria to the ventricles. However, the impulses coming from the atria can reach the ventricles only through a fast-conducting myocardium: the bundle of His and the two bundle branches permit contraction of the apex before the base of the ventricles, simultaneous contraction of both ventricles and ejection of blood through their OT.

Thus, the sinoatrial node and the AV node develop from the slow-conducting myocardium of the inflow tract and the AV canal, and the bundle of His and branch bundles develop from the fast-conducting ventricular myocardium [52].

Conclusion

Progress in molecular biology and genetics, with the development of animal models, has permitted the unravelling of many mechanisms that potentially lead to cardiac malformations. However, one must keep in mind that the cardiac phenotypes found in animal models should be carefully interpreted when compared with those found in humans. A next step towards a better knowledge of cardiac development could be multiscale cardiac modelling [37], which considers structure, function and behaviour at different levels of spatial (and time) scales simultaneously. In cardiac morphogenesis much can be gained by integrating models from the genetic, cellular, and tissue levels of granularity..

Acknowledgments

We thank Stéphane Andru, computer graphic designer, for the creation of three-dimensional virtual pictures and Dr. Bertrand Stos for drawings.

References

- [1] Khoshnood B, Lelong N, Houyel L, et al. Prevalence, timing of diagnosis and mortality of newborns with congenital heart defects: a population-based study. *Heart* 2012;98:1667-73.
- [2] Mikawa T. Cardiac lineages. In: Harvey RP, Rosenthal N, eds. *Heart Development*. San Diego, CA: Academic Press; 1999:19-33.
- [3] Olson EN. Gene regulatory networks in the evolution and development of the heart. *Science* 2006;313:1922-7.
- [4] Epstein JA, Franklin H. Epstein Lecture. Cardiac development and implications for heart disease. *N Engl J Med* 2010;363:1638-47.
- [5] Wu SM, Fujiwara Y, Cibulsky SM, et al. Developmental origin of a bipotential myocardial and smooth muscle cell precursor in the mammalian heart. *Cell* 2006;127:1137-50.
- [6] Zaffran S, Kelly RG, Meilhac SM, et al. Right ventricular myocardium derives from the anterior heart field. *Circ Res* 2004;95:261-8.
- [7] Cai CL, Liang X, Shi Y, et al. Isl1 identifies a cardiac progenitor population that proliferates prior to differentiation and contributes a majority of cells to the heart. *Dev Cell* 2003;5:877-89.
- [8] Ward C, Stadt H, Hutson M, et al. Ablation of the secondary heart field leads to tetralogy of Fallot and pulmonary atresia. *Dev Biol* 2005;284:72-83.
- [9] Douglas YL, Jongbloed MR, Deruiter MC, et al. Normal and abnormal development of pulmonary veins: state of the art and correlation with clinical entities. *Int J Cardiol* 2011;147:13-24.
- [10] Srivastava D. Making or breaking the heart: from lineage determination to morphogenesis. *Cell* 2006;126:1037-48.
- [11] Kirby ML, Waldo KL. Neural crest and cardiovascular patterning. *Circ Res* 1995;77:211-5.

- [12] Manner J. Cardiac looping in the chick embryo: a morphological review with special reference to terminological and biomechanical aspects of the looping process. *Anat Rec* 2000;259:248-62.
- [13] Nonaka S, Shiratori H, Saijoh Y, et al. Determination of left-right patterning of the mouse embryo by artificial nodal flow. *Nature* 2002;418:96-9.
- [14] Yelbuz TM, Waldo KL, Kumiski DH, et al. Shortened outflow tract leads to altered cardiac looping after neural crest ablation. *Circulation* 2002;106:504-10.
- [15] Gittenberger-de Groot AC. Mannheim Lecture. The quintessence of the making of the heart. *Cardiol Young* 2003;13:175-83.
- [16] Waldo KL, Hutson MR, Ward CC, et al. Secondary heart field contributes myocardium and smooth muscle to the arterial pole of the developing heart. *Dev Biol* 2005;281:78-90.
- [17] Bajolle F, Zaffran S, Kelly RG, et al. Rotation of the myocardial wall of the outflow tract is implicated in the normal positioning of the great arteries. *Circ Res* 2006;98:421-8.
- [18] Mjaatvedt CH, Yamamura H, Wessels A, et al. Mechanisms of segmentation, septation, and remodeling of the tubular heart: endocardial cushion fate and cardiac looping. In: Harvey RP, Rosenthal N, eds. *Heart Development*. San Diego, CA: Academic Press; 1999:159-77.
- [19] Anderson RH, Jacobs ML. The anatomy of tetralogy of Fallot with pulmonary stenosis. *Cardiol Young* 2008;18 Suppl 3:12-21.
- [20] Van Praagh R. The first Stella van Praagh memorial lecture: the history and anatomy of tetralogy of Fallot. *Semin Thorac Cardiovasc Surg Pediatr Card Surg Annu* 2009:19-38.
- [21] Lomonico MP, Bostrom MP, Moore GW, et al. Arrested rotation of the outflow tract may explain tetralogy of Fallot and transposition of the great arteries. *Pediatr Pathol* 1988;8:267-81.
- [22] Bartram U, Molin DG, Wisse LJ, et al. Double-outlet right ventricle and overriding tricuspid valve reflect disturbances of looping, myocardialization, endocardial cushion differentiation, and apoptosis in TGF-beta(2)-knockout mice. *Circulation* 2001;103:2745-52.

- [23] Snarr BS, O'Neal JL, Chintalapudi MR, et al. Isl1 expression at the venous pole identifies a novel role for the second heart field in cardiac development. *Circ Res* 2007;101:971-4.
- [24] Anderson RH, Brown NA, Webb S. Development and structure of the atrial septum. *Heart* 2002;88:104-10.
- [25] Kim JS, Viragh S, Moorman AF, et al. Development of the myocardium of the atrioventricular canal and the vestibular spine in the human heart. *Circ Res* 2001;88:395-402.
- [26] Moorman AF, Christoffels VM. Cardiac chamber formation: development, genes, and evolution. *Physiol Rev* 2003;83:1223-67.
- [27] Franco D, Meilhac SM, Christoffels VM, et al. Left and right ventricular contributions to the formation of the interventricular septum in the mouse heart. *Dev Biol* 2006;294:366-75.
- [28] Christoffels VM, Habets PE, Franco D, et al. Chamber formation and morphogenesis in the developing mammalian heart. *Dev Biol* 2000;223:266-78.
- [29] Van Mierop LH, Kutsche LM. Development of the ventricular septum of the heart. *Heart Vessels* 1985;1:114-9.
- [30] Patten BM. The heart. *Patten's Foundations of Embryology*. New York, NY: McGraw-Hill; 1954:545-69.
- [31] Hutson MR, Kirby ML. Model systems for the study of heart development and disease. Cardiac neural crest and conotruncal malformations. *Semin Cell Dev Biol* 2007;18:101-10.
- [32] Lelièvre CS, Le Douarin NM. Mesenchymal derivatives of the neural crest: analysis of chimeric quail and chick embryos. *J Embryol Exp Morphol* 1975;34:125-54.
- [33] Waldo KL, Hutson MR, Stadt HA, et al. Cardiac neural crest is necessary for normal addition of the myocardium to the arterial pole from the secondary heart field. *Dev Biol* 2005;281:66-77.
- [34] Anderson RH, Chaudhry B, Mohun TJ, et al. Normal and abnormal development of the intrapericardial arterial trunks in humans and mice. *Cardiovasc Res* 2012;95:108-15.

- [35] Ramsdell AF. Left-right asymmetry and congenital cardiac defects: getting to the heart of the matter in vertebrate left-right axis determination. *Dev Biol* 2005;288:1-20.
- [36] Markwald RR, Norris RA, Moreno-Rodriguez R, et al. Developmental basis of adult cardiovascular diseases: valvular heart diseases. *Ann N Y Acad Sci* 2010;1188:177-83.
- [37]
- 37 Abdulla T, Luna-Zurita L, Luis de la Pompa J, Schleich J-M, Summers R. Epithelial to mesenchymal transition. The roles of cell morphology, labile adhesion and junctional coupling. *Computer Methods and Programs in Biomedecine* 2013; 111: 435-46
- [38] Lamers WH, Viragh S, Wessels A, et al. Formation of the tricuspid valve in the human heart. *Circulation* 1995;91:111-21.
- [39] Kanani M, Moorman AF, Cook AC, et al. Development of the atrioventricular valves: clinicomorphological correlations. *Ann Thorac Surg* 2005;79:1797-804.
- [40] de Lange FJ, Moorman AF, Anderson RH, et al. Lineage and morphogenetic analysis of the cardiac valves. *Circ Res* 2004;95:645-54.
- [41] Leung MP, Baker EJ, Anderson RH, et al. Cineangiographic spectrum of Ebstein's malformation: its relevance to clinical presentation and outcome. *J Am Coll Cardiol* 1988;11:154-61.
- [42] Anderson RH, Cook A, Brown NA, et al. Development of the outflow tracts with reference to aortopulmonary windows and aortoventricular tunnels. *Cardiol Young* 2010;20 Suppl 3:92-9.
- [43] Hurle JM, Colvee E, Blanco AM. Development of mouse semilunar valves. *Anat Embryol (Berl)* 1980;160:83-91.
- [44] Kramer TC. The partitioning of the truncus and conus and the formation of the membranous portion of the interventricular septum in the human heart. *Anat Rec* 1942;71:343-70.
- [45] Fernandez B, Duran AC, Fernandez-Gallego T, et al. Bicuspid aortic valves with different spatial orientations of the leaflets are distinct etiological entities. *J Am Coll Cardiol* 2009;54:2312-8.

- [46] Reese DE, Mikawa T, Bader DM. Development of the coronary vessel system. *Circ Res* 2002;91:761-8.
- [47] Red-Horse K, Ueno H, Weissman IL, et al. Coronary arteries form by developmental reprogramming of venous cells. *Nature* 2010;464:549-53.
- [48] Wada AM, Willet SG, Bader D. Coronary vessel development: a unique form of vasculogenesis. *Arterioscler Thromb Vasc Biol* 2003;23:2138-45.
- [49] Olivey HE, Svensson EC. Epicardial-myocardial signaling directing coronary vasculogenesis. *Circ Res* 2010;106:818-32.
- [50] Bogers AJ, Gittenberger-de Groot AC, Poelmann RE, et al. Development of the origin of the coronary arteries, a matter of ingrowth or outgrowth? *Anat Embryol (Berl)* 1989;180:437-41.
- [51] Theveniau-Ruissy M, Dandonneau M, Mesbah K, et al. The del22q11.2 candidate gene *Tbx1* controls regional outflow tract identity and coronary artery patterning. *Circ Res* 2008;103:142-8.
- [52] Kirby ML. Neural crest, great arteries and outflow septation. In: Kirby ML, ed. *Cardiac Development*. New York, NY: Oxford University Press; 2007:143-60.
- [53] Liu C, Liu W, Palie J, et al. *Pitx2c* patterns anterior myocardium and aortic arch vessels and is required for local cell movement into atrioventricular cushions. *Development* 2002;129:5081-91.
- [54] McElhinney DB, Clark BJ, 3rd, Weinberg PM, et al. Association of chromosome 22q11 deletion with isolated anomalies of aortic arch laterality and branching. *J Am Coll Cardiol* 2001;37:2114-9.
- [55] Yashiro K, Shiratori H, Hamada H. Haemodynamics determined by a genetic programme govern asymmetric development of the aortic arch. *Nature* 2007;450:285-8.
- [56] Rudolph AM, Heymann MA, Spitznas U. Hemodynamic considerations in the development of narrowing of the aorta. *Am J Cardiol* 1972;30:514-25.
- [57] Jensen B, Boukens BJ, Postma AV, et al. Identifying the evolutionary building blocks of the cardiac conduction system. *PLoS One* 2012;7:e44231.

- [58] Bakker ML, Moorman AF, Christoffels VM. The atrioventricular node: origin, development, and genetic program. *Trends Cardiovasc Med* 2010;20:164-71.
- [59] Christoffels VM, Smits GJ, Kispert A, et al. Development of the pacemaker tissues of the heart. *Circ Res* 2010;106:240-54.
- [60] Sizarov A, Devalla HD, Anderson RH, et al. Molecular analysis of patterning of conduction tissues in the developing human heart. *Circ Arrhythm Electrophysiol* 2011;4:532-42.
- [61] Bakker ML, Boink GJ, Boukens BJ, et al. T-box transcription factor TBX3 reprogrammes mature cardiac myocytes into pacemaker-like cells. *Cardiovasc Res* 2012;94:439-49.
- [62] Ammirabile G, Tessari A, Pignataro V et al. Pitx2 confers left morphological, molecular, and functional identity to the sinus venosus myocardium. *Cardiovasc Res*. 2012;93:291-301.
- [63] Mommersteeg MT, Hoogaars WM, Prall OW, et al. Molecular pathway for the localized formation of the sinoatrial node. *Circ Res* 2007;100:354-62.

Figure legends

Figure 1. The primitive linear heart tube (in red) at the ventral part of the embryo.

Figure 2. The three main steps of cardiac development: early looping, convergence and wedging. Red circles: initial and final position of the future aortic valve. A: atria; AVC: atrioventricular canal; LV: left ventricle; OT: outflow tract; RV: right ventricle.

Figure 3. Normal cardiac looping. At day 23 of intrauterine life, the linear heart tube folds rightwards.

Figure 4. The four transitional zones: sinus venosus; primary fold; AV canal; and outflow tract endocardial cushions. Red star: inner curvature of the heart.

Figure 5. Atrial septation. (A) The septum primum (in yellow) with its mesenchymal cap (in white) and the vestibular spine (in blue) leaving a space corresponding to the ostium primum. (B) The ostium secundum appears by apoptosis at the upper part of the septum primum. (C) The septum secundum (in brown) develops by invagination of the roof of the right atrium, to the right of the septum primum; closure of the ostium primum and the inlet septum by mesenchymatous structures (in white) coming from the septum primum, vestibular spine and anterosuperior AV endocardial cushion.

Figure 6. Formation of the right atrioventricular junction. Red arrow: tricuspid gully. A: atria; AVC: atrioventricular canal; LV: left ventricle; OT: outflow tract; RV: right ventricle.

Figure 1

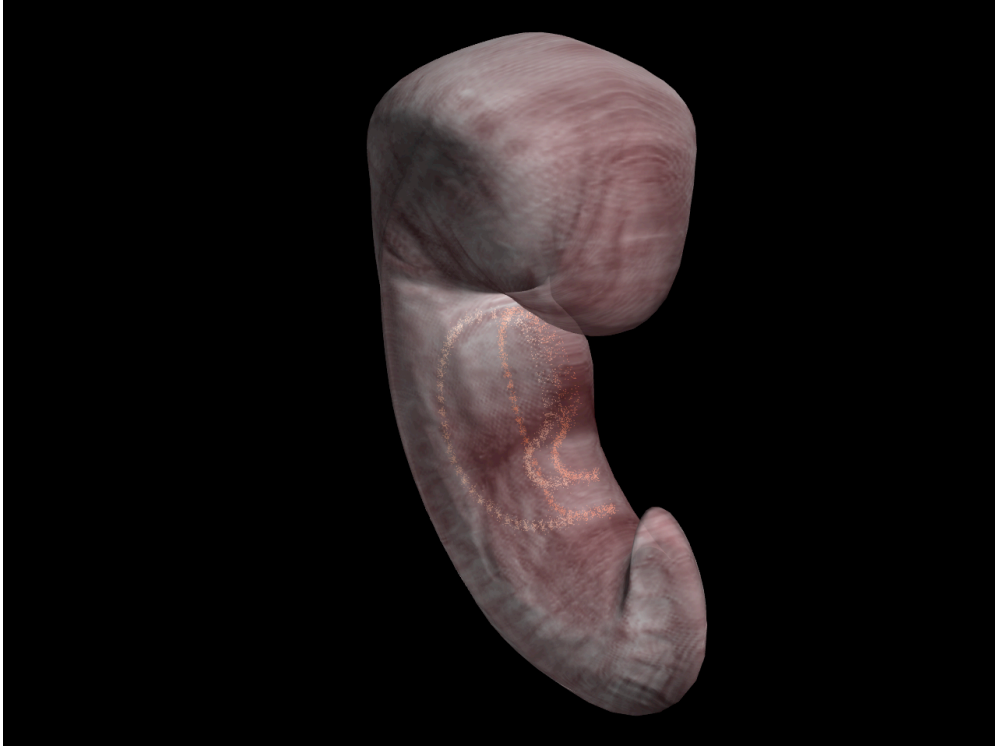


Figure 2

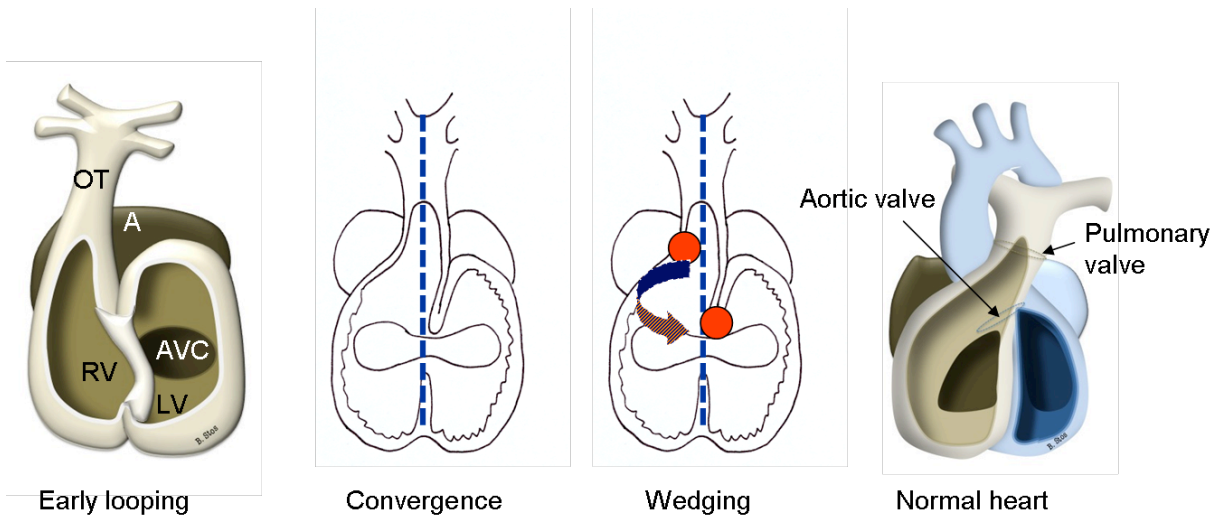


Figure 3

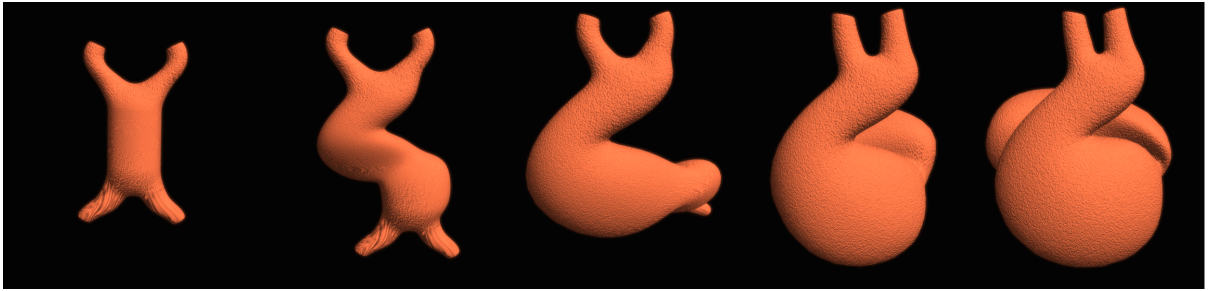


Figure 4

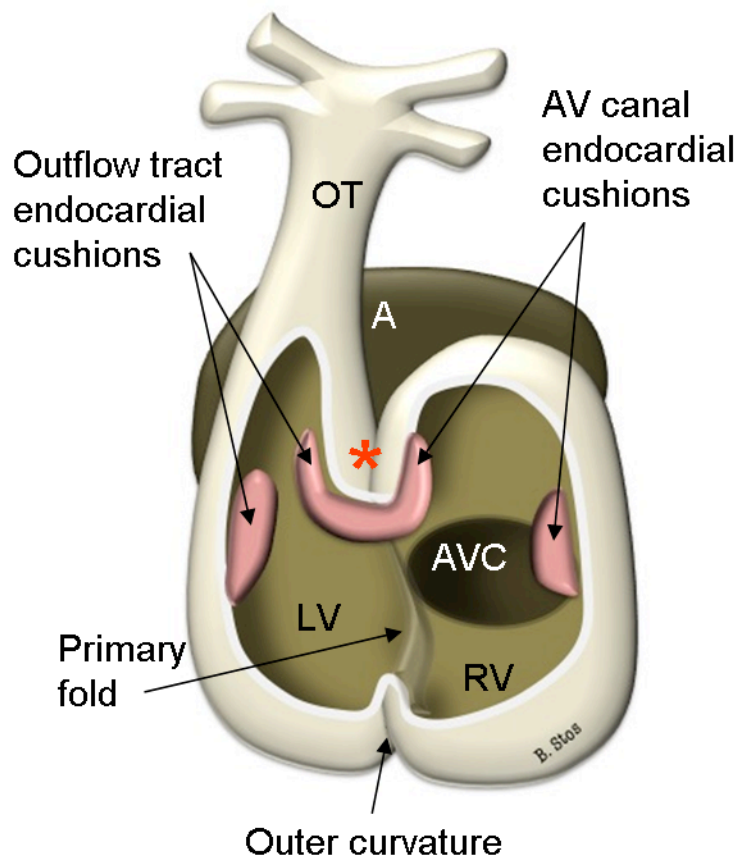


Figure 5A

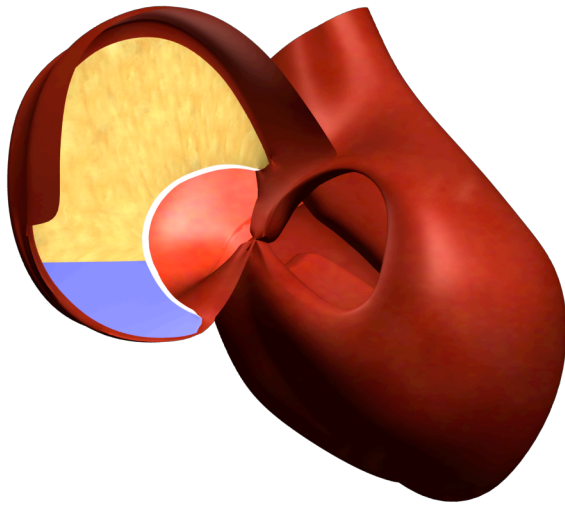


Figure 5B

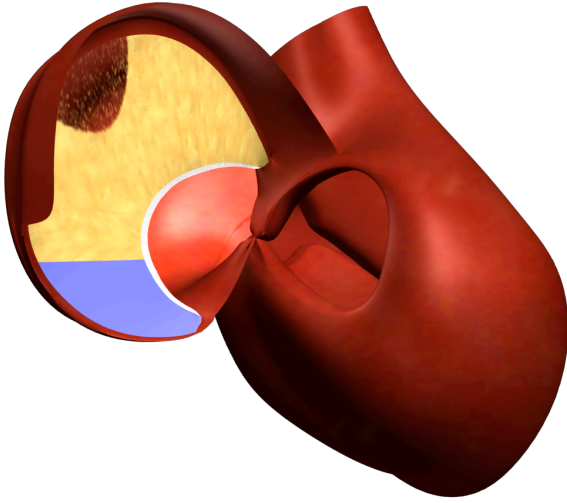


Figure 5C

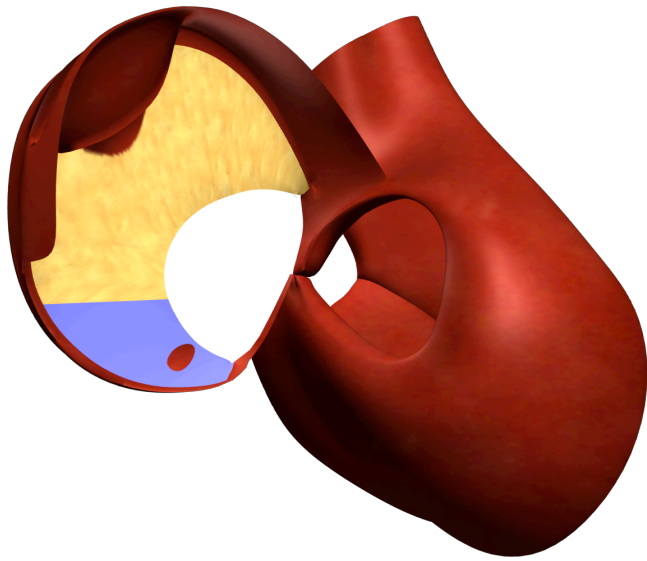


Figure 6

