



**HAL**  
open science

## Towards a new method for cardiac tissue velocity measurements using MRI, comparison with echocardiography

Christophe Meyer, Pierre-André Vuissoz, Jacques Felblinger, Laurent Bonnemains

### ► To cite this version:

Christophe Meyer, Pierre-André Vuissoz, Jacques Felblinger, Laurent Bonnemains. Towards a new method for cardiac tissue velocity measurements using MRI, comparison with echocardiography. *Journal of Cardiovascular Magnetic Resonance*, 2014, 16 (Suppl 1), pp.P44. inserm-00932140

**HAL Id: inserm-00932140**

**<https://inserm.hal.science/inserm-00932140>**

Submitted on 16 Jan 2014

**HAL** is a multi-disciplinary open access archive for the deposit and dissemination of scientific research documents, whether they are published or not. The documents may come from teaching and research institutions in France or abroad, or from public or private research centers.

L'archive ouverte pluridisciplinaire **HAL**, est destinée au dépôt et à la diffusion de documents scientifiques de niveau recherche, publiés ou non, émanant des établissements d'enseignement et de recherche français ou étrangers, des laboratoires publics ou privés.

POSTER PRESENTATION

Open Access

# Towards a new method for cardiac tissue velocity measurements using MRI, comparison with echocardiography

Christophe Meyer<sup>2,1\*</sup>, Pierre-André Vuissoz<sup>2,1</sup>, Jacques Felblinger<sup>1,4</sup>, Laurent Bonnemains<sup>1,3</sup>

From 17th Annual SCMR Scientific Sessions  
New Orleans, LA, USA. 16-19 January 2014

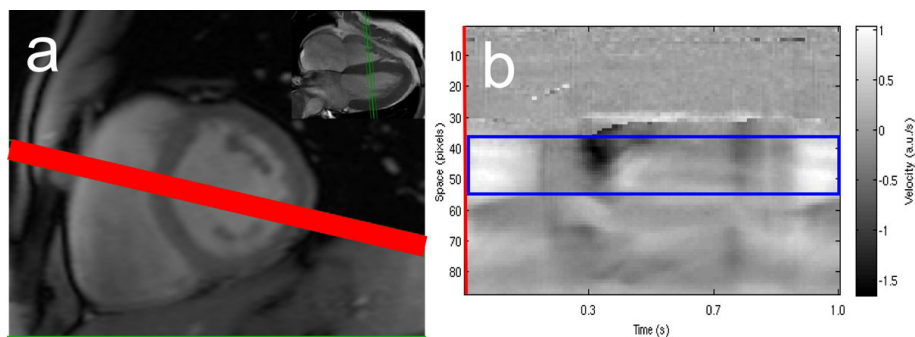
## Background

Echocardiography is currently the gold standard for cardiac tissue velocity measurement [1]. Phase contrast MRI with multiple excitations averaging has been proposed as an alternative solution [2]. In this study, we used a central k-space line phase contrast sequence [3] to acquire real-time velocity curves and compared them to echocardiography.

## Methods

Eighteen healthy volunteers underwent cardiac MRI examination on a Signa HDxt 3T scanner (General Electric, Waukesha). A phase contrast sequence modified to acquire only the central k-space line was used in a mid-ventricular small axis scan plane with through-plane velocity encoding during 128 heartbeats. The frequency encoding direction was angulated to encompass the

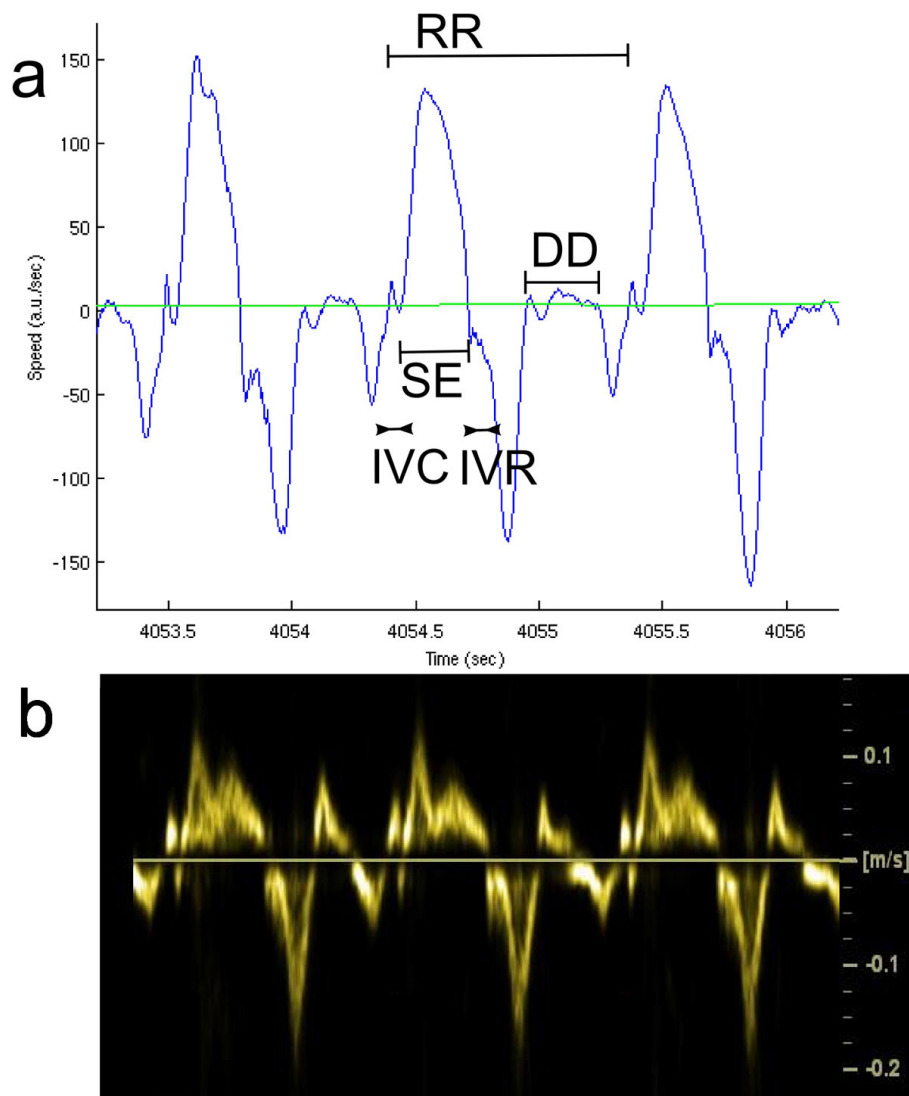
projection of the left ventricular outflow tract plane (Figure 1). Relevant parameters were: 256-point frequency k-space size, 35 cm FOV, 1 view per segment, 150 cm/s velocity encoding and 7 ms TR. Data were Fourier transformed into 1D+t image space, subjected to SVD decomposition for automatic spatial segmentation and finally automatic temporal domain peak detection. This process led to the measurement of four durations for each heartbeat (RR): IsoVolumic Contraction (IVC), Systolic Ejection (SE), IsoVolumic Relaxation (IVR), and Diastolic Diastasis (DD). For every cardiac cycle, the results of the automatic detection were quality controlled by a physician who could either discard the data, correct or accept it. Myocardial Performance Index (MPI) [4] was computed as  $(IVC+IVR)/SE$  as well as normalized systole duration  $(IVC+SE)/RR$  and normalized diastasis duration  $DD/RR$ . These values were checked



**Figure 1** (a) Placement of small axis plane (green) and frequency direction (red). (b) Time-space display of velocity data with automatically selected ROI (blue) corresponding to maximum spectral power in cardiac frequency band.

<sup>2</sup>IADI, Université de Lorraine, Nancy, France

Full list of author information is available at the end of the article



**Figure 2** (a) Example of velocity curve obtained from MRI computed as mean velocity in ROI of Figure 1 (blue). Cardiac cycle (RR), IsoVolumic Contraction (IVC), Systolic Ejection (SE), IsoVolumic Relaxation (IVR) and Diastolic Diastasis (DD) are depicted on the curve. (b) Similar velocity curve obtained from tissue Doppler echocardiography.

against similar indices assessed with tissue Doppler echocardiography performed a few hours before the MRI.

## Results

Seven subjects were discarded due to low echocardiographic or MRI data quality (impossibility to measure all the durations). One subject was manually post processed due to failure of automatic detection and a total of 360 heart beats were also discarded. For eleven subjects, velocity curves similar to echocardiographic ones were obtained (see Figure 2). Within the set of 1048 remaining heart beats, fair correlation was observed between echocardiographic values and the median of accepted

MRI cardiac cycles: r-squared = 0.52 for MPI, 0.61 for systole and 0.74 for diastasis.

## Conclusions

This new method provides velocity curves very similar to echocardiographic tissue Doppler ones and the measurements of duration of the main cardiac cycle components (systole, diastasis) as well as MPI were well correlated. This paves the way for the observation of beat to beat intra-subject variability of cardiac indices.

## Funding

None.

#### Authors' details

<sup>1</sup>IADI INSERM U947, Nancy, France. <sup>2</sup>IADI, Université de Lorraine, Nancy, France. <sup>3</sup>CHU Nancy, Nancy, France. <sup>4</sup>CIC-IT 801, INSERM, Nancy, France.

Published: 16 January 2014

#### References

1. Nagueh: *JASE* 2009.
2. Meyer: *MAGMA* 2013.
3. Tei: *JASE* 1997.
4. Möller: *JMRI* 1996.

doi:10.1186/1532-429X-16-S1-P44

**Cite this article as:** Meyer et al.: Towards a new method for cardiac tissue velocity measurements using MRI, comparison with echocardiography. *Journal of Cardiovascular Magnetic Resonance* 2014 **16** (Suppl 1):P44.

**Submit your next manuscript to BioMed Central  
and take full advantage of:**

- Convenient online submission
- Thorough peer review
- No space constraints or color figure charges
- Immediate publication on acceptance
- Inclusion in PubMed, CAS, Scopus and Google Scholar
- Research which is freely available for redistribution

Submit your manuscript at  
[www.biomedcentral.com/submit](http://www.biomedcentral.com/submit)

