



Corticospinal tract asymmetry and handedness in right- and left-handers by diffusion tensor tractography

Romuald Seizeur, Elsa Magro, Sylvain Prima, Nicolas Wiest-Daesslé, Camille Maumet, Xavier Morandi

► To cite this version:

Romuald Seizeur, Elsa Magro, Sylvain Prima, Nicolas Wiest-Daesslé, Camille Maumet, et al.. Corticospinal tract asymmetry and handedness in right- and left-handers by diffusion tensor tractography: Corticospinal tract asymmetry and handedness. *Surgical and Radiologic Anatomy*, 2013, 36 (2), pp.111-124. 10.1007/s00276-013-1156-7 . inserm-00853861

HAL Id: inserm-00853861

<https://inserm.hal.science/inserm-00853861>

Submitted on 8 Nov 2013

HAL is a multi-disciplinary open access archive for the deposit and dissemination of scientific research documents, whether they are published or not. The documents may come from teaching and research institutions in France or abroad, or from public or private research centers.

L'archive ouverte pluridisciplinaire **HAL**, est destinée au dépôt et à la diffusion de documents scientifiques de niveau recherche, publiés ou non, émanant des établissements d'enseignement et de recherche français ou étrangers, des laboratoires publics ou privés.

1 Title: **Corticospinal tract asymmetry and handedness in right- and left-handers by**
2 **diffusion tensor tractography**

3 Running title: **Corticospinal tract asymmetry and handedness**

5 Author names and affiliations

6 Romuald Seizeur^{1, 2}, Elsa Magro², Sylvain Prima³, Nicolas Wiest-Daesslé³, Camille Maumet³,
7 Xavier Morandi^{4, 5}.

8 1. INSERM UMR 1101, LaTIM, Brest, France

9 2. Service de Neurochirurgie, CHRU Cavale Blanche, Brest, France

10 3. IRISA Unité VisAGeS U746 INSERM / INRIA / CNRS /Université. Rennes 1, Rennes,
11 France

12 4. INSERM U 1099, Equipe MediCIS, Rennes, France

13 5. Service de Neurochirurgie, CHU Pontchaillou, Rennes, France

14 Postal address of each affiliation

15 1. LaTIM, INSERM UMR 1101, avenue Foch, Brest, F- 29200 France

16 2. Unité/Projet VisAGeS IRISA, INSERM U 746, Faculté de Médecine, 35043 Rennes
17 Cedex, France

18 3. CHRU Brest, Service de Neurochirurgie, Brest, F- 29200 France

19 4. Equipe MediCIS, INSERM U 1099, Faculté de Médecine, Rennes, F-35043 France

20 5. CHU Pontchaillou, Service de Neurochirurgie, Rennes, F- 35000 France

22 Corresponding author: Romuald Seizeur

23 Tel: +33 (0)298347314

24 Fax: +33 (0)298347846

25 E-mail: romuald.seizeur@chu-brest.fr

26 Postal address: Service de Neurochirurgie, Pôle Neurolocomoteur, CHU Cavale Blanche,
27 Boulevard Tanguy Prigent, F- 29200 Brest, France

“Corticospinal tract asymmetry and handedness in right- and left-handers by diffusion tensor tractography”

Abstract

Purpose

Cerebral hemispheres represent both structural and functional asymmetry, which differs among right- and left-handers. The left hemisphere is specialized for language and task execution of the right hand in right-handers. We studied the corticospinal tract in right- and left-handers by diffusion tensor imaging and tractography. The present study was aimed at revealing a morphological difference resulting from a region of interest (ROI) obtained by functional MRI (fMRI).

Methods

Twenty-five healthy participants (right-handed: 15, left-handed: 10) were enrolled in our assessment of morphological, functional and diffusion tensor MRI. Assessment of brain fibre reconstruction (tractography) was done using a deterministic algorithm. Fractional anisotropy (FA) and mean diffusivity (MD) were studied on the tractography traces of the reference slices.

Results

We observed a significant difference in number of leftward fibres based on laterality. The significant difference in regard to FA and MD was based on the slices obtained at different levels and the laterality index. We found left hand asymmetry and right hand asymmetry respectively for the MD and FA.

Conclusions

Our study showed the presence of hemispheric asymmetry based on laterality index in right- and left-handers. These results are inconsistent with some studies and consistent with others. The reported difference in hemispheric asymmetry could be related to dexterity (manual skill).

Keywords: corticospinal tract, deterministic tractography, diffusion tensor imaging, anatomy, MRI.

Introduction

Cerebral hemispheric asymmetry was brought up by Hippocrates. He demonstrated how a head wound on one side led to seizures and a hemiplegia of the opposite side of the body (*in* Adams [1]). Since antiquity, many descriptions of brain hemispheric asymmetry have been given. These regard the gray matter (cerebral cortex [29] and the basal ganglia [35]), as well as the white matter [27, 53].

Handedness is one example of lateralization of cerebral functions [15]. Several studies have shown a difference in hemispheric asymmetry, between right- and left-handers [27, 28], according to the assessed functions. Left hemisphere is attributed to language, gnosis and praxis. Right hemisphere is attributed to visuospatial and visuoconstructive perceptions and attention [20]. Language lateralization related to handedness was described by Broca in 1863 [8], stating that left hemisphere was specialized for language and the dominant hand manual task. Geschwind et al. [20, 21] showed that the left *planum temporale* was wider than the right one. Thus, these authors put forward an association between brain anatomical asymmetry and handedness.

More recently, in vivo magnetic resonance imaging (MRI) assessment of encephalic volume revealed the gray and white matter asymmetries [22, 39]. These studies were consistent with previous ones revealing a morphological lateralization of different cerebral lobes. Kertesz et al. [28] showed such lateralization by comparing 52 right-handers with 52 left-handers. They put forward an association between left hemispheric dominance and wider right frontal and left occipital lobes. Other studies have found an association between the depth of central sulcus and handedness [3], or a lateralization of lateral sulcus based on *planum temporale* asymmetry [42]. The encephalon MRI morphometry assessment of central sulcus by Amunts et al. [3] in 31 right-handed and 14 left-handed men, revealed a leftward lateralization of central sulcus in the right-handers. The left-handers showed a less significant lateralization. These authors assumed an association between handedness and a wider cerebral cortex area and likely a more significant cerebral connectivity. In a more recent study [2] by Amunts et al., the leftward lateralization of central sulcus was only observed in men. As a result, a difference in organisation of the cortex related to hand mobility between men and women was reported. Rubens et al. [42] evaluated 36 bodies by cerebral hemisphere photographic methods and assessing the length and shape of the lateral sulcus. The left lateral hemisphere was reported to be longer and more rectilinear than the right one. This could affect the size of neighboring brain structures such as *planum temporale*. The results of an evaluation of 100 bodies by Geschwind and Levitsky [21], were consistent with those of Rubens et al.: in accordance to the length of lateral sulcus, the left *planum temporale* was

reported to be wider (65% of cases) than the right one. However, Saenger et al. [43] studied brain asymmetries using MRI functional connectivity and gray matter volume in right- and left-handers. They concluded that functional asymmetries are not always concordant with morphological asymmetries.

Some authors also studied the association between handedness, or possible existence of dexterity (manual skill), and lateralization of the white matter [9, 24, 52]. Today, diffusion tensor imaging (DTI) and tractography allow the reconstruction of fibre tracts and even bringing light into the possible association between lateralization of the corticospinal tract (CST) and handedness. Büchel et al. [9] showed an increase in fractional anisotropy (FA) within the precentral gyrus, contralateral to the dominant hand. They revealed the following: an association between cerebral asymmetry and handedness, and the role of DTI in the assessment of the white matter. Westerhausen et al. [52] DTI assessment of the association between cerebral asymmetry and internal capsule asymmetry was conclusive. However, no evident correlation between internal capsule asymmetry and laterality was revealed. In his 2002 literature review, Hammond [24] stated that the dominant hemisphere, contralateral to the dominant hand, represented a better functional organisation via an increase in cortical connectivity of the primary motor area (M1). This could explain the better manual task performance of the dominant hand but does not prove a correlation with the CST volume.

The aim of our study was to evaluate the correlation between handedness and cerebral asymmetry through focusing on hand motor fibres within the CST. Using deterministic tractography, we aimed to highlight a difference between the right- and left- handers. The choice of our method followed the footsteps of a previous study [44] by comparing the following parameters: FA and mean diffusivity (MD).

Material

Subjects

Twenty-five healthy volunteers were enrolled in this study: fifteen right-handers (ten men and five women) and ten left-handers (six men and four women). They had no history of neurological disorders. Age ranged from 22 years to 46 years (mean age 30.8 years) for right-handers and 18 years to 42 years (mean age 29.2) for left-handers. Written informed consent was obtained from each subject and data were handled anonymously. Handedness

was determined using a test created by Dellatolas [17] for use on the healthy population in France, adapted from studies by Annett [4] and Oldfield [34]. Index laterality is summarised in table 1.

Magnetic Resonance (MR) data acquisition

Brain MR scans were carried out on each volunteer. MRI scans were performed on a Philips Achieva 3T system (Philips Medical Systems, Best, The Netherlands) using an 8-channel head coil. All volunteers were in supine position. To minimise involuntary head motion, bitemporal maintenance points were used.

The protocol used was the following:

- *Morphological MRI*: T1-weighted sequence in single shot echo-planar. All acquired volumes contained 184 sagittal slices, field of view (FOV): 256x256 mm; acquisition matrix: 256 x 256; voxel size: 1 x 1 x 1 mm³; TE / TR / Flip angle: 4.6 ms / 9.9 ms / 8°; SENSE factor: 2. Total duration of this sequence was 3min53s.

- Functional imaging sequence

The fMRI acquisition sequence used gradient echo-planar imaging (EPI) to provide BOLD contrast (blood oxygen-level dependent). Each volume represented comprised 24 contiguous 4 mm axial slices parallel to the AC-PC line, with parameters as follows: FOV: 230 mm; acquisition matrix: 80 x 80; reconstruction matrix after interpolation: 128 x 128; reconstructed voxel size: 1.8 x 1.8 x 4 mm³; TE / TR / Flip angle: 35 ms / 3000 ms / 90°. The acquisition of this 24-slice volume was repeated 62 times. Total duration of each sequence was 3min12s.

The paradigm followed a block design: seven interleaved 30s phases of rest and motor tasks were recorded. The motor tasks consisted of opening and closing the hand. After a period to obtain gradient stabilisation, acquisition of the first two 24-slice volumes was performed (6 s) in three sequences of alternating rest and activation, beginning with rest.

154 This protocol was performed twice, once for the right hand and once for the left one.

155

156 - *Diffusion weighted imaging (DWI) sequence*

157 The DWI acquisition sequence was an EPI, single shot spin echo Stejskal Tanner sequence,
158 combined with SENSE parallel imaging. Diffusion gradients were applied in 15 noncollinear
159 directions with $b = 800 \text{ sec/mm}^2$. Parameters were as follows: 60 2-mm slices; FOV: 256 mm;
160 acquisition matrix and reconstructed matrix: 128×128 ; reconstructed voxel size: $2 \times 2 \times 2$
161 mm^3 ; TE / TR / Flip angle: 64 ms / 10000 ms / 90° ; SENSE factor: 3. Total duration of this
162 sequence was 6min.12s.

163

164 **Method**

165

166 *Data processing and post-processing*

167

168 *Morphological MRI*

169 The MRI T1-weighted sequence was used to obtain a morphological image. This image was
170 used to segment ROIs and to visualize fibre bundles and ROIs on the same image after
171 registration of all sequences.

172 This sequence was used to determinate axial reference slices using fixed landmarks for all
173 subjects. Three reference slices (Figure 1) were localised in corona radiate, internal capsule
174 and diencephalon-mesencephalon junction. Diffusion parameters were recorded on these
175 slices.

176

177

178 *Functional MRI*

All post-processing calculations were carried out using SPM5 routines (statistical parametrical mapping SPM5 / Wellcome Department of Neurology, Institute of Neurology, London) as well as in-house Matlab scripts (Matlab (2007), The MathWorks Inc). The 24-slice, 62 volumes were automatically realigned with the first to correct head motions. For each volunteer, all volumes were smoothed (smoothness window: 6x6x6). Individual statistical parametric maps were calculated using the general linear model [19] to compare brain activation and stimulation. At the first level, the design matrix included one regressor to model the block paradigm with implicit baseline ("1" for action scans, "0" for rest scans). For each paradigm (left/right), the effect of interest was evaluated with the following contrast: $c=1$. Anatomical data and fMRI data were normalised and coregistered (nonlinear registration). Coregistered volumes were visually inspected to assess the quality of the registration. The fMRI data were used to segment a part of the superior ROI.

DTI data

Diffusion weighted imaging (DWI) scans were first realigned and corrected for eddy currents distortions. Each DWI image was realigned with the non-weighted image ($b=0$ s/mm²). For each voxel, a tensor was estimated using a linear regression method [18]. Tensor being a 3x3 symmetric definite positive matrix, it was diagonalised to obtain its eigenvalues (strictly positives) for each voxel, from which fractional anisotropy (FA) and mean diffusivity (MD) maps were derived.

Fibre tracking

DTI fibre tracking was performed using in-house software implementation of conventional fibre tracking algorithms. A deterministic algorithm was used. It was an integration method derived from the fibre assignment by continuous tracking (FACT) method [32], using second-order Runge-Kutta (RK2) [6, 14].

Integration methods use constant integration step size. The FACT method allows the prediction of the position of different points all along the fibre curve. The direction was provided step by step; the step size was 1mm (voxel size). The RK2 method provided an estimation of the trajectory. This trajectory was used to estimate a second, more precise trajectory using one other estimation of this trajectory.

210

211 *ROI segmentation*

212 We chose to track the CST with a multiple ROI method: the superior ROI (cortical area); the
213 inferior ROI (in the mesencephalon); and an exclusion ROI in the median sagittal plane. The
214 ROIs were segmented by a neuroanatomist.

215 The superior ROI was segmented using motor activation (fMRI) and the T1-weighted MR
216 images. Since this study focused on the CST, all non-cortical activations (e.g. cerebellar)
217 were discarded. We retain the activation from the fMRI corresponding to the hand motor area
218 using the anatomical landmark of the precentral gyrus described by Yousry et al. [54], and its
219 variations [11]. To focus the superior ROI around the hand motor area, a segmentation
220 algorithm (all non-connected components were discarded) was used to suppress adjacent
221 activations, i.e. contralateral activation, venous artefacts, activations from supplementary
222 motor area. This method allowed the preservation of each subject's motor activation in the
223 motor area [31] (Figure 2).

224 The inferior ROI was determined by manual segmentation based on our knowledge of the
225 CST anatomy in the mesencephalon. This ROI was located in the anterior part of the
226 peduncle (*crus cerebri*) (Figure 2). This segmentation was performed on the T1-weighted MR
227 image with Anatomist software (BrainVISA/Anatomist version 3.0.2).

228 A third ROI was considered and represented by the median sagittal plane. The fibre
229 reconstruction was done step by step hence this third ROI could not be reached by the
230 fibres.

231 *CST reconstruction by fibre tracking*

232 CST was reconstructed (tractography), using the algorithm based on RK2 previously
233 described, and between ROIs (superior and inferior). The fibres could not go through the
234 sagittal median plane (Figure 2). Two parameters were fixed to stop the tracking: the minimal
235 FA value was set to 0.2 and the maximal angle between two adjacent eigenvectors
236 (deviation angle) was less than 45°.

237 At each axial, coronal and sagittal slice, we observed and saved the fibre passing points. The
238 latter were called "traces". Traces were studied on the reference slice, described before, with
239 the point by point mean measurement of FA and MD (Figure 3).

240

241 *Evaluation*

242 Each fibre bundle was visually verified to ensure the quality and the reliability of the images.
243 Asymmetry and laterality were evaluated by several measurements: superior ROI volumes,
244 fibre number for all subjects on both sides, FA and MD on reference slices

245

246 *Statistical analysis*

247 For statistical analysis, Student t-tests were used for quantitative results (i.e. fibre number
248 and superior ROI volume) and a *Spearman correlation test* was used to find a correlation
249 between laterality and the measured parameters (FA, MD).

250 All statistical analyses were conducted using the SAS software (SAS Institute Inc., version
251 9.2).

252

253 **Results**

254 *ROI volume and laterality*

255 The ROI volumes are displayed in Table 2. No significant difference was observed between
256 left and right regions in right- and left-handers ($p=0.83$). No significant difference was
257 observed between right ($p=0.29$), and left ($p=0.07$) based on laterality.

258

259 *Fibre numbers and laterality*

260 The results of number of fibres are displayed in Table 3. No significant difference was
261 observed for the right hand side (*r*) or the left hand side (*l*), in right- ($p=0.31$) and left-
262 handers ($p=0.12$). However, a significant difference based on laterality was reported for the
263 left hand side ($p=0.03$) and none for the right hand side ($p=0.18$).

264

265

266

267

268 *Fractional anisotropy and laterality*

269 The FA measurements by level, side (r or l) and laterality (R or L) are summarised in Figure
270 4. Table 4 displays handedness and laterality results, the FA measurements: the minimum,
271 the maximum, the means, the medians and the p values.

272 In regard to asymmetry, we observed a significant difference in the right-handers at 2 of the 3
273 levels of the slice (level 2: $p < 0.0001$ and level 3: $p < 0.0001$). In fact, the FA mean and median
274 of the above 2 levels were higher for the left hand side. However, in the left-handers, level 2
275 ($p = 0.0007$) and 3 ($p = 0.0001$) means were higher for the right hand side.

276 In regard to laterality, very significant differences were observed at the 3 levels of the slice:
277 FA measurement was higher for the right-handers (both sides). The exception to this was
278 reported for the left hand side at level 1 where *corona radiata* was not significantly different.

279

280 *Mean diffusivity and laterality*

281 Figure 5 displays all the MD measurements: by level, side (r or l), and laterality (R or L).
282 Table 5 displays the MD results: minimum and maximum, means, medians and p values.

283 In regard to asymmetry, a significant difference was observed at slice level 2 ($p < 0.0001$) in
284 the right-handers. The mean and median were higher for the right hand side. There was a
285 significant difference at the 3 slice levels in the left-handers: level 1, 2 and 3, p -values were
286 respectively 0.0111, < 0.0001 , and < 0.0001 . The means were reported to be higher for the
287 right hand side.

288 In regard to laterality, significant differences were reported at the 3 slice levels. At the slice
289 level 1 and 2 for the left hand side and level 3 for the right hand side (all 3 levels of slice
290 $p < 0.0001$).

291

292 *Laterality correlation with FA and MD*

A correlation was reported for the FA ($r= 0.107$; $p<0.0001$) and MD ($r=-0.051$; $p=0.0199$) based on laterality in the left-handers (Table 1).

Discussion

Our results highlighted significant differences of FA and MD parameters at three different slice levels. In addition, we revealed a correlation between the laterality index and the FA and MD parameters. We would like to emphasize that in this study, the fMRI images labeled “right” or “left” side refers to the “hand” that was used for motor function assessment, i.e. the right hand side referred to the left hemisphere. Indeed, most of the literature mentioned here reported the cerebral hemisphere on which their study was based.

We selected one of the three ROI that was segmented from functional data taking into account the motor function area of the hand [30]. This study did not show a significant difference either of hemispheric asymmetry or laterality association with the ROI volumes. These results are not consistent with those of the literature reporting asymmetry of the motor functions by fMRI. This could be a bias of our results, given the published evidence that the functional activation is more important at the left motor cortex in right-handers (for the mobility of right and left hand) [23, 29]. This could be explained by the several CST fibres which do not decussate [53]. Other explanation could be the association with the laterality index. Dassonville et al. [16] studied the fMRI motor function of the dominant and non-dominant hand in seven right-handers and six left-handers. They demonstrated that the cortical function is more important for the dominant hand and that it is correlated with the laterality index in both right- and left-handers.

The hemispheric asymmetry revealed in our study was that of the left hand side FA, and that of the right hand side MD (i.e. respectively, the right and left hemisphere). In regard to the FA, we reported a significant difference between the right- and left-handers with a larger FA at right and left in the right-handers. The FA increased based on the laterality index in left-handers (7 to 20/20). There was no evidence of such correlation in the right-handers since our sample consisted of real right-handers except for one slightly ambidextrous (1/20). The FA points out the diffusion process direction [7] and it is influenced by axon myelination, cellular density as well as fibre diameter [46]. Our results are not consistent with those of the reviewed literature and did not conclude a difference in fibre organisation between the right-

and left-handers. Sullivan et al. [49], in their study on internal capsule FA in 24 right-handers, found different FA measures in different zones. They stated that this variation of FA was related to the diversity of fibres passing through the internal capsule. Our study took into account an overall FA at each slice level, but by analysing the fibres resulting from RK2 algorithm of CST reconstruction. We would like to emphasize the limitation of our fibres reconstruction method, deterministic tractography, unable to resolve “crossing” and “kissing” fibre bundles within a voxel [12, 40]. Our MD results were similar to the FA ones. However, there was a significant difference at the three slice levels: less homogenous results in regard to only one side at each level. A difference was reported at two slice levels for the left hand side, (i.e. the right hemisphere), being the non-dominant hand in right-handers and less often dominant in left-handers (15% of the cases [38]).

Our DTI and tractography study, at several levels of encephalon, of the white matter tracts run by CST hand motor fibres, did not allow to show a clear significant difference between the right- and left-handers. Several authors [9, 36, 41, 50, 52] have demonstrated an asymmetry between the right and left side of the encephalon. Some authors [41, 50], have reported results consistent with ours in regard to FA. Toosy et al. [50], in their study of 21 cases with amyotrophic lateral sclerosis and 14 controls, showed a gradual decrease of FA on the rostro-caudal axis in the controls. The FA was reported to have more significant difference at the internal capsule of the right hemisphere. The FA decrease was explained by the size of the studied structure within the brainstem and the number of crossing fibres. The above results cannot be compared with ours since we did not study the brainstem. Reich et al. [41], in their 3T scan assessment of CST in 20 volunteers, obtained a correlation between inter-hemispheric number of fibres. This asymmetry varies based on the zone in the nervous system, and an increase in MD asymmetry has been shown in the assessment of hemispheric zone of right CST. This was demonstrated in the study of posterior limb of internal capsule of 60 volunteers (30 right-handers and 30 left-handers) by Westerhausen et al. [52]. These authors showed an increase in left-hand FA and right-hand MD. However, no difference was observed based on laterality. One possible explanation was that the dominant hand muscles to be more innervated than the non-dominant hand muscles. This could explain the dexterity hypothesis [24].

To date, Büchel et al. [9] are the only authors demonstrating an association between handedness and part of the encephalon through an assessment of their second group (28 cases). They found asymmetric FA in the precentral gyrus, contralateral to the dominant hand. In their MRI morphometric evaluation of 56 young right-handed men, Hervé et al. [26] revealed asymmetric gray matter in the precentral and central regions and no neighbouring

white matter difference despite the observed left hand side asymmetry. In their fMRI DTI study of arcuate fasciculus in 12 cases (seven right-handers), Vernooij et al. [51] used CST as the reference bundle. They reported leftward asymmetric arcuate fasciculus without any relation with laterality (dominant hand or language), consistent with a previous study on CST (Cicarelli et al. [13]) and contrary to others on motor system [2, 3, 26].

Decussation of CST fibres could be one explanation for not observing an evidence of correlation with laterality. Yakovlev et Rakic [53], in their dissection of fibre bundles in 100 medulla oblonga and 130 spinal cords of foetus and new-borns, demonstrated that in 2/3 of the cases, there were more left hemisphere fibres decussating to the right, and more right hemisphere fibres running to the right of spinal cord. Consequently, the right side of the spinal cord could be considered as the dominant side since it receives more fibres from both sides of the encephalon. Thereafter, Kertesz et Geschwind [27] conducted a similar study by taking into account handedness of the cases, but did not find a correlation with laterality. Consistent results of a more recent study [33] on 70 spinal cord cases revealed right side fibre asymmetry in $\frac{3}{4}$ of the cases, and more fibres running to the right than left in $\frac{3}{4}$ of the cases. However, there was no evidence of correlation with handedness, sole a correlation with dexterity was suspected.

Laterality is different between men and women. There are more right-handed women, and thus more (> 25%) non-right-handed men (ambidextrous and left-handers) [47]. Hervé et al. [26] described a less significant *planum temporale* asymmetry in left-handers men. Shapleske et al. [45] found a significant *planum temporale* asymmetry for the left hand side. This difference was reported to decrease in left-handers and women. Amunts et al. [2] found that central sulcus was deeper based on laterality only in men (right central sulcus was deeper in 62% of left-handers). Pujol et al. [39] reported hemispheric volume asymmetry on MRI revealing a larger left hemisphere. This hemispheric volume asymmetry was reported to be more significant in men. Powell et al. [37] performed voxel-based statistical analysis on FA maps of 42 right-handers and 40 left handers. Leftward anisotropy was found in arcuate fasciculus regions (greater in right-handers). Studying differences between men and women, they concluded that sex had greater effect than handedness on FA asymmetries. In the previous cited study by Westerhausen et al. [52], a significant difference was reported with an increase in FA in male brains. These authors suggested a difference in CST organisation and structure within internal capsule between men and women. Given the bigger size of men's brain, the above hypothesis may indicate a variation of CST and thus of parameters such as FA representing its structure. The gender volume asymmetry difference disappeared

after matching data for brain size. Catani et al. [10] studied 40 right-handed adults and reported no difference in CST volume and FA parameter between men and women.

Most of the literature aiming at determining an association between asymmetry and laterality used a small sample size leading to their results limitation [25]. In addition, it is well known that left-handers are not a homogenous population – their dominant hemisphere is the right hemisphere in 15% of the cases [38] while some could be culturally and environmentally forced into right-handedness. In fact, most of variation in handedness is due to genetic effects [5], the rest being attributable to environmental influences [15]. Assessment of laterality is often done by various methods. It is worth mentioning that some studies have not used any assessment method [25]. For instance, Good et al. [22], conducted their laterality assessment of 67 left- and 398 right-handers based on the dominant hand for writing. Such assessment has its limitation in regard to the impact of laterality [47]. We chose an assessment method derived from studies done on a sample of French population free of neurological pathologies (e.g. our sample) [17].

To conclude, consistent with other studies, we demonstrated a CST hand motor task asymmetry in relation with laterality. In line with the literature [10], our study had its limitations such as our deterministic tractography method and our small size for each group. Our results did not allow us to draw conclusions in terms of laterality index. Thus, we suggest larger scale studies using other assessment methods such as diffusion direction imaging [48], i.e. MRI with a low angle diffusion, to obtain a more precise CST reconstruction in particular in the crossing and kissing fibre zones.

Aknowledgements

The authors would like to warmly thank Zarrin Alavi (MSc), INSERM CIC 0502, for her assistance to realize this manuscript.

Conflict of interest

The authors declare no conflict of interest in the realization of this study.

423

424 References

425

- 426 1. Adams F (1849) The genuine works of Hippocrates. William Woods, New York.
- 427 2. Amunts K, Jancke L, Mohlberg H, Steinmetz H, Zilles K (2000) Interhemispheric
428 asymmetry of the human motor cortex related to handedness and gender.
429 *Neuropsychologia* 38:304-312
- 430 3. Amunts K, Schlaug G, Schleicher A, Steinmetz H, Dabringhaus A, Roland PE, Zilles K
431 (1996) Asymmetry in the human motor cortex and handedness. *Neuroimage* 4:216-222
- 432 4. Annett M (1970) A classification of hand preference by association analysis. *Br J Psychol*
433 61:303-321
- 434 5. Annett M (1998) Handedness and cerebral dominance: the right shift theory. *J*
435 *Neuropsychiatry Clin Neurosci* 10:459-469
- 436 6. Basser PJ, Pajevic S, Pierpaoli C, Duda J, Aldroubi A (2000) In vivo fiber tractography
437 using DT-MRI data. *Magn Reson Med* 44:625-632
- 438 7. Beaulieu C (2002) The basis of anisotropic water diffusion in the nervous system - a
439 technical review. *NMR Biomed* 15:435-455
- 440 8. Broca P (1863) Localisation des fonctions cérébrales. Siège du langage articulé. *Bull Soc*
441 *Anthropol* 4:200-204
- 442 9. Büchel C, Raedler T, Sommer M, Sach M, Weiller C, Koch MA (2004) White matter
443 asymmetry in the human brain: a diffusion tensor MRI study. *Cereb Cortex* 14:945-951
- 444 10. Catani M, Forkel S, Thiebaut de SM (2010) Asymetry of white matter pathways. 177-209
- 445 11. Caulo M, Briganti C, Mattei PA, Perfetti B, Ferretti A, Romani GL, Tartaro A, Colosimo C
446 (2007) New morphologic variants of the hand motor cortex as seen with MR imaging in a
447 large study population. *AJNR Am J Neuroradiol* 28:1480-1485
- 448 12. Ciccarelli O, Catani M, Johansen-Berg H, Clark C, Thompson A (2008) Diffusion-based
449 tractography in neurological disorders: concepts, applications, and future developments.
450 *Lancet Neurol* 7:715-727
- 451 13. Ciccarelli O, Parker GJ, Toosy AT, Wheeler-Kingshott CA, Barker GJ, Boulby PA, Miller
452 DH, Thompson AJ (2003) From diffusion tractography to quantitative white matter tract
453 measures: a reproducibility study. *Neuroimage* 18:348-359
- 454 14. Conturo TE, Lori NF, Cull TS, Akbudak E, Snyder AZ, Shimony JS, McKinstry RC, Burton
455 H, Raichle ME (1999) Tracking neuronal fiber pathways in the living human brain. *Proc*
456 *Natl Acad Sci U S A* 96:10422-10427

15. Corballis MC, Badzakova-Trajkov G, Häberling IS (2012) Right hand, left brain: genetic and evolutionary bases of cerebral asymmetries for language and manual action. *WIREs Cogn Sci* 3:1-17
16. Dassonville P, Zhu XO, Ugurbil K, Kim SG, Ashe J (1997) Functional activation in motor cortex reflects the direction and the degree of handedness. *Proc Natl Acad Sci U S A* 94:14015-14018
17. Dellatolas G, De Agostini M, Jallon P, Poncet M, Rey M, Lellouch J (1988) Mesure de la préférence manuelle par autoquestionnaire dans la population française adulte. *Revue de Psychologie appliquée* 38:117-136
18. Fillard P, Arsigny V, Pennec X, Hayashi KM, Thompson PM, Ayache N (2007) Measuring brain variability by extrapolating sparse tensor fields measured on sulcal lines. *Neuroimage* 34:639-650
19. Friston KJ, Holmes AP, Worsley KJ, Poline J-P, Frith CD, Frackowiak RS (1995) Statistical parametric maps in functional imaging: a general linear approach. *Hum Brain Mapp* 2:189-210
20. Geschwind N (1972) Cerebral dominance and anatomic asymmetry. *N Engl J Med* 287:194-195
21. Geschwind N, Levitsky W (1968) Human brain: left-right asymmetries in temporal speech region. *Science* 161:186-187
22. Good CD, Johnsrude I, Ashburner J, Henson RN, Friston KJ, Frackowiak RS (2001) Cerebral asymmetry and the effects of sex and handedness on brain structure: a voxel-based morphometric analysis of 465 normal adult human brains. *Neuroimage* 14:685-700
23. Gut M, Urbanik A, Forsberg L, Binder M, Rymarczyk K, Sobiecka B, Kozub J, Grabowska A (2007) Brain correlates of right-handedness. *Acta Neurobiol Exp (Wars)* 67:43-51
24. Hammond G (2002) Correlates of human handedness in primary motor cortex: a review and hypothesis. *Neurosci Biobehav Rev* 26:285-292
25. Hatta T (2007) Handedness and the brain: a review of brain-imaging techniques. *Magn Reson Med Sci* 6:99-112
26. Hervé PY, Crivello F, Perchey G, Mazoyer B, Tzourio-Mazoyer N (2006) Handedness and cerebral anatomical asymmetries in young adult males. *Neuroimage* 29:1066-1079
27. Kertesz A, Geschwind N (1971) Patterns of pyramidal decussation and their relationship to handedness. *Arch Neurol* 24:326-332
28. Kertesz A, Polk M, Black SE, Howell J (1992) Anatomical asymmetries and functional laterality. *Brain* 115 (Pt 2):589-605
29. Kim SG, Ashe J, Hendrich K, Ellermann JM, Merkle H, Ugurbil K, Georgopoulos AP (1993) Functional magnetic resonance imaging of motor cortex: hemispheric asymmetry and handedness. *Science* 261:615-617

494 30. Kim YH, Kim DS, Hong JH, Park CH, Hua N, Bickart KC, Byun WM, Jang SH (2008)
495 Corticospinal tract location in internal capsule of human brain: diffusion tensor
496 tractography and functional MRI study. *Neuroreport* 19:817-820

497 31. Lotze M, Erb M, Flor H, Huelsmann E, Godde B, Grodd W (2000) fMRI evaluation of
498 somatotopic representation in human primary motor cortex. *Neuroimage* 11:473-481

499 32. Mori S, Crain BJ, Chacko VP, van Zijl PC (1999) Three-dimensional tracking of axonal
500 projections in the brain by magnetic resonance imaging. *Ann Neurol* 45:265-269

501 33. Nathan PW, Smith MC, Deacon P (1990) The corticospinal tracts in man. Course and
502 location of fibres at different segmental levels. *Brain* 113 (Pt 2):303-324

503 34. Oldfield RC (1971) The assessment and analysis of handedness: the Edinburgh
504 inventory. *Neuropsychologia* 9:97-113

505 35. Peterson BS, Riddle MA, Cohen DJ, Katz LD, Smith JC, Leckman JF (1993) Human
506 basal ganglia volume asymmetries on magnetic resonance images. *Magn Reson Imaging*
507 11:493-498

508 36. Powell HW, Parker GJ, Alexander DC, Symms MR, Boulby PA, Wheeler-Kingshott CA,
509 Barker GJ, Noppeney U, Koepp MJ, Duncan JS (2006) Hemispheric asymmetries in
510 language-related pathways: a combined functional MRI and tractography study.
511 *Neuroimage* 32:388-399

512 37. Powell JL, Parkes L, Kemp GJ, Sluming V, Barrick TR, Garcia-Finana M (2012) The
513 effect of sex and handedness on white matter anisotropy: a diffusion tensor magnetic
514 resonance imaging study. *Neuroscience* 207:227-242

515 38. Pujol J, Deus J, Losilla JM, Capdevila A (1999) Cerebral lateralization of language in
516 normal left-handed people studied by functional MRI. *Neurology* 52:1038-1043

517 39. Pujol J, Lopez-Sala A, Deus J, Cardoner N, Sebastian-Galles N, Conesa G, Capdevila A
518 (2002) The lateral asymmetry of the human brain studied by volumetric magnetic
519 resonance imaging. *Neuroimage* 17:670-679

520 40. Qazi AA, Radmanesh A, O'Donnell L, Kindlmann G, Peled S, Whalen S, Westin CF,
521 Golby AJ (2009) Resolving crossings in the corticospinal tract by two-tensor streamline
522 tractography: Method and clinical assessment using fMRI. *Neuroimage* 47 Suppl 2:T98-
523 106

524 41. Reich DS, Smith SA, Jones CK, Zackowski KM, van Zijl PC, Calabresi PA, Mori S (2006)
525 Quantitative characterization of the corticospinal tract at 3T. *AJNR Am J Neuroradiol*
526 27:2168-2178

527 42. Rubens AB, Mahowald MW, Hutton JT (1976) Asymmetry of the lateral (sylvian) fissures
528 in man. *Neurology* 26:620-624

43. Saenger VM, Fernando FA, Martinez-Gudino ML, Alcauter S (2012) Hemispheric asymmetries of functional connectivity and grey matter volume in the default mode network. *Neuropsychologia* 50:1308-1315
44. Seizeur R, Wiest-Daessle N, Prima S, Maumet C, Ferre JC, Morandi X (2012) Corticospinal tractography with morphological, functional and diffusion tensor MRI: a comparative study of four deterministic algorithms used in clinical routine. *Surg Radiol Anat* 34:709-719
45. Shapleske J, Rossell SL, Woodruff PW, David AS (1999) The planum temporale: a systematic, quantitative review of its structural, functional and clinical significance. *Brain Res Brain Res Rev* 29:26-49
46. Shimony JS, McKinstry RC, Akbudak E, Aronovitz JA, Snyder AZ, Lori NF, Cull TS, Conturo TE (1999) Quantitative diffusion-tensor anisotropy brain MR imaging: normative human data and anatomic analysis. *Radiology* 212:770-784
47. Sommer IEC (2010) Sex differences in handedness, brain asymmetry, and language lateralization. *Information Processing in the Cerebral Hemispheres*. 277-312
48. Stamm A, Perez P, Barillot C (2011) Diffusion Directions Imaging (DDI). Technical report, INRIA
49. Sullivan EV, Zahr NM, Rohlfing T, Pfefferbaum A (2010) Fiber tracking functionally distinct components of the internal capsule. *Neuropsychologia* 48:4155-4163
50. Toosy AT, Werring DJ, Orrell RW, Howard RS, King MD, Barker GJ, Miller DH, Thompson AJ (2003) Diffusion tensor imaging detects corticospinal tract involvement at multiple levels in amyotrophic lateral sclerosis. *J Neurol Neurosurg Psychiatry* 74:1250-1257
51. Vernooij MW, Smits M, Wielopolski PA, Houston GC, Krestin GP, van der LA (2007) Fiber density asymmetry of the arcuate fasciculus in relation to functional hemispheric language lateralization in both right- and left-handed healthy subjects: a combined fMRI and DTI study. *Neuroimage* 35:1064-1076
52. Westerhausen R, Huster RJ, Kreuder F, Wittling W, Schweiger E (2007) Corticospinal tract asymmetries at the level of the internal capsule: is there an association with handedness? *Neuroimage* 37:379-386
53. Yakovlev P, Rakic P (1966) Patterns of decussation of bulbar pyramids and distribution of pyramidal tracts on two sides of spinal cord. *Trans Am Neurol Assoc* 81:366-367
54. Yousry TA, Schmid UD, Alkadhi H, Schmidt D, Peraud A, Buettner A, Winkler P (1997) Localization of the motor hand area to a knob on the precentral gyrus. A new landmark. *Brain* 120 (Pt 1):141-157

565

566

567

568 Figures

569 Fig 1 Coronal slice of the brain through the anterior commissure. Reference slices in the brain for the study of traces. Level 1
570 (*corona radiata*), dorsal part of corpus callosum. Level 2 (internal capsule), dorsal part of the lenticular nucleus. Level 3
571 (diencephalon-mesencephalon junction), ventral part of the lenticular nucleus.

572

573 Fig 2 Coronal slice: tractography visualisation from merged images. Morphological MRI (T1); superior ROI (A and A'); inferior
574 ROI (B); sagittal median plan (C); tractographies (blue and red colours, right- and left- hand fibres respectively). Axial slice: crus
575 cerebri, inferior ROI on left side, location of CST on right side.

576

577 Fig 3 Tractography traces. Top left: coronal slice, top right: sagittal slice. Bottom: left to right, slice level inferior (1), middle (2),
578 superior (3). In white colour we visualised all points representing the traces with a clear asymmetry in the present case.

579

580 Fig 4: The FA measurements by level (lev), side (r or l) and laterality (R or L), along with the best fitted linear regression plot

581 (a) In Right-handers (R), (b) In Left-handers (L)

582

583 Fig 5: The MD measurements by level (lev), side (r or l) and laterality (R or L), along with the best fitted linear regression plot

584 (a) In Right-handers (R), (b) In Left-handers (L)

585

586 Tables

587

588 Table 1

589 Score and Laterality of subjects, test from [17], ranged from 0 to 20. R: right-hander (0/20), RA: right-handed ambidextrous (1 to
590 6/20), L: left-hander (17 to 20/20), LA: left-handed ambidextrous (7 to 16/20).

591

592 Table 2

593 Quantitative results, ROI volumes (mm³) from both right (r) and left (l) hand fMRI. Right-handers (R) are ranked 1 to 15, left-
594 handers (L) are ranked 16 to 25. SD: Standard Deviation.

595

596 Table 3

597 Quantitative results, number of fibres for RK2 algorithm. Right-handers (R) are ranked 1 to 15, left-handers (L) are ranked 16 to
598 25. SD: Standard Deviation.

599

600 Table 4

601 Brain asymmetry from laterality, FA results, mean, median, Standard Deviation (SD) and p value (t test). R vs L (right-side):
602 looking for a significant difference between right-handers (R) and left-handers (L) based on laterality.

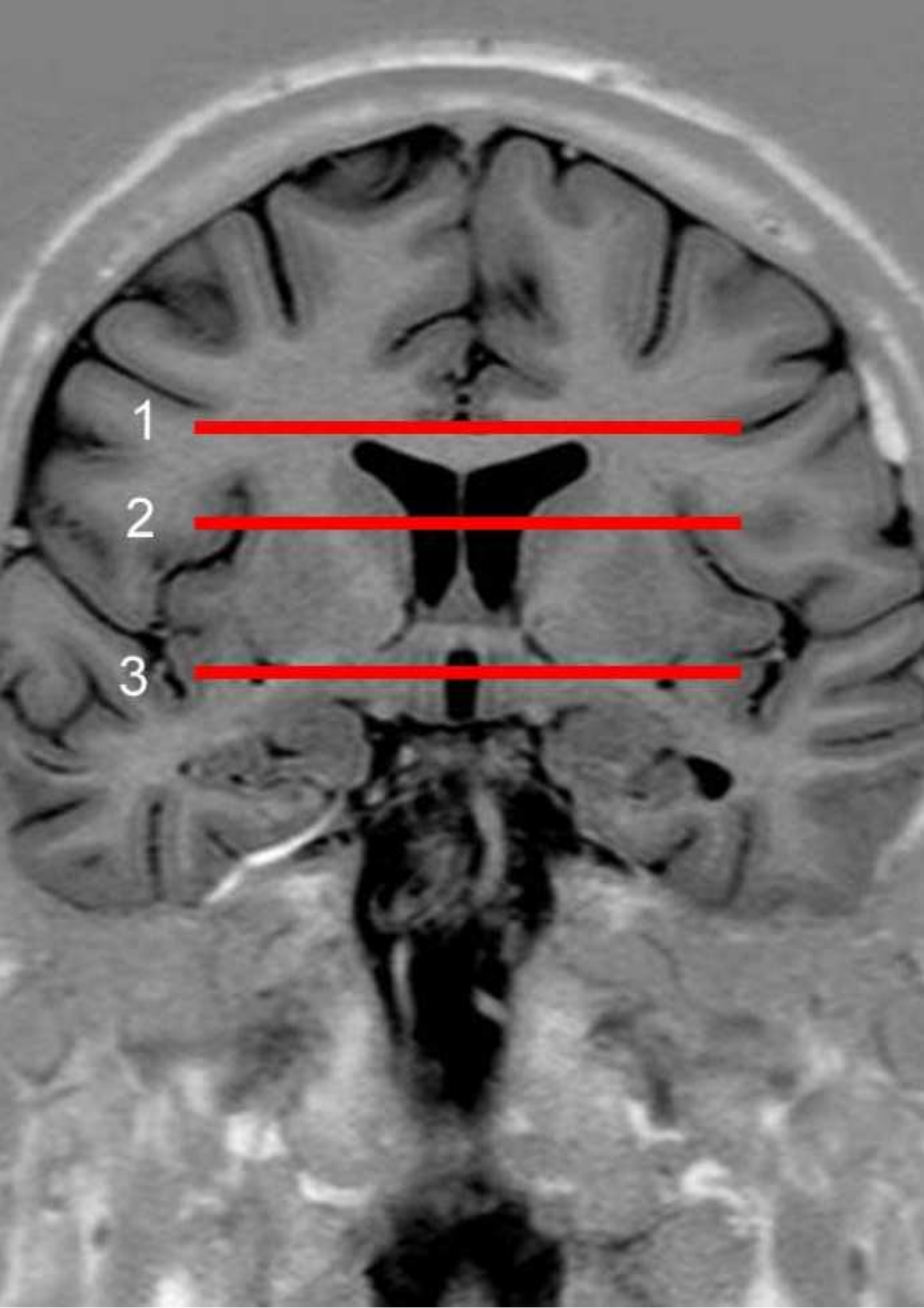
603

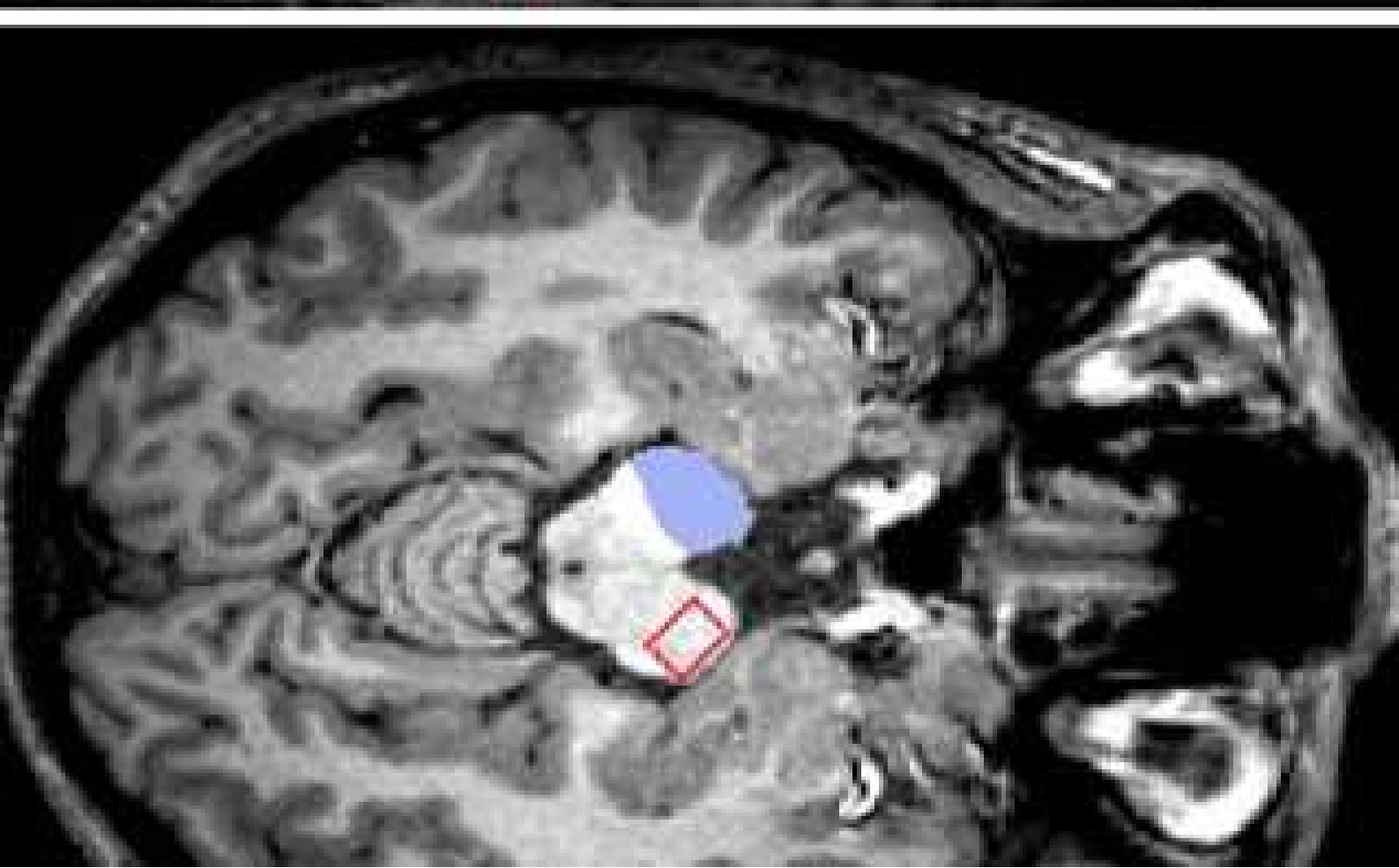
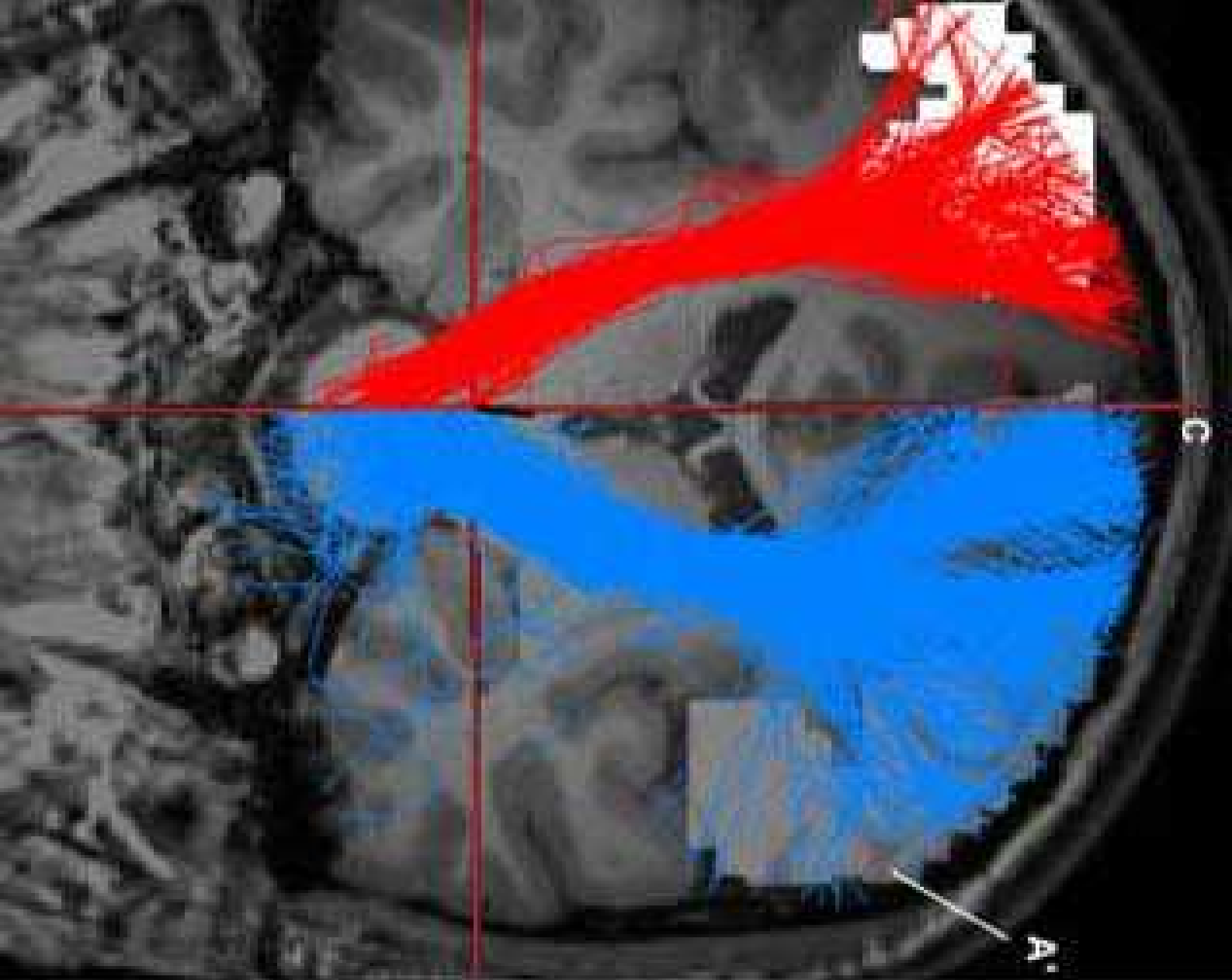
604 Table 5

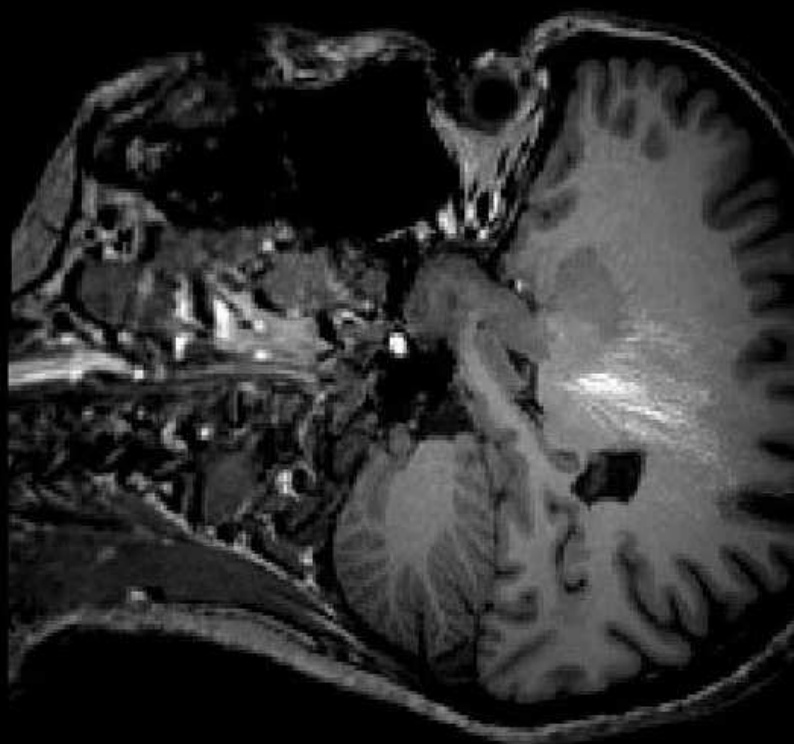
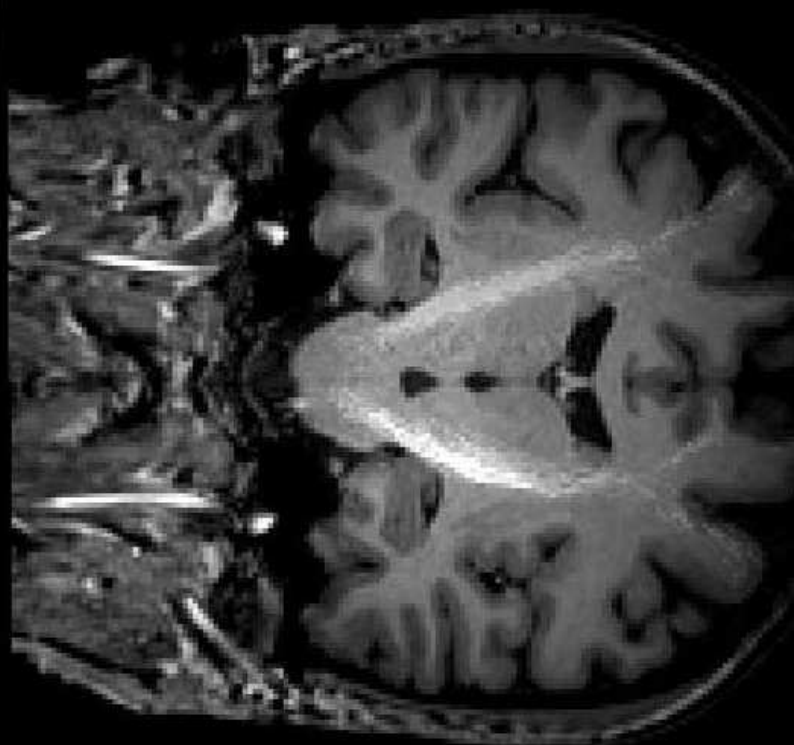
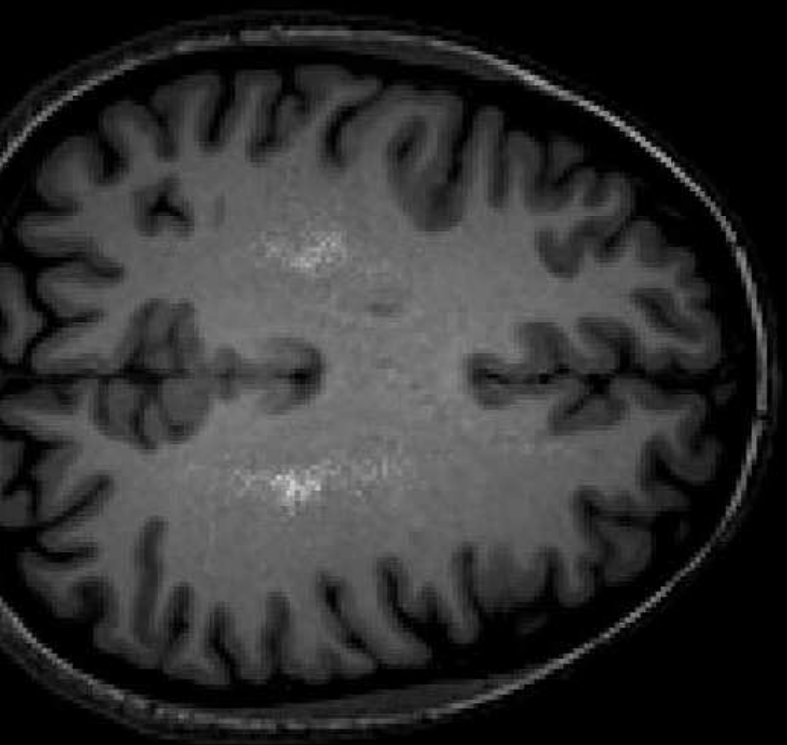
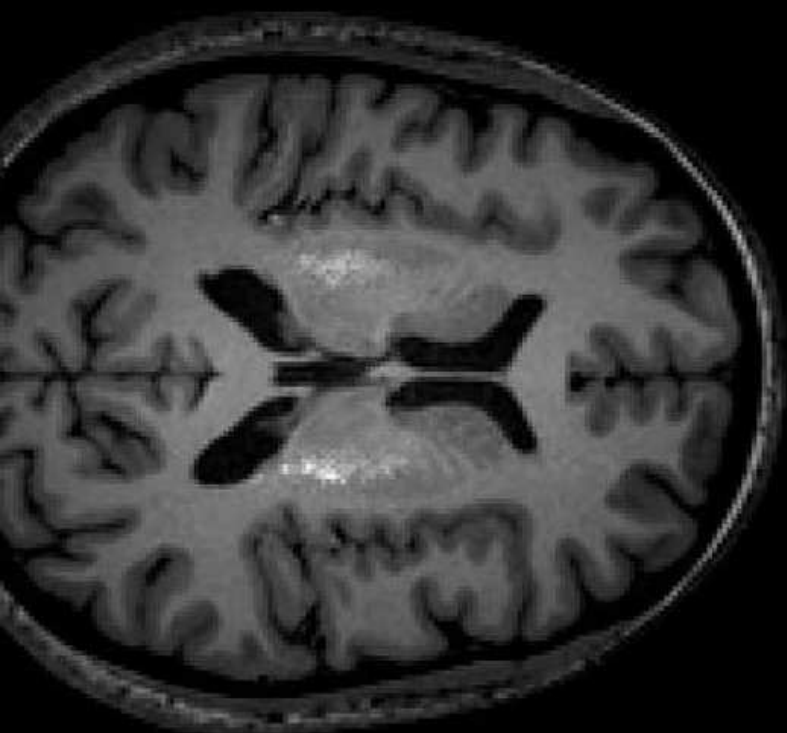
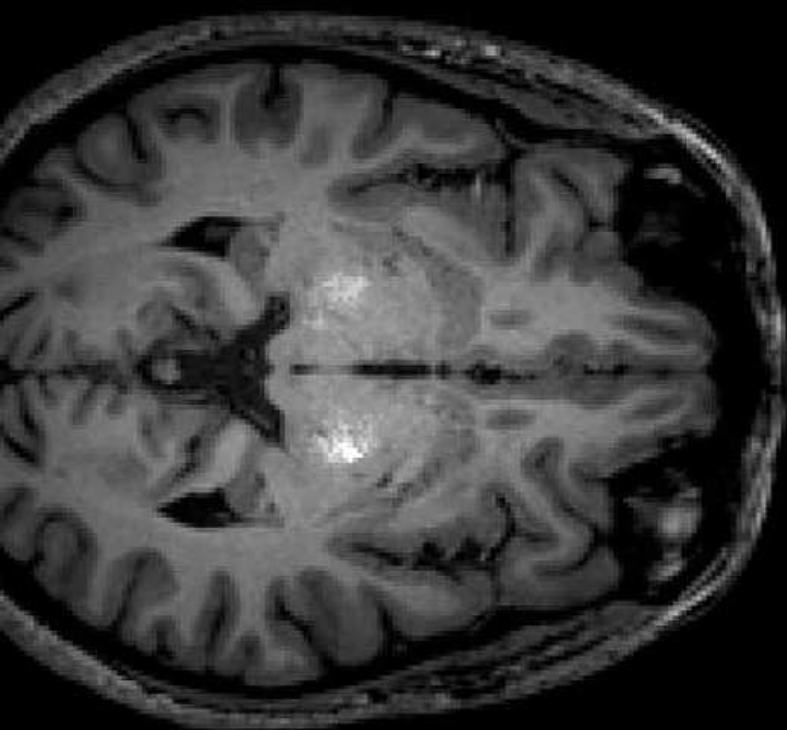
605 Brain asymmetry from laterality, MD results, mean, median, Standard Deviation (SD) and p value (t test). R vs L (right-side):
606 looking for a significant difference between right-handers (R) and left-handers (L) based on laterality.

607

608







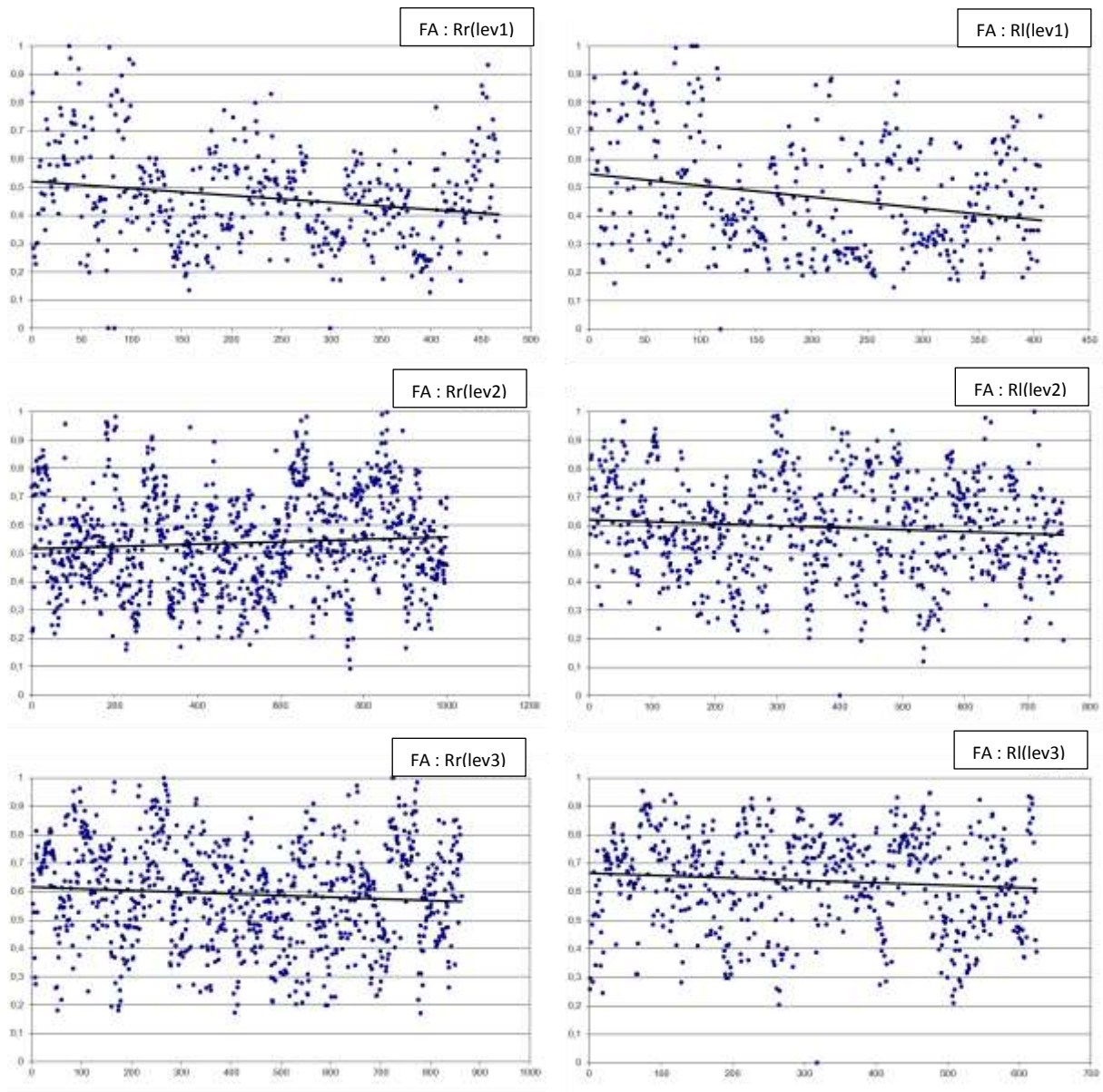


Figure 4a

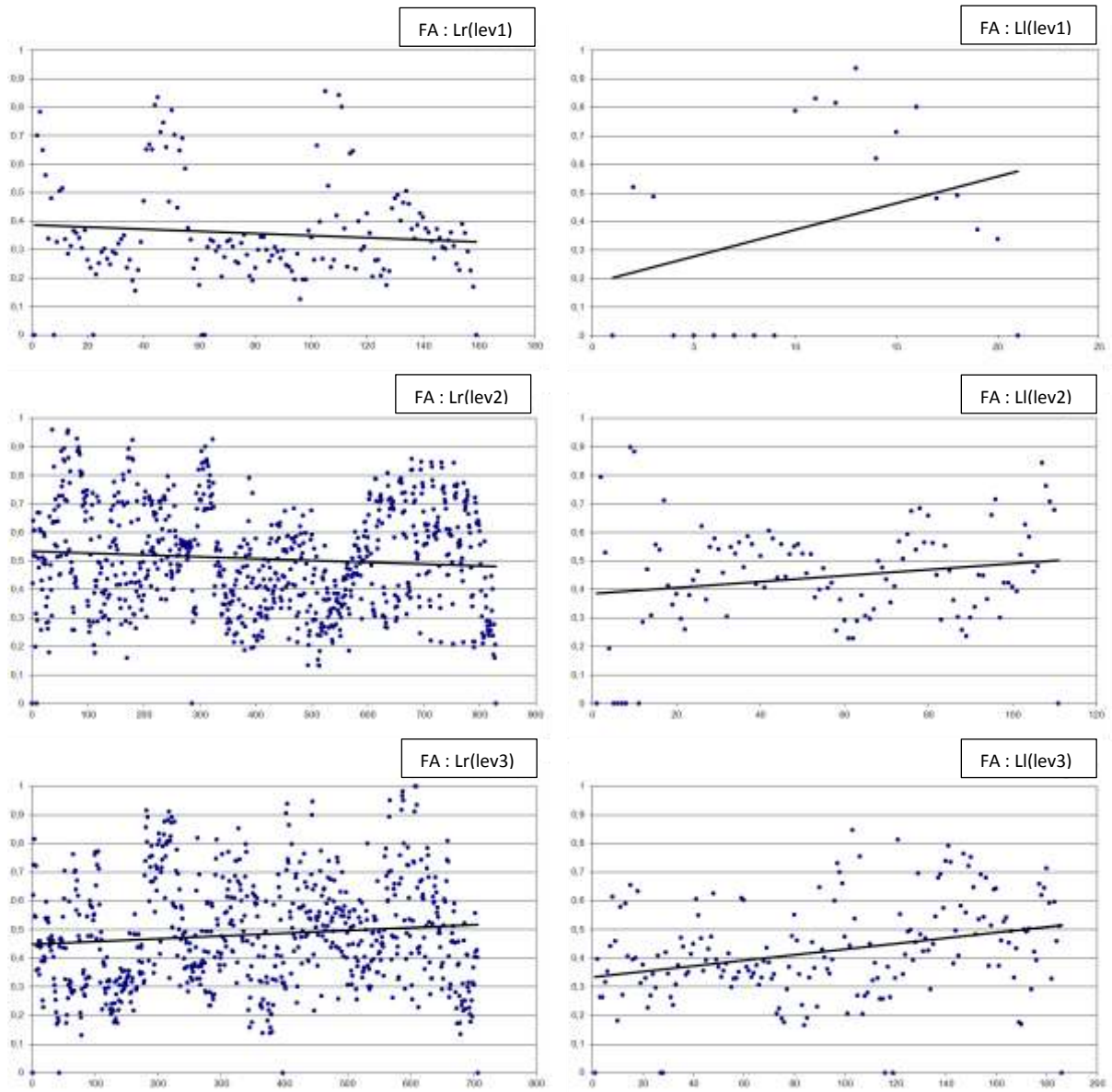


Figure 4b

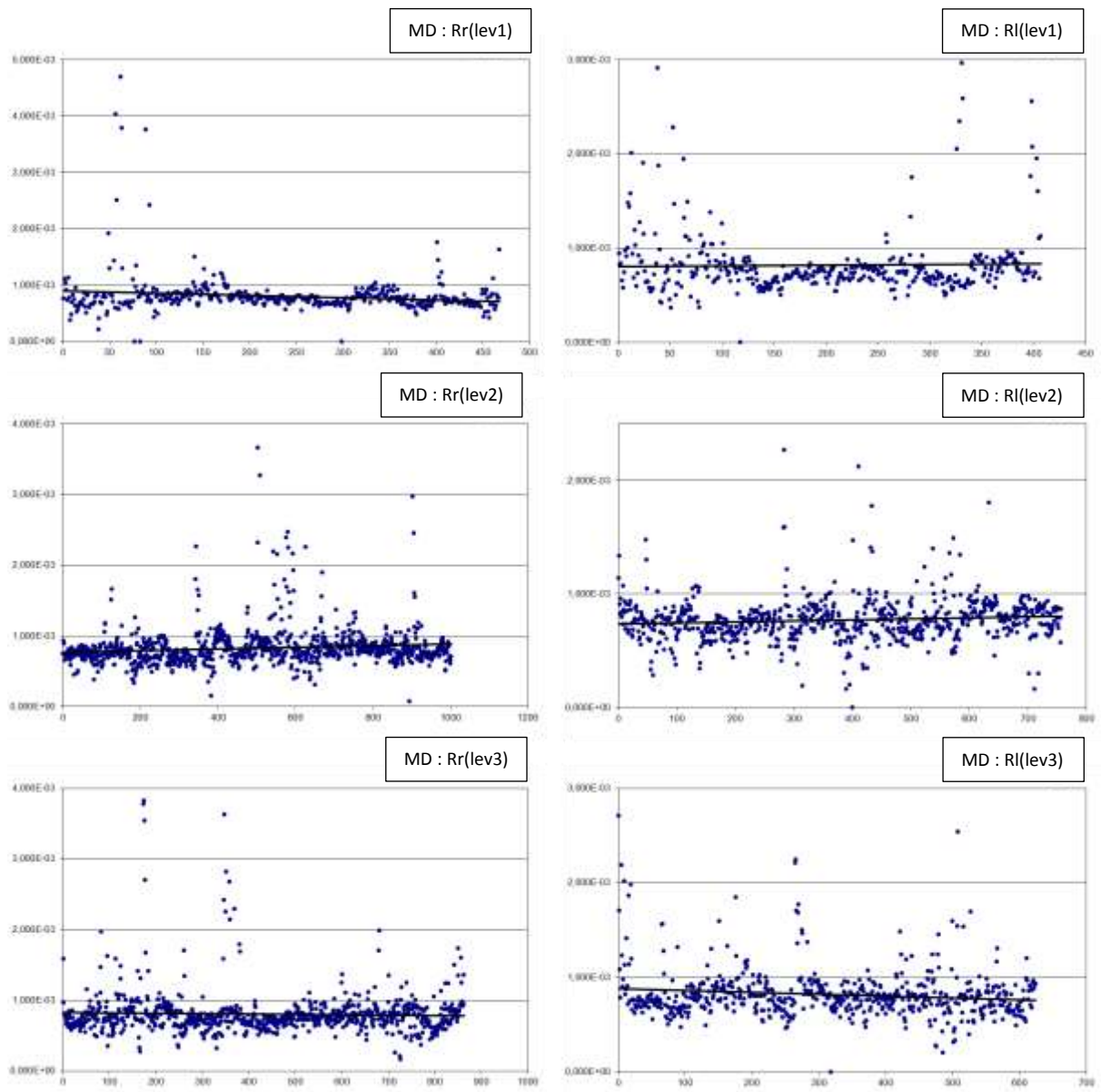


Figure 5a

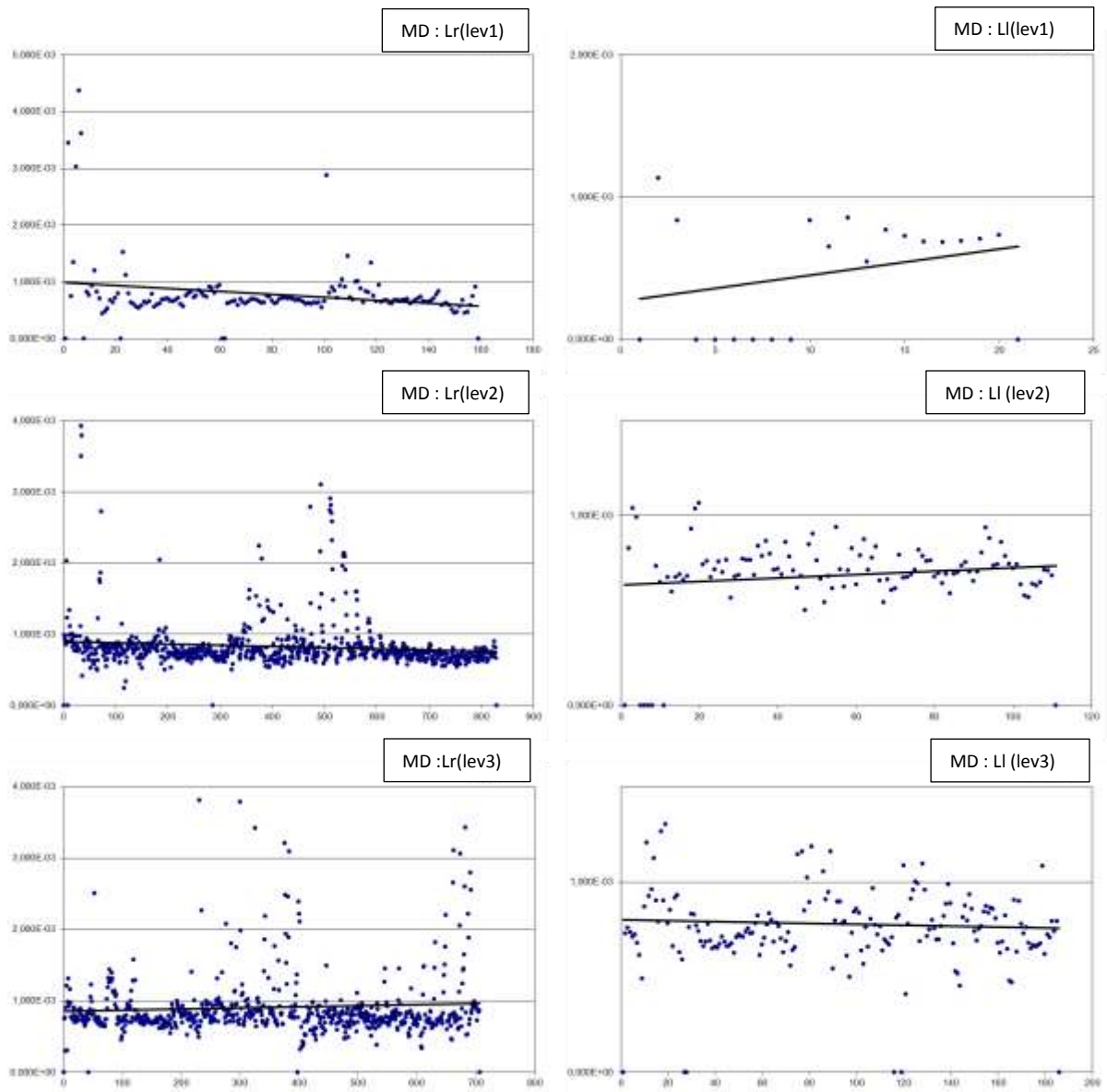


Figure 5b

Table 1

Subjects	score	laterality
1	0	R
2	0	R
3	0	R
4	0	R
5	0	R
6	1	RA
7	0	R
8	0	R
9	0	R
10	0	R
11	0	R
12	0	R
13	0	R
14	0	R
15	0	R
16	20	L
17	11	LA
18	20	L
19	14	LA
20	7	LA
21	13	LA
22	20	L
23	20	L
24	20	L
25	20	L

Table 2

R Subjects	Volume (r)	Volume (l)
1	11418	34339
2	13199	17914
3	18094	570
4	5450	8653
5	64991	14706
6	11764	23780
7	8042	12943
8	37227	4661
9	12367	11734
10	9284	22182
11	25755	19876
12	40297	48815
13	19418	50279
14	10162	700
15	19231	18376
mean	20446.6	19301.9
median	13199	17914
SD	15448.7	14678.1

L Subjects	Volume (r)	Volume (l)
16	5087	2778
17	14015	18080
18	19827	18212
19	13119	2778
20	18610	11077
21	14273	7132
22	35858	17892
23	8748	4189
24	118831	16309
25	9497	19325
mean	25786.5	11777.2
median	14144	13693
SD	32033.5	6615.5

Table 3

R Subjects	right hand	left hand
1	68	259
2	162	404
3	338	73
4	7	163
5	203	447
6	8	234
7	146	89
8	395	0
9	405	42
10	1	59
11	446	88
12	322	475
13	243	748
14	67	60
15	132	86
mean	196.2	215.1
median	162.0	89.0
SD	149.2	206.5

L Subjects	right hand	left hand
16	1	1
17	262	215
18	69	17
19	31	1
20	205	194
21	80	0
22	899	2
23	97	92
24	2804	156
25	20	34
mean	446.8	71.2
median	97.0	34.0
SD	825.0	82.1

Table 4

RK2		FA			
	laterality	Right-Handers		Left-Handers	
	hand	right	left	right	left
Level 1	minimum	0	0	0	0
	maximum	1	1	0.85596	0.93627
	mean	0.46223	0.46759	0.35706	0.39016
	median	0.45054	0.42144	0.31974	0.48064
	p value	0.671		0.6725	
	R vs L (right-side)	<0.0001			
	R vs L (left-side)	0.3237			
Level 2	minimum	0.09239	0	0	0
	maximum	0.99798	1	0.95827	0.89832
	mean	0.53480	0.59328	0.50709	0.44397
	median	0.52552	0.59975	0.50029	0.45063
	p value	<0.0001		0.0007	
	R vs L (right-side)	0.0007			
	R vs L (left-side)	<0.0001			
Level 3	minimum	0.171138	0	0	0
	maximum	1	0.95442	1	0.84667
	mean	0.58785	0.63625	0.48280	0.42517
	median	0.59605	0.66117	0.46439	0.40477
	p value	<0.0001		0.0001	
	R vs L (right-side)	<0.0001			
	R vs L (left-side)	<0.0001			

Table5

RK2		MD			
	laterality	Right-Handers		Left-Handers	
	hand	right	left	right	left
Level 1	minimum	0	0	0	0
	maximum	0.00469	0.00326	0.00437	0.00114
	mean	0.00081	0.00082	0.00078	0.00047
	median	0.00076	0.00074	0.00068	0.00068
	p value	0.6004		0.0111	
	R vs L (right-side)	0.6162			
	R vs L (left-side)	<0.0001			
Level 2	minimum	0.00008	0	0	0
	maximum	0.00366	0.00227	0.00392	0.00107
	mean	0.00083	0.00077	0.00082	0.00069
	median	0.00078	0.00076	0.00075	0.00071
	p value	<0.0001		<0.0001	
	R vs L (right-side)	0.8819			
	R vs L (left-side)	<0.0001			
Level 3	minimum	0.00017	0	0	0
	maximum	0.00383	0.00271	0.00517	0.00212
	mean	0.00082	0.00082	0.00091	0.00078
	median	0.00076	0.00078	0.00078	0.00075
	p value	0.9553		<0.0001	
	R vs L (right-side)	<0.0001			
	R vs L (left-side)	0.0868			