



HAL
open science

Emery-Dreifuss muscular dystrophy, laminopathies, and other nuclear envelopathies.

Gisèle Bonne, Susana Quijano-Roy

► **To cite this version:**

Gisèle Bonne, Susana Quijano-Roy. Emery-Dreifuss muscular dystrophy, laminopathies, and other nuclear envelopathies.. *Handb Clin Neurol*, 2013, 113, pp.1367-76. 10.1016/B978-0-444-59565-2.00007-1 . inserm-00826557

HAL Id: inserm-00826557

<https://inserm.hal.science/inserm-00826557v1>

Submitted on 27 May 2013

HAL is a multi-disciplinary open access archive for the deposit and dissemination of scientific research documents, whether they are published or not. The documents may come from teaching and research institutions in France or abroad, or from public or private research centers.

L'archive ouverte pluridisciplinaire **HAL**, est destinée au dépôt et à la diffusion de documents scientifiques de niveau recherche, publiés ou non, émanant des établissements d'enseignement et de recherche français ou étrangers, des laboratoires publics ou privés.

Emery-Dreifuss Muscular dystrophy. Laminopathies and other nuclear envelopathies

Gisèle Bonne¹ and Susana Quijano-Roy²

Affiliations

¹ Gisèle Bonne, PhD

- Inserm, UMR S974, Paris, F-75013, France;

- Université Pierre et Marie Curie-Paris 6, UM 76; CNRS, UMR7215; Institut de Myologie, IFR14, Paris, F-75013, France;

- AP-HP, Groupe Hospitalier Pitié-Salpêtrière, U.F. Cardiogénétique et Myogénétique Moléculaire, Service de Biochimie Métabolique, Paris, F-75013, France

Tel: +33 1 42 16 57 23 (or 17)

Fax: +33 1 42 16 57 00

E-mail: g.bonne@institut-myologie.org

<http://www.institut-myologie.org/>

² Susana Quijano-Roy MD, PhD

Praticien Hospitalier, Neurologie Pédiatrique.

- AP-HP, Pole de Pédiatrie. Centre de Référence de Maladies neuromusculaires GNMH, Hôpital Universitaire Raymond Poincaré, F-92380 Garches, France.

- CIC-IT - Faculté de Médecine Paris Ile de France Ouest - Université Versailles Saint Quentin en Yvelines UVSQ – France.

- Inserm, UMR S974, Paris, F-75013, France;

- Directeur du laboratoire d'EMG, Service des Explorations fonctionnelles, Hôpital Necker

Enfants Malades, F-75015 Paris, France.

Tel: +33 1 47 10 78 90 (or 79 00)

Fax: +33 1 47 10 76 43

E-mail: susana.quijano-roy@rpc.aphp.fr

ABSTRACT

Nuclear envelopathies or laminopathies are a group of hereditary diseases caused by mutations of genes that encode proteins of the nuclear envelope such as lamins and emerin. Concerning skeletal muscle, there is a spectrum of phenotypes of onset from birth to adult age. L-CMD is a severe congenital muscular dystrophy characterized either by the absence of motor acquisitions or by a striking loss of head support (dropped-head syndrome), associated with respiratory failure. The Emery-Dreifuss muscular dystrophy (EDMD) has a later onset and typically shows the triad of slowly progressive scapulo-peroneal muscular weakness, elbow joint contractures and cardiac disease. EDMD is genetically heterogeneous (*LMNA*, *EMD*, *FHL1*) and inheritance may be variable (X-linked, autosomal dominant or recessive). Other than skeletal muscle disorders, *LMNA* has also been involved in a cardiomyopathy with cardiac conduction disease, in an axonal neuropathy and, more surprisingly, in lipodystrophy and a wide spectrum of premature aging syndromes (progeria, mandibula acral dysplasia, restrictive dermopathy). It is still not clear how a single gene is responsible for such heterogeneous spectrum of conditions, but mutations in other genes implicated in the processing or maturation of nuclear lamins have been also found and the existence of modifying factors or genes is highly suspected.

INTRODUCTION

The nuclear envelopathies are a rapidly expanding group of human hereditary diseases caused by mutations of genes that encode proteins of the nuclear envelope. The most frequent and best known form is the Emery-Dreifuss muscular dystrophy (EDMD), a skeletal myopathy that typically presents between mid-childhood and the second decade of life with slowly progressive muscular weakness, joint contractures and cardiac disease. This nosological entity is genetically heterogeneous and inheritance may be variable. An X-linked form was first studied by Emery & Dreifuss more than 40 years ago (1966), and the eponymous association (EDMD) for this condition was proposed late in the seventies by Rowland *et al.* but it was not until 1994 that the gene *STA*, now called *EMD*, encoding emerin was identified as the cause of the disease (Bione *et al.*, 1994). In 1999, another gene linked to the nuclear envelope encoding lamins A and C, *LMNA*, was found to be mutated in a series of patients with the same clinical features described for the X-linked form but males and females were equally affected, showing a dominant transmission (Bonne *et al.*, 1999). Later on, mutations of *LMNA* were also reported in a family with an EDMD phenotype, this time inherited as a recessive autosomal trait (di Barletta *et al.*, 2000). Since then, the spectrum of conditions has been extraordinarily enlarged, from a congenital muscular dystrophy with severe paralytic or rapidly progressive picture (Quijano-Roy *et al.*, 2008) to a limb girdle muscular dystrophy with adult onset and much milder weakness (Muchir *et al.*, 2000). *LMNA* has also been involved in a form of isolated cardiomyopathy associated with cardiac conduction disease (Fatkin *et al.*, 1999) and in an axonal form of hereditary neuropathy (De Sandre-Giovannoli *et al.*, 2002). More surprising has been the identification of this gene in a number of non-neuromuscular disorders including lipodystrophy syndromes and a wide spectrum of premature aging syndromes ranging from mandibula acral dysplasia to restrictive dermopathy (for review see Worman and Bonne, 2007). Mutations in other genes implicated in the processing

or maturation of nuclear lamins have been also found in some of these diseases. The fact that the largest spectrum of phenotypes observed in nuclear envelopathies is mostly linked to lamin A/C gene defects, has lead to the emergence of the more extended term of *laminopathies* (Worman and Bonne, 2007). Intense research in the field is taking place and is currently generating huge amounts of data and revealing the extraordinary complexity of the molecular and physiopathologic mechanisms in these diseases. However, it is still not clear how a single gene is responsible for such heterogeneous spectrum of conditions. The occurrence of modifying factors or genes is highly suspected and has been occasionally proven. This and other investigations are helping in the better understanding of nuclear envelopathies, opening the possibility for the identification of new genes and the investigation of new therapeutic approaches. Work is in progress and allows expecting new and promising developments of these fascinating and complex conditions in the next coming years.

THE NUCLEAR ENVELOPE

The **nuclear lamina** is a network of lamin polymers, a fibrous layer that is embedded in the nucleoplasmic side of the inner nuclear membrane and provides an interface between the nuclear envelope and the genetic material inside the nucleus. The lamina consists of intermediate filaments called lamins and comprises A-type (lamins A and C) and B-type (lamins B1 and B2) lamins, and in human both A- and B-type lamins are known to cause diseases (Worman and Bonne, 2007). Lamins interact with chromatin as well as with other proteins of the inner nuclear membrane (lamina-associated proteins [LAPs] and emerin) through various binding sites (Figure 1).

Emerin, encoded by the *EMD* gene, is a transmembrane protein of the inner nuclear membrane that interacts with A-type lamins. *EMD* gene located on chromosome Xq28, is 2327 bp in length and consists of six exons. Emerin is ubiquitously expressed (Bione et al., 1994), not only at the

nuclear envelope but also expressed in other cell compartments in some tissues. The main disease in humans known to be caused by defects in emerin is the X-linked form of Emery-Dreifuss muscular dystrophy (XL-EDMD); although a few rare cases of limb-girdle muscular dystrophy and isolated cardiac diseases have been also published. So far, 131 different mutations in the *EMD* gene have been reported in 314 individuals and both genetic and clinical details are available in mutation database UMD-*EMD* that is maintained at the website address www.umd.be/EMD/.

Lamins A and C are A-type lamins both derived by alternative splicing from a same gene, *LMNA* located on chromosome 1q21. *LMNA* encompass 25 kb and contains 12 exons. A-Type lamins are not only present at the nuclear envelope but also in the nucleoplasm. They are expressed only in differentiated cells and appear in the course of development. In contrast to emerin, mutations in the *LMNA* gene have been reported to be associated with a number of different phenotypes (see Table 1) (for review see Worman and Bonne, 2007). A mutation database of *LMNA* mutations is available and constantly updated (www.umd.be/LMNA/), with more than 360 different mutations reported in 1732 individuals so far. The clinical diversity from a single causative gene is quite striking and the association between individual *LMNA* mutations and different phenotypes is not fully understood. Genotype-phenotype correlations are not always evident and marked inter- and intrafamilial clinical diversity has been reported (Bécane et al., 2000; Bonne et al., 2000). To explain the variety of severity associated with laminopathies, the coexistence of another co-inherited modifying gene or the effect of single nucleotide polymorphism should be considered. In this line we recently identified a modifier locus that may modulate the age at onset of myopathic symptoms (Granger et al., 2011). Digenism has also been identified in families with AD-EDMD and simultaneous mutations in *LMNA* and other genes [*EMD* (Ben Yaou et al., 2007) and *Desmin* (Muntoni et al., 2006)].

PATHOPHYSIOLOGY

It seems difficult to explain how defects in nuclear membrane proteins may cause so different diseases as muscle dystrophy, cardiac or nerve diseases, as well as lipodystrophy and premature aging syndromes. For emerin (and presumably lamins A/C), to function properly the protein must be correctly localized to the nuclear membrane. Any defect of the nuclear membrane could interfere with satellite cell function and thereby skeletal muscle regeneration because emerin appears to be important in the organization of the nuclear membrane during cell division (Holaska, 2008). As for other disorders with pathophysiology implicating the nucleus, cell death and apoptosis may play an important role in pathogenesis. Concerning laminopathies, to explain the extremely heterogeneous phenotypic consequences, several mechanisms are proposed, including mechanical stress, altered gene expression and accumulation of toxic prelamin A (Worman et al., 2009). Enhanced nuclear fragility may affect in particular mechanically stressed tissues such as cardiac or skeletal muscle. On the other hand, since lamin A/C and lamin-associated polypeptides physically interact with histones, chromatin, and transcription factors, altered gene expression may contribute to the pathogenesis of laminopathies. There is increasing evidence that the nuclear lamins A/C are crucially involved in the spatial organization of chromatin, gene regulation and signal transduction at the cellular level. The premature aging syndromes constitute a phenotypic continuum sharing a common physiopathologic mechanism in rapport with accumulation of a precursor (prelamin A) that stays abnormally farnesylated. This may be the consequence of mutations in *LMNA* or in genes leading to defective posttranslational processing of prelamin A (for a review see Navarro et al., 2006).

CLINICAL SPECTRUM

Striated muscle disorders

Globally, laminopathies affecting the striated muscles seem to constitute a continuous spectrum of successive phenotypes (Figure 2). There is a strong correlation between age of onset and the resulting phenotype in single patients. Overall, it appears that early prenatal onset may be associated with lethal foetal akinesia, late prenatal onset with severe L-CMD, onset before 1 year with dropped-head L-CMD, onset in childhood or young adulthood with classic EDMD, later onset with LGMD1B, and finally the end of the spectrum where no skeletal muscle involvement is noted (Quijano-Roy et al., 2008). The cardiac involvement seems to be a common feature in the course of the disease, independently of the form..

Lamin-related Congenital muscular dystrophy (L-CMD)

This recently described form of CMD is at the severe end of the spectrum of the striated muscle laminopathies (Quijano-Roy et al., 2008). Some patients were initially reported as severe EDMD patients, as they present with the typical humero-peroneal distribution of weakness and muscle wasting. However, the early onset, the progressive course, the extreme severity of presentation with some patients not achieving even head or trunk control and the absence of some hallmarks of the EDMD triad at early stages (elbow contractures, cardiac symptoms) are atypical features not easily recognisable as EDMD. Myopathic or dystrophic changes are seen in the muscle biopsies. Merosin and other routine immunostaining markers of congenital muscular dystrophies are usually normal. The serum CK levels are often increased but rarely more than 4 or 5 folds the normal values. Overall, the phenotype observed is so distinct that, in the absence of tissular, immunohistochemical or biochemical specific markers, diagnosis is based in the clinical findings. Two groups of severity are distinguished: a subgroup of patients with early severe onset that have very poor spontaneous movements and motor development (Fig. 2a), and another subset with initially milder disease, who are able to sit or walk and present with progressive neck weakness (dropped head syndrome) after acquiring head control (Fig. 2b). Despite this variability in clinical

presentation there is a strikingly similar pattern of muscle involvement. All children have a progressive course with an initial rapid decline in cervical/axial strength followed by a period of slower progression or stasis. Progressive restrictive respiratory insufficiency is a major complication and may require continuous mechanical ventilation, particularly in the most early and severe form. In our reported series of 15 patients (Quijano-Roy et al., 2008), respiratory failure was universal within the 2 first years of life in the severe group and arose before the age of 8 years in many children in the dropped-head group. Thus, these patients need close monitoring of respiratory function and gas exchange, especially after the onset of progressive motor decline. Cardiac involvement was rarely observed and was often subclinical in this series with most children under the age of 10, but one patient with dropped head syndrome died unexpectedly at age 3 years and another child with a more severe onset who never acquired trunk support presented rhythm disturbances at 7 years of age. Routinary cardiac tests to survey cardiac function and rhythm abnormalities regularly are therefore highly recommended from diagnosis

Emery-Dreyfuss Muscular Dystrophy (EDMD)

The overall prevalence of EDMD is not known, but the X-linked form is estimated to be 1:100,000. Hopkins and Warren (1992) estimated EDMD to be the third most prevalent muscular dystrophy, after the two dystrophinopathies (Duchenne muscular dystrophy and Becker muscular dystrophy). Most patients present autosomal-dominant EDMD due to a heterozygote mutation in the *LMNA* gene and a lesser proportion have the X-linked form, while the autosomal recessive transmission has only been reported in a family with a severe phenotype (di Barletta et al., 2000). Germinal mosaicism in the *LMNA* gene is possible and has to be distinguished from a recessive trait in families with several siblings affected (Bonne et al., 1999). However, in more than 60% of EDMD cases, no mutations are detected in *EMD* or *LMNA* genes. Recently, in a search for new causative gene for EDMD, via genome wide scan, mutations in *FHL1* gene were identified in a

number of unrelated patients with XL-EDMD (Gueneau et al., 2009). In this study, 28% of EDMD patients carried a mutation in *LMNA*, 8% in *EDM* and less than 2% in *FHL1*. Although FHL1 proteins are not nuclear envelope proteins, FHL1, A-type lamins and emerin share some functional features that will need to be further explored in the future.

Clinically, the typical EDMD phenotype is characterized by early joint contractures affecting selectively the Achilles tendons, the elbows and the neck extensor muscles. A rigid spine syndrome is the consequence of the progressive development of spinal cervico-dorsal and lumbar contractures (Fig. 2c, d). Muscle atrophy and weakness show also a very distinct pattern, with a humero peroneal distribution. Initially, muscle involvement in proximal muscles of upper extremities is predominantly proximal, while the weakness and wasting is mostly distal in the lower limbs. Although weakness later extends to the scapular and pelvic limb girdle musculature, course is slowly progressive or static and patients usually do not develop profound motor or respiratory dysfunction. However, EDMD is a potentially very severe condition due to the cardiac involvement that usually arises after the second decade of life and may lead to sudden death from heart block or due to progressive cardiac failure. Sudden cardiac death may be the first manifestation of the disorder (Bécane et al., 2000). The most frequent heart abnormalities are the conduction defects, ranging from sinus bradycardia, prolongation of the PR interval on electrocardiography to complete heart block. Atrial paralysis is almost pathognomonic of EDMD. Atrial arrhythmias (extrasystoles, atrial fibrillation, flutter) and ventricular arrhythmias (extrasystoles, ventricular tachycardia) are frequent (van Berlo et al., 2005). Besides arrhythmia, a dilated cardiomyopathy may also occur in the course of the disease. Cardiac symptoms include palpitations, presyncope and syncope, poor exercise tolerance and congestive heart failure. Sudden death may happen despite pacemaker implantation.

AD-EDMD and XL-EDMD have similar, but not identical, neuromuscular and cardiac involvements (Bécane et al., 2000; Bonne et al., 2000; di Barletta et al., 2000). In XL-EDMD, joint contractures are usually the first sign, whereas in AD-EDMD, joint contractures appear after the onset of muscle weakness. The progression of muscle wasting is usually slow in the first three decades of life, after which it becomes more rapid. Loss of ambulation can occur in AD-EDMD, but is rare in XL-EDMD (Bonne et al., 2000). In AD-EDMD, the risk of ventricular tachyarrhythmia and dilated cardiomyopathy manifested by left ventricular dilation and dysfunction is higher than in XL-EDMD (Bécane et al., 2000). Individuals are at risk for cerebral emboli and sudden death. A generalized dilated cardiomyopathy often occurs in the later stages of the disease.

AR-EDMD are extremely rare. So far only one family and an isolated patient have been reported with a homozygous mutation in *LMNA* (di Barletta et al., 2000) (Jimenez-Escrig et al. 2011). The isolated patient experienced difficulties when started walking at age 14 months, had severe joint contractures and loss walking at 5 years and by age 40 years he had severe and diffuse muscle wasting but cardiac evaluation revealed no abnormalities. In the recently reported family which was diagnosed using new techniques of exome sequencing (Jimenez-Escrig et al. 2011), the four affected siblings presented later in life, with a limb-girdle progressive muscular dystrophy of onset in the first to third decades of life. In addition, their father and his sister presented with syncopes due to severe rhythm disturbances after the age of 70 requiring both a pacemaker. Severity of weakness was variable among the siblings, but was progressive and they also developed neck, elbow and Achilles contractures in the course of the disease. Subclinical cardiac rhythm disturbances were detected in all in the fourth decade, after the homozygous *LMNA* mutation was identified.. Compared to AD-EDMD, phenotype was similar, although the onset of

cardiac involvement seems to occur later. Further identification of recessive families will address this issue better.

Genetics: In the case of XL-EDMD, a complete deletion of the gene can result from an inversion within the Xq28 region and, in fact, almost a quarter of cases carry this inversion although not all with the deletion of the *EMD* gene. Almost all mutations are null mutations (stop, splice site mutation or out-of frame deletion/insertion) and result in a complete absence of the emerin on both Western blotting and immunohistochemistry. Rare cases with a reduced amount of the protein (due to a rare missense mutation) may have a milder phenotype (Manilal et al., 1998; Bonne et al., 2003). Concerning *LMNA* mutations leading to EDMD, more than 80% are missense mutations leading most probably to the production of mutant proteins. The remaining *LMNA* mutations are nonsense or out-of-frame mutations and less frequently splice site mutations (see www.umd.be/LMNA/). These *LMNA* mutations lead to truncated proteins that are most certainly degraded (Bécane et al., 2000). Concerning *FHL1*, mutations in this gene mainly lead to truncated proteins and thus to absence or highly reduced FHL1 proteins (Gueneau et al., 2009). However, there is still a great proportion of EDMD patients for whom the genetic defect remains unknown.

Diagnosis: For the X-linked form, as emerin is ubiquitously expressed and most *EMD* mutations lead to the absence of emerin, it is possible to analyze the expression of **emerin** by immunofluorescence (IF) and/or by western blot (WB) not only in muscle (IF, WB) but also in various tissues easy to sample such as exfoliative buccal cells (IF), lymphocytes or lymphoblastoid cell lines (WB), and skin fibroblasts (IF, WB). In female carriers of XL-EDMD, emerin is absent in varying proportions in nuclei due to variable level of X chromosome inactivation, and WB may not be completely reliable in carrier detection as it may show either a

normal or reduced amount of emerin. As for FHL1, so far reduced or absence of FHL1 have been essentially tested in muscle tissues by WB and/or IF (Gueneau et al., 2009). In individuals with AD-EDMD, emerin and FHL1 are normally expressed.

Concerning laminopathies, diagnosis is mainly based in clinical features because other complementary tests, i.e. histology, IF, WB, are usually not specific. Serum **CK levels** are moderately increased, especially at the beginning of the disease (Bonne et al., 2000).

Electromyogram (EMG) shows often myopathic features with normal nerve conduction studies, but neuropathic signs have been described in patients with *LMNA* and *EMD* mutations. **Muscle histopathology** shows nonspecific myopathic or dystrophic changes, including variation in fibre size, increased number of internal nuclei, increase in endomysial connective tissue, and necrotic fibres. Inflammatory features have been observed especially in severe or progressive patients (Quijano-Roy et al., 2008). Electronic microscopy may reveal specific alterations in the nuclear architecture (Fidzianska and Hausmanowa-Petrusewicz, 2003). Muscle biopsy is now rarely performed for diagnostic purposes because of the lack of specificity of the dystrophic changes observed and the absence of immunostaining abnormalities on immunodetection for lamins A/C in AD-EDMD. **Muscle MRI of the lower limbs** in dominant *LMNA* mutations shows involvement of glutei, vasti, adductor longus and magnus, semimembranosus and the long head of the biceps femoralis muscles. In particular, a very severe and selective abnormal signal in vastus lateralis is often observed (Mercuri et al., 2002). In L-CMD, severe diffuse involvement sparing head and often forearm and psoas muscles are prominent features (Quijano-Roy et al., 2008). These findings may be useful to distinguish from other myopathies with overlapping clinical symptoms but different patterns of involvement, especially of the COLVI related myopathies [Ullrich congenital muscular dystrophy (UCMD) and Bethlem myopathy (BM)].

Limb-girdle muscular dystrophy type 1B (LGMD1B)

It is an autosomal dominant form of limb-girdle muscular dystrophy associated with atrioventricular conduction defect and *LMNA* mutation (Muchir et al., 2000) (Fig. 2e-h)

Dilated Cardiomyopathy with conduction defects (CMD1A or DCM-CD)

An autosomal dominant form of dilated cardiomyopathy with cardiac conduction defects has been described in which no skeletal muscle involvement are present (Fatkin et al., 1999; Bécane et al., 2000).

Differential diagnosis in muscle striated laminopathies

Making a diagnosis in those patients with advanced disease is usually easy because of the distinct and recognizable clinical picture, although there is clinical overlap with other muscular dystrophies and myopathies. In fact, in early stages patients may not show specific features, and complementary investigations (histology, immunohistochemistry, CK levels, muscle imaging) may be needed before molecular studies are intended. Patients with marked elbow contractures may be difficult sometimes to distinguish from the COLVI-related disorders, Ullrich congenital muscular dystrophy (UCMD) and Bethlem myopathy (BM). In this setting, dosage of CK levels and muscle MRI help to orientate the diagnosis. A severe and progressive course in a child with increased CK levels and no cognitive impairment may resemble a congenital muscular dystrophy due to mutations in *FKRP*, but L-CMD patients lack the muscle pseudohypertrophy and facial weakness typically observed in *FKRP*-related CMD (MDC1C), and increment in CK is usually less marked. The development of multiple contractures may be seen in merosin-deficient and UCMD patients, but different localization of the muscle and joint involvement and specific immunohistochemical and phenotypic markers (striking brain white matter changes and distal hyperlaxity respectively) are useful in distinguishing these disorders.

Genotype-Phenotype Correlations

- **EMD.** The majority of *EMD* mutations are null mutations that result in complete absence of emerin expression in nuclei; however, intra- and interfamilial variability in the severity of the phenotype associated with null mutations may be observed. The few missense mutations that have been identified are associated with decreased or normal amounts of emerin and result in a milder phenotype (www.umd.be/EMD/).

- **LMNA.** In L-CMD, so far, *LMNA* mutations reported arise all *de novo*, whereas, in EDMD, *de novo* mutations were found in up to 76% of the cases and LGMD1B cases are mostly familial (Bonne et al., 2000; Bonne et al., 2003). Certain mutations are only identified in L-CMD patients, which suggest a particular severe pathogenicity for these changes (Quijano-Roy et al., 2008). In contrast, in EDMD and LGMD patients there is not a clear genotype-phenotype correlation (Bonne et al., 2003) and, in fact, marked intra- and interfamilial variability is observed for the same *LMNA* mutation, not only in severity, but also in the pattern of muscular or cardiac involvement (Bécane et al. 2000; Bonne et al. 2000; Brodsky et al. 2000). Thus, in a given family the same mutation can cause AD-EDMD, LGMD1B or isolated DCM-CD (Bécane et al., 2000; Brodsky et al., 2000). Interestingly, severe and variable pictures have been reported in different individuals of a large family with cosegregation of mutations in both *EMD* and *LMNA* (i.e. CMT2, CMT2- EDMD, and isolated cardiomyopathy) (Ben Yaou et al., 2007). Furthermore, extreme phenotypic diversity and low penetrance has been observed in patients with certain missense mutations in the *LMNA* gene. For example, R644C has been found in patients with mild to severe myopathy, arthrogryposis with myocardiopathy, motor neuropathy, limb girdle muscle weakness, dilated cardiomyopathy atypical progeria, left ventricular hypertrophy, lipodystrophy, insulin resistance and focal segmental glomerulosclerosis (Rankin et al., 2008).

Management and treatment

Evaluations recommended following initial diagnosis in patients with myopathy are mainly orthopaedic (spinal X-rays, assessment of spinal and joint contractures), neurological (motor function and muscle testing), respiratory (spirometry, blood gases, sleep studies) and cardiac (ultrasound, 24h Holter-ECG). These last aspects are particularly important, since respiratory and cardiac complications may be subclinical and life-threatening from very early in life and should be studied at least annually. Concerning pulmonary follow-up, night studies are recommended when vital capacity on supine position is under 60% of theoretic values due to the risk of nocturnal hypoventilation.. Other examinations are dependant of the severity of muscle disease and secondary complications. Although no swallowing and facial involvement is relevant even in severe congenital cases, some patients may require gastrostomy due to difficulties in feeding, frequent hypoglycaemias, failure to thrive and hypotrophy that are multifactorial and often more related to respiratory or cardiac insufficiency than to digestive problems. Metabolic complications such as insulin resistance and diabetes are likely to happen more frequently in *LMNA* mutated patients than in the general population.

At present, no etiological treatment is available and therefore, therapy is basically preventive and/or symptomatic. In patients with myopathy, orthopaedic treatment to minimize progression of joint contractures and spinal deformity are often required. Orthosis may be useful, for example night cast to fight against Achilles tendon tightness and trunk or neck bracing for severe trunk or neck hypotonia or scoliosis. They may prevent joint surgery for tenotomy or delay spinal fusion until spinal growth is finished (scoliosis). Mechanical aids will be necessary in cases with severe phenotype or progressive course (canes, walkers, orthosis, wheelchairs). Cardiac treatments including antiarrhythmic drugs, cardiac pacemaker and implantable cardioverter defibrillator (ICD) are used in patients with arrhythmias, AV conduction disorders and congestive heart failure. Heart transplantation may be necessary in case of heart failure (Bécane et al., 2000;

Bonne et al., 2000). Progressive restrictive respiratory insufficiency requiring nocturnal or continuous mechanical ventilation is a constant complication in children with the congenital form (L-CMD) and often in those patients with EDMD and onset is early in the first decade of the life.

Prevention: Regular physical therapy and trunk and limb orthosis are important in patients with myopathy symptoms or joint contractures. In certain cases with subclinical arrhythmias, cardiac defibrillators have been shown to reduce mortality by detecting life-threatening events that were reverted (Meune et al., 2006). Thromboembolic complications in case of decreased left ventricular function or atrial arrhythmias may be prevented by using antithromboembolic drugs (Boriani et al., 2003).

Testing of relatives at risk is highly recommended in AD-EDMD, LGMD1B and DCM-CD because of the incomplete penetrance of the cardiac disease at young age. Cardiac evaluation is recommended for female carriers of an *EMD* mutation (Bonne et al., 2003).

Disorders of the peripheral nerve

CMT2B1. An autosomal recessive form of axonal Charcot-Marie-Tooth disease has been described, with the founder mutation p.Arg298Cys (De Sandre-Giovannoli et al., 2002) (see Charcot-Marie-Tooth type 2). Other mutations have also been associated with axonal motor neuropathy (p.R644C, Rankin et al., 2008). In addition, autosomal dominant forms associating CMT2 with other phenotypic features have been described as case reports: CMT2 associated with muscular dystrophy, cardiomyopathy and leukonychia or with myopathy (for review see Worman and Bonne, 2007).

Premature aging disorders

The premature aging syndromes constitute a phenotypic continuum ranging from the Mandibulo Acral Dysplasia and the Hutchinson-Gilford progeria syndrome to the Restrictive Dermopathy.

They share a common feature which is the accumulation of prelamin A (normal or truncated) that stays abnormally farnesylated. These entities may be the consequence not only of *LMNA* but also of mutations in the gene *FACE1/ZMPSTE24* which encodes a determinant enzyme responsible for maturation of the prelamin A (Navarro et al., 2006).

Hutchinson-Gilford progeria syndrome (HGPS) is a severe and fatal developmental disorder characterized by severe growth retardation, usually associated to skeletal alterations (osteolyses, osteoporosis), marked amyotrophy, lipodystrophy, skin atrophy with sclerodermatous focal lesions and alopecia. Affected children present with severe atherosclerosis. Cognitive functions are fully preserved. Death occurs at the mean age of 13.5 years, mostly due to myocardial infarction. HGPS is in most cases due to *de novo* dominant mutations at codon 608 of *LMNA* gene, which introduce a cryptic splice site leading to a truncated protein that lacks the major site of posttranslational modification necessary for correct maturation of prelamin A into lamin A. Therefore, this pre-protein is stocked in the nuclear envelope as a incompletely processed farnesylated precursor which exerts toxic functions (Navarro et al., 2006).

Mandibulo Acral Dysplasia (MAD) is an autosomal recessive disorder characterized by growth retardation, postnatal onset of craniofacial anomalies with mandibular hypoplasia, progressive acral osteolysis, and skin changes including mottled pigmentation, skin atrophy, and lipodystrophy affecting the face as well as the extremities. Some patients show progeroid features such as thin nose, sparse, brittle hair and sclerodermatous (stiff and parched) skin and may have a severe progressive glomerulopathy. Owing to its slowly progressive course, the syndrome has been recognized in adults, and paediatric case reports are scarce. They may present metabolic complications due to insulin resistance and diabetes. MAD is most often due to founder mutations in *LMNA* (p.Arg527His) (Novelli et al, AJHG, 2002), but there are also patients

reported with mutations in the *ZMPSTE24* gene, some of them with progeroid features (Navarro et al., 2006).

Restrictive Dermopathy (RD) is a perinatal lethal genodermatosis, mainly characterized by intrauterine growth retardation, tight and rigid skin, prominent superficial vessels, micrognathism, bone mineralization defects and multiple joint contractures. RD represent the most severe end of the spectrum of laminopathies and is due either to a p.G608G *LMNA* mutation (Navarro et al., 2004) or to *ZMPSTE24* mutations leading to loss of function of this enzyme (Navarro et al., 2006).

Other phenotype variants were reported completing the continuum of premature aging syndrome (table 1 and for a review Navarro et al., 2006).

Other Disorders

Autosomal dominant Dunnigan type of familial partial lipodystrophy (FPLD)

Lipodystrophies represent a group of diseases characterized by altered body fat repartition and major metabolic alterations with insulin resistance. Dunnigan syndrome (FPLD) is a genetic form of partial lipodystrophy inherited in an autosomal dominant trait, characterized by subcutaneous lipoatrophy but preserved or increased fat at the level of face and neck. The majority of FPLD cases are caused by mutations in the *LMNA* gene affecting codon Arg482, leading to several amino acid substitutions (Bonne et al., 2003; www.umd.be/LMNA/). Other associated features of FPLD are muscular hypertrophy, hyperandrogenism, acanthosis nigricans, hepatomegaly with steatosis and at the biological level, marked hypertriglyceridaemia, low HDL cholesterol, insulin resistance and altered glucose tolerance or diabetes. These signs occur after puberty and are more marked in females. Partial lipodystrophy has been reported also in patients with mutations in *LMNA* associated with myopathy or with syndromes of premature ageing.

REFERENCES

- Bécane HM, Bonne G, Varnous S, Muet al (2000). High incidence of sudden death with conduction system and myocardial disease due to lamins A and C gene mutation. *Pacing Clin Electrophysiol* 23: 1661-1666.
- Ben Yaou R, Toutain A, Arimura T, Deet al (2007). Multitissular involvement in a family with LMNA and EMD mutations: Role of digenic mechanism? *Neurology* 68: 1883-1894.
- Bione S, Maestrini E, Rivella S, et al (1994). Identification of a novel X-linked gene responsible for Emery-Dreifuss muscular dystrophy. *Nature Genet* 8: 323-327.
- Bonne G, Ben Yaou R, Beroud C, (2003). 108th ENMC International Workshop, 3rd Workshop of the MYO-CLUSTER project: EUROMEN, 7th International Emery-Dreifuss Muscular Dystrophy (EDMD) Workshop, 13–15 September 2002, Naarden, The Netherlands. *Neuromusc Disord* 13: 508-515.
- Bonne G, Di Barletta MR, Varnous S, et al (1999). Mutations in the gene encoding lamin A/C cause autosomal dominant Emery-Dreifuss muscular dystrophy. *Nature Genet* 21: 285-288.
- Bonne G, Mercuri E, Muchir A, et al (2000). Clinical and molecular genetic spectrum of autosomal dominant Emery Dreifuss muscular dystrophy due to mutations of the lamin A/C gene. *Ann Neurol* 48: 170-180.
- Boriani G, Gallina M, Merlini L, et al (2003). Clinical relevance of atrial fibrillation/flutter, stroke, pacemaker implant, and heart failure in Emery-Dreifuss muscular dystrophy: a long-term longitudinal study. *Stroke* 34: 901-908.
- Brodsky GL, Muntoni F, Miocic S, et al (2000). Lamin A/C gene mutation associated with dilated cardiomyopathy with variable skeletal muscle involvement. *Circulation* 101: 473-476.
- De Sandre-Giovannoli A, Chaouch M, Kozlov S, et al (2002). Homozygous defects in *LMNA*, encoding lamin A/C nuclear-envelope proteins, cause autosomal recessive axonal neuropathy in human (Charcot- Marie-Tooth Disorder Type 2) and mouse. *Am J Hum Genet* 70: 726-736.
- di Barletta MR, Ricci E, Galluzzi G, et al (2000). Different mutations in the LMNA gene cause autosomal dominant and autosomal recessive Emery-Dreifuss muscular dystrophy. *Am J Hum Genet* 66: 1407-1412.
- Emery AEH and Dreifuss FE (1966). Unusual type of benign X-linked muscular dystrophy. *J Neurol Neurosurg Psychiat* 29: 338-342.

Fatkin D, MacRae C, Sasaki T, et al (1999). Missense Mutations in the Rod Domain of the Lamin A/C Gene as Causes of Dilated Cardiomyopathy and Conduction-System Disease. *N Engl J Med* 341: 1715-1724.

Fidzianska A and Hausmanowa-Petrusewicz I (2003). Architectural abnormalities in muscle nuclei. Ultrastructural differences between X-linked and autosomal dominant forms of EDMD. *J Neurol Sci* 210: 47-51.

Granger B, Gueneau L, Drouin-Garraud V, Pedergnana V, Gagnon F, Ben Yaou R, Tezenas du Montcel S, and Bonne G. (2011). Modifier locus of the skeletal muscle involvement in Emery-Dreifuss muscular dystrophy. *Hum Genet* 129(2): 149-159.

Gueneau L, Bertrand AT, Jais JP, et al (2009). Mutations of the FHL1 gene cause Emery-Dreifuss muscular dystrophy. *Am J Hum Genet* 85: 338-353.

Holaska JM (2008). Emerin and the nuclear lamina in muscle and cardiac disease. *Circ Res* 103: 16-23.

Hopkins LC and Warren S (1992). Emery-Dreifuss muscular dystrophy. in *Handbook of Clinical Neurology: Myopathies* (ed. L.P. Rowland and S. DiMauro), pp. 145-160. Elsevier Science, Amsterdam.

Jimenez-Escrig A, Gobernado I, Garcia-Villanueva M, Sanchez-Herranz A. (2011) Autosomal recessive Emery-Dreifuss muscular dystrophy caused by a novel mutation (R225Q) in the laminA/C gene identified by exome sequencing, in press.

Manilal S, Recan D, Sewry CA, et al (1998). Mutations in Emery-Dreifuss muscular dystrophy and their effects on emerin protein expression. *Hum Mol Genet* 7: 855-864.

Mercuri E, Counsell S, Allsop J, et al (2002). Selective muscle involvement on magnetic resonance imaging in autosomal dominant Emery-Dreifuss muscular dystrophy. *Neuropediatrics* 33: 10-14.

Meune C, Van Berlo JH, Anselme F, et al (2006). Primary prevention of sudden death in patients with lamin A/C gene mutations. *N Engl J Med* 354: 209-210.

Muchir A, Bonne G, van der Kooij AJ, et al (2000). Identification of mutations in the gene encoding lamins A/C in autosomal dominant limb girdle muscular dystrophy with atrioventricular conduction disturbances (LGMD1B). *Hum Mol Genet* 9: 1453-1459.

Muntoni F, Bonne G, Goldfarb LG, et al (2006). Disease severity in dominant Emery Dreifuss is increased by mutations in both emerin and desmin proteins. *Brain* 129: 1260-1268.

- Navarro C, De Sandre-Giovannoli A, Bernard R, et al (2004). Lamin A and ZMPSTE24 (FACE-1) defects cause nuclear disorganisation and identify restrictive dermopathy as a lethal neonatal laminopathy. *Hum Mol Genet* 13: 2493-2503.
- Navarro CL, Cau P and Levy N (2006). Molecular bases of progeroid syndromes. *Hum Mol Genet* 15 Spec No 2: R151-161.
- Novelli G, Muchir A, Sangiuolo F, Helbling-Leclerc A, D'Apice MR, Massart C, Capon, F, Sbraccia P, Federici M, Lauro R et al. (2002). Mandibuloacral dysplasia is caused by a mutation in LMNA-encoding lamins A/C. *Am J Hum Genet* 71(2): 426-431.
- Quijano-Roy S, Mbieleu B, Bonnemann CG, et al (2008). De novo lmna mutations cause a new form of congenital muscular dystrophy. *Ann Neurol* 64: 177-186.
- Rankin J, Auer-Grumbach M, Bagg W, et al (2008). Extreme phenotypic diversity and nonpenetrance in families with the LMNA gene mutation R644C. *Am J Med Genet A* 146A: 1530-1542.
- van Berlo JH, de Voogt WG, van der Kooi AJ, et al (2005). Meta-analysis of clinical characteristics of 299 carriers of LMNA gene mutations: do lamin A/C mutations portend a high risk of sudden death? *J Mol Med* 83: 79-83.
- Worman HJ and Bonne G (2007). "Laminopathies": a wide spectrum of human diseases. *Exp Cell Res* 313: 2121-2133.
- Worman HJ, Fong LG, Muchir A, et al (2009). Laminopathies and the long strange trip from basic cell biology to therapy. *J Clin Invest* 119: 1825-1836.

TABLE 1.- List of lamin A/C gene related diseases.

Phenotype	OMIM #
<i>Diseases of striated muscle</i>	
Autosomal dominant Emery–Dreifuss muscular dystrophy	#181350
Autosomal recessive Emery–Dreifuss muscular dystrophy	#604929
Autosomal dominant cardiomyopathy dilated 1A	#115200
Autosomal dominant limb girdle muscular dystrophy type 1B	#159001
Autosomal dominant heart-hand syndrome, slovenian type	#610140
Autosomal dominant <i>LMNA</i> related Congenital muscular dystrophy	
<i>Peripheral neuropathy</i>	
Autosomal recessive Charcot-Marie-Tooth disorder type 2B1	#605588
<i>Lipodystrophy syndromes</i>	
Autosomal dominant Dunnigan-type familial partial	#151660

lipodystrophy	
Autosomal dominant lipoatrophy with diabetes, hepatic steatosis, hypertrophic cardiomyopathy and leukomelanodermic papules	#608056
<i>Premature aging disorders</i>	
Autosomal recessive mandibuloacral dysplasia	#248370
Autosomal dominant Hutchinson-Gilford progeria syndrome	#176670
Autosomal dominant atypical Werner Syndrome	#277700
Autosomal dominant restrictive dermopathy lethal	#275210
Arthropathy, tendinous calcinosis and progeroid features	#611618

FIGURES and LEGENDS

Figure 1. *Model of the location of nuclear lamins and their interaction with nearby localized proteins.* Lamins bind directly to various integral membrane proteins of the inner nuclear membrane (LBR, LAP2, emerin, MAN1, nesprins-1 and -2), but also to several proteins localised within the nuclear matrix (BAF, Rb, SREBP1, histone proteins) as well as DNA, and thereby mediate association with a scala of interacting structural proteins, linking the cytoplasm to the nuclear interior. Question marks indicate suggested but not yet proven interactions. *Reproduced with autorisation from Broers et al, 2006.*

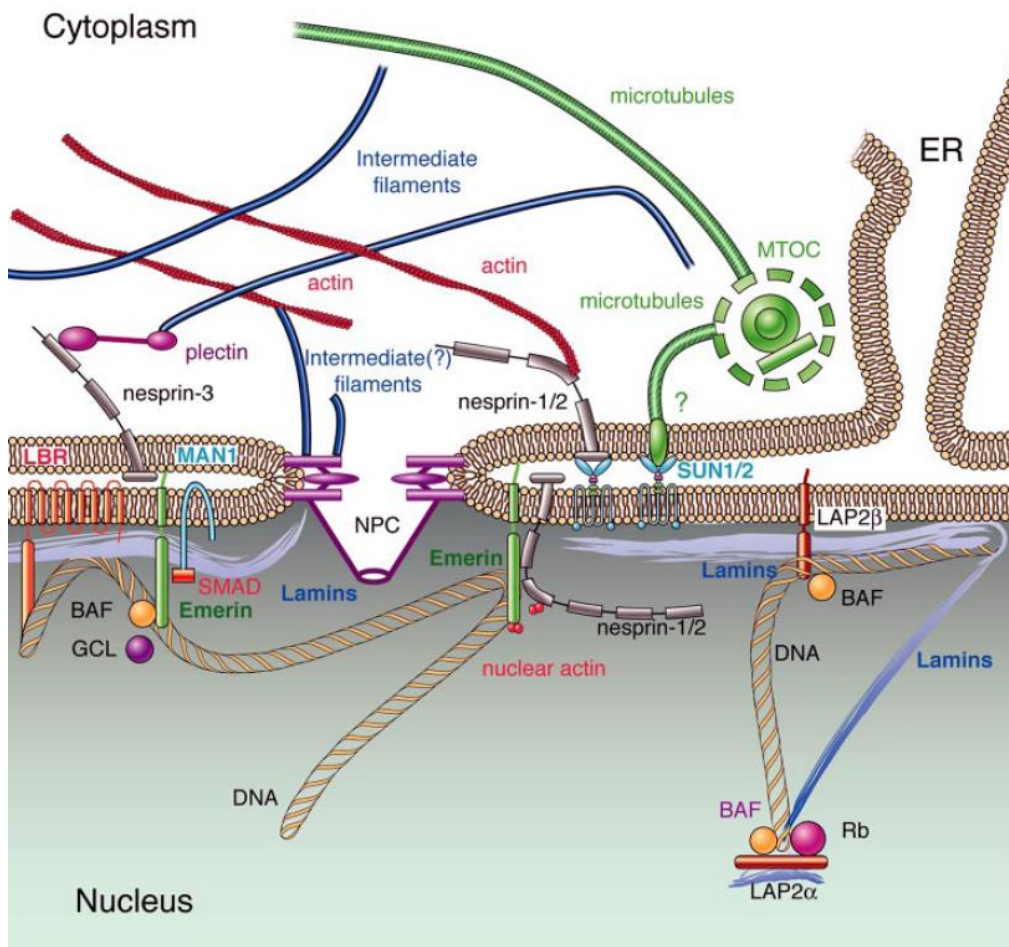


Figure 2. Clinical spectrum of the striated laminopathies: congenital muscular dystrophy (A, B); Emery-Dreifuss muscular dystrophy (C,D); limb-girdle muscular dystrophy (E-H) (A) **Severe L-CMD.**- Two year-old boy with absent motor acquisitions, continuous mechanical ventilation, talipes and knee contractures. (B) **Dropped head syndrome L-CMD.**- Eight year-old boy who lost walking and developed marked cervical weakness but dorsal spinal stiffness and hyperextension. (C and D) **EDMD** boy with joint contractures (elbows, ankles) and diffuse muscle wasting of humeroperoneal predominance. (E-H) **LGMD1B.**- Clinical features (E, F) and muscle MRI findings (G,H) in the pelvic and thigh regions. Prominent involvement of vasti and biceps femoris muscles with moderate affected gluteus maximus, adductor longus and major muscles. Pictures C-H were kindly provided by Prof. Bruno Eymard (Groupe Hospitalier Pitié-Salpêtrière, Paris, France).

