Figure 2

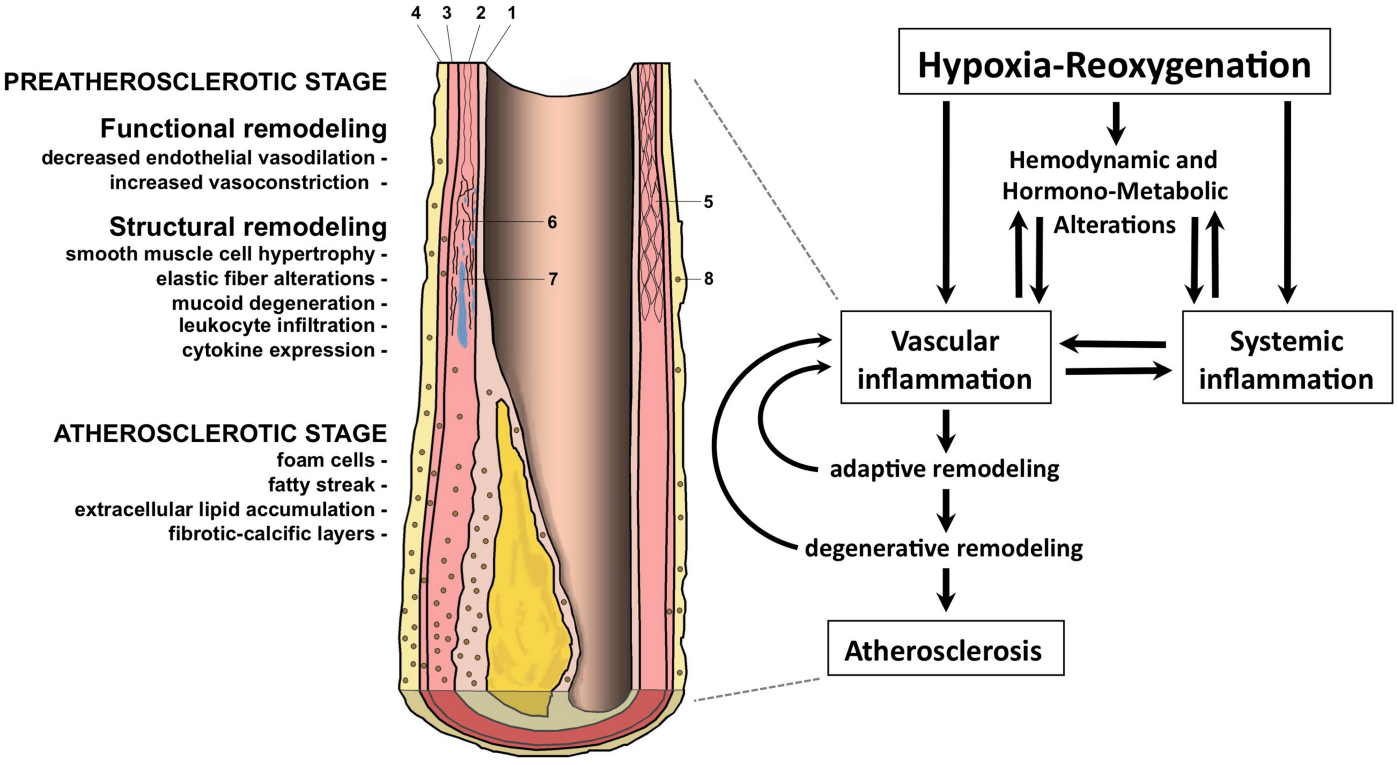
PREATHEROSCLEROTIC STAGE
Functional remodeling
decreased endothelial vasodilation -
increased vasoconstriction -
Structural remodeling
smooth muscle cell hypertrophy -
elastic fiber alterations -
mucoid degeneration -
leukocyte infiltration -
cytokine expression -
ATHEROSCLEROTIC STAGE
foam cells -
fatty streak -
extracellular lipid accumulation -
fibrotic-calcific layers -
4
3
2
1
5
6
7
8
Hypoxia-Reoxygenation
Hemodynamic and
Hormono-Metabolic
Alterations
Vascular
inflammation
Systemic
inflammation
adaptive remodeling
degenerative remodeling
Atherosclerosis