

Fertility and pregnancy outcomes following conservative treatment for placenta accreta

Loïc Sentilhes^{1 2 *}, Clémence Ambroselli³, Gilles Kayem^{4 5}, Magali Provansal^{6 7}, Hervé Fernandez⁸, Franck Perrotin⁹, Norbert Winer¹⁰, Fabrice Pierre¹¹, Alexandra Benachi¹², Michel Dreyfus¹³, Estelle Bauville³, Dominique Mahieu-Caputo¹⁴, Loïc Marpeau², Philippe Descamps¹, Florence Bretelle^{6 7}, François Goffinet⁵

¹ Service de gynécologie-obstétrique [Angers] CHU Angers , Angers,FR

² Service de gynécologie-obstétrique [Rouen] CHU Rouen , Hôpital Charles Nicolle , Rouen,FR

³ Pôle de gynécologie, obstétrique et médecine de la reproduction[Rennes] Hôpital Anne-de-Bretagne , CHU Rennes , 16, boulevard de Bulgarie, BP 90347, 35203 Rennes cedex 2,FR

⁴ Service de gynécologie et obstétrique CHI Créteil , FR

⁵ Service de gynécologie-obstétrique [Cochin] Assistance publique - Hôpitaux de Paris (AP-HP) , Hôpital Cochin , Université Paris V - Paris Descartes , Maternité Port-Royal, Paris,FR

⁶ Service de gynécologie-obstétrique [Conception] AP-HM , Hôpital de la Conception , Université de la Méditerranée - Aix-Marseille II , Marseille,FR

⁷ Service de gynécologie-obstétrique [Nord] AP-HM , Hôpital nord , Université de la Méditerranée - Aix-Marseille II , Marseille,FR

⁸ Service de gynécologie-obstétrique, médecine de la reproduction [Béclère] Assistance publique - Hôpitaux de Paris (AP-HP) , Hôpital Antoine Béchère , Université Paris XI - Paris Sud , 157, rue de la Porte de Trivaux 92141 Clamart,FR

⁹ Service de gynécologie-obstétrique [Tours] CHRU Tours , Tours,FR

¹⁰ Service d'obstétrique-gynécologie [Nantes] CHU Nantes , 38, boulevard Jean-Monnet, 44093 Nantes,FR

¹¹ Service de gynécologie et obstétrique [Poitiers] CHU Poitiers , Université de Poitiers , FR

¹² Service de gynécologie-obstétrique [Necker] Assistance publique - Hôpitaux de Paris (AP-HP) , Hôpital Necker - Enfants Malades , Paris,FR

¹³ Service de Gynécologie - Obstétrique et médecine de la reproduction [Caen] CHU Caen , bâtiment FEH, avenue de la Côte-de-Nacre, 14033 Caen cedex 9,FR

¹⁴ Service de gynécologie-obstétrique Assistance publique - Hôpitaux de Paris (AP-HP) , Hôpital Bichat - Claude Bernard , Université Paris VII - Paris Diderot , FR

* Correspondence should be addressed to: Loïc Sentilhes <loicsentilhes@hotmail.com >

Abstract

Objective

To estimate the fertility and pregnancy outcomes after successful conservative treatment for placenta accreta.

Methods

This retrospective national multicenter study included women with a history of conservative management for placenta accreta in French university hospitals from 1993 through 2007. Success of conservative treatment was defined by uterine preservation. Data were retrieved from medical files and telephone interviews.

Results

Follow-up data were available for 96 (73.3%) of the 131 women included in the study. Eight women had severe intrauterine synechiae and were amenorrheic. Of the 27 women who wanted more children, three women were attempting to become pregnant (mean duration: 11.7 months, range: 7–14 months), and 24 (88.9% [95% CI, 70.8–97.6%]) women had had 34 pregnancies (21 third-trimester deliveries, one ectopic pregnancy, two elective abortions, and 10 miscarriages) with a mean time to conception of 17.3 months (range, 2–48 months). All 21 deliveries resulted in healthy babies born after 34 weeks of gestation. Placenta accreta recurred in 6 of 21 cases (28.6% [95% CI, 11.3–52.2%]) and was associated with placenta previa in 4 cases. Postpartum hemorrhage occurred in four (19.0% [95% CI, 5.4–41.9%]) cases, related to placenta accreta in three and to uterine atony in one.

Conclusions

Successful conservative treatment for placenta accreta does not appear to compromise the patients' subsequent fertility or obstetric outcome. Nevertheless, these women should be advised of the high risk that placenta accreta may recur during future pregnancies.

MESH Keywords Adult ; Female ; Fertility ; Gynatresia ; etiology ; Humans ; Placenta Accreta ; therapy ; Postpartum Hemorrhage ; etiology ; surgery ; Pregnancy ; Pregnancy Outcome ; Retrospective Studies ; Treatment Outcome

Author Keywords Placenta accreta or percreta ; conservative treatment ; embolization ; fertility ; pregnancy.

INTRODUCTION

Placenta accreta is a life-threatening condition characterized by placental villi abnormally adherent to the myometrium due to the absence or defects in the normal decidual basalis and the fibrinous Nitabuch layer [1]. In the past 30 years, the rate of placenta accreta has dramatically increased in conjunction with the rate of cesarean deliveries; it now occurs in developed countries at a frequency of 1 per 2,500 and has even been reported as often as 1 per 530 deliveries [2–3]. Placenta accreta has become an important cause of maternal morbidity and mortality and is the leading cause of peripartum hysterectomy [4], failed vessel ligation [5–6], and failed pelvic arterial embolization [7]. The optimal management of placenta accreta remains a topic of debate. The extirpative approach, consisting in forcible manual removal of the placenta, is associated with massive hemorrhage and emergency hysterectomy [8–9]. Therefore, this option should be abandoned [8–9]. The approach most often recommended is a cesarean-hysterectomy, with no attempt to detach the placenta [10–11]. However, hysterectomy makes future childbearing impossible and is associated with significant morbidity in women with placenta accreta or percreta [8, 11]. Recent studies have shown the interest of attempting to preserve the uterus and avoid hysterectomy by leaving part or all of the adherent placenta in utero, thereby maintaining fertility and potentially minimizing complications [9, 11–12]. In a large national multicenter study we recently showed that this conservative treatment preserved the uterus in 78.4% (95% CI, 71.4–84.4%) of women, with a severe maternal morbidity rate of only 6% (95% CI, 2.9–10.7%) [12]. Although one of the main reason for choosing conservative treatment is the strong desire to remain fertile, almost nothing is known about fertility and pregnancy outcome in women who have undergone successful conservative management for placenta accreta [13–14]. The size and follow-up rate of these two small case series are limited, and they provided no information about the women who were presumably still fertile and desired more children but did not become pregnant. The aim of this study was to evaluate the impact on fertility and pregnancy outcome of successful conservative management for placenta accreta.

MATERIALS AND METHODS

This retrospective nationwide multicenter study was approved by our national Ethics Committee (Comité d’Ethique de la Recherche en Obstétrique et Gynécologie). Of 45 obstetrics departments in tertiary hospitals in France, 40 agreed to participate and retrieved data from their databases about women who had successful conservative management for placenta accreta in their department from January 1993 through December 2007. Successful conservative treatment was defined by uterine preservation, i.e., the absence of either immediate or delayed hysterectomy due to placenta accreta. Therefore, women who underwent an immediate or delayed hysterectomy after the conservative treatment were excluded (n=36) [12]. The long-term maternal outcome of several of these women has been reported earlier [9, 13, 15]. We have previously described the diagnosis and management of placenta accreta [12]. Briefly, the clinical criteria for diagnosis were: 1) manual removal of the placenta was partially or totally impossible and there was no cleavage plane between part or all of the placenta and the uterus, and 2) the prenatal diagnosis of placenta accreta was confirmed by the failure of its gentle attempted removal during the third stage of labor. Conservative management followed the obstetrician’s decision to leave the placenta in situ partially or totally, with no attempt to remove it forcibly. At the obstetrician’s discretion and depending on the circumstances and course, additional treatment could include uterotonic drugs (oxytocin and/or sulprostone), prophylactic antibiotic therapy, methotrexate, preoperative ureteric stent placement, balloon catheter occlusion, and uterine devascularization procedures such as pelvic arterial embolization, surgical vessel ligation (uterine and/or hypogastric artery ligation and/or stepwise uterine devascularization), or uterine compression sutures (B-Lynch and Cho sutures). Stepwise uterine devascularization, as previously reported by AbdRabbo [16], consisted of normal and low bilateral uterine artery ligation, followed by bilateral utero-ovarian ligament ligation because of persistent hemorrhage [5–6, 17].

During April and June 2008, one of the authors (C.A.) attempted to contact all the women by telephone to determine the mid- and long-term outcome of conservative treatment. Women were asked about resumption of menses, their desire for subsequent pregnancies, attempts to conceive, and results. Mean time to conception was measured from the date at which the woman decided to attempt conception. Intrauterine synechiae were categorized, in accordance with the American Fertility Society classification, into three stages, that is, mild (stage I), moderate (stage II), and severe (stage III) [18]. Data about subsequent pregnancies came from the medical records or the attending physician. Descriptive characteristics were calculated for the variables of interest. Statistical analysis, including rates with their 95% confidence intervals, used StatXact.4 (Cytel Software Corporation, Cambridge, MA).

RESULTS

Of the 45 French university hospitals, 40 (88.9%) agreed to participate in the study, and 25 had used conservative treatment at least once (range 1–46), treating 167 women. Of the 131 women who had successful conservative management of placenta accreta and were included in the study, 96 (73.3%) women were successfully contacted at follow-up (range, 2–172 months) (Figure 1). Follow-up information about the subsequent outcome of the placenta was available for 88 of these 96 (91.7%) women. In 75 (85.2%) cases,

spontaneous placental resorption occurred, while hysteroscopic resection or curettage or both were used to remove the retained placenta in 13 cases (14.8%).

Of the 96 women successfully contacted at follow-up, 88 had resumed menstruation. Severe intrauterine synechiae (stage III) were identified during ambulatory hysteroscopy in the eight women with amenorrhea. One of these eight women declined further treatment; hysteroscopic treatment of the synechiae was successful for six of the seven (Figure 1). Twelve other women, five complaining of decreased menstrual flow, and seven for routine reasons, also underwent outpatient hysteroscopy, which was normal in all cases. Nine non-amenorrheic women had voluntarily undergone ligation of fallopian tubes, so that only 85 (89.5%) women in this study remained fertile (Figure 1).

Of these 85 women, 58 (68.3% [95% CI, 57.2–77.9%]), including the six women for whom severe intrauterine synechiae were successfully treated, did not want to become pregnant, at least in part because either the obstetrician 32.8% (19/58) [95% CI, 21.0–46.3%] and or the woman herself (22.4% (13/58) [95% CI, 12.5–35.3%]) feared a recurrence of placenta accreta (Figure 1).

None of the 27 women who wanted another pregnancy have thus far required an assisted reproductive procedure. Three women are currently trying to become pregnant (mean duration of attempt: 11.7 months, range, 7–14 months), whereas 24 (88.9% [95% CI, 70.8–97.6 %]) women had already had 34 spontaneous pregnancies, with a mean time to conception of 17.3 months (range, 2–48 months). Five (18.5%) women took more than 24 months to become pregnant (women 4, 7, 8, 12, 14) (Table 1): one had a history of pregnancy following conservative treatment with a time to conception of 12 months (woman 12) (Table 1), two had a history of infertility requiring assisted reproductive procedures, and two women had a history of at least one pregnancy with a time to conception of more than 24 months. Of these 34 pregnancies, 21 ended after 34 weeks' gestation, while 13 ended during the first trimester of pregnancy: two elective abortions (one due to the fear that placenta accreta would recur), one ectopic pregnancy treated by salpingotomy, and ten miscarriages, one complicated by a hemorrhage treated successfully by oxytocin (Figure 1).

Table 1 summarizes the characteristics of the 21 pregnancies delivered during the third trimester. Eighteen women gave birth to 21 healthy singletons. Only one had a low birth weight for gestational age (case 15) (see below). Delivery was moderately preterm for four (19.0% [95% CI, 5.4–41.9%]), because of preeclampsia associated with intrauterine growth restriction in a woman with a history of preeclampsia (case 15), bleeding in a woman with placenta previa (case 8), premature rupture of membranes (case 6), and elective cesarean in a woman with suspected placenta accreta (case 5).

Placenta accreta recurred in 6 of 21 cases (28.6% [95% CI, 11.3–52.2%]) and was associated with placenta previa in 4 cases. In four of these six cases, the placenta accreta was managed successfully by conservative treatment, in one case by a cesarean and hysterectomy, and in one case by unsuccessful extirpative treatment followed by a peripartum hysterectomy (Table 1). Postpartum hemorrhage occurred in four (19.0% [95% CI, 5.4–41.9%]) women, related to placenta accreta in three cases and to uterine atony in one.

DISCUSSION

Placenta accreta is thought to be due to an absence or deficiency of Nitabuch's layer or the decidua spongiosa, following the failure of the endometrium/decidua basalis to re-form after trauma to the endometrium from surgical procedures [19]. The pathophysiology of placenta accreta is therefore similar to that of intrauterine synechiae, based as it is on endometrial alteration that might promote abnormal implantation, resulting in infertility, miscarriage, or recurrent placenta accreta [19]. Hypothetically, conservative treatment might worsen the endometrial disease, due to more uterine scars (i.e., by cesarean), uterine devascularization procedures (i.e., embolization or surgical vessel ligation), or clinical or subclinical uterine infection. Our results are therefore reassuring and suggest that successful conservative treatment for placenta accreta does not appear to compromise the patients' subsequent fertility or obstetric outcome, but that the risk of placenta accreta recurrence during future deliveries is high.

However, we found severe intrauterine synechiae, known to affect fertility adversely, in the eight women who did not resume menstruation among the 96 women followed up after successful conservative treatment. Fertility was clearly altered in the two women for whom synechiae were not removed. Fertility outcome could not be determined for the remaining six women whose severe synechiae were successfully treated, because none wanted another child. This relatively high rate of synechiae following placenta accreta is consistent with a previous smaller and more limited study that suggested that placenta accreta might be a risk factor for synechiae [20]. Moreover, the frequency of intrauterine synechia in the group presumed fertile is probably underestimated: mild or moderate synechiae are frequently asymptomatic, and hysteroscopy was not performed routinely for women after conservative treatment. Subclinical synechiae or endometrial diseases may be one of the factors responsible for the high number of miscarriages observed in our study (10 for 34 pregnancies) and may result in implantation failure.

The 21 subsequent third-trimester pregnancies resulted in 21 healthy babies, with normal birth weight for age, except for one whose mother had current and past preeclampsia. The absence of pregnancy complications observed in our study, except for abnormal placentation and postpartum hemorrhage, is consistent with the few previous reports on pregnancy after conservative treatment for placenta accreta [13–15].

Moreover, no adverse neonatal outcome was observed in women who underwent additional embolization or vessel ligation (n=7) with the conservative treatment. This result is also consistent with the literature, as previous reports suggest that neither vessel ligation [5, 21] nor pelvic arterial embolization [20, 22] compromises subsequent obstetric outcome. Although neonatal outcome was favorable for all the pregnancies, the recurrence rate of placenta accreta was high (28.6%). This result is consistent with the literature review performed by Alanis *et al.* [14]. The high rate of recurrence is not surprising, for all the women had acquired risk factors for abnormal placentation that resulted in the history of placenta accreta required for inclusion in this study. Furthermore, still other risk factors for placenta accreta (age > 35 years, additional cesarean delivery, previous history of placenta accreta) were added to the previous ones. We cannot rule out the possibility that this high rate of recurrent placenta accreta was also related, at least in part, to the uterine devascularization procedures performed as part of the conservative treatment. It has been suggested that implantation and trophoblast invasion in subsequent pregnancies may be modified in a uterus previously devascularized, either by stepwise uterine devascularization [5] or pelvic arterial embolization [20–21]. Nevertheless, interestingly, in our study, placenta accreta recurred in only 2 of the 7 women who had undergone an additional uterine devascularization procedure concomitantly with the previous conservative treatment.

We might speculate that relatively few parous women who have undergone conservative treatment and therefore also close monitoring for several months would want another child, especially in view of the potential risk of another episode of placenta accreta. Our study shows that this percentage is not that low (31.7%; 27/85). It is even higher (36.5%; 27/74) if we do not consider the women who reported it was too soon after their last delivery to become pregnant again (n=11). Interestingly, the primary reason that women decided against another pregnancy was that their obstetrician strongly recommended against it. Nevertheless, the second leading reason was the woman's own fear of a recurrence of placenta accreta. Four earlier studies report similar results: women with a history of severe postpartum hemorrhage requiring pelvic arterial embolization and/or uterine-sparing surgical procedures are likely to decide against another pregnancy because of their fear of another hemorrhage [5, 20–22]. Several limitations of our study must be underlined. The first is its retrospective design, common to all studies that have thus far assessed maternal outcome after placenta accreta. Accordingly, all the flaws of retrospective analyses apply. In particular, some eligible cases may not have been detected. Second, 26.7% of eligible women were lost to follow-up during this 15-year period study. Third, it is possible that some women did not actually have placenta accreta; pathological confirmation is of course impossible after successful conservative treatment, i.e., in cases without a hysterectomy specimen [12]. Nevertheless, our results reflect the long-term consequences in real life of conservative treatment for placenta accreta. In conclusion, our study suggests that successful conservative treatment for placenta accreta does not appear to compromise the patients' subsequent fertility or obstetric outcome. Women who want another pregnancy should, however, be advised that the risk of recurrence is high.

List of all participating centers in alphabetical order with collaborators (number of cases included in the study are in parentheses)

CHU d'Angers: Dr. Sentilhes, Dr. Gillard, Dr. Catala and Pr. Descamps. CHU d'Amiens: Pr. Gondry and Dr. Mamy. CHU de Besançon: Pr. Riethmuller and Dr. Broche. CHU de Bordeaux: Pr. Horowitz and Pr. Lebrun. CHU de Brest: Pr. Collet. CHU de Caen: Pr. Dreyfus. CHU de Clamart: Pr. Fernandez and Dr. Faivre. CHU de Clermont-Ferrand (Polyclinique-Hôtel-Dieu): Pr. Mage. CHU de Colombes: Pr. Mandelbrot. CHU de Dijon: Pr. Sagot. CHU de Grenoble: Pr. Schaal. CHU de Kremlin-Bicêtre: Pr. Fernandez. CHU de Lille: Pr. Deruelle. CHU de Limoges: Pr. Aubart. CHU de Lyon (Hospices Civils de Lyon): Pr. Gaucherand. CHU de Lyon (Lyon Sud): Pr. Raudrant and Pr. Dupuis. CHU de Marseille: Pr. Bretelle, Dr. Provansal, Pr. D'Ercole, Pr. Boubli and Pr. Gamerre. CHU de Montpellier: Pr. Boulot. CHU de Nancy: Dr. Barbier and Pr. Judlin. CHU de Nantes: Dr. Winer. CHU de Nîmes: Pr. Mares and Pr. De Tayrac. CHU de Nice: Pr. Bongain and Dr. Delotte. Paris (Maternité de Port-Royal): Dr. Kayem and Pr. Goffinet. Paris (Hôpital Necker-Enfants Malades): Dr. Benachi. Paris (Hôpital Bichat Claude-Bernard): Pr. Mahieu-Caputo. Paris (Hôpital de la Pitié-Salpêtrière): Dr. Fortin and Pr. Dommergues. Paris (Hôpital St-Antoine): Pr. Carbonne. Paris (Hôpital Tenon): Dr. Berkane and Pr. Uzan. Paris (Hôpital Beaujon): Dr. Ducarme and Pr. Luton. Paris (Hôpital Robert-Debré): Pr. Oury. Paris (Hôpital St Vincent de Paul): Pr. Lepercq. Paris (Hôpital Trousseau): Pr. Benifla. CHU de Poitiers: Pr. Pierre and Dr. Boileau. CHU de Rennes: Dr. Bauville and Pr. Poulain. CHU de Rouen: Dr. Sentilhes, Dr. Resch, Pr. Verspyck and Pr. Marpeau. CHU de St-Etienne: Dr. Chauleur and Pr. Seffert. CHU de Strasbourg: Pr. Langer. CHU de Toulouse: Dr. Parant and Pr. Vayssi  re. CHU de Tours: Dr. Benabu-Saada and Pr. Perrotin.

References:

1. Tseng JJ, Hsu SL, Wen MC, Ho ES, Chou MM. Expression of epidermal growth factor receptor and c-erbB-2 oncoprotein in trophoblast populations of placenta accreta. *Am J Obstet Gynecol*. 2004; 191: 2106–13.
2. Wu S, Kocherginsky M, Hibbard JU. Abnormal placentation: twenty-year analysis. *Am J Obstet Gynecol*. 2005; 192: 1458–61.
3. Miller DA, Chollet JA, Goodwin TM. Clinical risk factors for placenta previa-placenta accreta. *Am J Obstet Gynecol*. 1997; 177: 210–4.
4. Daskalakis G, Anastasakis E, Papantoniou N, Mesogitis S, Theodora M, Antsaklis A. Emergency obstetric hysterectomy. *Acta Obstet Gynecol Scand*. 2007; 86: 223–227.

- 5 . Sentilhes L , Trichot C , Resch B , Sergent F , Roman H , Marpeau L , Verspyck E . Fertility and pregnancy outcomes following uterine devascularization for postpartum haemorrhage . *Hum Reprod* . 2008 ; 23 : 1087 - 92
- 6 . Sentilhes L , Gromez A , Descamps P , Marpeau L . Why stepwise uterine devascularization should be the first-line conservative surgical treatment to control severe postpartum hemorrhage? . *Acta Obstet Gynecol Scand* . 2009 ; 88 : 490 - 2
- 7 . Sentilhes L , Gromez A , Clavier E , Resch B , Verspyck E , Marpeau L . Predictors of failed pelvic arterial embolization for severe postpartum hemorrhage . *Obstet Gynecol* . 2009 ; 113 : 99 - 9
- 8 . Eller AG , Porter TF , Soisson P , Silver RM . Optimal management strategies for placenta accreta . *BJOG* . 2009 ; 116 : 648 - 54
- 9 . Kayem G , Davy C , Goffinet F , Thomas C , Clement D , Cabrol D . Conservative versus extirpative management in cases of placenta accreta . *Obstet Gynecol* . 2004 ; 104 : 531 - 6
- 10 . American College of Obstetricians and Gynecologists . ACOG committee opinion. Placenta accreta. No 266, Jan 2002 . *Int J Gynecol Obstet* . 2002 ; 77 : 77 - 8
- 11 . Oyelese Y , Smulian JC . Placenta previa, placenta accreta, and vasa previa . *Obstet Gynecol* . 2006 ; 107 : 927 - 41
- 12 . Sentilhes L , Ambroselli C , Kayem G , Provansal M , Fernandez H , Perrotin F , Winer N , Pierre F , Benachi A , Dreyfus M , Poulain P , Mahieu-Caputo D , Marpeau L , Descamps P , Goffinet F , Bretelle F . Maternal outcome after conservative treatment for placenta accreta . *Obstet Gynecol* . 2010 ; 115 : 526 - 34
- 13 . Kayem G , Pannier E , Goffinet F , Grange G , Cabrol D . Fertility after conservative treatment of placenta accreta . *Fertil Steril* . 2002 ; 78 : 637 - 8
- 14 . Alanis M , Hurst BS , Marshburn PB , Matthews ML . Conservative management of placenta increta with selective arterial embolization preserves future fertility and results in a favorable outcome in subsequent pregnancies . *Fertil Steril* . 2006 ; 86 : 1514.e3 - 7
- 15 . Bretelle F , Courbiere B , Mazouni C , Agostini A , Cravello L , Boubli L , Gamarre M , D'Ercole C . Management of placenta accreta: morbidity and outcome . *Eur J Obstet Gynecol Reprod Biol* . 2007 ; 133 : 34 - 9
- 16 . AbdRabbo S . Stepwise uterine devascularization: a novel technique for management of uncontrollable postpartum hemorrhage with preservation of the uterus . *AJOG* . 1994 ; 171 : 694 - 700
- 17 . Sentilhes L , Gromez A , Razzouk K , Resch B , Verspyck E , Marpeau L . B-Lynch suture for massive persistent postpartum hemorrhage following stepwise uterine devascularization . *Acta Obstet Gynecol Scand* . 2008 ; 87 : 1020 - 6
- 18 . American Fertility Society . Classification of Intrauterine Adhesions . Available at: www.asrm.org/Literature/classifications/intrauterine_adhesions.pdf . Retrieved December 5, 2009
- 19 . Benirschke K , Kaufmann P . Pathology of the human placenta . 4 New York (NY) Springer ; 2000 ;
- 20 . Sentilhes L , Gromez A , Clavier E , Resch B , Verspyck E , Marpeau L . Fertility and pregnancy following pelvic arterial embolisation for postpartum haemorrhage . *BJOG* . 2010 ; 117 : 84 - 93
- 21 . Nizard J , Barrinque L , Frydman R , Fernandez H . Fertility and pregnancy outcomes following hypogastric artery ligation for severe post-partum hemorrhage . *Hum Reprod* . 2003 ; 18 : 844 - 8
- 22 . Salomon LJ , de Tayrac R , Castaigne-Meary V , Audibert F , Musset D , Ciorascu R , Frydman R , Fernandez H . Fertility and pregnancy outcome following pelvic arterial embolization for severe post-partum haemorrhage. A cohort study . *Hum Reprod* . 2003 ; 18 : 849 - 852

Figure 1

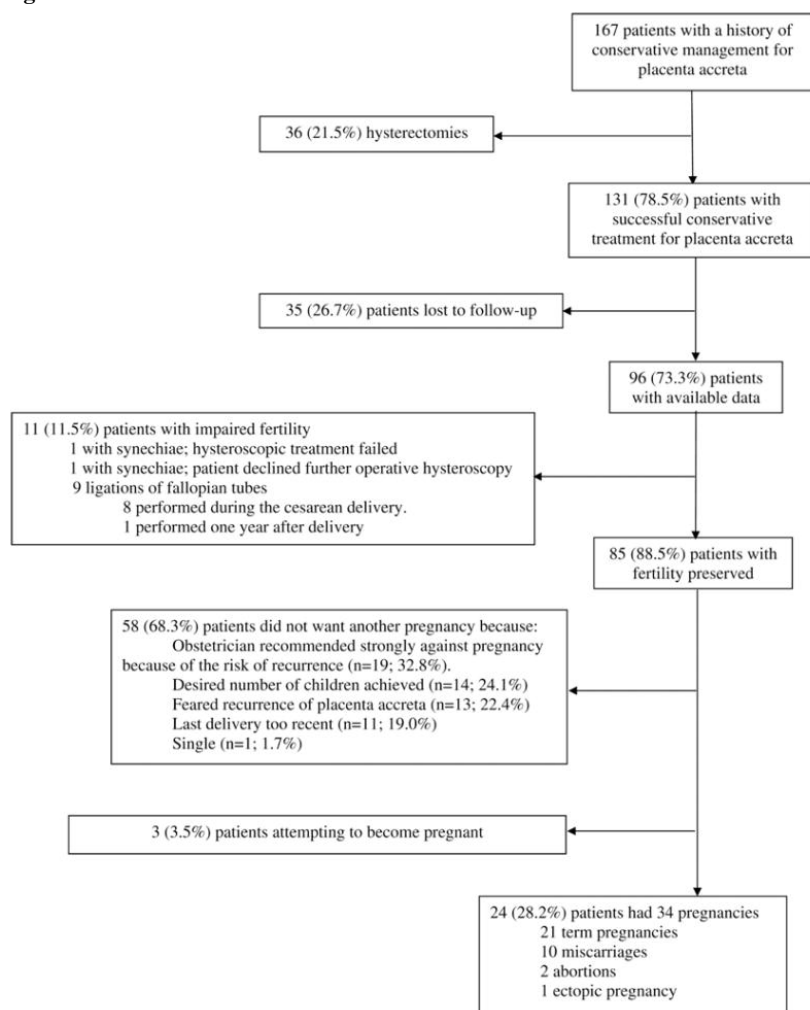


Table I

Demographic and obstetrical characteristics at the first conservative treatment for the women included in the study and those lost to follow-up.

	Women included in the study (<i>n</i> = 96)	Women lost to follow-up (<i>n</i> = 35)	<i>P</i> -value
Demographic characteristics			
Age (years)	33.3 ± 4.6	32.5 ± 5.2	0.38
Geographic origin			0.39
Europe	74 (77.1)	27 (77.1)	
Sub-Saharan Africa	12 (12.5)	7 (20.0)	
North Africa	6 (6.3)	1 (2.9)	
Asia	4 (4.2)	0	
Parity	1 (0–8)	0 (0–5)	0.80
Number of pregnancies	3 (1–12)	3 (1–11)	0.82
Obstetrical characteristics			
Placenta percreta	5 (5.2)	5 (14.3)	0.13
Gestational age at delivery (week)	33.9 ± 5.2	35.0 ± 4.4	0.27
cesarean section	74 (77.1)	29 (82.9)	0.63
Placenta left entirely <i>in situ</i>	35 (36.4)	13 (37.1)	>0.99
Primary post-partum hemorrhage *	41 (42.7)	15 (42.9)	>0.99
Additional uterine devascularization procedure†	66 (68.8)	21 (60.0)	0.40
Transfusion patients	30 (31.2)	9 (25.7)	0.67
Transfer to intensive care unit	15 (15.6)	8 (22.3)	0.44
Infection‡	23 (24.0)	8 (22.3)	>0.99
Severe maternal morbidity§	1 (1.0)	0	>0.99

Data are mean ± SD, *n* (%) or median (range).

* Primary post-partum hemorrhage was defined as bleeding requiring medical or interventional treatment in the 24 h after delivery.

† Uterine devascularization procedure included pelvic arterial embolization, surgical vessel ligation (uterine or hypogastric artery ligation, stepwise uterine devascularization) and/or uterine compression sutures (B-Lynch and Cho sutures).

‡ Infection included endometritis, wound infection, peritonitis, pyelonephritis, vesicouterine fistula, uterine necrosis and isolated post-partum fever higher than 38.5°C for 24 h.

§ Severe maternal morbidity was defined as any of the following: sepsis, septic shock, peritonitis, uterine necrosis, post-partum uterine rupture, fistula, injury to adjacent organs, acute pulmonary edema, acute renal failure, deep vein thrombophlebitis or pulmonary embolism, or maternal death.